

# World Journal of *Gastrointestinal Oncology*

*World J Gastrointest Oncol* 2020 November 15; 12(11): 1216-1380



### ORIGINAL ARTICLE

#### Basic Study

- 1216** Pathological significance of abnormal recepteur d'origine nantaïs and programmed death ligand 1 expression in colorectal cancer  
*Liu YZ, Han DT, Shi DR, Hong B, Qian Y, Wu ZG, Yao SH, Tang TM, Wang MH, Xu XM, Yao HP*
- 1237** Decreased expression of the long non-coding RNA HOXD-AS2 promotes gastric cancer progression by targeting HOXD8 and activating PI3K/Akt signaling pathway  
*Yao L, Ye PC, Tan W, Luo YJ, Xiang WP, Liu ZL, Fu ZM, Lu F, Tang LH, Xiao JW*
- 1255** Programmed death 1, ligand 1 and 2 correlated genes and their association with mutation, immune infiltration and clinical outcomes of hepatocellular carcinoma  
*Sheng QJ, Tian WY, Dou XG, Zhang C, Li YW, Han C, Fan YX, Lai PP, Ding Y*

#### Case Control Study

- 1272** LncRNA C9orf139 can regulate the growth of pancreatic cancer by mediating the miR-663a/Sox12 axis  
*Ge JN, Yan D, Ge CL, Wei MJ*

#### Retrospective Cohort Study

- 1288** Cancer-related microangiopathic hemolytic anemia in patients with advanced gastric cancer: A retrospective single-center analysis  
*Berger AK, Allgäuer M, Apostolidis L, Schulze-Schleithoff AE, Merle U, Jaeger D, Haag GM*
- 1296** Influence of primary tumor location and resection on survival in metastatic colorectal cancer  
*Tharin Z, Blanc J, Charifi Alaoui I, Bertaut A, Ghiringhelli F*

#### Retrospective Study

- 1311** Highly accurate colorectal cancer prediction model based on Raman spectroscopy using patient serum  
*Ito H, Uragami N, Miyazaki T, Yang W, Issha K, Matsuo K, Kimura S, Arai Y, Tokunaga H, Okada S, Kawamura M, Yokoyama N, Kushima M, Inoue H, Fukagai T, Kamijo Y*
- 1325** Subtotal gastrectomy combined with chemotherapy: An effective therapy for patients with circumscribed Borrmann type IV gastric cancer  
*Huang HB, Gao ZM, Sun AQ, Liang WT, Li K*

#### Randomized Controlled Trial

- 1336** Diagnostic value of novel retroflexion colonoscopy in the right colon: A randomized controlled trial  
*Li WK, Wang Y, Wang YD, Liu KL, Guo CM, Su H, Liu H, Wu J*

**META-ANALYSIS**

- 1346** Efficacy and safety of anti-PD-1/anti-PD-L1 antibody therapy in treatment of advanced gastric cancer or gastroesophageal junction cancer: A meta-analysis

*Yang L, Dong XZ, Xing XX, Cui XH, Li L, Zhang L*

**CASE REPORT**

- 1364** Inferior mesenteric arteriovenous fistula during treatment with bevacizumab in colorectal cancer patient: A case report

*Doi A, Takeda H, Umemoto K, Oumi R, Wada S, Hamaguchi S, Mimura H, Arai H, Horie Y, Mizukami T, Izawa N, Ogura T, Nakajima TE, Sunakawa Y*

- 1372** Cutaneous metastases of pancreatic carcinoma to the labia majora: A case report and review of literature

*Shi Y, Li SS, Liu DY, Yu Y*

**ABOUT COVER**

Editorial Board Member of *World Journal of Gastrointestinal Oncology*, Tomohide Hori, PhD, MD, FACS, is an Attending Surgeon at the Affiliated Hospital with Kyoto University (Kyoto, Japan). Dr. Hori obtained his medical doctor license from Tokyo Medical University (Japan) in 1997 and his Doctor of Philosophy degree from Mie University Graduate School of Medicine (Japan) in 2007. Dr. Hori is certified and qualified by many international and domestic societies, including the American College of Surgeons and Japan Society of Endoscopic Surgery. From 2009 to 2011, he worked at Mayo Clinic (Jacksonville, FL, United States). Dr. Hori's research career has spanned the fields of gastroenterology, hepatology, transplant immunology, and gastrointestinal, colorectal, hepatobiliary, pancreatic, transplant and pediatric surgeries, yielding more than 200 medical publications in international journals. (L-Editor: Filipodia)

**AIMS AND SCOPE**

The primary aim of *World Journal of Gastrointestinal Oncology* (WJGO, *World J Gastrointest Oncol*) is to provide scholars and readers from various fields of gastrointestinal oncology with a platform to publish high-quality basic and clinical research articles and communicate their research findings online.

WJGO mainly publishes articles reporting research results and findings obtained in the field of gastrointestinal oncology and covering a wide range of topics including liver cell adenoma, gastric neoplasms, appendiceal neoplasms, biliary tract neoplasms, hepatocellular carcinoma, pancreatic carcinoma, cecal neoplasms, colonic neoplasms, colorectal neoplasms, duodenal neoplasms, esophageal neoplasms, gallbladder neoplasms, etc.

**INDEXING/ABSTRACTING**

The WJGO is now indexed in Science Citation Index Expanded (also known as SciSearch®), PubMed, and PubMed Central. The 2020 edition of Journal Citation Reports® cites the 2019 impact factor (IF) for WJGO as 2.898; IF without journal self cites: 2.880; 5-year IF: 3.316; Ranking: 143 among 244 journals in oncology; Quartile category: Q3; Ranking: 55 among 88 journals in gastroenterology and hepatology; and Quartile category: Q3.

**RESPONSIBLE EDITORS FOR THIS ISSUE**

Production Editor: Jia-Hui Li; Production Department Director: Xiang Li; Editorial Office Director: Jin-Lei Wang.

**NAME OF JOURNAL**

*World Journal of Gastrointestinal Oncology*

**ISSN**

ISSN 1948-5204 (online)

**LAUNCH DATE**

February 15, 2009

**FREQUENCY**

Monthly

**EDITORS-IN-CHIEF**

Rosa M Jimenez Rodriguez, Pashtoon Kasi, Monjur Ahmed

**EDITORIAL BOARD MEMBERS**

<https://www.wjgnet.com/1948-5204/editorialboard.htm>

**PUBLICATION DATE**

November 15, 2020

**COPYRIGHT**

© 2020 Baishideng Publishing Group Inc

**INSTRUCTIONS TO AUTHORS**

<https://www.wjgnet.com/bpg/gerinfo/204>

**GUIDELINES FOR ETHICS DOCUMENTS**

<https://www.wjgnet.com/bpg/GerInfo/287>

**GUIDELINES FOR NON-NATIVE SPEAKERS OF ENGLISH**

<https://www.wjgnet.com/bpg/gerinfo/240>

**PUBLICATION ETHICS**

<https://www.wjgnet.com/bpg/GerInfo/288>

**PUBLICATION MISCONDUCT**

<https://www.wjgnet.com/bpg/gerinfo/208>

**ARTICLE PROCESSING CHARGE**

<https://www.wjgnet.com/bpg/gerinfo/242>

**STEPS FOR SUBMITTING MANUSCRIPTS**

<https://www.wjgnet.com/bpg/GerInfo/239>

**ONLINE SUBMISSION**

<https://www.f6publishing.com>



## Inferior mesenteric arteriovenous fistula during treatment with bevacizumab in colorectal cancer patient: A case report

Ayako Doi, Hiroyuki Takeda, Kumiko Umemoto, Ryosuke Oumi, Shinji Wada, Shingo Hamaguchi, Hidefumi Mimura, Hiroyuki Arai, Yoshiki Horie, Takuro Mizukami, Naoki Izawa, Takashi Ogura, Takako Eguchi Nakajima, Yu Sunakawa

**ORCID number:** Ayako Doi 0000-0003-3140-2654; Hiroyuki Takeda 0000-0002-2847-7105; Kumiko Umemoto 0000-0001-8698-3893; Ryosuke Oumi 0000-0001-8071-828X; Shinji Wada 0000-0001-7172-1508; Shingo Hamaguchi 0000-0003-0354-417X; Hidefumi Mimura 0000-0002-5205-6394; Hiroyuki Arai 0000-0001-5447-4197; Yoshiki Horie 0000-0001-5568-6562; Takuro Mizukami 0000-0002-9960-5629; Naoki Izawa 0000-0003-3653-5325; Takashi Ogura 0000-0002-6326-9993; Takako Eguchi Nakajima 0000-0002-4589-2335; Yu Sunakawa 0000-0002-0163-7543.

**Author contributions:** Doi A was the patient's medical oncologist, reviewed the literature, and contributed to manuscript drafting; Takeda H, Umemoto K, Arai H, Horie Y, Mizukami T, Izawa N, Ogura T, Nakajima TE, and Sunakawa Y reviewed the literature and contributed to manuscript drafting; Oumi R was the gastroenterology disease consultation, reviewed the literature, and drafted the manuscript; Wada S, Hamaguchi S, and Mimura H interpreted the imaging findings and contributed to manuscript drafting; All authors issued final approval for the version to be submitted.

**Informed consent statement:**

Ayako Doi, Hiroyuki Takeda, Kumiko Umemoto, Hiroyuki Arai, Yoshiki Horie, Takuro Mizukami, Naoki Izawa, Takashi Ogura, Yu Sunakawa, Department of Clinical Oncology, St. Marianna University School of Medicine, Kanagawa 216-8511, Japan

Ryosuke Oumi, Department of Gastroenterology, St. Marianna University School of Medicine, Kanagawa 216-8511, Japan

Shinji Wada, Shingo Hamaguchi, Hidefumi Mimura, Department of Radiology, St. Marianna University School of Medicine, Kanagawa 216-8511, Japan

Takako Eguchi Nakajima, Innovation Center for Next Generation Clinical Trials and iPS Cell Therapy, Kyoto University Hospital, Kyoto 606-8507, Japan

**Corresponding author:** Yu Sunakawa, PhD, Associate Professor, Department of Clinical Oncology, St. Marianna University School of Medicine, 2-16-1, Sugao, Miyamae-ku, Kawasaki, Kanagawa 216-8511, Japan. [y.sunakawa@marianna-u.ac.jp](mailto:y.sunakawa@marianna-u.ac.jp)

### Abstract

#### BACKGROUND

Fistula formation is a severe adverse event related to antiangiogenic agents such as bevacizumab and inferior mesenteric arteriovenous fistula (IMAVF) is a result of acquired factor, especially colon surgery. However, IMAVF occurs very rarely and there are few reports in patients during chemotherapy. We report a case of a patient who developed IMAVF during treatment with bevacizumab in metastatic colorectal cancer (mCRC) after colon surgery.

#### CASE SUMMARY

An 81-year-old man was diagnosed with descending colon cancer and underwent left hemicolectomy without any complications. He was definitely diagnosed with high-risk stage 2 and received tegafur-uracil plus leucovorin as adjuvant chemotherapy. Three years and 6 mo after the operation, the cancer relapsed with peritoneal dissemination. The patient underwent CyberKnife radiosurgery targeting the recurrent tumor and received chemotherapy with S-1 plus bevacizumab. At 1 year after chemotherapy, he complained of severe diarrhea, which is suspected drug-induced colitis. As diarrhea worsened despite the termination of treatment, he underwent colonoscopy and computed tomography



Informed written consent was obtained from the patient for publication of this report and any accompanying images.

**Conflict-of-interest statement:** All authors have declared no conflicts of interest.

**CARE Checklist (2016) statement:** The authors have read the CARE Checklist (2016), and the manuscript was prepared and revised according to the CARE Checklist (2016).

**Open-Access:** This article is an open-access article that was selected by an in-house editor and fully peer-reviewed by external reviewers. It is distributed in accordance with the Creative Commons Attribution NonCommercial (CC BY-NC 4.0) license, which permits others to distribute, remix, adapt, build upon this work non-commercially, and license their derivative works on different terms, provided the original work is properly cited and the use is non-commercial. See: <http://creativecommons.org/licenses/by-nc/4.0/>

**Manuscript source:** Unsolicited manuscript

**Specialty type:** Oncology

**Country/Territory of origin:** Japan

**Peer-review report's scientific quality classification**

Grade A (Excellent): 0  
Grade B (Very good): 0  
Grade C (Good): C  
Grade D (Fair): 0  
Grade E (Poor): 0

**Received:** June 24, 2020

**Peer-review started:** June 24, 2020

**First decision:** August 9, 2020

**Revised:** August 20, 2020

**Accepted:** September 22, 2020

**Article in press:** September 22, 2020

**Published online:** November 15, 2020

**P-Reviewer:** Jesus-Silva SG

**S-Editor:** Ma YJ

**L-Editor:** Filipodia

**P-Editor:** Li JH

(CT) scans that revealed edematous change from sigmoid to rectosigmoid colon. CT scans also revealed an aneurysm adjacent to the inferior mesenteric vein and multidetector CT angiography showed the IMAVF. Elective angiography confirmed the diagnosis of an IMAVF and it was successfully treated by arterial embolization. The patient resumed chemotherapy with only S-1 6 mo after embolization.

## CONCLUSION

Clinicians should keep in mind the probability of severe diarrhea arose from IMAVF in mCRC patients treated with bevacizumab.

**Key Words:** Metastatic cancer; Colon surgery; Chemotherapy; Fistula formation; Inferior mesenteric artery; Interventional radiology; Case report

©The Author(s) 2020. Published by Baishideng Publishing Group Inc. All rights reserved.

**Core Tip:** Gastrointestinal perforation and fistula formation are s bevacizumab-induced serious adverse events (SAEs). Arteriovenous fistula may occur during bevacizumab treatment *via* the action of antiangiogenetic agent. Inferior mesenteric arteriovenous fistula (IMAVF) arises from acquired factors especially colon surgery, although there has been no report related to chemotherapy including bevacizumab. We report a case of IMAVF in metastatic colorectal cancer (mCRC) during bevacizumab treatment. This patient complained of severe diarrhea caused by ischemic colitis due to IMAVF. As fistula may be lethal complications, clinicians should pay attention to SAEs including IMAVF for mCRC patients during bevacizumab treatment.

**Citation:** Doi A, Takeda H, Umemoto K, Oumi R, Wada S, Hamaguchi S, Mimura H, Arai H, Horie Y, Mizukami T, Izawa N, Ogura T, Nakajima TE, Sunakawa Y. Inferior mesenteric arteriovenous fistula during treatment with bevacizumab in colorectal cancer patient: A case report. *World J Gastrointest Oncol* 2020; 12(11): 1364-1371

**URL:** <https://www.wjgnet.com/1948-5204/full/v12/i11/1364.htm>

**DOI:** <https://dx.doi.org/10.4251/wjgo.v12.i11.1364>

## INTRODUCTION

Angiogenesis is important for cancer proliferation and promotion since blood vessels in tumors supply oxygen and nutrients, which support cancer growth. Vascular endothelial growth factor (VEGF) is a key factor for angiogenesis, promoting new blood vessel formation<sup>[1-3]</sup>. Bevacizumab is a recombinant humanized monoclonal IgG1 antibody that acts as an antiangiogenic drug targeting VEGF-A related to angiogenesis and inhibits the growth of tumor vessels as well as tumor proliferation. Hence, it has survival benefits for patients with metastatic colorectal cancer (mCRC) and is a useful standard therapy not only in the first-line but also for second-line treatment of mCRC<sup>[4-6]</sup>.

Major adverse events (AEs) of bevacizumab include secondary hypertension, wound healing complications, and proteinuria. Practitioners should also be aware of certain rare but fatal bevacizumab-induced AEs such as hemorrhage, thrombosis, gastrointestinal (GI), non-GI perforation, and fistula formation. Although perforation and fistula formation have been reported in various cancers, they have been predominantly observed in GI sites and very rarely in non-GI sites. Non-GI fistula formation has been reported at tracheoesophageal, bronchopleural, biliary, vaginal, renal, and bladder sites in patients treated with bevacizumab; however, few have been observed in patients with mCRC. Alternative drugs for mCRC targeting angiogenesis include aflibercept, ramucirumab, and regorafenib. The incidence of fistula formation during treatment with antiangiogenetic agents ranged from less than 1% to 1.5% across previous phase III clinical trials of mCRC, specifically 0.9% (6/694) during bevacizumab treatment<sup>[6]</sup>, 1.5% (9/611) during aflibercept treatment<sup>[7]</sup>, 0.8% (4/529) during ramucirumab treatment<sup>[8]</sup>, and 0.4% (2/500) during regorafenib treatment<sup>[9]</sup>.

To inform clinicians of the possibility of this rare AE, we herein report a patient who



developed an inferior mesenteric arteriovenous fistula (IMAVF) during bevacizumab treatment.

## CASE PRESENTATION

### Chief complaints

An 81-year-old man complained of frequent diarrhea more than 10 times per day without bleeding and abdominal pain. The patient's symptom started 1 year after the start of palliative chemotherapy with S-1 plus bevacizumab. The diarrhea worsened progressively, and we suspected S-1-induced AE. However, despite the termination of treatment for 1 mo, severe diarrhea did not improve; therefore, a careful investigation was conducted into the cause of the serious adverse event (SAE).

### History of present illness

The patient was diagnosed with descending colon cancer and underwent laparoscopic left hemicolectomy without any complications at 5 years prior to this report. However, he was later pathologically diagnosed with high-risk stage 2 descending colon cancer with venous and lymph duct invasion for which he received tegafur-uracil plus leucovorin for 6 mo as an adjuvant chemotherapy. At 3 years and 6 mo after the operation, the cancer relapsed with peritoneal dissemination in front of the left kidney. Stereotactic CyberKnife radiosurgery targeting the limited margin of the recurrent tumor resulting in tumor shrinkage, and the patient went onto palliative chemotherapy with S-1 plus bevacizumab for the remaining tumors.

### History of past illness

He underwent surgery for appendicitis in his 20s and received *Helicobacter pylori* eradication therapy for gastric ulcer in his 80s.

### Physical examination

The patient's temperature was 36.5 °C, heart rate was 86 beats per min, respiratory rate was 18 breaths per min, blood pressure was 122/71 mmHg, and oxygen saturation in room air was 98%. In clinical abdominal examination, his abdomen was soft, flat with spontaneous pain and tenderness in the left lower quadrant.

### Laboratory examinations

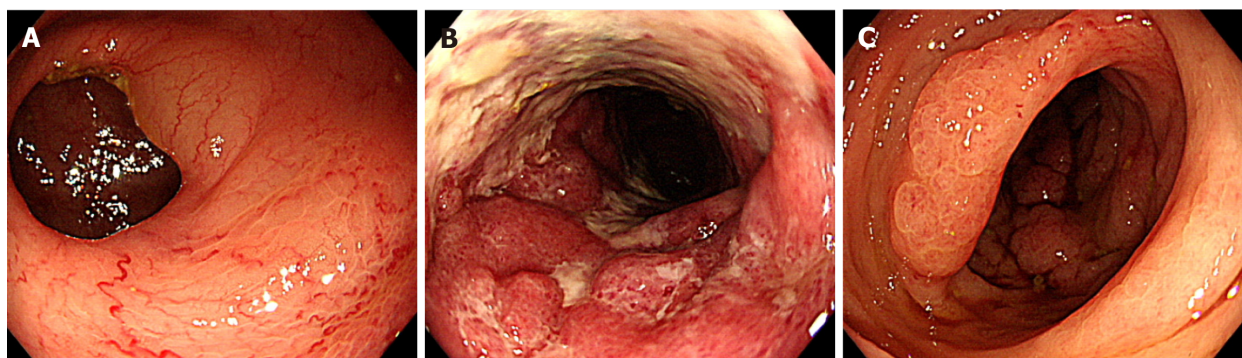
Laboratory test results were almost normal. Blood analysis revealed that hemoglobin and hematocrit were slightly decreased at 12.2 g/dL and 37.0%, respectively, with normal leukocyte and platelet count. Prothrombin percentage activity was slightly decreased at 71% with normal activated partial thromboplastin time and d-dimers were slightly increased at 0.9 µg/mL. Serum C-reactive protein was slightly increased at 1.58 mg/dL (normal range < 0.3 mg/dL) and erythrocyte sedimentation rate at 21 mm/h. The blood biochemistries were almost normal. Urine analysis revealed mild proteinuria at 50 mg/dL. Chest X-ray was normal and electrocardiogram showed QT prolongation without clinical importance.

### Imaging examinations

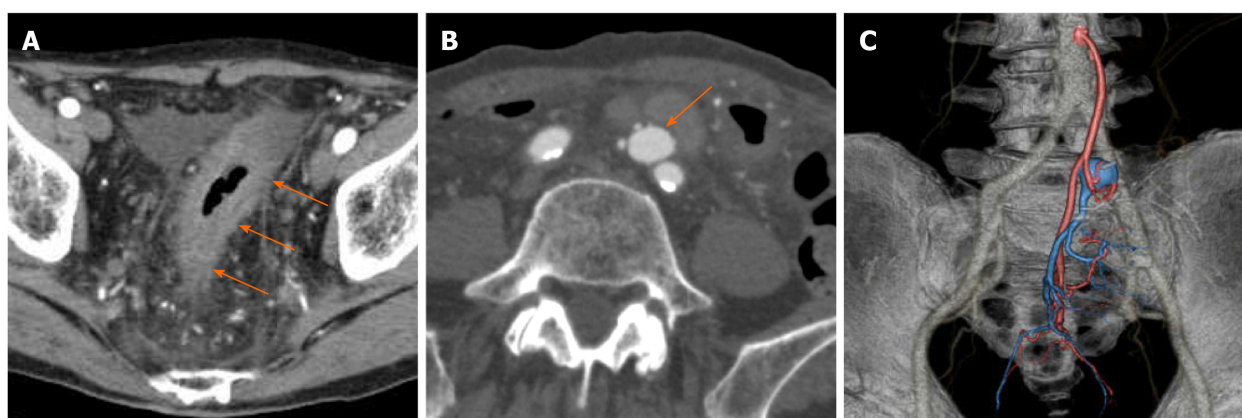
Colonoscopy showed abnormal colonic edematous mucosa with multiple ulcers stretching from the sigmoid colon (distal to the anastomotic site) to the rectosigmoid colon (Figure 1). Abdominal contrast-enhanced computed tomography (CT) scans revealed edematous change from the sigmoid colon to the rectum and a 1.8 cm × 1.3 cm aneurysm adjacent to the inferior mesenteric vein (IMV) (Figure 2A and B). Multidetector CT (MDCT) angiography showed the arteriovenous fistula with nidus involving the branches of the inferior mesenteric artery (IMA) and IMV (Figure 2C). An elective angiography of the IMA confirmed the existence of an IMAVF and defined several shunting points of the fistula from the branch of the IMA (Figure 3A and B).

## FINAL DIAGNOSIS

The final diagnosis of the presented case was IMAVF with ischemic colitis.



**Figure 1** Colonoscopy showed abnormal colonic edematous mucosa with multiple ulcers from the sigmoid colon, distal to the anastomotic site, to the rectosigmoid colon and rectum below the peritoneal reflection. A: Mild inflammation in the anastomotic site; B: Severe inflammation with multiple ulcers and edematous mucosa in the sigmoid colon; C: Rectum below the peritoneal reflection with almost normal findings.



**Figure 2** Abdominal contrast-enhanced computed tomography at 5 year after left hemicolectomy and at 1 year after the start of palliative chemotherapy. A: Computed tomography (CT) showed edematous change from the sigmoid colon to the rectum (triple arrow); B: An aneurysm adjacent to the inferior mesenteric vein (IMV) (arrow); C: Multidetector CT angiography (three-dimensional volume-rendered image) showed the arteriovenous fistula with nidus involving the branches of the inferior mesenteric artery and IMV.

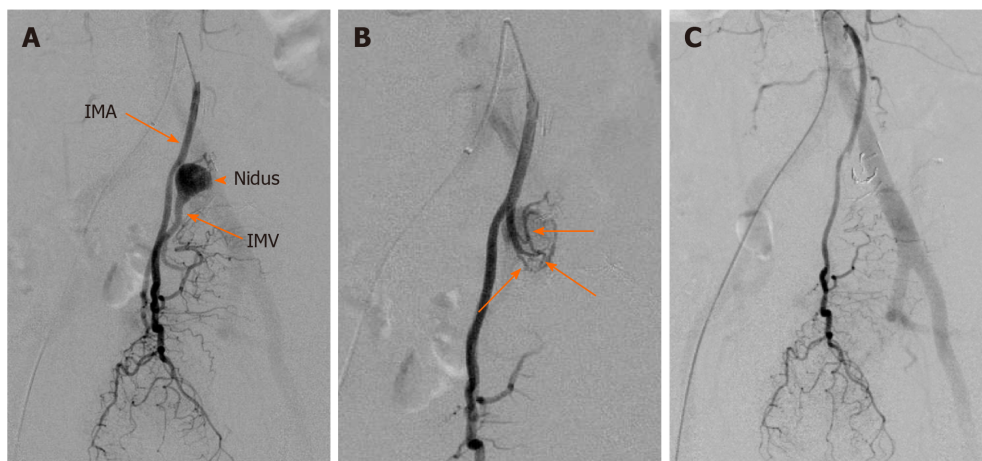
## TREATMENT

This diagnosis was followed by treatment with interventional radiology (IR) on the same day. Abdominal angiography revealed that four small feeding arteries from the branch of the IMA were involved in AVF. Interventional radiologists judged that this case was candidate for transcatheter arterial embolization (TAE). TAE was performed by using detachable micro coils with 2 mm in diameter through the microcatheter, which was utilized to access the AVF. We did not use a liquid agent because there was a risk of rectal ischemia by accidental embolization of the superior rectal artery distal to AVF. Treatment succeeded without any complications and the AVF completely disappeared (Figure 3C).

## OUTCOME AND FOLLOW-UP

Twelve days after fistula embolization, the patient's symptom improved, and CT findings indicated an improvement in the edematous change of the colon. Reattempt colonoscopy also showed improvement of the colonic edematous mucosa. At 6 mo after the procedure, the patient recovered and resumed palliative chemotherapy with only S-1. He has continued the same treatment without any complications as of June 2020.





**Figure 3 An elective angiography of the inferior mesenteric artery.** A: Angiography revealed the nidus of fistula supplied by the inferior mesenteric artery (IMA) (arrow head); B: Several shunting points of the fistula from the branch of the IMA (arrows), which confirmed the existence of an inferior mesenteric arteriovenous fistula (IMAVF); C: The IMAVF completely disappeared after arterial embolization. IMV: Inferior mesenteric vein.

## DISCUSSION

Previous studies<sup>[10,11]</sup> have reported the risk factors for GI perforation or fistula formation, which induce several types of cancer such as colorectal, ovarian, or renal cell cancer, as well as untreated primary tumor, colorectal surgery, abdominal irradiation, and chemotherapy-induced colitis. More than once surgery, irradiation, peritoneal dissemination, and cancer infiltration of the digestive tract were shown to be particularly high-risk factors<sup>[10,11]</sup>. The average period for the development of perforation or fistula formation after the start of treatment with bevacizumab was around 15 wk in several studies<sup>[11,12]</sup>. Most fistula formation occurs as a rectoperineal or colovesical fistulae in GI sites<sup>[12]</sup>, while an AVF in CRC is extremely rare.

We report a case in which a patient with CRC developed an IMAVF during cancer treatment with bevacizumab after colorectal surgery. AVF including the IMA has been reported in only 35 cases so far. Among them, only seven articles available in the English language reported IMAVF following colorectal surgery from the PubMed database. Four of these patients were males and three females, with a median age of 63 years (range, 59–81 years) (Table 1)<sup>[13–17]</sup>. Most cases received surgical resection of the left colon involving the IMA and IMV. The median interval to diagnosis after the surgery was 5 years, and common symptoms were abdominal pain and GI bleeding. Only three cases of IMAVF have been observed in patients with CRC<sup>[16–18]</sup>. However, there has been no reported case of IMAVF related to chemotherapy, such as treatment with bevacizumab or other antiangiogenic agents.

Angiography is useful for diagnosis of the IMAVF as it provides specific findings such as influent artery dilatation, abnormal blood vessel gathering, and early venous return. Recently, it has been shown that minimally invasive examinations including MR angiography and three- or four-dimensional CT angiography are also effective for diagnosis of IMAVF<sup>[18–20]</sup>. Treatment for the IMAVF includes surgery, IR, or both<sup>[13,14]</sup>. In the previous reported IMAVF cases, about half of the patients underwent surgical treatment or intra-arterial embolization, and only one patient underwent both treatments due to failure of the first embolization treatment<sup>[13–17]</sup>. Recently, IR has become the preferred method of treatment as it is easily repeatable and less invasive. It presents a good option in cases with identified fistula sites or when surgery is difficult due to complications. In the present case, the IMAVF was diagnosed by abdominal MDCT, and the diagnosis was confirmed by angiography. Since the location of the fistula and its feeding vessels were known, the IMAVF was treated by using arterial embolization. However, embolization may cause extensive arterial thrombosis followed by organ ischemia or recurrence in cases with more than one feeding vessel; therefore, it should not be performed in cases where the fistula has developed in a large vessel or has multiple feeding vessels<sup>[13,21]</sup>. In this case, an alternative possible treatment for ischemic colitis is resection of sigmoid colon and part of the rectum that are supplied by the IMA. Surgery may also be required in complications such as rebleeding, intestinal stenosis, or necrosis after IR.

To the best of our knowledge, the current case is the first report of an IMAVF in a patient with CRC who received palliative chemotherapy. The IMAVF occurred at 5

**Table 1 Cases of inferior mesenteric arteriovenous fistula after colorectal surgery**

Ref.	Sex	Age	Surgery	Interval to diagnosis	Symptoms	Treatment
Capron <i>et al</i> <sup>[14]</sup> , 1984	F	60	Colon resection	11 yr	Abdominal pain, Meteorism	Embolization
Peer <i>et al</i> <sup>[15]</sup> , 1989	M	63	Anterior resection of rectum	5 wk	Abdominal pain, Upper GI bleeding	Left colectomy
Pietri <i>et al</i> <sup>[13]</sup> , 1990	M	72	Left colectomy	Unknown	Abdominal mass	Left colectomy
	F	60	Left colectomy	Unknown	Lower GI bleeding	Embolization
Okada <i>et al</i> <sup>[16]</sup> , 2002	F	69	Sigmoidectomy	8 yr	Abdominal mass	Left colectomy
Gorospa <i>et al</i> <sup>[17]</sup> , 2012	M	59	Right hemicolectomy	5 yr	Abdominal pain, Lower GI bleeding, Diarrhea	Embolization, Total colectomy
Current case	M	81	Left hemicolectomy	5 yr	Diarrhea	Embolization

F: Female; GI: Gastrointestinal; M: Male.

years after surgery (similar to the previously reported median time post-surgery) and 1 year after the initiation of bevacizumab treatment, which was later the average period of perforation or fistula formation after bevacizumab treatment initiation<sup>[12-17]</sup>. Also, although irradiation is considered to be a risk factor for perforation or fistula formation, it is unlikely to be the cause of the fistula in this case, because the recurrent site treated with CyberKnife stereotactic radiosurgery was distant from the site of the IMAVF and irradiation was limited to the margin of the tumor.

An AVF could occur due to acquired factors such as the spontaneous rupture of an aneurysm, trauma, or surgery. These are responsible for fistula formation in approximately 60% of cases, whereas 25% of fistula are due to congenital factors such as arteriovenous malformation<sup>[13]</sup>. AVF most often develops in the celiac artery or one of its branches, especially the hepatic artery (45%), or the splenic artery (30%). An IMAVF may cause ischemic colitis by steal syndrome causing a reduction in blood flow supply to the bowel wall because arterial blood directly flows into venous blood<sup>[13,21]</sup>. Several reports have indicated the IMAVF formation after colectomy to hematoma or infection followed by necrosis of the vessel wall with pseudoaneurysm formation, such as vessel injury and ligation, during surgical procedures<sup>[22,23]</sup>. However, the mechanisms by which surgery or chemotherapy with antiangiogenic agent or both treatments cause IMAVF formation remain unclear. The risk of IMAVF formation during treatment with antiangiogenic agent in CRC patients after colorectal surgery has significant implications for clinicians. Most patients with IMAVF complained of symptoms such as abdominal pain and GI bleeding followed by diarrhea<sup>[13-17]</sup>, which overlapped in some cases. These symptoms are very common in mCRC patients due to cancer itself or other drug related adverse events and they are many mCRC patients during treatment with antiangiogenic agent, which is most bevacizumab, after colorectal surgery. Therefore, this is an extremely important case report that clinician need to know. In order to avoid SAEs like this case, we should pay attention to abdominal related symptoms, such as pain, bloody stool and diarrhea, then diagnose and treat a patient as rapidly as possible.

## CONCLUSION

We report on a case of IMAVF to have occurred during bevacizumab treatment in a patient with mCRC after colon surgery. There are many recurrent CRC patients after colon surgery and they routinely receive bevacizumab in clinical practice; however, as this case indicates, clinicians need to pay attention to SAEs related to bevacizumab. Formation of IMAVF and other fistula are potentially lethal complications causing massive bleeding and peritonitis. Accordingly, the clinician should keep in mind the probability of vascular-related AEs, including IMAVF, if patients complain of severe diarrhea during treatment with bevacizumab or other antiangiogenic agents.

## REFERENCES

- 1 **Dvorak HF.** Vascular permeability factor/vascular endothelial growth factor: a critical cytokine in tumor angiogenesis and a potential target for diagnosis and therapy. *J Clin Oncol* 2002; **20**: 4368-4380 [PMID: 12409337 DOI: 10.1200/JCO.2002.10.088]
- 2 **Hicklin DJ, Ellis LM.** Role of the vascular endothelial growth factor pathway in tumor growth and angiogenesis. *J Clin Oncol* 2005; **23**: 1011-1027 [PMID: 15585754 DOI: 10.1200/JCO.2005.06.081]
- 3 **Folkman J.** Tumor angiogenesis: therapeutic implications. *N Engl J Med* 1971; **285**: 1182-1186 [PMID: 4938153 DOI: 10.1056/NEJM197111182852108]
- 4 **Giantonio BJ, Catalano PJ, Meropol NJ, O'Dwyer PJ, Mitchell EP, Alberts SR, Schwartz MA, Benson AB 3rd, Eastern Cooperative Oncology Group Study E3200.** Bevacizumab in combination with oxaliplatin, fluorouracil, and leucovorin (FOLFOX4) for previously treated metastatic colorectal cancer: results from the Eastern Cooperative Oncology Group Study E3200. *J Clin Oncol* 2007; **25**: 1539-1544 [PMID: 17442997 DOI: 10.1200/JCO.2006.09.6305]
- 5 **Kozloff M, Yood MU, Berlin J, Flynn PJ, Kabbinnavar FF, Purdie DM, Ashby MA, Dong W, Sugrue MM, Grothey A; Investigators of the BRiTE study.** Clinical outcomes associated with bevacizumab-containing treatment of metastatic colorectal cancer: the BRiTE observational cohort study. *Oncologist* 2009; **14**: 862-870 [PMID: 19726453 DOI: 10.1634/theoncologist.2009-0071]
- 6 **Saltz LB, Clarke S, Diaz-Rubio E, Scheithauer W, Figuer A, Wong R, Koski S, Lichinitser M, Yang TS, Rivera F, Couture F, Sirzén F, Cassidy J.** Bevacizumab in combination with oxaliplatin-based chemotherapy as first-line therapy in metastatic colorectal cancer: a randomized phase III study. *J Clin Oncol* 2008; **26**: 2013-2019 [PMID: 18421054 DOI: 10.1200/JCO.2007.14.9930]
- 7 **Van Cutsem E, Tabernero J, Lakomy R, Prenen H, Prausová J, Macarulla T, Ruff P, van Hazel GA, Moiseyenko V, Ferry D, McKendrick J, Polikoff J, Tellier A, Castan R, Allegra C.** Addition of aflibercept to fluorouracil, leucovorin, and irinotecan improves survival in a phase III randomized trial in patients with metastatic colorectal cancer previously treated with an oxaliplatin-based regimen. *J Clin Oncol* 2012; **30**: 3499-3506 [PMID: 22949147 DOI: 10.1200/JCO.2012.42.8201]
- 8 **Tabernero J, Yoshino T, Cohn AL, Obermannova R, Bodoky G, Garcia-Carbonero R, Ciuleanu TE, Portnoy DC, Van Cutsem E, Grothey A, Prausová J, Garcia-Alfonso P, Yamazaki K, Clingan PR, Lonardi S, Kim TW, Simms L, Chang SC, Nasroulah F; RAISE Study Investigators.** Ramucicromab vs placebo in combination with second-line FOLFIRI in patients with metastatic colorectal carcinoma that progressed during or after first-line therapy with bevacizumab, oxaliplatin, and a fluoropyrimidine (RAISE): a randomised, double-blind, multicentre, phase 3 study. *Lancet Oncol* 2015; **16**: 499-508 [PMID: 25877855 DOI: 10.1016/S1470-2045(15)70127-0]
- 9 **Grothey A, Van Cutsem E, Sobrero A, Siena S, Falcone A, Ychou M, Humblet Y, Bouché O, Mineur L, Barone C, Adenis A, Tabernero J, Yoshino T, Lenz HJ, Goldberg RM, Sargent DJ, Cihon F, Cupit L, Wagner A, Laurent D; CORRECT Study Group.** Regorafenib monotherapy for previously treated metastatic colorectal cancer (CORRECT): an international, multicentre, randomised, placebo-controlled, phase 3 trial. *Lancet* 2013; **381**: 303-312 [PMID: 23177514 DOI: 10.1016/S0140-6736(12)61900-X]
- 10 **Hapani S, Chu D, Wu S.** Risk of gastrointestinal perforation in patients with cancer treated with bevacizumab: a meta-analysis. *Lancet Oncol* 2009; **10**: 559-568 [PMID: 19482548 DOI: 10.1016/S1470-2045(09)70112-3]
- 11 **Sliesoraitis S, Tawfik B.** Bevacizumab-induced bowel perforation. *J Am Osteopath Assoc* 2011; **111**: 437-441 [PMID: 21803880]
- 12 **Ganapathi AM, Westmoreland T, Tyler D, Mantyh CR.** Bevacizumab-associated fistula formation in postoperative colorectal cancer patients. *J Am Coll Surg* 2012; **214**: 582-8; discussion 588-90 [PMID: 22321523 DOI: 10.1016/j.jamcollsurg.2011.12.030]
- 13 **Pietri J, Remond A, Reix T, Abet D, Sevestre H, Sevestre MA.** Arterioportal fistulas: twelve cases. *Ann Vasc Surg* 1990; **4**: 533-539 [PMID: 2261320 DOI: 10.1016/S0890-5096(06)60834-0]
- 14 **Capron JP, Gineston JL, Remond A, Lallement PY, Delamarre J, Revert R, Veyssier P.** Inferior mesenteric arteriovenous fistula associated with portal hypertension and acute ischemic colitis. Successful occlusion by intraarterial embolization with steel coils. *Gastroenterology* 1984; **86**: 351-355 [PMID: 6690362]
- 15 **Peer A, Slutski S, Witz E, Abrahmsohn R, Bogokowsky H, Leonov Y.** Transcatheter occlusion of inferior mesenteric arteriovenous fistula: a case report. *Cardiovasc Intervent Radiol* 1989; **12**: 35-37 [PMID: 2496926 DOI: 10.1007/BF02577124]
- 16 **Okada K, Furusyo N, Sawayama Y, Ishikawa N, Nabeshima S, Tsuchihashi T, Kashiwagi S, Hayashi J.** Inferior mesenteric arteriovenous fistula eight years after sigmoidectomy. *Intern Med* 2002; **41**: 543-548 [PMID: 12132522 DOI: 10.2169/internalmedicine.41.543]
- 17 **Gorospe EC, Leggett CL, Sun G.** Inferior mesenteric arteriovenous malformation: an unusual cause of ischemic colitis. *Ann Gastroenterol* 2012; **25**: 165 [PMID: 24714150]
- 18 **Kai K, Sano K, Higuchi K, Uchiyama S, Sueta H, Nanashima A.** A rare case of simultaneous rectal and gastric carcinomas accompanied with inferior mesenteric arterioportal fistula: case report. *Surg Case Rep* 2019; **5**: 82 [PMID: 31102060 DOI: 10.1186/s40792-019-0630-9]
- 19 **Lee S, Chung J, Ahn B, Lee S, Baek S.** Inferior mesenteric arteriovenous fistula. *Ann Surg Treat Res* 2017; **93**: 225-228 [PMID: 29094033 DOI: 10.4174/astr.2017.93.4.225]
- 20 **Cheng L, Zhao R, Guo D, Cai K, Zou K, Yang J, Zhu L.** Inferior mesenteric arteriovenous fistula with nonpulsatile abdominal mass: A case report and a mini-review. *Medicine (Baltimore)* 2017; **96**: e8717 [PMID: 29310345 DOI: 10.1097/MD.00000000000008717]
- 21 **Metcalf DR, Nivatvongs S, Andrews JC.** Ischemic colitis: an unusual case of inferior mesenteric arteriovenous fistula causing venous hypertension. Report of a case. *Dis Colon Rectum* 2008; **51**: 1422-1424 [PMID: 18521673 DOI: 10.1007/s10350-008-9377-2]
- 22 **Rossi P, Carillo FJ, Alfidi RJ, Ruzicka FF Jr.** Iatrogenic arteriovenous fistulas. *Radiology* 1974; **111**: 47-51 [PMID: 4856165 DOI: 10.1148/111.1.47]

- 23 **Athanasίου A**, Michalinos A, Alexandrou A, Georgopoulos S, Felekouras E. Inferior mesenteric arteriovenous fistula: case report and world-literature review. *World J Gastroenterol* 2014; **20**: 8298-8303 [PMID: 25009407 DOI: 10.3748/wjg.v20.i25.8298]



Published by **Baishideng Publishing Group Inc**  
7041 Koll Center Parkway, Suite 160, Pleasanton, CA 94566, USA

**Telephone:** +1-925-3991568

**E-mail:** [bpgoffice@wjgnet.com](mailto:bpgoffice@wjgnet.com)

**Help Desk:** <https://www.f6publishing.com/helpdesk>

<https://www.wjgnet.com>

