

# World Journal of *Gastrointestinal Oncology*

*World J Gastrointest Oncol* 2020 December 15; 12(12): 1381-1463



### ORIGINAL ARTICLE

#### Retrospective Cohort Study

- 1381** Cholecystectomy reduces subsequent cholangiocarcinoma risk in choledocholithiasis patients undergoing endoscopic intervention

*Wang CC, Tseng MH, Wu SW, Yang TW, Chen HY, Sung WW, Su CC, Wang YT, Lin CC, Tsai MC*

- 1394** Comparison of survival between adolescent and young adult *vs* older patients with hepatocellular carcinoma

*Ren J, Tong YM, Cui RX, Wang Z, Li QL, Liu W, Qu K, Zhang JY, Liu C, Wan Y*

#### Retrospective Study

- 1407** Robotic resection of liver focal nodal hyperplasia guided by indocyanine green fluorescence imaging: A preliminary analysis of 23 cases

*Li CG, Zhou ZP, Tan XL, Wang ZZ, Liu Q, Zhao ZM*

- 1416** Clinicopathological characteristics and prognosis of 77 cases with type 3 gastric neuroendocrine tumours

*Li YL, Qiu XD, Chen J, Zhang Y, Li J, Xu JM, Wang C, Qi ZR, Luo J, Tan HY*

#### Observational Study

- 1428** Outcomes of neoadjuvant chemoradiotherapy followed by radical resection for T4 colorectal cancer

*Huang CM, Huang CW, Ma CJ, Tsai HL, Su WC, Chang TK, Huang MY, Wang JY*

### META-ANALYSIS

- 1443** Prognostic impact of at least 12 lymph nodes after neoadjuvant therapy in rectal cancer: A meta-analysis

*Tan L, Liu ZL, Ma Z, He Z, Tang LH, Liu YL, Xiao JW*

### CASE REPORT

- 1456** Pancreatic mucinous cystadenocarcinoma in a patient harbouring *BRCA1* germline mutation effectively treated with olaparib: A case report

*Di Marco M, Carloni R, De Lorenzo S, Mosconi C, Palloni A, Grassi E, Filippini DM, Ricci AD, Rizzo A, Di Federico A, Santini D, Turchetti D, Ricci C, Ingaldi C, Alberici L, Minni F, Golfieri R, Brandi G, Casadei R*

**ABOUT COVER**

Editorial Board Member of *World Journal of Gastrointestinal Oncology*, Dr. Lin is a distinguished professor at the Hebei Medical University in Shijiazhuang, China. Dr. Lin received his Bachelor's degree from Tianjin Medical University in 1998 and undertook his postgraduate training at Hebei Medical University, receiving his PhD in 2007. He rose to Chief Oncologist in the Department of Oncology, North China Petroleum Bureau General Hospital Affiliated to Hebei Medical University in 2013 and has held the position since. Further, he has served as one of the academic leaders of the five Key Developing Disciplines (Oncology) in Hebei Province since 2017. He also currently serves as Secretary General of the Clinical Committee of Anticancer Drugs, China Pharmaceutical Industry Research and Development Association. His ongoing research interests involve the application of evidence-based medicine in digestive oncology and thoracic oncology. (L-Editor: Filipodia)

**AIMS AND SCOPE**

The primary aim of *World Journal of Gastrointestinal Oncology* (WJGO, *World J Gastrointest Oncol*) is to provide scholars and readers from various fields of gastrointestinal oncology with a platform to publish high-quality basic and clinical research articles and communicate their research findings online.

WJGO mainly publishes articles reporting research results and findings obtained in the field of gastrointestinal oncology and covering a wide range of topics including liver cell adenoma, gastric neoplasms, appendiceal neoplasms, biliary tract neoplasms, hepatocellular carcinoma, pancreatic carcinoma, cecal neoplasms, colonic neoplasms, colorectal neoplasms, duodenal neoplasms, esophageal neoplasms, gallbladder neoplasms, etc.

**INDEXING/ABSTRACTING**

The WJGO is now indexed in Science Citation Index Expanded (also known as SciSearch®), PubMed, and PubMed Central. The 2020 edition of Journal Citation Reports® cites the 2019 impact factor (IF) for WJGO as 2.898; IF without journal self cites: 2.880; 5-year IF: 3.316; Ranking: 143 among 244 journals in oncology; Quartile category: Q3; Ranking: 55 among 88 journals in gastroenterology and hepatology; and Quartile category: Q3.

**RESPONSIBLE EDITORS FOR THIS ISSUE**

Production Editor: Jia-Hui Li; Production Department Director: Xiang Li; Editorial Office Director: Jin-Lei Wang.

**NAME OF JOURNAL**

*World Journal of Gastrointestinal Oncology*

**ISSN**

ISSN 1948-5204 (online)

**LAUNCH DATE**

February 15, 2009

**FREQUENCY**

Monthly

**EDITORS-IN-CHIEF**

Rosa M Jimenez Rodriguez, Pashtoon Kasi, Monjur Ahmed

**EDITORIAL BOARD MEMBERS**

<https://www.wjgnet.com/1948-5204/editorialboard.htm>

**PUBLICATION DATE**

December 15, 2020

**COPYRIGHT**

© 2020 Baishideng Publishing Group Inc

**INSTRUCTIONS TO AUTHORS**

<https://www.wjgnet.com/bpg/gerinfo/204>

**GUIDELINES FOR ETHICS DOCUMENTS**

<https://www.wjgnet.com/bpg/GerInfo/287>

**GUIDELINES FOR NON-NATIVE SPEAKERS OF ENGLISH**

<https://www.wjgnet.com/bpg/gerinfo/240>

**PUBLICATION ETHICS**

<https://www.wjgnet.com/bpg/GerInfo/288>

**PUBLICATION MISCONDUCT**

<https://www.wjgnet.com/bpg/gerinfo/208>

**ARTICLE PROCESSING CHARGE**

<https://www.wjgnet.com/bpg/gerinfo/242>

**STEPS FOR SUBMITTING MANUSCRIPTS**

<https://www.wjgnet.com/bpg/GerInfo/239>

**ONLINE SUBMISSION**

<https://www.f6publishing.com>





## Pancreatic mucinous cystadenocarcinoma in a patient harbouring *BRCA1* germline mutation effectively treated with olaparib: A case report

Mariacristina Di Marco, Riccardo Carloni, Stefania De Lorenzo, Cristina Mosconi, Andrea Palloni, Elisa Grassi, Daria Maria Filippini, Angela Dalia Ricci, Alessandro Rizzo, Alessandro Di Federico, Donatella Santini, Daniela Turchetti, Claudio Ricci, Carlo Ingaldi, Laura Alberici, Francesco Minni, Rita Golfieri, Giovanni Brandi, Riccardo Casadei

**ORCID number:** Mariacristina Di Marco 0000-0002-3470-9494; Riccardo Carloni 0000-0003-2061-5451; Stefania De Lorenzo 0000-0002-4866-4864; Cristina Mosconi 0000-0001-6822-9053; Andrea Palloni 0000-0003-1260-2765; Elisa Grassi 0000-0003-0311-6933; Daria Maria Filippini 0000-0003-3328-7282; Angela Dalia Ricci 0000-0002-0701-6764; Alessandro Rizzo 0000-0002-5257-8678; Alessandro Di Federico 0000-0001-8877-4315; Donatella Santini 0000-0002-1692-6348; Daniela Turchetti 0000-0002-6792-3921; Claudio Ricci 0000-0001-5566-8444; Carlo Ingaldi 0000-0001-7054-145X; Laura Alberici 0000-0002-4339-8894; Francesco Minni 0000-0002-9679-8971; Rita Golfieri 0000-0001-8809-9989; Giovanni Brandi 0000-0003-0013-2858; Riccardo Casadei 0000-0002-4044-3557.

**Author contributions:** Di Marco M, Carloni R and De Lorenzo S reviewed the literature and contributed to manuscript drafting; Brandi G, Grassi E, Di Federico A and Palloni A were the patient's attending physicians and contributed to manuscript drafting; Golfieri R and Mosconi C reviewed the MRI findings and selected the figures; Filippini DM, Ricci AD

Mariacristina Di Marco, Riccardo Carloni, Andrea Palloni, Daria Maria Filippini, Angela Dalia Ricci, Alessandro Rizzo, Alessandro Di Federico, Giovanni Brandi, Department of Experimental, Diagnostic, and Specialty Medicine-DIMES, Sant'Orsola-Malpighi Hospital, University of Bologna, Bologna 40138, Italy

Mariacristina Di Marco, Stefania De Lorenzo, Giovanni Brandi, Division of Oncology, Azienda Ospedaliero-Universitaria di Bologna, Bologna 40138, Italy

Cristina Mosconi, Rita Golfieri, Radiology Unit, Department of Diagnostic Medicine and Prevention, Sant'Orsola-Malpighi Hospital, University of Bologna, Bologna 40138, Italy

Elisa Grassi, Medical Oncology, Ospedale Degli Infermi, Faenza 48018, Italy

Donatella Santini, Pathology Unit, Sant'Orsola-Malpighi Hospital, Bologna 40138, Italy

Daniela Turchetti, Unit of Medical Genetics, Sant'Orsola-Malpighi Hospital, University of Bologna, Bologna 40138, Italy

Claudio Ricci, Carlo Ingaldi, Laura Alberici, Francesco Minni, Riccardo Casadei, Division of Pancreatic Surgery, Azienda Ospedaliero-Universitaria Di Bologna, Bologna 40138, Italy

Claudio Ricci, Carlo Ingaldi, Laura Alberici, Francesco Minni, Riccardo Casadei, Department of Internal Medicine and Surgery, Alma Mater Studiorum, University of Bologna, Bologna 40138, Italy

**Corresponding author:** Riccardo Carloni, MD, Doctor, Department of Experimental, Diagnostic, and Specialty Medicine-DIMES, Sant'Orsola-Malpighi Hospital, University of Bologna, Via Massarenti 9, Bologna 40138, Italy. [riccardo.carloni2@studio.unibo.it](mailto:riccardo.carloni2@studio.unibo.it)

### Abstract

#### BACKGROUND

Pancreatic mucinous cystadenocarcinoma (MCAC) is a rare malignancy with a poor prognosis when it presents metastases at diagnosis. Due to its very low incidence, there are no clear recommendations for the treatment of advanced

and Rizzo A reviewed the literature; Ricci C, Ingaldi C, Alberici L, Minni F and Casadei R were the patient's surgeons and reviewed the literature; Santini D and Turchetti D performed pathological examinations and BRCA testing, respectively, and reviewed the literature; Di Marco M was responsible for revision of the manuscript for important intellectual content; all authors issued final approval for the version to be submitted.

**Informed consent statement:** The patient provided informed consent for the publication of her case.

**Conflict-of-interest statement:** The authors declare that they have no conflicts of interest.

**CARE Checklist (2016) statement:**

The authors have read the CARE Checklist (2016), and the manuscript was prepared and revised according to the CARE Checklist (2016).

**Open-Access:** This article is an open-access article that was selected by an in-house editor and fully peer-reviewed by external reviewers. It is distributed in accordance with the Creative Commons Attribution NonCommercial (CC BY-NC 4.0) license, which permits others to distribute, remix, adapt, build upon this work non-commercially, and license their derivative works on different terms, provided the original work is properly cited and the use is non-commercial. See: <http://creativecommons.org/licenses/by-nc/4.0/>

**Manuscript source:** Unsolicited manuscript

**Specialty type:** Oncology

**Country/Territory of origin:** Italy

**Peer-review report's scientific quality classification**

Grade A (Excellent): A  
Grade B (Very good): B  
Grade C (Good): 0  
Grade D (Fair): 0  
Grade E (Poor): 0

disease. Olaparib (an oral PARP inhibitor) has been approved for the maintenance treatment of patients with metastatic pancreatic adenocarcinoma harbouring germline *BRCA1/2* mutations. Herein, we report the first case of a germline *BRCA1* mutated unresectable MCAC which was effectively treated with olaparib.

### CASE SUMMARY

A 41-year-old woman, without personal or family history of cancer, was diagnosed with ovarian and peritoneal metastases of MCAC. She underwent 12 cycles of gemcitabine plus oxaliplatin (GEMOX) obtaining a partial response and allowing radical surgery. One year later, local recurrence was documented, and other 12 cycles of GEMOX were administered obtaining a complete response. Seven years later, another local recurrence, not amenable to surgical resection, was diagnosed. She started FOLFIRINOX (oxaliplatin, irinotecan, leucovorin and fluorouracil), obtaining a partial response after 8 cycles. Given the excellent response to platinum-based chemotherapy, *BRCA* testing was performed, and a *BRCA1* germline mutation was detected. She was switched to maintenance olaparib due to chemotherapy-related toxicities and achieved an almost complete metabolic response, with a reduction in the diameter of the lesion, after three months of therapy.

### CONCLUSION

The current case suggests the beneficial effect of olaparib in *BRCA* mutated MCAC. However, further studies are required.

**Key Words:** Mucinous cystadenocarcinoma; Pancreatic cancer; *BRCA1* gene; Olaparib; Case report

©The Author(s) 2020. Published by Baishideng Publishing Group Inc. All rights reserved.

**Core Tip:** Pancreatic mucinous cystadenocarcinoma (MCAC) is a rare malignancy with a poor prognosis when it presents metastases at diagnosis. Due to its very low incidence, there are no clear recommendations for the treatment of advanced disease. Olaparib (an oral PARP inhibitor) has remarkable curative effects in *BRCA* mutated pancreatic ductal adenocarcinoma, breast and ovarian cancers. However, there are few data on its efficacy in the treatment of other types of pancreatic malignancies. Herein, we report the first case of a germline *BRCA1* mutated MCAC which was effectively treated with olaparib. We also provide a brief overview of the most relevant clinical features of MCAC.

**Citation:** Di Marco M, Carloni R, De Lorenzo S, Mosconi C, Palloni A, Grassi E, Filippini DM, Ricci AD, Rizzo A, Di Federico A, Santini D, Turchetti D, Ricci C, Ingaldi C, Alberici L, Minni F, Golfieri R, Brandi G, Casadei R. Pancreatic mucinous cystadenocarcinoma in a patient harbouring *BRCA1* germline mutation effectively treated with olaparib: A case report. *World J Gastrointest Oncol* 2020; 12(12): 1456-1463

**URL:** <https://www.wjgnet.com/1948-5204/full/v12/i12/1456.htm>

**DOI:** <https://dx.doi.org/10.4251/wjgo.v12.i12.1456>

## INTRODUCTION

Mucinous cystic neoplasms (MCNs) of the pancreas range from benign mucinous cystadenoma to malignant cystadenocarcinoma, and they represent 23% of all resected pancreatic cysts<sup>[1]</sup>. Lou *et al*<sup>[2]</sup> estimated that pancreatic mucinous cystadenocarcinoma (MCAC) accounts for approximately 0.5% of all pancreatic malignancies, using the Surveillance, Epidemiology and End Results program database. Surgery represents the first choice of treatment for patients with resectable disease. The prognosis of resectable MCAC seems to be significantly more favourable compared to that of pancreatic ductal adenocarcinoma (PDAC)<sup>[3]</sup>. However, locally advanced and metastatic MCACs have a poor prognosis. Due to the very low incidence of MCAC, both controlled prospective studies and clear recommendations for the treatment of

**Received:** October 13, 2020

**Peer-review started:** October 13, 2020

**First decision:** October 23, 2020

**Revised:** November 1, 2020

**Accepted:** November 10, 2020

**Article in press:** November 10, 2020

**Published online:** December 15, 2020

**P-Reviewer:** Tanabe H

**S-Editor:** Zhang H

**L-Editor:** Webster JR

**P-Editor:** Ma YJ



advanced disease are lacking<sup>[4]</sup>.

*BRCA1* and *BRCA2* genes code for proteins that are involved in homologous recombination repair of double-strand DNA breaks, and their mutations are associated with an increased risk of several types of cancer<sup>[5]</sup>. In pancreatic adenocarcinoma, the prevalence of germline *BRCA1/2* mutations among patients with apparently sporadic forms of the disease ranges from 1.8% to 4.6%<sup>[6,7]</sup>. Recently, maintenance olaparib (an oral PARP inhibitor) has been approved for the treatment of patients with metastatic pancreatic adenocarcinoma harbouring germline *BRCA1/2* mutations based on the results of the POLO trial<sup>[8]</sup>. Nevertheless, the prevalence of germline *BRCA1/2* mutations in pancreatic MCAC is unclear, and there are no data on the efficacy of PARP inhibitors in the treatment of *BRCA1/2* mutated MCAC.

## CASE PRESENTATION

### Chief complaints

A 41-year-old Caucasian woman was referred to our centre. She had a history of nausea, constipation and epigastric pain for several months.

### History of present illness

The patient had no relevant events in her medical history.

### History of past illness

The patient had no relevant events in her medical history.

### Personal and family history

No significant personal or family history.

### Physical examination

Unremarkable.

### Laboratory examinations

The serum cancer antigen (CA) 125 level was 150 IU/mL (reference range 0.00–35.00 IU/mL), while serum CA19-9 level was 354 IU/mL (reference range 0.00–37.00 IU/mL) and serum carcinoembryonic antigen (CEA) level was 13.4 ng/mL (reference range 0.00–5.00 ng/mL for non-smokers).

### Imaging examinations

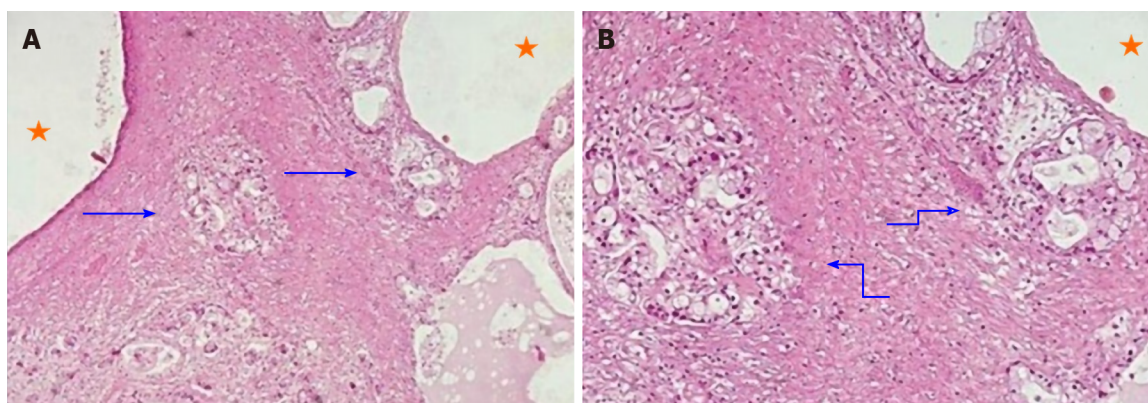
She underwent computed tomography (CT) which revealed two bilateral ovarian masses 145 mm and 71 mm in diameter, respectively, and a lesion measuring 40 mm in the body of the pancreas.

## FINAL DIAGNOSIS

Pathology revealed ovarian and peritoneal metastases of pancreatic MCAC.

## TREATMENT

Suspecting two different tumours, she underwent surgery with radical intent in November 2008. The surgeons immediately detected a previously unrecognized peritoneal carcinosis during the exploratory laparotomy. Nonetheless, they still performed a hysterectomy and a bilateral salpingo-oophorectomy to resolve the associated symptoms caused by these masses. The surgical specimen included the uterus and ovaries, which were macroscopically infiltrated by two cystic lesions measuring 65 mm × 60 mm × 40 mm and 100 mm × 90 mm × 50 mm, respectively. Pathology revealed ovarian and peritoneal metastases of pancreatic MCAC (Figure 1). One month later, she started chemotherapy with gemcitabine plus oxaliplatin (GEMOX, gemcitabine 1000 mg/sm/d1 and oxaliplatin 100 mg/sm/d2 every two weeks) obtaining a partial response after 12 cycles. Given the excellent response to chemotherapy, we performed a second exploratory laparotomy in October 2009 during which no peritoneal carcinosis was found. She underwent distal pan-



**Figure 1** Histological examination of the ovarian metastases. A: Hematoxylin-eosin staining ( $\times 10$ ) of the resected specimen showing glandular areas (arrows) next to cystic spaces (stars); B: Higher-power view ( $\times 20$ ) of the glands shown before displaying malignant cytology and an infiltrating pattern.

createctomy and pathological examination confirmed the initial diagnosis of pancreatic MCAC. The patient remained disease-free until September 2011, when both CT and 18F-fluoro-D-glucose positron emission tomography/X-ray computed tomography (18F-FDG PET-CT) showed a local recurrence and GEMOX was restarted obtaining a complete response after 12 cycles (confirmed both by CT and 18-FDG PET-CT). In June 2019, during the follow-up program, laboratory tests documented an increase of serum CEA (14.2 ng/mL), while serum CA125 and CA19-9 were normal. We performed magnetic resonance imaging and 18F-FDG PET-CT (Figure 2) which showed a local recurrence not amenable to surgical resection (invasion of the hepatic artery and superior mesenteric vein). The diagnosis was confirmed with an endoscopic ultrasound-guided biopsy. She started FOLFIRINOX (oxaliplatin 85 mg/sm, irinotecan 180 mg/sm, leucovorin 400 mg/sm and fluorouracil 400 mg/sm given as a bolus followed by 2400 mg/sm as a 46 h continuous infusion, every two weeks) obtaining a significant response, with a decrease of 18F-FDG uptake ( $SUV = 3.9$  vs 6) and reduction in CEA level (2.78 ng/mL) after 8 cycles (Figure 3). However, toxicities were observed and included febrile neutropenia and grade 3 vomiting. Considering the excellent radiological response to platinum-based chemotherapy, we performed BRCA testing. Constitutional DNA of the patient was analyzed for BRCA1 and BRCA2 variants using Next Generation Sequencing (ION Torrent S5) and the variant c.4117G>T (p.Glu1373Ter) was detected in the BRCA1 gene. In January 2020 she was switched to maintenance olaparib tablets (300 mg twice daily) with good tolerance, except for anaemia G2 and fatigue G1.

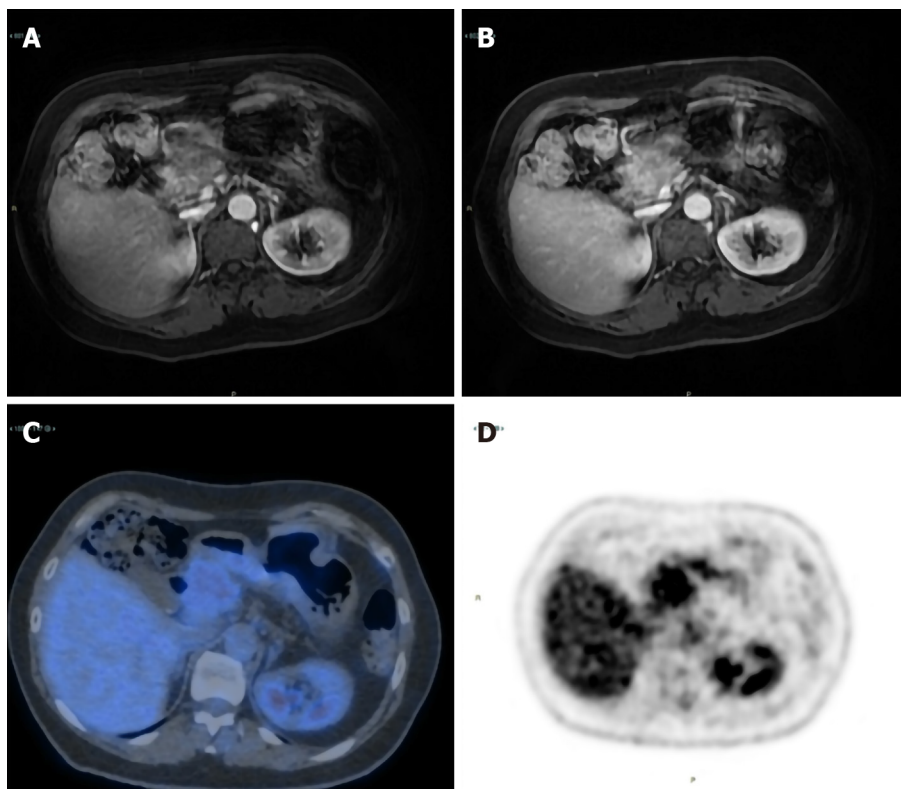
## OUTCOME AND FOLLOW-UP

An 18F-FDG PET-CT performed in May 2020 documented an almost complete metabolic response ( $SUV = 2.1$ ) with a reduction in the diameter of the lesion (Figure 4). Over the next three weeks, treatment was discontinued due to drug shortage related to the COVID-19 pandemic. In June 2020, treatment was restarted and another 18F-FDG PET-CT performed in September 2020 revealed 18F-FDG uptake similar to that shown in May 2020 ( $SUV = 2.3$ ), while CEA level was 1.45 ng/mL. The patient is still well and receiving olaparib.

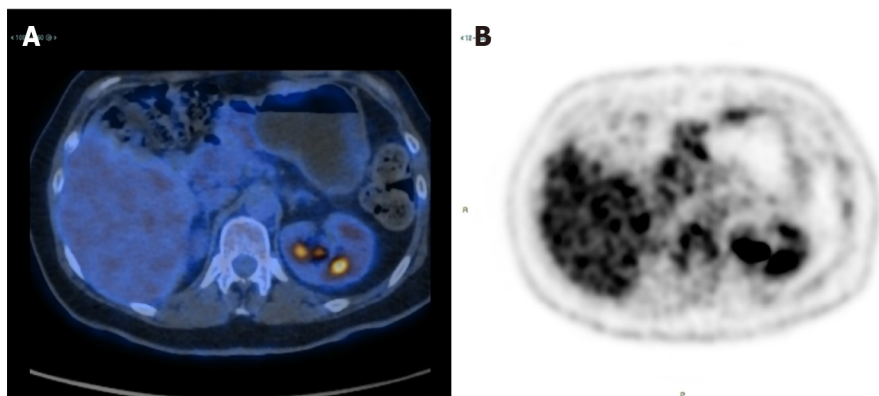
## DISCUSSION

Mucin-producing cystic tumours of the pancreas are classified into two different entities: Intraductal papillary mucinous neoplasms (IPMNs) and MCNs, which are defined by the presence of ovarian-type stroma and do not communicate with the ductal system, unlike IPMNs<sup>[9-13]</sup>. MCNs represent 23% of all resected pancreatic cysts with a mean age at diagnosis of 51 years<sup>[1]</sup>, whereas the mean age at diagnosis for MCAC is higher with a difference of more than ten years (mean 64 years)<sup>[2]</sup>. MCAC represents the malignant form of a mucinous cystic neoplasm; approximately 70% of all patients are female presenting with a relatively large tumour (median size 5.5 cm) which is mainly located in the body/tail of the pancreas<sup>[14]</sup>. MCAC is usually





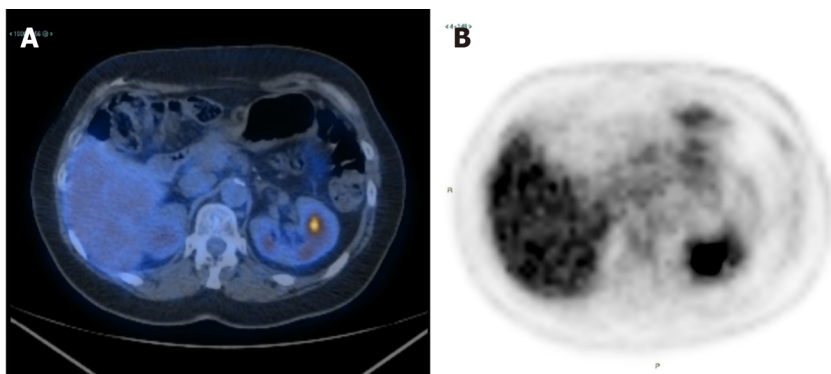
**Figure 2 Magnetic resonance imaging and 18F-fluoro-D-glucose positron emission tomography/X-ray computed tomography.** June 2019, Magnetic resonance imaging (MRI) shows the presence of a lesion approximately 4.4 cm × 3.2 cm in the cephalopancreatic area, with MRI characteristics compatible with local recurrence of the basic neoplastic pathology; A: Arterial phase; B: Portal phase; C and D: 18F-fluoro-D-glucose (FDG) positron emission tomography/X-ray computed tomography confirms the diagnostic suspicion of disease recurrence showing a pathological 18F-FDG uptake.



**Figure 3 18F-fluoro-D-glucose positron emission tomography/X-ray computed tomography performed after eight courses of FOLFIRINOX.** A and B: 18F-fluoro-D-glucose positron emission tomography/X-ray computed tomography shows a metabolic reduction in cephalopancreatic disease.

symptomatic at the time of diagnosis with pain (59%) and jaundice (32%) being the two most frequent symptoms. Also, serum CA19-9 level is often increased<sup>[15]</sup>. The prognosis of resectable MCAC seems to be significantly more favourable compared to pancreatic ductal adenocarcinoma<sup>[2,3]</sup>. In a retrospective study involving 507 patients with MCAC, the median observed survival for patients with resectable disease was 111.0 mo *vs* 14.0 mo and 4.0 mo for those with regional and metastatic disease, respectively<sup>[14]</sup>. Interestingly, the performance of curative-intent surgery and the tumour stage were independent predictors of survival. Instead, tumour size seemed to have an insignificant impact on the disease-specific survival of patients with localized MCAC, different to pancreatic ductal adenocarcinoma<sup>[16]</sup>. Due to the very low incidence of this malignancy, there are no prospective studies focusing on chemotherapy for MCAC, and data are available from only case series and case





**Figure 4** 18F-fluoro-D-glucose positron emission tomography/X-ray computed tomography performed after three months of maintenance olaparib. A and B: 18F-fluoro-D-glucose positron emission tomography/X-ray computed tomography shows complete metabolic normalization of the pancreatic lesion, which is also reduced in size.

reports. Thus, it is unclear what is the most appropriate therapeutic approach for advanced disease<sup>[4,17,18]</sup>. This fact is reflected in the poor prognosis of advanced MCAC, especially when compared with that of resectable disease.

BRCA1 and BRCA2 proteins play a crucial role in repairing double-strand DNA breaks *via* the homologous DNA repair mechanism. Deleterious mutations within these genes are associated with an increased risk of breast, ovarian and prostate cancer<sup>[19,20]</sup>. In addition, germline *BRCA1* and *BRCA2* mutations are associated with a relative risk of 2.26 and 3.51 for developing pancreatic adenocarcinoma, respectively<sup>[21,22]</sup>. PARP inhibitors interfere with base excision repair, a crucial pathway in the repair of DNA single-strand breaks, causing an accumulation of single-strand DNA breaks which result into DNA double-strand breaks. Inactivation of *BRCA1* or *BRCA2* genes sensitizes cells to the inhibition of PARP, causing cell cycle arrest and apoptosis when cells are exposed to PARP inhibitors<sup>[23]</sup>. Olaparib (an oral PARP inhibitor) has recently been approved for the maintenance treatment of patients with metastatic pancreatic adenocarcinoma that had not progressed during first-line platinum-based chemotherapy<sup>[8]</sup>. To date, there are no reports of *BRCA*-mutated MCAC treated with PARP inhibitors.

At the time of diagnosis, our patient had metastatic disease, but an aggressive surgical approach associated with a marked response to platinum-based chemotherapy allowed a complete response. Although her family history was negative for cancer, given the impressive response to platinum-based chemotherapy, we investigated and detected a *BRCA1* germline mutation. Historically, screening for *BRCA* mutations was offered only to those patients with a family history highly suspicious for a genetic predisposition syndrome<sup>[24]</sup>. However, this strategy fails to identify a relevant proportion of patients with germline *BRCA1/2* mutations<sup>[24]</sup>. Given the results of the POLO trial, and emerging evidence on the efficacy of platinum-based chemotherapy in *BRCA* mutated PDAC, National Comprehensive Cancer Network guidelines now recommend germline testing for all patients with PDAC<sup>[25-27]</sup>.

To our knowledge, this is the first report on the efficacy of a PARP inhibitor in a MCAC patient harbouring a germline *BRCA* mutation. After three months of treatment with maintenance olaparib, we documented a deep metabolic response with a reduction in the diameter of the lesion and after seven months of therapy 18F-FDG PET-CT still shows an almost complete metabolic response. Treatment was well tolerated except for anaemia G2 and fatigue G1, and it was discontinued for only one week due to fatigue. Reported toxicities in our case are in line with previous studies, with fatigue (60%), nausea (45%) and anaemia (27%) being the three most common adverse events reported in the POLO trial<sup>[8]</sup>.

## CONCLUSION

Increased use of *BRCA* testing, not based only on personal or family history of cancer, may help to identify a higher number of patients which could benefit from target therapies. As previously demonstrated in the treatment of patients with other types of cancers harbouring a germline *BRCA* mutation, we suggest that maintenance olaparib should also be considered for MCAC patients as it is safe and effective. However,

further studies are needed to confirm our results.

## ACKNOWLEDGEMENTS

We would like to thank the Centro Interdipartimentale di Ricerca sul Cancro “Giorgio Prodi” for the support.

## REFERENCES

- Valsangkar NP**, Morales-Oyarvide V, Thayer SP, Ferrone CR, Wargo JA, Warshaw AL, Fernández-del Castillo C. 851 resected cystic tumors of the pancreas: a 33-year experience at the Massachusetts General Hospital. *Surgery* 2012; **152**: S4-12 [PMID: [22770958](#) DOI: [10.1016/j.surg.2012.05.033](#)]
- Luo G**, Fan Z, Gong Y, Jin K, Yang C, Cheng H, Huang D, Ni Q, Liu C, Yu X. Characteristics and Outcomes of Pancreatic Cancer by Histological Subtypes. *Pancreas* 2019; **48**: 817-822 [PMID: [31210663](#) DOI: [10.1097/MPA.0000000000001338](#)]
- Ridder GJ**, Maschek H, Klempnauer J. Favourable prognosis of cystadeno- over adenocarcinoma of the pancreas after curative resection. *Eur J Surg Oncol* 1996; **22**: 232-236 [PMID: [8654602](#) DOI: [10.1016/s0748-7983\(96\)80008-4](#)]
- Brunetti O**, Aprile G, Marchetti P, Vasile E, Casadei Gardini A, Scartozzi M, Barni S, Delfanti S, De Vita F, Di Costanzo F, Milella M, Cella CA, Berardi R, Cataldo I, Scarpa A, Basile D, Mazzuca F, Graziano G, Argentiero A, Santini D, Reni M, Cascinu S, Silvestris N. Systemic Chemotherapy for Advanced Rare Pancreatic Histotype Tumors: A Retrospective Multicenter Analysis. *Pancreas* 2018; **47**: 759-771 [PMID: [29771769](#) DOI: [10.1097/MPA.0000000000001063](#)]
- Walsh CS**. Two decades beyond BRCA1/2: Homologous recombination, hereditary cancer risk and a target for ovarian cancer therapy. *Gynecol Oncol* 2015; **137**: 343-350 [PMID: [25725131](#) DOI: [10.1016/j.ygyno.2015.02.017](#)]
- Shindo K**, Yu J, Suenaga M, Fesharakizadeh S, Cho C, Macgregor-Das A, Siddiqui A, Witmer PD, Tamura K, Song TJ, Navarro Almario JA, Brant A, Borges M, Ford M, Barkley T, He J, Weiss MJ, Wolfgang CL, Roberts NJ, Hruban RH, Klein AP, Goggins M. Deleterious Germline Mutations in Patients With Apparently Sporadic Pancreatic Adenocarcinoma. *J Clin Oncol* 2017; **35**: 3382-3390 [PMID: [28767289](#) DOI: [10.1200/JCO.2017.72.3502](#)]
- Holter S**, Borgida A, Dodd A, Grant R, Semotiuk K, Hedley D, Dhani N, Narod S, Akbari M, Moore M, Gallinger S. Germline BRCA Mutations in a Large Clinic-Based Cohort of Patients With Pancreatic Adenocarcinoma. *J Clin Oncol* 2015; **33**: 3124-3129 [PMID: [25940717](#) DOI: [10.1200/JCO.2014.59.7401](#)]
- Golan T**, Hammel P, Reni M, Van Cutsem E, Macarulla T, Hall MJ, Park JO, Hochhauser D, Arnold D, Oh DY, Reinacher-Schick A, Tortora G, Algül H, O'Reilly EM, McGuinness D, Cui KY, Schlienger K, Locker GY, Kindler HL. Maintenance Olaparib for Germline BRCA-Mutated Metastatic Pancreatic Cancer. *N Engl J Med* 2019; **381**: 317-327 [PMID: [31157963](#) DOI: [10.1056/NEJMoa1903387](#)]
- Klöppel G**, Solcia E, Longnecker DS, Capella C, SOBIN L. Histological typing of tumors of the exocrine pancreas. World Health Organization. Geneva, Switzerland: Springer; 1996. Available from: <https://www.springer.com/gp/book/9783540602804>
- Stark A**, Donahue TR, Reber HA, Hines OJ. Pancreatic Cyst Disease: A Review. *JAMA* 2016; **315**: 1882-1893 [PMID: [27139061](#) DOI: [10.1001/jama.2016.4690](#)]
- Tanaka M**, Fernández-del Castillo C, Adsay V, Chari S, Falconi M, Jang JY, Kimura W, Levy P, Pitman MB, Schmidt CM, Shimizu M, Wolfgang CL, Yamaguchi K, Yamao K; International Association of Pancreatology. International consensus guidelines 2012 for the management of IPMN and MCN of the pancreas. *Pancreatol* 2012; **12**: 183-197 [PMID: [22687371](#) DOI: [10.1016/j.pan.2012.04.004](#)]
- Tanaka M**, Chari S, Adsay V, Fernandez-del Castillo C, Falconi M, Shimizu M, Yamaguchi K, Yamao K, Matsuno S; International Association of Pancreatology. International consensus guidelines for management of intraductal papillary mucinous neoplasms and mucinous cystic neoplasms of the pancreas. *Pancreatol* 2006; **6**: 17-32 [PMID: [16327281](#) DOI: [10.1159/000090023](#)]
- Reddy RP**, Smyrk TC, Zapiach M, Levy MJ, Pearson RK, Clain JE, Farnell MB, Sarr MG, Chari ST. Pancreatic mucinous cystic neoplasm defined by ovarian stroma: demographics, clinical features, and prevalence of cancer. *Clin Gastroenterol Hepatol* 2004; **2**: 1026-1031 [PMID: [15551256](#) DOI: [10.1016/s1542-3565\(04\)00450-1](#)]
- Doulamis IP**, Mylonas KS, Kalfountzos CE, Mou D, Haj-Ibrahim H, Nasioudis D. Pancreatic mucinous cystadenocarcinoma: Epidemiology and outcomes. *Int J Surg* 2016; **35**: 76-82 [PMID: [27638187](#) DOI: [10.1016/j.ijssu.2016.09.017](#)]
- Le Borgne J**, de Calan L, Partensky C. Cystadenomas and cystadenocarcinomas of the pancreas: a multiinstitutional retrospective study of 398 cases. French Surgical Association. *Ann Surg* 1999; **230**: 152-161 [PMID: [10450728](#) DOI: [10.1097/00000658-199908000-00004](#)]
- Park H**, An S, Eo SH, Song KB, Park JH, Kim KP, Lee SS, Cho H, Seo DW, Kim SC, Yu E, Hong

- SM. Survival effect of tumor size and extrapancreatic extension in surgically resected pancreatic cancer: proposal for improved T classification. *Hum Pathol* 2014; **45**: 2341-2346 [PMID: [25248573](#) DOI: [10.1016/j.humpath.2014.06.030](#)]
- 17 **Björk Werner J**, Stureson C, Dawiskiba S, Andersson R. Mucinous cystadenocarcinoma of the pancreas - outcome following different modes of treatment. *Ann Gastroenterol* 2011; **24**: 213-217 [PMID: [24713784](#)]
  - 18 **Shimada K**, Iwase K, Aono T, Takeda S, Yoshida H, Koma M, Nomura M, Nishikawa K, Tamagawa H, Matsuda C, Fushimi H, Tanaka Y. A case of advanced mucinous cystadenocarcinoma of the pancreas with peritoneal dissemination responding to gemcitabine. *Gan To Kagaku Ryoho* 2009; **36**: 995-998 [PMID: [19542723](#)]
  - 19 **Wooster R**, Weber BL. Breast and ovarian cancer. *N Engl J Med* 2003; **348**: 2339-2347 [PMID: [12788999](#) DOI: [10.1056/NEJMra012284](#)]
  - 20 **Castro E**, Eeles R. The role of BRCA1 and BRCA2 in prostate cancer. *Asian J Androl* 2012; **14**: 409-414 [PMID: [22522501](#) DOI: [10.1038/aja.2011.150](#)]
  - 21 **Breast Cancer Linkage Consortium**. Cancer risks in BRCA2 mutation carriers. *J Natl Cancer Inst* 1999; **91**: 1310-1316 [PMID: [10433620](#) DOI: [10.1093/jnci/91.15.1310](#)]
  - 22 **Thompson D**, Easton DF; Breast Cancer Linkage Consortium. Cancer Incidence in BRCA1 mutation carriers. *J Natl Cancer Inst* 2002; **94**: 1358-1365 [PMID: [12237281](#) DOI: [10.1093/jnci/94.18.1358](#)]
  - 23 **Farmer H**, McCabe N, Lord CJ, Tutt AN, Johnson DA, Richardson TB, Santarosa M, Dillon KJ, Hickson I, Knights C, Martin NM, Jackson SP, Smith GC, Ashworth A. Targeting the DNA repair defect in BRCA mutant cells as a therapeutic strategy. *Nature* 2005; **434**: 917-921 [PMID: [15829967](#) DOI: [10.1038/nature03445](#)]
  - 24 **Wong W**, Raufi AG, Safyan RA, Bates SE, Manji GA. BRCA Mutations in Pancreas Cancer: Spectrum, Current Management, Challenges and Future Prospects. *Cancer Manag Res* 2020; **12**: 2731-2742 [PMID: [32368150](#) DOI: [10.2147/CMAR.S211151](#)]
  - 25 **Wattenberg MM**, Asch D, Yu S, O'Dwyer PJ, Domchek SM, Nathanson KL, Rosen MA, Beatty GL, Siegelman ES, Reiss KA. Platinum response characteristics of patients with pancreatic ductal adenocarcinoma and a germline BRCA1, BRCA2 or PALB2 mutation. *Br J Cancer* 2020; **122**: 333-339 [PMID: [31787751](#) DOI: [10.1038/s41416-019-0582-7](#)]
  - 26 **Golan T**, Kanji ZS, Epelbaum R, Devaud N, Dagan E, Holter S, Aderka D, Paluch-Shimon S, Kaufman B, Gershoni-Baruch R, Hedley D, Moore MJ, Friedman E, Gallinger S. Overall survival and clinical characteristics of pancreatic cancer in BRCA mutation carriers. *Br J Cancer* 2014; **111**: 1132-1138 [PMID: [25072261](#) DOI: [10.1038/bjc.2014.418](#)]
  - 27 **National Comprehensive Cancer Network**. Pancreatic Adenocarcinoma (Version 3. 2019). Available from: <https://www.nccn.org/>





Published by **Baishideng Publishing Group Inc**  
7041 Koll Center Parkway, Suite 160, Pleasanton, CA 94566, USA

**Telephone:** +1-925-3991568

**E-mail:** [bpgoffice@wjgnet.com](mailto:bpgoffice@wjgnet.com)

**Help Desk:** <https://www.f6publishing.com/helpdesk>

<https://www.wjgnet.com>

