

World Journal of *Gastrointestinal Oncology*

World J Gastrointest Oncol 2021 October 15; 13(10): 1213-1543



FRONTIER

- 1213** Engineering nanotheranostic strategies for liver cancer

Cao L, Zhu YQ, Wu ZX, Wang GX, Cheng HW

REVIEW

- 1229** Role of autophagy in cholangiocarcinoma: An autophagy-based treatment strategy

Koustas E, Trifylli EM, Sarantis P, Papavassiliou AG, Karamouzis MV

- 1244** Role of autophagy in gastric carcinogenesis

Papaefthymiou A, Christodoulidis G, Koffas A, Doulberis M, Polyzos SA, Manolakis A, Potamianos S, Kapsoritakis A, Kountouras J

- 1263** Liquid biopsy approach to pancreatic cancer

Perales S, Torres C, Jimenez-Luna C, Prados J, Martinez-Galan J, Sanchez-Manas JM, Caba O

- 1288** Molecular testing for colorectal cancer: Clinical applications

Imyanitov E, Kuligina E

- 1302** New frontiers in liver ultrasound: From mono to multi parametricity

Bartolotta TV, Taibbi A, Randazzo A, Gagliardo C

- 1317** Gallbladder cancer: Historical treatment and new management options

Okumura K, Gogna S, Gachabayov M, Felsenreich DM, McGuirk M, Rojas A, Quintero L, Seshadri R, Gu K, Dong XD

- 1336** Review of incidence and outcomes of treatment of cholangiocarcinoma in patients with primary sclerosing cholangitis

Saffioti F, Mavroedis VK

- 1367** Diverse roles of FOXO family members in gastric cancer

Chen YH, Li CL, Chen WJ, Liu J, Wu HT

MINIREVIEWS

- 1383** Endoscopic radiofrequency ablation for malignant biliary obstruction

Jarosova J, Macinga P, Hujova A, Kral J, Urban O, Spicak J, Hucl T

- 1397** Thermal ablation and immunotherapy for hepatocellular carcinoma: Recent advances and future directions

Bo XW, Sun LP, Yu SY, Xu HX

- 1412** Lateral pelvic lymph nodes for rectal cancer: A review of diagnosis and management

Ogawa S, Itabashi M, Inoue Y, Ohki T, Bamba Y, Koshino K, Nakagawa R, Tani K, Aihara H, Kondo H, Yamaguchi S, Yamamoto M

- 1425** Proliferating cell nuclear antigen clamp associated factor, a potential proto-oncogene with increased expression in malignant gastrointestinal tumors
Liu LJ, Liao JM, Zhu F
- 1440** Nutritional therapy for hepatocellular carcinoma
Ruiz-Margáin A, Román-Calleja BM, Moreno-Guillén P, González-Regueiro JA, Kúsulas-Delint D, Campos-Murguía A, Flores-García NC, Macías-Rodríguez RU
- 1453** Radiotherapy for gastric mucosa-associated lymphoid tissue lymphoma
Quéro L, Labidi M, Bollet M, Bommier C, Guillermin S, Hennequin C, Thieblemont C
- 1466** Endoscopic papillectomy for ampullary adenomatous lesions: A literature review
Li SL, Li W, Yin J, Wang ZK
- 1475** Endoscopic ultrasound assessment and tissue acquisition of mediastinal and abdominal lymph nodes
Tamanini G, Cominardi A, Brighi N, Fusaroli P, Lisotti A

ORIGINAL ARTICLE**Basic Study**

- 1492** Direct interaction between Rab5a and Rab4a enhanced epidermal growth factor-stimulated proliferation of gastric cancer cells
Cao GJ, Wang D, Zeng ZP, Wang GX, Hu CJ, Xing ZF
- 1506** Combination of neutrophil gelatinase-associated lipocalin and matrix metalloproteinase-9 are biomarkers for the detection of colon tubular adenocarcinoma
Yuan JH, Xie LS, Zhu YH, Wang XH, Zhang YJ, Wang XJ
- 1518** Survival effect of probiotics in a rat model of colorectal cancer treated with capecitabine
Gigola G, Carriere P, Novoa Díaz MB, Perdigon G, Zwenger AO, Gentili C

Prospective Study

- 1532** Efficacy and toxicity of capecitabine combined with intensity-modulated radiotherapy after D1/D2 lymph node dissection in patients with gastric cancer
Wang X, Wang WH, Wang SL, Song YW, Liu YP, Tang Y, Li N, Liu WY, Fang H, Li YX, Zhao DB, Chi Y, Yang L, Jin J

ABOUT COVER

Editorial Board Member of *World Journal of Gastrointestinal Oncology*, Guido Giordano, MD, Research Assistant Professor, Department of Medical and Surgical Sciences; Unit of Medical Oncology and Biomolecular Therapy, University of Foggia, Policlinico Riuniti, Foggia 71122, Italy. giordano.guido81@gmail.com

AIMS AND SCOPE

The primary aim of *World Journal of Gastrointestinal Oncology* (WJGO, *World J Gastrointest Oncol*) is to provide scholars and readers from various fields of gastrointestinal oncology with a platform to publish high-quality basic and clinical research articles and communicate their research findings online.

WJGO mainly publishes articles reporting research results and findings obtained in the field of gastrointestinal oncology and covering a wide range of topics including liver cell adenoma, gastric neoplasms, appendiceal neoplasms, biliary tract neoplasms, hepatocellular carcinoma, pancreatic carcinoma, cecal neoplasms, colonic neoplasms, colorectal neoplasms, duodenal neoplasms, esophageal neoplasms, gallbladder neoplasms, *etc.*

INDEXING/ABSTRACTING

The WJGO is now indexed in Science Citation Index Expanded (also known as SciSearch®), PubMed, PubMed Central, and Scopus. The 2021 edition of Journal Citation Reports® cites the 2020 impact factor (IF) for WJGO as 3.393; IF without journal self cites: 3.333; 5-year IF: 3.519; Journal Citation Indicator: 0.5; Ranking: 163 among 242 journals in oncology; Quartile category: Q3; Ranking: 60 among 92 journals in gastroenterology and hepatology; and Quartile category: Q3. The WJGO's CiteScore for 2020 is 3.3 and Scopus CiteScore rank 2020: Gastroenterology is 70/136.

RESPONSIBLE EDITORS FOR THIS ISSUE

Production Editor: *Ying-Yi Yuan*; Production Department Director: *Xiang Li*; Editorial Office Director: *Ya-Juan Ma*.

NAME OF JOURNAL

World Journal of Gastrointestinal Oncology

ISSN

ISSN 1948-5204 (online)

LAUNCH DATE

February 15, 2009

FREQUENCY

Monthly

EDITORS-IN-CHIEF

Rosa M Jimenez Rodriguez, Pashtoon M Kasi, Monjur Ahmed, Florin Burada

EDITORIAL BOARD MEMBERS

<https://www.wjgnet.com/1948-5204/editorialboard.htm>

PUBLICATION DATE

October 15, 2021

COPYRIGHT

© 2021 Baishideng Publishing Group Inc

INSTRUCTIONS TO AUTHORS

<https://www.wjgnet.com/bpg/gerinfo/204>

GUIDELINES FOR ETHICS DOCUMENTS

<https://www.wjgnet.com/bpg/GerInfo/287>

GUIDELINES FOR NON-NATIVE SPEAKERS OF ENGLISH

<https://www.wjgnet.com/bpg/gerinfo/240>

PUBLICATION ETHICS

<https://www.wjgnet.com/bpg/GerInfo/288>

PUBLICATION MISCONDUCT

<https://www.wjgnet.com/bpg/gerinfo/208>

ARTICLE PROCESSING CHARGE

<https://www.wjgnet.com/bpg/gerinfo/242>

STEPS FOR SUBMITTING MANUSCRIPTS

<https://www.wjgnet.com/bpg/GerInfo/239>

ONLINE SUBMISSION

<https://www.f6publishing.com>



Radiotherapy for gastric mucosa-associated lymphoid tissue lymphoma

Laurent Quéro, Mouna Labidi, Marc Bollet, Côme Bommier, Sophie Guillerme, Christophe Hennequin, Catherine Thieblemont

ORCID number: Laurent Quéro 0000-0002-8781-2540; Mouna Labidi 0000-0002-7648-4836; Marc Bollet 0000-0002-0441-955X; Côme Bommier 0000-0002-5695-911X; Sophie Guillerme 0000-0003-0711-0280; Christophe Hennequin 0000-0002-8355-3801; Catherine Thieblemont 0000-0002-9941-2448.

Author contributions: Quéro L designed, researched and analyzed the literature, and helped write the paper; Labidi M, Bollet M, Guillerme S, Hennequin C and Thieblemont C analyzed the literature, and helped write the paper.

Conflict-of-interest statement: The authors have no conflict of interest related to the manuscript.

Open-Access: This article is an open-access article that was selected by an in-house editor and fully peer-reviewed by external reviewers. It is distributed in accordance with the Creative Commons Attribution NonCommercial (CC BY-NC 4.0) license, which permits others to distribute, remix, adapt, build upon this work non-commercially, and license their derivative works on different terms, provided the original work is properly cited and the use is non-commercial. See: <http://creativecommons.org/License>

Laurent Quéro, Mouna Labidi, Sophie Guillerme, Christophe Hennequin, Department of Radiation Oncology, AP-HP, Saint Louis Hospital, Paris 75010, France

Laurent Quéro, Côme Bommier, Christophe Hennequin, Catherine Thieblemont, Faculty of Medicine, Université de Paris, Paris 75005, France

Marc Bollet, Department of Radiation Oncology, Hartmann Oncology Radiotherapy Group, Levallois-Perret 92044, France

Catherine Thieblemont, Hemato-Oncology, DMU DHI, AP-HP, Saint Louis Hospital, Paris 75010, France

Corresponding author: Laurent Quéro, MD, MSc, PhD, Professor, Department of Radiation Oncology, AP-HP, Saint Louis Hospital, 1 Avenue Claude Vellefaux, Paris 75010, France. laurent.querro@aphp.fr

Abstract

Gastric mucosa-associated lymphoid tissue (MALT) lymphoma is a rare disease which is often associated with *Helicobacter pylori* (*H. pylori*) infection. First-line treatment of stage IE and IIE localized gastric MALT lymphoma is based on the eradication of *H. pylori*. The presence of *H. pylori* resistance factors such as translocation t (11;18), peri-gastric lymph node involvement and the degree of tumor infiltration of the gastric wall; or lack of response to antibiotic therapy are two main indications to treat with definitive radiotherapy (RT). RT is an effective treatment in localized gastric MALT lymphoma. A moderate dose of 30 Gy allows a high cure rate while being well tolerated. After treatment, regular gastric endoscopic follow-up is necessary to detect a potential occurrence of gastric adenocarcinoma.

Key Words: Radiotherapy; Mucosa-associated lymphoid tissue; MALT; *Helicobacter pylori*; Lymphoma; Review

©The Author(s) 2021. Published by Baishideng Publishing Group Inc. All rights reserved.

s/by-nc/4.0/

Manuscript source: Invited manuscript**Specialty type:** Oncology**Country/Territory of origin:** France**Peer-review report's scientific quality classification**

Grade A (Excellent): 0

Grade B (Very good): B, B

Grade C (Good): C

Grade D (Fair): 0

Grade E (Poor): E

Received: March 6, 2021**Peer-review started:** March 6, 2021**First decision:** June 4, 2021**Revised:** July 9, 2021**Accepted:** August 30, 2021**Article in press:** August 30, 2021**Published online:** October 15, 2021**P-Reviewer:** Nath J, Pruthi DS, Sun Y, Wang SY**S-Editor:** Fan JR**L-Editor:** A**P-Editor:** Liu JH

Core Tip: In this review, after *Helicobacter pylori* eradication failure, radiotherapy is an effective and well tolerated treatment in localized gastric mucosa-associated lymphoid tissue lymphoma. A moderate dose of 30 Gy allows a high cure rate while being well tolerated. Long-term gastric endoscopy follow-up is necessary to detect a possible occurrence of a stomach carcinoma.

Citation: Quero L, Labidi M, Bollet M, Bommier C, Guillermin S, Hennequin C, Thieblemont C. Radiotherapy for gastric mucosa-associated lymphoid tissue lymphoma. *World J Gastrointest Oncol* 2021; 13(10): 1453-1465

URL: <https://www.wjgnet.com/1948-5204/full/v13/i10/1453.htm>

DOI: <https://dx.doi.org/10.4251/wjgo.v13.i10.1453>

INTRODUCTION

Extranodal marginal zone lymphoma (EMZL) is an indolent non-Hodgkin's B-cell lymphoma. It belongs to the heterogeneous group of MZLs, beside splenic MZL and nodal MZL. It has an extra-nodal origin. EMZL can develop from mucosal, called also mucosa-associated lymphoid tissue (MALT) lymphoma, and non-mucosal sites, in various organs such as the stomach, small intestine, bronchi, thyroid gland, liver, kidney, breast, salivary glands, orbit/orbital adnexa, or skin. It can be associated with autoimmune diseases such as Hashimoto's thyroiditis or Sjögren's syndrome. The most common sites of EMZL are the stomach, the orbit/orbital adnexa and the skin, and gastric MALT-lymphoma accounts for 30%–50% of all MALT-lymphoma locations[1, 2].

The incidence of non-Hodgkin lymphoma (NHL) has increased by 70% between 1975 and 2017[3]. MALT gastric lymphoma is rare: It represents 4% of all NHL and approximately 5% of primary gastric neoplasms[4]. According to the SEER United States database, new cases of NHL and gastric cancer were respectively 77240 and 27600 in 2020 in the United States of America[3], which corresponds to between 1380 and 3090 new cases of gastric MALT lymphoma.

The MALT-IPI index was developed to identify patients with a poor prognosis and thus to allow for appropriate treatment of patients with EMZL. This index classified patients into three prognostic groups (low, intermediate, and high) that are predictive for event-free, progression-free and overall survival (OS), whatever the extranodal site of the lymphoma, gastric or non-gastric. The 5-year event-free survival (EFS) rates in the low-, intermediate-, and high-risk groups were 70%, 56%, and 29%, respectively. This index was based on: Age \geq 70 years, Ann Arbor stage III or IV and elevated lactate dehydrogenase (LDH). The MALT-IPI has been developed from 401 patients treated with chlorambucil, rituximab, or both in the international randomized trial IELSG-19. The index was subsequently validated by merging three independent cohorts of MALT lymphoma patients ($n = 633$ patients)[5].

In 90% of cases, gastric MALT lymphoma is associated with a *Helicobacter pylori* (*H. pylori*) infection. *H. pylori* prevalence in developed countries decreased after 2000: In Europe from 48.8% to 39.8%, in Northern America from 42.7% to 26.6%, and in Oceania from 26.6% to 18.7% whereas it remained stable elsewhere: In Asia (53.6% before 2000 vs 54.3% after 2000) and South America and the Caribbean (62.8% before 2000 vs 60.2% after 2000)[6]. In Europe, the prevalence of *H. pylori* infection decreased from 92% in the 80's to 61% between 1995-2004 and then to 32% between 2005-2013 for the United Kingdom, from 82% between 1999-2003 to 69% between 2004-2014 in Austria and from 61% between 1997-2002 to 17% between 2004-2014 for Italy[7-10] (Figure 1).

First-line treatment of stage IE and IIE localized gastric MALT lymphoma is based on the eradication of *H. pylori*. Recommended anti-*H. pylori* therapy includes a proton pump inhibitor (or ranitidine bismuth citrate), clarithromycin and amoxicillin (or metronidazole).

Because MALT lymphoma is rare, treatment recommendations are based on studies with low levels of evidence (Figure 2). The aim of this review is to assess the effectiveness and tolerance of radiotherapy (RT) and the alternative treatments.




Figure 1 Prevalence of *Helicobacter pylori* infection in gastric marginal zone lymphoma. MALT: Mucosa-associated lymphoid tissue.

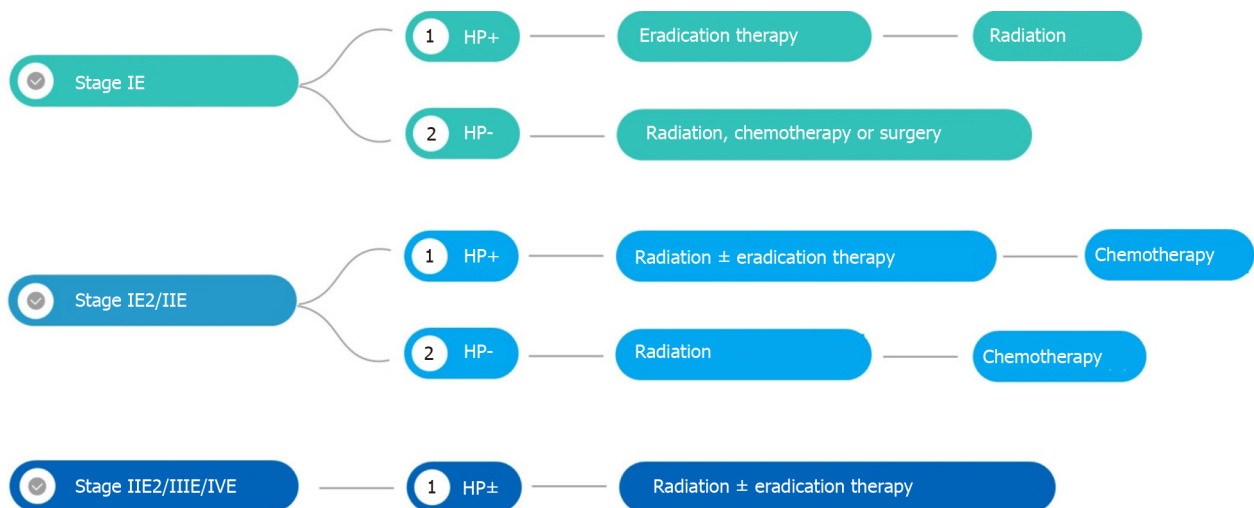


Figure 2 Gastric mucosa-associated lymphoid tissue lymphoma therapeutic algorithm. HP: *Helicobacter pylori*.

STAGING OF GASTRIC MALT LYMPHOMA

Previously, staging of MALT gastric lymphoma was based on Lugano staging system [11] which is a modification of the Ann Arbor staging system. More recently, Paris staging system [12] which corresponds to the tumor, node, metastasis system for gastric cancer, has been proposed. The Paris system has the advantage, over the Lugano staging system, of better describing the depth of invasion into the gastric wall (Tables 1 and 2).

According to ESMO guidelines, initial staging should include history and physical examination, full blood and differential counts, biochemistry including renal and liver function tests, protein electrophoresis, LDH and beta2-microglobulin, serum and urine immunofixation, serology for hepatitis B virus, hepatitis C virus (HCV) and human immunodeficiency virus and cryoglobulins and cryocrit if HCV-positive.

Staging should include

Gastroduodenal endoscopy of any abnormal lesion associated with systematic multiple biopsies. The following tumor analyses from biopsies, performed by an expert pathologist in hematology, are mandatory: (1) Immunohistochemistry panel analysis: CD20, CD3, CD5, CD10, BCL2, kappa/Lambda, CD21 or CD23, BCL6, cyclin D1 and immunoglobulin D; and (2) *H. pylori* testing: The detection of the t (11;18)

Table 1 Paris staging system

	Tumour extension
T1m N0 M0	Mucosa
T1sm N0 M0	Submucosa
T2 N0 M0	Muscularis propria
T3 N0 M0	Serosa
T1-3 N1 M0	Perigastric lymph nodes
T1-3 N2 M0	More distant regional nodes
T4 N0-2 M0	Invasion of adjacent structures with or without abdominal lymph nodes
T1-4 N3 M0	Extra-abdominal lymph nodes
T1-4 N0-3 M1	Distant (non-contiguous) GI sites involvement
T1-4 N0-3 M2	Non-GI sites involvement

T: Tumor; N: Nodes; M: Metastasis; GI: Gastrointestinal

Table 2 Lugano staging system

Stage	
Stage I	Confined to the GI tract (single primary or multiple, non-contiguous)
Stage II	Extension into abdomen
II1	Local nodal involvement
II2	Distant nodal involvement
Stage IIE	Penetration of serosa to involve adjacent organs or tissues
Stage IV	Disseminated extranodal involvement or concomitant supra-diaphragmatic nodal involvement

GI: Gastrointestinal.

(q21;q21) translocation by Fluorescence in situ hybridization is only recommended in case of failure of anti-*H. pylori* antibiotic treatment.

Endoscopic ultrasound is recommended to evaluate gastric wall infiltration and perigastric lymph node involvement.

Imaging includes chest and abdominal computed tomography (CT); Positron emission tomography (PET)/CT is not recommended before the treatment.

H. PYLORI ERADICATION

In a study of 103 patients with stage IE and IIE gastric MALT lymphoma, Moleiro *et al* [13] reported 83% complete response (CR) (78/103) with a mean follow-up of 7 mo (2–63 mo) after *H. pylori* eradication treatment and 86% (67/103) with a mean follow-up time of 105 mo. *H. pylori* infection ($P = 0.004$) and lymphoma location to the antrum/body ($P = 0.016$) were significantly associated with higher and lower CR rates, respectively. Relapse occurred in 11/78 (14%) patients after a mean time-lapse of 21 mo. The absence of *H. pylori* re-infection ($P = 0.038$), the need for only one eradication regimen ($P = 0.009$) and antrum lymphomas ($P = 0.031$) correlated with lower relapse rates. At stage IIE, *H. pylori* eradication was performed in 17/24 patients but only five experienced CR (30%) [13].

A systematic review of 32 publications revealed that CR was achieved in 78% of 1408 patients with low-grade stage I/II1 gastric MALT lymphoma in treated with *H. pylori* eradication [14].

In a Japanese multicenter cohort study, 420 patients with gastric MALT had undergone successful *H. pylori* eradication. Seventy-seven percent (323 patients) responded to *H. pylori* eradication. Absence of *H. pylori*, submucosal invasion and t

(11;18)/API2-MALT1 were independent predictors of resistance to *H. pylori* eradication. Among responders, MALT relapsed in 3% of patients while progressive disease occurred in 27% of non-responders (27/97). After a median follow-up of 6 years, freedom from treatment failure (FFTF), OS and EFS at 10 years were 90%, 95% and 86%, respectively. Peri-gastric lymph node involvement and the depth of tumor infiltration in the gastric wall are factors also associated with a poor tumor response after *H. pylori* eradication[15].

H. pylori disappears usually 6 wk after the start of *H. pylori* eradication, soon after the completion of drug therapy, whereas MALT lymphoma usually takes several months to disappear (median 6 mo; extremes 3-24 mo).

However, if there is no *H. pylori* infection, the remission rate after antibiotic therapy is low (between 15% and 30%).

The translocation t (11;18) (q21;q21)/(API2-MALT1) is observed in 20 to 30% of gastric MALT lymphomas. It is associated with a higher rate of recurrence after eradication. This translocation is also associated with a lower response rate after alkylating-agent-based chemotherapy (90% *vs* 40% approximately), but not with rituximab.

According to ESMO clinical practice guidelines, the presence of *H. pylori* resistance factors, or lack of response to antibiotic therapy are the two main indications to treat with definitive RT. Given the possibility of a delayed response, RT should not be recommended for asymptomatic patients with non-progressive residual disease within the 9-12 mo following successful *H. pylori* eradication therapy. Patients with asymptomatic minimal residual disease may have an indolent course and may not require further treatment.

Some expert groups recommend RT in the case of localized disease and chemotherapy with or without immunotherapy in the case of advanced disease.

RT FOR GASTRIC MALT LYMPHOMA

Results of RT

Indolent NHLs are sensitive to moderate doses of RT. In this literature review, the median delivered dose was 30 Gy (Table 3). For localized gastric lymphomas, exclusive RT in the case of failure of *H. pylori* eradication gives very good results with a complete remission rate of 96% to 100% for a median follow-up of between 1.3 and 4.1 years without long-term side effects. The local tumor control is excellent after exclusive RT with fewer than 5% of patients experiencing local relapse after treatment. Gastric RT is well tolerated with hardly any severe (G3+) acute or late toxicities. Some studies have reported only mild (G1-2) and transient acute gastro-intestinal toxicities.

In the IELSG retrospective multicentric international study, Wirth *et al*[16] reported in 102 patients treated by extended field or whole abdomen RT for gastric MZL and persistent *H. pylori* infection after eradication or *H. pylori*, 88% of FFTF at 10-years. RT median dose delivered to the stomach was 40 Gy (26-46). In this study, RT field size, RT dose, and failure of prior therapy (*H. pylori* eradication, chemotherapy or surgery) were not associated with inferior RT efficacy[16]. Second malignancies were reported in 5 of 41 patients who had gastric/nodal irradiation only, of which two were likely in-field (2 colon), one was likely out of field (bladder) and two had uncertain relationship to field (1 breast, 1 lung).

In a retrospective monocentric study that evaluated the outcome of 32 patients treated for gastric MALT lymphoma with involved site radiation therapy using intensity modulated radiation therapy (IMRT), Pinnix *et al*[17] have reported excellent outcome with 2-year Freedom from local treatment failure, FFTF, and OS of 100%, 100% and 97%, respectively. Moreover, they did not observe any association between the lower 24 Gy dose with FFLTF ($P = 0.819$), FFTF ($P = 0.819$) or OS ($P = 0.469$)[17].

The excellent results and safety of moderate-dose RT, 30 Gy, have been confirmed by the GELD/FFCD prospective study that included 53 patients, all well selected (*H. pylori* eradication failure, *H. pylori* negative). The response rate was very high (98%). After 4.9-years median follow-up, the overall lymphoma survival was 94%[18]. Neither local or distant relapses nor severe acute or late G3+ toxicities were observed.

In a large retrospective monocentric study from the Memorial Sloan Kettering Hospital New York, Teckie *et al*[19] reported very favorable outcome in patients treated for gastric MALT lymphoma by moderate dose of RT (30 Gy). Indeed, gastric location was associated with the best relapse free-survival among patients treated by RT for MZL. After a long follow-up [62 mo (2-256)], local failures occurred in only 7 out of 102 treated patients[19].

Table 3 Studies of radiotherapy for gastric mucosa-associated lymphoid tissue lymphoma

Ref.	Country	Patients, <i>n</i> (%)	Stage	Failure of <i>H. pylori</i> eradication or <i>H. pylori</i>	<i>H. pylori</i>	Median [Total RT dose]	Median F/U (mo)	Survival	Relapse (Local/distant)	Toxicity G3+
Schechter <i>et al</i> [31], 1998	NY, United States	17	IE = 71%; I1 = 24%, I2 = 5%	17/17	12/17	30 Gy [28.5–43.5]	27 [11–68]	NR	0/0	0
Park <i>et al</i> [32], 2002	Korea	6	IE = 100%	4/6	1/6	30.6 Gy [30–39]	12	100%	0/0	0
Tsang <i>et al</i> [33], 2003	Canada	13/93 (gastric and RT subgroup)	IA = 88%; IIA = 10%, IIB = 2%	13/13	7/15	26.2 [20–35]	61	98% at 5 yr for the entire cohort	0/0	0
Koch <i>et al</i> [24], 2005	Germany	144/332 (indolent subgroup with conservative management)	I = 66%; I1 = 17%; I2 = 17%	NR	NR	40 Gy	42 [0.07–97.4]	93% at 3.5 yr	6	9
Avilés <i>et al</i> [34], 2005	Mexico	78/241 (RT group)	IE = 73%; IIE = 27%	NR	NR	40 Gy	90 [58–139]	75% at 10 yr	0/30	0
Sugimoto <i>et al</i> [35], 2006	Japan	3	I = 3	3/3	0	39 Gy [36–40]	42 [24–72]	100%	0/0	0
Tsai <i>et al</i> [36], 2007	MA, United States	18/77 gastric and RT subgroup	IE = 100%	6/18	NR	30 Gy [18–40]	61 [2–177]	91% at 5 yr for the entire cohort	0 over 11 patients treated by RT	NR
Yamashita <i>et al</i> [37], 2008	Japan	11/41 gastric subgroup	IE = 90%; IIE = 10% (whole cohort)	6/11	5/11	30 Gy	32 [2–162]	100%	0/0	0
Vrieling <i>et al</i> [38], 2008	The Netherlands	68/115 (RT subgroup)	I = 79%; I1 = 12%, I2 = 9%	85/115	13/115	40 Gy [31–44]	150 [7–301] (radiotherapy only cohort)	78% at 5 yr (entire cohort)	3/4	NR
Gobbi <i>et al</i> [39], 2009	Italy	5	IE = 4; IIE = 1	5/5	0/5	30 Gy	48 [21–70]	80%	0	0
Tomita <i>et al</i> [40], 2009	Japan	20/50 (gastric subgroup)	IE = 96%; IIE = 4% (entire cohort)	20/20	7/20	32 Gy [25.6–50]	92	97% at 5 yr (entire cohort)	0	2% for all cohort
Goda <i>et al</i> [41], 2010	Canada	25/167 (gastric subgroup)	IA = 90%; IIA = 9%; IIB = 1%	19/19	5/19	30 Gy [20–35]	89 [8–194]	95% at 5-yr (entire cohort)	0	NR
Okada <i>et al</i> [42], 2012	Japan	22	IE = 19; IIE = 3	22/22	14/22	30 Gy	74 [27–159]	91% at 5-yr	0/3	0
Kim <i>et al</i> [43]; 2013	Korea	64	IE = 53 (83%); IIE = 11 (17%)	56/60	33/64	36 Gy	39 [9–131]	94% at 5-yr	5	0
Wirth <i>et al</i> [16], 2013	International	102	IE = 84%; IIE =	80/102	45/90	40 Gy [26–46]	95 [4–528]	70% at 10 yr	7/5	NR

	(IELSG)		16%							
Nam <i>et al</i> [44], 2014	Korea	41 (MALT subgroup)	IE = 77%; IIE = 23%	29/41	29.6% (whole cohort)	30.6 Gy [30.6-43.2]	48 [6-158]	90% at 5-yr (entire cohort)	1/0	0
Abe <i>et al</i> [45], 2013	Japan	34	IE = 34 (100%)	34/34	17/34	30 Gy	90 (14-156)	100% at 5-yr	1 (emergency gastrectomy during RT at 15 Gy for acute bleeding)/0	1
Ruskoné-Fourmestraux <i>et al</i> [18], 2015	France	53	IE = 45 (85%); IIE = 8 (15%)	53/53	15/53	30 Gy	59 (4-199)	94% at 5-yr	0/0	0
Lim <i>et al</i> [46], 2016	Korea	33	IE = 30 (91%); IIE = 3 (9%)	33/33	17/33	30.6 Gy	50 (12-145)	97% at 5-yr	0	0
Ohkubo <i>et al</i> [47], 2017	Japan	27	IE = 27 (100%)	24/27	15/27	30 Gy [30-39.5]	121 (8-176)	92% at 5-yr; 87% at 10-yr	0/2	2/27 (White blood cell count decreases)
Teckie <i>et al</i> [48], 2017	NY, United States	122/225 (gastric and RT subgroup)	IE = 225 (92%); IIE = 19 (8%)	115/122	78/122	30 Gy	62 [2-256]	92% at 5-yr; 79% at 10-yr for all the subgroups	7 (gastric subgroup)	NR
Pinnix <i>et al</i> [17], 2019	TX, United States	32	IE = 25(78%); IIE = 5 (16%); IV = 2 (6%)	32/32	25/32	36 Gy (2; 6%); 30 Gy (n = 19; 59%); 24 Gy (n = 11; 34%)	55 [32-78]	97% at 2-yr	1/1	NR
Schmelz <i>et al</i> [49], 2019	Germany	22	IE = 20; IIE = 2	22/22	0/22	25.2 Gy/36 Gy	79 [36.4 -143.8]	100% at 56.6 yr	0	NR
Watanabe <i>et al</i> [50], 2020	Japan	30/34 (gastric subgroup)	IE = 100%	26/30	16/30	30 Gy [30-40]	61 [9-136]	94.7% at 5 yr	0/2	0

RT: Radiotherapy; NR: Not reported; *H. pylori*: *Helicobacter pylori*.

The main weaknesses of most of the studies reported in this review are, their retrospective nature, often monocentric, their small sample size, their short follow-up and that some studies have included patients who had not failed to *H. pylori* eradication.

The median delivered dose in this literature review is in accordance with the ILROG guidelines: 30-30.6 Gy in conventional fractionation (1.8 to 2 Gy/d and 5 d *per week*) on gastric and peri gastric lymph node volumes (involved site RT)[20]. During RT, proton pump inhibitor and 5-HT3 serotonin receptor antagonist are recommended to prevent acute side effects.

RT treatment planification

CT Simulation: Patients must be simulated and treated with an empty stomach after a fast of at least 4 h or overnight.

Patients should be simulated supine with arms up using customized immobilization device.

A small volume (50 cc) of oral contrast medium should be used.

CT images should be acquired before and after oral contrast medium.

Intravenous contrast medium injection is recommended in case of lymph nodes involvement.

In order to reduce margins, respiratory motion should be assessed with 4D-CT.

Volume definition (ILROG recommendations)

The gross tumor volume corresponds to the gastric tumor and the macroscopically invaded lymph nodes determined on CT or PET-CT.

Because gastric MALT lymphoma is often associated with multifocal involvement of the stomach and may spread to regional lymph nodes, radiation volumes should include the entire stomach as well as the perigastric lymph nodes of the lesser and greater curvatures.

The clinical target volume (CTV) corresponds to the entire stomach from the gastroesophageal junction to the duodenal bulb; the whole gastric wall and the perigastric lymph nodes must be included.

The internal target volume needs to be determined by 4D-CT in order to take into account stomach mobility during breathing.

In the absence of 4D-CT, 2 cm margins should be added to the CTV to take into account the respiratory movement of the stomach.

For the planning target volume (PTV), an additional margin of 0.5 to 1 cm should be added, to take into account setup variation.

In order to reduce the margins due to respiratory movements, modern irradiation techniques such as deep-inspiratory breath-hold (DIBH) and 4D-Cone Beam Computed Tomography (CBCT)-Image Guided Radiation Therapy, should be used. In a retrospective study of 10 patients treated for gastric NHL including 5 MALT and 5 DLBCL, Christopherson *et al*[21] have reported that DIBH led to reduced dose to the heart and the kidneys, through improved spatial separation between the heart and the stomach, while simultaneously allowing for reduced target volumes, without compromising target coverage or increasing dose to other organs at risk (OAR)[21].

Shimohigashi *et al*[22] reported that the use of 4D-CBCT reduced the PTV when applying 4D soft-tissue matching, compared to skin and bone matchings. Based on these results, authors recommended daily 4D-CBCT during RT treatment[22].

The following OAR should be delineated: Liver, kidneys, bowels, heart, lungs and spinal cord. 3D conformal RT, IMRT or VMAT (Figure 3), are recommended to reduce the dose delivered to the kidneys and liver.

Prescribed dose

The median delivered dose in this literature review is in agreement with the ILROG guidelines: 30-30.6 Gy in conventional fractionation (1.8 to 2 Gy/d and 5 d *per week*) on gastric and perigastric lymph node volumes (involved site RT)[23].

Prevention of side effects

During RT, proton pump inhibitor and 5-HT3 serotonin receptor antagonist are recommended to prevent acute side effects.

OTHER TREATMENT APPROCHES

Surgery

In the GIT NHL 02/96 multicentric non-randomized German study, Koch *et al*[24] have reported no survival advantage at 42 mo of surgery ± adjuvant RT in case of R1/R2 resection grade or stage II disease in comparison with exclusive RT without surgery in 144 patients treated for localized primary gastric indolent lymphoma (86% *vs* 91%)[24].

In clinical practice, surgical treatment is rarely indicated. The only current indications are emergency situations such as perforation or uncontrolled bleeding in endoscopy.

Systemic therapy

In the IELSG-19 randomized trial that included 401 patients with localized or disseminated gastric and non-gastric MALT lymphoma, the combination of rituximab and

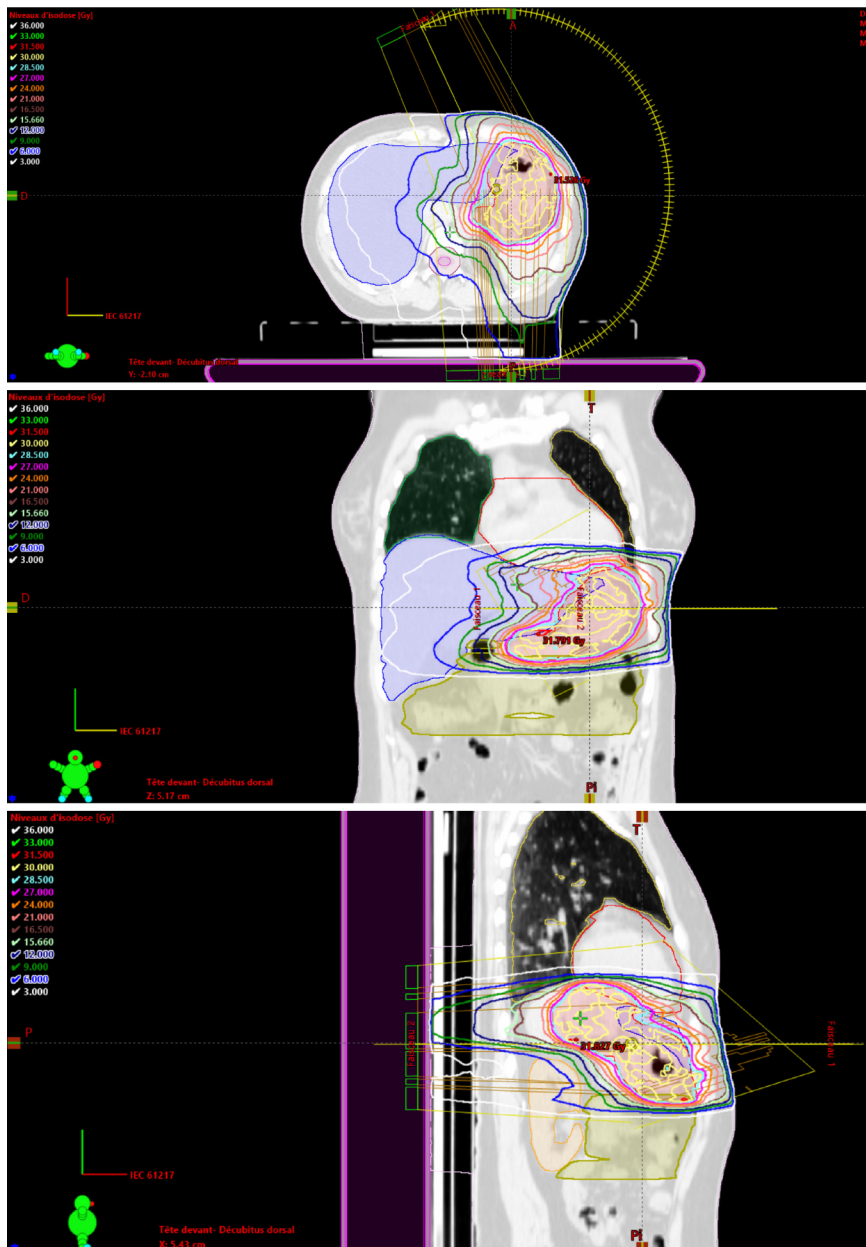


Figure 3 Example of dose distribution using volumetric modulated arc therapy in gastric mucosa-associated lymphoid tissue lymphoma.

chlorambucil was significantly superior to chlorambucil monotherapy and rituximab monotherapy in terms of response rate [79% *vs* 63% *vs* 56%, respectively ($P < 0.001$)], EFS (68% *vs* 51% *vs* 51%, $P = 0.0009$) and progression-free survival at 5 years (72% *vs* 59% *vs* 57%, $P = 0.0119$). Five-year OS was approximately 90% in each arm. All treatments were well tolerated. No unexpected toxicities were reported[23].

In the MALT2008-01 phase II Spanish multicentric study that included 57 patients with localized or disseminated gastric and non-gastric MALT lymphoma, the combination of bendamustine and rituximab for first-line systemic treatment resulted in a complete or unconfirmed CR rates of 98% and an EFS at 4 years of 88%. Progression-free survival at 4 years was 93% with no differences between patients with gastric and non-gastric sites[25].

Watchful waiting

Long-term complications after treatment of indolent lymphomas have been reported, including a significant increase in secondary cancers. The risk of recurrence in patients with minimal residual gastric MALT lymphoma after successful eradication of *H. pylori* without oncological treatment, is low. Watchful waiting with regular endoscopies and biopsies could therefore be considered, particularly in elderly patients or in patients with comorbidity[26]. This decision to treat or not, should be

discussed in the setting of a multidisciplinary meeting.

FOLLOW-UP

Follow-up after treatment of localized gastric-MALT is based on upper gastrointestinal endoscopy. The follow-up differs slightly between expert groups.

NCCN recommendations

Endoscopic control 3 mo after RT: In case of CR: Clinical follow-up every 3–6 mo for 5 years and then yearly or as clinically indicated.

The timing of endoscopy and imaging is not determined: They should be decided on according to clinical symptoms.

ESMO recommendations

Following RT treatment, endoscopic controls with gastric biopsies and systemic follow-up (clinical examination, blood counts) every 12–18 mo are recommended.

Follow-up after *H. pylori* eradication

Following the documentation of *H. pylori* eradication, strict endoscopic follow-up is recommended, with multiple biopsies taken 2–3 mo after treatment to rule out tumor progression, and subsequently every 6 mo for 2 years to monitor the histological regression of the gastric lymphoma.

Because of its reliability, it is recommended to use the GELA histological scoring system for post-therapy biopsies evaluation[27]. Comparison with previous biopsies is helpful to assess response.

SECONDARY GASTRIC CANCERS

In spite of the excellent cure rate, long-term follow-up by endoscopy is required as cases of gastric adenocarcinomas have been reported during follow-up of cured lymphomas[26,28,29]. Moreover, the Dutch epidemiological study by Capelle *et al*[30] found a 6-fold increase in the risk of gastric adenocarcinoma compared to the general population in patients with a history of gastric lymphoma regardless of treatment. This risk was 16.6 times higher in patients with gastric MALT lymphoma aged between 45 and 59 years than in the Dutch population ($P < 0.001$)[30].

CONCLUSION

RT is a highly effective treatment in the management of localized gastric MALT lymphomas resistant to *H. pylori* eradication with a cure rate close to 100% and no major toxicity. Long follow-up with gastric endoscopy monitoring is necessary to diagnose at an early stage the potential occurrence of gastric adenocarcinoma.

ACKNOWLEDGEMENTS

The authors would like to thank Mr. Abdellah El Mouqaddem, a physicist from our department, for the dosimetry using VMAT technique presented in this article.

REFERENCES

- 1 **Zucca E**, Bertoni F. The spectrum of MALT lymphoma at different sites: biological and therapeutic relevance. *Blood* 2016; **127**: 2082–2092 [PMID: 26989205 DOI: 10.1182/blood-2015-12-624304]
- 2 **Khalili M**, Sakhaee E, Aflatoonian MR, Abdollahpour G, Tabrizi SS, Damaneh EM, Hossini-Nasab S. Seroprevalence of bovine leptospiral antibodies by microscopic agglutination test in Southeast of Iran. *Asian Pac J Trop Biomed* 2014; **4**: 354–357 [PMID: 25182718 DOI: 10.12980/APJTB.4.2014C1206]
- 3 **NIH**. SEER Preliminary Cancer Incidence Rate Estimates for 2017, and diagnosis years 2000 to 2017: Cancer Stat Facts: Non-Hodgkin Lymphoma. Surveillance Epidemiology and End Results

- Program: National Cancer Institute Bethesda MD, 2020. [cited 10 February 2021]. Available from: <https://seer.cancer.gov/statistics/preliminary-estimates/>
- 4 **Müller AM**, Ihorst G, Mertelsmann R, Engelhardt M. Epidemiology of non-Hodgkin's lymphoma (NHL): trends, geographic distribution, and etiology. *Ann Hematol* 2005; **84**: 1-12 [PMID: [15480663](#) DOI: [10.1007/s00277-004-0939-7](#)]
 - 5 **Thieblemont C**, Cascione L, Conconi A, Kiesewetter B, Raderer M, Gaidano G, Martelli M, Laszlo D, Coiffier B, Lopez Guillermo A, Torri V, Cavalli F, Johnson PW, Zucca E. A MALT lymphoma prognostic index. *Blood* 2017; **130**: 1409-1417 [PMID: [28720586](#) DOI: [10.1182/blood-2017-03-771915](#)]
 - 6 **Hooi JKY**, Lai WY, Ng WK, Suen MMY, Underwood FE, Tanyingoh D, Malfertheiner P, Graham DY, Wong VWS, Wu JCY, Chan FKL, Sung JY, Kaplan GG, Ng SC. Global Prevalence of Helicobacter pylori Infection: Systematic Review and Meta-Analysis. *Gastroenterology* 2017; **153**: 420-429 [PMID: [28456631](#) DOI: [10.1053/j.gastro.2017.04.022](#)]
 - 7 **Doglioni C**, Wotherspoon AC, Moschini A, de Boni M, Isaacson PG. High incidence of primary gastric lymphoma in northeastern Italy. *Lancet* 1992; **339**: 834-835 [PMID: [1347858](#) DOI: [10.1016/0140-6736\(92\)90280-g](#)]
 - 8 **Luminari S**, Cesaretti M, Marcheselli L, Rashid I, Madrigali S, Maiorana A, Federico M. Decreasing incidence of gastric MALT lymphomas in the era of anti-Helicobacter pylori interventions: results from a population-based study on extranodal marginal zone lymphomas. *Ann Oncol* 2010; **21**: 855-859 [PMID: [19850642](#) DOI: [10.1093/annonc/mdp402](#)]
 - 9 **Raderer M**, Wöhrer S, Kiesewetter B, Dolak W, Lagler H, Wotherspoon A, Muellauer L, Chott A. Antibiotic treatment as sole management of Helicobacter pylori-negative gastric MALT lymphoma: a single center experience with prolonged follow-up. *Ann Hematol* 2015; **94**: 969-973 [PMID: [25579756](#) DOI: [10.1007/s00277-014-2298-3](#)]
 - 10 **Sena Teixeira Mendes L**, D Attygalle A, C Wotherspoon A. Helicobacter pylori infection in gastric extranodal marginal zone lymphoma of mucosa-associated lymphoid tissue (MALT) lymphoma: a re-evaluation. *Gut* 2014; **63**: 1526-1527 [PMID: [24951256](#) DOI: [10.1136/gutjnl-2014-307389](#)]
 - 11 **Rohatiner A**, d'Amore F, Coiffier B, Crowther D, Gospodarowicz M, Isaacson P, Lister TA, Norton A, Salem P, Shipp M. Report on a workshop convened to discuss the pathological and staging classifications of gastrointestinal tract lymphoma. *Ann Oncol* 1994; **5**: 397-400 [PMID: [8075046](#) DOI: [10.1093/oxfordjournals.annonc.a058869](#)]
 - 12 **Ruskoné-Fourmestraux A**, Fischbach W, Aleman BM, Boot H, Du MQ, Megraud F, Montalban C, Raderer M, Savio A, Wotherspoon A; EGILS group. EGILS consensus report. Gastric extranodal marginal zone B-cell lymphoma of MALT. *Gut* 2011; **60**: 747-758 [PMID: [21317175](#) DOI: [10.1136/gut.2010.224949](#)]
 - 13 **Moleiro J**, Ferreira S, Lage P, Dias Pereira A. Gastric malt lymphoma: Analysis of a series of consecutive patients over 20 years. *United European Gastroenterol J* 2016; **4**: 395-402 [PMID: [27403306](#) DOI: [10.1177/2050640615612934](#)]
 - 14 **Zullo A**, Hassan C, Cristofari F, Andriani A, De Francesco V, Ierardi E, Tomao S, Stolte M, Morini S, Vaira D. Effects of Helicobacter pylori eradication on early stage gastric mucosa-associated lymphoid tissue lymphoma. *Clin Gastroenterol Hepatol* 2010; **8**: 105-110 [PMID: [19631287](#) DOI: [10.1016/j.cgh.2009.07.017](#)]
 - 15 **Nakamura S**, Sugiyama T, Matsumoto T, Iijima K, Ono S, Tajika M, Tari A, Kitadai Y, Matsumoto H, Nagaya T, Kamoshida T, Watanabe N, Chiba T, Origasa H, Asaka M; JAPAN GAST Study Group. Long-term clinical outcome of gastric MALT lymphoma after eradication of Helicobacter pylori: a multicentre cohort follow-up study of 420 patients in Japan. *Gut* 2012; **61**: 507-513 [PMID: [21890816](#) DOI: [10.1136/gutjnl-2011-300495](#)]
 - 16 **Wirth A**, Gospodarowicz M, Aleman BM, Bressel M, Ng A, Chao M, Hoppe RT, Thieblemont C, Tsang R, Moser L, Specht L, Szpytma T, Lennard A, Seymour JF, Zucca E. Long-term outcome for gastric marginal zone lymphoma treated with radiotherapy: a retrospective, multi-centre, International Extranodal Lymphoma Study Group study. *Ann Oncol* 2013; **24**: 1344-1351 [PMID: [23293112](#) DOI: [10.1093/annonc/mds623](#)]
 - 17 **Pinnix CC**, Gunther JR, Milgrom SA, Cruz Chamorro RJ, Medeiros LJ, Khoury JD, Amini B, Neelapu S, Lee HJ, Westin J, Fowler N, Nastoupil L, Dabaja B. Outcomes After Reduced-Dose Intensity Modulated Radiation Therapy for Gastric Mucosa-Associated Lymphoid Tissue (MALT) Lymphoma. *Int J Radiat Oncol Biol Phys* 2019; **104**: 447-455 [PMID: [30769175](#) DOI: [10.1016/j.ijrobp.2019.02.002](#)]
 - 18 **Ruskoné-Fourmestraux A**, Matysiak-Budnik T, Fabiani B, Cervera P, Brixi H, Le Malicot K, Nion-Larmurier I, Fléjou JF, Hennequin C, Quéro L; Groupe d'Étude des Lymphomes Digestifs (GELD) & Fédération Francophone de Cancérologie Digestive. Exclusive moderate-dose radiotherapy in gastric marginal zone B-cell MALT lymphoma: Results of a prospective study with a long term follow-up. *Radiother Oncol* 2015; **117**: 178-182 [PMID: [26395311](#) DOI: [10.1016/j.radonc.2015.08.029](#)]
 - 19 **Teckie S**, Qi S, Lovie S, Navarrett S, Hsu M, Noy A, Portlock C, Yahalom J. Long-term outcomes and patterns of relapse of early-stage extranodal marginal zone lymphoma treated with radiation therapy with curative intent. *Int J Radiat Oncol Biol Phys* 2015; **92**: 130-137 [PMID: [25863760](#) DOI: [10.1016/j.ijrobp.2015.01.040](#)]
 - 20 **Wirth A**, Mikhaeel NG, Aleman BMP, Pinnix CC, Constine LS, Ricardi U, Illidge TM, Eich HT, Hoppe BS, Dabaja B, Ng AK, Kirova Y, Berthelsen AK, Dieckmann K, Yahalom J, Specht L. Involved Site Radiation Therapy in Adult Lymphomas: An Overview of International Lymphoma

- Radiation Oncology Group Guidelines. *Int J Radiat Oncol Biol Phys* 2020; **107**: 909-933 [PMID: 32272184 DOI: 10.1016/j.ijrobp.2020.03.019]
- 21 **Christopherson KM**, Gunther JR, Fang P, Peterson SL, Roach KE, Wong PF, Mirkovic D, Lim TY, Wang H, Wang XA, Wang C, Garcia J, Dabaja BS, Pinnix CC. Decreased heart dose with deep inspiration breath hold for the treatment of gastric lymphoma with IMRT. *Clin Transl Radiat Oncol* 2020; **24**: 79-82 [PMID: 32642563 DOI: 10.1016/j.ctro.2020.05.013]
- 22 **Shimohigashi Y**, Toya R, Saito T, Kono Y, Doi Y, Fukugawa Y, Watakabe T, Matsumoto T, Kai Y, Maruyama M, Oya N. Impact of four-dimensional cone-beam computed tomography on target localization for gastric mucosa-associated lymphoid tissue lymphoma radiotherapy: reducing planning target volume. *Radiat Oncol* 2021; **16**: 14 [PMID: 33446225 DOI: 10.1186/s13014-020-01734-w]
- 23 **Zucca E**, Conconi A, Martinelli G, Bouabdallah R, Tucci A, Vitolo U, Martelli M, Pettengell R, Salles G, Sebban C, Guillermo AL, Pinotti G, Devizzi L, Morschhauser F, Tilly H, Torri V, Hohaus S, Ferreri AJM, Zachée P, Bosly A, Haioun C, Stelitano C, Bellei M, Ponzoni M, Moreau A, Jack A, Campo E, Mazzucchelli L, Cavalli F, Johnson P, Thieblemont C. Final Results of the IELSG-19 Randomized Trial of Mucosa-Associated Lymphoid Tissue Lymphoma: Improved Event-Free and Progression-Free Survival With Rituximab Plus Chlorambucil Versus Either Chlorambucil or Rituximab Monotherapy. *J Clin Oncol* 2017; **35**: 1905-1912 [PMID: 28355112 DOI: 10.1200/JCO.2016.70.6994]
- 24 **Koch P**, Probst A, Berdel WE, Willich NA, Reinartz G, Brockmann J, Liersch R, del Valle F, Clasen H, Hirt C, Breitsprecher R, Schmits R, Freund M, Fietkau R, Ketterer P, Freitag EM, Hinkelbein M, Heinecke A, Parwaresch R, Tiemann M. Treatment results in localized primary gastric lymphoma: data of patients registered within the German multicenter study (GIT NHL 02/96). *J Clin Oncol* 2005; **23**: 7050-7059 [PMID: 16129843 DOI: 10.1200/JCO.2005.04.031]
- 25 **Salar A**, Domingo-Domenech E, Panizo C, Nicolás C, Bargay J, Muntanola A, Canales M, Bello JL, Sancho JM, Tomás JF, Rodríguez MJ, Peñalver FJ, Grande C, Sánchez-Blanco JJ, Palomera L, Arranz R, Conde E, García M, García JF, Caballero D, Montalbán C; Grupo Español de Linfomas/Trasplante de Médula Ósea (GELTAMO). First-line response-adapted treatment with the combination of bendamustine and rituximab in patients with mucosa-associated lymphoid tissue lymphoma (MALT2008-01): a multicentre, single-arm, phase 2 trial. *Lancet Haematol* 2014; **1**: e104-e111 [PMID: 27029228 DOI: 10.1016/S2352-3026(14)00021-0]
- 26 **Fischbach W**, Goebeler ME, Ruskone-Fourmestiaux A, Wündisch T, Neubauer A, Raderer M, Savio A; EGILS (European Gastro-Intestinal Lymphoma Study) Group. Most patients with minimal histological residuals of gastric MALT lymphoma after successful eradication of *Helicobacter pylori* can be managed safely by a watch and wait strategy: experience from a large international series. *Gut* 2007; **56**: 1685-1687 [PMID: 17639089 DOI: 10.1136/gut.2006.096420]
- 27 **Copie-Bergman C**, Wotherspoon AC, Capella C, Motta T, Pedrinis E, Pileri SA, Bertoni F, Conconi A, Zucca E, Ponzoni M, Ferreri AJ. Gela histological scoring system for post-treatment biopsies of patients with gastric MALT lymphoma is feasible and reliable in routine practice. *Br J Haematol* 2013; **160**: 47-52 [PMID: 23043300 DOI: 10.1111/bjh.12078]
- 28 **Copie-Bergman C**, Locher C, Levy M, Chaumette MT, Haioun C, Delfau-Larue MH, Leroy K, Gaulard P, Delchier JC. Metachronous gastric MALT lymphoma and early gastric cancer: is residual lymphoma a risk factor for the development of gastric carcinoma? *Ann Oncol* 2005; **16**: 1232-1236 [PMID: 15890667 DOI: 10.1093/annonc/mdi242]
- 29 **Zullo A**, Hassan C, Andriani A, Cristofari F, Cardinale V, Spinelli GP, Tomao S, Morini S. Primary low-grade and high-grade gastric MALT-lymphoma presentation. *J Clin Gastroenterol* 2010; **44**: 340-344 [PMID: 19745757 DOI: 10.1097/MCG.0b013e3181b4b1ab]
- 30 **Capelle LG**, de Vries AC, Looman CW, Casparie MK, Boot H, Meijer GA, Kuipers EJ. Gastric MALT lymphoma: epidemiology and high adenocarcinoma risk in a nation-wide study. *Eur J Cancer* 2008; **44**: 2470-2476 [PMID: 18707866 DOI: 10.1016/j.ejca.2008.07.005]
- 31 **Schechter NR**, Portlock CS, Yahalom J. Treatment of mucosa-associated lymphoid tissue lymphoma of the stomach with radiation alone. *J Clin Oncol* 1998; **16**: 1916-1921 [PMID: 9586910 DOI: 10.1200/JCO.1998.16.5.1916]
- 32 **Park HC**, Park W, Hahn JS, Kim CB, Lee YC, Noh JK, Suh CO. Low grade MALT lymphoma of the stomach: treatment outcome with radiotherapy alone. *Yonsei Med J* 2002; **43**: 601-606 [PMID: 12402372 DOI: 10.3349/ymj.2002.43.5.601]
- 33 **Tsang RW**, Gospodarowicz MK, Pintilie M, Wells W, Hodgson DC, Sun A, Crump M, Patterson BJ. Localized mucosa-associated lymphoid tissue lymphoma treated with radiation therapy has excellent clinical outcome. *J Clin Oncol* 2003; **21**: 4157-4164 [PMID: 14615444 DOI: 10.1200/JCO.2003.06.085]
- 34 **Avilés A**, Nambo MJ, Neri N, Talavera A, Cleto S. Mucosa-associated lymphoid tissue (MALT) lymphoma of the stomach: results of a controlled clinical trial. *Med Oncol* 2005; **22**: 57-62 [PMID: 15750197 DOI: 10.1385/MO.22.1.057]
- 35 **Sugimoto M**, Kajimura M, Shirai N, Furuta T, Kanaoka S, Ikuma M, Sato Y, Hishida A. Outcome of radiotherapy for gastric mucosa-associated lymphoid tissue lymphoma refractory to *Helicobacter pylori* eradication therapy. *Intern Med* 2006; **45**: 405-409 [PMID: 16617193 DOI: 10.2169/internalmedicine.45.1473]
- 36 **Tsai HK**, Li S, Ng AK, Silver B, Stevenson MA, Mauch PM. Role of radiation therapy in the treatment of stage I/II mucosa-associated lymphoid tissue lymphoma. *Ann Oncol* 2007; **18**: 672-678 [PMID: 17218489 DOI: 10.1093/annonc/mdl468]

- 37 **Yamashita H**, Nakagawa K, Asari T, Murakami N, Igaki H, Ohtomo K. Radiotherapy for 41 patients with stages I and II MALT lymphoma: a retrospective study. *Radiother Oncol* 2008; **87**: 412-417 [PMID: 18423914 DOI: 10.1016/j.radonc.2008.03.012]
- 38 **Vrieling C**, de Jong D, Boot H, de Boer JP, Wegman F, Aleman BM. Long-term results of stomach-conserving therapy in gastric MALT lymphoma. *Radiother Oncol* 2008; **87**: 405-411 [PMID: 18343513 DOI: 10.1016/j.radonc.2008.02.012]
- 39 **Gobbi PG**, Corbella F, Valentino F, Bergonzi M, Sangalli C, Perfetti V, Corazza GR. Complete long-term response to radiotherapy of gastric early-stage marginal zone lymphoma resistant to both anti-*Helicobacter pylori* antibiotics and chemotherapy. *Ann Oncol* 2009; **20**: 465-468 [PMID: 19074214 DOI: 10.1093/annonc/mdn668]
- 40 **Tomita N**, Kodaira T, Tachibana H, Nakamura T, Mizoguchi N, Takada A. Favorable outcomes of radiotherapy for early-stage mucosa-associated lymphoid tissue lymphoma. *Radiother Oncol* 2009; **90**: 231-235 [PMID: 19135751 DOI: 10.1016/j.radonc.2008.12.004]
- 41 **Goda JS**, Gospodarowicz M, Pintilie M, Wells W, Hodgson DC, Sun A, Crump M, Tsang RW. Long-term outcome in localized extranodal mucosa-associated lymphoid tissue lymphomas treated with radiotherapy. *Cancer* 2010; **116**: 3815-3824 [PMID: 20564130 DOI: 10.1002/cncr.25226]
- 42 **Okada H**, Takemoto M, Kawahara Y, Nasu J, Takenaka R, Kawano S, Inoue M, Ichimura K, Tanaka T, Shinagawa K, Yoshino T, Yamamoto K. A prospective analysis of efficacy and long-term outcome of radiation therapy for gastric mucosa-associated lymphoid tissue lymphoma. *Digestion* 2012; **86**: 179-186 [PMID: 22907329 DOI: 10.1159/000339497]
- 43 **Kim SW**, Lim DH, Ahn YC, Kim WS, Kim SJ, Ko YH, Kim KM. Clinical outcomes of radiation therapy for early-stage gastric mucosa-associated lymphoid tissue lymphoma. *World J Gastroenterol* 2013; **19**: 6062-6068 [PMID: 24106407 DOI: 10.3748/wjg.v19.i36.6062]
- 44 **Nam TK**, Ahn JS, Choi YD, Jeong JU, Kim YH, Yoon MS, Song JY, Ahn SJ, Chung WK. The role of radiotherapy in the treatment of gastric mucosa-associated lymphoid tissue lymphoma. *Cancer Res Treat* 2014; **46**: 33-40 [PMID: 24520221 DOI: 10.4143/crt.2014.46.1.33]
- 45 **Abe S**, Oda I, Inaba K, Suzuki H, Yoshinaga S, Nonaka S, Morota M, Murakami N, Itami J, Kobayashi Y, Maeshima AM, Saito Y. A retrospective study of 5-year outcomes of radiotherapy for gastric mucosa-associated lymphoid tissue lymphoma refractory to *Helicobacter pylori* eradication therapy. *Jpn J Clin Oncol* 2013; **43**: 917-922 [PMID: 23878345 DOI: 10.1093/jjco/hyt097]
- 46 **Lim HW**, Kim TH, Choi IJ, Kim CG, Lee JY, Cho SJ, Eom HS, Moon SH, Kim DY. Radiation therapy for gastric mucosa-associated lymphoid tissue lymphoma: dose-volumetric analysis and its clinical implications. *Radiat Oncol J* 2016; **34**: 193-201 [PMID: 27730803 DOI: 10.3857/roj.2016.01865]
- 47 **Ohkubo Y**, Saito Y, Ushijima H, Onishi M, Kazumoto T, Saitoh JI, Kubota N, Kobayashi H, Maseki N, Nishimura Y, Kurosumi M. Radiotherapy for localized gastric mucosa-associated lymphoid tissue lymphoma: long-term outcomes over 10 years. *J Radiat Res* 2017; **58**: 537-542 [PMID: 28077625 DOI: 10.1093/jrr/rrw044]
- 48 **Teckie S**, Qi S, Chelius M, Lovie S, Hsu M, Noy A, Portlock C, Yahalom J. Long-term outcome of 487 patients with early-stage extra-nodal marginal zone lymphoma. *Ann Oncol* 2017; **28**: 1064-1069 [PMID: 28327924 DOI: 10.1093/annonc/mdx025]
- 49 **Schmelz R**, Miehke S, Thiede C, Brueckner S, Dawel M, Kuhn M, Ruskoné-Formestaux A, Stolte M, Jentsch C, Hampe J, Morgner A. Sequential H. pylori eradication and radiation therapy with reduced dose compared to standard dose for gastric MALT lymphoma stages IE & IIE: a prospective randomized trial. *J Gastroenterol* 2019; **54**: 388-395 [PMID: 30327875 DOI: 10.1007/s00535-018-1517-4]
- 50 **Watanabe S**, Ogino I, Hata M. Radiotherapy for non-gastric intestinal vs gastric MALT lymphoma: a comparison of treatment outcomes. *Blood Res* 2020; **55**: 200-205 [PMID: 33139588 DOI: 10.5045/br.2020.2020174]



Published by **Baishideng Publishing Group Inc**
7041 Koll Center Parkway, Suite 160, Pleasanton, CA 94566, USA

Telephone: +1-925-3991568

E-mail: bpgoffice@wjgnet.com

Help Desk: <https://www.f6publishing.com/helpdesk>

<https://www.wjgnet.com>

