

# World Journal of *Gastrointestinal Oncology*

*World J Gastrointest Oncol* 2021 October 15; 13(10): 1213-1543



**FRONTIER**

- 1213** Engineering nanotheranostic strategies for liver cancer

*Cao L, Zhu YQ, Wu ZX, Wang GX, Cheng HW*

**REVIEW**

- 1229** Role of autophagy in cholangiocarcinoma: An autophagy-based treatment strategy

*Koustas E, Trifylli EM, Sarantis P, Papavassiliou AG, Karamouzis MV*

- 1244** Role of autophagy in gastric carcinogenesis

*Papaefthymiou A, Christodoulidis G, Koffas A, Doulberis M, Polyzos SA, Manolakis A, Potamianos S, Kapsoritakis A, Kountouras J*

- 1263** Liquid biopsy approach to pancreatic cancer

*Perales S, Torres C, Jimenez-Luna C, Prados J, Martinez-Galan J, Sanchez-Manas JM, Caba O*

- 1288** Molecular testing for colorectal cancer: Clinical applications

*Imyanitov E, Kuligina E*

- 1302** New frontiers in liver ultrasound: From mono to multi parametricity

*Bartolotta TV, Taibbi A, Randazzo A, Gagliardo C*

- 1317** Gallbladder cancer: Historical treatment and new management options

*Okumura K, Gogna S, Gachabayov M, Felsenreich DM, McGuirk M, Rojas A, Quintero L, Seshadri R, Gu K, Dong XD*

- 1336** Review of incidence and outcomes of treatment of cholangiocarcinoma in patients with primary sclerosing cholangitis

*Saffioti F, Mavroedis VK*

- 1367** Diverse roles of FOXO family members in gastric cancer

*Chen YH, Li CL, Chen WJ, Liu J, Wu HT*

**MINIREVIEWS**

- 1383** Endoscopic radiofrequency ablation for malignant biliary obstruction

*Jarosova J, Macinga P, Hujova A, Kral J, Urban O, Spicak J, Hucl T*

- 1397** Thermal ablation and immunotherapy for hepatocellular carcinoma: Recent advances and future directions

*Bo XW, Sun LP, Yu SY, Xu HX*

- 1412** Lateral pelvic lymph nodes for rectal cancer: A review of diagnosis and management

*Ogawa S, Itabashi M, Inoue Y, Ohki T, Bamba Y, Koshino K, Nakagawa R, Tani K, Aihara H, Kondo H, Yamaguchi S, Yamamoto M*

- 1425** Proliferating cell nuclear antigen clamp associated factor, a potential proto-oncogene with increased expression in malignant gastrointestinal tumors  
*Liu LJ, Liao JM, Zhu F*
- 1440** Nutritional therapy for hepatocellular carcinoma  
*Ruiz-Margáin A, Román-Calleja BM, Moreno-Guillén P, González-Regueiro JA, Kúsulas-Delint D, Campos-Murguía A, Flores-García NC, Macías-Rodríguez RU*
- 1453** Radiotherapy for gastric mucosa-associated lymphoid tissue lymphoma  
*Quéro L, Labidi M, Bollet M, Bommier C, Guillermin S, Hennequin C, Thieblemont C*
- 1466** Endoscopic papillectomy for ampullary adenomatous lesions: A literature review  
*Li SL, Li W, Yin J, Wang ZK*
- 1475** Endoscopic ultrasound assessment and tissue acquisition of mediastinal and abdominal lymph nodes  
*Tamanini G, Cominardi A, Brighi N, Fusaroli P, Lisotti A*

**ORIGINAL ARTICLE****Basic Study**

- 1492** Direct interaction between Rab5a and Rab4a enhanced epidermal growth factor-stimulated proliferation of gastric cancer cells  
*Cao GJ, Wang D, Zeng ZP, Wang GX, Hu CJ, Xing ZF*
- 1506** Combination of neutrophil gelatinase-associated lipocalin and matrix metalloproteinase-9 are biomarkers for the detection of colon tubular adenocarcinoma  
*Yuan JH, Xie LS, Zhu YH, Wang XH, Zhang YJ, Wang XJ*
- 1518** Survival effect of probiotics in a rat model of colorectal cancer treated with capecitabine  
*Gigola G, Carriere P, Novoa Díaz MB, Perdigon G, Zwenger AO, Gentili C*

**Prospective Study**

- 1532** Efficacy and toxicity of capecitabine combined with intensity-modulated radiotherapy after D1/D2 lymph node dissection in patients with gastric cancer  
*Wang X, Wang WH, Wang SL, Song YW, Liu YP, Tang Y, Li N, Liu WY, Fang H, Li YX, Zhao DB, Chi Y, Yang L, Jin J*

**ABOUT COVER**

Editorial Board Member of *World Journal of Gastrointestinal Oncology*, Guido Giordano, MD, Research Assistant Professor, Department of Medical and Surgical Sciences; Unit of Medical Oncology and Biomolecular Therapy, University of Foggia, Policlinico Riuniti, Foggia 71122, Italy. [giordano.guido81@gmail.com](mailto:giordano.guido81@gmail.com)

**AIMS AND SCOPE**

The primary aim of *World Journal of Gastrointestinal Oncology* (WJGO, *World J Gastrointest Oncol*) is to provide scholars and readers from various fields of gastrointestinal oncology with a platform to publish high-quality basic and clinical research articles and communicate their research findings online.

WJGO mainly publishes articles reporting research results and findings obtained in the field of gastrointestinal oncology and covering a wide range of topics including liver cell adenoma, gastric neoplasms, appendiceal neoplasms, biliary tract neoplasms, hepatocellular carcinoma, pancreatic carcinoma, cecal neoplasms, colonic neoplasms, colorectal neoplasms, duodenal neoplasms, esophageal neoplasms, gallbladder neoplasms, *etc.*

**INDEXING/ABSTRACTING**

The WJGO is now indexed in Science Citation Index Expanded (also known as SciSearch®), PubMed, PubMed Central, and Scopus. The 2021 edition of Journal Citation Reports® cites the 2020 impact factor (IF) for WJGO as 3.393; IF without journal self cites: 3.333; 5-year IF: 3.519; Journal Citation Indicator: 0.5; Ranking: 163 among 242 journals in oncology; Quartile category: Q3; Ranking: 60 among 92 journals in gastroenterology and hepatology; and Quartile category: Q3. The WJGO's CiteScore for 2020 is 3.3 and Scopus CiteScore rank 2020: Gastroenterology is 70/136.

**RESPONSIBLE EDITORS FOR THIS ISSUE**

Production Editor: *Ying-Yi Yuan*; Production Department Director: *Xiang Li*; Editorial Office Director: *Ya-Juan Ma*.

**NAME OF JOURNAL**

*World Journal of Gastrointestinal Oncology*

**ISSN**

ISSN 1948-5204 (online)

**LAUNCH DATE**

February 15, 2009

**FREQUENCY**

Monthly

**EDITORS-IN-CHIEF**

Rosa M Jimenez Rodriguez, Pashtoon Kasi, Monjur Ahmed, Florin Burada

**EDITORIAL BOARD MEMBERS**

<https://www.wjgnet.com/1948-5204/editorialboard.htm>

**PUBLICATION DATE**

October 15, 2021

**COPYRIGHT**

© 2021 Baishideng Publishing Group Inc

**INSTRUCTIONS TO AUTHORS**

<https://www.wjgnet.com/bpg/gerinfo/204>

**GUIDELINES FOR ETHICS DOCUMENTS**

<https://www.wjgnet.com/bpg/GerInfo/287>

**GUIDELINES FOR NON-NATIVE SPEAKERS OF ENGLISH**

<https://www.wjgnet.com/bpg/gerinfo/240>

**PUBLICATION ETHICS**

<https://www.wjgnet.com/bpg/GerInfo/288>

**PUBLICATION MISCONDUCT**

<https://www.wjgnet.com/bpg/gerinfo/208>

**ARTICLE PROCESSING CHARGE**

<https://www.wjgnet.com/bpg/gerinfo/242>

**STEPS FOR SUBMITTING MANUSCRIPTS**

<https://www.wjgnet.com/bpg/GerInfo/239>

**ONLINE SUBMISSION**

<https://www.f6publishing.com>



Basic Study

# Combination of neutrophil gelatinase-associated lipocalin and matrix metalloproteinase-9 are biomarkers for the detection of colon tubular adenocarcinoma

Jun-Hua Yuan, Li-Shuang Xie, Yu-Hua Zhu, Xiao-Hua Wang, Yi-Jing Zhang, Xiao-Jun Wang

**ORCID number:** Jun-Hua Yuan 0000-0002-5219-2900; Li-Shuang Xie 0000-0003-3614-3209; Yu-Hua Zhu 0000-0003-2179-8923; Xiao-Hua Wang 0000-0002-8530-1210; Yi-Jing Zhang 0000-0003-2267-608X; Xiao-Jun Wang 0000-0002-5439-782X.

**Author contributions:** Yuan JH, Xie LS and Zhang YJ designed the research; Yuan JH, Wang XH and Zhu YH performed the experiments; Xie LS, Zhang YJ and Wang XJ analyzed the data and participated in the discussion; Yuan JH and Xie LS wrote and revised the paper; all authors reviewed the manuscript.

**Supported by** Shandong Key Research and Development Plan, No. 2016GSF201020.

**Institutional review board statement:** The study was reviewed and approved by the "Shenghua Hospital of Shandong Province, Biomedical Research Ethics Committee" Institutional Review Board (Approval No.2021-005).

**Conflict-of-interest statement:** The authors declare that they have no conflict of interest.

**Data sharing statement:** No

**Jun-Hua Yuan, Yi-Jing Zhang, Xiao-Jun Wang,** Department of Geriatric Gastroenterology, Shandong Provincial Hospital Affiliated to Shandong First Medical University, Jinan 250021, Shandong Province, China

**Li-Shuang Xie,** Medical Records Room, Yinan County People's Hospital, Yinan 276399, Shandong Province, China

**Yu-Hua Zhu,** Department of Infectious Diseases, Shandong Provincial Hospital Affiliated to Shandong First Medical University, Jinan 250021, Shandong Province, China

**Xiao-Hua Wang,** Department of Infectious Diseases and Liver Diseases, Jinan Infectious Disease Hospital, Shandong University School of Medicine, Jinan 250021, Shandong Province, China

**Corresponding author:** Jun-Hua Yuan, MD, Chief Physician, Department of Geriatric Gastroenterology, Shandong Provincial Hospital Affiliated to Shandong First Medical University, No. 324 Jingwu Weiqi Road, Huaiyin District, Jinan 250021, Shandong Province, China. [yjh717299@126.com](mailto:yjh717299@126.com)

## Abstract

### BACKGROUND

Tubular adenocarcinoma of the colon, which originates from the epithelium of the glands, is a major health concern worldwide. However, it is difficult to detect at an early stage. The lack of biomarkers is a main barrier to the diagnosis and treatment of tubular adenocarcinoma. Neutrophil gelatinase-associated lipocalin (NGAL) is a secreted protein that induces the expression of matrix metalloproteinase-9 (MMP-9) and is involved in various tumors. NGAL and MMP-9 have been reported to be associated with tumorigenesis and development. They may have potential as biomarkers for diagnosis of tubular adenocarcinoma of the colon.

### AIM

To determine whether NGAL and MMP-9 can be used as potential biomarkers to indicate the progression of tubular adenocarcinoma of the colon.

### METHODS

Samples were collected from surgically excised tissue from various patients. The

additional data are available.

**Open-Access:** This article is an open-access article that was selected by an in-house editor and fully peer-reviewed by external reviewers. It is distributed in accordance with the Creative Commons Attribution NonCommercial (CC BY-NC 4.0) license, which permits others to distribute, remix, adapt, build upon this work non-commercially, and license their derivative works on different terms, provided the original work is properly cited and the use is non-commercial. See: <http://creativecommons.org/licenses/by-nc/4.0/>

**Manuscript source:** Unsolicited manuscript

**Specialty type:** Oncology

**Country/Territory of origin:** China

**Peer-review report's scientific quality classification**

Grade A (Excellent): 0  
Grade B (Very good): B, B  
Grade C (Good): 0  
Grade D (Fair): 0  
Grade E (Poor): 0

**Received:** February 23, 2021

**Peer-review started:** February 23, 2021

**First decision:** April 19, 2021

**Revised:** April 22, 2021

**Accepted:** July 21, 2021

**Article in press:** July 21, 2021

**Published online:** October 15, 2021

**P-Reviewer:** Arville B, Shimizu Y

**S-Editor:** Gong ZM

**L-Editor:** Webster JR

**P-Editor:** Liu JH



content of pro-gastrin-releasing peptide (pro-GRP) in the serum was measured by an electrochemiluminescence immunoassay. The expression patterns of NGAL and MMP-9 and the relationship between NGAL and MMP-9 were examined by quantitative real-time PCR, Western blotting and immunohistochemical analysis.

## RESULTS

In this study, we found that NGAL and MMP-9 can be used as biomarkers for the detection of tubular adenocarcinoma of the colon and that their combination improved diagnostic accuracy. By analyzing the expression of NGAL in tubular adenocarcinoma at different levels, we found that NGAL expression was significantly upregulated in primary tubular adenocarcinoma tissues compared with normal tissues. The upregulation of NGAL expression was strongly correlated with both the degree of differentiation and the disease stage (I-III), indicating that NGAL could serve as a diagnostic biomarker for tubular adenocarcinoma. When using NGAL as a biomarker for diagnosis, the accuracy was similar to that achieved with the widely used biomarker pro-GRP, suggesting that NGAL is reliable. Moreover, the expression of MMP-9 was also strongly correlated with the differentiation stage, demonstrating that MMP-9 could be used as a biomarker to indicate the progression of tubular adenocarcinoma of the colon. More importantly, the combination of NGAL and MMP-9 produced a more accurate diagnosis of tubular adenocarcinoma, and these results were further confirmed by immunohistochemical analysis of tissue sections.

## CONCLUSION

Our study demonstrated that both NGAL and MMP-9 can be used as biomarkers for the diagnosis of colon tubular adenocarcinoma and that the results could be further improved by combining them.

**Key Words:** Tubular adenocarcinoma; Colon; Neutrophil gelatinase-associated lipocalin; Matrix metalloproteinase-9; Biomarker

©The Author(s) 2021. Published by Baishideng Publishing Group Inc. All rights reserved.

**Core Tip:** Neutrophil gelatinase-associated lipocalin (NGAL) is a secreted protein, which modulates the expression of matrix metalloproteinase-9 (MMP-9) and is present in various cancers. However, it has not been determined whether NGAL or MMP-9 can be used as biomarkers in the diagnosis of tubular adenocarcinoma of the colon. In the present study, we demonstrated that both NGAL and MMP-9 could be used as biomarkers for diagnosis of tubular adenocarcinoma of the colon. By using them together, diagnostic accuracy can be further improved.

**Citation:** Yuan JH, Xie LS, Zhu YH, Wang XH, Zhang YJ, Wang XJ. Combination of neutrophil gelatinase-associated lipocalin and matrix metalloproteinase-9 are biomarkers for the detection of colon tubular adenocarcinoma. *World J Gastrointest Oncol* 2021; 13(10): 1506-1517

**URL:** <https://www.wjgnet.com/1948-5204/full/v13/i10/1506.htm>

**DOI:** <https://dx.doi.org/10.4251/wjgo.v13.i10.1506>

## INTRODUCTION

Colorectal cancer (CRC) is the third most common cancer worldwide with 1.36 million people diagnosed in 2012, which contributed to 9.7% of cancer cases[1]. In China, CRC is the fourth most common malignant cancer, and has increased rapidly, especially in developing regions[2,3]. CRC is caused by numerous factors, which are associated with heritability, lifestyle, chronic inflammation and so on[4-6]. Although early stage I-II CRC can be cured *via* surgical excision, advanced stage III-IV CRC is usually lethal and incurable[7,8]. Most CRC cases are tubular adenocarcinomas, which comprise approximately 95%, and are characterized by peritoneal dissemination and infiltrative

growth[9]. Early diagnosis of colorectal adenocarcinoma is obviously important in the treatment of primary or recurrent colorectal adenocarcinoma.

Advances in the understanding of colorectal carcinogenesis offer opportunities to identify biomarkers for earlier diagnosis. Recent studies demonstrated that neutrophil gelatinase-associated lipocalin (NGAL) and matrix metalloproteinase-9 (MMP-9) could be used as diagnostic and prognostic biomarkers in various cancers, including breast cancer[10], bladder cancer[11,12], gastric cancer[13], endometrial cancer[14] and kidney tumors[15]. NGAL, also called lipocalin-2 (LCN2), is a small glycoprotein, which is encoded by the *LCN2* gene. As a member of the lipocalin family, NGAL participates in the transportation of lipophilic substances. Additionally, it has also been reported that NGAL is associated with the delivery of iron from the extracellular space into the inner cell, which may promote tumor development and support the proliferation of neoplastic cells[16,17]. Previous studies revealed that increased expression of NGAL contributed to the progression of cancers[18,19], and in a number of malignancies, NGAL was over-expressed[20,21]. MMP-9 is one of the matrix metalloproteinases, whose activity is modulated by NGAL[22]. MMP-9 can degrade the extracellular matrix (ECM), which is the barrier to cell invasion. Degradation of the ECM can provide a favorable environment for promoting the growth and dissemination of cancer cells. The increased expression level of MMP-9 has been observed in several cancers, which was related to the aggressiveness of cancer cells and the overall survival of patients[23]. In combination with NGAL, MMP-9 can avoid proteolytic degradation, which increases its enzymatic activity and the movability of malignancies [10].

NGAL, MMP-9, and their complex have shown value as diagnostic and prognostic biomarkers in several cancers. However, their value in tubular adenocarcinoma of the colon remains unknown. Therefore, in the present study, we evaluated the potential of NGAL and MMP-9 as biomarkers for the early detection of tubular adenocarcinoma of the colon and explored the possible application of combining these two biomarkers.

## MATERIALS AND METHODS

### *Patients and samples*

This study included 15 female and 32 male patients aged 45 to 80 years treated in the Provincial Hospital Affiliated to Shandong University. In total, 30 samples of tubular adenocarcinoma of the colon were collected from the patients who underwent surgical excision between 2015 and 2019. Ten patients had polyps (I), 10 patients had mild tubular adenocarcinoma (II) and 10 patients had severe tubular adenocarcinoma (III), respectively, confirmed by a pathologist. In addition, 10 normal samples were included as controls. All experiments were in compliance with the ethical standards of the World Medical Association Declaration of Helsinki, the samples were only used for research and consent was obtained from the patients before the start of the experiment.

### *Detection of pro-gastrin-releasing peptide*

Serum samples were tested using a commercial electrochemiluminescence immunoassay for pro-gastrin-releasing peptide (pro-GRP) with the Roche C6000 automated immunoassay analyzer (Roche Diagnostics GmbH, Penzberg, Germany) [24].

### *Quantitative real-time PCR analysis*

Total RNA was extracted from serum samples with TRIzol Reagent (DP405-02, TIANGEN Biotech, Beijing, China), after which cDNA was synthesized with reverse transcriptase (RR047B, Takara, Beijing, China) in accordance with the manufacturer's instructions. Quantitative real-time PCR (qRT-PCR) was performed using SYBR® Premix Ex Taq™ II (Tli RNaseH Plus, TaKaRa, Japan) to detect the mRNA levels of NGAL and MMP9. Reaction parameters were as follows: 95°C for 30 s, followed by 45 cycles at 95°C for 5 s and 60°C for 40 s. Data were collected and analyzed with GraphPad and SPSS 25.0. The expression of genes within a sample was normalized to GAPDH expression by employing the  $2^{-\Delta\Delta Ct}$  method. The primers used in the present study were as follows: NGAL (Forward: ACAAAGACCCGCAAAAGATG; Reverse: TTGGGACAGGGAAGACGAT), and MMP9 (Forward: GAGCACGGAGACG-GGTATC; Reverse: ACTCGTCATCGTCGAAATGG).

**Table 1 Serum levels of pro-gastrin-releasing peptide and neutrophil gelatinase-associated lipocalin in tubular adenocarcinoma patients**

Case	Gender	Age	Pathologic grade	pro-GRP (pg/mL)	Relative NGAL expression
Normal	M	64	Polyps	12.32 ± 0.30	1 ± 0.02
P1	M	76	Mild tubular adenocarcinoma	50.02 ± 0.80	10.62 ± 0.10
P2	F	78	Mild tubular adenocarcinoma	58.86 ± 1.31	19.90 ± 0.22
P3	F	45	Mild tubular adenocarcinoma	50.99 ± 0.85	12.17 ± 0.15
P4	M	74	Mild tubular adenocarcinoma	55.71 ± 1.15	17.14 ± 0.20
P5	M	65	Mild tubular adenocarcinoma	65.87 ± 2.61	22.56 ± 0.27
P6	F	80	Mild tubular adenocarcinoma	52.52 ± 1.01	15.34 ± 0.19

M: Male; F: Female; NGAL: Neutrophil gelatinase-associated lipocalin pro-GRP: Pro-gastrin-releasing peptide.

### Western blotting

Western blotting for NGAL and MMP-9 was carried out. Serum sample lysates were thawed and mixed with an equal volume of 2X buffer. 10% sodium dodecyl sulfate polyacrylamide gel electrophoresis (SDS-PAGE) was used to separate proteins and the proteins were then transferred onto a polyvinylidene difluoride (PVDF) membrane. Anti-NGAL antibody (ab41105) and anti-MMP-9 antibody (ab38898) obtained from Abcam (Cambridge, United Kingdom) and B-actin monoclonal antibody (YM3028) obtained from Immunoway (Plano, United States) were employed as primary antibodies. The membrane was incubated with primary antibodies at 4°C overnight and secondary antibodies at 37°C for 40 min, respectively. Enhanced chemiluminescence (ECL, WBKLS0500, Millipore, MA, United States) solution was used to visualize the bands. The blots were subsequently scanned, and band intensity was quantified based on densitometry software (ImageJ, National Institutes of Health, Bethesda, MD, United States).

### Immunohistochemical analysis

For immunohistochemical (IHC) analysis of tumor tissues, the samples were rinsed with PBS, fixed with 4% paraformaldehyde for 1 h and embedded in paraffin. Sections of 5 µm thickness were prepared for IHC staining. Briefly, the slides were rehydrated using a gradient. Sodium citrate buffer solution (pH 6.0) was used for antigen retrieval. To avoid the influence of endogenous peroxidase activity, 0.3% hydrogen peroxide was added for 10 min. In addition, 3% calf serum was applied to block the sections. The sections were subsequently stained with the same primary antibodies as above. Then the samples were incubated with the universal secondary antibody and VECTASTAIN Elite ABC reagent (PK6200, Vector, Germany), reacted with 3,3'-Diaminobenzidine tetra hydrochloride hydrate (DAB, Thermo Fisher Scientific, Waltham, United States), and counterstained with hematoxylin (H3404, Vector, Germany). The images were captured using an optical microscope.

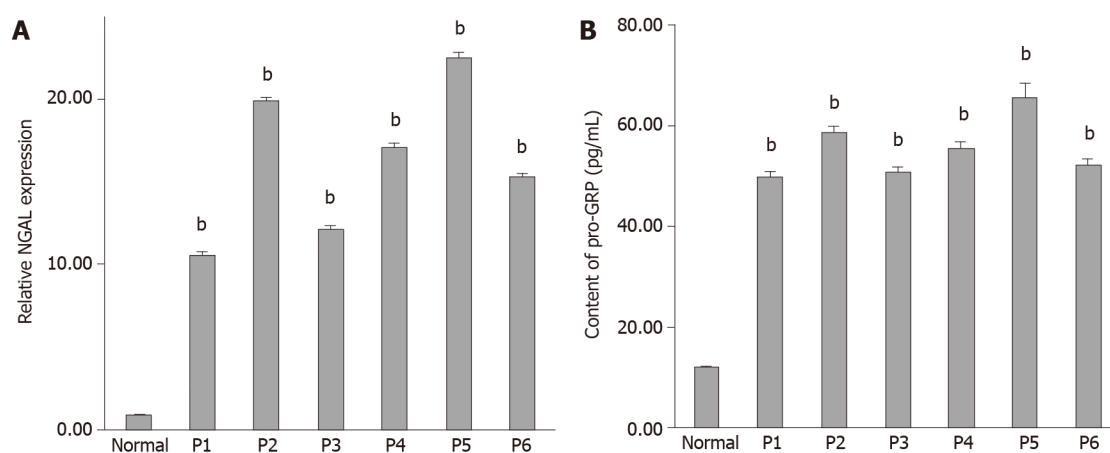
### Statistical analysis

Unless otherwise indicated, all experiments were carried out in triplicate. Error bars represent standard deviations. Data are presented as mean value ± SE from three independent measurements, and values of  $P < 0.05$  were considered statistically significant. Graphs were plotted and analyzed using GraphPad and SPSS 25.0.

## RESULTS

### *The expression of NGAL was positively correlated with the occurrence of tubular adenocarcinoma of the colon*

It has been reported that NGAL can be used as a biomarker to detect some cancers. However, the potential value of NGAL in tubular adenocarcinoma of the colon remains unknown. Therefore, we first analyzed 6 samples from patients (Table 1), who were diagnosed with tubular adenocarcinoma of the colon. The mRNA expression level of NGAL was evaluated by qRT-PCR. Figure 1A shows that the expression of



**Figure 1 The relative expression of neutrophil gelatinase-associated lipocalin was consistent with the content of pro-gastrin-releasing peptide in serum.** A: The relative gene expression of neutrophil gelatinase-associated lipocalin in serum in normal and six samples of tubular adenocarcinoma of the colon (P1 to P6); B: The content of pro-gastrin-releasing peptide (pg/mL) in serum. Three independent experiments were carried out and analyzed. Data are expressed as mean values  $\pm$  SE,  $^bP < 0.01$ , two-tailed Student's *t*-tests. NGAL: Neutrophil gelatinase-associated lipocalin; pro-GRP: Pro-gastrin-releasing peptide.

NGAL was significantly higher in tubular adenocarcinoma of the colon in comparison with the control sample. The biomarker pro-GRP, is commonly used in the diagnosis of tubular adenocarcinoma[24,25]. As shown in Figure 1B and Table 1, pro-GRP was detected in the serum of these 6 patients. According to the results obtained, we found that the expression of NGAL was consistent with the expression of pro-GRP in various patients, suggesting that the expression of NGAL in serum was positively correlated with the occurrence of tubular adenocarcinomas of the colon.

#### **NGAL and MMP-9 can indicate the progression of tubular adenocarcinoma**

In order to confirm the relationship between NGAL and the occurrence of tubular adenocarcinoma, more samples were analyzed. We collected more samples of tubular adenocarcinoma of the colon, including polyps (I), mild tubular adenocarcinoma (II) and severe tubular adenocarcinoma (III), as shown in Table 2. The qRT-PCR results in Figure 2A reveal that increased gene expression of NGAL was found in all cases, while the increment varied. In addition, we also found that with the development of tubular adenocarcinoma, the mean expression levels of NGAL were increased, and the expression of NGAL was higher in stage II and III than that in stage I. We then assessed the expression of MMP-9, which can be induced by NGAL. As expected, both NGAL and MMP-9 gradually increased with progression of the disease, although the gene expression of MMP-9 was extremely low in stage I, it was still slightly higher than that in the control group (Figure 2B).

We further determined the protein level of NGAL and MMP-9 using Western blotting. Typical samples (N-4, I-5, II-3, III-6) were selected for tested. According to the results, we found that the hybridization signal of NGAL was gradually enhanced from the control group to stage III, indicating the progression of tubular adenocarcinoma (Figure 2C), which was consistent with the results of qRT-PCR. The expression level of MMP-9 in stage I was slightly higher than that in the control group, and it continued to increase in stage II and III (Figure 2D), suggesting that MMP-9 was induced by NGAL, and the expression of MMP-9 might occur later than NGAL. More importantly, it was also found that MMP-9 increased as tubular adenocarcinoma of the colon progressed.

IHC staining was also used to detect the *in situ* expression of NGAL and MMP-9. The tissue samples used for IHC staining were from the same patients (N-4, I-5, II-3, III-6). Hybridization with anti-NGAL and anti-MMP-9 antibodies revealed that NGAL and MMP-9 in the lesion were both higher than those in the control. With progression of the disease, the signals became stronger (Figure 3). Therefore, it can be concluded that both NGAL and MMP-9 can be used as biomarkers to indicate the progression of tubular adenocarcinoma of the colon.

#### **The combination of NGAL and MMP-9 can improve the accuracy of the diagnosis of tubular adenocarcinoma of the colon**

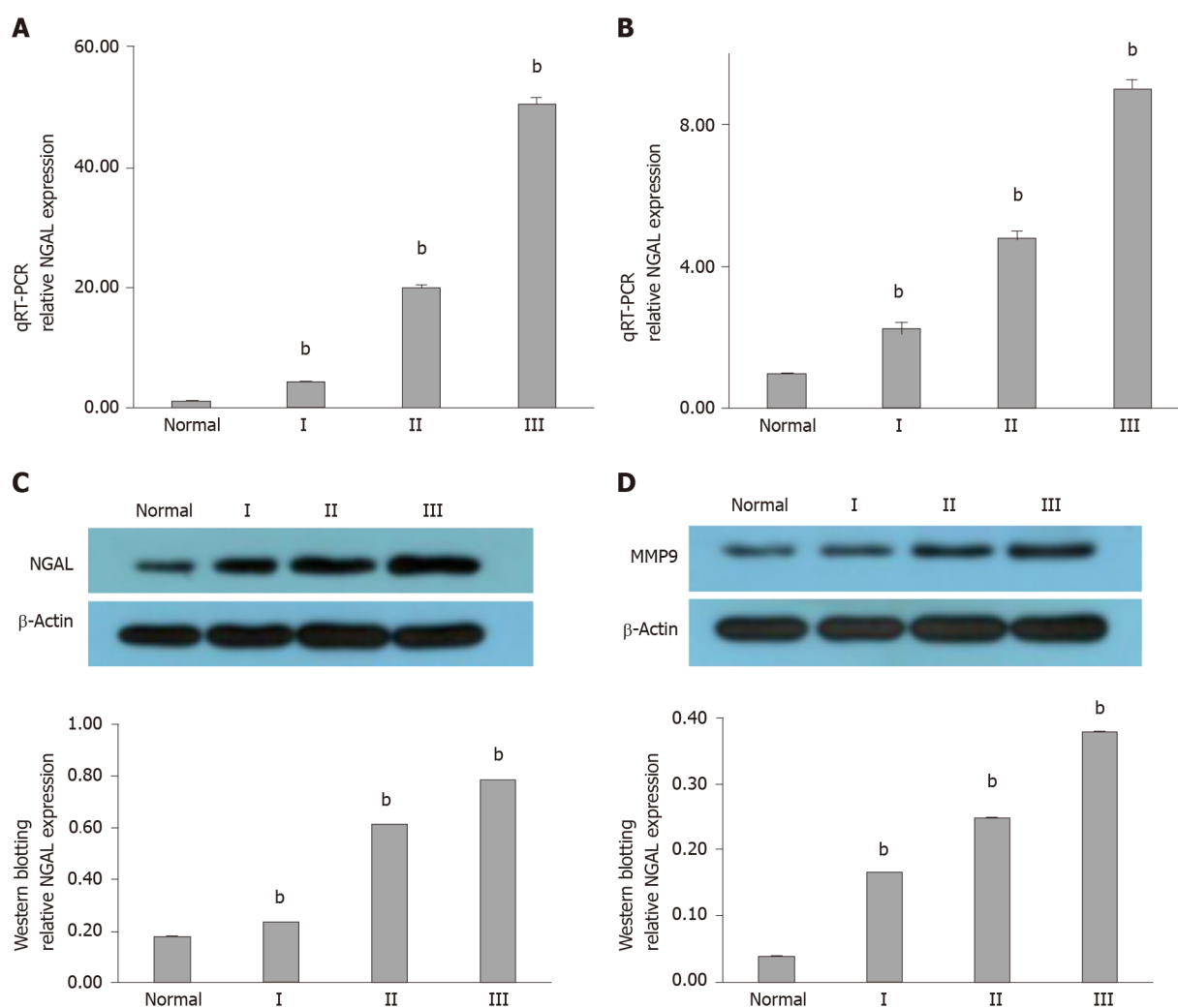
Although both NGAL and MMP-9 exhibited potential value as independent biomarkers in the detection of tubular adenocarcinoma of the colon, their accuracy was

**Table 2 Serum levels of pro-gastrin-releasing peptide, neutrophil gelatinase-associated lipocalin/matrix metalloproteinase-9 in different patient groups**

Group	Case	Gender	Age	Pathologic grade	pro-GRP (pg/mL)	Relative NGAL expression	Relative MMP-9 expression
Normal	N-1	M	64	--	11.51 ± 0.31	1.00 ± 0.02	1.00 ± 0.01
Normal	N-2	M	62	--	6.33 ± 0.13	0.81 ± 0.01	0.98 ± 0.01
Normal	N-3	M	59	--	8.54 ± 0.12	0.93 ± 0.03	0.94 ± 0.02
Normal	N-4	M	67	--	15.67 ± 0.37	1.03 ± 0.02	0.97 ± 0.01
Normal	N-5	M	48	--	8.34 ± 0.21	1.12 ± 0.03	1.02 ± 0.02
Normal	N-6	M	52	--	13.51 ± 0.33	0.96 ± 0.01	1.04 ± 0.02
Normal	N-7	M	69	--	16.62 ± 0.41	0.89 ± 0.01	1.00 ± 0.01
Normal	N-8	M	56	--	6.88 ± 0.22	1.08 ± 0.04	2.03 ± 0.03
Normal	N-9	M	70	--	17.36 ± 0.31	0.97 ± 0.03	0.96 ± 0.01
Normal	N-10	M	65	--	18.24 ± 0.35	1.21 ± 0.03	1.06 ± 0.02
I	I-1	M	54	Polyps	15.68 ± 0.27	1.31 ± 0.02	1.02 ± 0.01
I	I-2	F	65	Polyps	17.83 ± 0.31	1.42 ± 0.04	1.08 ± 0.02
I	I-3	F	66	Polyps	20.12 ± 0.35	1.90 ± 0.04	1.28 ± 0.03
I	I-4	M	74	Polyps	24.38 ± 0.46	2.84 ± 0.06	4.32 ± 0.12
I	I-5	M	65	Polyps	29.67 ± 0.36	3.85 ± 0.07	2.35 ± 0.06
I	I-6	F	71	Polyps	62.56 ± 0.83	4.24 ± 0.10	2.76 ± 0.07
I	I-7	F	55	Polyps	38.94 ± 0.46	2.09 ± 0.06	3.00 ± 0.06
I	I-8	M	62	Polyps	40.54 ± 0.52	5.56 ± 0.12	5.12 ± 0.13
I	I-9	M	64	Polyps	43.86 ± 0.49	7.21 ± 0.16	3.44 ± 0.09
I	I-10	M	68	Polyps	60.91 ± 0.75	8.23 ± 0.20	3.71 ± 0.11
II	II-1	M	68	Mild tubular adenocarcinoma	55.32 ± 0.46	3.97 ± 0.12	4.06 ± 0.12
II	II-2	M	72	Mild tubular adenocarcinoma	30.13 ± 0.36	13.81 ± 0.23	4.53 ± 0.18
II	II-3	F	65	Mild tubular adenocarcinoma	52.54 ± 0.53	15.06 ± 0.25	4.89 ± 0.20
II	II-4	F	70	Mild tubular adenocarcinoma	58.25 ± 0.49	5.68 ± 0.18	4.07 ± 0.17
II	II-5	M	75	Mild tubular adenocarcinoma	35.02 ± 0.56	18.37 ± 0.29	4.61 ± 0.22
II	II-6	M	77	Mild tubular adenocarcinoma	61.45 ± 0.67	21.35 ± 0.35	2.92 ± 0.15
II	II-7	M	65	Mild tubular adenocarcinoma	62.38 ± 0.74	23.69 ± 0.37	4.82 ± 0.27
II	II-8	F	63	Mild tubular adenocarcinoma	64.43 ± 0.48	24.92 ± 0.24	4.85 ± 0.26
II	II-9	M	57	Mild tubular adenocarcinoma	68.67 ± 0.46	26.74 ± 0.30	5.68 ± 0.22
II	II-10	M	62	Mild tubular adenocarcinoma	70.5 ± 0.71	28.32 ± 0.32	6.04 ± 0.17
III	III-1	M	67	Severe tubular adenocarcinoma	72.53 ± 0.83	31.03 ± 0.26	6.36 ± 0.22
III	III-2	M	65	Severe tubular adenocarcinoma	76.27 ± 0.96	37.17 ± 0.32	6.47 ± 0.20
III	III-3	F	80	Severe tubular adenocarcinoma	79.81 ± 1.13	38.44 ± 0.41	7.53 ± 0.31
III	III-4	F	76	Severe tubular adenocarcinoma	84.56 ± 1.41	43.68 ± 0.50	8.68 ± 0.25
III	III-5	M	65	Severe tubular adenocarcinoma	86.01 ± 1.06	45.79 ± 0.55	4.70 ± 0.19
III	III-6	F	71	Severe tubular adenocarcinoma	90.12 ± 1.28	49.31 ± 0.61	9.05 ± 0.35

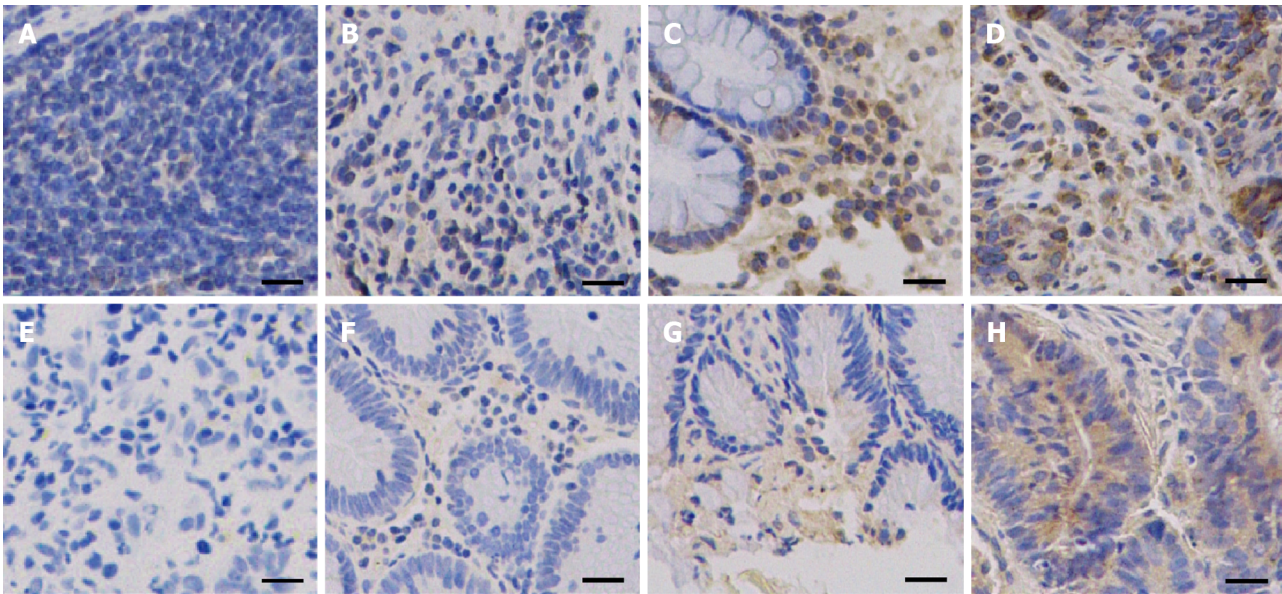
III	III-7	M	66	Severe tubular adenocarcinoma	93.17 ± 1.33	53.81 ± 0.53	9.52 ± 0.28
III	III-8	M	78	Severe tubular adenocarcinoma	94.24 ± 1.57	54.68 ± 0.62	9.35 ± 0.34
III	III-9	F	67	Severe tubular adenocarcinoma	93.08 ± 1.82	65.76 ± 0.72	9.41 ± 0.27
III	III-10	F	72	Severe tubular adenocarcinoma	107.38 ± 2.34	85.91 ± 0.96	14.84 ± 0.38

M: Male; F: Female; NGAL: Neutrophil gelatinase-associated lipocalin pro-GRP; Pro-gastrin-releasing peptide; MMP-9: Matrix metalloproteinase-9.

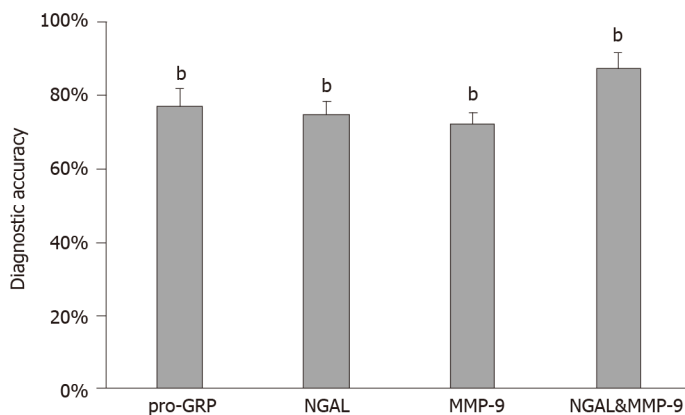


**Figure 2** Expression of neutrophil gelatinase-associated lipocalin and matrix metalloproteinase-9 in tubular adenocarcinoma of the colon. A and B: The relative neutrophil gelatinase-associated lipocalin (NGAL) (A) and matrix metalloproteinase-9 (MMP-9) (B) gene expression in serum samples from normal tissues ( $n = 10$ ) and patient tissues with different stages of tubular adenocarcinoma of the colon (From I to III) ( $n = 30$ ); C and D: Western blotting analysis of the expression of NGAL (C) and MMP-9 (D) at the protein level. Three independent experiments were carried and analyzed. Data are expressed as mean values  $\pm$  SE, <sup>b</sup> $P < 0.01$ , two-tailed Student's *t*-tests. NGAL: Neutrophil gelatinase-associated lipocalin; MMP-9: Matrix metalloproteinase-9.

still a problem for clinical application. In addition, some of the cases in our study would be misdiagnosed if we measured only one of them. The expression of NGAL in 10 cases did not match the pathological examination results, and the accuracy of NGAL was 75% (Table 2). Similarly, the accuracy of MMP-9 was 72.5%. However, we found that the accuracy was improved to 87.5% when NGAL and MMP-9 were combined for the diagnosis of tubular adenocarcinoma of the colon. Only one of 40 cases was misdiagnosed (Table 2, Figure 4). Therefore, it is suggested that NGAL and MMP-9 may be used in combination to enhance diagnostic accuracy of tubular adenocarcinoma of the colon.



**Figure 3** Neutrophil gelatinase-associated lipocalin and matrix metalloproteinase-9 immunoexpression in tubular adenocarcinoma of the colon (original magnification, 200 ×). Upper panel: Neutrophil gelatinase-associated lipocalin staining; Lower panel: Matrix metalloproteinase-9 staining. A and E: Control; B and F: Polyps; C and G: Mild tubular adenocarcinoma; D and H: Severe tubular adenocarcinoma.



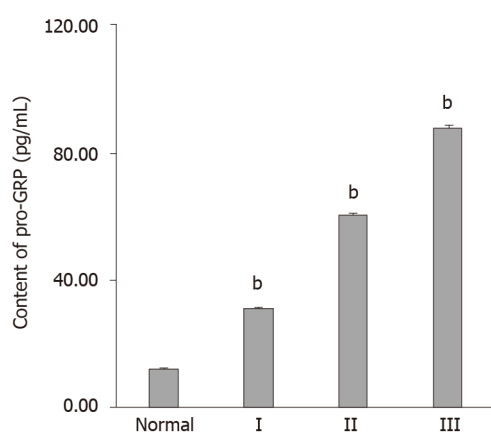
**Figure 4** The combination of neutrophil gelatinase-associated lipocalin and matrix metalloproteinase-9 improved the accuracy of the diagnosis of tubular adenocarcinoma of the colon. Data are expressed as mean values  $\pm$  SE,  $^bP < 0.01$ , two-tailed Student's *t*-tests. NGAL: Neutrophil gelatinase-associated lipocalin; pro-GRP: Pro-gastrin-releasing peptide; MMP-9: Matrix metalloproteinase-9.

### **The diagnostic value of the combination of NGAL and MMP-9 in clinical application**

As pro-GRP is a commonly used tumor diagnostic marker, we measured the content of pro-GRP in these 40 cases, and 77.5% of the measured pro-GRP values correctly indicated the progression of tubular adenocarcinoma of the colon (Figure 5 and Table 2). By comparing the diagnostic results of the combination of NGAL and MMP-9, we found that most of results were consistent, indicating that the combination of NGAL and MMP-9 is reliable in clinical application. Moreover, although using pro-GRP was more accurate than using NGAL or MMP-9 alone, there was still a 22.5% probability of error, which was diagnosed correctly when using NGAL and MMP-9 together.

## **DISCUSSION**

Despite significant medical progress in recent years, cancer is still one of the most common causes of death. Early-stage tubular adenocarcinoma of the colon is usually cured by surgical excision, but it is difficult to detect this disease in the early stage[10, 11], which is due to the lack of effective biomarkers. More importantly, it is necessary



**Figure 5** Content of pro-gastrin-releasing peptide (pg/mL) in serum samples from normal tissues ( $n = 10$ ) and from patient tissues with different stages of tubular adenocarcinoma of the colon (stage I-III) ( $n = 10$ ). Three independent experiments were carried out and analyzed. Data are expressed as mean values  $\pm$  SE, <sup>b</sup> $P < 0.01$ , two-tailed Student's  $t$ -tests. pro-GRP: Pro-gastrin-releasing peptide.

to determine the progression of tubular adenocarcinoma of the colon during treatment, to allow efficient evaluation and adjustment of therapeutic strategies.

NGAL and MMP-9 have been reported to be involved in several types of cancers and have been used as biomarkers to indicate disease progression[10-15]. In our study, we found that the expression of NGAL was positively related to the occurrence of tubular adenocarcinoma of the colon using qRT-PCR. The expression of NGAL was closely related to the development of tubular adenocarcinoma of the colon, suggesting that NGAL could be used to indicate progression. The results for NGAL were consistent with those for pro-GRP, suggesting that NGAL is reliable for indicating disease progression. On the other hand, we also demonstrated that MMP-9 could be considered another potential biomarker for tubular adenocarcinoma of the colon. Our results showed that although the expression of MMP-9 in patients with stage I disease was only slightly higher than that in the control, it was lower than the expression of NGAL in stage I disease, which was consistent with the conclusion of a previous study which showed that the expression of MMP-9 was induced by NGAL[22]. The expression of MMP-9 continued to increase as tubular adenocarcinoma of the colon progressed, suggesting that MMP-9 is also suitable for indicating disease progression. We also detected protein expression and analyzed pathological tissue using Western blotting and IHC staining, respectively, and the findings were consistent with the results shown above and demonstrated the potential value of NGAL and MMP-9 as biomarkers for clinical application.

Most importantly, we found that the combination of NGAL and MMP-9 in the diagnosis of 40 clinical cases significantly improved diagnostic accuracy up to 87.5%, which was higher than that achieved using NGAL, MMP-9 or the traditional biomarker pro-GPR alone. This result suggested that combining NGAL and MMP-9 has great potential for detecting tubular adenocarcinoma of the colon. Only one case could not be identified by NGAL and MMP-9. The mechanism of tumorigenesis in this case may have been abnormal and complex, which requires further study.

## CONCLUSION

In summary, our study demonstrated that both NGAL and MMP-9 could be used to detect tubular adenocarcinoma of the colon and that the combination of NGAL and MMP-9 showed greater diagnostic accuracy than either biomarker alone. As abnormal expression of NGAL/MMP-9 has been observed in several cancers, such as breast cancer, bladder cancer and gastric cancer, these two biomarkers described here for tubular adenocarcinoma of the colon may also be useful in other cancers.

## ARTICLE HIGHLIGHTS

### Research background

Tubular adenocarcinoma of the colon, which originates from the epithelium of glands, is a major health concern worldwide. However, it is difficult to detect at an early stage. The lack of biomarkers is a main barrier in the diagnosis and treatment of tubular adenocarcinoma. Neutrophil gelatinase-associated lipocalin (NGAL) is a secreted protein, which induces the expression of matrix metalloproteinase-9 (MMP-9) and is involved in various tumors. NGAL and MMP-9 have been reported to be associated with tumorigenesis and tumor development. They may be potential biomarkers for the diagnosis of tubular adenocarcinoma of the colon.

### Research motivation

The combination of NGAL and MMP9 are promising biomarkers for the early detection of tubular adenocarcinoma of the colon. To evaluate whether NGAL and MMP-9 can be used as potential biomarkers to indicate the progression of tubular adenocarcinoma of the colon, it may be beneficial to detect this tumor at the molecular level in the very early stage.

### Research objectives

We evaluated whether NGAL and MMP-9 can be used as potential biomarkers to indicate the progression of tubular adenocarcinoma of the colon as patients with this disease will require early diagnosis and treatment.

### Research methods

Samples were collected from the colonic mucosa of various patients. Ten patients had polyps (I), 10 patients had mild tubular adenocarcinoma (II) and 10 patients had severe tubular adenocarcinoma (III), respectively, confirmed by a pathologist. In addition, 10 normal samples were included as controls. The content of pro-gastrin-releasing peptide (pro-GRP) in serum was measured by an electrochemiluminescence immunoassay. The mRNA expression of NGAL and MMP-9 was examined by quantitative real-time PCR (qRT-PCR) analysis, and their protein expression was examined by Western blotting and immunohistochemical (IHC) analysis. According to the status of tubular adenocarcinoma of the colon, the patients were divided into three groups. Thus, the clinical grouping in this research was novel, which has not adopted in other studies.

### Research results

In this study, we found that NGAL and MMP-9 can be used as biomarkers for detecting tubular adenocarcinoma of the colon and their combination resulted in better diagnostic accuracy. By analyzing the expression of NGAL in tubular adenocarcinoma at different levels, we found that NGAL was significantly up-regulated in primary tubular adenocarcinoma compared with normal tissues. The up-regulation of NGAL was strongly correlated with both the degree of differentiation and the disease stage (I–III), indicating that NGAL could serve as a diagnostic biomarker for tubular adenocarcinoma. Using NGAL as a biomarker for diagnosis, the accuracy was similar to the widely used biomarker pro-GRP, suggesting that NGAL is a reliable biomarker. In addition, the expression of MMP-9 was also strongly correlated with differentiation and stage, demonstrating that MMP-9 can be used as a biomarker to indicate the progression of tubular adenocarcinoma of the colon. More importantly, the combination of NGAL and MMP-9 achieved greater diagnostic accuracy in tubular adenocarcinoma, and these results were further confirmed by immunohistochemical analysis of tissue sections.

### Research conclusions

In this study, the up-regulation of NGAL and MMP-9 was strongly correlated with both the degree of differentiation and stage of tubular adenocarcinoma of the colon. Both NGAL and MMP-9 can be used as biomarkers for detecting tubular adenocarcinoma of the colon and their combination achieved better diagnostic accuracy. Patients who develop tubular adenocarcinoma of colon will require early diagnosis and early treatment.

### Research perspectives

It is necessary to study more cases of tubular adenocarcinoma of the colon as other

factors may be involved in the progression of this disease. A larger scale clinical study may be the best method for future research on this tumor.

## REFERENCES

- 1 **Ferlay J**, Soerjomataram I, Dikshit R, Eser S, Mathers C, Rebelo M, Parkin DM, Forman D, Bray F. Cancer incidence and mortality worldwide: sources, methods and major patterns in GLOBOCAN 2012. *Int J Cancer* 2015; **136**: E359-E386 [PMID: [25220842](#) DOI: [10.1002/ijc.29210](#)]
- 2 **Kontos CK**, Tsiakanikas P, Avgeris M, Papadopoulos IN, Scorilas A. miR-15a-5p, A Novel Prognostic Biomarker, Predicting Recurrent Colorectal Adenocarcinoma. *Mol Diagn Ther* 2017; **21**: 453-464 [PMID: [28405803](#) DOI: [10.1007/s40291-017-0270-3](#)]
- 3 **Yu L**, Liu ZY, Jiao J, Shi XL, Cui WL, Zhang W, Li QX. [Polymorphisms of mTORC1 genes and risk of primary colorectal adenocarcinoma in Chinese populations]. *Zhonghua Bing Li Xue Za Zhi* 2018; **47**: 492-498 [PMID: [29996312](#) DOI: [10.3760/cma.j.issn.0529-5807.2018.07.003](#)]
- 4 **Chen L**, Zhu YY, Zhang XJ, Wang GL, Li XY, He S, Zhang JB, Zhu JW. TSPAN1 protein expression: a significant prognostic indicator for patients with colorectal adenocarcinoma. *World J Gastroenterol* 2009; **15**: 2270-2276 [PMID: [19437569](#) DOI: [10.3748/wjg.15.2270](#)]
- 5 **Lualdi M**, Cavalleri A, Battaglia L, Colombo A, Garrone G, Morelli D, Pignoli E, Sottotetti E, Leo E. Early detection of colorectal adenocarcinoma: a clinical decision support tool based on plasma porphyrin accumulation and risk factors. *BMC Cancer* 2018; **18**: 841 [PMID: [30134852](#) DOI: [10.1186/s12885-018-4754-2](#)]
- 6 **Gannam CV**, Chin KL, Gandhi RP. Caries risk assessment. *Gen Dent* 2018; **66**: 12-17 [PMID: [30444701](#)]
- 7 **Luo C**, Cen S, Ding G, Wu W. Mucinous colorectal adenocarcinoma: clinical pathology and treatment options. *Cancer Commun (Lond)* 2019; **39**: 13 [PMID: [30922401](#) DOI: [10.1186/s40880-019-0361-0](#)]
- 8 **Wu XL**, Wang YY, Wang LK, Xue J, Yang DD, Qu M, Wang CY, Guo F, Yang RM, Liu B. Id-1 expression in colorectal adenocarcinoma tissues and its clinical significance. *Rev Assoc Med Bras (1992)* 2019; **65**: 404-409 [PMID: [30994840](#) DOI: [10.1590/1806-9282.65.3.404](#)]
- 9 **Reynolds IS**, O'Connell E, Fichtner M, McNamara DA, Kay EW, Prehn JHM, Furney SJ, Burke JP. Mucinous adenocarcinoma is a pharmacogenomically distinct subtype of colorectal cancer. *Pharmacogenomics J* 2020; **20**: 524-532 [PMID: [31819162](#) DOI: [10.1038/s41397-019-0137-6](#)]
- 10 **Metallinou D**, Lykeridou K, Karampas G, Liosis GT, Skevaki C, Rizou M, Papassotiropoulos I, Rizos D. Postpartum human breast milk levels of neutrophil gelatinase-associated lipocalin (NGAL) and matrix metalloproteinase-9 (MMP-9)/NGAL complex in normal and pregnancies complicated with insulin-dependent gestational diabetes mellitus. A prospective pilot case-control study. *J Obstet Gynaecol* 2020; **40**: 461-467 [PMID: [31353996](#) DOI: [10.1080/01443615.2019.1628191](#)]
- 11 **Candido S**, Di Maso M, Serrano D, McCubrey JA, Bortolus R, Zanin M, Battiston M, Salemi R, Libra M, Polesel J. Diagnostic value of neutrophil gelatinase-associated lipocalin/matrix metalloproteinase-9 pathway in transitional cell carcinoma of the bladder. *Tumour Biol* 2016; **37**: 9855-9863 [PMID: [26810191](#) DOI: [10.1007/s13277-016-4872-x](#)]
- 12 **Ricci S**, Bruzzese D, DI Carlo A. Evaluation of MMP-2, MMP-9, TIMP-1, TIMP-2, NGAL and MMP-9/NGAL complex in urine and sera from patients with bladder cancer. *Oncol Lett* 2015; **10**: 2527-2532 [PMID: [26622883](#) DOI: [10.3892/ol.2015.3558](#)]
- 13 **Smyth EC**, Nilsson M, Grabsch HI, van Grieken NC, Lordick F. Gastric cancer. *Lancet* 2020; **396**: 635-648 [PMID: [32861308](#) DOI: [10.1016/S0140-6736\(20\)31288-5](#)]
- 14 **Cymbaluk-Płoska A**, Chudecka-Głaz A, Pius-Sadowska E, Sompolska-Rzechuła A, Chudecka K, Bulsa M, Machaliński B, Menkiszak J. Clinical Relevance of NGAL/MMP-9 Pathway in Patients with Endometrial Cancer. *Dis Markers* 2017; **2017**: 6589262 [PMID: [29089666](#) DOI: [10.1155/2017/6589262](#)]
- 15 **DI Carlo A**. Evaluation of neutrophil gelatinase-associated lipocalin (NGAL), matrix metalloproteinase-9 (MMP-9) and their complex MMP-9/NGAL in sera and urine of patients with kidney tumors. *Oncol Lett* 2013; **5**: 1677-1681 [PMID: [23760084](#) DOI: [10.3892/ol.2013.1252](#)]
- 16 **Buonafina M**, Martinez-Martinez E, Jaisser F. More than a simple biomarker: the role of NGAL in cardiovascular and renal diseases. *Clin Sci (Lond)* 2018; **132**: 909-923 [PMID: [29739822](#) DOI: [10.1042/CS20171592](#)]
- 17 **Shalenkova MA**, Mikhailova ZD, Klimkin PF. [NGAL as a marker for some extrarenal complications in acute coronary syndrome]. *Kardiologiia* 2018; **19**: 26 [PMID: [29782286](#)]
- 18 **Marchewka Z**, Tacik A, Piwowar A. [KIM-1 and NGAL as potential biomarkers for the diagnosis and cancer progression]. *Postepy Hig Med Dosw (Online)* 2016; **70**: 329-336 [PMID: [27117109](#) DOI: [10.5604/17322693.1199716](#)]
- 19 **Dahiya K**, Gupta K, Dhankhar R, Atri R, Goyal N, Dalal D, Pal S, Ahlawat R, Kumar S. Chemoradiation in Lung Cancer: Effect on Levels of NGAL and Vitamin D in Serum. *Clin Lab* 2020; **66** [PMID: [32902227](#) DOI: [10.7754/Clin.Lab.2020.191246](#)]
- 20 **Chappell WH**, Candido S, Abrams SL, Russo S, Ove R, Martelli AM, Cocco L, Ramazzotti G, Cervello M, Montalto G, Steelman LS, Leng X, Arlinghaus RB, Libra M, McCubrey JA. Roles of p53, NF-κB and the androgen receptor in controlling NGAL expression in prostate cancer cell lines.

- Adv Biol Regul* 2018; **69**: 43-62 [PMID: [29861174](#) DOI: [10.1016/j.jbior.2018.05.002](#)]
- 21 **Falzone L**, Candido S, Salemi R, Basile MS, Scalisi A, McCubrey JA, Torino F, Signorelli SS, Montella M, Libra M. Computational identification of microRNAs associated to both epithelial to mesenchymal transition and NGAL/MMP-9 pathways in bladder cancer. *Oncotarget* 2016; **7**: 72758-72766 [PMID: [27602581](#) DOI: [10.18632/oncotarget.11805](#)]
  - 22 **Eilenberg W**, Stojkovic S, Kaider A, Kozakowski N, Domenig CM, Burghuber C, Nanobachvili J, Huber K, Klinger M, Neumayer C, Huk I, Wojta J, Demyanets S. NGAL and MMP-9/NGAL as biomarkers of plaque vulnerability and targets of statins in patients with carotid atherosclerosis. *Clin Chem Lab Med* 2017; **56**: 147-156 [PMID: [28672747](#) DOI: [10.1515/ccbm-2017-0156](#)]
  - 23 **Mondal S**, Adhikari N, Banerjee S, Amin SA, Jha T. Matrix metalloproteinase-9 (MMP-9) and its inhibitors in cancer: A minireview. *Eur J Med Chem* 2020; **194**: 112260 [PMID: [32224379](#) DOI: [10.1016/j.ejmech.2020.112260](#)]
  - 24 **Cavalieri S**, Morelli D, Martinetti A, Galli G, Nichetti F, de Braud F, Platania M. Clinical implications for pro-GRP in small cell lung cancer. A single center experience. *Int J Biol Markers* 2018; **33**: 55-61 [PMID: [28967066](#) DOI: [10.5301/ijbm.5000305](#)]
  - 25 **Kiseli M**, Caglar GS, Yarci Gursay A, Tasci T, Candar T, Akincioglu E, Pabuccu EG, Boran N, Tulunay G, Umudum H. Pro-Gastrin Releasing Peptide: A New Serum Marker for Endometrioid Adenocarcinoma. *Gynecol Obstet Invest* 2018; **83**: 540-545 [PMID: [29898448](#) DOI: [10.1159/000488854](#)]



Published by **Baishideng Publishing Group Inc**  
7041 Koll Center Parkway, Suite 160, Pleasanton, CA 94566, USA

**Telephone:** +1-925-3991568

**E-mail:** [bpgoffice@wjgnet.com](mailto:bpgoffice@wjgnet.com)

**Help Desk:** <https://www.f6publishing.com/helpdesk>

<https://www.wjgnet.com>

