

# World Journal of *Gastrointestinal Oncology*

*World J Gastrointest Oncol* 2021 November 15; 13(11): 1544-1849



### EDITORIAL

- 1544** Inhibition of poly (ADP-Ribose) polymerase: A promising strategy targeting pancreatic cancer with BRCAness phenotype  
*Jeong KY, Lee H*

### OPINION REVIEW

- 1551** New drugs for the treatment of metastatic colorectal cancer  
*Cherri S, Libertini M, Zaniboni A*

### REVIEW

- 1561** Extracellular vesicles: General features and usefulness in diagnosis and therapeutic management of colorectal cancer  
*Mammes A, Pasquier J, Mammes O, Conti M, Douard R, Loric S*
- 1599** Radiomics in hepatocellular carcinoma: A state-of-the-art review  
*Yao S, Ye Z, Wei Y, Jiang HY, Song B*
- 1616** Gut microbiota and immune system in liver cancer: Promising therapeutic implication from development to treatment  
*Bartolini I, Risaliti M, Tucci R, Muiesan P, Ringressi MN, Taddei A, Amedei A*
- 1632** Role of mammalian target of rapamycin complex 2 in primary and secondary liver cancer  
*Joechle K, Guenzle J, Hellerbrand C, Strnad P, Cramer T, Neumann UP, Lang SA*
- 1648** Regulatory role of the transforming growth factor- $\beta$  signaling pathway in the drug resistance of gastrointestinal cancers  
*Lv X, Xu G*

### MINIREVIEWS

- 1668** Novel perspective in pancreatic cancer therapy: Targeting ferroptosis pathway  
*Yang Y, Zhang ZJ, Wen Y, Xiong L, Huang YP, Wang YX, Liu K*
- 1680** Liver tumors in children with chronic liver diseases  
*Sintusek P, Phewplung T, Sanpavat A, Poovorawan Y*
- 1696** Non-surgical treatment of hilar cholangiocarcinoma  
*Inchingolo R, Acquafredda F, Ferraro V, Laera L, Surico G, Surgo A, Fiorentino A, Marini S, de'Angelis N, Memeo R, Spiliopoulos S*

**ORIGINAL ARTICLE****Basic Study**

- 1709** Genome-wide CRISPR-Cas9 screening identifies that hypoxia-inducible factor-1a-induced CBX8 transcription promotes pancreatic cancer progression *via* IRS1/AKT axis  
*Teng BW, Zhang KD, Yang YH, Guo ZY, Chen WW, Qiu ZJ*
- 1725** Shuyu pills inhibit immune escape and enhance chemosensitization in hepatocellular carcinoma  
*Deng Z, Teng YJ, Zhou Q, Ouyang ZG, Hu YX, Long HP, Hu MJ, Mei S, Lin FX, Dai XJ, Zhang BY, Feng T, Tian XF*
- 1741** Preventive and inhibitive effects of Yiwei Xiaoyu granules on the development and progression of spasmolytic polypeptide-expressing metaplasia lesions  
*Chen WQ, Tian FL, Zhang JW, Yang XJ, Li YP*
- 1755** Effects of dietary zinc deficiency on esophageal squamous cell proliferation and the mechanisms involved  
*Chen Y, Liu FX, Liu H*

**Case Control Study**

- 1766** Genetic variation of TGF- $\beta$ 2 as a protective genotype for the development of colorectal cancer in men  
*Stanilov N, Grigorova A, Velikova T, Stanilova SA*

**Clinical Trials Study**

- 1781** Induction chemotherapy with albumin-bound paclitaxel plus lobaplatin followed by concurrent radiochemotherapy for locally advanced esophageal cancer  
*Yan MH, Liu F, Qu BL, Cai BN, Yu W, Dai XK*

**SYSTEMATIC REVIEWS**

- 1791** Colorectal cancer in Arab world: A systematic review  
*Makhlouf NA, Abdel-Gawad M, Mahros AM, Lashen SA, Zaghloul M, Eliwa A, Elshemy EE, Ali-Eldin Z, Abdeltawab D, El-Raey F, Omran D, Khalaf M, Fanous N, Abdelmohsen AS, Abu-Elfath A, Abdelghani M, Farouk M, Abdelaziz M, Alboraie M*
- 1799** Cell-free DNA liquid biopsy for early detection of gastrointestinal cancers: A systematic review  
*Uhe I, Hagen ME, Ris F, Meyer J, Toso C, Douissard J*
- 1813** Atezolizumab plus bevacizumab versus sorafenib or atezolizumab alone for unresectable hepatocellular carcinoma: A systematic review  
*Ahmed F, Onwumeh-Okwundu J, Yukselen Z, Endaya Coronel MK, Zaidi M, Guntipalli P, Garimella V, Gudapati S, Mezidor MD, Andrews K, Mouchli M, Shahini E*

**META-ANALYSIS**

- 1833** Anatomical *vs* nonanatomical liver resection for solitary hepatocellular carcinoma: A systematic review and meta-analysis  
*Liu H, Hu FJ, Li H, Lan T, Wu H*

**LETTER TO THE EDITOR**

- 1847**    Hepatocellular carcinoma biomarkers, an imminent need

*Zamora-León SP*

**ABOUT COVER**

Editorial Board Member of *World Journal of Gastrointestinal Oncology*, Wen-Wei Sung, MD, PhD, Associate Professor, Doctor, Surgeon, Department of Urology; School of Medicine, Chung Shan Medical University Hospital, Taichung, Taiwan, Taichung 40201, Taiwan. flutewayne@gmail.com

**AIMS AND SCOPE**

The primary aim of *World Journal of Gastrointestinal Oncology* (WJGO, *World J Gastrointest Oncol*) is to provide scholars and readers from various fields of gastrointestinal oncology with a platform to publish high-quality basic and clinical research articles and communicate their research findings online.

WJGO mainly publishes articles reporting research results and findings obtained in the field of gastrointestinal oncology and covering a wide range of topics including liver cell adenoma, gastric neoplasms, appendiceal neoplasms, biliary tract neoplasms, hepatocellular carcinoma, pancreatic carcinoma, cecal neoplasms, colonic neoplasms, colorectal neoplasms, duodenal neoplasms, esophageal neoplasms, gallbladder neoplasms, etc.

**INDEXING/ABSTRACTING**

The WJGO is now indexed in Science Citation Index Expanded (also known as SciSearch®), PubMed, PubMed Central, and Scopus. The 2021 edition of Journal Citation Reports® cites the 2020 impact factor (IF) for WJGO as 3.393; IF without journal self cites: 3.333; 5-year IF: 3.519; Journal Citation Indicator: 0.5; Ranking: 163 among 242 journals in oncology; Quartile category: Q3; Ranking: 60 among 92 journals in gastroenterology and hepatology; and Quartile category: Q3. The WJGO's CiteScore for 2020 is 3.3 and Scopus CiteScore rank 2020: Gastroenterology is 70/136.

**RESPONSIBLE EDITORS FOR THIS ISSUE**

Production Editor: Ying-Yi Yuan; Production Department Director: Xiang Li; Editorial Office Director: Ya-Juan Ma.

**NAME OF JOURNAL**

*World Journal of Gastrointestinal Oncology*

**ISSN**

ISSN 1948-5204 (online)

**LAUNCH DATE**

February 15, 2009

**FREQUENCY**

Monthly

**EDITORS-IN-CHIEF**

Rosa M Jimenez Rodriguez, Pashtoon M Kasi, Monjur Ahmed, Florin Burada

**EDITORIAL BOARD MEMBERS**

<https://www.wjgnet.com/1948-5204/editorialboard.htm>

**PUBLICATION DATE**

November 15, 2021

**COPYRIGHT**

© 2021 Baishideng Publishing Group Inc

**INSTRUCTIONS TO AUTHORS**

<https://www.wjgnet.com/bpg/gerinfo/204>

**GUIDELINES FOR ETHICS DOCUMENTS**

<https://www.wjgnet.com/bpg/GerInfo/287>

**GUIDELINES FOR NON-NATIVE SPEAKERS OF ENGLISH**

<https://www.wjgnet.com/bpg/gerinfo/240>

**PUBLICATION ETHICS**

<https://www.wjgnet.com/bpg/GerInfo/288>

**PUBLICATION MISCONDUCT**

<https://www.wjgnet.com/bpg/gerinfo/208>

**ARTICLE PROCESSING CHARGE**

<https://www.wjgnet.com/bpg/gerinfo/242>

**STEPS FOR SUBMITTING MANUSCRIPTS**

<https://www.wjgnet.com/bpg/GerInfo/239>

**ONLINE SUBMISSION**

<https://www.f6publishing.com>



## Radiomics in hepatocellular carcinoma: A state-of-the-art review

Shan Yao, Zheng Ye, Yi Wei, Han-Yu Jiang, Bin Song

**ORCID number:** Shan Yao 0000-0002-0665-2566; Zheng Ye 0000-0001-6715-0183; Yi Wei 0000-0003-3993-9747; Han-Yu Jiang 0000-0002-7726-1618; Bin Song 0000-0001-7007-6367.

**Author contributions:** Yao S and Song B designed the research; Yao S and Ye Z conducted literature search and analysis; Yao S wrote the paper; Yao S and Ye Z made critical revisions to the manuscript; Wei Y and Jiang HY provided material support; Song B provided funding for the article.

**Supported by** The Science and Technology Support Program of Sichuan Province, No. 2021YFS0021 and No. 2021YFS0144; and the National Natural Science Foundation of China, No. 81771797 and No. 81971571.

**Conflict-of-interest statement:** All authors declare no potential conflict of interests related to this publication.

**Open-Access:** This article is an open-access article that was selected by an in-house editor and fully peer-reviewed by external reviewers. It is distributed in accordance with the Creative Commons Attribution NonCommercial (CC BY-NC 4.0) license, which permits others to distribute, remix, adapt, build upon this work non-commercially,

Shan Yao, Zheng Ye, Yi Wei, Han-Yu Jiang, Bin Song, Department of Radiology, West China Hospital, Sichuan University, Chengdu 610041, Sichuan Province, China

**Corresponding author:** Bin Song, MD, PhD, Chief Doctor, Director, Professor, Department of Radiology, West China Hospital, Sichuan University, No. 37 Guoxue Alley, Chengdu 610041, Sichuan Province, China. [cjr.songbin@vip.163.com](mailto:cjr.songbin@vip.163.com)

### Abstract

Hepatocellular carcinoma (HCC) is the most common cancer and the second major contributor to cancer-related mortality. Radiomics, a burgeoning technology that can provide invisible high-dimensional quantitative and mineable data derived from routine-acquired images, has enormous potential for HCC management from diagnosis to prognosis as well as providing contributions to the rapidly developing deep learning methodology. This article aims to review the radiomics approach and its current state-of-the-art clinical application scenario in HCC. The limitations, challenges, and thoughts on future directions are also summarized.

**Key Words:** Hepatocellular carcinoma; Radiomics; Deep learning; Artificial intelligence; Medical imaging; Predictive modeling

©The Author(s) 2021. Published by Baishideng Publishing Group Inc. All rights reserved.

**Core Tip:** Medical imaging plays an indispensable role in hepatocellular carcinoma (HCC) clinical settings. Conventional imaging methods, however, provide limited and insufficient information. Recent studies have shown that radiomics and deep learning enable comprehensive insightful data mining that has achieved favorable performance in the detection and classification, diagnosis and differentiation, staging and grading, aggressive behavior, treatment responses, prognosis, and survival rates of HCC. Nevertheless, the wide implementation of radiomics and deep learning in actual routine clinical practice requires sustainable validation and optimization.

**Citation:** Yao S, Ye Z, Wei Y, Jiang HY, Song B. Radiomics in hepatocellular carcinoma: A state-of-the-art review. *World J Gastrointest Oncol* 2021; 13(11): 1599-1615

**URL:** <https://www.wjgnet.com/1948-5204/full/v13/i11/1599.htm>

**DOI:** <https://dx.doi.org/10.4251/wjgo.v13.i11.1599>

and license their derivative works on different terms, provided the original work is properly cited and the use is non-commercial. See: <http://creativecommons.org/licenses/by-nc/4.0/>

#### Provenance and peer review:

Invited article; Externally peer reviewed.

**Specialty type:** Gastroenterology and hepatology

**Country/Territory of origin:** China

#### Peer-review report's scientific quality classification

Grade A (Excellent): 0

Grade B (Very good): B

Grade C (Good): 0

Grade D (Fair): 0

Grade E (Poor): 0

**Received:** February 22, 2021

**Peer-review started:** February 22, 2021

**First decision:** April 19, 2021

**Revised:** April 22, 2021

**Accepted:** August 20, 2021

**Article in press:** August 20, 2021

**Published online:** November 15, 2021

**P-Reviewer:** Lee Y

**S-Editor:** Wu YXJ

**L-Editor:** Wang TQ

**P-Editor:** Yuan YY



## INTRODUCTION

Hepatocellular carcinoma (HCC) is the most common cancer with fast rising incidence in both males and females and the second major contributor to cancer-related mortality worldwide[1,2]. Medical imaging has been playing a pivotal role in the entire diagnosis and management process of HCC, with the capacity to non-invasively provide multi-parameter, multidimensional, and multi-modality structural and functional information on lesion and peri-tissues on computed tomography (CT) and magnetic resonance imaging (MRI)[3-7].

Although the current diagnosis and treatment system continues to improve progressively, some crucial aspects such as the high heterogeneity and diverse biological behaviors of HCC tumors, which directly affect the prognosis and survival of patients, remain a concern and need to be addressed[8,9].

However, certain limitations of traditional imaging and report methods such as insufficient depth of imaging feature interpretations, the influence of subjective variability among observers, and unavailability to meet the needs of modern precise medicine may hinder comprehensive evaluations and personalized treatment of HCC.

In recent years, with rapid developments in big data mining and artificial intelligence (AI) fields, medical imaging in gastrointestinal and abdominal diseases has been empowered with more efficient combinations of data[10-12]. Radiomics, a burgeoning technology that could transform potential pathological and physiological information from routine-acquired images into high-dimensional quantitative and mineable imaging data[13-15], has been demonstrating great potential in the diagnosis, classification and staging, clinical decision assistance, and prognosis and survival predictions of HCC.

Hence, this article reviews the radiomics approach and its current state-of-the-art clinical application scenario in HCC. Additionally, the limitations, challenges, and thoughts on future directions are summarized.

## RADIOMICS BASIC WORKFLOW IN HCC

Radiomics is a multi-disciplinary technology that refers to extraction and analysis of a large number of advanced and quantitative image features from medical imaging such as CT, MRI, positron emission tomography (PET), or ultrasound (US), with high fidelity and high throughput[13,15,16]. The core steps include data acquisition, image segmentation, feature extractions, analysis, and model building and validation. Most current research on radiomics in HCC was performed with the general procedure described above (Figure 1).

### Image acquisition and preprocessing

At the beginning and as the basis of radiomics flow, medical images can be acquired using CT, MRI, US, or PET for single- or multi-center studies with retrospective or prospective cohorts and different task targets. CT and MRI-based, retrospective, single-center studies account for the vast majority of HCC radiomics publications. Given that the reproducibility and comparability of image characteristic analysis are influenced by facilities, platforms, parameters, and factors like those in clinical practice, there is a clear need for standardized image acquisition and reconstruction protocols[15,16]. Besides, in order to avoid bias due to inconsistent pixels, gray levels, or variable resolutions, image preprocessing mainly using resampling and normalization is indispensable to ensure a feasible and repeatable subsequent analysis[17,18].

### Segmentation

Segmentation of the regions of interest (ROIs) or the volumes of interest (VOIs) is normally performed in three ways: Manual, semi-automatic, and automatic, among which the first is used most often at present. Manual segmentation relies on the radiologists to identify and annotate lesions manually. It has the advantage of higher accuracy, although it is time-consuming with low efficiency and inter-operator variability. There is a great availability of open-source software for segmentation, such as ITK-SNAP ([www.itksnap.org](http://www.itksnap.org)), 3D Slicer ([www.slicer.org](http://www.slicer.org)), MIM ([www.mimsoft.com](http://www.mimsoft.com)), and ImageJ (<https://imagej.nih.gov/ij/>). In recent years, semi-automatic and automatic segmentations have been more developed with the assistance of a series of computer algorithms[19-23].



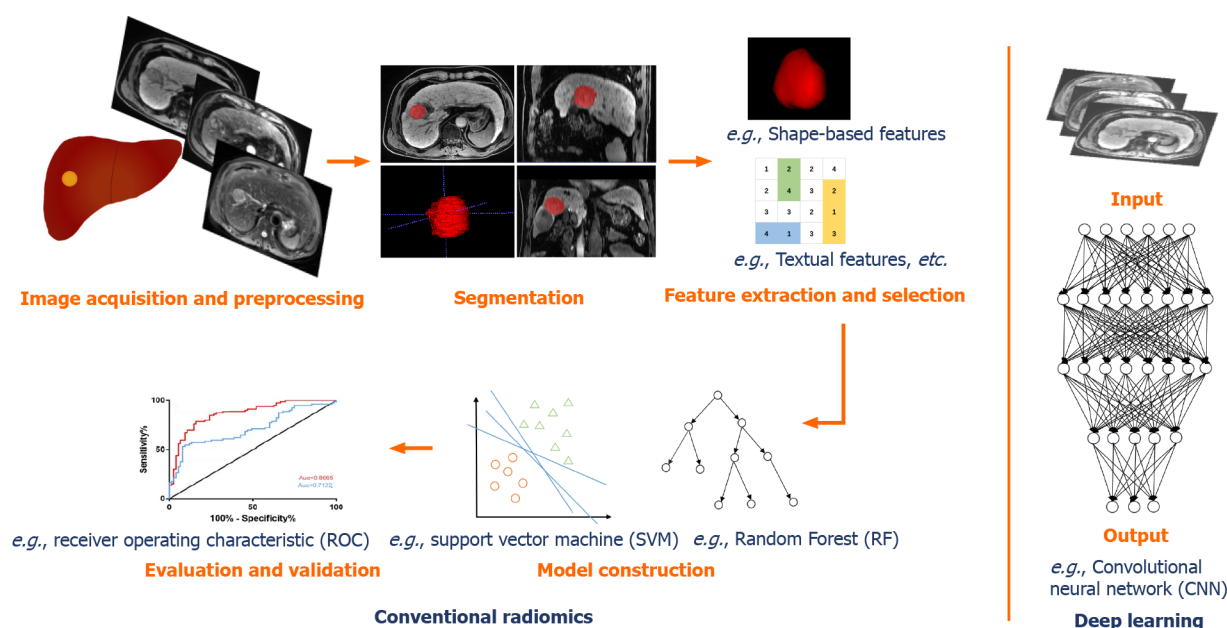


Figure 1 General workflow of radiomics and deep learning in hepatocellular carcinoma.

### Feature extraction and selection

A number of features can be extracted from the 2D ROIs or 3D VOIs, which are attributed to the basis of radiomics analysis. Features can be divided into two types: “Semantic” and “agnostic”[15]. The “semantic” features include qualitative features like location, size, shape, and vascularity. The “agnostic” features refer to mathematically quantitative descriptions of the invisible characteristics of lesions, which can be roughly classified into four types: (1) Morphologic features that are expressed as statistical values; (2) First-order features (histogram features) reflecting the distributions of different gray levels of lesion, mainly including the standard deviation, energy, entropy, kurtosis, sharpness, skewness, and variance; (3) Second-order features (textual features) that describe the tumor heterogeneity addressing the spatial relationships of pixels or voxels, commonly using a gray-level co-occurrence matrix and gray-level run-length matrix[24,25]; and (4) Higher-order features that were extracted utilizing various filters, such as wavelet transforms, Laplacian filters, and Minkowski functionals.

However, several features are not desirable. Redundant and irrelevant features affect the accuracy and robustness of the model. In order to avoid overfitting and improve accuracy, it is necessary to select the most significant and informative features from a large number of extracted features for dimensionality reduction prior to modeling. This step has been commonly carried out in a variety of machine learning methods, such as filter-type methods like correlation or univariate regression, and embedding methods like least absolute shrinkage and the selection operator (LASSO) algorithm[26].

### Model construction and validation

Clinical task-oriented models are built utilizing selected significant features, appropriately with the addition of some clinical indicators and laboratory indexes. In traditional machine learning, the commonly used methods are logistic regression, support vector machines (SVMs), decision trees, random forest (RF), K-nearest neighbor, and clustering analysis, *etc.* According to Parmar *et al*[26], the choice of modeling method has a dominant influence on the radiomics analysis results. Hence, various methods can be applied to select the model with the best performance in practice.

Taking into account the reliability and generalizability, each model must be evaluated and validated. The area under the receiver operating characteristic curve (AUC), decision curve analysis, and nomograms are commonly used for performance evaluations. Internal validation is indispensable, and external (multi-center) validation should also be conducted if conditions permit. However, most of the present studies are single-center studies with small samples, and by contrast, only a few omics models have been validated externally by multiple centers.



## APPLICATIONS OF RADIOMICS IN HCC

Radiomics has been widely applied in diagnosis or differential diagnosis, pathological grading, aggressiveness evaluation, clinical treatment assistance, and recurrence and survival predictions of HCC. The tasks, methods, and results of some representative studies are listed in [Table 1](#).

### Diagnosis and differentiation of HCC

Early and accurate diagnosis of tumors is decisive for clinical decision-making and treatments. As the most common primary liver cancer, HCC can be diagnosed based on medical imaging findings without histopathological confirmation according to clinical practice guidelines[27,28].

However, some lesions with similar imaging manifestations to HCC, such as combined hepatocellular cholangiocarcinoma (cHCC-CC), intrahepatic cholangiocarcinoma (ICC), hepatic adenoma (HCA), and hepatic hemangioma (HH), are still challenging regarding diagnosis in conventional imaging. Liu *et al*[29] investigated the differentiation of HCC from non-HCC tumors (cHCC-CC and CC) with MRI and CT radiomics features using an SVM machine learning algorithm. Their results showed that contrast-enhanced MRI (CE-MRI) phases were quite useful for differentiation of HCC from non-HCC with an AUC of 0.79-0.81, as well as pre-contrast and portal phase CT with an AUC of 0.81 and 0.71, respectively. Although the study was limited by inconsistent imaging protocols and a sample size that was too small to separate into training and validation cohorts. Lewis *et al*[30] used the histogram parameters of apparent diffusion coefficient (ADC) of diffusion weighted imaging (DWI) and liver imaging reporting and data system (LI-RADS) classifications to distinguish HCC from other primary liver cancers (ICC and cHCC-ICC). The results presented that the prediction model combined with gender, ADC fifth percentile, and LI-RADS classification obtained the best predictive performance with an AUC of 0.90[30]. Regarding the distinction of HCA and HCC, Nie *et al*[31] reported that the CT-based radiomics nomogram was a potential tool to accurately differentiate HCA from HCC in the noncirrhotic liver with favorable performance (AUC of 0.96 in the training set and 0.94 in the test set). Similarly, this CT-based radiomics nomogram also achieved effective values in the preoperative differential diagnosis of FNH and HCC in the noncirrhotic liver (AUC of 0.979 in the training set and 0.917 in the test set)[32]. Another study by Wu *et al*[33] developed and validated a radiomics signature using derived features from pre-contrast MR imaging sets to distinguish HCC and HH. The results witnessed an improved diagnostic performance of combination of in-phase, out-phase, T2 weighted imaging (T2WI), and DWI with logistic regression (AUC: 0.86 in the training set and 0.89 in the test set), which outperformed the less experienced radiologist and was nearly equal to the experienced radiologist. These radiomics studies contributed potential supplements to accurate diagnosis and differentiation of HCC in medical imaging, but the results remain to be widely validated and amended in the clinical practice.

### Pathological grading of HCC

The pathological grade is one of the vital factors affecting intrahepatic tumors recurrence, that is, high-grade tumors are associated with a high intrahepatic recurrence rate[34,35]. The management of HCC varies with different pathological grades, and patients with higher intrahepatic recurrence rates require special treatments for surgery and follow-up compared with the lower-risk patients[6,36]. Thus, accurate prediction of HCC pathological grade might promote clinical decision-making and formulation of the most appropriate treatment plan. Wu *et al*[37] built radiomics signatures on the basis of T1-weighted imaging (T1WI) and T2WI generated in LASSO, and assessed the predicted values of radiomics, clinical factors, and the combined models. The results showed that there were significant differences in categorization of high- and low-grade HCCs in MRI-based radiomics signatures ( $P < 0.05$ ). The predictive value of the radiomics signature model outperformed the clinical factors-based model (AUC: 0.74 *vs* 0.60, respectively), whereas the combined model incorporating both achieved the best performance with an AUC of 0.80 [95% confidence interval (CI): 0.65-0.90][37]. Another similar study by Mao *et al*[38] aimed to predict the pathological grades of HCC preoperatively based on contrast-enhanced CT (CECT)-derived radiomics signatures. They established models using shape, first-order, second order, and higher-order features extracted from arterial phase (AP)- and venous phase-CECT images *via* recursive feature elimination and eXtreme Gradient Boosting (XGBoost). They also found that combining radiomics signatures with clinical factors

Table 1 Some representative studies of radiomics in hepatocellular carcinoma

Ref.	Application task	Study design	Imaging modality	Radiomics features	Algorithm	Sample size	Training set	Test/validation set	Performance
Liu <i>et al</i> [29], 2021	Differentiation of cHCC-CC from HCC and CC	Retrospective, single-center	CT, MRI	1419	SVM	85 patients with HCC (37), cHCC-CC (24) and CC (24)	85	NA	Excellent performance for differentiation of HCC from non-HCC (AUC: 0.79-0.81 in MRI, AUC: 0.71-0.81 in CT)
Nie <i>et al</i> [32], 2020	Differentiation of HCA from HCC	Retrospective, two-institutes	CT	3768	mRMR, LASSO	131 patients with HCC (85) and HCA (46)	93	38	Favorable performance (AUC: 0.96 in training set, AUC: 0.94 in test set)
Wu <i>et al</i> [33], 2019	Pathological grade of HCC	Retrospective, single-center	MRI	656	LASSO	170 patients with HCCs	125	45	Radiomics signature model outperformed the clinical factors-based model; the combined model achieved the best performance (AUC: 0.80)
Mao <i>et al</i> [38], 2020	Pathological grade of HCC	Retrospective, single-center	CT	3376	RFE, XGBoost	297 patients with HCCs	237	60	The radiomics signatures combined with clinical factors significantly achieved the best performance (AUC: 0.8014)
Xu <i>et al</i> [43], 2019	Preoperative prediction of MVI in HCC	Retrospective, single-center	CT	7260	Ref-SVM, Multivariable logistic regression	495 patients with HCC	300	145 (test); 50 (validation)	Good performance (AUC: 0.909 in the training/ validation set, AUC: 0.889 in the test set)
Chong <i>et al</i> [47], 2021	Preoperative prediction of MVI in HCC	Retrospective, single-center	MRI	854	LASSO, RF, logistic regression	356 patients with HCCs $\leq 5$ cm	250	106	AUC: 0.920 using RF; AUC: 0.879 using logistic regression (in validation set)
Fu <i>et al</i> [54], 2019	Assistant in optimal treatment choices of HCC between LR and TACE	Retrospective, multi-center (5 institutions)	MRI	708	LASSO, Akaike information criterion	520 patients with HCC	302	218	Good discrimination and calibrations for 3-year PFS (AUC: 0.80 in training set, AUC: 0.75 in validation set); threshold $\leq -5.00$ : suggesting LR, threshold $> -5.00$ : suggesting TACE
Sun <i>et al</i> [56], 2020	Predicting the outcome of TACE for unresectable HCC	Retrospective, single-center	MRI	3376	LASSO, multivariable logistic regression	84 patients with BCLC B stage HCC	67	17	The radiomics signatures combined with clinical factors significantly achieved the best performance (AUC: 0.8014)
Ji <i>et al</i> [66], 2020	Predicting early recurrence after LR	Retrospective, multi-center (3 institutions)	CT	846	LASSO-Cox regression	295 patients with HCC	177 (Institution 1)	118 (Institution 2 and 3, external validation)	Better prognostic ability (C-index: 0.77, $P < 0.05$ ), lower prediction error (integrated brier score: 0.14), and better clinical usefulness than rival models and staging systems
Zhao <i>et al</i> [67], 2020	Predicting early recurrence after LR	Retrospective, single-center	MRI	1146	LASSO, stepwise and multivariable logistic regression	113 patients with HCC	78	35	The nomogram integrating the Rad score and clinicopathologic-radiologic risk factors

									showed better discrimination and clinical utility (AUC: 0.873)
Wang <i>et al</i> [75], 2020	Predicting 5-year survival after LR	Retrospective, multi-center (2 institutions)	MRI	3144	RF, multivariate logistic regression	201 patients with HCC	160	41 (five-fold cross-validation)	The model incorporating the radiomics signature and clinical risk factors obtained good calibration and satisfactory discrimination (AUC: 0.9804 in training set, AUC: 0.7578 in validation set)
Song <i>et al</i> [76], 2020	Predicting RFS after TACE	Retrospective, single-center	MRI	396	LASSO-Cox regression, multivariate Cox regression	184 patients with HCC	110	74	The model using the radiomics signature with the clinical-radiological risk factors showed the best performance (C-index: 0.802)

cHCC-CC: Combined hepatocellular cholangiocarcinoma; NA: Not available; HCC: Hepatocellular carcinoma; CC: Cholangiocarcinoma; CT: Computed tomography; MRI: Magnetic resonance imaging; GLCM: Gray-level co-occurrence matrix; SVM: Support vector machine; AUC: Area under the receiver operating characteristic curve; HCA: Hepatic adenoma; mRMR: Maximal relevance and minimum redundancy; LASSO: Least absolute shrinkage and the selection operator; RFE: Recursive feature elimination; XGBoost: eXtreme gradient boosting; MVI: Microvascular invasion; Ref-SVM: Recursive feature selection support vector machine; RF: Random forest; LR: Liver resection; TACE: Transarterial chemoembolization; PFS: Progression-free survival; BCLC: Barcelona clinic liver cancer; C-index: Concordance index; RFS: Recurrence free survival.

significantly improved the prediction performance at an AUC of 0.8014 (95%CI: 0.6899-0.9129)[38]. It can be known that radiomics is a powerful tool for predicting the pathological grade of HCC closely related to the follow-up management, as well as extending the predictive value of clinical factors.

### Aggressiveness evaluation of HCC

The aggressive tumor behavior is strongly linked to the prognosis of HCC patients. Microvascular invasion (MVI), defined as tumor cell nest in vessels lined with the endothelium that can only be determined on the postoperative histologic examination, is one of the crucial independent predictors of early recurrence (ER) of HCC patients after surgical treatment[39-41]. So, it is of remarkable importance to accurately evaluate and predict the MVI of HCC preoperatively, so as to ensure and improve the prognosis of patients. Since Bakr *et al*[42] pointed out the potential of a CT-based radiomics signature as a surrogate for MVI in HCC (AUC: 0.76, 95%CI: 0.58-0.94) though in a small cohort, various researchers have explored an underlying association focusing on this field. Xu *et al*[43] developed a CT-based radiomics model integrating large-scale clinical factors and imaging features to predict the MVI and outcomes in surgically resected patients with HCC. The approach demonstrated good performance with an AUC of 0.909 in the training/validation set and 0.889 in the test set[43]. A radiomics nomogram based on CECT established by Ma *et al*[44] showed that portal venous phase (PVP) radiomics signatures exhibited better performance to predict MVI than AP and delay phase (DP) (AUC in validation sets: 0.793 *vs* 0.684 and 0.490, respectively). Another study performed in two independent centers by Zhang *et al*[45] shared the same goal as those above, constructing CECT-based radiomics signatures in a LASSO algorithm and multivariable logistic regression. Enrolled patients from institution 1 were divided into the training and the test set, and patients from institution 2 served as an independent validation set, of which the AUC of MVI status predictions were 0.780, 0.776, and 0.743, respectively, and the AUC of the final MVI risk classifier-integrated clinical stage reached 0.783, 0.778, and 0.740, respectively[45].

Regarding an MRI radiomics model for MVI prediction in HCC, Feng *et al*[46] first reported that the combined intratumoral and peritumoral radiomics model derived from gadolinium-ethoxybenzyl-diethylenetriamine (Gd-EOB-DTPA)-enhanced MRI showed effective value with an AUC of 0.83 (95%CI: 0.71-0.95) in the validation cohort along with a sensitivity of 90% and specificity of 75%[46]. Additionally, specific to solitary HCCs  $\leq 5$  cm, Chong *et al*[47] built a multi-scale and multi-parametric radiomics nomogram based on Gd-EOB-DTPA MRI, and this also yielded favorable performance for preoperative MVI predictions, of which the AUC reached up to 0.920

(95% CI: 0.861-0.979) using RF and 0.879 (95% CI: 0.820-0.938) using logistic regression in the validation set[47]. Another study by Yang *et al*[48] indicated the helpful value of hepatobiliary phase (HBP) for predicting MVI, showing that HBP T1WI images and HBP T1 maps were independent risk factors for MVI and the model incorporating the clinicoradiological factors and HBP-derived radiomic features outperformed the former only in the training cohort (AUC: 0.943 *vs* 0.850,  $P = 0.002$ ), though there was no statistical significance in the validation set (AUC: 0.861 *vs* 0.759,  $P = 0.111$ )[48]. These studies provided new perspectives and approaches for aggressiveness evaluation of HCC and might help to improve the prognosis of patients and assist in the precise treatment plan making.

### **Clinical treatment assistance for HCC**

Caution needs to be taken comprehensively when it comes to selecting the optimal treatment for HCC patients. In addition to the patients' conditions and tumor stage, the trauma of the treatments which is associated with deterioration of liver function leading to death should be also given full consideration[49]. For example, liver resection (LR) is curative to remove the tumor completely but highly traumatic. Transarterial chemoembolization (TACE) is minimally invasive while may leave some residual tumors. And their adaptation has expanded and even overlapped with the development of medical technologies[50-53]. Focusing on this, Fu *et al*[54] proposed an individualized model to assist appropriate treatment choices for HCC patients between LR and TACE. They extracted radiomics features from CT images of HCC patients in five centers and combined them with clinical factors and radiological characteristics to construct a progression-free survival (PFS) model. The model yielded good discrimination and calibrations for 3-year PFS with an AUC of 0.80 in the training set and 0.75 in the validation set, outperforming the other four state-of-the-art models. And a nomogram was built to subdivide patients for optimal treatments by the threshold of the score difference. In the threshold  $\leq -5.00$  group, LR provided better PFS than TACE, which suggested LR to be a potential better option [hazard ratio (HR) = 0.50,  $P = 0.014$  in the training set; HR = 0.52,  $P = 0.026$  in the validation set]. For the other patients, LR and TACE had similar PFS (HR = 0.84,  $P = 0.388$  in the training set; HR = 1.14,  $P = 0.614$  in the validation set). TACE seemed to be a better choice as it was less invasive and helped to control unnecessary trauma and risks[54]. Moreover, for HCC patients who underwent hepatectomy, Cai *et al*[55] developed and validated a radiomics-based nomogram derived from PVP-CT images to predict posthepatectomy liver failure (PHLF) preoperatively, which exhibited superior discrimination with an AUC of 0.896 (95% CI: 0.774-1.000) in the validation set rather than other three methods [Child-Pugh, Model of End Stage Liver Disease (MELD), and albumin bilirubin]. Furthermore, another 13 patients served for a pilot prospective analysis, and the radiomics nomogram predicted PHLF effectively with an AUC of 0.833 (95% CI: 0.591-1.000)[55]. For unresectable HCC patients, Sun *et al*[56] established a radiomics model based on preoperative multiparameter MRI (mp-MRI) predicting early progression after TACE. The results identified the radiomics signature as an independent parameter of progressive disease (PD), and the mp-MRI signature achieved the greatest benefit with an AUC of 0.800 compared with the single ones[56]. These studies demonstrated the guiding significance of radiomics in assisting clinical treatment selections for HCC, especially when there were more controversies, which could help patients and doctors weigh the advantages and disadvantages and choose the optimal personalized plan.

### **Recurrence and survival prediction in HCC**

In routine clinical settings, LR is preferred as the first-line treatment option for HCC patients at an early stage and with preserved liver function, whereas liver transplantation (LT) is recommended for end-stage HCC patients with clinically proven portal hypertension and early-stage HCC meeting the Milan criteria. For patients who are not suitable for LR or LT (Barcelona Clinic Liver Cancer (BCLC) stage 0-A and some selected BCLC stage B), non-surgical local ablation techniques are considered as best choices[27,28,57,58]. However, post-treatment recurrence remains a thorny problem that hinders clinical management progress and patient survival[59-65]. Therefore, it is of emerging significance to preoperatively predict the recurrence risk after treatments.

Several radiomics studies based on preoperative CT or MRI have yielded favorable performance in post-LR ER predictions[66-72]. In a recent multi-center study by Ji *et al* [66], recurrence-related radiomic features were extracted from preoperative CECT images of 295 surgically proven HCC patients from three independent institutions and then built with LASSO and Cox regression. The two radiomics-based models pre-

sented better prognostic ability [concordance index (C-index): 0.77,  $P < 0.05$ ], lower prediction error (integrated Brier score: 0.14), and better clinical usefulness than rival models and staging systems[66]. Another mp-MRI based radiomics study by Zhao *et al* [67] established radiomics models deriving from in-out-phase T1WI, T2WI, DWI, and CE-MRI images. The combined nomogram integrating the Rad score and clinicopathologic-radiologic (CPR) risk factors showed better discrimination and clinical utility than the CPR and radiomics models alone (AUC: 0.873 *vs* 0.742, respectively). For recurrence predictions for HCC after LT, Guo *et al*[73] also combined the CT-based radiomics signature and clinical risk factors to develop and validate a radiomics nomogram in LASSO and Cox regression algorithm, which achieved good predictive performance for recurrence-free survival with a C-index of 0.785 (95%CI: 0.674-0.895) in the training set and 0.789 (95%CI: 0.620-0.957) in the validation set. As for HCC patients who underwent ablation, Yuan *et al*[74] extracted radiomics features from three-phase preoperative CECT images (AP, PVP, and parenchymal phase), selected the significant features by mMRF, and then built a radiomics signature using LASSO and Cox regression. Similarly, the PVP-combined model adding the clinicopathological factors produced the best predictive performance to predict ER after curative ablation with a C-index of 0.792 (95%CI: 0.727-0.857) in the training set and 0.755 (95%CI: 0.651-0.860) in the validation set[74].

A radiomics approach has demonstrated encouraging results in survival analysis of post-treatment HCC patients[75-78]. In a recent multi-center study, Wang *et al*[75] worked on predicting the 5-year survival of HCC patients after LR using an MRI-based radiomics model. They built radiomics signatures with an RF method and developed a combined model incorporating radiomics signatures and clinical risk factors, which obtained good calibration and satisfactory discrimination for survival prediction with an AUC of 0.9804 in the training set and 0.7578 in the validation set [75]. Kim *et al*[77] predicted the overall survival (OS) of HCC patients who underwent TACE with the use of a pretreatment CT-based radiomics model. They applied LASSO-Cox regression algorithm for optimal survival-related feature selection and constructed a predictive model combining radiomics signature with clinical factors. The results suggested that the composite model can better predict the OS after TACE (HR: 19.88, 95%CI: 6.37-92.02,  $P < 0.001$ ) compared with radiomics and clinical models only[77]. In these studies, a substantial growth was observed in the performance of the state-of-the-art conventional models when adding the radiomics signature. They demonstrated the considerable value of radiomics approach to predict the ER risk and survival conditions of post-treatment HCC patients, which may facilitate personalized risk stratification and enlighten a new way for further clinical decision-making for HCC patients.

## DEEP LEARNING BASED RADIOMICS

Deep learning, a ramification of machine learning algorithms developed from neural networks with multiple layers, has been widely used in medical image analysis with promising expectations[79,80]. As a type of representation learning method, deep learning takes the strength of excellent self-taught ability which enables automatic learning and training of target-related features without manual segmentation and extraction (Figure 1). It has demonstrated deeper and more comprehensive data mining compared with radiomics based on traditional machine learning. Convolutional neural network (CNN) is the most popular model, meanwhile stacked autoencoders (SAEs), restricted Boltzmann machines (RBM), deep belief network (DBN), GAN, and U-net have been also applied[81-85]. CNNs are mainly composed of three network layers, namely, the convolutional, the sampling, and the full connection layer, of which the core mechanisms include multi-layer stacking, local connection, weight sharing, and pooling. Automatic learning of informative features of medical images is accomplished without the need for manual segmentation and feature extraction. SAE is an unsupervised learning method, which trains the models by adjusting the advantage parameters of the encoder and layer. RBM, composed of visible units and hidden units, is a kind of generative stochastic neural network that learns probability distributions from input data sets. DBN can train the weights between its multiple neurons, which enables the whole neural network to generate training data according to the maximum probability. The models are chosen for different oriented tasks in HCC, including segmentation, tumor detection or classification, diagnosis and differentiation, aggressiveness evaluation, prognosis and survival analysis, and image quality improvement. The tasks, methods, and results of some representative studies of deep



learning in HCC are presented in [Table 2](#).

## APPLICATIONS OF DEEP LEARNING-BASED RADIOMICS IN HCC

### **Detection and segmentation of HCC**

Manual segmentation is limited as it is time-consuming with low efficiency and inter-operator variability. Thus, accurate and automatic liver and tumor segmentation methods are demanded in clinical practice. Deep learning algorithms, by contrast, enable automated segmentation and have been applied in various studies[86-91]. Bousabarah *et al*[91] trained a deep CNN (DCNN) with a U-net architecture using multiphasic CE-MRI images and the dice similarity coefficient (DSC) was used to evaluate the performance. Their approach demonstrated the feasibility of automatically detecting and segmenting the liver and HCCs, and the mean DSC between automatically detected lesions using the DCNN + RF + thresholding and corresponding manual segmentations was 0.64/0.68 (validation/test), and 0.91/0.91 for liver segmentations[91]. However, most studies investigated the whole liver, liver tissues, or malignant tumors, whereas a few focused specifically on automatic segmentation of HCC, which should be developed and validated in further studies.

### **Diagnosis, differentiation, and classification of HCC**

Yasaka *et al*[92] utilized a deep learning algorithm with CNN to differentiate HCCs and other liver masses based on three-phase CT images (pre-contrast, AP, and DP) and obtained an accuracy of 84% in the test set. Hamm *et al*[93] designed a proof-of-concept CNN-based deep learning system (DLS) for liver tumor diagnosis on the basis of mp-MRI. The DLS achieved an accuracy of 92% and an AUC of 0.992 for HCC classification. And they further indicated an “interpretable” DLS that could identify the correct radiological features of each test lesion on MR images with a positive predictive value of 76.5% and sensitivity of 82.9%[94]. Another pilot study by Yamashita *et al*[95] developed a CNN-based model with LIRADS to diagnose and categorize HCC on CT and MRI. It exhibited that the transfer learning model outperformed the custom-made model with an overall accuracy of 60.4% and AUCs of 0.85, 0.90, 0.63, and 0.82 for LR-1/2, LR-3, LR-4, and LR-5, respectively, whereas the external validation results were not accurate enough[95]. Although the results were promising, those studies were preliminary and demonstrated the initial feasibility of deep learning in the diagnosis, differentiation, and classification of HCC.

### **Aggressiveness, treatment outcomes, and survival evaluation of HCC**

The application of deep learning in aggressiveness behavior evaluation, treatment outcome prediction, and recurrence and survival analysis of HCC were not as sophisticated as those of conventional radiomics, but they also witnessed dramatic potential and clinical value. For MVI prediction, Wang *et al*[96] established a deep learning model with a CNN based on preoperative DWI and reported that the combination of deep features from the  $b = 0$ ,  $b = 100$ ,  $b = 600$ , and ADC images presented the best results (AUC: 0.79,  $P = 0.002$ )[96]. With regard to prediction of treatment responses, Peng *et al*[97] trained and validated a deep learning model using ResNet50 on pre-operative CT images of HCC patients who underwent TACE from three independent institutions. This multi-center study yielded excellent predictive performance for complete response, partial response, stable disease, and PD with an accuracy of 84.3% and AUC of 0.97, 0.96, 0.95, and 0.96, respectively, in the training set, and an accuracy of 85.1% and 82.8% in the two validation sets[97]. Another multi-center study by Zhang *et al*[98] involved preoperative CECT images and they adopted a deep learning-based model utilizing DenseNet to predict OS of HCC patients treated with TACE plus sorafenib, which achieved favorable prediction performance with a C-index of 0.717 in the training set and 0.714 in the validation set.

### **Image quality improvement**

Deep learning has been applied for image quality improvement, which helps with the diagnosis and interpretation of HCC and other liver lesions more accurately. For example, Tamada *et al*[99] indicated a CNN-based method in Gd-enhanced MR images in the AP to improve the imaging quality, and the magnitude of the artifacts and blurring induced by respiratory motion were significantly reduced. Additionally, Esses *et al*[100] described an CNN-based method in T2WI liver MRI images for automated image quality evaluation, which yielded a high negative predictive value

**Table 2** Some representative studies of deep learning in hepatocellular carcinoma

Ref.	Application task	Study design	Imaging modality	Algorithm	Sample size	Training set	Test/validation set	Performance
Bousabarah <i>et al</i> [91], 2021	Automatic detection and segmentation of HCC	Retrospective, single-center	CT	DCNN, U-net	174 patients with 231 lesions	165	33 (test); 33 (validation)	Mean DSC between automatically detected lesions using the DCNN + RF + TR and corresponding manual segmentations: 0.64/0.68 (validation/test), and 0.91/0.91 for liver segmentations
Yasaka <i>et al</i> [92], 2018	Differentiation of HCC and other liver tumors	Retrospective, single-center	CT	CNN	560 patients	460	100	Accuracy: 84% in test set
Hamm <i>et al</i> [93], 2019	Diagnosis and classification of HCC	Retrospective, single-center	MRI	CNN	494 patients	434	60	Accuracy: 92%, AUC: 0.992
Yamashita <i>et al</i> [95], 2020	Diagnosis and categorization of HCC with LI-RADS	Retrospective, multi-center	CT, MRI	CNN	314 patients (163 CT, 151 MRI)	220	47 (test); 47 (internal validation); 112 (external validation)	Overall accuracy: 60.4% and AUCs: 0.85, 0.90, 0.63, and 0.82 for LR-1/2, LR-3, LR-4, and LR-5, respectively
Wang <i>et al</i> [96], 2020	Preoperative prediction of MVI in HCC	Retrospective, single-center	MRI	CNN	97 patients with 100 HCCs	60 HCCs	40 HCCs	The combination of deep features from the $b = 0$ , $b = 100$ , $b = 600$ , and ADC images presented the best results (AUC: 0.79)
Peng <i>et al</i> [97], 2020	Prediction of treatment response of TACE	Retrospective, multi-center (3 institutions)	CT	ResNet50	789 patients with HCC	562 (Institution 1)	89 (Institution 2); 138 (Institution 3)	Excellent predictive performance for CR, PR, SD, and PD (accuracy: 84.3%; AUCs: 0.97, 0.96, 0.95, and 0.96 in training set, accuracies: 85.1% and 82.8% in the two validation sets)
Zhang <i>et al</i> [98], 2020	Predicting OS after TACE + Sorafenib	Retrospective, multi-center (3 institutions)	CT	DenseNet (CNN)	201 patients with HCC	120 (Institutions 1 and 2)	81 (Institution 3)	Favorable prediction performance (C-index: 0.717 in training set, C-index: 0.714 in validation set)
Tamada <i>et al</i> [99], 2020	Motion artifact reduction	Retrospective, single-center	MRI	CNN	34 patients with HCC	14	20	Significant reduction of the magnitude of the artifacts and blurring induced by respiratory motion
Esses <i>et al</i> [100], 2018	Automated image quality evaluation	Retrospective, single-center	MRI	CNN	522 patients with HCC	351	171	High negative predictive value (94% and 86% relative to two readers)

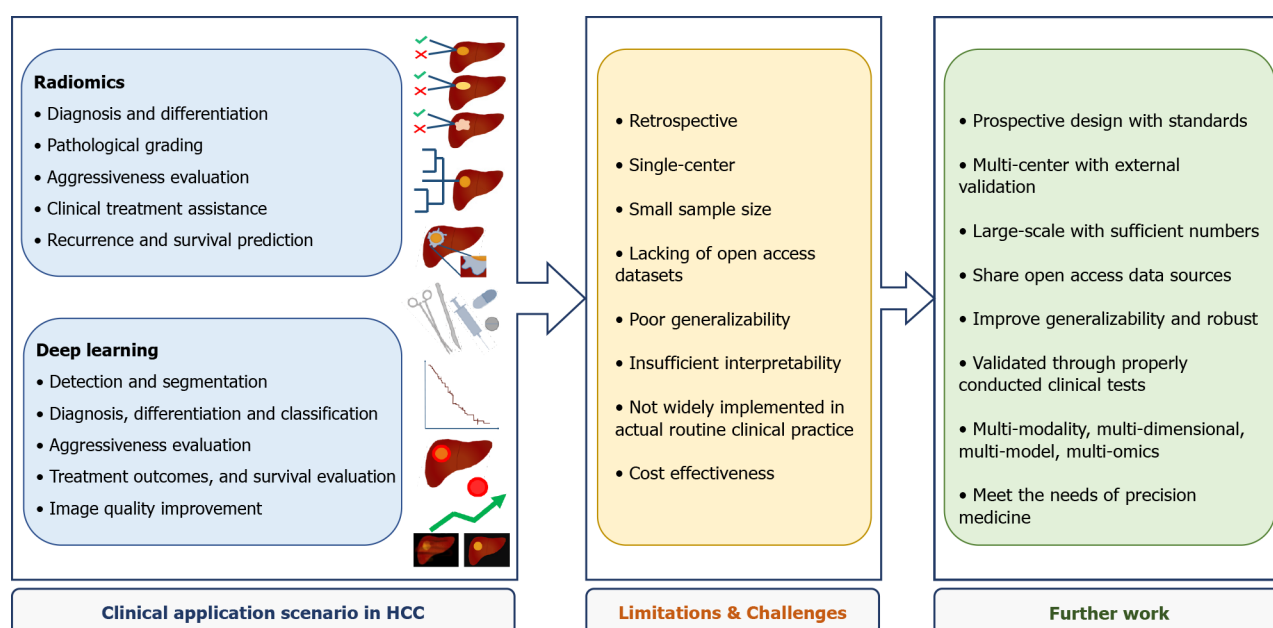
DCNN: Deep convolutional neural network; TR: Thresholding; DSC: Dice similarity coefficient; CNN: Convolutional neural network; LI-RADS: Liver imaging reporting and data system; CR: Complete response; PR: Partial response; SD: Stable disease; PD: Progressive disease.

(94% and 86% relative to two readers) for screening diagnostic and nondiagnostic liver T2WI. The applications of deep learning for medical imaging technologies will be strikingly expanded in further explorations.

## LIMITATIONS, CHALLENGES, AND FUTURE DIRECTIONS

Despite the encouraging achievements and progress of radiomics and deep learning in HCC, the prior studies also highlighted the limitations and challenges that must be addressed (Figure 2). First and most critically, the majority of current studies were retrospective with a small sample size performed in single center, lacking of uniform standards and external validation. The enrolled samples, imaging acquisition protocols, facilities, platforms, segmentation methods, modeling algorithms, and radiomics tools differed in various studies, which accounted for variations and poor generalizability. The studies based on radiomics quality score and Transparent Reporting of a Multivariable Prediction Model for Individual Prognosis or Diagnosis





**Figure 2** Summary of the clinical application scenario, limitations, challenges, and further work of state-of-the-art radiomics and deep learning in hepatocellular carcinoma.

have also emphasized these insufficiencies[101,102]. Getting with the consensus guidelines published by the image biomarker standardization initiative may help to cope with the problem[103]. More importantly, prospective-design, multi-center, large-sample studies are urgently warranted in further investigation on HCC, along with intensive and standardized quality controls throughout the entire workflow.

Deep learning has been putting a brand-new step forward in radiomics, demonstrating superior potential in HCC-oriented tasks while requiring large-scale validation and long-term justification in further studies. Besides, the insufficient interpretability of these AI-medical imaging-combined approaches remains a concern, meaning that it is still quite challenging to adequately explain the underlying associations of radiomics analysis results and tumor heterogeneity and biological behaviors of HCC.

Moreover, few valuable datasets were shared with open access, which got in the way of accumulating sufficient numbers for statistical power. Therefore, it is an expecting choice to share open access database sources across institutions to strengthen the generalization ability and establish well-curated databases and networks, as the Quantitative Imaging Network (QIN) proposing[104]. By the way, the cost-effectiveness of a radiomics or deep learning approach is also supposed to be weighted when applying it to a specific clinical situation of HCC, as it is procedure-complex, time-consuming, labor-intensive, and hardware- and software-demanding.

To date, radiomics and deep learning have been applied in numerous HCC studies, but they have not been widely implemented into routine clinical practice, which requires to be extensively validated and optimized through further appropriate clinical trials. Radiogenomics, an encouraging field considered as a bridge connecting radiomics with genomics[105], is also of promising value in HCC whereas not in the scope of this review. Radiologists ought to get more involved to take full advantage of AI to improve the working efficiency and tackle problems driven by clinical demanding. For the foreseeable future, the multi-modality, multi-dimensional, and multi-model radiomics integrating clinical factors, laboratory information, and other omics has become the next trend of AI-driven medicine for novel evaluation and management of HCC.

## CONCLUSION

To conclude, radiomics has enormous potential to become a powerful tool for HCC management covering detection and classification, diagnosis and differentiation, staging and grading, assessment of aggressive behavior and treatment responses, and prognosis and survival prediction. However, the underlying value of radiomics and

deep learning based radiomics in HCC has not been fully investigated, as well as the applicability and generalizability in routine clinical practice. In the face of great opportunities albeit with challenges, the multi-modality, multi-dimensional, multi-model radiomics and multi-omics studies will become the most appropriate clinical research approaches, so as to meet the developing needs of precision medicine and enhance precision medicine initiatives.

## REFERENCES

- 1 Siegel RL, Miller KD, Jemal A. Cancer statistics, 2019. *CA Cancer J Clin* 2019; **69**: 7-34 [PMID: 30620402 DOI: 10.3322/caac.21551]
- 2 Chen W, Zheng R, Baade PD, Zhang S, Zeng H, Bray F, Jemal A, Yu XQ, He J. Cancer statistics in China, 2015. *CA Cancer J Clin* 2016; **66**: 115-132 [PMID: 26808342 DOI: 10.3322/caac.21338]
- 3 Villanueva A. Hepatocellular Carcinoma. *N Engl J Med* 2019; **380**: 1450-1462 [PMID: 30970190 DOI: 10.1056/NEJMra1713263]
- 4 Yang JD, Heimbach JK. New advances in the diagnosis and management of hepatocellular carcinoma. *BMJ* 2020; **371**: m3544 [PMID: 33106289 DOI: 10.1136/bmj.m3544]
- 5 Roberts LR, Sirlin CB, Zaiem F, Almasri J, Prokop LJ, Heimbach JK, Murad MH, Mohammed K. Imaging for the diagnosis of hepatocellular carcinoma: A systematic review and meta-analysis. *Hepatology* 2018; **67**: 401-421 [PMID: 28859233 DOI: 10.1002/hep.29487]
- 6 Bruix J, Sherman M; American Association for the Study of Liver Diseases. Management of hepatocellular carcinoma: an update. *Hepatology* 2011; **53**: 1020-1022 [PMID: 21374666 DOI: 10.1002/hep.24199]
- 7 Hricak H. Oncologic imaging: a guiding hand of personalized cancer care. *Radiology* 2011; **259**: 633-640 [PMID: 21493796 DOI: 10.1148/radiol.11110252]
- 8 Lu LC, Hsu CH, Hsu C, Cheng AL. Tumor Heterogeneity in Hepatocellular Carcinoma: Facing the Challenges. *Liver Cancer* 2016; **5**: 128-138 [PMID: 27386431 DOI: 10.1159/000367754]
- 9 Calderaro J, Ziol M, Paradis V, Zucman-Rossi J. Molecular and histological correlations in liver cancer. *J Hepatol* 2019; **71**: 616-630 [PMID: 31195064 DOI: 10.1016/j.jhep.2019.06.001]
- 10 Jiménez Pérez M, Grande RG. Application of artificial intelligence in the diagnosis and treatment of hepatocellular carcinoma: A review. *World J Gastroenterol* 2020; **26**: 5617-5628 [PMID: 33088156 DOI: 10.3748/wjg.v26.i37.5617]
- 11 Goyal H, Mann R, Gandhi Z, Perisetti A, Zhang Z, Sharma N, Saligram S, Inamdar S, Tharian B. Application of artificial intelligence in pancreaticobiliary diseases. *Ther Adv Gastrointest Endosc* 2021; **14**: 2631774521993059 [PMID: 33644756 DOI: 10.1177/2631774521993059]
- 12 Goyal H, Mann R, Gandhi Z, Perisetti A, Ali A, Aman Ali K, Sharma N, Saligram S, Tharian B, Inamdar S. Scope of Artificial Intelligence in Screening and Diagnosis of Colorectal Cancer. *J Clin Med* 2020; **9** [PMID: 33076511 DOI: 10.3390/jcm9103313]
- 13 Lambin P, Rios-Velazquez E, Leijenaar R, Carvalho S, van Stiphout RG, Granton P, Zegers CM, Gillies R, Boellard R, Dekker A, Aerts HJ. Radiomics: extracting more information from medical images using advanced feature analysis. *Eur J Cancer* 2012; **48**: 441-446 [PMID: 22257792 DOI: 10.1016/j.ejca.2011.11.036]
- 14 Aerts HJ, Velazquez ER, Leijenaar RT, Parmar C, Grossmann P, Carvalho S, Bussink J, Monshouwer R, Haibe-Kains B, Rietveld D, Hoebers F, Rietbergen MM, Leemans CR, Dekker A, Quackenbush J, Gillies RJ, Lambin P. Decoding tumour phenotype by noninvasive imaging using a quantitative radiomics approach. *Nat Commun* 2014; **5**: 4006 [PMID: 24892406 DOI: 10.1038/ncomms5006]
- 15 Gillies RJ, Kinahan PE, Hricak H. Radiomics: Images Are More than Pictures, They Are Data. *Radiology* 2016; **278**: 563-577 [PMID: 26579733 DOI: 10.1148/radiol.201511169]
- 16 Kumar V, Gu Y, Basu S, Berglund A, Eschrich SA, Schabath MB, Forster K, Aerts HJ, Dekker A, Fenstermacher D, Goldgof DB, Hall LO, Lambin P, Balagurunathan Y, Gatenby RA, Gillies RJ. Radiomics: the process and the challenges. *Magn Reson Imaging* 2012; **30**: 1234-1248 [PMID: 22898692 DOI: 10.1016/j.mri.2012.06.010]
- 17 Shafiq-Ul-Hassan M, Zhang GG, Latifi K, Ullah G, Hunt DC, Balagurunathan Y, Abdalah MA, Schabath MB, Goldgof DG, Mackin D, Court LE, Gillies RJ, Moros EG. Intrinsic dependencies of CT radiomic features on voxel size and number of gray levels. *Med Phys* 2017; **44**: 1050-1062 [PMID: 28112418 DOI: 10.1002/mp.12123]
- 18 Scalco E, Belfatto A, Mastropietro A, Rancati T, Avuzzi B, Messina A, Valdagni R, Rizzo G. T2w-MRI signal normalization affects radiomics features reproducibility. *Med Phys* 2020; **47**: 1680-1691 [PMID: 31971614 DOI: 10.1002/mp.14038]
- 19 Massotier L, Casciaro S. A new fully automatic and robust algorithm for fast segmentation of liver tissue and tumors from CT scans. *Eur Radiol* 2008; **18**: 1658-1665 [PMID: 18369633 DOI: 10.1007/s00330-008-0924-y]
- 20 Smeets D, Loeckx D, Stijnen B, De Dobbelaer B, Vandermeulen D, Suetens P. Semi-automatic level set segmentation of liver tumors combining a spiral-scanning technique with supervised fuzzy pixel classification. *Med Image Anal* 2010; **14**: 13-20 [PMID: 19828356 DOI: 10.1016/j.media.2009.09.002]

- 21 **Häme Y**, Pollari M. Semi-automatic liver tumor segmentation with hidden Markov measure field model and non-parametric distribution estimation. *Med Image Anal* 2012; **16**: 140-149 [PMID: 21742543 DOI: 10.1016/j.media.2011.06.006]
- 22 **Li G**, Chen X, Shi F, Zhu W, Tian J, Xiang D. Automatic Liver Segmentation Based on Shape Constraints and Deformable Graph Cut in CT Images. *IEEE Trans Image Process* 2015; **24**: 5315-5329 [PMID: 26415173 DOI: 10.1109/TIP.2015.2481326]
- 23 **Huang Q**, Ding H, Wang X, Wang G. Fully automatic liver segmentation in CT images using modified graph cuts and feature detection. *Comput Biol Med* 2018; **95**: 198-208 [PMID: 29524804 DOI: 10.1016/j.compbiomed.2018.02.012]
- 24 **Haralick RM**, Shanmugam K, Dinstein IH. Textural Features for Image Classification. *IEEE Transact Sys Man Cybernet* 1973; **SMC-3**: 610-621 [DOI: 10.1109/TSMC.1973.4309314]
- 25 **Galloway MM**. Texture analysis using gray level run lengths. *Comput Graph Image Process* 1975; **4**: 172-179 [DOI: 10.1016/S0146-664X(75)80008-6]
- 26 **Parmar C**, Grossmann P, Bussink J, Lambin P, Aerts HJWL. Machine Learning methods for Quantitative Radiomic Biomarkers. *Sci Rep* 2015; **5**: 13087 [PMID: 26278466 DOI: 10.1038/srep13087]
- 27 **European Association for the Study of the Liver**; European Organisation for Research and Treatment of Cancer. EASL-EORTC clinical practice guidelines: management of hepatocellular carcinoma. *J Hepatol* 2012; **56**: 908-943 [PMID: 22424438 DOI: 10.1016/j.jhep.2011.12.001]
- 28 **European Association for the Study of the Liver**. EASL Clinical Practice Guidelines: Management of hepatocellular carcinoma. *J Hepatol* 2018; **69**: 182-236 [PMID: 29628281 DOI: 10.1016/j.jhep.2018.03.019]
- 29 **Liu X**, Khalvati F, Namdar K, Fischer S, Lewis S, Taouli B, Haider MA, Jhaveri KS. Can machine learning radiomics provide pre-operative differentiation of combined hepatocellular cholangiocarcinoma from hepatocellular carcinoma and cholangiocarcinoma to inform optimal treatment planning? *Eur Radiol* 2021; **31**: 244-255 [PMID: 32749585 DOI: 10.1007/s00330-020-07119-7]
- 30 **Lewis S**, Peti S, Hectors SJ, King M, Rosen A, Kamath A, Putra J, Thung S, Taouli B. Volumetric quantitative histogram analysis using diffusion-weighted magnetic resonance imaging to differentiate HCC from other primary liver cancers. *Abdom Radiol (NY)* 2019; **44**: 912-922 [PMID: 30712136 DOI: 10.1007/s00261-019-01906-7]
- 31 **Nie P**, Wang N, Pang J, Yang G, Duan S, Chen J, Xu W. CT-Based Radiomics Nomogram: A Potential Tool for Differentiating Hepatocellular Adenoma From Hepatocellular Carcinoma in the Noncirrhotic Liver. *Acad Radiol* 2021; **28**: 799-807 [PMID: 32386828 DOI: 10.1016/j.acra.2020.04.027]
- 32 **Nie P**, Yang G, Guo J, Chen J, Li X, Ji Q, Wu J, Cui J, Xu W. A CT-based radiomics nomogram for differentiation of focal nodular hyperplasia from hepatocellular carcinoma in the non-cirrhotic liver. *Cancer Imaging* 2020; **20**: 20 [PMID: 32093786 DOI: 10.1186/s40644-020-00297-z]
- 33 **Wu J**, Liu A, Cui J, Chen A, Song Q, Xie L. Radiomics-based classification of hepatocellular carcinoma and hepatic haemangioma on precontrast magnetic resonance images. *BMC Med Imaging* 2019; **19**: 23 [PMID: 30866850 DOI: 10.1186/s12880-019-0321-9]
- 34 **Sasaki A**, Kai S, Iwashita Y, Hirano S, Ohta M, Kitano S. Microsatellite distribution and indication for locoregional therapy in small hepatocellular carcinoma. *Cancer* 2005; **103**: 299-306 [PMID: 15578688 DOI: 10.1002/cncr.20798]
- 35 **Martins-Filho SN**, Paiva C, Azevedo RS, Alves VAF. Histological Grading of Hepatocellular Carcinoma-A Systematic Review of Literature. *Front Med (Lausanne)* 2017; **4**: 193 [PMID: 29209611 DOI: 10.3389/fmed.2017.00193]
- 36 **Bruix J**, Sherman M; Practice Guidelines Committee, American Association for the Study of Liver Diseases. Management of hepatocellular carcinoma. *Hepatology* 2005; **42**: 1208-1236 [PMID: 16250051 DOI: 10.1002/hep.20933]
- 37 **Wu M**, Tan H, Gao F, Hai J, Ning P, Chen J, Zhu S, Wang M, Dou S, Shi D. Predicting the grade of hepatocellular carcinoma based on non-contrast-enhanced MRI radiomics signature. *Eur Radiol* 2019; **29**: 2802-2811 [PMID: 30406313 DOI: 10.1007/s00330-018-5787-2]
- 38 **Mao B**, Zhang L, Ning P, Ding F, Wu F, Lu G, Geng Y, Ma J. Preoperative prediction for pathological grade of hepatocellular carcinoma via machine learning-based radiomics. *Eur Radiol* 2020; **30**: 6924-6932 [PMID: 32696256 DOI: 10.1007/s00330-020-07056-5]
- 39 **Lim KC**, Chow PK, Allen JC, Chia GS, Lim M, Cheow PC, Chung AY, Ooi LL, Tan SB. Microvascular invasion is a better predictor of tumor recurrence and overall survival following surgical resection for hepatocellular carcinoma compared to the Milan criteria. *Ann Surg* 2011; **254**: 108-113 [PMID: 21527845 DOI: 10.1097/SLA.0b013e31821ad884]
- 40 **Sumie S**, Nakashima O, Okuda K, Kuromatsu R, Kawaguchi A, Nakano M, Satani M, Yamada S, Okamura S, Hori M, Kakuma T, Torimura T, Sata M. The significance of classifying microvascular invasion in patients with hepatocellular carcinoma. *Ann Surg Oncol* 2014; **21**: 1002-1009 [PMID: 24254204 DOI: 10.1245/s10434-013-3376-9]
- 41 **Rodríguez-Perálvarez M**, Luong TV, Andreana L, Meyer T, Dhillon AP, Burroughs AK. A systematic review of microvascular invasion in hepatocellular carcinoma: diagnostic and prognostic variability. *Ann Surg Oncol* 2013; **20**: 325-339 [PMID: 23149850 DOI: 10.1245/s10434-012-2513-1]
- 42 **Bakr S**, Echegaray S, Shah R, Kamaya A, Louie J, Napel S, Kothary N, Gevaert O. Noninvasive

- radiomics signature based on quantitative analysis of computed tomography images as a surrogate for microvascular invasion in hepatocellular carcinoma: a pilot study. *J Med Imaging (Bellingham)* 2017; **4**: 041303 [PMID: 28840174 DOI: 10.1117/1.JMI.4.4.041303]
- 43 **Xu X**, Zhang HL, Liu QP, Sun SW, Zhang J, Zhu FP, Yang G, Yan X, Zhang YD, Liu XS. Radiomic analysis of contrast-enhanced CT predicts microvascular invasion and outcome in hepatocellular carcinoma. *J Hepatol* 2019; **70**: 1133-1144 [PMID: 30876945 DOI: 10.1016/j.jhep.2019.02.023]
  - 44 **Ma X**, Wei J, Gu D, Zhu Y, Feng B, Liang M, Wang S, Zhao X, Tian J. Preoperative radiomics nomogram for microvascular invasion prediction in hepatocellular carcinoma using contrast-enhanced CT. *Eur Radiol* 2019; **29**: 3595-3605 [PMID: 30770969 DOI: 10.1007/s00330-018-5985-y]
  - 45 **Zhang X**, Ruan S, Xiao W, Shao J, Tian W, Liu W, Zhang Z, Wan D, Huang J, Huang Q, Yang Y, Yang H, Ding Y, Liang W, Bai X, Liang T. Contrast-enhanced CT radiomics for preoperative evaluation of microvascular invasion in hepatocellular carcinoma: A two-center study. *Clin Transl Med* 2020; **10**: e111 [PMID: 32567245 DOI: 10.1002/ctm2.111]
  - 46 **Feng ST**, Jia Y, Liao B, Huang B, Zhou Q, Li X, Wei K, Chen L, Li B, Wang W, Chen S, He X, Wang H, Peng S, Chen ZB, Tang M, Chen Z, Hou Y, Peng Z, Kuang M. Preoperative prediction of microvascular invasion in hepatocellular cancer: a radiomics model using Gd-EOB-DTPA-enhanced MRI. *Eur Radiol* 2019; **29**: 4648-4659 [PMID: 30689032 DOI: 10.1007/s00330-018-5935-8]
  - 47 **Chong HH**, Yang L, Sheng RF, Yu YL, Wu DJ, Rao SX, Yang C, Zeng MS. Multi-scale and multi-parametric radiomics of gadoxetate disodium-enhanced MRI predicts microvascular invasion and outcome in patients with solitary hepatocellular carcinoma  $\leq 5$  cm. *Eur Radiol* 2021; **31**: 4824-4838 [PMID: 33447861 DOI: 10.1007/s00330-020-07601-2]
  - 48 **Yang L**, Gu D, Wei J, Yang C, Rao S, Wang W, Chen C, Ding Y, Tian J, Zeng M. A Radiomics Nomogram for Preoperative Prediction of Microvascular Invasion in Hepatocellular Carcinoma. *Liver Cancer* 2019; **8**: 373-386 [PMID: 31768346 DOI: 10.1159/000494099]
  - 49 **Dhir M**, Melin AA, Douaiher J, Lin C, Zhen WK, Hussain SM, Geschwind JF, Doyle MB, Abou-Alfa GK, Are C. A Review and Update of Treatment Options and Controversies in the Management of Hepatocellular Carcinoma. *Ann Surg* 2016; **263**: 1112-1125 [PMID: 26813914 DOI: 10.1097/SLA.0000000000001556]
  - 50 **Pinter M**, Huckle F, Graziadei I, Vogel W, Maieron A, Königsberg R, Stauber R, Grünberger B, Müller C, Kölblinger C, Peck-Radosavljevic M, Sieghart W. Advanced-stage hepatocellular carcinoma: transarterial chemoembolization vs sorafenib. *Radiology* 2012; **263**: 590-599 [PMID: 22438359 DOI: 10.1148/radiol.12111550]
  - 51 **Yang T**, Lin C, Zhai J, Shi S, Zhu M, Zhu N, Lu JH, Yang GS, Wu MC. Surgical resection for advanced hepatocellular carcinoma according to Barcelona Clinic Liver Cancer (BCLC) staging. *J Cancer Res Clin Oncol* 2012; **138**: 1121-1129 [PMID: 22402598 DOI: 10.1007/s00432-012-1188-0]
  - 52 **Yin L**, Li H, Li AJ, Lau WY, Pan ZY, Lai EC, Wu MC, Zhou WP. Partial hepatectomy vs. transcatheter arterial chemoembolization for resectable multiple hepatocellular carcinoma beyond Milan Criteria: a RCT. *J Hepatol* 2014; **61**: 82-88 [PMID: 24650695 DOI: 10.1016/j.jhep.2014.03.012]
  - 53 **Vitale A**, Burra P, Frigo AC, Trevisani F, Farinati F, Spolverato G, Volk M, Giannini EG, Ciccarese F, Piscaglia F, Rapaccini GL, Di Marco M, Caturelli E, Zoli M, Borzio F, Cabibbo G, Felder M, Gasbarrini A, Sacco R, Foschi FG, Missale G, Morisco F, Svegliati Baroni G, Virdone R, Cillo U; Italian Liver Cancer (ITA. LI.CA) group. Survival benefit of liver resection for patients with hepatocellular carcinoma across different Barcelona Clinic Liver Cancer stages: a multicentre study. *J Hepatol* 2015; **62**: 617-624 [PMID: 25450706 DOI: 10.1016/j.jhep.2014.10.037]
  - 54 **Fu S**, Wei J, Zhang J, Dong D, Song J, Li Y, Duan C, Zhang S, Li X, Gu D, Chen X, Hao X, He X, Yan J, Liu Z, Tian J, Lu L. Selection Between Liver Resection Versus Transarterial Chemoembolization in Hepatocellular Carcinoma: A Multicenter Study. *Clin Transl Gastroenterol* 2019; **10**: e00070 [PMID: 31373932 DOI: 10.14309/ctg.0000000000000070]
  - 55 **Cai W**, He B, Hu M, Zhang W, Xiao D, Yu H, Song Q, Xiang N, Yang J, He S, Huang Y, Huang W, Jia F, Fang C. A radiomics-based nomogram for the preoperative prediction of posthepatectomy liver failure in patients with hepatocellular carcinoma. *Surg Oncol* 2019; **28**: 78-85 [PMID: 30851917 DOI: 10.1016/j.suronc.2018.11.013]
  - 56 **Sun Y**, Bai H, Xia W, Wang D, Zhou B, Zhao X, Yang G, Xu L, Zhang W, Liu P, Xu J, Meng S, Liu R, Gao X. Predicting the Outcome of Transcatheter Arterial Embolization Therapy for Unresectable Hepatocellular Carcinoma Based on Radiomics of Preoperative Multiparameter MRI. *J Magn Reson Imaging* 2020; **52**: 1083-1090 [PMID: 32233054 DOI: 10.1002/jmri.27143]
  - 57 **Bruix J**, Reig M, Sherman M. Evidence-Based Diagnosis, Staging, and Treatment of Patients With Hepatocellular Carcinoma. *Gastroenterology* 2016; **150**: 835-853 [PMID: 26795574 DOI: 10.1053/j.gastro.2015.12.041]
  - 58 **Hasegawa K**, Aoki T, Ishizawa T, Kaneko J, Sakamoto Y, Sugawara Y, Kokudo N. Comparison of the therapeutic outcomes between surgical resection and percutaneous ablation for small hepatocellular carcinoma. *Ann Surg Oncol* 2014; **21** Suppl 3: S348-S355 [PMID: 24566865 DOI: 10.1245/s10434-014-3585-x]
  - 59 **Poon RT**, Fan ST, Lo CM, Liu CL, Wong J. Long-term survival and pattern of recurrence after resection of small hepatocellular carcinoma in patients with preserved liver function: implications for a strategy of salvage transplantation. *Ann Surg* 2002; **235**: 373-382 [PMID: 11882759 DOI: 10.1007/s00309-002-0000-0]



- 10.1097/00000658-200203000-00009]
- 60 **Cheng Z**, Yang P, Qu S, Zhou J, Yang J, Yang X, Xia Y, Li J, Wang K, Yan Z, Wu D, Zhang B, Hüser N, Shen F. Risk factors and management for early and late intrahepatic recurrence of solitary hepatocellular carcinoma after curative resection. *HPB (Oxford)* 2015; **17**: 422-427 [PMID: 25421805 DOI: 10.1111/hpb.12367]
  - 61 **Xu XF**, Xing H, Han J, Li ZL, Lau WY, Zhou YH, Gu WM, Wang H, Chen TH, Zeng YY, Li C, Wu MC, Shen F, Yang T. Risk Factors, Patterns, and Outcomes of Late Recurrence After Liver Resection for Hepatocellular Carcinoma: A Multicenter Study From China. *JAMA Surg* 2019; **154**: 209-217 [PMID: 30422241 DOI: 10.1001/jamasurg.2018.4334]
  - 62 **Taketomi A**, Fukuhara T, Morita K, Kayashima H, Ninomiya M, Yamashita Y, Ikegami T, Uchiyama H, Yoshizumi T, Soejima Y, Shirabe K, Maehara Y. Improved results of a surgical resection for the recurrence of hepatocellular carcinoma after living donor liver transplantation. *Ann Surg Oncol* 2010; **17**: 2283-2289 [PMID: 20204531 DOI: 10.1245/s10434-010-0999-y]
  - 63 **Mazzaferro V**, Llovet JM, Miceli R, Bhoori S, Schiavo M, Mariani L, Camerini T, Roayaie S, Schwartz ME, Grazi GL, Adam R, Neuhaus P, Salizzoni M, Bruix J, Forner A, De Carlis L, Cillo U, Burroughs AK, Troisi R, Rossi M, Gerunda GE, Lerut J, Belghiti J, Boin I, Gugenheim J, Rochling F, Van Hoek B, Majno P; Metroticket Investigator Study Group. Predicting survival after liver transplantation in patients with hepatocellular carcinoma beyond the Milan criteria: a retrospective, exploratory analysis. *Lancet Oncol* 2009; **10**: 35-43 [PMID: 19058754 DOI: 10.1016/S1470-2045(08)70284-5]
  - 64 **Pompili M**, Saviano A, de Matthaeis N, Cucchetti A, Ardito F, Federico B, Brunello F, Pinna AD, Giorgio A, Giulini SM, De Sio I, Torzilli G, Fornari F, Capussotti L, Guglielmi A, Piscaglia F, Aldrighetti L, Caturelli E, Calise F, Nuzzo G, Rapaccini GL, Giuliani F. Long-term effectiveness of resection and radiofrequency ablation for single hepatocellular carcinoma  $\leq 3$  cm. Results of a multicenter Italian survey. *J Hepatol* 2013; **59**: 89-97 [PMID: 23523578 DOI: 10.1016/j.jhep.2013.03.009]
  - 65 **Heimbach JK**, Kulik LM, Finn RS, Sirlin CB, Abecassis MM, Roberts LR, Zhu AX, Murad MH, Marrero JA. AASLD guidelines for the treatment of hepatocellular carcinoma. *Hepatology* 2018; **67**: 358-380 [PMID: 28130846 DOI: 10.1002/hep.29086]
  - 66 **Ji GW**, Zhu FP, Xu Q, Wang K, Wu MY, Tang WW, Li XC, Wang XH. Radiomic Features at Contrast-enhanced CT Predict Recurrence in Early Stage Hepatocellular Carcinoma: A Multi-Institutional Study. *Radiology* 2020; **294**: 568-579 [PMID: 31934830 DOI: 10.1148/radiol.2020191470]
  - 67 **Zhao Y**, Wu J, Zhang Q, Hua Z, Qi W, Wang N, Lin T, Sheng L, Cui D, Liu J, Song Q, Li X, Wu T, Guo Y, Cui J, Liu A. Radiomics Analysis Based on Multiparametric MRI for Predicting Early Recurrence in Hepatocellular Carcinoma After Partial Hepatectomy. *J Magn Reson Imaging* 2021; **53**: 1066-1079 [PMID: 33217114 DOI: 10.1002/jmri.27424]
  - 68 **Ji GW**, Zhu FP, Xu Q, Wang K, Wu MY, Tang WW, Li XC, Wang XH. Machine-learning analysis of contrast-enhanced CT radiomics predicts recurrence of hepatocellular carcinoma after resection: A multi-institutional study. *EBioMedicine* 2019; **50**: 156-165 [PMID: 31735556 DOI: 10.1016/j.ebiom.2019.10.057]
  - 69 **Zhang Z**, Jiang H, Chen J, Wei Y, Cao L, Ye Z, Li X, Ma L, Song B. Hepatocellular carcinoma: radiomics nomogram on gadoteric acid-enhanced MR imaging for early postoperative recurrence prediction. *Cancer Imaging* 2019; **19**: 22 [PMID: 31088553 DOI: 10.1186/s40644-019-0209-5]
  - 70 **Zhou Y**, He L, Huang Y, Chen S, Wu P, Ye W, Liu Z, Liang C. CT-based radiomics signature: a potential biomarker for preoperative prediction of early recurrence in hepatocellular carcinoma. *Abdom Radiol (NY)* 2017; **42**: 1695-1704 [PMID: 28180924 DOI: 10.1007/s00261-017-1072-0]
  - 71 **Shan QY**, Hu HT, Feng ST, Peng ZP, Chen SL, Zhou Q, Li X, Xie XY, Lu MD, Wang W, Kuang M. CT-based peritumoral radiomics signatures to predict early recurrence in hepatocellular carcinoma after curative tumor resection or ablation. *Cancer Imaging* 2019; **19**: 11 [PMID: 30813956 DOI: 10.1186/s40644-019-0197-5]
  - 72 **Kim S**, Shin J, Kim DY, Choi GH, Kim MJ, Choi JY. Radiomics on Gadoteric Acid-Enhanced Magnetic Resonance Imaging for Prediction of Postoperative Early and Late Recurrence of Single Hepatocellular Carcinoma. *Clin Cancer Res* 2019; **25**: 3847-3855 [PMID: 30808773 DOI: 10.1158/1078-0432.CCR-18-2861]
  - 73 **Guo D**, Gu D, Wang H, Wei J, Wang Z, Hao X, Ji Q, Cao S, Song Z, Jiang J, Shen Z, Tian J, Zheng H. Radiomics analysis enables recurrence prediction for hepatocellular carcinoma after liver transplantation. *Eur J Radiol* 2019; **117**: 33-40 [PMID: 31307650 DOI: 10.1016/j.ejrad.2019.05.010]
  - 74 **Yuan C**, Wang Z, Gu D, Tian J, Zhao P, Wei J, Yang X, Hao X, Dong D, He N, Sun Y, Gao W, Feng J. Prediction early recurrence of hepatocellular carcinoma eligible for curative ablation using a Radiomics nomogram. *Cancer Imaging* 2019; **19**: 21 [PMID: 31027510 DOI: 10.1186/s40644-019-0207-7]
  - 75 **Wang XH**, Long LH, Cui Y, Jia AY, Zhu XG, Wang HZ, Wang Z, Zhan CM, Wang ZH, Wang WH. MRI-based radiomics model for preoperative prediction of 5-year survival in patients with hepatocellular carcinoma. *Br J Cancer* 2020; **122**: 978-985 [PMID: 31937925 DOI: 10.1038/s41416-019-0706-0]
  - 76 **Song W**, Yu X, Guo D, Liu H, Tang Z, Liu X, Zhou J, Zhang H, Liu Y. MRI-Based Radiomics: Associations With the Recurrence-Free Survival of Patients With Hepatocellular Carcinoma Treated With Conventional Transcatheter Arterial Chemoembolization. *J Magn Reson Imaging* 2020; **52**:

- 461-473 [PMID: 31675174 DOI: 10.1002/jmri.26977]
- 77 **Kim J**, Choi SJ, Lee SH, Lee HY, Park H. Predicting Survival Using Pretreatment CT for Patients With Hepatocellular Carcinoma Treated With Transarterial Chemoembolization: Comparison of Models Using Radiomics. *AJR Am J Roentgenol* 2018; **211**: 1026-1034 [PMID: 30240304 DOI: 10.2214/AJR.18.19507]
  - 78 **Liu Q**, Li J, Liu F, Yang W, Ding J, Chen W, Wei Y, Li B, Zheng L. A radiomics nomogram for the prediction of overall survival in patients with hepatocellular carcinoma after hepatectomy. *Cancer Imaging* 2020; **20**: 82 [PMID: 33198809 DOI: 10.1186/s40644-020-00360-9]
  - 79 **Chartrand G**, Cheng PM, Vorontsov E, Drozdal M, Turcotte S, Pal CJ, Kadoury S, Tang A. Deep Learning: A Primer for Radiologists. *Radiographics* 2017; **37**: 2113-2131 [PMID: 29131760 DOI: 10.1148/rg.2017170077]
  - 80 **Litjens G**, Kooi T, Bejnordi BE, Setio AAA, Ciompi F, Ghafoorian M, van der Laak JAWM, van Ginneken B, Sánchez CI. A survey on deep learning in medical image analysis. *Med Image Anal* 2017; **42**: 60-88 [PMID: 28778026 DOI: 10.1016/j.media.2017.07.005]
  - 81 **Shen D**, Wu G, Suk HI. Deep Learning in Medical Image Analysis. *Annu Rev Biomed Eng* 2017; **19**: 221-248 [PMID: 28301734 DOI: 10.1146/annurev-bioeng-071516-044442]
  - 82 **Lee JG**, Jun S, Cho YW, Lee H, Kim GB, Seo JB, Kim N. Deep Learning in Medical Imaging: General Overview. *Korean J Radiol* 2017; **18**: 570-584 [PMID: 28670152 DOI: 10.3348/kjr.2017.18.4.570]
  - 83 **Bernhard S**, John P, Thomas H. Greedy Layer-Wise Training of Deep Networks. Advances in Neural Information Processing Systems 19: Proceedings of the 2006 Conference: MIT Press, 2007: 153-160
  - 84 **Vincent P**, Larochelle H, Lajoie I, Bengio Y, Manzagol P-A. Stacked Denoising Autoencoders: Learning Useful Representations in a Deep Network with a Local Denoising Criterion. *J Mach Learn Res* 2010; **11**: 3371-3408
  - 85 **Hinton GE**. A Practical Guide to Training Restricted Boltzmann Machines. In: Montavon G, Orr GB, Müller K-R, editors. Neural Networks: Tricks of the Trade: Second Edition. Berlin, Heidelberg: Springer, 2012: 599-619 [DOI: 10.1007/978-3-642-35289-8\_32]
  - 86 **Weston AD**, Korfiatis P, Kline TL, Philbrick KA, Kostandy P, Sakinis T, Sugimoto M, Takahashi N, Erickson BJ. Automated Abdominal Segmentation of CT Scans for Body Composition Analysis Using Deep Learning. *Radiology* 2019; **290**: 669-679 [PMID: 30526356 DOI: 10.1148/radiol.2018181432]
  - 87 **Guo X**, Schwartz LH, Zhao B. Automatic liver segmentation by integrating fully convolutional networks into active contour models. *Med Phys* 2019; **46**: 4455-4469 [PMID: 31356688 DOI: 10.1002/mp.13735]
  - 88 **Gibson E**, Giganti F, Hu Y, Bonmati E, Bandula S, Gurusamy K, Davidson B, Pereira SP, Clarkson MJ, Barratt DC. Automatic Multi-Organ Segmentation on Abdominal CT With Dense V-Networks. *IEEE Trans Med Imaging* 2018; **37**: 1822-1834 [PMID: 29994628 DOI: 10.1109/TMI.2018.2806309]
  - 89 **Li X**, Chen H, Qi X, Dou Q, Fu CW, Heng PA. H-DenseUNet: Hybrid Densely Connected UNet for Liver and Tumor Segmentation From CT Volumes. *IEEE Trans Med Imaging* 2018; **37**: 2663-2674 [PMID: 29994201 DOI: 10.1109/TMI.2018.2845918]
  - 90 **Ouhmich F**, Agnus V, Noblet V, Heitz F, Pessaux P. Liver tissue segmentation in multiphase CT scans using cascaded convolutional neural networks. *Int J Comput Assist Radiol Surg* 2019; **14**: 1275-1284 [PMID: 31041697 DOI: 10.1007/s11548-019-01989-z]
  - 91 **Bousabarah K**, Letzen B, Tefera J, Savic L, Schobert I, Schlachter T, Staib LH, Kocher M, Chapiro J, Lin M. Automated detection and delineation of hepatocellular carcinoma on multiphase contrast-enhanced MRI using deep learning. *Abdom Radiol (NY)* 2021; **46**: 216-225 [PMID: 32500237 DOI: 10.1007/s00261-020-02604-5]
  - 92 **Yasaka K**, Akai H, Abe O, Kiryu S. Deep Learning with Convolutional Neural Network for Differentiation of Liver Masses at Dynamic Contrast-enhanced CT: A Preliminary Study. *Radiology* 2018; **286**: 887-896 [PMID: 29059036 DOI: 10.1148/radiol.2017170706]
  - 93 **Hamm CA**, Wang CJ, Savic LJ, Ferrante M, Schobert I, Schlachter T, Lin M, Duncan JS, Weinreb JC, Chapiro J, Letzen B. Deep learning for liver tumor diagnosis part I: development of a convolutional neural network classifier for multi-phasic MRI. *Eur Radiol* 2019; **29**: 3338-3347 [PMID: 31016442 DOI: 10.1007/s00330-019-06205-9]
  - 94 **Wang CJ**, Hamm CA, Savic LJ, Ferrante M, Schobert I, Schlachter T, Lin M, Weinreb JC, Duncan JS, Chapiro J, Letzen B. Deep learning for liver tumor diagnosis part II: convolutional neural network interpretation using radiologic imaging features. *Eur Radiol* 2019; **29**: 3348-3357 [PMID: 31093705 DOI: 10.1007/s00330-019-06214-8]
  - 95 **Yamashita R**, Mittendorf A, Zhu Z, Fowler KJ, Santillan CS, Sirlin CB, Bashir MR, Do RKG. Deep convolutional neural network applied to the liver imaging reporting and data system (LI-RADS) version 2014 category classification: a pilot study. *Abdom Radiol (NY)* 2020; **45**: 24-35 [PMID: 31696269 DOI: 10.1007/s00261-019-02306-7]
  - 96 **Wang G**, Jian W, Cen X, Zhang L, Guo H, Liu Z, Liang C, Zhou W. Prediction of Microvascular Invasion of Hepatocellular Carcinoma Based on Preoperative Diffusion-Weighted MR Using Deep Learning. *Acad Radiol* 2020 [PMID: 33303346 DOI: 10.1016/j.acra.2020.11.014]
  - 97 **Peng J**, Kang S, Ning Z, Deng H, Shen J, Xu Y, Zhang J, Zhao W, Li X, Gong W, Huang J, Liu L. Residual convolutional neural network for predicting response of transarterial chemoembolization in

- hepatocellular carcinoma from CT imaging. *Eur Radiol* 2020; **30**: 413-424 [PMID: [31332558](#) DOI: [10.1007/s00330-019-06318-1](#)]
- 98 **Zhang L**, Xia W, Yan ZP, Sun JH, Zhong BY, Hou ZH, Yang MJ, Zhou GH, Wang WS, Zhao XY, Jian JM, Huang P, Zhang R, Zhang S, Zhang JY, Li Z, Zhu XL, Gao X, Ni CF. Deep Learning Predicts Overall Survival of Patients With Unresectable Hepatocellular Carcinoma Treated by Transarterial Chemoembolization Plus Sorafenib. *Front Oncol* 2020; **10**: 593292 [PMID: [33102242](#) DOI: [10.3389/fonc.2020.593292](#)]
  - 99 **Tamada D**, Kromrey ML, Ichikawa S, Onishi H, Motosugi U. Motion Artifact Reduction Using a Convolutional Neural Network for Dynamic Contrast Enhanced MR Imaging of the Liver. *Magn Reson Med Sci* 2020; **19**: 64-76 [PMID: [31061259](#) DOI: [10.2463/mrms.mp.2018-0156](#)]
  - 100 **Esses SJ**, Lu X, Zhao T, Shanbhogue K, Dane B, Bruno M, Chandarana H. Automated image quality evaluation of T<sub>2</sub>-weighted liver MRI utilizing deep learning architecture. *J Magn Reson Imaging* 2018; **47**: 723-728 [PMID: [28577329](#) DOI: [10.1002/jmri.25779](#)]
  - 101 **Park JE**, Kim D, Kim HS, Park SY, Kim JY, Cho SJ, Shin JH, Kim JH. Quality of science and reporting of radiomics in oncologic studies: room for improvement according to radiomics quality score and TRIPOD statement. *Eur Radiol* 2020; **30**: 523-536 [PMID: [31350588](#) DOI: [10.1007/s00330-019-06360-z](#)]
  - 102 **Wakabayashi T**, Ouhmich F, Gonzalez-Cabrera C, Felli E, Saviano A, Agnus V, Savadjiev P, Baumert TF, Pessaux P, Marescaux J, Gallix B. Radiomics in hepatocellular carcinoma: a quantitative review. *Hepatol Int* 2019; **13**: 546-559 [PMID: [31473947](#) DOI: [10.1007/s12072-019-09973-0](#)]
  - 103 **Zwanenburg A**, Vallières M, Abdalah MA, Aerts HJWL, Andrearczyk V, Apte A, Ashrafinia S, Bakas S, Beukinga RJ, Boellaard R, Bogowicz M, Boldrini L, Buvat I, Cook GJR, Davatzikos C, Depeursinge A, Desseroit MC, Dinapoli N, Dinh CV, Echegaray S, El Naqa I, Fedorov AY, Gatta R, Gillies RJ, Goh V, Götz M, Guckenberger M, Ha SM, Hatt M, Isensee F, Lambin P, Leger S, Leijenaar RTH, Lenkowicz J, Lippert F, Losnegård A, Maier-Hein KH, Morin O, Müller H, Napel S, Nioche C, Orlhac F, Pati S, Pfaehler EAG, Rahmim A, Rao AUK, Scherer J, Siddique MM, Sijtsma NM, Socarras Fernandez J, Spezi E, Steenbakkers RJHM, Tanadini-Lang S, Thorwarth D, Troost EGC, Upadhyaya T, Valentini V, van Dijk LV, van Griethuysen J, van Velden FHP, Whybra P, Richter C, Lööck S. The Image Biomarker Standardization Initiative: Standardized Quantitative Radiomics for High-Throughput Image-based Phenotyping. *Radiology* 2020; **295**: 328-338 [PMID: [32154773](#) DOI: [10.1148/radiol.2020191145](#)]
  - 104 **Clarke LP**, Nordstrom RJ, Zhang H, Tandon P, Zhang Y, Redmond G, Farahani K, Kelloff G, Henderson L, Shankar L, Deye J, Capala J, Jacobs P. The Quantitative Imaging Network: NCI's Historical Perspective and Planned Goals. *Transl Oncol* 2014; **7**: 1-4 [PMID: [24772201](#) DOI: [10.1593/tlo.13832](#)]
  - 105 **Bodalal Z**, Trebeschi S, Nguyen-Kim TDL, Schats W, Beets-Tan R. Radiogenomics: bridging imaging and genomics. *Abdom Radiol (NY)* 2019; **44**: 1960-1984 [PMID: [31049614](#) DOI: [10.1007/s00261-019-02028-w](#)]





Published by **Baishideng Publishing Group Inc**  
7041 Koll Center Parkway, Suite 160, Pleasanton, CA 94566, USA

**Telephone:** +1-925-3991568

**E-mail:** [bpgoffice@wjgnet.com](mailto:bpgoffice@wjgnet.com)

**Help Desk:** <https://www.f6publishing.com/helpdesk>

<https://www.wjgnet.com>

