

World Journal of *Gastrointestinal Oncology*

World J Gastrointest Oncol 2022 January 15; 14(1): 1-368



REVIEW

- 1 Molecular regulatory mechanism of ferroptosis and its role in gastrointestinal oncology: Progress and updates
Yang F, Sun SY, Wang S, Guo JT, Liu X, Ge N, Wang GX
- 19 Biomarkers for response to immune checkpoint inhibitors in gastrointestinal cancers
Li M, Kaili D, Shi L
- 38 Proteasome regulators in pancreatic cancer
Murugan NJ, Voutsadakis IA
- 55 Effects of *Helicobacter pylori* infection in gastrointestinal tract malignant diseases: From the oral cavity to rectum
Kuo YC, Yu LY, Wang HY, Chen MJ, Wu MS, Liu CJ, Lin YC, Shih SC, Hu KC
- 75 Bromodomain and extra-terminal inhibitors emerge as potential therapeutic avenues for gastrointestinal cancers
Sun HY, Du ST, Li YY, Deng GT, Zeng FR
- 90 Gastric cancer: An epigenetic view
Tang SY, Zhou PJ, Meng Y, Zeng FR, Deng GT
- 110 Statin as a therapeutic agent in gastroenterological cancer
Uemura N, Hayashi H, Baba H
- 124 Development of artificial intelligence technology in diagnosis, treatment, and prognosis of colorectal cancer
Liang F, Wang S, Zhang K, Liu TJ, Li JN

MINIREVIEWS

- 153 Impact of the microenvironment on the pathogenesis of mucosa-associated lymphoid tissue lymphomas
Uhl B, Prochazka KT, Fechter K, Pansy K, Greinix HT, Neumeister P, Deutsch AJ
- 163 Immunotherapy in liver transplantation for hepatocellular carcinoma: Pros and cons
Luo Y, Teng F, Fu H, Ding GS
- 181 Trimodality treatment in gastric and gastroesophageal junction cancers: Current approach and future perspectives
Charalampakis N, Tsakatikas S, Schizas D, Kykalos S, Tolia M, Fioretzaki R, Papageorgiou G, Katsaros I, Abdelhakeem AAF, Sewastjanow-Silva M, Rogers JE, Ajani JA
- 203 Radiofrequency ablation in the management of primary hepatic and biliary tumors
Hendriquez R, Keihanian T, Goyal J, Abraham RR, Mishra R, Girotra M

- 216 Immune evasion mechanisms and therapeutic strategies in gastric cancer

Ma ES, Wang ZX, Zhu MQ, Zhao J

- 230 Early-onset colorectal cancer: Current insights and future directions

Wu CWK, Lui RN

ORIGINAL ARTICLE

Basic Study

- 242 Hydrogen-rich water exerts anti-tumor effects comparable to 5-fluorouracil in a colorectal cancer xenograft model

Asgharzadeh F, Tarnava A, Mostafapour A, Khazaei M, LeBaron TW

- 253 Lnc524369 promotes hepatocellular carcinoma progression and predicts poor survival by activating YWHAZ-RAF1 signaling

Zheng W, Shen GL, Xu KY, Yin QQ, Hui TC, Zhou ZW, Xu CA, Wang SH, Wu WH, Shi LF, Pan HY

Retrospective Study

- 265 Characterization of E-cadherin expression in normal mucosa, dysplasia and adenocarcinoma of gastric cardia and its influence on prognosis

Wang HL, Zhao XK, Zhou FY, Song X, Li LY, Huang GR, Bao QD, Lei LL, Yang HJ, Li L, Xu RH, Li AL, Wang XZ, Han WL, Ren JL, Wang LD

Observational Study

- 278 Digestive cancer incidence and mortality among young adults worldwide in 2020: A population-based study

Li J

Prospective Study

- 295 Intertwined leukocyte balances in tumours and peripheral blood as robust predictors of right and left colorectal cancer survival

Cantero-Cid R, Montalbán-Hernández KM, Guevara J, Pascual-Iglesias A, Pulido E, Casavilla JC, Marcano C, Serrano CB, Valentín J, Bonel-Pérez GC, Avendaño-Ortiz J, Terrón V, Lozano-Rodríguez R, Martín-Quirós A, Marín E, Pena E, Guerra-Pastrián L, López-Collazo E, Aguirre LA

Randomized Controlled Trial

- 319 Effects of cognitive behavior therapy combined with Baduanjin in patients with colorectal cancer

Lin ZG, Li RD, Ai FL, Li S, Zhang XA

SYSTEMATIC REVIEWS

- 334 Exosomes as potential diagnosis and treatment for liver cancer

Wei XC, Liu LJ, Zhu F

META-ANALYSIS

- 348** Increased risk of colorectal neoplasia in inflammatory bowel disease patients with post-inflammatory polyps: A systematic review and meta-analysis

He DG, Chen XJ, Huang JN, Chen JG, Lv MY, Huang TZ, Lan P, He XS

LETTER TO THE EDITOR

- 362** Liquid biopsy: Precise diagnosis and therapy for cholangiocarcinoma

Wang SQ, Chai CX, Wang BR, Zhu F, Shang D, Li M

- 366** Comment on “Outcomes of curative liver resection for hepatocellular carcinoma in patients with cirrhosis”

Tang XL, Miao YD, Mi DH

ABOUT COVER

Editorial Board Member of *World Journal of Gastrointestinal Oncology*, Esther Una Cidon, MD, MSc, PhD, Doctor, Department of Medical Oncology, Royal Bournemouth and Christchurch Hospitals NHS Foundation Trust, Bournemouth BH7 7DW, United Kingdom. aunacid@hotmail.com

AIMS AND SCOPE

The primary aim of *World Journal of Gastrointestinal Oncology* (WJGO, *World J Gastrointest Oncol*) is to provide scholars and readers from various fields of gastrointestinal oncology with a platform to publish high-quality basic and clinical research articles and communicate their research findings online.

WJGO mainly publishes articles reporting research results and findings obtained in the field of gastrointestinal oncology and covering a wide range of topics including liver cell adenoma, gastric neoplasms, appendiceal neoplasms, biliary tract neoplasms, hepatocellular carcinoma, pancreatic carcinoma, cecal neoplasms, colonic neoplasms, colorectal neoplasms, duodenal neoplasms, esophageal neoplasms, gallbladder neoplasms, *etc.*

INDEXING/ABSTRACTING

The WJGO is now indexed in Science Citation Index Expanded (also known as SciSearch®), PubMed, PubMed Central, and Scopus. The 2021 edition of Journal Citation Reports® cites the 2020 impact factor (IF) for WJGO as 3.393; IF without journal self cites: 3.333; 5-year IF: 3.519; Journal Citation Indicator: 0.5; Ranking: 163 among 242 journals in oncology; Quartile category: Q3; Ranking: 60 among 92 journals in gastroenterology and hepatology; and Quartile category: Q3. The WJGO's CiteScore for 2020 is 3.3 and Scopus CiteScore rank 2020: Gastroenterology is 70/136.

RESPONSIBLE EDITORS FOR THIS ISSUE

Production Editor: *Ying-Yi Yuan*; Production Department Director: *Xiang Li*; Editorial Office Director: *Ya-Juan Ma*.

NAME OF JOURNAL

World Journal of Gastrointestinal Oncology

ISSN

ISSN 1948-5204 (online)

LAUNCH DATE

February 15, 2009

FREQUENCY

Monthly

EDITORS-IN-CHIEF

Monjur Ahmed, Florin Burada

EDITORIAL BOARD MEMBERS

<https://www.wjgnet.com/1948-5204/editorialboard.htm>

PUBLICATION DATE

January 15, 2022

COPYRIGHT

© 2022 Baishideng Publishing Group Inc

INSTRUCTIONS TO AUTHORS

<https://www.wjgnet.com/bpg/gerinfo/204>

GUIDELINES FOR ETHICS DOCUMENTS

<https://www.wjgnet.com/bpg/GerInfo/287>

GUIDELINES FOR NON-NATIVE SPEAKERS OF ENGLISH

<https://www.wjgnet.com/bpg/gerinfo/240>

PUBLICATION ETHICS

<https://www.wjgnet.com/bpg/GerInfo/288>

PUBLICATION MISCONDUCT

<https://www.wjgnet.com/bpg/gerinfo/208>

ARTICLE PROCESSING CHARGE

<https://www.wjgnet.com/bpg/gerinfo/242>

STEPS FOR SUBMITTING MANUSCRIPTS

<https://www.wjgnet.com/bpg/GerInfo/239>

ONLINE SUBMISSION

<https://www.f6publishing.com>



Radiofrequency ablation in the management of primary hepatic and biliary tumors

Richard Hendriquez, Tara Keihanian, Jatinder Goyal, Rtika R Abraham, Rajnish Mishra, Mohit Girotra

ORCID number: Richard Hendriquez 0000-0001-6958-9931; Tara Keihanian 0000-0002-1753-985X; Jatinder Goyal 0000-0002-8699-6149; Rtika R Abraham 0000-0002-4608-7899; Rajnish Mishra 0000-0003-1295-1260; Mohit Girotra 0000-0002-7086-7211.

Author contributions: Henriquez R, Keihanian T and Goyal G performed data review, prepared and edited the manuscript; Abraham RR and Mishra R performed edited manuscript; Girotra M conceptualized and prepared, edited the manuscript and provided final approval; all authors wrote, read and approved the final manuscript.

Conflict-of-interest statement: The authors have no disclosures or conflicts of interest.

Country/Territory of origin: United States

Specialty type: Gastroenterology and hepatology

Provenance and peer review: Invited article; Externally peer reviewed.

Peer-review model: Single blind

Peer-review report's scientific quality classification
Grade A (Excellent): 0
Grade B (Very good): 0

Richard Hendriquez, Department of Internal Medicine, University of Central Florida, Orlando, FL 32816, United States

Tara Keihanian, Department of Gastroenterology and Hepatology, University of Miami, Miami, FL 33136, United States

Jatinder Goyal, Department of Gastroenterology and Hepatology, Wellspan Digestive Health - York Hospital, York, PA 17403, United States

Rtika R Abraham, Department of Endocrinology, Swedish Medical Center, Seattle, WA 98104, United States

Rajnish Mishra, Mohit Girotra, Digestive Health Institute, Section of Gastroenterology and Interventional Endoscopy, Swedish Medical Center, Seattle, WA 98104, United States

Corresponding author: Mohit Girotra, FACG, FACP, MD, Digestive Health Institute, Section of Gastroenterology and Interventional Endoscopy, Swedish Medical Center, 1221 Madison Street, Ste 1220, Seattle, WA 98104, United States. girotra.mohit@gmail.com

Abstract

In the United States, 80%-90% of primary hepatic tumors are hepatocellular carcinomas and 10%-15% are cholangiocarcinomas (CCA), both with high mortality rate, particularly CCA, which portends a worse prognosis. Traditional management with surgery has good outcomes in appropriately selected patients; however, novel ablative treatment options have emerged, such as radiofrequency ablation (RFA), which can improve the prognosis of both hepatic and biliary tumors. RFA is aimed to generate an area of necrosis within the targeted tissue by applying thermal therapy *via* an electrode, with a goal to completely eradicate the tumor while preserving surrounding healthy tissue. Role of RFA in management of hepatic and biliary tumors forms the focus of our current mini-review article.

Key Words: Radiofrequency ablation; Radiofrequency ablation; Hepatic tumor; Biliary tumor; Cholangiocarcinoma; Hepatocellular carcinoma; Cholangiocarcinomas; Hepatocellular carcinomas

©The Author(s) 2022. Published by Baishideng Publishing Group Inc. All rights reserved.

Grade C (Good): C, C
 Grade D (Fair): 0
 Grade E (Poor): 0

Open-Access: This article is an open-access article that was selected by an in-house editor and fully peer-reviewed by external reviewers. It is distributed in accordance with the Creative Commons Attribution NonCommercial (CC BY-NC 4.0) license, which permits others to distribute, remix, adapt, build upon this work non-commercially, and license their derivative works on different terms, provided the original work is properly cited and the use is non-commercial. See: <http://creativecommons.org/licenses/by-nc/4.0/>

Received: March 28, 2021

Peer-review started: March 28, 2021

First decision: June 7, 2021

Revised: June 15, 2021

Accepted: December 7, 2021

Article in press: December 7, 2021

Published online: January 15, 2022

P-Reviewer: Lang SA

S-Editor: Wang LL

L-Editor: A

P-Editor: Wang LL



Core Tip: Radiofrequency ablation (RFA) generates an area of necrosis within the targeted tissue by applying thermal therapy *via* an electrode, with a goal to completely eradicate the tumor while preserving surrounding healthy tissue. RFA can maintain biliary drainage by tumor ablation within the biliary ducts or occluded metallic stents, which improves survival and quality of life in unresectable cholangiocarcinomas patients. In hepatocellular carcinoma, RFA is used alone or in combination (with hepatectomy/transcatheter arterial chemoembolization) for ablation of tumors < 2 cm, and improves local tumor progression and recurrence-free survival, and considered by some to be comparative to hepatectomy.

Citation: Hendriquez R, Keihanian T, Goyal J, Abraham RR, Mishra R, Girotra M. Radiofrequency ablation in the management of primary hepatic and biliary tumors. *World J Gastrointest Oncol* 2022; 14(1): 203-215

URL: <https://www.wjgnet.com/1948-5204/full/v14/i1/203.htm>

DOI: <https://dx.doi.org/10.4251/wjgo.v14.i1.203>

INTRODUCTION

Most primary hepatic tumors are found to be either Hepatocellular Carcinoma (HCC) or Cholangiocarcinoma (CCA). Specifically, within the United States, 80%-90% of these tumors are found to be HCCs, and the remaining 10%-15% being CCAs[1-9]. These hepatic tumors have a high mortality rate, particularly CCA, which portends a worse prognosis[7,10-14]. Traditionally, surgical resection has been shown to have good outcomes in appropriately selected patients. However, with the advent of novel ablative treatment options such as radiofrequency ablation (RFA), the prognosis of both hepatic and biliary tumors can be improved[12,15,16].

Radiofrequency ablation (RFA) is aimed to generate an area of necrosis within the targeted tissue by applying thermal therapy *via* an electrode[17-20], with a goal to eradicate the tumor while preserving surrounding healthy tissue[12,21,22]. Thermal ablation has been used for management of a wide range of lesions, from renal tumors to uterine fibroids. However, more data is emerging in its role as a curative or palliative option in those with primary and secondary hepatobiliary malignancies[11, 18-20]. In this mini-review article, we discuss the role of RFA in patients with primary-hepatic and biliary tumors.

RFA TECHNIQUE AND PROCEDURE

RFA utilizes electrodes to provide an alternating current, causing the ions to reverberate rapidly, thereby increasing tissue temperature[8,16,23-26]. This thermal energy induces coagulative necrosis and subsequent death of the malignant cells. RFA can be accomplished through multiple approaches, including surgical, percutaneous, and more recently, endoscopic modality[19,27,28]. Several studies have explored the safety, efficacy and feasibility of RFA for loco-regional control of tumor growth. To facilitate this, a specialized catheter named Endo Luminal Radiofrequency Ablation (ELRA) was developed (STARmed, Goyang, Korea), which is a 7-Fr bipolar catheter with a 1750 mm length, with an automatic temperature probe, allowing the user to avoid excessive heating and collateral damage to surrounding healthy tissue, thus decreasing the rates of procedure-related adverse events[29-32]. Four different exposure lengths are available (11, 18, 22 and 33 mm) to allow RFA of strictures of varying lengths, with recommended power setting of 7-10 W and target temperature of 80 °C for up to 2 min. A similar Habib EndoHPB catheter (Boston Scientific, Marlborough, MA, United States) is an 1800 mm long 8-Fr device with two distal tip electrodes placed 8 mm apart, to achieve biliary RFA. Novel devices have been developed to achieve the same *via* endoscopic ultrasound (EUS) approach. For example, the Habib endoscopic ultrasound (EUS) RFA device is a 1-Fr wire monopolar electrode inserted inside a standard EUS fine-needle aspiration (FNA) needle that can achieve coagulation of specific target tissue[12,21,33,34]. During endoscopic retrograde cholangiography (ERCP), after biliary cannulation a guidewire is passed through the

strictured segment of bile duct, over which the RFA catheter is advanced and electrodes are positioned under fluoroscopic guidance to achieve ablation over bursts of 60 s. For longer strictures, stepwise ablation is performed to cover the entire length, or alternately catheter with varying exposure length can be utilized, if available. This modality can also be used to treat tumor/tissue ingrowth within metallic stents placed for cholangiocarcinoma (Figure 1). For strictures involving the hilum, ablation of both right and left hepatic ducts is performed after placement of two bilateral guidewires. After improvement of stricture, upstream debris removal is performed, followed by cholangiogram to assess for complications including bile leak, prior to stent placement.

RFA IN CCC

CCA represents approximately 2%-3% of malignancies arising from the gastrointestinal (GI) system, but is second most common primary liver tumor[7,34,35]. Specifically, these malignancies arise from the cells that line the biliary tree, and categorized as extra-hepatic or intra-hepatic, depending on their extent of ductal infiltration and location in relation to the cystic duct insertion; as most famously reported using the Bismuth-Corlette system[13,34]. Supplementary classifications of CCAs have been proposed, which in addition to tumor extent within the biliary system also take into account the size of the tumor, vascular (hepatic artery/portal vein) and lymph node involvement, distant metastases, and estimated post-resection hepatic volume [36], which have advantage over Bismuth-Corlette system which does not provide information on vascular encasement or metastatic disease, includes only peri-hilar CCA but not intrahepatic CCA, and does not necessarily determine local resectability, and hence of limited prognostic value. In fact, there is emerging evidence that although resection of type IV CCA is technically demanding with high morbidity, it can be performed with low mortality and offers better survival probability in selected patients[37].

When it comes to the treatment of CCAs, anatomical location and resectability play a crucial role. For those lesions that are considered resectable, surgical resection can be curable. Chemotherapy and radiation are typically utilized for unresectable lesions or can be used as neoadjuvant therapy for resectable tumors. For those tumors that cause obstruction, biliary drainage is usually the mainstay therapy with stent placement[29,32,38]. At present, extra-hepatic CCA is considered the condition most effectively treated with biliary RFA. Performance of RFA for intrahepatic CCA is challenging, and can be achieved *via* ERCP or EUS or percutaneous approach. RFA has also been employed to prolong the patency of stents in malignant obstructive tumors[27,38,39]. Typically the deployment of a self-expandable metallic stent (SEMS) is the mainstay palliative therapy in these patients. By prolonging the patency of stents, it improves survival and quality of life in patients with unresectable CCA.

Multiple studies have appraised the efficacy of RFA in the treatment of CCA and stent patency[33,40,41]. Cui and colleagues evaluated the effect of RFA on stent patency in malignant biliary obstruction, and while there was no significant difference in the overall survival, patency time was significantly increased in the RFA group at 7.6 mo when compared to 4.3 mo in the stent without RFA group. Another retrospective study by Li *et al*[29] determined that stent patency was prolonged in those patients who underwent RFA plus stenting compared to stenting alone (81% *vs* 35%) with a $P < 0.05$. Furthermore, a meta-analysis by Sofi and colleagues, which included eight observational studies and one randomized controlled trial of RFA in malignant biliary obstruction showed not only a significantly prolonged stent patency in the RFA group when compared to the control group, but also a significant increase in overall survival in the RFA group ($n = 504$; 95%CI: 1.145-1.7; $P < 0.01$)[18]. Yang *et al*[20] performed a randomized control trial on patients with unresectable distal CCA and perihilar CCA; one group received RFA plus stenting ($n = 32$) and the other group received stenting alone ($n = 33$). Compared to stenting alone, the RFA plus stent group had a statistically significant increase in both patency (6.8 mo; 95%CI: 3.6-8.2 *vs* 3.4 mo; 95%CI: 2.4-6.5) and overall survival (13.2 mo *vs* 8.3 mo)[20]. These results are in contrast to previous reports, like by Wu *et al*[32], which has shown efficacy of RFA for stent patency, but no survival benefit. A detailed summary is provided in Table 1. Few studies have also compared Photodynamic therapy (PDT) with RFA, mostly without any statistically significant difference in overall survival between the two treatment approaches[42]. However, one of the retrospective studies did show that RFA conferred a short-term advantage in decline in bilirubin[43,44].

Table 1 Utilization of radiofrequency ablation for cholangiocarcinoma

Technique	Ref.	Number of Patients	Location	Stent type	Mean number of sessions	Patency of stent (d, median)	Stent occlusion	Survival	Adverse events
Percutaneous	Mizandari <i>et al</i> [78], 2013	39	CCA (17); Bismuth I (5); II (1); IIIa (4); IV (7)-Panc CA (11), GB CA (4), HCC (1), Ampullary CA (1), Metastatic CA (5)	SEMS (all)	1	84.5	1	3 mo (median)	Abdominal pain (15)
	Wu <i>et al</i> [32], 2017	71[RFA and stenting = 35, stenting alone = 36]	Extra-hepatic distal CCA	Covered SEMS (7); uncovered SEMS (28)	1	Uncovered SEMS (241); covered SEMS (212)	-	Uncovered SEMS (245 d, median); covered SEMS (278 d, median)	Abdominal pain (27)
	Li <i>et al</i> [29], 2015	26[RFA and stenting = 12, stenting alone = 14]	Hilar (2), middle and distal CBD(7), Panc CA (2), ampullary CA (1)	SEMS (all)	1	RFA group (0), control group (3)	RFA group 100%; control group 85% at 90 d	-	Cholangitis (3)
	Wu <i>et al</i> [31], 2015	47	Hilar (7), distal CBD (16);ampullary CA (8); Panc CA (6); GB CA (4); HCC(2); Metastatic disease(4)	SEMS	1.38	149	11	6 mo	Abdominal pain (21), intra-abdominal hemorrhage (1)
	Wang <i>et al</i> [28], 2016	9	Bismuth IIIa (1); IIIb (1); IV (7)	SEMS	1 (only 1 patient had 2 sessions)	100	-	5.3 mo	Abdominal pain (3); Cholangitis (4)
	Wang <i>et al</i> [39], 2016	12	Bismuth I (5); IIIa (1); IV (3); Gastric CA (1); HCC(1); Congenital Choledochal cyst (1)	Plastic (7); SEMs (4)	1	125	-	7.7 mo (median)	Fever (2), pancreatitis (1)
	Laquière <i>et al</i> [81], 2016	12	Bismuth I (4); II (3); III (2); IV (3)	Plastic and Metallic (does not quantify)	1.63	-	4	12.3 mo	Sepsis (1), early stent migration (1), late stent migration(1), cholangitis (1)
Endoscopic	Sharaiha <i>et al</i> [86], 2015	69	Hilar (23); proximal CBD (7); distal CBD (7); Bismuth I (4); Bismuth III (2); Bismuth IV (5); Panc CA (19); GB CA (2); Gastric CA (1), Metastasis disease (3)	Metallic (49); Plastic (20)	1.3	95% at 30 d	3	17.7 ± 15.4 mo	Pancreatitis (1); Cholecystitis(2); Haemobilia (1); abdominal pain (3)
	Strand <i>et al</i> [87], 2014	16	Intrahepatic/proximal (1); Hilar (13); Extrahepatic/distal (2)	Plastic (3); fully covered SEMS (3); uncovered SEMS (11)	1.19	-	0.06	9.6 mo	Stent migration (0.02); cholangitis (0.13); hepatic abscess (0.02); need for percutaneous drainage (0.01); severe abdominal pain (0.02) (occurrence per month)
	Sharaiha <i>et al</i> [30], 2014	64	CCA (18); Panc CA (8)	Covered SEMS (8); uncovered SEMS (7); Plastic (11)	1	100% at 90 d	0	5.9 mo	Abdominal pain(3); Pancreatitis (1); Cholecystitis (1)
	Alis <i>et al</i> [88], 2013	10	Bismuth I (4); Distal CBD (6)	SEMS (all)	1	270	0	-	Pancreatitis (2)
	Figueroa	20	CCA (11); Panc CA (7);	Plastic (6);	1.25	100% at 30	0	-	Abdominal pain

	Barojas <i>et al</i> [49], 2013		Gastric Ca (1), IPMN with high grade dysplasia (1)	covered SEMS (13); uncovered SEMS (1)		d			(5); Pancreatitis (1); Cholecystitis (1)
	Steel <i>et al</i> [19], 2011	21	CCA (6); Panc CA (16)	Uncovered SEMS (all)	2	114 (median stent patency at 9- d)	4	-	Pancreatitis (1); cholecystitis (2), obstructive jaundice/ death (1)
Percutaneous and endoscopic	Dolak <i>et al</i> [27], 2014	58	Bismuth I (5); II (1); III (6); IV (33); distal CBD (5);Panc CA (4), central HCC,mCRC(3)	Plastic (19); SEMS (35); no stent (4)	1.44	170 (Metallic stent = 218, Plastic stent = 115)	-	10.9 mo (median)	Cholangitis (5); hemobilia (2); sepsis (2); hepatic coma (1); hepatic infarction (1)

CBD: Common bile duct; CCA: Cholangiocarcinoma; GA Ca: Gallbladder cancer; Panc CA: Pancreatic cancer; mCRC: Metastatic colorectal cancer; SEMS: Self-expanding metallic stent.

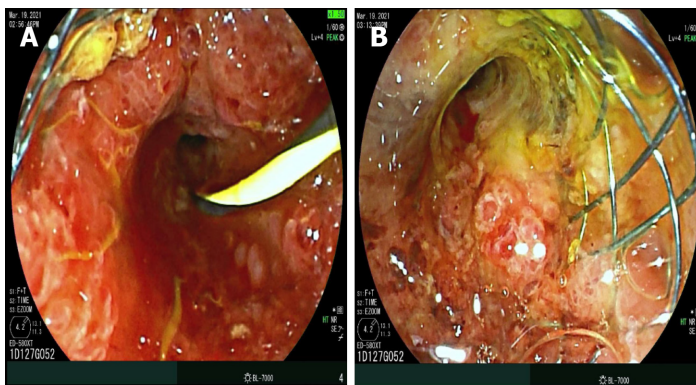


Figure 1 Cholangiocarcinoma stricture and radiofrequency ablation. A: Tumor ingrowth into uncovered metallic stent (placed for distal cholangiocarcinoma), allowing passage of guidewire but no other equipment; B: Treated with Habib radiofrequency ablation probe, to achieve patency of stent, which allowed successful biliary drainage.

To summarize, RFA is a successful strategy for loco-regional management of extra-hepatic CCA, management of malignant biliary obstruction, as well as blocked metallic stents. The performance of RFA is operator dependent, and not protocol based, and hence timing and interval of RFA remains unclear, as well as choice of stents (plastic *vs* metallic). For intra-hepatic CCA, the access using ERCP-RFA catheters can be challenging, and alternative approaches may include EUS-RFA or percutaneous RFA by Interventional Radiology. Alternatives to RFA include Photodynamic Therapy (PDT), Microwave Ablation (MWA) and Irreversible Electroporation Ablation (IRE), all of which are complex and expensive procedures, which require highly specialized equipment, have side effects (photosensitivity with PDT) and complication profile, and hence not commonly performed worldwide. IRE is a non-thermal ablation modality, the basic principle of which is to create irreversible pores in cellular bi-lipid membranes by subjecting them to series of high intensity electrical pulses for short duration of time, resulting in cell death due to apoptosis, especially used for tumors located close to porta-hepatis. On the other hand, in MWA, tumor tissue is destroyed by direct hyperthermic injury produced by electromagnetic waves emitted from non-insulated portions of antenna, resulting in larger volume of active heating resulting in shorter procedure times, higher tissue temperatures beyond the threshold of water vaporization and less susceptibility to the heat sink effect of blood flow. Detailed discussion regarding these modalities is beyond the scope of this mini-review manuscript.

RFA IN HCC

HCC is the most common primary liver cancer and has the third-highest cancer-related mortality worldwide, exceeding 700000 deaths per year [2,3,5,6,45-47]. There

are different causes of HCC, which vary worldwide; in Africa, aflatoxin B1 and chronic Hepatitis B infection seem to account for the most incidence of HCC, whereas cases in North America, Japan, and Europe are related to alcoholism and Hepatitis C infection [2,3,5,6,45-47]. Currently, the curative management options for HCC include liver transplantation, hepatectomy, or ablative therapies. Most patients diagnosed with HCC are not surgical candidates due to the advanced tumor size, invasion, or presence of metastasis [1-4,48]. Most management algorithms worldwide employ a specific scoring system named Barcelona Clinic Liver Cancer guidelines [1-6,48-50], to aid clinicians in determining the most appropriate management modality. Patients with early-stage HCC without any vascular invasion are classified as BCLC-A, which are suitable candidates for resection, ablation, or transplantation. On the other end of the treatment spectrum, patients with extra-hepatic tumor spread or vascular invasion are classified as BCLC-C, and are best managed with systemic therapies such as Sorafenib [1-6,48-50].

With the introduction of the Milan criteria, an increase in liver transplantation has been witnessed, ushering in a new era of curative treatment for HCC [51,52]. However, transplantation is dependent on donor availability, and since there are a limited number of donors, only a finite number of patients can undergo successful treatment. More importantly, patients may spend long periods of time awaiting transplant, allowing cancer to progress, which may disqualify formerly eligible patients from transplantation. To avoid this clinical dilemma, ablative techniques such as RFA become important for the crucial role they can play in delaying the malignancy progression [24,53-56]. A distinct advantage of these ablation techniques is that they can be performed safely on suboptimal surgical candidates.

RFA is the most widely used thermal ablative procedure used in patients with HCC [49,54,57,58], the success of which is inversely related to tumor size. Complete remission is achieved in approximately 90%-92% in those with tumor size < 2 cm whereas remission rates decrease to 20%-40% in those \geq 2 cm in size [59]. While theoretically, multipolar electrodes may expand the ablation zone of RFA, this has not been panned out in clinical studies. Cartier *et al* [60] compared traditional monopolar electrode RFA with multipolar electrodes in patients with tumors > 2.5 cm, and found no difference in residual tumor or recurrence. RFA seems to be a safe treatment option with procedure-related mortality of approximately 0.2% and an overall complication rate of 2.2% [61,62]. A novel RFA technique being studied is the "no-touch RFA protocol," which involves inserting multiple electrodes within the tissue that surrounds the tumor [62], which avoids direct contact with the tumor, allowing thermal ablation to be conducted with decreased risk of tumor seeding by the probe.

Several studies have investigated the effectiveness of RFA in HCC (Table 2). Liao *et al* [63] randomized 96 patients into those undergoing wide margin (WM \geq 10 mm) ablation ($n = 48$) and normal margin (NM: \geq 5 but < 10 mm) ablation ($n = 48$), and followed for mean period of 38.3 ± 4.8 mos. When analyzed based on intention-to-treat strategy, the 3-year incidences of local tumor progression (LTP) (14.9% *vs* 30.2%), intrahepatic recurrence (IHR) (15.0% *vs* 32.7%), and recurrence-free survival (RFS) (31.7 ± 12.1 *vs* 24.0 ± 11.7 mo) for WM group were significantly improved compared to NM group [63]. Getting recurrence-free survival advantage with RFA is a major success, for which RFA is adopted widely worldwide for smaller HCC, especially in non-resectable candidates. In regards to the "no-touch RFA protocol," a multicenter retrospective study of HCC < 5 cm in diameter ($n = 362$) showed effectiveness of this approach over monopolar RFA in terms of recurrence rates [62,63], but no statistical difference in 5-year survival rates (monopolar 37.2% *vs* no-touch multipolar 46.4% $P = 0.378$). Some investigators have proposed that stereotactic body radiotherapy (SBRT) was more effective than RFA, which has been challenged in recent studies [64,65]. In 2018, Rajyaguru *et al* [64] compared the effectiveness of RFA ($n = 3684$) against SBRT ($n = 296$), and their analysis support superior survival with RFA for non-surgically managed patients with stage I or II HCC. Various studies have investigated predictive factors to achieve improved outcomes in HCC when utilizing RFA. In a recent meta-analysis by Giardini *et al* [61,65-68] (34 studies; $n = 11,216$), alpha-fetoprotein (AFP) < 20 ng/mL, Child-Pugh class A and albumin-bilirubin index of 1 were noted to confer increased survival benefit. In addition, survival also increased in patients with single tumor < 2 cm in diameter and preserved hepatic function [61,69-71].

Several studies have also explored the comparative success rates of RFA *vs* hepatectomy in HCC. A meta-analysis by Xu *et al* [72] indicated that RFA and surgical hepatectomy had similar overall survival at 1 year (relative risk [RR], 1.39; 95% confidence interval [CI]: 0.36, 5.33; $P = 0.63$) and 3 years (RR, 1.40; 95%CI: 0.75, 2.62; $P = 0.29$), whereas RFA resulted in decreased overall survival compared with HR at 5 years (RR: 1.91; 95%CI: 1.32, 2.79; $P = 0.001$) [72]. However, closer analysis of subgroup

Table 2 Utilization of Radiofrequency ablation for hepatocellular carcinoma

Ref.	Type	N	Technique	Survival	Recurrence	Adverse Events	Outcome
Zhang <i>et al</i> [89], 2013	Retrospective	155	RFA (78- 93 sessions) and MWA (77-91 sessions)	1-, 3-, and 5-year overall survival rates: RFA: 91.0%, 64.1% and 41.3%; MWA: 92.2%, 51.7%, and 38.5%	RFA: 11/93 (11.8%) and MWA: 11/105 (10.5%)	RFA group: persistent jaundice (n = 1) and biliary fistula (n = 1). MWA group: hemothorax and intrahepatic hematoma (n = 1) and peritoneal hemorrhage (n = 1)	No significant differences LTP, DR, and overall survival
Karla <i>et al</i> [90], 2017	Prospective	50	RFA alone (25) and RFA + alcohol ablation (25)	RFA alone 84%; RFA + alcohol (80%) (at 6 month)	Local recurrence (11); Distant intrahepatic tumor recurrence (4)	Hemoperitoneum (1)	Combined use of RFA and alcohol did not improve the local tumor control and survival
Abdelaziz <i>et al</i> [91], 2017	Retrospective	67	TACE-RFA (22) and TACE-MWA (45)	Survival at 1, 2 and 3 years: TACE-MWA: 83.3%, 64.7%, 64.7%; TACE-RFA: 73.1%, 40.6% and 16.2% ($P = 0.08$)	TACE-RFA: 4 (18.2%); TACE-MWA: 8 (17.8%)	TACE-RFA: bone metastases 1 (4.5%), Ascites 3 (13.6%), variceal bleeding 5 (22.7%); TACE-MWA: portal vein thrombosis: 1 (2.2%), ascites 6 (13.3%), variceal bleeding: 4 (8.9%)	No significant difference in overall survival was observed
Gyori <i>et al</i> [92], 2017	Retrospective	150	54% ($n = 81$) received TACE-based LRT, 26% ($n = 39$) PEI/RFA regimen, and 17% ($n = 26$) had no treatment while on the waiting list	No difference in overall survival after liver transplantation when comparing TACE- and RFA-based regimens.			TACE- and RFA-based regimens showed equal outcomes in terms of transplantation rate, tumor response, and post-transplant survival. Lower survival in recipients of Multimodality LRT.
Hao <i>et al</i> [93], 2017	Retrospective	237	50 pathologically early HCCs, 187 typical HCCs		LTP observed in 1 Early HCC (2%); 46 Typical HCC (24.6%)	Fever, abdominal pain and elevated liver enzyme levels.	Rate of LTP for early HCCs after RFA was significantly lower than typical HCCs.
Liao <i>et al</i> [63], 2017	Prospective randomized	96	48 patients wide margin (WM) ablation (≥ 10 mm) and 48 normal margin (NM) ablation (≥ 5 mm but < 10 mm)	The 1-, 2-, and 3-year survival rates: WM: 95.8%, 91.6%, and 74.6%; NM: 95.8%, 78.4%, and 60.2%	3-year LTP: WM: 14.9%; NM: 30.2% Intrahepatic recurrence (IHR): WM: 15.0% NM: 32.7%	Perihepatic bile collection (1); intrahepatic hemorrhage(1); fever(1); liver infarction (1); thermal skin injury (1); pleural effusion (1)	WM-RFA may reduce the incidence of tumor recurrence among cirrhotic patients with small HCCs
Rajyaguru <i>et al</i> [64], 2018	Observational	3980	RFA (3,684) and SBRT (296)	5 yr overall survival: RFA: 29.8% (95%CI: 24.5-35.3%); SBRT: 19.3% (95%CI: 13.5-25.9%)			Treatment with RFA yields superior survival compared with SBRT for nonsurgically managed patients with stage I or II HCC
Parick <i>et al</i> [65], 2018	Retrospective cohort	440	RFA (408) and SBRT (32)	RFA patients had better overall survival ($P < 0.001$)			SBRT (HR 1.80; 95%CI: 1.15-2.82) associated with worse survival
Santambrogio <i>et al</i> [94], 2018	Prospective controlled	264	Laparoscopic hepatic resection (LHR = 59) vs laparoscopic ablation therapy (LAT = 205)	Survival rates LHR at 1, 3, and 5 years were 93, 82, and 56%. In LAT = 91%, 62%, and 40%	LHR = 24/59 (41%); LAT = 135/205 (66%)		LAT found to be adequate alternative

OLT: Orthotopic liver transplantation; LRT: Locoregional treatment; LTP: Local Tumor Progression; TACE: Transarterial chemoembolization; PEI: Percutaneous ethanol injection; SBRT: Stereotactic body radiotherapy; MWA: Microwave ablation; DR: Distant recurrence.

data, results showed no difference in survival between the groups in tumors less than 2.0 cm in size[72]. The Surveillance, Epidemiology and End Results (SEER) database explored the same question further stratified by age[65], and noted that patients older than 65 years with tumors less than 2 cm had similar survival to their propensity-matched group age less than 65 years. Interestingly, those < 65 years and tumors > 3.0 cm had an increased overall survival with hepatectomy compared to RFA. However,

large-scale studies have not been able to incorporate the novel RFA techniques previously discussed compared to hepatectomy[59,73,74]. Further studies will need to be conducted to answer this question.

Several studies have explored the role of combination therapy with RFA. In a recent meta-analysis, the pooled results showed that the 1-, 3-, 5-year overall survival rate in the combined RFA+hepatectomy group were comparable with those in the hepatectomy alone group (OR = 0.77, 0.96, 0.88; P = 0.33, 0.88, 0.70, respectively). Similarly, there was no significant difference in 1-, 3-, 5-year disease free survival rate between the combined group and the surgical alone group (OR = 0.57, 0.83, 0.72; P = 0.17, 0.37, 0.32, respectively). These results indicated that the hepatectomy combined with RFA could reach a long-term survival outcome similar to curative surgical resection for multifocal HCC patients, and this approach may be a promising alternative for patients with marginal liver function or complicated tumor distribution [75]. But, RFA+hepatectomy is limited due to its increased rate of post-op complications such as liver failure and death. Transcatheter arterial chemoembolization (TACE) is another commonly used percutaneous non-ablative treatment for HCC[76], which when combined with RFA yields a feasible treatment strategy with promising outcomes. In study by Kim *et al*[77], 1 mo, 6 mo, and 1-year tumor responses of TACE-RFA were similar to those of RFA and better than those of TACE. A distinct advantage of this combination therapy may be in patients with tumors located close to major vessels, wherein TACE occludes the hepatic artery flow, allowing a larger area for RFA ablation. This strategy minimizes the "heat-sink" effect associated with RFA. Regardless, the TACE-RFA group showed longer hospital stay and more frequent patient discomfort requiring medication than TACE or RFA monotherapy groups (P < 0.001), as well as the frequency of overall complications after TACE-RFA was higher than TACE (P = 0.006) or RFA (P = 0.009)[52,74,76-78]. Finally, RFA is also being utilized in combination with Sorafenib for management of HCC. A recent meta-analysis (15 studies, 2227 patients) showed that compared to RFA-alone, the patients in RFA+Sorafenib had longer 1-, 2- and 3-year overall survival (P < 0.05), better overall efficacy (P < 0.0001), longer RFA interval (P < 0.001) and lower 2-year recurrence rate (P = 0.02). However, this came at the cost of higher adverse reactions compared to RFA-alone group, including hand-foot skin reactions (P < 0.001), diarrhea and constipation (P < 0.0001), hypertension (P = 0.009) and alopecia (P < 0.001)[79]. Therefore, cognizance of overall adverse events is necessary while choosing the most optimal strategy. Despite these limitations, overall improvements in technology under development show promising prospects in the treatment of HCC.

ADVERSE EVENTS AND LIMITATIONS OF RFA

Several adverse events have been associated with RFA, the most common being post-procedure mild abdominal pain following either endoscopic or percutaneous RFA approaches. There seems to be a higher incidence of bleeding with percutaneous RFA, whereas a higher association of pancreatitis with the endoscopic approach[59,80]. Other post-procedure complications, such as hemobilia and hepatic artery pseudoaneurysms, have been postulated to be due to thermal injury[38,81]. This can be avoided with the newer ELRA RF catheter, which has a temperature probe. Further complications have been listed in Tables 1 and 2.

RFA does have its limitations. The therapeutic efficacy of RFA is inversely associated with tumor size and location[59]. RFA needs direct contact with the tissue, which can pose a challenge to treat tumors in inaccessible sites. Furthermore, tumors in close proximity to large vessels pose interesting therapeutic challenges[10,18,22,41,82,83]. Tumors located near large portal and hepatic vein branches can result in a "heat-sink" effect, which results in the inability to reach maximal ablation temperatures, thereby causing incomplete cell death[84]. It is important to keep in mind that RFA cannot be used in pregnancy or patients with cardiac devices or coagulopathy[24,73,82,83,85].

CONCLUSION

RFA has been established as novel and safe minimally invasive management tool for HCC. While multiple studies optimizing these techniques have shown promising results in patients with CCA, the low incidence of these biliary tumors makes it challenging to coordinate high-powered RCTs comparing various techniques and

treatment strategies. It is paramount that future studies are coordinated through collaboration between various institutions of excellence for the progress of this still novel technique.

REFERENCES

- 1 **Avolio AW**, Cillo U, Salizzoni M, De Carlis L, Colledan M, Gerunda GE, Mazzaferro V, Tisone G, Romagnoli R, Caccamo L, Rossi M, Vitale A, Cucchetti A, Lupo L, Gruttadauria S, Nicolotti N, Burra P, Gasbarrini A, Agnes S; Donor-to-Recipient Italian Liver Transplant (D2R-ILTx) Study Group. Balancing donor and recipient risk factors in liver transplantation: the value of D-MELD with particular reference to HCV recipients. *Am J Transplant* 2011; **11**: 2724-2736 [PMID: [21920017](#) DOI: [10.1111/j.1600-6143.2011.03732.x](#)]
- 2 **Bosetti C**, Levi F, Boffetta P, Lucchini F, Negri E, La Vecchia C. Trends in mortality from hepatocellular carcinoma in Europe, 1980-2004. *Hepatology* 2008; **48**: 137-145 [PMID: [18537177](#) DOI: [10.1002/hep.22312](#)]
- 3 **Bruix J**, Gores GJ, Mazzaferro V. Hepatocellular carcinoma: clinical frontiers and perspectives. *Gut* 2014; **63**: 844-855 [PMID: [24531850](#) DOI: [10.1136/gutjnl-2013-306627](#)]
- 4 **Bruix J**, Sherman M; Practice Guidelines Committee, American Association for the Study of Liver Diseases. Management of hepatocellular carcinoma. *Hepatology* 2005; **42**: 1208-1236 [PMID: [16250051](#) DOI: [10.1002/hep.20933](#)]
- 5 **Bruix J**, Sherman M; American Association for the Study of Liver Diseases. Management of hepatocellular carcinoma: an update. *Hepatology* 2011; **53**: 1020-1022 [PMID: [21374666](#) DOI: [10.1002/hep.24199](#)]
- 6 **Forner A**, Llovet JM, Bruix J. Hepatocellular carcinoma. *Lancet* 2012; **379**: 1245-1255 [PMID: [22353262](#) DOI: [10.1016/s0140-6736\(11\)61347-0](#)]
- 7 **Green BL**, House MG. Nonsurgical Approaches to Treat Biliary Tract and Liver Tumors. *Surg Oncol Clin N Am* 2019; **28**: 573-586 [PMID: [31472906](#) DOI: [10.1016/j.soc.2019.06.013](#)]
- 8 **Lencioni R**, Cioni D, Crocetti L, Franchini C, Pina CD, Lera J, Bartolozzi C. Early-stage hepatocellular carcinoma in patients with cirrhosis: long-term results of percutaneous image-guided radiofrequency ablation. *Radiology* 2005; **234**: 961-967 [PMID: [15665226](#) DOI: [10.1148/radiol.2343040350](#)]
- 9 **Loriaud A**, Denys A, Seror O, Vietti Violi N, Digkila A, Duran R, Trillaud H, Hocquet A. Hepatocellular carcinoma abutting large vessels: comparison of four percutaneous ablation systems. *Int J Hyperthermia* 2018; **34**: 1171-1178 [PMID: [29457510](#) DOI: [10.1080/02656736.2018.1440017](#)]
- 10 **Buerlein RCD**, Wang AY. Endoscopic Retrograde Cholangiopancreatography-Guided Ablation for Cholangiocarcinoma. *Gastrointest Endosc Clin N Am* 2019; **29**: 351-367 [PMID: [30846158](#) DOI: [10.1016/j.giec.2018.11.006](#)]
- 11 **Chahal P**, Baron TH. Endoscopic palliation of cholangiocarcinoma. *Curr Opin Gastroenterol* 2006; **22**: 551-560 [PMID: [16891889](#) DOI: [10.1097/01.mog.0000239872.12081.a4](#)]
- 12 **Labib PL**, Davidson BR, Sharma RA, Pereira SP. Locoregional therapies in cholangiocarcinoma. *Hepat Oncol* 2017; **4**: 99-109 [PMID: [29367874](#) DOI: [10.2217/hep-2017-0014](#)]
- 13 **Qureshi K**, Jesudoss R, Al-Osaimi AM. The treatment of cholangiocarcinoma: a hepatologist's perspective. *Curr Gastroenterol Rep* 2014; **16**: 412 [PMID: [25183579](#) DOI: [10.1007/s11894-014-0412-2](#)]
- 14 **Razumilava N**, Gores GJ. Classification, diagnosis, and management of cholangiocarcinoma. *Clin Gastroenterol Hepatol* 2013; **11**: 13-21.e1; quiz e3 [PMID: [22982100](#) DOI: [10.1016/j.cgh.2012.09.009](#)]
- 15 **Nault JC**, Sutter O, Nahon P, Ganne-Carrié N, S  r  r O. Percutaneous treatment of hepatocellular carcinoma: State of the art and innovations. *J Hepatol* 2018; **68**: 783-797 [PMID: [29031662](#) DOI: [10.1016/j.jhep.2017.10.004](#)]
- 16 **Shiina S**, Tateishi R, Arano T, Uchino K, Enooku K, Nakagawa H, Asaoka Y, Sato T, Masuzaki R, Kondo Y, Goto T, Yoshida H, Omata M, Koike K. Radiofrequency ablation for hepatocellular carcinoma: 10-year outcome and prognostic factors. *Am J Gastroenterol* 2012; **107**: 569-77; quiz 578 [PMID: [22158026](#) DOI: [10.1038/ajg.2011.425](#)]
- 17 **Lee EW**, Chen C, Prieto VE, Dry SM, Loh CT, Kee ST. Advanced hepatic ablation technique for creating complete cell death: irreversible electroporation. *Radiology* 2010; **255**: 426-433 [PMID: [20413755](#) DOI: [10.1148/radiol.10090337](#)]
- 18 **Sofi AA**, Khan MA, Das A, Sachdev M, Khuder S, Nawras A, Lee W. Radiofrequency ablation combined with biliary stent placement vs stent placement alone for malignant biliary strictures: a systematic review and meta-analysis. *Gastrointest Endosc* 2018; **87**: 944-951.e1 [PMID: [29108980](#) DOI: [10.1016/j.gie.2017.10.029](#)]
- 19 **Steel AW**, Postgate AJ, Khorsandi S, Nicholls J, Jiao L, Vlavianos P, Habib N, Westaby D. Endoscopically applied radiofrequency ablation appears to be safe in the treatment of malignant biliary obstruction. *Gastrointest Endosc* 2011; **73**: 149-153 [PMID: [21184881](#) DOI: [10.1016/j.gie.2010.09.031](#)]
- 20 **Yang J**, Wang J, Zhou H, Zhou Y, Wang Y, Jin H, Lou Q, Zhang X. Efficacy and safety of endoscopic radiofrequency ablation for unresectable extrahepatic cholangiocarcinoma: a randomized

- trial. *Endoscopy* 2018; **50**: 751-760 [PMID: 29342492 DOI: 10.1055/s-0043-124870]
- 21 **Larghi A**, Rimbaş M, Tringali A, Boškoski I, Rizzatti G, Costamagna G. Endoscopic radiofrequency biliary ablation treatment: A comprehensive review. *Dig Endosc* 2019; **31**: 245-255 [PMID: 30444547 DOI: 10.1111/den.13298]
 - 22 **Lee DH**, Lee JM. Recent Advances in the Image-Guided Tumor Ablation of Liver Malignancies: Radiofrequency Ablation with Multiple Electrodes, Real-Time Multimodality Fusion Imaging, and New Energy Sources. *Korean J Radiol* 2018; **19**: 545-559 [PMID: 29962861 DOI: 10.3348/kjr.2018.19.4.545]
 - 23 **Kim YS**, Lim HK, Rhim H, Lee MW, Choi D, Lee WJ, Paik SW, Koh KC, Lee JH, Choi MS, Gwak GY, Yoo BC. Ten-year outcomes of percutaneous radiofrequency ablation as first-line therapy of early hepatocellular carcinoma: analysis of prognostic factors. *J Hepatol* 2013; **58**: 89-97 [PMID: 23023009 DOI: 10.1016/j.jhep.2012.09.020]
 - 24 **Livraghi T**, Meloni F, Di Stasi M, Rolle E, Solbiati L, Tinelli C, Rossi S. Sustained complete response and complications rates after radiofrequency ablation of very early hepatocellular carcinoma in cirrhosis: Is resection still the treatment of choice? *Hepatology* 2008; **47**: 82-89 [PMID: 18008357 DOI: 10.1002/hep.21933]
 - 25 **Tateishi R**, Shiina S, Teratani T, Obi S, Sato S, Koike Y, Fujishima T, Yoshida H, Kawabe T, Omata M. Percutaneous radiofrequency ablation for hepatocellular carcinoma. An analysis of 1000 cases. *Cancer* 2005; **103**: 1201-1209 [PMID: 15690326 DOI: 10.1002/cncr.20892]
 - 26 **Yan K**, Chen MH, Yang W, Wang YB, Gao W, Hao CY, Xing BC, Huang XF. Radiofrequency ablation of hepatocellular carcinoma: long-term outcome and prognostic factors. *Eur J Radiol* 2008; **67**: 336-347 [PMID: 17765421 DOI: 10.1016/j.ejrad.2007.07.007]
 - 27 **Dolak W**, Schreiber F, Schwaighofer H, Gschwantler M, Plieschnegger W, Ziachehabi A, Mayer A, Kramer L, Kopecky A, Schrutka-Köbl C, Wolkersdörfer G, Madl C, Berr F, Trauner M, Püspök A; Austrian Biliary RFA Study Group. Endoscopic radiofrequency ablation for malignant biliary obstruction: a nationwide retrospective study of 84 consecutive applications. *Surg Endosc* 2014; **28**: 854-860 [PMID: 24196547 DOI: 10.1007/s00464-013-3232-9]
 - 28 **Wang F**, Li Q, Zhang X, Jiang G, Ge X, Yu H, Nie J, Ji G, Miao L. Endoscopic radiofrequency ablation for malignant biliary strictures. *Exp Ther Med* 2016; **11**: 2484-2488 [PMID: 27284336 DOI: 10.3892/etm.2016.3235]
 - 29 **Li TF**, Huang GH, Li Z, Hao CF, Ren JZ, Duan XH, Zhang K, Chen C, Han XW, Jiao DC, Zhang MF, Wang YL. Percutaneous transhepatic cholangiography and intraductal radiofrequency ablation combined with biliary stent placement for malignant biliary obstruction. *J Vasc Interv Radiol* 2015; **26**: 715-721 [PMID: 25817458 DOI: 10.1016/j.jvir.2015.01.037]
 - 30 **Sharaiha RZ**, Natov N, Glockenberg KS, Widmer J, Gaidhane M, Kahaleh M. Comparison of metal stenting with radiofrequency ablation vs stenting alone for treating malignant biliary strictures: is there an added benefit? *Dig Dis Sci* 2014; **59**: 3099-3102 [PMID: 25033929 DOI: 10.1007/s10620-014-3264-6]
 - 31 **Wu TT**, Li HC, Li WM, Ao GK, Lin H, Zheng F, Song JY. Percutaneous Intraluminal Radiofrequency Ablation for Malignant Extrahepatic Biliary Obstruction: A Safe and Feasible Method. *Dig Dis Sci* 2015; **60**: 2158-2163 [PMID: 25648642 DOI: 10.1007/s10620-015-3547-6]
 - 32 **Wu TT**, Li WM, Li HC, Ao GK, Zheng F, Lin H. Percutaneous Intraductal Radiofrequency Ablation for Extrahepatic Distal Cholangiocarcinoma: A Method for Prolonging Stent Patency and Achieving Better Functional Status and Quality of Life. *Cardiovasc Intervent Radiol* 2017; **40**: 260-269 [PMID: 27743089 DOI: 10.1007/s00270-016-1483-2]
 - 33 **Cui W**, Fan W, Lu M, Zhang Y, Yao W, Li J, Wang Y. The safety and efficacy of percutaneous intraductal radiofrequency ablation in unresectable malignant biliary obstruction: A single-institution experience. *BMC Cancer* 2017; **17**: 288 [PMID: 28438130 DOI: 10.1186/s12885-017-3278-5]
 - 34 **Shaib Y**, El-Serag HB. The epidemiology of cholangiocarcinoma. *Semin Liver Dis* 2004; **24**: 115-125 [PMID: 15192785 DOI: 10.1055/s-2004-828889]
 - 35 **Ferlay J**, Shin HR, Bray F, Forman D, Mathers C, Parkin DM. Estimates of worldwide burden of cancer in 2008: GLOBOCAN 2008. *Int J Cancer* 2010; **127**: 2893-2917 [PMID: 21351269 DOI: 10.1002/ijc.25516]
 - 36 **Deoliveira ML**, Schulick RD, Nimura Y, Rosen C, Gores G, Neuhaus P, Clavien PA. New staging system and a registry for perihilar cholangiocarcinoma. *Hepatology* 2011; **53**: 1363-1371 [PMID: 21480336 DOI: 10.1002/hep.24227]
 - 37 **Ebata T**, Mizuno T, Yokoyama Y, Igami T, Sugawara G, Nagino M. Surgical resection for Bismuth type IV perihilar cholangiocarcinoma. *Br J Surg* 2018; **105**: 829-838 [PMID: 28488733 DOI: 10.1002/bjs.10556]
 - 38 **Tal AO**, Vermehren J, Friedrich-Rust M, Bojunga J, Sarrazin C, Zeuzem S, Trojan J, Albert JG. Intraductal endoscopic radiofrequency ablation for the treatment of hilar non-resectable malignant bile duct obstruction. *World J Gastrointest Endosc* 2014; **6**: 13-19 [PMID: 24527176 DOI: 10.4253/wjge.v6.i1.13]
 - 39 **Wang Y**, Cui W, Fan W, Zhang Y, Yao W, Huang K, Li J. Percutaneous intraductal radiofrequency ablation in the management of unresectable Bismuth types III and IV hilar cholangiocarcinoma. *Oncotarget* 2016; **7**: 53911-53920 [PMID: 27322076 DOI: 10.18632/oncotarget.10116]
 - 40 **Cui W**, Wang Y, Fan W, Lu M, Zhang Y, Yao W, Li J. Comparison of intraluminal radiofrequency ablation and stents vs stents alone in the management of malignant biliary obstruction. *Int J Hyperthermia* 2017; **33**: 853-861 [PMID: 28540797 DOI: 10.1080/02656736.2017.1309580]

- 41 **Lee YN**, Jeong S, Choi HJ, Cho JH, Cheon YK, Park SW, Kim YS, Lee DH, Moon JH. The safety of newly developed automatic temperature-controlled endobiliary radiofrequency ablation system for malignant biliary strictures: A prospective multicenter study. *J Gastroenterol Hepatol* 2019; **34**: 1454-1459 [PMID: [30861593](#) DOI: [10.1111/jgh.14657](#)]
- 42 **Yang J**, Shen H, Jin H, Lou Q, Zhang X. Treatment of unresectable extrahepatic cholangiocarcinoma using hematoporphyrin photodynamic therapy: A prospective study. *Photodiagnosis Photodyn Ther* 2016; **16**: 110-118 [PMID: [27720942](#) DOI: [10.1016/j.pdpdt.2016.10.001](#)]
- 43 **Patel J**, Rizk N, Kahaleh M. Role of photodynamic therapy and intraductal radiofrequency ablation in cholangiocarcinoma. *Best Pract Res Clin Gastroenterol* 2015; **29**: 309-318 [PMID: [25966430](#) DOI: [10.1016/j.bpg.2015.02.008](#)]
- 44 **Schmidt A**, Bloechinger M, Weber A, Siveke J, von Delius S, Prinz C, Schmitt W, Schmid RM, Neu B. Short-term effects and adverse events of endoscopically applied radiofrequency ablation appear to be comparable with photodynamic therapy in hilar cholangiocarcinoma. *United European Gastroenterol J* 2016; **4**: 570-579 [PMID: [27536367](#) DOI: [10.1177/2050640615621235](#)]
- 45 **Ikenaga N**, Chijiwa K, Otani K, Ohuchida J, Uchiyama S, Kondo K. Clinicopathologic characteristics of hepatocellular carcinoma with bile duct invasion. *J Gastrointest Surg* 2009; **13**: 492-497 [PMID: [19011945](#) DOI: [10.1007/s11605-008-0751-0](#)]
- 46 **Mazzafiero V**, Regalia E, Doci R, Andreola S, Pulvirenti A, Bozzetti F, Montalto F, Ammatuna M, Morabito A, Gennari L. Liver transplantation for the treatment of small hepatocellular carcinomas in patients with cirrhosis. *N Engl J Med* 1996; **334**: 693-699 [PMID: [8594428](#) DOI: [10.1056/nejm199603143341104](#)]
- 47 **Murray KF**, Carithers RL Jr, AASLD. AASLD practice guidelines: Evaluation of the patient for liver transplantation. *Hepatology* 2005; **41**: 1407-1432 [PMID: [15880505](#) DOI: [10.1002/hep.20704](#)]
- 48 **Arii S**, Teramoto K, Kawamura T, Okamoto H, Kaido T, Mori A, Imamura M. Characteristics of recurrent hepatocellular carcinoma in Japan and our surgical experience. *J Hepatobiliary Pancreat Surg* 2001; **8**: 397-403 [PMID: [11702247](#) DOI: [10.1007/s005340100000](#)]
- 49 **Figuerola-Barojas P**, Bakhru MR, Habib NA, Ellen K, Millman J, Jamal-Kabani A, Gaidhane M, Kahaleh M. Safety and efficacy of radiofrequency ablation in the management of unresectable bile duct and pancreatic cancer: a novel palliation technique. *J Oncol* 2013; **2013**: 910897 [PMID: [23690775](#) DOI: [10.1155/2013/910897](#)]
- 50 **Freeman RB**, Edwards EB, Harper AM. Waiting list removal rates among patients with chronic and malignant liver diseases. *Am J Transplant* 2006; **6**: 1416-1421 [PMID: [16686765](#) DOI: [10.1111/j.1600-6143.2006.01321.x](#)]
- 51 **Huang J**, Yan L, Cheng Z, Wu H, Du L, Wang J, Xu Y, Zeng Y. A randomized trial comparing radiofrequency ablation and surgical resection for HCC conforming to the Milan criteria. *Ann Surg* 2010; **252**: 903-912 [PMID: [21107100](#) DOI: [10.1097/SLA.0b013e3181efc656](#)]
- 52 **Liu W**, Zheng Y, He W, Zou R, Qiu J, Shen J, Yang Z, Zhang Y, Wang C, Wang Y, Zuo D, Li B, Yuan Y. Microwave vs radiofrequency ablation for hepatocellular carcinoma within the Milan criteria: a propensity score analysis. *Aliment Pharmacol Ther* 2018; **48**: 671-681 [PMID: [30063081](#) DOI: [10.1111/apt.14929](#)]
- 53 **DuBay DA**, Sandroussi C, Kachura JR, Ho CS, Beecroft JR, Vollmer CM, Ghanekar A, Guba M, Cattral MS, McGilvray ID, Grant DR, Greig PD. Radiofrequency ablation of hepatocellular carcinoma as a bridge to liver transplantation. *HPB (Oxford)* 2011; **13**: 24-32 [PMID: [21159100](#) DOI: [10.1111/j.1477-2574.2010.00228.x](#)]
- 54 **Fisher RA**, Maluf D, Cotterell AH, Stravitz T, Wolfe L, Luketic V, Sterling R, Shiffman M, Posner M. Non-resective ablation therapy for hepatocellular carcinoma: effectiveness measured by intention-to-treat and dropout from liver transplant waiting list. *Clin Transplant* 2004; **18**: 502-512 [PMID: [15344951](#) DOI: [10.1111/j.1399-0012.2004.00196.x](#)]
- 55 **Lu DS**, Yu NC, Raman SS, Lassman C, Tong MJ, Britten C, Durazo F, Saab S, Han S, Finn R, Hiatt JR, Busuttil RW. Percutaneous radiofrequency ablation of hepatocellular carcinoma as a bridge to liver transplantation. *Hepatology* 2005; **41**: 1130-1137 [PMID: [15841454](#) DOI: [10.1002/hep.20688](#)]
- 56 **Toso C**, Dupuis-Lozeron E, Majno P, Berney T, Kneteman NM, Perneger T, Morel P, Mentha G, Combescure C. A model for dropout assessment of candidates with or without hepatocellular carcinoma on a common liver transplant waiting list. *Hepatology* 2012; **56**: 149-156 [PMID: [22271250](#) DOI: [10.1002/hep.25603](#)]
- 57 **Fontana RJ**, Hamidullah H, Nghiem H, Greenson JK, Hussain H, Marrero J, Rudich S, McClure LA, Arenas J. Percutaneous radiofrequency thermal ablation of hepatocellular carcinoma: a safe and effective bridge to liver transplantation. *Liver Transpl* 2002; **8**: 1165-1174 [PMID: [12474157](#) DOI: [10.1053/jlts.2002.36394](#)]
- 58 **Hansen PD**, Cassera MA, Wolf RF. Ablative technologies for hepatocellular, cholangiocarcinoma, and metastatic colorectal cancer of the liver. *Surg Oncol Clin N Am* 2015; **24**: 97-119 [PMID: [25444471](#) DOI: [10.1016/j.soc.2014.09.003](#)]
- 59 **Jiang YQ**, Wang ZX, Deng YN, Yang Y, Wang GY, Chen GH. Efficacy of Hepatic Resection vs Radiofrequency Ablation for Patients With Very-Early-Stage or Early-Stage Hepatocellular Carcinoma: A Population-Based Study With Stratification by Age and Tumor Size. *Front Oncol* 2019; **9**: 113 [PMID: [30863723](#) DOI: [10.3389/fonc.2019.00113](#)]
- 60 **Cartier V**, Boursier J, Lebigot J, Oberti F, Fouchard-Hubert I, Aubé C. Radiofrequency ablation of hepatocellular carcinoma: Mono or multipolar? *J Gastroenterol Hepatol* 2016; **31**: 654-660 [PMID: [26414644](#) DOI: [10.1111/jgh.13179](#)]

- 61 **Casadei Gardini A**, Marisi G, Canale M, Foschi FG, Donati G, Ercolani G, Valgiusti M, Passardi A, Frassinetti GL, Scarpi E. Radiofrequency ablation of hepatocellular carcinoma: a meta-analysis of overall survival and recurrence-free survival. *Onco Targets Ther* 2018; **11**: 6555-6567 [PMID: 30323628 DOI: 10.2147/ott.S170836]
- 62 **Hocquelet A**, Aubé C, Rode A, Cartier V, Sutter O, Manichon AF, Boursier J, N'kontchou G, Merle P, Blanc JF, Trillaud H, Seror O. Comparison of no-touch multi-bipolar vs monopolar radiofrequency ablation for small HCC. *J Hepatol* 2017; **66**: 67-74 [PMID: 27422750 DOI: 10.1016/j.jhep.2016.07.010]
- 63 **Liao M**, Zhong X, Zhang J, Liu Y, Zhu Z, Wu H, Zeng Y, Huang J. Radiofrequency ablation using a 10-mm target margin for small hepatocellular carcinoma in patients with liver cirrhosis: A prospective randomized trial. *J Surg Oncol* 2017; **115**: 971-979 [PMID: 28334430 DOI: 10.1002/jso.24607]
- 64 **Rajyaguru DJ**, Borgert AJ, Smith AL, Thomes RM, Conway PD, Halfdanarson TR, Truty MJ, Kurup AN, Go RS. Radiofrequency Ablation Versus Stereotactic Body Radiotherapy for Localized Hepatocellular Carcinoma in Nonsurgically Managed Patients: Analysis of the National Cancer Database. *J Clin Oncol* 2018; **36**: 600-608 [PMID: 29328861 DOI: 10.1200/jco.2017.75.3228]
- 65 **Parikh ND**, Marshall VD, Green M, Lawrence TS, Razumilava N, Owen D, Singal AG, Feng M. Effectiveness and cost of radiofrequency ablation and stereotactic body radiotherapy for treatment of early-stage hepatocellular carcinoma: An analysis of SEER-medicare. *J Med Imaging Radiat Oncol* 2018; **62**: 673-681 [PMID: 29877615 DOI: 10.1111/1754-9485.12754]
- 66 **Nicoli N**, Casaril A, Marchiori L, Mangiante G, Hasheminia AR. Treatment of recurrent hepatocellular carcinoma by radiofrequency thermal ablation. *J Hepatobiliary Pancreat Surg* 2001; **8**: 417-421 [PMID: 11702250 DOI: 10.1007/s005340100003]
- 67 **Pai M**, Spalding D, Jiao L, Habib N. Use of bipolar radiofrequency in parenchymal transection of the liver, pancreas and kidney. *Dig Surg* 2012; **29**: 43-47 [PMID: 22441619 DOI: 10.1159/000335732]
- 68 **Pulvirenti A**, Garbagnati F, Regalia E, Coppa J, Marchiano A, Romito R, Schiavo M, Fabbri A, Burgoa L, Mazzaferro V. Experience with radiofrequency ablation of small hepatocellular carcinomas before liver transplantation. *Transplant Proc* 2001; **33**: 1516-1517 [PMID: 11267402 DOI: 10.1016/s0041-1345(00)02577-x]
- 69 **Brillet PY**, Paradis V, Brancatelli G, Rangheard AS, Consigny Y, Plessier A, Durand F, Belghiti J, Sommacale D, Vilgrain V. Percutaneous radiofrequency ablation for hepatocellular carcinoma before liver transplantation: a prospective study with histopathologic comparison. *AJR Am J Roentgenol* 2006; **186**: S296-S305 [PMID: 16632691 DOI: 10.2214/ajr.04.1927]
- 70 **Chan AC**, Poon RT, Cheung TT, Chok KS, Chan SC, Fan ST, Lo CM. Survival analysis of re-resection vs radiofrequency ablation for intrahepatic recurrence after hepatectomy for hepatocellular carcinoma. *World J Surg* 2012; **36**: 151-156 [PMID: 22030561 DOI: 10.1007/s00268-011-1323-0]
- 71 **Cho YK**, Kim JK, Kim MY, Rhim H, Han JK. Systematic review of randomized trials for hepatocellular carcinoma treated with percutaneous ablation therapies. *Hepatology* 2009; **49**: 453-459 [PMID: 19065676 DOI: 10.1002/hep.22648]
- 72 **Xu XL**, Liu XD, Liang M, Luo BM. Radiofrequency Ablation vs Hepatic Resection for Small Hepatocellular Carcinoma: Systematic Review of Randomized Controlled Trials with Meta-Analysis and Trial Sequential Analysis. *Radiology* 2018; **287**: 461-472 [PMID: 29135366 DOI: 10.1148/radiol.2017162756]
- 73 **Majumdar A**, Roccarina D, Thorburn D, Davidson BR, Tsochatzis E, Gurusamy KS. Management of people with early- or very early-stage hepatocellular carcinoma: an attempted network meta-analysis. *Cochrane Database Syst Rev* 2017; **3**: CD011650 [PMID: 28351116 DOI: 10.1002/14651858.CD011650.pub2]
- 74 **Mohkam K**, Dumont PN, Manichon AF, Jouvét JC, Bousset L, Merle P, Ducerf C, Lesurtel M, Rode A, Mabrut JY. No-touch multipolar radiofrequency ablation vs surgical resection for solitary hepatocellular carcinoma ranging from 2 to 5 cm. *J Hepatol* 2018; **68**: 1172-1180 [PMID: 29410287 DOI: 10.1016/j.jhep.2018.01.014]
- 75 **Xu LL**, Zhang M, Yi PS, Zheng XB, Feng L, Lan C, Tang JW, Ren SS, Xu MQ. Hepatic resection combined with radiofrequency ablation vs hepatic resection alone for multifocal hepatocellular carcinomas: A meta-analysis. *J Huazhong Univ Sci Technolog Med Sci* 2017; **37**: 974-980 [PMID: 29270762 DOI: 10.1007/s11596-017-1836-3]
- 76 **Martin AN**, Wilkins LR, Das D, Johnston LE, Bauer TW, Adams RB, Zaydfudim VM. Efficacy of Radiofrequency Ablation versus Transarterial Chemoembolization for Patients with Solitary Hepatocellular Carcinoma \leq 3 cm. *Am Surg* 2019; **85**: 150-155 [PMID: 30819290]
- 77 **Kim W**, Cho SK, Shin SW, Hyun D, Lee MW, Rhim H. Combination therapy of transarterial chemoembolization (TACE) and radiofrequency ablation (RFA) for small hepatocellular carcinoma: comparison with TACE or RFA monotherapy. *Abdom Radiol (NY)* 2019; **44**: 2283-2292 [PMID: 30806742 DOI: 10.1007/s00261-019-01952-1]
- 78 **Mizandari M**, Pai M, Xi F, Valek V, Tomas A, Quaretti P, Golfieri R, Mosconi C, Guokun A, Kyriakides C, Dickinson R, Nicholls J, Habib N. Percutaneous intrahepatic radiofrequency ablation is a safe treatment for malignant biliary obstruction: feasibility and early results. *Cardiovasc Intervent Radiol* 2013; **36**: 814-819 [PMID: 23232859 DOI: 10.1007/s00270-012-0529-3]
- 79 **Jin M**, Yu Q, Liu Y, Xu W, Fu X, Ji B. Safety and Efficacy of Physical Thermal Ablation Combined Sorafenib for Hepatocellular Carcinoma: A Meta-analysis. *J Clin Transl Hepatol* 2021; **9**: 149-159 [PMID: 34007796 DOI: 10.14218/jeth.2020.00125]
- 80 **Germani G**, Pleguezuelo M, Gurusamy K, Meyer T, Isgrò G, Burroughs AK. Clinical outcomes of

- radiofrequency ablation, percutaneous alcohol and acetic acid injection for hepatocellular carcinoma: a meta-analysis. *J Hepatol* 2010; **52**: 380-388 [PMID: 20149473 DOI: 10.1016/j.jhep.2009.12.004]
- 81 **Laquière A**, Boustière C, Leblanc S, Penaranda G, Désilets E, Prat F. Safety and feasibility of endoscopic biliary radiofrequency ablation treatment of extrahepatic cholangiocarcinoma. *Surg Endosc* 2016; **30**: 1242-1248 [PMID: 26162420 DOI: 10.1007/s00464-015-4322-7]
- 82 **Kang TW**, Lim HK, Cha DI. Percutaneous ablation for perivascular hepatocellular carcinoma: Refining the current status based on emerging evidence and future perspectives. *World J Gastroenterol* 2018; **24**: 5331-5337 [PMID: 30598578 DOI: 10.3748/wjg.v24.i47.5331]
- 83 **Lurje I**, Czigan Z, Bednarsch J, Roderburg C, Isfort P, Neumann UP, Lurje G. Treatment Strategies for Hepatocellular Carcinoma - a Multidisciplinary Approach. *Int J Mol Sci* 2019; **20** [PMID: 30909504 DOI: 10.3390/ijms20061465]
- 84 **Weber JC**, Navarra G, Jiao LR, Nicholls JP, Jensen SL, Habib NA. New technique for liver resection using heat coagulative necrosis. *Ann Surg* 2002; **236**: 560-563 [PMID: 12409660 DOI: 10.1097/00000658-200211000-00004]
- 85 **Koda M**, Ueki M, Maeda Y, Mimura KI, Okamoto K, Matsunaga Y, Kawakami M, Hosho K, Murawaki Y. The influence on liver parenchymal function and complications of radiofrequency ablation or the combination with transcatheter arterial embolization for hepatocellular carcinoma. *Hepatol Res* 2004; **29**: 18-23 [PMID: 15135342 DOI: 10.1016/j.hepres.2004.02.001]
- 86 **Sharaiha RZ**, Sethi A, Weaver KR, Gonda TA, Shah RJ, Fukami N, Kedia P, Kumta NA, Clavo CM, Saunders MD, Cerecedo-Rodriguez J, Barojas PF, Widmer JL, Gaidhane M, Brugge WR, Kahaleh M. Impact of Radiofrequency Ablation on Malignant Biliary Strictures: Results of a Collaborative Registry. *Dig Dis Sci* 2015; **60**: 2164-2169 [PMID: 25701319 DOI: 10.1007/s10620-015-3558-3]
- 87 **Strand DS**, Cosgrove ND, Patrie JT, Cox DG, Bauer TW, Adams RB, Mann JA, Sauer BG, Shami VM, Wang AY. ERCP-directed radiofrequency ablation and photodynamic therapy are associated with comparable survival in the treatment of unresectable cholangiocarcinoma. *Gastrointest Endosc* 2014; **80**: 794-804 [PMID: 24836747 DOI: 10.1016/j.gie.2014.02.1030]
- 88 **Alis H**, Sengoz C, Gonenc M, Kalayci MU, Kocatay A. Endobiliary radiofrequency ablation for malignant biliary obstruction. *Hepatobiliary Pancreat Dis Int* 2013; **12**: 423-427 [PMID: 23924501 DOI: 10.1016/s1499-3872(13)60066-1]
- 89 **Zhang L**, Wang N, Shen Q, Cheng W, Qian GJ. Therapeutic efficacy of percutaneous radiofrequency ablation vs microwave ablation for hepatocellular carcinoma. *PLoS One* 2013; **8**: e76119 [PMID: 24146824 DOI: 10.1371/journal.pone.0076119]
- 90 **Kalra N**, Kang M, Duseja AK, Bhatia A, Singh V, Dhiman RK, Rajwanshi A, Chawla YK, Khandelwal N. Comparison of radiofrequency ablation alone and in combination with percutaneous ethanol injection for management of hepatocellular carcinoma. *Indian J Med Res* 2017; **146**: S30-S37 [PMID: 29578192 DOI: 10.4103/ijmr.IJMR_1812_15]
- 91 **Abdelaziz AO**, Abdelmaksoud AH, Nabeel MM, Shousha HI, Cordie AA, Mahmoud SH, Medhat E, Omran D, Elbaz TM. Transarterial Chemoembolization Combined with Either Radiofrequency or Microwave Ablation in Management of Hepatocellular Carcinoma Asian Pac J Cancer Prev 2017; **18**: 189-194 [PMID: 28240516 DOI: 10.22034/apjcp.2017.18.1.189]
- 92 **Györi GP**, Felsenreich DM, Silberhumer GR, Soliman T, Berlakovich GA. Multimodality locoregional treatment strategies for bridging HCC patients before liver transplantation. *Eur Surg* 2017; **49**: 236-243 [PMID: 29104589 DOI: 10.1007/s10353-017-0487-8]
- 93 **Hao Y**, Numata K, Ishii T, Fukuda H, Maeda S, Nakano M, Tanaka K. Rate of local tumor progression following radiofrequency ablation of pathologically early hepatocellular carcinoma. *World J Gastroenterol* 2017; **23**: 3111-3121 [PMID: 28533668 DOI: 10.3748/wjg.v23.i17.3111]
- 94 **Santambrogio R**, Barabino M, Bruno S, Mariani N, Maroni N, Bertolini E, Franceschelli G, Opocher E. Surgical Resection vs Ablative Therapies Through a Laparoscopic Approach for Hepatocellular Carcinoma: a Comparative Study. *J Gastrointest Surg* 2018; **22**: 650-660 [PMID: 29235004 DOI: 10.1007/s11605-017-3648-y]



Published by **Baishideng Publishing Group Inc**
7041 Koll Center Parkway, Suite 160, Pleasanton, CA 94566, USA

Telephone: +1-925-3991568

E-mail: bpgoffice@wjgnet.com

Help Desk: <https://www.f6publishing.com/helpdesk>

<https://www.wjgnet.com>

