

# World Journal of *Gastrointestinal Oncology*

*World J Gastrointest Oncol* 2024 January 15; 16(1): 1-250



## EDITORIAL

- 1 Present situation and prospect of immunotherapy for unresectable locally advanced esophageal cancer during peri-radiotherapy  
*Wang FM, Mo P, Yan X, Lin XY, Fu ZC*
- 8 Early gastric cancer recurrence after endoscopic submucosal dissection: Not to be ignored!  
*Zeng Y, Yang J, Zhang JW*

## REVIEW

- 13 New trends in diagnosis and management of gallbladder carcinoma  
*Pavlidis ET, Galanis IN, Pavlidis TE*

## ORIGINAL ARTICLE

## Clinical and Translational Research

- 30 Mechanism of pachymic acid in the treatment of gastric cancer based on network pharmacology and experimental verification  
*Du YH, Zhao JJ, Li X, Huang SC, Ning N, Chen GQ, Yang Y, Nan Y, Yuan L*

## Retrospective Cohort Study

- 51 Trends in colorectal cancer incidence according to an increase in the number of colonoscopy cases in Korea  
*Kim GH, Lee YC, Kim TJ, Hong SN, Chang DK, Kim YH, Yang DH, Moon CM, Kim K, Kim HG, Kim ER*

## Retrospective Study

- 61 C-reactive protein to albumin ratio predict responses to programmed cell death-1 inhibitors in hepatocellular carcinoma patients  
*Li BB, Chen LJ, Lu SL, Lei B, Yu GL, Yu SP*
- 79 Impact of propofol and sevoflurane anesthesia on cognition and emotion in gastric cancer patients undergoing radical resection  
*Li AH, Bu S, Wang L, Liang AM, Luo HY*
- 90 Development and validation of a machine learning-based early prediction model for massive intraoperative bleeding in patients with primary hepatic malignancies  
*Li J, Jia YM, Zhang ZL, Liu CY, Jiang ZW, Hao ZW, Peng L*
- 102 Comparative study between Embosphere® and Marine gel® as embolic agents for chemoembolization of hepatocellular carcinoma  
*Kim HC, Choi JW*

- 110 Clinical value of oral contrast-enhanced ultrasonography in diagnosis of gastric tumors

*Wang CY, Fan XJ, Wang FL, Ge YY, Cai Z, Wang W, Zhou XP, Du J, Dai DW*

#### Observational Study

- 118 Prognostic significance and relationship of SMAD3 phospho-isoforms and VEGFR-1 in gastric cancer: A clinicopathological study

*Lv SL, Guo P, Zou JR, Chen RS, Luo LY, Huang DQ*

- 133 Colonoscopy plays an important role in detecting colorectal neoplasms in patients with gastric neoplasms

*Liu XR, Wen ZL, Liu F, Li ZW, Liu XY, Zhang W, Peng D*

#### Basic Study

- 144 Analysis of the potential biological value of pyruvate dehydrogenase E1 subunit  $\beta$  in human cancer

*Rong Y, Liu SH, Tang MZ, Wu ZH, Ma GR, Li XF, Cai H*

- 182 Colorectal cancer's burden attributable to a diet high in processed meat in the Belt and Road Initiative countries

*Liu G, Li CM, Xie F, Li QL, Liao LY, Jiang WJ, Li XP, Lu GM*

#### SYSTEMATIC REVIEWS

- 197 Comprehensive analysis of the role of ubiquitin-specific peptidases in colorectal cancer: A systematic review

*Al-Balushi E, Al Marzouqi A, Tavoosi S, Baghsheikhi AH, Sadri A, Aliabadi LS, Salarabedi MM, Rahman SA, Al-Yateem N, Jarrahi AM, Halimi A, Ahmadvand M, Abdel-Rahman WM*

#### META-ANALYSIS

- 214 Application of neoadjuvant chemoradiotherapy and neoadjuvant chemotherapy in curative surgery for esophageal cancer: A meta-analysis

*Yuan MX, Cai QG, Zhang ZY, Zhou JZ, Lan CY, Lin JB*

#### CASE REPORT

- 234 Emerging role of liquid biopsy in rat sarcoma virus mutated metastatic colorectal cancer: A case report

*Gramaça J, Fernandes IG, Trabulo C, Gonçalves J, dos Santos RG, Baptista A, Pina I*

- 244 Comprehensive evaluation of rare case: From diagnosis to treatment of a sigmoid Schwannoma: A case report

*Li JY, Gao XZ, Zhang J, Meng XZ, Cao YX, Zhao K*

**ABOUT COVER**

Editorial Board Member of *World Journal of Gastrointestinal Oncology*, Wael M Abdel-Rahman, MD, PhD, Full Professor, Chairman, Department of Medical Laboratory Sciences, College of Health Sciences and Research Institute of Medical and Health Sciences, University of Sharjah, Sharjah 27272, United Arab Emirates. whassan@sharjah.ac.ae

**AIMS AND SCOPE**

The primary aim of *World Journal of Gastrointestinal Oncology* (WJGO, *World J Gastrointest Oncol*) is to provide scholars and readers from various fields of gastrointestinal oncology with a platform to publish high-quality basic and clinical research articles and communicate their research findings online.

WJGO mainly publishes articles reporting research results and findings obtained in the field of gastrointestinal oncology and covering a wide range of topics including liver cell adenoma, gastric neoplasms, appendiceal neoplasms, biliary tract neoplasms, hepatocellular carcinoma, pancreatic carcinoma, cecal neoplasms, colonic neoplasms, colorectal neoplasms, duodenal neoplasms, esophageal neoplasms, gallbladder neoplasms, etc.

**INDEXING/ABSTRACTING**

The WJGO is now abstracted and indexed in PubMed, PubMed Central, Science Citation Index Expanded (SCIE, also known as SciSearch®), Journal Citation Reports/Science Edition, Scopus, Reference Citation Analysis, China Science and Technology Journal Database, and Superstar Journals Database. The 2023 edition of Journal Citation Reports® cites the 2022 impact factor (IF) for WJGO as 3.0; IF without journal self cites: 2.9; 5-year IF: 3.0; Journal Citation Indicator: 0.49; Ranking: 157 among 241 journals in oncology; Quartile category: Q3; Ranking: 58 among 93 journals in gastroenterology and hepatology; and Quartile category: Q3. The WJGO's CiteScore for 2022 is 4.1 and Scopus CiteScore rank 2022: Gastroenterology is 71/149; Oncology is 197/366.

**RESPONSIBLE EDITORS FOR THIS ISSUE**

Production Editor: Xiang-Di Zhang; Production Department Director: Xiang Li; Editorial Office Director: Jia-Ru Fan.

**NAME OF JOURNAL**

*World Journal of Gastrointestinal Oncology*

**ISSN**

ISSN 1948-5204 (online)

**LAUNCH DATE**

February 15, 2009

**FREQUENCY**

Monthly

**EDITORS-IN-CHIEF**

Monjur Ahmed, Florin Burada

**EDITORIAL BOARD MEMBERS**

<https://www.wjgnet.com/1948-5204/editorialboard.htm>

**PUBLICATION DATE**

January 15, 2024

**COPYRIGHT**

© 2023 Baishideng Publishing Group Inc

**INSTRUCTIONS TO AUTHORS**

<https://www.wjgnet.com/bpg/gerinfo/204>

**GUIDELINES FOR ETHICS DOCUMENTS**

<https://www.wjgnet.com/bpg/GerInfo/287>

**GUIDELINES FOR NON-NATIVE SPEAKERS OF ENGLISH**

<https://www.wjgnet.com/bpg/gerinfo/240>

**PUBLICATION ETHICS**

<https://www.wjgnet.com/bpg/GerInfo/288>

**PUBLICATION MISCONDUCT**

<https://www.wjgnet.com/bpg/gerinfo/208>

**ARTICLE PROCESSING CHARGE**

<https://www.wjgnet.com/bpg/gerinfo/242>

**STEPS FOR SUBMITTING MANUSCRIPTS**

<https://www.wjgnet.com/bpg/GerInfo/239>

**ONLINE SUBMISSION**

<https://www.f6publishing.com>



## Emerging role of liquid biopsy in rat sarcoma virus mutated metastatic colorectal cancer: A case report

João Gramaça, Isabel Gomes Fernandes, Carolina Trabulo, Joana Gonçalves, Rita Gameiro dos Santos, Adriano Baptista, Idília Pina

**Specialty type:** Oncology

**Provenance and peer review:**

Unsolicited article; Externally peer reviewed.

**Peer-review model:** Single blind

**Peer-review report's scientific quality classification**

Grade A (Excellent): 0

Grade B (Very good): B

Grade C (Good): C

Grade D (Fair): 0

Grade E (Poor): 0

**P-Reviewer:** Gao W, China; Wu HT, China

**Received:** July 27, 2023

**Peer-review started:** July 27, 2023

**First decision:** September 5, 2023

**Revised:** September 28, 2023

**Accepted:** November 8, 2023

**Article in press:** November 8, 2023

**Published online:** January 15, 2024



**João Gramaça**, Centro Hospitalar Barreiro Montijo, Centro Hospitalar Barreiro Montijo, Setúbal, Barreiro 2830-003, Portugal

**Isabel Gomes Fernandes, Carolina Trabulo, Joana Gonçalves, Rita Gameiro dos Santos, Adriano Baptista, Idília Pina**, Medical Oncology Unit, Centro Hospitalar Barreiro Montijo, Setúbal, Barreiro 2830-003, Portugal

**Corresponding author:** João Gramaça, MD, Doctor, Centro Hospitalar Barreiro Montijo, Centro Hospitalar Barreiro Montijo, Avenida Movimento das Forças Armadas, Setúbal, Barreiro 2830-003, Portugal. [jgramaca@gmail.com](mailto:jgramaca@gmail.com)

### Abstract

#### BACKGROUND

In patients with metastatic colorectal cancer (mCRC), the treatment options are limited and have been proved to be affected by rat sarcoma virus (RAS) mutational status. In RAS wild-type (wt) patients, the combination of anti-epidermal growth factor receptor (EGFR) monoclonal antibodies with chemotherapy (CT) is more effective than CT alone. On the other hand, RAS-mutated patients are not eligible for treatment with anti-EGFR antibodies.

#### CASE SUMMARY

Eleven patients with initially RAS-mutated mCRC were followed from diagnosis to May 2022. At the time of cell-free DNA determination, five patients had undergone one CT line, five patients had undergone two CT lines, and one patient had undergone three CT lines (all in combination with bevacizumab). At the second and third treatment lines [second line (2L), third line (3L)], patients with neo-RAS wt received a combination of CT and cetuximab. In neo-RAS wt patients treated with anti-EGFR, our findings indicated an increase in progression-free survival for both 2L and 3L (14.5 mo,  $P = 0.119$  and 3.9 mo,  $P = 0.882$ , respectively). Regarding 2L overall survival, we registered a slight increase in neo-RAS wt patients treated with anti-EGFR (33.6 mo *vs* 32.4 mo,  $P = 0.385$ ). At data cut-off, two patients were still alive: A RAS-mutated patient undergoing 3L treatment and a neo-RAS wt patient who received 2L treatment with anti-EGFR (ongoing).

#### CONCLUSION

Our case series demonstrated that monitoring RAS mutations in mCRC by liquid biopsy may provide an additional treatment line for neo-RAS wt patients.

**Key Words:** Metastatic colorectal cancer; Rat sarcoma virus mutational status; Liquid biopsy; Rat sarcoma virus wild-type; Neo-rat sarcoma virus wild-type; Anti-epidermal growth factor receptor therapy; Case report

©The Author(s) 2024. Published by Baishideng Publishing Group Inc. All rights reserved.

**Core Tip:** In patients with metastatic colorectal cancer (mCRC), the treatment options are limited and have been proved to be affected by rat sarcoma virus (RAS) mutational status. This manuscript describes a series of 11 RAS-mutated mCRC patients who were treated with a combination of chemotherapy and bevacizumab at first line. Four patients became neo-RAS wild-type after first or second line treatment and were treated with cetuximab, with advantages in terms of survival and disease progression.

**Citation:** Gramaça J, Fernandes IG, Trabulo C, Gonçalves J, dos Santos RG, Baptista A, Pina I. Emerging role of liquid biopsy in rat sarcoma virus mutated metastatic colorectal cancer: A case report. *World J Gastrointest Oncol* 2024; 16(1): 234-243

**URL:** <https://www.wjgnet.com/1948-5204/full/v16/i1/234.htm>

**DOI:** <https://dx.doi.org/10.4251/wjgo.v16.i1.234>

## INTRODUCTION

Data provided by the World Health Organization indicates that colorectal cancer (CRC) was ranked as the third most prevalent cancer globally in 2020, with over two million documented cases, and was the second leading contributor to cancer-related fatalities, resulting in approximately one million deaths annually[1,2]. Approximately 15% to 30% of patients have metastatic disease at presentation and about 20% to 50% will develop metastatic disease in the future, most of them with rat sarcoma virus (RAS)-mutated tumours[3-5].

In general, patients with metastatic CRC (mCRC) have limited treatment options and certain cases are candidates for primary surgery with metastasectomy, with or without systemic treatment. Current evidence demonstrates that the combination of chemotherapy (CT) with anti-epidermal growth factor receptor (EGFR) monoclonal antibodies, such as cetuximab and panitumumab, is more effective than CT alone, in RAS wild-type (wt) mCRC patients that are non-mutated at disease presentation[6]. However, RAS-mutated patients are not eligible for treatment with anti-EGFR antibodies[7,8] and, at this point, a systemic molecularly targeted treatment has not been approved for these patients[9].

Considering that the presence of RAS mutations will determine the treatment pathway, enabling more personalized treatments, the European Society for Medical Oncology (ESMO) guidelines recommend RAS gene testing in mCRC tissue or liquid biopsy (LB) as a mandatory prerequisite prior to treatment with anti-EGFR antibodies[3]. It has been hypothesized that tumour heterogeneity is related to the limited prognosis of mCRC, presenting a significant obstacle to the efficacy of current cancer therapy[10]. After the first cycles of CT treatment of RAS-mutated mCRC patients, RAS-mutated alleles disappear, with conversion to RAS wt in 20% to 80% of patients[4,6,11]. LB with evaluation of cell-free DNA (cfDNA) has shown to be an adequate tool to monitor the conversion of RAS mutant mCRC into RAS wt (Neo-RAS wt)[12]; in accordance, ESMO guidelines recommend testing not only prior to anti-EGFR treatment but also after two lines of treatment. Furthermore, even though data are still scarce, Neo-RAS wt patients seem to benefit from anti-EGFR treatment[6,13,14] and, as such, a deeper understanding of the mechanisms and clinical implications of this possibility is warranted. In this case series, we retrospectively analyzed a series of 11 patients with mCRC who were studied in terms of RAS mutational state by LB, aiming to evaluate the impact of the collected data on the therapeutic decision, progression-free survival (PFS), and overall survival (OS).

## CASE PRESENTATION

### Chief complaints

Eleven patients with mCRC, who were included in the Digestive Tumours consultation of our hospital, were followed since diagnosis to May 2022 (Table 1). All the patients were initially RAS-mutated. The median age was 66 years (50-77) and 18.2% were female.

All the analyzed primary tumours were v-raf murine sarcoma viral oncogene homolog B1 (BRAF) wt and had microsatellite stability; none of them had neurotrophic tropomyosin-receptor kinase (NTRK) rearrangements. Regarding immunochemistry-determined human epidermal growth factor receptor 2 (HER2) overexpression, 27.3% had +1 expression, 27.3% were non-determined, and 45.5% had 0 expression. In terms of differentiation grade, 45.5% were grade 2 and 54.5% were grade 1.

In this series, 54.5% of the patients had stage IV *de novo* disease while 45.5% had stage IV relapsed disease after localized disease treatment. Regarding primary tumour location, 36.4% of the patients had right-side disease and 63.6% had left-side disease (including rectal cancer).



**Table 1 Clinical information of the 11 patients at baseline**

Case	Age	Gender	mCRC location	RAS Mutation	AA change	Histological grade	Metastasis	Presentation at baseline
Case 1	70	Female	Left colon	c.38G>A p. (Gly13Asp) KRAS	KRAS G13D	2	Lung, peritoneal	Relapse
Case 2	62	Male	Right colon	p.Ala146Thr/Val/Pro (c.436G>C; c.436G>A; c.437C>T) KRAS	KRAS A146T/V/P	1	Liver	Relapse
Case 3	61	Male	Rectal	c.34G>T p. (Gly12Cys) KRAS	KRAS G12C	2	Lung	Relapse
Case 4	65	Female	Right colon	c.181C>A p. (Gln61Lys) NRAS	NRAS Q61K	1	Lung, peritoneal	De novo
Case 5	52	Male	Rectal	c.35G>A p. (Gly12Asp) KRAS	KRAS G12D	2	Lung, liver	Relapse
Case 6	66	Male	Rectal	c.38G>A p. (Gly13Asp) KRAS	KRAS G13D	1	Liver	De novo
Case 7	69	Male	Rectal	c.436G>A (p.Ala146Thr) NRAS A146T	NRAS A146T	1	Lung, liver	De novo
Case 8	50	Male	Right colon	c.34G>T p. (Gly12Cys) KRAS	KRAS G12C	2	Lung, bone CNS	Relapse
Case 9	77	Male	Right colon	c.35G>A p. (Gly12Asp) KRAS	KRAS G12D	1	Liver, peritoneal, suprarenal	De novo
Case 10	67	Male	Left colon	c.35G>T p. (Gly12Val) KRAS	KRAS G12V	1	Lung	De novo
Case 11	68	Male	Left colon	c.35G>T p. (Gly12Val) KRAS	KRAS G12V	2	Liver	De novo

mCRC: Metastatic colorectal cancer; KRAS: Kirsten rat sarcoma viral oncogene homolog; RAS: Rat sarcoma virus.

### History of present illness

The basic clinical characteristics of our patients are outlined in Table 1. Despite the absence of symptoms, Case 1 had relapsed disease, with lung and peritoneal metastasis. The patient had slow progressive disease, with progression under first line (1L) treatment in the lung, peritoneal cavity, and left adrenal gland; at this point, the patient was Neo-RAS wt. In this context, the patient started CT and anti-EGFR therapy; the latter was suspended after an ocular toxicity G3 Common Terminology Criteria of Adverse Events (CTCAE) v5.0 event. Despite this, the patient was kept on maintenance CT and showed a very long and sustained response. Case 2 had right-sided relapsed mCRC with liver metastasis. Although the patient became Neo-RAS wt after two lines of treatment, his response to anti-EGFR therapy and single-drug CT was weak. Case 7 had *de novo* rectal cancer with lung and liver metastasis, anorexia, fatigue, and bloody stools at presentation. The patient became Neo-RAS wt after one systemic treatment line; despite the very good clinical response, anti-EGFR therapy was suspended after two treatment cycles due to a cutaneous toxicity G2-3 CTCAE v5.0 event. Case 11 also had *de novo* left-sided mCRC and presented with a high tumour burden in the liver, with abdominal pain and hepatomegaly, both at presentation and progression under 1L.

### History of past illness

Cases 1 and 9 had a long-standing history of essential hypertension, for over 10 years. Case 1 also had hyperlipidaemia for the same period. Cases 10 and 11 had diabetes mellitus type 2 for over 5 years. In the remaining cases, past history did not present relevant events.

### Personal and family history

Personal and family histories did not retrieve significant mCRC related details.

### Laboratory examinations

All the analyzed primary tumours were RAS mutated, BRAF wt, and showed microsatellite stability; none of them had NTRK rearrangements. Regarding immunochemistry-determined HER2 overexpression, 27.3% of the patients had +1 expression, 27.3% were non-determined, and 45.5% had 0 expression. In terms of differentiation grade, 45.5% of the patients were grade 2 and 54.5% were grade 1. The LB study was performed on cfDNA from blood plasma collected in Streck tubes, obtained after centrifugation; samples were analyzed at an outside institution. The search for mutations in the Kirsten rat sarcoma viral oncogene homolog (KRAS) (NM\_033360.3) (codons 12, 13, 59 and 61), neuroblastoma rat sarcoma virus viral oncogene homolog (NRAS) (NM\_002524.4) (codons 12, 13, 59 and 61) and BRAF (MN\_004333.4) (codon 600) genes was performed through next-generation sequencing using the “Oncomine Lung cfDNA assay” (Ion Torrent™ Oncomine™ assays – Thermo Fisher Scientific). With a molecular coverage of 2500 ×, this method enables the

detection of mutations with an allelic fraction of up to 0.1%, with a sensitivity > 90% and specificity > 98% (*i.e.* it allows the detection of one copy of mutated DNA in 1000 copies of wt DNA). This method was validated by a third-party laboratory. In LB specimens, quality control values greater than 26 and 35.5 for KRAS and NRAS/BRAF, respectively, suggested low amounts of cfDNA and thus a negative result did not exclude the presence of mutations in these genes. In these cases, a new blood sample was collected.

### Imaging examinations

All patients had identifiable metastatic lesions evidenced by computed tomography, magnetic resonance imaging, or positron emission tomography-computed tomography. Regarding patients with Neo-RAS wt status, the best imaging response was partial response in one case, stable disease in two cases, and disease progression in one case. To illustrate, Case 11, who had liver-only metastasis, had a partial response at the first imaging evaluation, which was performed three mo after starting anti-EGFR therapy plus CT (Figure 1), with associated liver function improvement.

## FINAL DIAGNOSIS

In this series, 54.5% of the patients had stage IV *de novo* CRC, while 45.5% had stage IV relapsed CRC after localized disease treatment. All patients had KRAS or NRAS somatic mutation at treatment initiation and all underwent cfDNA determination after one or two lines of systemic treatment.

Regarding metastasis location, at the time of cfDNA determination, 63.6% of patients had liver metastasis, 27.3% had peritoneal involvement, and 63.6% had lung metastasis; of the latter, five patients had lung involvement without liver disease (Table 1).

## TREATMENT

At the time of cfDNA determination, five patients had undergone one CT line, five patients had undergone two CT lines, and one patient had undergone three CT lines. In 1L treatments, 90.9% of patients received oxaliplatin + capecitabine/oxaliplatin + folinic acid + fluorouracil and bevacizumab, with a median number of cycles of 9 (4-25); one patient was treated with irinotecan + folinic acid + fluorouracil and bevacizumab (Table 2).

Regarding treatment sequencing (Figure 2), most patients were treated with folinic acid + fluorouracil + irinotecan and bevacizumab in second line (2L), except for patients with Neo-RAS wt, who were treated with folinic acid + fluorouracil + irinotecan and cetuximab.

A Neo-RAS wt patient, who reached later treatment lines, was treated with folinic acid + fluorouracil + irinotecan and cetuximab in third line (3L). The majority of the remaining patients who received 3L treatment throughout follow-up were administered trifluridine/tipiracil in that setting.

## OUTCOME AND FOLLOW-UP

The study was approved by the Ethics Committee of Centro Hospitalar Barreiro Montijo. The study was implemented and conducted in accordance with the principles of the Declaration of Helsinki. Informed consent to publish this paper was obtained from all patients. Follow-up contacts were made during outpatient clinical appointments. When needed, certificates were requested.

We employed SPSS 22.0 software to perform statistical data description and analysis. OS was defined as the duration from the initial diagnosis to either death or loss to follow-up; PFS was defined as the time from CT to the occurrence of relapse, disease progression, death from any cause, or last follow-up assessment. OS and PFS were calculated using the Kaplan-Meier method and survival curves were drawn. To assess the differences in survival times among patients treated with various regimens, the log-rank method was used ( $P < 0.05$  was statistically significant).

### Survival analysis

Our series had a 1L median PFS of 7.29 mo. Of the 11 patients, 4 were Neo-RAS wt in the cfDNA analysis (36.4%), 3 of them after one treatment line and the other after two lines (Table 3). Table 4 provides information regarding allele frequencies on cfDNA analysis.

Focusing on clinical outcomes, despite the reduced number of patients in our series, our results showed a 2L PFS of 14.5 mo *vs* 9.3 mo (Neo-RAS wt treated with anti-EGFR in 2L line *vs* all other patients),  $P = 0.119$ . In the nine patients who received 3L treatment, the data showed a PFS of 3.9 mo *vs* 3.8 *vs* 5.1 (Neo-RAS wt treated with anti-EGFR in 3L *vs* RAS mutated *vs* previous Neo-RAS wt treated with anti-EGFR),  $P = 0.882$ . Regarding OS data after 2L line, we saw only a slight trend in favour of the Neo-RAS wt patients treated with anti-EGFR (33.6 mo *vs* 32.4 mo,  $P = 0.385$ ), statistically limited due to sample size. At data cut-off, two patients were still alive. One was a RAS-mutated patient undergoing 3L treatment and the other was a neo-RAS wt patient who received 2L treatment with anti-EGFR (ongoing).



**Table 2 Treatment strategy**

Case	1L	2L	3L	4L
Case 1	Oxaliplatin	Irinotecan	Irinotecan	NA <sup>3</sup>
	Folinic acid	Folinic acid	Folinic acid	
	Fluorouracil	Fluorouracil	Fluorouracil	
	Bevacizumab (7 cycles)	Cetuximab (30 cycles)	Bevacizumab (2 cycles)	
Case 2	Oxaliplatin	Irinotecan	Irinotecan	Trifluridine/tipiracil
	Capecitabine	Folinic acid	Folinic acid	
	Bevacizumab (4 cycles)	Fluorouracil Bevacizumab (4 cycles)	Fluorouracil Cetuximab (5 cycles)	
Case 3	Oxaliplatin	Irinotecan	Trifluridine/tipiracil (8 cycles)	Oxaliplatin
	Folinic acid	Folinic acid		Folinic acid
	Fluorouracil (8 cycles)	Fluorouracil Bevacizumab (30 cycles)		Fluorouracil
Case 4	Oxaliplatin	Irinotecan	Trifluridine/tipiracil (3 cycles)	Fluorouracil
	Folinic acid	Folinic acid		Bevacizumab
	Fluorouracil (23 cycles)	Fluorouracil Bevacizumab (12 cycles)		
Case 5	Oxaliplatin	Irinotecan	Trifluridine/tipiracil (4 cycles)	Oxaliplatin
	Folinic acid	Folinic acid		Bevacizumab
	Fluorouracil (12 cycles)	Fluorouracil Bevacizumab (11 cycles)		
Case 6	Oxaliplatin	Irinotecan	Trifluridine/tipiracil (2 cycles)	NA
	Folinic acid	Folinic acid		
	Fluorouracil	Fluorouracil		
	Bevacizumab (7 cycles)	Bevacizumab (21 cycles)		
Case 7	Oxaliplatin	Irinotecan	Trifluridine/tipiracil (5 cycles)	Oxaliplatin
	Folinic acid	Folinic acid		Capecitabine
	Fluorouracil	Fluorouracil		Bevacizumab
	Bevacizumab (9 cycles)	Cetuximab (16 cycles)		
Case 8	Oxaliplatin	Oxaliplatin	NA <sup>1</sup>	NA
	Folinic acid	Capecitabine		
	Fluorouracil	Bevacizumab (5 cycles)		
	Bevacizumab (12 cycles)			
Case 9	Oxaliplatin	Irinotecan	Trifluridine/tipiracil (4 cycles)	Oxaliplatin

	Capecitabine	Folinic acid		Capecitabine
	Bevacizumab	Fluorouracil		Bevacizumab
	(6 cycles)	Bevacizumab		
		(22 cycles)		
Case 10	Oxaliplatin	Irinotecan	Trifluridine/tipiracil (12 cycles)	NA
	Folinic acid	Folinic acid		
	Fluorouracil	Fluorouracil		
	Bevacizumab	Bevacizumab		
	(10 cycles)	(7 cycles)		
Case 11	Oxaliplatin	Irinotecan	NA <sup>2</sup>	NA
	Capecitabine	Folinic acid		
	Bevacizumab	Fluorouracil		
	(25 cycles)	Cetuximab		
		(8 cycles)		

<sup>1</sup>The patient had no conditions to change treatment.

<sup>2</sup>Stable disease.

<sup>3</sup>Death. 1L: First line; 2L: Second line; 3L: Third line; 4L: Fourth line; NA: Not applied.

**Table 3 Rat sarcoma virus mutation status and survival outcomes after second line and third line treatment**

Case	2L	PFS 2L (mo)	OS since 2L (mo)	3L	PFS 3L (mo)	OS since 3L (mo)
Case 1	Wild-type	35.86	46.61	Wild-type	6.21	9.96
Case 2	Mutated	3.54	33.57	Neo-RAS	3.86	29.50
Case 3	Mutated	24.39	44.82	Mutated	8.96	12.50
Case 4	Mutated	11.25	28.64	Mutated	3.79	16.39
Case 5	Mutated	9.29	34.61	Mutated	5.18	23.57
Case 6	Mutated	11.25	14.71	Mutated	2.29	2.29
Case 7	Wild-type	14.54	27.64	Wild-type	5.14	11.71
Case 8	Mutated	3.79	4.43	NA	NA	NA
Case 9	Mutated	18.96	32.39	Mutated	3.07	12.43
Case 10	Mutated	4.79	20.93	Mutated	12.93	12.93
Case 11	Wild-type	8.39	8.39	NA	NA	NA

1L: First line; 2L: Second line; 3L: Third line; NA: Not applied; PFS: Progression-free survival; OS: Overall survival; ND: Not determined as patients were kept on second line treatment due to absence of conditions to escalate treatment (Case 8) or to non-progressive disease (Case 11).

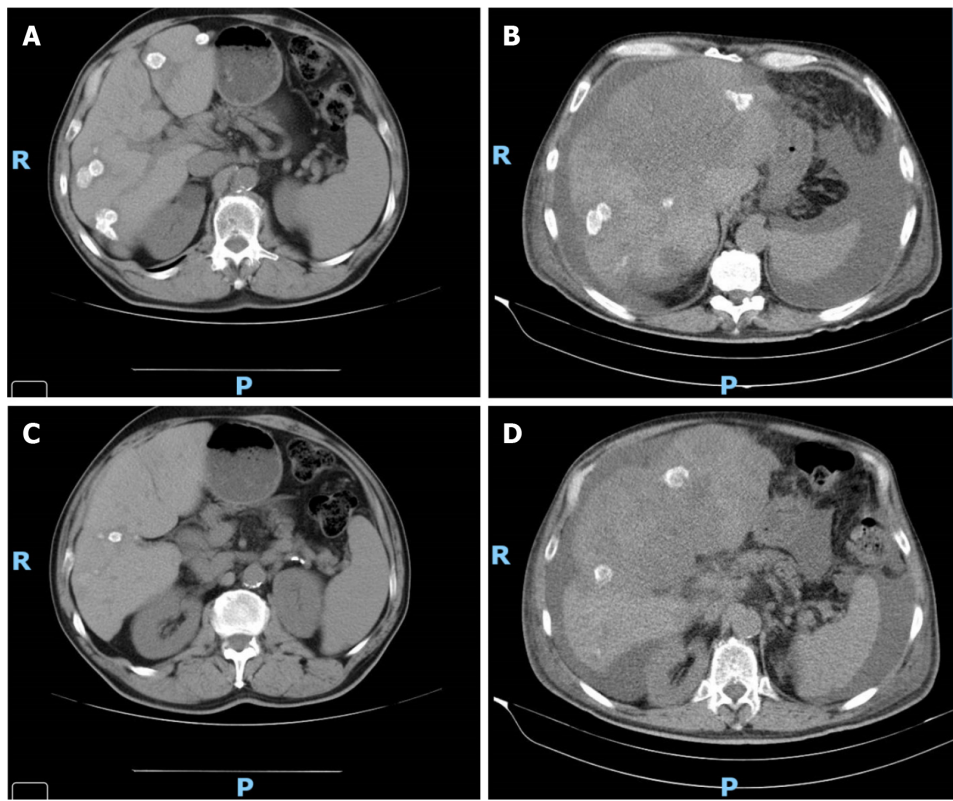
## DISCUSSION

Herein, we describe a series of 11 RAS-mutated mCRC patients who were treated with a combination of CT and bevacizumab at 1L. Four patients became neo-RAS wt after 1L or 2L treatment and were treated with cetuximab, with advantages in terms of survival and disease progression.

Detection of RAS mutations is essential for selection of the best treatment option for mCRC patients. These mutations lead to constitutive activation of GTPase KRAS, resulting in permanent activation of downstream signalling of EGFR. Recent genomic studies performed through LB in mCRC patients have revealed the disappearance of RAS mutant clones in plasma. The results of these studies provided the first evidence of an unforeseen negative selection of RAS mutations during the clonal evolution of mCRC, even early in mCRC treatment. As a proof-of-concept, Gazzaniga *et al*[13] described the case where a patient initially diagnosed with a primary RAS mutant mCRC switched to wt RAS status in plasma, following failure of 1L therapy; the patient underwent an anti-EGFR 2L treatment, which led to a sustained clinical improvement. Later, the analysis of a small series of patients also showed a degree of benefit with anti-EGFR treatment in

Table 4 Allele frequencies of rat sarcoma virus mutated patients	
Case	Allele frequency
Case 1	ND
Case 2	ND
Case 3	36.7
Case 4	20.4
Case 5	2.6
Case 6	12.4
Case 7	ND
Case 8	45.7
Case 9	54.8
Case 10	7.6
Case 11	ND

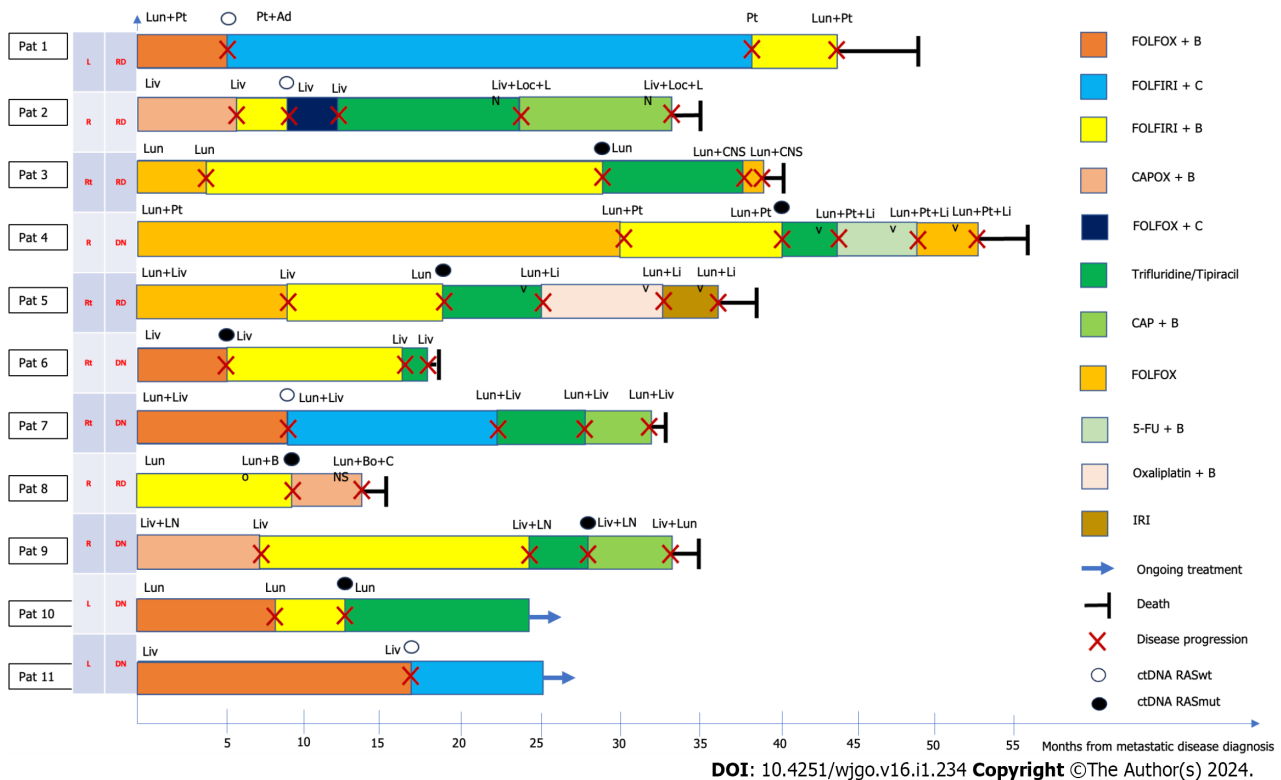
ND: Not determined.



DOI: 10.4251/wjgo.v16.i1.234 Copyright ©The Author(s) 2024.

**Figure 1** Imaging evaluation of Case 11. A: Imaging evaluation at baseline (July 2021), upper axial plane, [flat chemotherapy (CT) scan with IV contrast]; B: Imaging evaluation at 3 mo (October 2021, on the right) upper axial plane, (flat CT scan with IV contrast); C: Imaging evaluation at baseline (July 2021), lower axial plane, (flat CT scan with IV contrast); D: Imaging evaluation at 3 mo (October 2021), lower axial plane, (flat CT scan with IV contrast).

mCRC patients who were initially RAS-mutated and became RAS wt on LB, after one or more lines of treatment. For example, Raimondi *et al*[14] reported PFS of 12, 10, and 6 mo in three patients treated with 2L anti-EGFR; a patient treated with fourth line anti-EGFR showed a PFS of 4 mo. Bouchahda *et al*[6] reported nine neo-RAS wt patients (out of 16) who underwent treatment with anti-EGFR and CT, after a median of three CT protocols; the patients showed an objective tumour response rate of 50%, including one complete response and four partial responses, and a 1-year survival rate of 60%.



**Figure 2 Disease progression after second-line treatment.** 5-FU: 5-fluorouracil; Ad: Adrenal; B: Bevacizumab; Bo: Bone; C: Cetuximab; CAP: Capecitabine; CAPOX: Capecitabine + oxaliplatin; CNS: Central nervous system; ctDNA: Circulating DNA; DN: De novo disease; FOLFIRI: Folinic acid + fluorouracil + irinotecan; FOLFOX: Folinic acid + fluorouracil, and oxaliplatin; IRI: Irinotecan; Liv: Liver; Loc: Local; LN: Lymph node; Lun: Lung; Oxali: Oxaliplatin; Pat: Patient; Pt: Peritoneal; RASmut: RAS mutated; RASwt: RAS wild-type; RD: Relapsing disease; Rt: Rectum.

The proposed mechanism for the variable proportions of mutant and wt RAS clones throughout the clinical course of mCRC involves the existence of molecularly distinct subclones within the tumours. Under the stress applied by both the tumour microenvironment and therapies, these subclones continuously compete for space and resources[15]. In this scenario, a dynamic evaluation of the clonal evolution in blood may open new opportunities for treatment[4,16]. In fact, some patients may experience advantages from the use of cetuximab, after disease progression with treatment schemes with the same drug in previous treatment lines, as shown in RAS wt mCRC[17]. In our case series, we observed a lower incidence of Neo-RAS wt (36.4%) but encouraging results with the combination of anti-EGFR therapy and CT treatment, with a 2L PFS of 14.5 mo in Neo-RAS wt patients after one line of treatment. These patients presented with KRAS mutation and lung and/or liver metastasis at the start of treatment, of note, the patient without liver involvement had an adrenal lesion. The best outcomes were obtained in left-sided primary tumours; however, this shall be analyzed considering that the only right-sided tumour had the LB only after two lines of treatment. Even though in our series we observed limiting skin and ocular toxicity secondary to anti-EGFR treatment in half of the patients, this strategy appears to be effective and is in line with the results of other reports and with historical PFS values regarding 2L line treatment in mCRC[11].

## CONCLUSION

In RAS mutated mCRC patients, retesting RAS mutational status may be considered upon evident failure of standard-of-care regimens. To date, the ideal point in time to perform RAS retesting is unclear, but data regarding testing in earlier lines is promising. This strategy would allow different types of treatment in the continuum of care of a mCRC patient, as evidenced in our series. For further elucidation, prospective clinical trials are warranted. At this point, there are four prospective phase II trials ongoing; three of them are studying the efficacy of anti-EGFR therapy in Neo-RAS wt mCRC patients in earlier lines of treatment (the KAIROS trial[13], the ConVertex study[18] and the MoLiMoR study[11]). Before the publication of these results, our study evidenced the prevalence of Neo-RAS wt tumours in initially RAS-mutated mCRC, in a small subset of patients. It also validated the efficacy and safety of 2L anti-EGFR plus CT treatment in this subset of mCRC patients who converted to RAS wt at the time of first progression, translating a personalized and dynamic strategy.

In conclusion, our case series showed that guiding the evolution of RAS mutations in mCRC by LB may provide an additional treatment line for Neo-RAS wt patients in advanced disease phases, in which the available therapeutic options are limited.

## ACKNOWLEDGEMENTS

The authors would like to thank Paula Pinto, PharmD, PhD (PMA-Pharmaceutical Medicine Academy) for providing medical writing and editorial assistance.

## FOOTNOTES

**Author contributions:** Gramaça J and Pina I contributed to conceptualization and manuscript design; Gramaça J, Fernandes IG, Trabulo C, Gonçalves J, dos Santos RG and Baptista A contributed to data collection and interpretation; Gramaça J contributed to manuscript drafting; Gramaça J contributed to critical revision of the article.

**Informed consent statement:** Informed written consent was obtained from the patients for publication of this report and any accompanying images.

**Conflict-of-interest statement:** Dr. Gramaça reports non-financial support from Merck KGaA, Darmstadt, during the conduct of the study.

**CARE Checklist (2016) statement:** The authors have read the CARE Checklist (2016), and the manuscript was prepared and revised according to the CARE Checklist (2016).

**Open-Access:** This article is an open-access article that was selected by an in-house editor and fully peer-reviewed by external reviewers. It is distributed in accordance with the Creative Commons Attribution NonCommercial (CC BY-NC 4.0) license, which permits others to distribute, remix, adapt, build upon this work non-commercially, and license their derivative works on different terms, provided the original work is properly cited and the use is non-commercial. See: <https://creativecommons.org/licenses/by-nc/4.0/>

**Country/Territory of origin:** Portugal

**ORCID number:** João Gramaça 0000-0001-6968-0436.

**S-Editor:** Qu XL

**L-Editor:** Webster JR

**P-Editor:** Zhang XD

## REFERENCES

- 1 **World Health Organization.** Colorectal cancer [DOI: [10.1007/s11888-011-0094-1](https://doi.org/10.1007/s11888-011-0094-1)]
- 2 **Sung H, Ferlay J, Siegel RL, Laversanne M, Soerjomataram I, Jemal A, Bray F.** Global Cancer Statistics 2020: GLOBOCAN Estimates of Incidence and Mortality Worldwide for 36 Cancers in 185 Countries. *CA Cancer J Clin* 2021; **71**: 209-249 [PMID: [33538338](https://pubmed.ncbi.nlm.nih.gov/33538338/) DOI: [10.3322/caac.21660](https://doi.org/10.3322/caac.21660)]
- 3 **Cervantes A, Adam R, Roselló S, Arnold D, Normanno N, Taïeb J, Seligmann J, De Baere T, Osterlund P, Yoshino T, Martinelli E; ESMO Guidelines Committee.** Metastatic colorectal cancer: ESMO Clinical Practice Guideline for diagnosis, treatment and follow-up. *Ann Oncol* 2023; **34**: 10-32 [PMID: [36307056](https://pubmed.ncbi.nlm.nih.gov/36307056/) DOI: [10.1016/j.annonc.2022.10.003](https://doi.org/10.1016/j.annonc.2022.10.003)]
- 4 **Klein-Scory S, Wahner I, Maslova M, Al-Sewaidi Y, Pohl M, Mika T, Ladigan S, Schroers R, Baraniskina A.** Evolution of RAS Mutational Status in Liquid Biopsies During First-Line Chemotherapy for Metastatic Colorectal Cancer. *Front Oncol* 2020; **10**: 1115 [PMID: [32766143](https://pubmed.ncbi.nlm.nih.gov/32766143/) DOI: [10.3389/fonc.2020.01115](https://doi.org/10.3389/fonc.2020.01115)]
- 5 **Peeters M, Kafatos G, Taylor A, Gastanaga VM, Oliner KS, Hechmati G, Terwey JH, van Krieken JH.** Prevalence of RAS mutations and individual variation patterns among patients with metastatic colorectal cancer: A pooled analysis of randomised controlled trials. *Eur J Cancer* 2015; **51**: 1704-1713 [PMID: [26049686](https://pubmed.ncbi.nlm.nih.gov/26049686/) DOI: [10.1016/j.ejca.2015.05.017](https://doi.org/10.1016/j.ejca.2015.05.017)]
- 6 **Bouchahda M, Saffroy R, Karaboué A, Hamelin J, Innominato P, Saliba F, Lévi F, Bosselut N, Lemoine A.** Undetectable RAS-Mutant Clones in Plasma: Possible Implication for Anti-EGFR Therapy and Prognosis in Patients With RAS-Mutant Metastatic Colorectal Cancer. *JCO Precis Oncol* 2020; **4** [PMID: [33015528](https://pubmed.ncbi.nlm.nih.gov/33015528/) DOI: [10.1200/PO.19.00400](https://doi.org/10.1200/PO.19.00400)]
- 7 **Schirripa M, Cremolini C, Loupakakis F, Morvillo M, Bergamo F, Zoratto F, Salvatore L, Antoniotti C, Marmorino F, Sensi E, Lupi C, Fontanini G, De Gregorio V, Giannini R, Basolo F, Masi G, Falcone A.** Role of NRAS mutations as prognostic and predictive markers in metastatic colorectal cancer. *Int J Cancer* 2015; **136**: 83-90 [PMID: [24806288](https://pubmed.ncbi.nlm.nih.gov/24806288/) DOI: [10.1002/ijc.28955](https://doi.org/10.1002/ijc.28955)]
- 8 **Douillard JY, Oliner KS, Siena S, Tabernero J, Burkes R, Barugel M, Humblet Y, Bodoky G, Cunningham D, Jasssem J, Rivera F, Kocákova I, Ruff P, Błasińska-Morawiec M, Šmakal M, Canon JL, Rother M, Williams R, Rong A, Wietorek J, Sidhu R, Patterson SD.** Panitumumab-FOLFOX4 treatment and RAS mutations in colorectal cancer. *N Engl J Med* 2013; **369**: 1023-1034 [PMID: [24024839](https://pubmed.ncbi.nlm.nih.gov/24024839/) DOI: [10.1056/NEJMoa1305275](https://doi.org/10.1056/NEJMoa1305275)]
- 9 **Patelli G, Tosi F, Amatu A, Mauri G, Curaba A, Patané DA, Pani A, Scaglione F, Siena S, Sartore-Bianchi A.** Strategies to tackle RAS-mutated metastatic colorectal cancer. *ESMO Open* 2021; **6**: 100156 [PMID: [34044286](https://pubmed.ncbi.nlm.nih.gov/34044286/) DOI: [10.1016/j.esmoop.2021.100156](https://doi.org/10.1016/j.esmoop.2021.100156)]
- 10 **Siravegna G, Mussolin B, Buscarino M, Corti G, Cassingena A, Crisafulli G, Ponzetti A, Cremolini C, Amatu A, Lauricella C, Lamba S, Hobor S, Avallone A, Valtorta E, Rospo G, Medico E, Motta V, Antoniotti C, Tatangelo F, Bellosillo B, Veronese S, Budillon A, Montagut C, Racca P, Marsoni S, Falcone A, Corcoran RB, Di Nicolantonio F, Loupakakis F, Siena S, Sartore-Bianchi A, Bardelli A.** Clonal evolution and resistance to EGFR blockade in the blood of colorectal cancer patients. *Nat Med* 2015; **21**: 827 [PMID: [26151329](https://pubmed.ncbi.nlm.nih.gov/26151329/) DOI: [10.1038/nm0715-827b](https://doi.org/10.1038/nm0715-827b)]

- 11 **Osumi H**, Vecchione L, Keilholz U, Vollbrecht C, Alig AHS, von Einem JC, Stahler A, Striefler JK, Kurreck A, Kind A, Modest DP, Stintzing S, Jelas I. NeoRAS wild-type in metastatic colorectal cancer: Myth or truth?-Case series and review of the literature. *Eur J Cancer* 2021; **153**: 86-95 [PMID: 34153718 DOI: 10.1016/j.ejca.2021.05.010]
- 12 **Loree JM**, Strickler JH, Pereira AAL, Lam M, Raghav KPS, Morris VK, Menter D, Banks K, Nagy RJ, Raymond V, Overman MJ, Talasz A, Lanman RB, Kopetz S. Serial monitoring of ctDNA to highlight mutation profiles in colorectal cancer. *Journal of Clinical Oncology* 2018; **36**: 641 [DOI: 10.1200/jco.2018.36.4\_suppl.641]
- 13 **Gazzaniga P**, Raimondi C, Urbano F, Cortesi E. EGFR Inhibitor as Second-Line Therapy in a Patient With Mutant RAS Metastatic Colorectal Cancer: Circulating Tumor DNA to Personalize Treatment. *JCO Precis Oncol* 2018; **2**: 1-6 [PMID: 35135115 DOI: 10.1200/PO.17.00277]
- 14 **Raimondi C**, Nicolazzo C, Belardinilli F, Loreni F, Gradilone A, Mahdavian Y, Gelibter A, Giannini G, Cortesi E, Gazzaniga P. Transient Disappearance of RAS Mutant Clones in Plasma: A Counterintuitive Clinical Use of EGFR Inhibitors in RAS Mutant Metastatic Colorectal Cancer. *Cancers (Basel)* 2019; **11** [PMID: 30621206 DOI: 10.3390/cancers11010042]
- 15 **Russo M**, Crisafulli G, Sogari A, Reilly NM, Arena S, Lamba S, Bartolini A, Amodio V, Magri A, Novara L, Sarotto I, Nagel ZD, Pietti CG, Amatu A, Sartore-Bianchi A, Siena S, Bertotti A, Trusolino L, Corigliano M, Gherardi M, Lagomarsino MC, Di Nicolantonio F, Bardelli A. Adaptive mutability of colorectal cancers in response to targeted therapies. *Science* 2019; **366**: 1473-1480 [PMID: 31699882 DOI: 10.1126/science.aav4474]
- 16 **Goldberg RM**, Montagut C, Wainberg ZA, Ronga P, Audhuy F, Taieb J, Stintzing S, Siena S, Santini D. Optimising the use of cetuximab in the continuum of care for patients with metastatic colorectal cancer. *ESMO Open* 2018; **3**: e000353 [PMID: 29765773 DOI: 10.1136/esmoopen-2018-000353]
- 17 **Rossini D**, Cremolini C, Conca E, del Re M, Busico A, Pietrantonio F, Bergamo F, Danesi R, Cardellino G, Tamburini E, Dell'Aquila E, Strippoli A, Masi G, Tonini G, Negri F, Corsi D, Pella N, Intini R, Falcone A, Santini D. Liquid biopsy allows predicting benefit from rechallenge with cetuximab(cet)+irinotecan(iri) in RAS/BRAF wild-type mCRC patients(pts) with resistance to 1st-line cet+iri: Final results and translational analyses of the CRICKET study by GONO. *Annals of Oncology* 2018; **29**: v102 [DOI: 10.1093/annonc/mdy149.006]
- 18 **Fernández Montes A**, Martínez Lago N, de la Cámara Gómez J, Covela Rúa M, Cousillas Castiñeiras A, Gonzalez Villarroel P, Méndez Méndez J. FOLFIRI plus panitumumab as second-line treatment in mutated RAS metastatic colorectal cancer patients who converted to wild type RAS after receiving first-line FOLFOX/CAPOX plus bevacizumab-based treatment: Phase II CONVERTIX trial. *Annals of On* 2019; **29**: 23-24 [DOI: 10.1093/annonc/mdz155.088]





Published by **Baishideng Publishing Group Inc**  
7041 Koll Center Parkway, Suite 160, Pleasanton, CA 94566, USA

**Telephone:** +1-925-3991568

**E-mail:** [bpgoffice@wjgnet.com](mailto:bpgoffice@wjgnet.com)

**Help Desk:** <https://www.f6publishing.com/helpdesk>

<https://www.wjgnet.com>

