

World Journal of *Gastrointestinal Oncology*

World J Gastrointest Oncol 2024 March 15; 16(3): 571-1090



EDITORIAL

- 571 Synchronous gastric and colon cancers: Important to consider hereditary syndromes and chronic inflammatory disease associations
Shenoy S
- 577 Neutrophil-to-lymphocyte ratio and platelet-to-lymphocyte ratio: Markers predicting immune-checkpoint inhibitor efficacy and immune-related adverse events
Jiang QY, Xue RY
- 583 Early-onset gastrointestinal cancer: An epidemiological reality with great significance and implications
Triantafyllidis JK, Georgiou K, Konstadoulakis MM, Papalois AE

REVIEW

- 598 Management of obstructed colorectal carcinoma in an emergency setting: An update
Pavlidis ET, Galanis IN, Pavlidis TE
- 614 Unraveling the enigma: A comprehensive review of solid pseudopapillary tumor of the pancreas
Xu YC, Fu DL, Yang F

MINIREVIEWS

- 630 Roles and application of exosomes in the development, diagnosis and treatment of gastric cancer
Guan XL, Guan XY, Zhang ZY
- 643 Prognostic and predictive role of immune microenvironment in colorectal cancer
Kuznetsova O, Fedyanin M, Zavalishina L, Moskvina L, Kuznetsova O, Lebedeva A, Tryakin A, Kireeva G, Borshchev G, Tjulandin S, Ignatova E
- 653 Pylorus-preserving gastrectomy for early gastric cancer
Sun KK, Wu YY

ORIGINAL ARTICLE

Case Control Study

- 659 N-glycan biosignatures as a potential diagnostic biomarker for early-stage pancreatic cancer
Wen YR, Lin XW, Zhou YW, Xu L, Zhang JL, Chen CY, He J
- 670 Expression and significance of pigment epithelium-derived factor and vascular endothelial growth factor in colorectal adenoma and cancer
Yang Y, Wen W, Chen FL, Zhang YJ, Liu XC, Yang XY, Hu SS, Jiang Y, Yuan J

- 687 Impact of Alcian blue and periodic acid Schiff expression on the prognosis of gastric signet ring cell carcinoma

Lin J, Chen ZF, Guo GD, Chen X

Retrospective Cohort Study

- 699 Clinical profile and outcomes of hepatocellular carcinoma in primary Budd-Chiari syndrome

Agarwal A, Biswas S, Swaroop S, Aggarwal A, Agarwal A, Jain G, Elhence A, Vaidya A, Gupte A, Mohanka R, Kumar R, Mishra AK, Gamanagatti S, Paul SB, Acharya SK, Shukla A, Shalimar

- 716 Chinese herbal medicine decreases incidence of hepatocellular carcinoma in diabetes mellitus patients with regular insulin management

Lai HC, Cheng JC, Yip HT, Jeng LB, Huang ST

- 732 Combining systemic inflammatory response index and albumin fibrinogen ratio to predict early serious complications and prognosis after resectable gastric cancer

Ren JY, Wang D, Zhu LH, Liu S, Yu M, Cai H

- 750 Mucosa color and size may indicate malignant transformation of chicken skin mucosa-positive colorectal neoplastic polyps

Zhang YJ, Yuan MX, Wen W, Li F, Jian Y, Zhang CM, Yang Y, Chen FL

- 761 Epidemiology, therapy and outcome of hepatocellular carcinoma between 2010 and 2019 in Piedmont, Italy

Bracco C, Gallarate M, Badinella Martini M, Magnino C, D'Agnano S, Canta R, Racca G, Melchio R, Serraino C, Polla Mattiot V, Gollè G, Fenoglio L

- 773 Study on sex differences and potential clinical value of three-dimensional computerized tomography pelvimetry in rectal cancer patients

Zhou XC, Ke FY, Dhamija G, Chen H, Wang Q

Retrospective Study

- 787 High patatin like phospholipase domain containing 8 expression as a biomarker for poor prognosis of colorectal cancer

Zhou PY, Zhu DX, Chen YJ, Feng QY, Mao YH, Zhuang AB, Xu JM

- 798 Combining prognostic value of serum carbohydrate antigen 19-9 and tumor size reduction ratio in pancreatic ductal adenocarcinoma

Xia DQ, Zhou Y, Yang S, Li FF, Tian LY, Li YH, Xu HY, Xiao CZ, Wang W

- 810 Influence of transcatheter arterial embolization on symptom distress and fatigue in liver cancer patients

Yang XM, Yang XY, Wang XY, Gu YX

- 819 T2-weighted imaging-based radiomic-clinical machine learning model for predicting the differentiation of colorectal adenocarcinoma

Zheng HD, Huang QY, Huang QM, Ke XT, Ye K, Lin S, Xu JH

- 833 Predictive value of positive lymph node ratio in patients with locally advanced gastric remnant cancer

Zhuo M, Tian L, Han T, Liu TF, Lin XL, Xiao XY

- 844 Risk of cardiovascular death in patients with hepatocellular carcinoma based on the Fine-Gray model
Zhang YL, Liu ZR, Liu Z, Bai Y, Chi H, Chen DP, Zhang YM, Cui ZL
- 857 Preoperatively predicting vessels encapsulating tumor clusters in hepatocellular carcinoma: Machine learning model based on contrast-enhanced computed tomography
Zhang C, Zhong H, Zhao F, Ma ZY, Dai ZJ, Pang GD
- 875 Comparison of mismatch repair and immune checkpoint protein profile with histopathological parameters in pancreatic, peripapillary/ampullary, and choledochal adenocarcinomas
Aydin AH, Turhan N
- 883 Assessment of programmed death-ligand 1 expression in primary tumors and paired lymph node metastases of gastric adenocarcinoma
Coimbra BC, Pereira MA, Cardili L, Alves VAF, de Mello ES, Ribeiro U Jr, Ramos MFKP

Observational Study

- 894 Identification of breath volatile organic compounds to distinguish pancreatic adenocarcinoma, pancreatic cystic neoplasm, and patients without pancreatic lesions
Tiankanon K, Pungpipattrakul N, Sukaram T, Chaiteerakij R, Rerknimitr R
- 907 Clinical features and prognostic factors of duodenal neuroendocrine tumours: A comparative study of ampullary and nonampullary regions
Fang S, Shi YP, Wang L, Han S, Shi YQ

Clinical and Translational Research

- 919 Construction of an immune-related gene signature for overall survival prediction and immune infiltration in gastric cancer
Ma XT, Liu X, Ou K, Yang L
- 933 Clinical efficacy and pathological outcomes of transanal endoscopic intersphincteric resection for low rectal cancer
Xu ZW, Zhu JT, Bai HY, Yu XJ, Hong QQ, You J
- 945 Identification of a novel inflammatory-related gene signature to evaluate the prognosis of gastric cancer patients
Hu JL, Huang MJ, Halina H, Qiao K, Wang ZY, Lu JJ, Yin CL, Gao F

Basic Study

- 968 Verteporfin fluorescence in antineoplastic-treated pancreatic cancer cells found concentrated in mitochondria
Zhang YQ, Liu QH, Liu L, Guo PY, Wang RZ, Ba ZC
- 979 Effects of *Helicobacter pylori* and Moluodan on the Wnt/ β -catenin signaling pathway in mice with precancerous gastric cancer lesions
Wang YM, Luo ZW, Shu YL, Zhou X, Wang LQ, Liang CH, Wu CQ, Li CP

- 991** Mitochondrial carrier homolog 2 increases malignant phenotype of human gastric epithelial cells and promotes proliferation, invasion, and migration of gastric cancer cells
Zhang JW, Huang LY, Li YN, Tian Y, Yu J, Wang XF
- 1006** Ubiquitin-specific protease 21 promotes tumorigenicity and stemness of colorectal cancer by deubiquitinating and stabilizing ZEB1
Lin JJ, Lu YC
- 1019** Long non-coding RNA GATA6-AS1 is mediated by N6-methyladenosine methylation and inhibits the proliferation and metastasis of gastric cancer
Shen JJ, Li MC, Tian SQ, Chen WM
- 1029** CALD1 facilitates epithelial-mesenchymal transition progression in gastric cancer cells by modulating the PI3K-Akt pathway
Ma WQ, Miao MC, Ding PA, Tan BB, Liu WB, Guo S, Er LM, Zhang ZD, Zhao Q

META-ANALYSIS

- 1046** Efficacy and safety of perioperative therapy for locally resectable gastric cancer: A network meta-analysis of randomized clinical trials
Kuang ZY, Sun QH, Cao LC, Ma XY, Wang JX, Liu KX, Li J

SCIENTOMETRICS

- 1059** Insights into the history and tendency of glycosylation and digestive system tumor: A bibliometric-based visual analysis
Jiang J, Luo Z, Zhang RC, Wang YL, Zhang J, Duan MY, Qiu ZJ, Huang C

CASE REPORT

- 1076** Managing end-stage carcinoid heart disease: A case report and literature review
Bulj N, Tomasic V, Cigrovski Berkovic M
- 1084** Hemorrhagic cystitis in gastric cancer after nanoparticle albumin-bound paclitaxel: A case report
Zhang XJ, Lou J

ABOUT COVER

Peer Review of *World Journal of Gastrointestinal Oncology*, Noha Elkady, MD, Assistant Professor, Department of Pathology, Faculty of Medicine Menoufia University, Shibin Elkom 32511, Egypt. drnohaelkady@gmail.com

AIMS AND SCOPE

The primary aim of *World Journal of Gastrointestinal Oncology* (WJGO, *World J Gastrointest Oncol*) is to provide scholars and readers from various fields of gastrointestinal oncology with a platform to publish high-quality basic and clinical research articles and communicate their research findings online.

WJGO mainly publishes articles reporting research results and findings obtained in the field of gastrointestinal oncology and covering a wide range of topics including liver cell adenoma, gastric neoplasms, appendiceal neoplasms, biliary tract neoplasms, hepatocellular carcinoma, pancreatic carcinoma, cecal neoplasms, colonic neoplasms, colorectal neoplasms, duodenal neoplasms, esophageal neoplasms, gallbladder neoplasms, *etc.*

INDEXING/ABSTRACTING

The WJGO is now abstracted and indexed in PubMed, PubMed Central, Science Citation Index Expanded (SCIE, also known as SciSearch®), Journal Citation Reports/Science Edition, Scopus, Reference Citation Analysis, China Science and Technology Journal Database, and Superstar Journals Database. The 2023 edition of Journal Citation Reports® cites the 2022 impact factor (IF) for WJGO as 3.0; IF without journal self cites: 2.9; 5-year IF: 3.0; Journal Citation Indicator: 0.49; Ranking: 157 among 241 journals in oncology; Quartile category: Q3; Ranking: 58 among 93 journals in gastroenterology and hepatology; and Quartile category: Q3. The WJGO's CiteScore for 2022 is 4.1 and Scopus CiteScore rank 2022: Gastroenterology is 71/149; Oncology is 197/366.

RESPONSIBLE EDITORS FOR THIS ISSUE

Production Editor: Xiang-Di Zhang; Production Department Director: Xiang Li; Editorial Office Director: Jia-Ru Fan.

NAME OF JOURNAL

World Journal of Gastrointestinal Oncology

ISSN

ISSN 1948-5204 (online)

LAUNCH DATE

February 15, 2009

FREQUENCY

Monthly

EDITORS-IN-CHIEF

Monjur Ahmed, Florin Burada

EDITORIAL BOARD MEMBERS

<https://www.wjgnet.com/1948-5204/editorialboard.htm>

PUBLICATION DATE

March 15, 2024

COPYRIGHT

© 2024 Baishideng Publishing Group Inc

INSTRUCTIONS TO AUTHORS

<https://www.wjgnet.com/bpg/gerinfo/204>

GUIDELINES FOR ETHICS DOCUMENTS

<https://www.wjgnet.com/bpg/GerInfo/287>

GUIDELINES FOR NON-NATIVE SPEAKERS OF ENGLISH

<https://www.wjgnet.com/bpg/gerinfo/240>

PUBLICATION ETHICS

<https://www.wjgnet.com/bpg/GerInfo/288>

PUBLICATION MISCONDUCT

<https://www.wjgnet.com/bpg/gerinfo/208>

ARTICLE PROCESSING CHARGE

<https://www.wjgnet.com/bpg/gerinfo/242>

STEPS FOR SUBMITTING MANUSCRIPTS

<https://www.wjgnet.com/bpg/GerInfo/239>

ONLINE SUBMISSION

<https://www.f6publishing.com>



Hemorrhagic cystitis in gastric cancer after nanoparticle albumin-bound paclitaxel: A case report

Xin-Jie Zhang, Jian Lou

Specialty type: Oncology

Provenance and peer review:

Unsolicited article; Externally peer reviewed.

Peer-review model: Single blind

Peer-review report's scientific quality classification

Grade A (Excellent): 0
Grade B (Very good): B
Grade C (Good): C
Grade D (Fair): 0
Grade E (Poor): 0

P-Reviewer: Ghannam WM, Egypt;
Tangsuwanaruk T, Thailand

Received: December 24, 2023

Peer-review started: December 24, 2023

First decision: January 10, 2024

Revised: January 18, 2024

Accepted: January 27, 2024

Article in press: January 27, 2024

Published online: March 15, 2024



Xin-Jie Zhang, Jian Lou, Department of Cancer Center, The Fifth Affiliated Hospital of Wenzhou Medical University, Lishui 323000, Zhejiang Province, China

Corresponding author: Jian Lou, MM, Chief Physician, Department of Cancer Center, The Fifth Affiliated Hospital of Wenzhou Medical University, No. 289 Kuocang Road, Liandu District, Lishui 323000, Zhejiang Province, China. 19994454@qq.com

Abstract

BACKGROUND

The advanced first-line regimen for advanced gastric cancer is based on a combination of fluoropyrimidine and platinum and/or paclitaxel (PTX), forming a two- or three-drug regimen. Compared to conventional PTX, nanoparticle albumin-bound PTX (Nab-PTX) has better therapeutic effects and fewer adverse effects reported in studies. Nab-PTX is a great option for patients presenting with advanced gastric cancer. Herein, we highlight an adverse event (hemorrhagic cystitis) of Nab-PTX in advanced gastric cancer.

CASE SUMMARY

A 55-year-old male was diagnosed with lymph node metastasis after a laparoscopic-assisted radical gastrectomy for gastric cancer that was treated by Nab-PTX and S-1 (AS). On the 15th day after treatment with AS, he was diagnosed with hemorrhagic cystitis.

CONCLUSION

Physicians should be aware that hemorrhagic cystitis is a potential adverse event associated with Nab-PTX treatment.

Key Words: Nanoparticle albumin-bound paclitaxel; Hemorrhagic cystitis; Gastric cancer; Adverse event; Case report

©The Author(s) 2024. Published by Baishideng Publishing Group Inc. All rights reserved.

Core Tip: Chemotherapy is an important treatment method for advanced gastric cancer. Up to now, nanoparticle albumin-bound paclitaxel (Nab-PTX) has shown promising responses in advanced gastric cancer. We aim to draw attention to a rarely treatment-related adverse event after Nab-PTX.

Citation: Zhang XJ, Lou J. Hemorrhagic cystitis in gastric cancer after nanoparticle albumin-bound paclitaxel: A case report. *World J Gastrointest Oncol* 2024; 16(3): 1084-1090

URL: <https://www.wjgnet.com/1948-5204/full/v16/i3/1084.htm>

DOI: <https://dx.doi.org/10.4251/wjgo.v16.i3.1084>

INTRODUCTION

There were approximately 1089103 new cases of gastric cancer and 768693 gastric cancer-related deaths in 2020, making gastric cancer the 5th most common cancer worldwide and the 4th leading cause of death[1]. Due to the difficulty in diagnosing early-stage gastric cancer, patients with advanced gastric cancer often have metastases, resulting in poor treatment outcomes and a 5-year survival rate < 10% [2]. Current treatments for advanced gastric cancer include radiotherapy, chemotherapy, immunotherapy, and targeted therapy. Moreover, fluoropyrimidine, platinum, and paclitaxel (PTX) are the main therapeutic drugs for advanced gastric cancer. Usually, the advanced first-line regimen is based on a combination of fluoropyrimidine and platinum and/or PTX, forming a two- or three-drug regimen[3]. PTX is a compound extracted from *Taxus chinensis* that promotes the assembly of microtubule proteins into microtubules, prevents microtubule dissociation, blocks cell cycle progression, prevents mitosis, and inhibits cancer cell growth[4]. Nanoparticle albumin-bound PTX (Nab-PTX) has a 33% greater uptake in tumors than PTX[5]. Nab-PTX is rapidly dissolved and released after entering the bloodstream and exists in the form of free PTX and albumin-bound PTX complexes. The vast majority of Nab-PTX complexes enter the intercellular matrix through active transportation and binds to the Sparc protein expressed in tumor tissues. Nab-PTX is enriched in tumor tissues to exert anti-tumor effects with relative targeting[6]. Moreover, Nab-PTX does not contain solvents, such as ethanol and polyoxyethylene castor oil, so steroids or antihistamines can prevent allergic reactions and can be used in patients with an alcohol allergy.

The combination of Nab-PTX and S-1 (AS), an oral 5-FU derivative, has been reported to have a synergistic anti-tumor effect in preclinical mouse models[7]. In a phase III non-inferiority clinical study of advanced gastric cancer, the median overall survival of patients treated with Nab-PTX was not inferior to PTX[8]. In a multicenter, randomized, phase III clinical study on advanced gastric cancer, the efficacy of Nab-PTX combined with S-1 was compared to oxaliplatin combined with S-1 (SOX). The results showed a median progression-free survival of 9.03 months in the AS group and 5.07 months in the SOX group. Of note, the study was discontinued due to slow enrollment and a change in treatment strategies; however, the mid-term results indicated that progression-free survival after AS treatment was superior to SOX treatment[9]. The most common adverse events reported in Nab-PTX clinical trials are like conventional PTX and include bone marrow suppression, sensory neuropathy, hair loss, and fatigue[8,9].

CASE PRESENTATION

Chief complaints

A 55-year-old male presented to the hospital with hemorrhagic cystitis after chemotherapy.

History of present illness

Over the past 2 wk, the patient experienced worsening frequency, urgency, and dysuria with gross hematuria.

History of past illness

The patient had a history of cystitis in 2021.

Personal and family history

The patient denied any family history of malignant tumors.

Physical examination

The physical examination revealed normal vital signs.

Laboratory examinations

The urine routine showed a 1+ white blood cell count, 3+ occult blood count, and 4+ red blood cell count. No abnormalities were detected on routine blood analyses. The urine bacterial culture showed no bacterial growth and acid-fast staining was negative for bacteria. A tuberculosis-specific enzyme-linked immunospot assay (T-SPOT.TB) examination showed negative results. No malignant cells were detected in the urine cytologic evaluation.

Imaging examinations

An abdominal enhanced computer tomography (CT) scan revealed thickening of the gastric wall near the lesser curvature of the stomach and ulcerations, suggesting a malignant tumor on December 25, 2020 (Figure 1A).

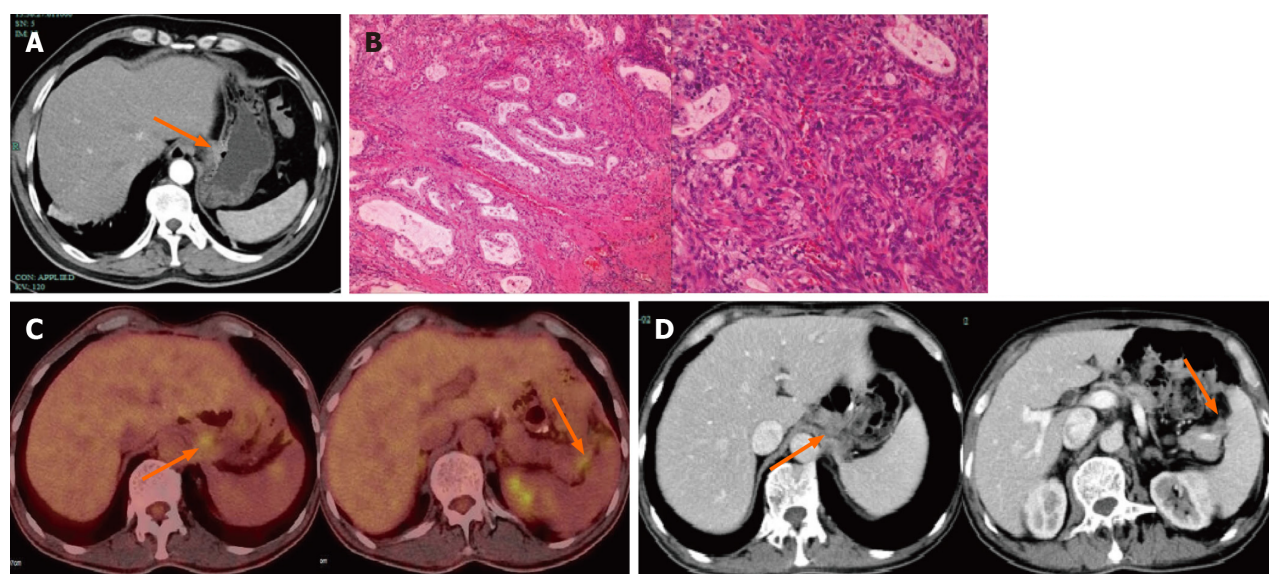


Figure 1 Computed tomography scans taken before and after treatment and Pathology of surgical specimens after total gastrectomy. A: Enhanced computed tomography (CT) scan of the abdomen before surgery: Thickening of the gastric wall near the lesser curvature of the stomach and formation of ulcers; B: Pathology of surgical specimens after total gastrectomy: Histological type: moderately differentiated adenocarcinoma; Lauren's classification: Intestinal type; Infiltration depth: Infiltration to the sub-serosal layer, involving nerves; C: Abdominal lymph node metastasis positron emission tomography-CT: Enlarged lymph nodes in the left upper peritoneum and splenic and pancreatic space; D: Enhanced CT scan of the abdomen after 6 cycles of treatment: Lymph node reduction compared to before treatment. The orange arrows showed the location and range of the tumor.

The postoperative pathologic evaluation after a laparoscopic-assisted radical gastrectomy for gastric cancer performed on January 10, 2021 revealed that the histologic type was a moderately differentiated adenocarcinoma. Immunohistochemistry of omental adipose tissue revealed the following: P53+ (wild-type); Ki-67+ (approximately 40%); CerbB-2 (2+); MSH2+; MSH6+; PMS2+; MLH1+; S-100-; SALL4-; AFP±; SATB2-; CDX2-; and CK20± (Figure 1B). Staging of gastric cancer according to the 8th edition of the AJCC was as follows: T3N2M0, stage IIIA. The patient received six cycles of the SOX regimen [S-1 (60 mg po bid d1-d14) and oxaliplatin (150 mg d1)] after surgery. During this period, numbness and discomfort occurred in the hands and feet, suggesting peripheral neurotoxicity caused by oxaliplatin.

On April 27, 2023, a follow-up abdominal enhanced CT scan revealed multiple enlarged lymph nodes in the abdominal cavity. On May 3, 2023, a positron emission tomography-CT scan revealed enlarged lymph nodes in the left upper peritoneum and splenopancreatic space after gastric cancer surgery, with increased 18 F-fluorodeoxyglucose metabolism, suggesting metastasis (Figure 1C).

After surgery, fluorescence in situ hybridization for human epidermal growth factor receptor 2 was negative with no gene amplification. The tumor cell proportion score < 1% and programmed cell death ligand-1 programmed death ligand-1 Yielded the combined positive score < 1. On May 5, 2023, the first course of Nab-PTX (130 mg/m² on days 1 and 8) combined with S-1 chemotherapy (60 mg twice daily for 14 d) was initiated.

The patient developed bladder symptoms, including frequent urination, urgency, and pain, on the third day after treatment began but did not seek medical attention at that time. On the 5th day, he purchased levofloxacin tablets (500 mg qd orally for 1 wk) at a pharmacy because the symptoms persisted, but there was no improvement. Due to symptoms of cystitis, he did not return to the hospital to complete Nab-PTX chemotherapy on the 8th day. On the 12th day after treatment began, the patient had a consultation in the Urology Department. On the 15th day the frequency, urgency, and dysuria worsened with gross hematuria.

Cystoscopy revealed edema, inflammation, and bleeding of the bladder mucosa, suggesting hemorrhagic cystitis. The pathologic results of a biopsy under cystoscopy revealed chronic inflammation of the bladder mucosa with granulation tissue formation (Figure 2).

FINAL DIAGNOSIS

Hemorrhagic cystitis associated with Nab-PTX was the final diagnosis.

TREATMENT

Sustained-release mirabelon tablets and piperacillin sulbactam sodium were administered and the bladder was irrigated. Hemorrhagic cystitis was relieved 2 wk later.

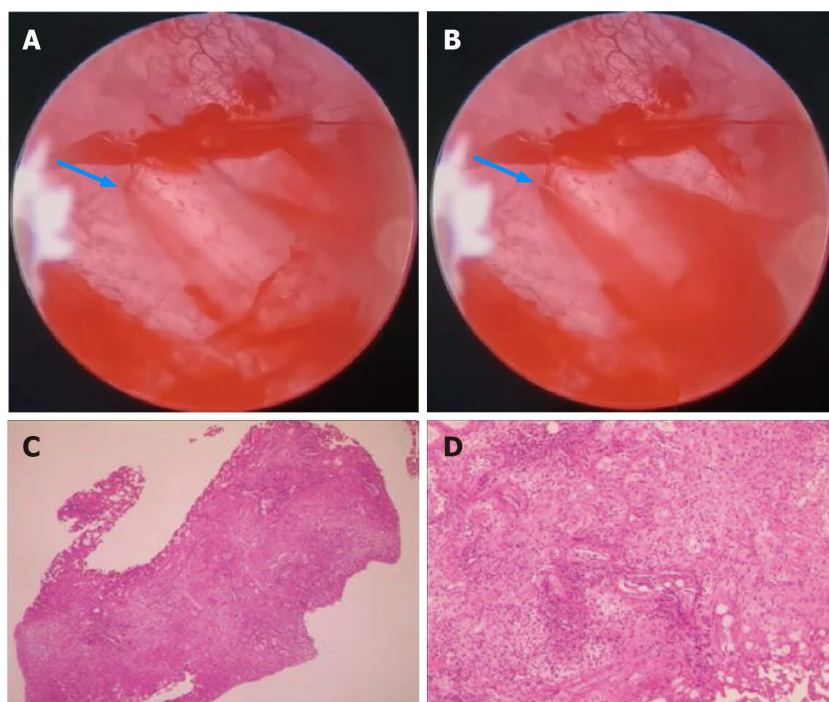


Figure 2 Cystoscopy and pathological results of biopsy under cystoscopy. A and B: Cystoscopy shows bleeding of the bladder mucosa (blue arrow); C and D: Pathological results of biopsy under cystoscopy showed that the lesion was tumor-free.

OUTCOME AND FOLLOW-UP

Considering the limited availability of drugs for advanced gastric cancer, the patient continued to receive 5 cycles Nab-PTX combined with S-1 chemotherapy. The bladder was protected with 2-mercaptoethane sodium sulfonate on the day of intravenous chemotherapy.

During the treatment period regular abdominal enhanced CT scans were performed. On August 31, 2023, an abdominal enhanced CT scan showed a reduction in the size of abdominal lymph nodes (Figure 1D). During the treatment period the patient had repeated episodes of frequent urination, urgency, and pain, but no hematuria was observed. After completing six cycles of Nab-PTX combined with S-1 chemotherapy, the patient underwent 25 sessions of radiation therapy on enlarged lymph nodes in the abdominal cavity and received synchronous oral chemotherapy with S-1. There was no further visual hematuria after radiotherapy, and the frequent urination, urgency, and pain improved significantly. A routine urinalysis revealed no white blood cells, red blood cells, or occult blood. The patient's treatment process is shown in Figure 3.

DISCUSSION

Nab-PTX is a cytotoxic drug used clinically for anti-tumor activity. Nab-PTX is widely used in solid tumors, such as breast, gastric, ovarian, pancreatic, and non-small cell lung cancers. Since 1992, PTX has been approved by the Food and Drug Administration (FDA) for the treatment of ovarian cancer and various forms, such as docetaxel, albumin-bound PTX, and liposome PTX, have been approved for cancer treatment. Clinical studies have shown that compared to conventional PTX, Nab-PTX exhibits good efficacy and safety[10].

The combination of oxaliplatin and fluoropyrimidine has a Class 1A level of evidence in the first-line treatment of advanced gastric cancer, making the oxaliplatin and fluoropyrimidine combination a first-line treatment for metastatic gastric cancer[3]. However, oxaliplatin has dose-limiting toxicity, and when the cumulative dose reaches 800 mg/m², oxaliplatin may cause permanent sensory abnormalities and functional impairment. In our case, the patient underwent six cycles of the SOX regimen followed by adjuvant chemotherapy after surgery and developed numbness in the hands and feet during the adjuvant treatment period, which persisted until recurrence and metastasis. Considering the better safety of Nab-PTX, we treated our patient with the AS chemotherapy regimen in the advanced frontline. The patient had previously received oral S-1 chemotherapy during adjuvant therapy, completing a total of 6 cycles without any symptoms of hemorrhagic cystitis. Moreover, after completion of a Nab-PTX intravenous infusion, the cystitis symptoms gradually improved during maintenance chemotherapy with S-1. Therefore, we are of the opinion that the hemorrhagic cystitis was mainly related to Nab-PTX. We use Naranjo's algorithm (adverse drug reaction probability scale) to evaluate the causality of adverse events of Nab-PTX. The total score was 8 points, which means that hemorrhagic cystitis probably caused by Nab-PTX.

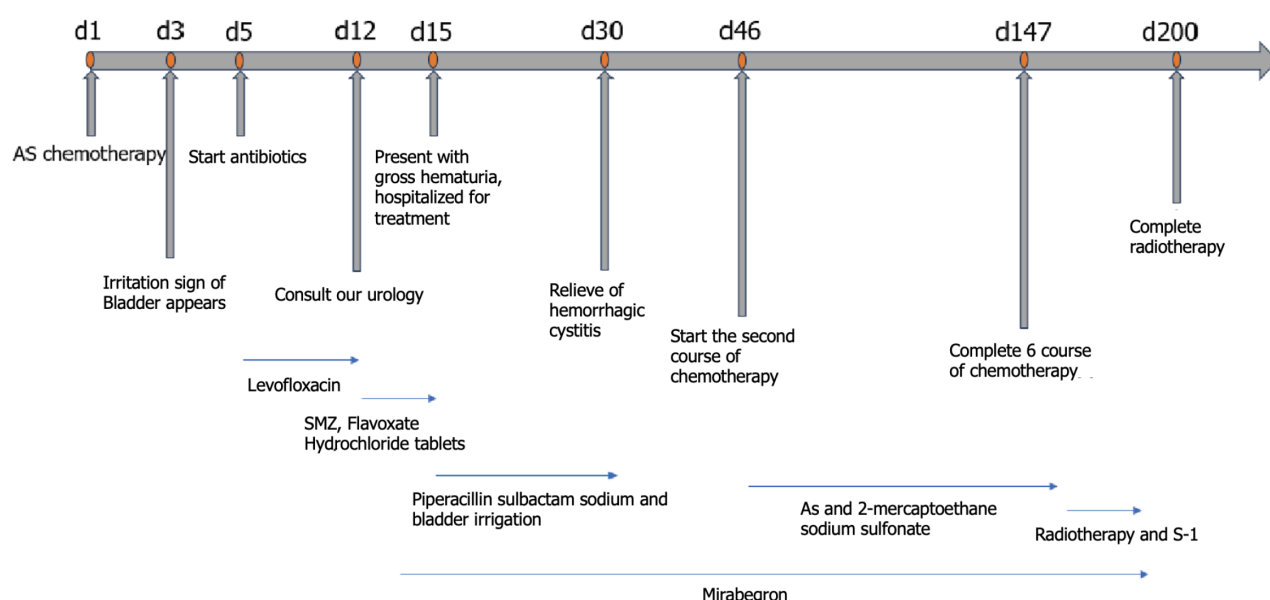


Figure 3 Timeline of chemotherapy, urologic symptoms, and concomitant treatment. SMZ: Sulfamethoxazole; AS: Nab-paclitaxel combined with S-1.

Hemorrhagic cystitis is a severe adverse event that can occur in cancer patients receiving cytotoxic drug treatment. The common symptoms include bleeding, frequent urination, urgency, and dysuria, which severely affect a patient's quality of life. Treatment mainly includes continuous bladder flushing, hydration, alkalization of urine with sodium bicarbonate, protection of bladder with sodium mesilate, and anti-infectives. It has also been reported that hyperbaric oxygen treatment temporarily alleviates hemorrhagic cystitis caused by cyclophosphamide in breast cancer patients[11].

In non-grassroots invasive bladder urothelial carcinoma, hemorrhagic cystitis is common in response to BCG and mitomycin C bladder infusion chemotherapy[12], which is caused by direct contact between bladder infusion chemotherapy and the bladder mucosa, leading to bladder mucosa damage. Hemorrhagic cystitis has been reported after chemotherapy with cyclophosphamide and ifosfamide, mainly related to the metabolite, acrolein[13], but there are few reports involving other chemotherapy drugs[14]. A 73-year-old male patient with prostate cancer developed hemorrhagic cystitis after receiving chemotherapy with docetaxel. After continuous bladder irrigation and fluid replacement, the condition improved after 2 wk[15]. A phase II clinical study using PTX combined with carboplatin in the treatment of advanced lung cancer reported that approximately 1% of patients developed hemorrhagic cystitis during treatment[16]. Wang and Liu[17] analyzed the adverse events of Nab-PTX using the United States FDA adverse event reporting system and identified 1659 adverse events, including 18 cases of urinary tract infections and no reported adverse events consistent with hemorrhagic cystitis. Only one case involving a 69-year-old breast cancer patient who received Nab-PTX chemotherapy developed hemorrhagic cystitis has been reported[14]. He improved after drug withdrawal, bladder irrigation, and oral glucocorticoid for 2 wk. Interestingly, the breast cancer patient had a history of cystitis, as occurred in our patient.

The mechanism underlying hemorrhagic cystitis caused by Nab-PTX is not clear. After entering the body, 94% of nab-PTX is bound to plasma proteins and 6% is unbound to PTX. Nab-PTX is mainly metabolized by CYP2C8 in liver microsomes, with < 1% metabolized by the kidneys. According to the pharmacokinetics and pharmacologic toxicity of Nab-PTX[18,19], we speculate that this may be related to oxidative stress, inflammatory response and disruption of the urothelial barrier, especially in patients with a history of cystitis. In conclusion, further research is needed to determine the mechanisms underlying the occurrence and development of hemorrhagic cystitis in patients treated with Nab-PTX.

CONCLUSION

Physicians should be aware that hemorrhagic cystitis is a potential adverse event associated with Nab-PTX treatment, especially in patients with a history of cystitis.

FOOTNOTES

Author contributions: Zhang XJ collected data and drafted the manuscript; Lou J revised and finalized the manuscript; all authors have read and approved the final manuscript.

Informed consent statement: Written informed consent was obtained from the patient for publication of this report and any

accompanying images.

Conflict-of-interest statement: All the authors report no relevant conflicts of interest for this article.

CARE Checklist (2016) statement: The authors have read the CARE Checklist (2016), and the manuscript was prepared and revised according to the CARE Checklist (2016).

Open-Access: This article is an open-access article that was selected by an in-house editor and fully peer-reviewed by external reviewers. It is distributed in accordance with the Creative Commons Attribution NonCommercial (CC BY-NC 4.0) license, which permits others to distribute, remix, adapt, build upon this work non-commercially, and license their derivative works on different terms, provided the original work is properly cited and the use is non-commercial. See: <https://creativecommons.org/licenses/by-nc/4.0/>

Country/Territory of origin: China

ORCID number: Xin-Jie Zhang 0009-0002-8906-140X; Jian Lou 0000-0002-5382-8173.

S-Editor: Fan JR

L-Editor: A

P-Editor: Zhang XD

REFERENCES

- 1 Sung H, Ferlay J, Siegel RL, Laversanne M, Soerjomataram I, Jemal A, Bray F. Global Cancer Statistics 2020: GLOBOCAN Estimates of Incidence and Mortality Worldwide for 36 Cancers in 185 Countries. *CA Cancer J Clin* 2021; **71**: 209-249 [PMID: 33538338 DOI: 10.3322/caac.21660]
- 2 Yang L, Ying X, Liu S, Lyu G, Xu Z, Zhang X, Li H, Li Q, Wang N, Ji J. Gastric cancer: Epidemiology, risk factors and prevention strategies. *Chin J Cancer Res* 2020; **32**: 695-704 [PMID: 33446993 DOI: 10.21147/j.issn.1000-9604.2020.06.03]
- 3 Wang FH, Zhang XT, Li YF, Tang L, Qu XJ, Ying JE, Zhang J, Sun LY, Lin RB, Qiu H, Wang C, Qiu MZ, Cai MY, Wu Q, Liu H, Guan WL, Zhou AP, Zhang YJ, Liu TS, Bi F, Yuan XL, Rao SX, Xin Y, Sheng WQ, Xu HM, Li GX, Ji JF, Zhou ZW, Liang H, Zhang YQ, Jin J, Shen L, Li J, Xu RH. The Chinese Society of Clinical Oncology (CSCO): Clinical guidelines for the diagnosis and treatment of gastric cancer, 2021. *Cancer Commun (Lond)* 2021; **41**: 747-795 [PMID: 34197702 DOI: 10.1002/cac2.12193]
- 4 Zhu L, Chen L. Progress in research on paclitaxel and tumor immunotherapy. *Cell Mol Biol Lett* 2019; **24**: 40 [PMID: 31223315 DOI: 10.1186/s11658-019-0164-y]
- 5 Chan DL, Sjoquist KM, Goldstein D, Price TJ, Martin AJ, Bang YJ, Kang YK, Pavlakakis N. The effect of anti-angiogenic agents on overall survival in metastatic oesophago-gastric cancer: A systematic review and meta-analysis. *PLoS One* 2017; **12**: e0172307 [PMID: 28222158 DOI: 10.1371/journal.pone.0172307]
- 6 Yardley DA. nab-Paclitaxel mechanisms of action and delivery. *J Control Release* 2013; **170**: 365-372 [PMID: 23770008 DOI: 10.1016/j.jconrel.2013.05.041]
- 7 Li JA, Xu XF, Han X, Fang Y, Shi CY, Jin DY, Lou WH. Nab-Paclitaxel Plus S-1 Shows Increased Antitumor Activity in Patient-Derived Pancreatic Cancer Xenograft Mouse Models. *Pancreas* 2016; **45**: 425-433 [PMID: 26495780 DOI: 10.1097/MPA.0000000000000501]
- 8 Shitara K, Takashima A, Fujitani K, Koeda K, Hara H, Nakayama N, Hironaka S, Nishikawa K, Makari Y, Amagai K, Ueda S, Yoshida K, Shimodaira H, Nishina T, Tsuda M, Kurokawa Y, Tamura T, Sasaki Y, Morita S, Koizumi W. Nab-paclitaxel versus solvent-based paclitaxel in patients with previously treated advanced gastric cancer (ABSOLUTE): an open-label, randomised, non-inferiority, phase 3 trial. *Lancet Gastroenterol Hepatol* 2017; **2**: 277-287 [PMID: 28404157 DOI: 10.1016/S2468-1253(16)30219-9]
- 9 Dai YH, Yu XJ, Xu HT, Zhuang L, Zhang MS, Zou YM, Fu Q, Qiu H, Yuan XL. Nab-paclitaxel plus S-1 versus oxaliplatin plus S-1 as first-line treatment in advanced gastric cancer: results of a multicenter, randomized, phase III trial (GAPSO study). *Ther Adv Med Oncol* 2022; **14**: 17588359221118020 [PMID: 35983025 DOI: 10.1177/17588359221118020]
- 10 Yoneshima Y, Morita S, Ando M, Miura S, Yoshioka H, Abe T, Kato T, Kondo M, Hosomi Y, Hotta K, Yamamoto N, Kishimoto J, Nakanishi Y, Okamoto I. Treatment Rationale and Design for J-AXEL: A Randomized Phase 3 Study Comparing Nab-Paclitaxel With Docetaxel in Patients With Previously Treated Advanced Non-Small-Cell Lung Cancer. *Clin Lung Cancer* 2017; **18**: 100-103 [PMID: 28341108 DOI: 10.1016/j.clcc.2016.08.003]
- 11 Tanaka T, Nakashima Y, Sasaki H, Masaki M, Mogi A, Tamura K, Takamatsu Y. Severe Hemorrhagic Cystitis Caused by Cyclophosphamide and Capecitabine Therapy in Breast Cancer Patients: Two Case Reports and Literature Review. *Case Rep Oncol* 2019; **12**: 69-75 [PMID: 31043944 DOI: 10.1159/000496331]
- 12 Shelley MD, Court JB, Kynaston H, Wilt TJ, Coles B, Mason M. Intravesical bacillus Calmette-Guerin versus mitomycin C for Ta and T1 bladder cancer. *Cochrane Database Syst Rev* 2003; CD003231 [PMID: 12917955 DOI: 10.1002/14651858.Cd003231]
- 13 Korkmaz A, Topal T, Oter S. Pathophysiological aspects of cyclophosphamide and ifosfamide induced hemorrhagic cystitis; implication of reactive oxygen and nitrogen species as well as PARP activation. *Cell Biol Toxicol* 2007; **23**: 303-312 [PMID: 17225077 DOI: 10.1007/s10565-006-0078-0]
- 14 Ichioka E, Iguchi-Manaka A, Oikawa T, Sawa A, Okazaki M, Saito T, Kiyomatsu H, Ikeda T, Bando H, Hara H. A case of hemorrhagic cystitis caused by nab-paclitaxel. *Int Cancer Conf J* 2016; **5**: 187-191 [PMID: 31149452 DOI: 10.1007/s13691-016-0255-9]
- 15 Ntekim AI, Ajekigbe A. Hemorrhagic cystitis in a patient receiving docetaxel for prostate cancer. *Clin Med Insights Oncol* 2010; **4**: 11-13 [PMID: 20567631 DOI: 10.4137/cmo.s4477]
- 16 Langer CJ, Leighton J, McAleer C, Comis R, O'Dwyer P, Ozols R. Paclitaxel and carboplatin in the treatment of advanced non-small cell lung cancer. *Semin Oncol* 1995; **22**: 64-69 [PMID: 7541156]
- 17 Wang Y, Liu X. Safety signals of albumin-bound paclitaxel: Data mining of the Food and Drug Administration adverse event reporting system.

- Indian J Pharmacol* 2023; **55**: 167-173 [PMID: 37555411 DOI: 10.4103/ijp.ijp_640_22]
- 18 **Liourdi D**, Kallidonis P, Kyriazis I, Tsamandas A, Karnabatidis D, Kitrou P, Spyroulias GA, Kostopoulou ON, Marousis K, Kalpaxis DL, Goumenos DS, Liatsikos E. Evaluation of the distribution of Paclitaxel by immunohistochemistry and nuclear magnetic resonance spectroscopy after the application of a drug-eluting balloon in the porcine ureter. *J Endourol* 2015; **29**: 580-589 [PMID: 25441059 DOI: 10.1089/end.2014.0683]
- 19 **Çomaklı S**, Özdemir S, Güloğlu M. Chrysin attenuates paclitaxel-induced hepatorenal toxicity in rats by suppressing oxidative damage, inflammation, and apoptosis. *Life Sci* 2023; **332**: 122096 [PMID: 37716503 DOI: 10.1016/j.lfs.2023.122096]



Published by **Baishideng Publishing Group Inc**
7041 Koll Center Parkway, Suite 160, Pleasanton, CA 94566, USA

Telephone: +1-925-3991568

E-mail: office@baishideng.com

Help Desk: <https://www.f6publishing.com/helpdesk>

<https://www.wjgnet.com>

