

World Journal of *Gastrointestinal Oncology*

World J Gastrointest Oncol 2024 March 15; 16(3): 571-1090



EDITORIAL

- 571 Synchronous gastric and colon cancers: Important to consider hereditary syndromes and chronic inflammatory disease associations
Shenoy S
- 577 Neutrophil-to-lymphocyte ratio and platelet-to-lymphocyte ratio: Markers predicting immune-checkpoint inhibitor efficacy and immune-related adverse events
Jiang QY, Xue RY
- 583 Early-onset gastrointestinal cancer: An epidemiological reality with great significance and implications
Triantafyllidis JK, Georgiou K, Konstadoulakis MM, Papalois AE

REVIEW

- 598 Management of obstructed colorectal carcinoma in an emergency setting: An update
Pavlidis ET, Galanis IN, Pavlidis TE
- 614 Unraveling the enigma: A comprehensive review of solid pseudopapillary tumor of the pancreas
Xu YC, Fu DL, Yang F

MINIREVIEWS

- 630 Roles and application of exosomes in the development, diagnosis and treatment of gastric cancer
Guan XL, Guan XY, Zhang ZY
- 643 Prognostic and predictive role of immune microenvironment in colorectal cancer
Kuznetsova O, Fedyanin M, Zavalishina L, Moskvina L, Kuznetsova O, Lebedeva A, Tryakin A, Kireeva G, Borshchev G, Tjulandin S, Ignatova E
- 653 Pylorus-preserving gastrectomy for early gastric cancer
Sun KK, Wu YY

ORIGINAL ARTICLE

Case Control Study

- 659 N-glycan biosignatures as a potential diagnostic biomarker for early-stage pancreatic cancer
Wen YR, Lin XW, Zhou YW, Xu L, Zhang JL, Chen CY, He J
- 670 Expression and significance of pigment epithelium-derived factor and vascular endothelial growth factor in colorectal adenoma and cancer
Yang Y, Wen W, Chen FL, Zhang YJ, Liu XC, Yang XY, Hu SS, Jiang Y, Yuan J

- 687 Impact of Alcian blue and periodic acid Schiff expression on the prognosis of gastric signet ring cell carcinoma

Lin J, Chen ZF, Guo GD, Chen X

Retrospective Cohort Study

- 699 Clinical profile and outcomes of hepatocellular carcinoma in primary Budd-Chiari syndrome

Agarwal A, Biswas S, Swaroop S, Aggarwal A, Agarwal A, Jain G, Elhence A, Vaidya A, Gupte A, Mohanka R, Kumar R, Mishra AK, Gamanagatti S, Paul SB, Acharya SK, Shukla A, Shalimar

- 716 Chinese herbal medicine decreases incidence of hepatocellular carcinoma in diabetes mellitus patients with regular insulin management

Lai HC, Cheng JC, Yip HT, Jeng LB, Huang ST

- 732 Combining systemic inflammatory response index and albumin fibrinogen ratio to predict early serious complications and prognosis after resectable gastric cancer

Ren JY, Wang D, Zhu LH, Liu S, Yu M, Cai H

- 750 Mucosa color and size may indicate malignant transformation of chicken skin mucosa-positive colorectal neoplastic polyps

Zhang YJ, Yuan MX, Wen W, Li F, Jian Y, Zhang CM, Yang Y, Chen FL

- 761 Epidemiology, therapy and outcome of hepatocellular carcinoma between 2010 and 2019 in Piedmont, Italy

Bracco C, Gallarate M, Badinella Martini M, Magnino C, D'Agnano S, Canta R, Racca G, Melchio R, Serraino C, Polla Mattiot V, Gollè G, Fenoglio L

- 773 Study on sex differences and potential clinical value of three-dimensional computerized tomography pelvimetry in rectal cancer patients

Zhou XC, Ke FY, Dhamija G, Chen H, Wang Q

Retrospective Study

- 787 High patatin like phospholipase domain containing 8 expression as a biomarker for poor prognosis of colorectal cancer

Zhou PY, Zhu DX, Chen YJ, Feng QY, Mao YH, Zhuang AB, Xu JM

- 798 Combining prognostic value of serum carbohydrate antigen 19-9 and tumor size reduction ratio in pancreatic ductal adenocarcinoma

Xia DQ, Zhou Y, Yang S, Li FF, Tian LY, Li YH, Xu HY, Xiao CZ, Wang W

- 810 Influence of transcatheter arterial embolization on symptom distress and fatigue in liver cancer patients

Yang XM, Yang XY, Wang XY, Gu YX

- 819 T2-weighted imaging-based radiomic-clinical machine learning model for predicting the differentiation of colorectal adenocarcinoma

Zheng HD, Huang QY, Huang QM, Ke XT, Ye K, Lin S, Xu JH

- 833 Predictive value of positive lymph node ratio in patients with locally advanced gastric remnant cancer

Zhuo M, Tian L, Han T, Liu TF, Lin XL, Xiao XY

- 844 Risk of cardiovascular death in patients with hepatocellular carcinoma based on the Fine-Gray model
Zhang YL, Liu ZR, Liu Z, Bai Y, Chi H, Chen DP, Zhang YM, Cui ZL
- 857 Preoperatively predicting vessels encapsulating tumor clusters in hepatocellular carcinoma: Machine learning model based on contrast-enhanced computed tomography
Zhang C, Zhong H, Zhao F, Ma ZY, Dai ZJ, Pang GD
- 875 Comparison of mismatch repair and immune checkpoint protein profile with histopathological parameters in pancreatic, peripapillary/ampullary, and choledochal adenocarcinomas
Aydin AH, Turhan N
- 883 Assessment of programmed death-ligand 1 expression in primary tumors and paired lymph node metastases of gastric adenocarcinoma
Coimbra BC, Pereira MA, Cardili L, Alves VAF, de Mello ES, Ribeiro U Jr, Ramos MFKP

Observational Study

- 894 Identification of breath volatile organic compounds to distinguish pancreatic adenocarcinoma, pancreatic cystic neoplasm, and patients without pancreatic lesions
Tiankanon K, Pungpipattrakul N, Sukaram T, Chaiteerakij R, Rerknimitr R
- 907 Clinical features and prognostic factors of duodenal neuroendocrine tumours: A comparative study of ampullary and nonampullary regions
Fang S, Shi YP, Wang L, Han S, Shi YQ

Clinical and Translational Research

- 919 Construction of an immune-related gene signature for overall survival prediction and immune infiltration in gastric cancer
Ma XT, Liu X, Ou K, Yang L
- 933 Clinical efficacy and pathological outcomes of transanal endoscopic intersphincteric resection for low rectal cancer
Xu ZW, Zhu JT, Bai HY, Yu XJ, Hong QQ, You J
- 945 Identification of a novel inflammatory-related gene signature to evaluate the prognosis of gastric cancer patients
Hu JL, Huang MJ, Halina H, Qiao K, Wang ZY, Lu JJ, Yin CL, Gao F

Basic Study

- 968 Verteporfin fluorescence in antineoplastic-treated pancreatic cancer cells found concentrated in mitochondria
Zhang YQ, Liu QH, Liu L, Guo PY, Wang RZ, Ba ZC
- 979 Effects of *Helicobacter pylori* and Moluodan on the Wnt/ β -catenin signaling pathway in mice with precancerous gastric cancer lesions
Wang YM, Luo ZW, Shu YL, Zhou X, Wang LQ, Liang CH, Wu CQ, Li CP

- 991** Mitochondrial carrier homolog 2 increases malignant phenotype of human gastric epithelial cells and promotes proliferation, invasion, and migration of gastric cancer cells
Zhang JW, Huang LY, Li YN, Tian Y, Yu J, Wang XF
- 1006** Ubiquitin-specific protease 21 promotes tumorigenicity and stemness of colorectal cancer by deubiquitinating and stabilizing ZEB1
Lin JJ, Lu YC
- 1019** Long non-coding RNA GATA6-AS1 is mediated by N6-methyladenosine methylation and inhibits the proliferation and metastasis of gastric cancer
Shen JJ, Li MC, Tian SQ, Chen WM
- 1029** CALD1 facilitates epithelial-mesenchymal transition progression in gastric cancer cells by modulating the PI3K-Akt pathway
Ma WQ, Miao MC, Ding PA, Tan BB, Liu WB, Guo S, Er LM, Zhang ZD, Zhao Q

META-ANALYSIS

- 1046** Efficacy and safety of perioperative therapy for locally resectable gastric cancer: A network meta-analysis of randomized clinical trials
Kuang ZY, Sun QH, Cao LC, Ma XY, Wang JX, Liu KX, Li J

SCIENTOMETRICS

- 1059** Insights into the history and tendency of glycosylation and digestive system tumor: A bibliometric-based visual analysis
Jiang J, Luo Z, Zhang RC, Wang YL, Zhang J, Duan MY, Qiu ZJ, Huang C

CASE REPORT

- 1076** Managing end-stage carcinoid heart disease: A case report and literature review
Bulj N, Tomasic V, Cigrovski Berkovic M
- 1084** Hemorrhagic cystitis in gastric cancer after nanoparticle albumin-bound paclitaxel: A case report
Zhang XJ, Lou J

ABOUT COVER

Peer Review of *World Journal of Gastrointestinal Oncology*, Noha Elkady, MD, Assistant Professor, Department of Pathology, Faculty of Medicine Menoufia University, Shibin Elkom 32511, Egypt. drnohaelkady@gmail.com

AIMS AND SCOPE

The primary aim of *World Journal of Gastrointestinal Oncology* (WJGO, *World J Gastrointest Oncol*) is to provide scholars and readers from various fields of gastrointestinal oncology with a platform to publish high-quality basic and clinical research articles and communicate their research findings online.

WJGO mainly publishes articles reporting research results and findings obtained in the field of gastrointestinal oncology and covering a wide range of topics including liver cell adenoma, gastric neoplasms, appendiceal neoplasms, biliary tract neoplasms, hepatocellular carcinoma, pancreatic carcinoma, cecal neoplasms, colonic neoplasms, colorectal neoplasms, duodenal neoplasms, esophageal neoplasms, gallbladder neoplasms, *etc.*

INDEXING/ABSTRACTING

The WJGO is now abstracted and indexed in PubMed, PubMed Central, Science Citation Index Expanded (SCIE, also known as SciSearch®), Journal Citation Reports/Science Edition, Scopus, Reference Citation Analysis, China Science and Technology Journal Database, and Superstar Journals Database. The 2023 edition of Journal Citation Reports® cites the 2022 impact factor (IF) for WJGO as 3.0; IF without journal self cites: 2.9; 5-year IF: 3.0; Journal Citation Indicator: 0.49; Ranking: 157 among 241 journals in oncology; Quartile category: Q3; Ranking: 58 among 93 journals in gastroenterology and hepatology; and Quartile category: Q3. The WJGO's CiteScore for 2022 is 4.1 and Scopus CiteScore rank 2022: Gastroenterology is 71/149; Oncology is 197/366.

RESPONSIBLE EDITORS FOR THIS ISSUE

Production Editor: Xiang-Di Zhang; Production Department Director: Xiang Li; Editorial Office Director: Jia-Ru Fan.

NAME OF JOURNAL

World Journal of Gastrointestinal Oncology

ISSN

ISSN 1948-5204 (online)

LAUNCH DATE

February 15, 2009

FREQUENCY

Monthly

EDITORS-IN-CHIEF

Monjur Ahmed, Florin Burada

EDITORIAL BOARD MEMBERS

<https://www.wjgnet.com/1948-5204/editorialboard.htm>

PUBLICATION DATE

March 15, 2024

COPYRIGHT

© 2024 Baishideng Publishing Group Inc

INSTRUCTIONS TO AUTHORS

<https://www.wjgnet.com/bpg/gerinfo/204>

GUIDELINES FOR ETHICS DOCUMENTS

<https://www.wjgnet.com/bpg/GerInfo/287>

GUIDELINES FOR NON-NATIVE SPEAKERS OF ENGLISH

<https://www.wjgnet.com/bpg/gerinfo/240>

PUBLICATION ETHICS

<https://www.wjgnet.com/bpg/GerInfo/288>

PUBLICATION MISCONDUCT

<https://www.wjgnet.com/bpg/gerinfo/208>

ARTICLE PROCESSING CHARGE

<https://www.wjgnet.com/bpg/gerinfo/242>

STEPS FOR SUBMITTING MANUSCRIPTS

<https://www.wjgnet.com/bpg/GerInfo/239>

ONLINE SUBMISSION

<https://www.f6publishing.com>



Case Control Study

Expression and significance of pigment epithelium-derived factor and vascular endothelial growth factor in colorectal adenoma and cancer

Ye Yang, Wu Wen, Feng-Lin Chen, Ying-Jie Zhang, Xiao-Cong Liu, Xiao-Yan Yang, Shan-Shan Hu, Ye Jiang, Jing Yuan

Specialty type: Gastroenterology and hepatology

Provenance and peer review:

Unsolicited article; Externally peer reviewed.

Peer-review model: Single blind

Peer-review report's scientific quality classification

Grade A (Excellent): 0
Grade B (Very good): B
Grade C (Good): 0
Grade D (Fair): 0
Grade E (Poor): 0

P-Reviewer: Šarenac TM, Serbia

Received: November 7, 2023

Peer-review started: November 7, 2023

First decision: December 31, 2023

Revised: January 16, 2024

Accepted: February 4, 2024

Article in press: February 4, 2024

Published online: March 15, 2024



Ye Yang, Digestive Diseases, Chengdu Qingbaijiang District People's Hospital, Chengdu 610300, Sichuan Province, China

Wu Wen, Ying-Jie Zhang, Xiao-Cong Liu, Xiao-Yan Yang, Shan-Shan Hu, Ye Jiang, Jing Yuan, Digestive Diseases, Chengdu Second People's Hospital, Chengdu 610000, Sichuan Province, China

Feng-Lin Chen, Graduate School, Chengdu Medical College, Chengdu 610000, Sichuan Province, China

Corresponding author: Wu Wen, Doctor, Chief Physician, Digestive Diseases, Chengdu Second People's Hospital, No. 10 Qingyunan Street, Jinjiang District, Chengdu 610000, Sichuan Province, China. wenwu2@qq.com

Abstract

BACKGROUND

The incidence and mortality of colorectal cancer (CRC) are among the highest in the world, and its occurrence and development are closely related to tumor neovascularization. When the balance between pigment epithelium-derived factors (PEDF) that inhibit angiogenesis and vascular endothelial growth factors (VEGF) that stimulate angiogenesis is broken, angiogenesis is out of control, resulting in tumor development. Therefore, it is very necessary to find more therapeutic targets for CRC for early intervention and later treatment.

AIM

To investigate the expression and significance of PEDF, VEGF, and CD31-stained microvessel density values (CD31-MVD) in normal colorectal mucosa, adenoma, and CRC.

METHODS

In this case-control study, we collected archived wax blocks of specimens from the Digestive Endoscopy Center and the General Surgery Department of Chengdu Second People's Hospital from April 2022 to October 2022. Fifty cases of specimen wax blocks were selected as normal intestinal mucosa confirmed by electronic colonoscopy and concurrent biopsy (normal control group), 50 cases of specimen

wax blocks were selected as colorectal adenoma confirmed by electronic colonoscopy and pathological biopsy (adenoma group), and 50 cases of specimen wax blocks were selected as CRC confirmed by postoperative pathological biopsy after inpatient operation of general surgery (CRC group). An immunohistochemical staining experiment was carried out to detect PEDF and VEGF expression in three groups of specimens, analyze their differences, study the relationship between the two and clinicopathological factors in CRC group, record CD31-MVD in the three groups, and analyze the correlation of PEDF, VEGF, and CD31-MVD in the colorectal adenoma group and the CRC group. The *F* test or adjusted *F* test is used to analyze measurement data statistically. Kruskal-Wallis rank sum test was used between groups for ranked data. The chi-square test, adjusted chi-square test, or Fisher's exact test were used to compare the rates between groups. All differences between groups were compared using the Bonferroni method for multiple comparisons. Spearman correlation analysis was used to test the correlation of the data. The test level (α) was 0.05, and a two-sided $P < 0.05$ was considered statistically significant.

RESULTS

The positive expression rate and expression intensity of PEDF were gradually decreased in the normal control group, adenoma group, and CRC group (100% *vs* 78% *vs* 50%, $\chi^2 = 34.430$, $P < 0.001$; ++~++ *vs* +~++ *vs* ~+, $H = 94.059$, $P < 0.001$), while VEGF increased gradually (0% *vs* 68% *vs* 96%, $\chi^2 = 98.35$, $P < 0.001$; - *vs* ~+ *vs* ++~++, $H = 107.734$, $P < 0.001$). In the CRC group, the positive expression rate of PEDF decreased with the increase of differentiation degree, invasion depth, lymph node metastasis, distant metastasis, and TNM stage ($\chi^2 = 20.513, 4.160, 5.128, 6.349, 5.128$, $P < 0.05$); the high expression rate of VEGF was the opposite ($\chi^2 = 10.317, 13.134, 17.643, 21.844, 17.643$, $P < 0.05$). In the colorectal adenoma group, the expression intensity of PEDF correlated negatively with CD31-MVD ($r = -0.601$, $P < 0.001$), whereas VEGF was not significantly different ($r = 0.258$, $P = 0.07$). In the CRC group, the expression intensity of PEDF correlated negatively with the expression intensity of CD31-MVD and VEGF ($r = -0.297$, $P < 0.05$; $r = -0.548$, $P < 0.05$), while VEGF expression intensity was positively related to CD31-MVD ($r = 0.421$, $P = 0.002$).

CONCLUSION

It is possible that PEDF can be used as a new treatment and prevention target for CRC by upregulating the expression of PEDF while inhibiting the expression of VEGF.

Key Words: Pigment epithelium-derived factors; Vascular endothelial growth factor; Microvessel density; Colorectal adenoma; Colorectal cancer; Targeted therapy

©The Author(s) 2024. Published by Baishideng Publishing Group Inc. All rights reserved.

Core Tip: Targeted therapy is one of the most widely recognized and accepted methods for the treatment of colorectal cancer (CRC). Recent years have brought an intense focus to the study of the angiogenic signaling pathway, there have been studies showing that the infiltration, staging, and metastasis of colorectal are related to pigment epithelium-derived factors (PEDF) and vascular endothelial growth factors, but the current domestic and foreign studies on PEDF almost do not involve colorectal adenoma, a precancerous lesion. In our study, colorectal adenoma, a precancerous lesion, was added to analyze and explore the possibility of PEDF as a new target for early prevention and later treatment of CRC.

Citation: Yang Y, Wen W, Chen FL, Zhang YJ, Liu XC, Yang XY, Hu SS, Jiang Y, Yuan J. Expression and significance of pigment epithelium-derived factor and vascular endothelial growth factor in colorectal adenoma and cancer. *World J Gastrointest Oncol* 2024; 16(3): 670-686

URL: <https://www.wjgnet.com/1948-5204/full/v16/i3/670.htm>

DOI: <https://dx.doi.org/10.4251/wjgo.v16.i3.670>

INTRODUCTION

Colorectal cancer (CRC) has become the third most prevalent cancer, and its mortality rate ranks second in the world[1], every year, approximately 1 million new cases are diagnosed[2]. According to estimates, 3.2 million new cases of CRC will be diagnosed by 2040, while 1.6 million people will die from the disease[3]. Therefore, human health has been seriously threatened by CRC. The evolution of the sequence of "normal intestinal epithelium → adenoma → cancer" represents the occurrence process of most CRCs[4,5]. Colorectal adenoma is a major precancerous disease of CRC, accounting for at least 70%-90% of all precancerous diseases of CRC[6,7]. Endoscopic resection of adenomas is recognized as an effective method to prevent CRC, but the recurrence rate of adenomas in situ and at other sites after resection is still high[8,9], and subsequent chemoprevention, regular follow-up colonoscopy, and even repeated resection are still required. In recent years, advances in the understanding of species biology have facilitated the development of targeted therapies and also provided new ideas for the treatment of CRC. Finding a new target that can prevent colorectal

adenoma from progressing to CRC and treat CRC at the same time deserves further study.

In the development of any solid tumor, the growth of neovascularization is essential[10]. CRC is one of the many malignant solid tumors involving angiogenesis, and angiogenesis is also crucial in the occurrence and development of CRC. Although vascular endothelial cells are normally quiescent, proangiogenic factors such as vascular endothelial growth factor (VEGF) can induce sprouting and initiate the formation of new blood vessels[11]. VEGF is a highly specific mitogen that plays an important role in angiogenesis and neovascularization. It was independently isolated and discovered in 1989 by Leung *et al*[12], and in 1993, it was found that inhibition of VEGF-induced angiogenesis with specific monoclonal antibodies significantly inhibited the growth of a variety of tumors[13]. These findings provided important evidence that inhibition of angiogenesis can suppress growth and lead to tumor blocking. At present, the research on VEGF in CRC has been relatively mature. Existing studies have confirmed that the expression of VEGF is up-regulated in CRC, and it is negatively correlated with tumor stage, metastasis and prognosis[14,15]. VEGF level increases with the increase of CRC stage, and it can be used as an independent predictor of overall survival in patients with CRC [16]. The prognosis of CRC patients with high expression of VEGF is poor[17]. Angiogenesis is crucial for tumor growth and metastasis. The expression of VEGF is related to the increase of microvessel density in CRC. VEGF is not only a major mediator of angiogenesis, but also a key factor promoting the formation of vascular endothelial cells and lymphatic vessels[18]. It promotes the occurrence and development of CRC and is an important angiogenic factor in primary and metastatic CRC. In addition, some researchers have done relevant studies on whether VEGF can predict the pathological complete response (pCR) of preoperative chemoradiotherapy (preCRT) in rectal cancer, and the results show that patients with high expression of VEGF have a significantly higher pCR rate[19]. VEGF can not only be used as a prognostic factor for CRC, but also can be used to predict the response to conventional systemic therapy and local radiotherapy in CRC. During the recent years, as scholars have studied the angiogenesis signaling pathway in-depth, it has been found that neovascularization is already active in the earliest stage of CRC occurrence and development[20]. In colorectal adenomas, some studies have found that VEGF is highly expressed in colorectal adenomas and low-grade intraepithelial neoplasia [15], and VEGF may be used to risk stratifying intestinal polyps with different risk of progression[21]. However, few studies have investigated the relationship between VEGF expression and angiogenesis in the sequence of "normal intestinal epithelium → adenoma → carcinoma" from the early stage of CRC.

In the process of CRC occurrence and progression, the balance between stimulating and inhibiting factors of angiogenesis is destroyed, which causes CRC to develop abnormal blood vessels, and further promotes the occurrence and progression of tumors. As the core factors regulating tumor vascular microenvironment, pigment epithelium-derived factors (PEDF) play a key role in regulating tumor angiogenesis and blood supply metastasis[22]. The ratio of PEDF/VEGF finely regulates blood vessel formation, and the balance between the two plays a crucial role in angiogenesis[23, 24]. PEDF is an endogenous neovascularization inhibitor, also known as early population double level c DNA-1 (EPC-1), which is composed of 418 amino acids with a molecular mass of about 50 kDa. PEDF was first identified as a neuronal differentiation inducer in conditioned medium of human retinal pigment epithelium cells in 1989. And it is an inducer of neuronal differentiation in Y79 retinoblastoma cells[25]. PEDF shares structural and sequence homology with members of the serine protease inhibitor (SERPIN) superfamily[26]. In 1999 Dawson *et al*[27] found that PEDF has potent antiangiogenic activity and is more potent than angiostatin in inhibiting angiogenesis. Significant reductions in PEDF levels have been found in age-related macular degeneration and diabetic retinopathy, two pathological processes dependent on angiogenesis[28,29]. PEDF can also induce the differentiation of neuroblastoma tumor cells and promote the neuroendocrine function of prostate cancer cells[30,31]. PEDF, encoded by the SERPINF1 gene, first appeared in vertebrates and has shown strong conservation in the evolution of mammalian species. The PEDF gene is widely expressed in eye, prostate, mammary gland, cervix, lung, pancreas, liver, colorectal and other tissues, and the regulatory and biological role of the gene is preserved in spinal animals[32]. The human PEDF gene is located in 17p13.1, which is a region containing a group of cancer-related genes[33,34]. This also indicates that PEDF, as a multifunctional protein, not only participates in physiological and pathological reactions such as neuroprotection, regulation of oxidative stress, inhibition of blood vessels, osteogenesis, anti-inflammation, lipid metabolism [35-38], but also may have anti-tumor effects.

Compared with normal tissues, the expression of PEDF is decreased in cancer tissues of solid tumors such as gonadal tumors, lung cancer, and pancreatic cancer[39-42], suggesting that the loss of PEDF may play a key role in tumorigenesis. Gene therapy of PEDF or PEDF therapy with recombinant proteins has been used in ovarian cancer and lung cancer[43, 44]. PEDF can play an anti-tumor role by inhibiting tumor angiogenesis, proliferation, migration, invasion and metastasis of tumor cells, and inducing apoptosis of cancer cells[45]. The expression of PEDF is closely related to tumor progression and survival prognosis, and the low expression of PEDF often predicts tumor progression and shorter survival time[46]. Among the few studies on PEDF in CRC at home and abroad, most of them showed that the expression level of PEDF in CRC tissues was lower than that in adjacent tissues, and its expression was negatively correlated with tumor stage[47]. However, some studies showed that the expression of PEDF in CRC tissues was not significantly different from that in paired normal tissues[48]. In addition, the current research on PEDF at home and abroad almost does not involve colorectal adenoma, which is a precancerous disease.

At present, endothelial cells are attractive targets for the treatment of diseases that depend on the formation of new blood vessels, such as cancer. The activity of neovascularization has occurred in the earliest stage of CRC, and the formation of blood vessels runs through the entire occurrence and development process of CRC[47]. VEGF-targeted drugs are effective and safe for treating CRC have been confirmed and widely promoted[49]. PEDF related formulation mainly include peptide formulation, physical and chemical carriers, and biological carriers. At present, no toxicity caused by PEDF formulation itself has been observed in anti-tumor vascular animal models. Therefore, we boldly speculate that PEDF, as an antagonist of VEGF, may become a new target for early prevention and later treatment of CRC.

Microvessel density (MVD) has been regarded as an extremely important marker of tumor microangiogenesis by researchers. CD31 is selected by immunohistochemical staining to mark microvessels, and microvessel density is calculated, which is a commonly used detection method for quantitative analysis of tumor angiogenesis[50]. In this study, we investigated the expression of PEDF and VEGF in normal colorectal mucosa, adenomas and CRC, and their relationship with the clinicopathological characteristics of CRC, starting from the earliest stage of CRC development and including colorectal adenoma, a precancerous lesion. At the same time, the microvessels were marked with CD31, and the MVD of each tissue was calculated, and the difference and correlation between them were analyzed. To investigate the role and significance of PEDF and VEGF in the pathogenesis of CRC from normal intestinal epithelium to adenoma and then to cancer.

MATERIALS AND METHODS

Materials

We collected the archived wax blocks of specimens submitted by the Department of Digestive Endoscopy Center and General Surgery of Chengdu Second People's Hospital from April 2022 to October 2022. Fifty cases of specimen wax blocks were selected as normal intestinal mucosa confirmed by electronic colonoscopy and concurrent biopsy (normal control group), 50 cases of specimen wax blocks confirmed as colorectal adenoma by electronic colonoscopy and pathological biopsy (colorectal adenoma group), and 50 cases of specimen wax blocks were selected as CRC confirmed by postoperative pathological biopsy after inpatient operation in the Department of General Surgery (CRC group).

Inclusion criteria: (1) Pathological biopsy confirmed that all specimens were normal colorectal mucosa, colorectal adenoma, or CRC, respectively; (2) The included specimens had complete case data; and (3) None of the patients with CRC included had a history of colorectal surgery, and none had received chemoradiotherapy or other anti-tumor therapy.

Exclusion criteria: (1) Patients previously diagnosed with other malignant tumors; (2) Patients with eye and immune system diseases; and (3) Patients with a combined history of intestinal tuberculosis, familial intestinal polyposis, inflammatory bowel disease, and hamartomatous polyposis syndrome.

This study was approved by Chengdu Second People's Hospital's Ethics Committee and all patients signed informed consent forms.

Immunohistochemistry

We used a rotary microtome (Leica, Germany) to re-cut each of the above-selected wax blocks into 3 consecutive slices with a thickness of 3µm and used the Roche BenchMark GX automatic immunohistochemical dye machine for immunohistochemical staining of PEDF, VEGF, and CD31. Rabbit anti-human VEGF monoclonal antibody (UK Abcam) working concentration: 1:100; rabbit anti-human CD31 polyclonal antibody (UK Abcam) working concentration: 1:2000; rabbit anti-human PEDF polyclonal antibody (US GeneTex) working concentration: 1:500; PBS phosphate buffer (Fuzhou Maixin Technology Development Co., LTD., China); DAB dyeing solution (Ventana Medical Systems, United States).

Every batch of experiments was accompanied by positive and negative controls. Negative controls were PBS buffer rather than primary antibodies, and the positive control was referred to as a known positive image.

Automatic immunohistochemical dyeing machine dyeing process: (1) Baking: temperature 75 °C, time 4 min; (2) Dewaxing: add EZ prep liquid, dewaxing temperature 76 °C for 4 min, then rinse the sections with EZ prep liquid twice; (3) Antigen repair: hot repair temperature of 99 °C, incubation time of 30 min, repair solution: CC1, PH 8.5, rinse with reaction buffer after repair; (4) Block endogenous peroxidase: add 100 µL inhibitor, add oil membrane LCS, incubate at 37 °C for 4 min, and rinse reaction buffer after incubation; (5) Incubate for 32 min at 37 °C with the primary antibody. Rinse with reaction buffer after incubation; (6) The second antibody was incubated at 37 °C for 8 min and rinsed with reaction buffer after incubation; (7) Color development: Add 100 µL of DAB and 100 microliters of H₂O₂ for color development, then add oil film LCS, incubate at 37 °C for 8 min, and rinse with reaction buffer after incubation; (8) Add 100 µL of color enhancer, incubate at 37 °C for 4 min, and rinse with reaction buffer after incubation; (9) Interlining: Add 100 µL hematoxylin II, incubate at 37 °C for 8 min, and rinse with reaction buffer after incubation; (10) Interlining: blue return, temperature 37 °C, incubation time 4 min, rinse with reaction buffer after incubation; and (11) Finish dyeing.

Interpretive standard

Immunohistochemical interpretation criteria for PEDF and VEGF were as follows: PEDF positive expression was located in the nucleus, and study cells with light yellow, yellow, or brownish-yellow nuclei in tissue sections were identified as positive cells. VEGF is widely expressed in large intestine stromal cells and vascular endothelial cells in yellow or brownish yellow color, and this expression is used as a positive internal control in the interpretation of VEGF, and the study cells with light yellow, yellow, or brownish-yellow cytoplasm in the tissue section are judged as positive cells. First, the whole film was scanned with a low-power lens (100 ×) to preliminatively determine whether there were positive cells. Then, the study cell distribution area was switched to a high-power lens (200 ×) to observe 5 visual fields, and a comprehensive score was scored on the strength of staining and the number and percentage of positive cells. A five-grade system was used to score the percentage of positive cells: zero points for no positive cells, one point for 1%-25%, two points for 25%-50%, three points for 50%-75%, and four points for over 75%. The dyeing intensity score is divided into four levels: 0, 1, 2, and 3 points for no staining, light yellow, yellow, and brownish-yellow. The final score of the staining result = (percentage score of the number of positive cells above) × (staining intensity score); the final score of 0 is judged as negative (-), 1-4 is judged as weak positive (+), 5-8 is judged as medium positive (+), and 9-12 is judged as strong positive (+++). Counting microvessels marked by CD31 staining: Brown-colored endothelial cells and clusters can be counted as

microvessels if they are separated from adjacent blood vessels, tumor cells, and other connective tissues. The entire film is first scanned with a low-power lens (100 ×) in order to find areas where the microvascular density is evenly distributed, so as to identify areas of high-density blood vessels, which are called "hot spots". Then each section was observed in 5 random fields of the "hot spot" area under a high-power lens (200 ×), and a mean microvascular density value was determined by the average number of blood vessels in each field.

The above results were interpreted by two experienced film readers in the department of pathology who independently read the tissue sections in double-blind conditions. If the score of the film reading results for the same tissue section was inconsistent, the average score used was taken as final.

Statistical analysis

The statistical review of the study was conducted by a biomedical statistician. All data were analyzed and processed by IBM SPSS Statistics 26.0 (Armonk, NY, United States). The measurement data in this experimental study followed the normal distribution and were statistically described in the form of mean ± SD. The *F*-test or corrected *F*-test (Welch's test) was used for statistical analysis of measurement data. The Kruskal-Wallis rank sum test was used between groups for ranked data, and if statistical differences between groups existed, the Bonferroni method was further used for multiple comparisons. The counting data were described in the form of the number of cases (percentage). Chi-square test, corrected chi-square test or Fisher's exact test were used to complete the comparison of rates between groups and if the difference between groups was statistically significant, Bonferroni method was further used for pairwise comparison. Spearman correlation analysis was used to test the correlation of the data. The test level (α) was 0.05, and a two-sided $P < 0.05$ was considered statistically significant.

RESULTS

General data

In the normal control group, there were 25 cases (50%) of males and 25 cases (50%) of females, aged 24-80 years old, with an average age of 55.58 ± 13.670 years old. Pathological specimens were obtained from the rectum in 15 cases (30%), the left half colon in 23 cases (46%), and the right half colon in 12 cases (24%). In the colorectal adenoma group, there were 28 males (56%) and 22 females (44%), aged 31-84 years, with an average age of 56.46 ± 12.755 years. Pathological specimens were obtained from the rectum in 14 cases (28%), the left colon in 23 cases (46%), and the right colon in 13 cases (26%). In the CRC group, there were 33 males (66%) and 17 females (34%), aged 30-91 years, with an average age of (60.16 ± 14.435) years. Pathological specimens were obtained from the rectum in 24 cases (48%), the left half colon in 14 cases (28%), and the right half colon in 12 cases (24%). The three groups did not differ statistically significantly in gender ($\chi^2 = 2.617$, $P = 0.263$) (Figure 1A), age ($F = 1.588$, $P = 0.208$) (Figure 1B), or specimen source location ($\chi^2 = 6.188$, $P = 0.186$) (Figure 1C).

Positive expression of PEDF and VEGF

Normal control subjects had the highest positive expression rate of PEDF, followed by the colorectal adenoma group, and the CRC group had the lowest (100%, 78%, 50%). However, positive expression rates for VEGF were highest among CRC group, followed by colorectal adenoma group, and lowest among normal control subjects (96%, 68%, 0%). Positive expression rates for PEDF and VEGF were significantly different among all groups ($P < 0.05$) (Figure 2A and C).

Expression intensity of PEDF and VEGF

There were statistically significant differences between the three groups in terms of PEDF and VEGF expression intensity ($P < 0.001$), and there were statistically significant differences in the expression intensity of PEDF and VEGF in the three groups, respectively ($P < 0.001$) (Figure 2B and D). The expression intensity of PEDF was the highest in the normal control group, with mainly medium positive (++) and strong positive (+++) expression (Figure 3A and B). And in the colorectal adenoma group, weak positive (+) and medium positive (++) were predominant (Figure 3C and D). The lowest was found in the CRC group, with negative (-) and weakly positive (+) expressions predominant (Figure 3E and F). On the contrary, the expression intensity of VEGF was the highest in the CRC group, with mainly medium positive (++) and strong positive (+++) expression (Figure 4E and F). In the colorectal adenoma group, the expression of negative (-) and weak positive (+) was the second (Figure 4C and D). The lowest was found in the normal control group, all of which had negative (-) expression (Figure 4A and B).

VEGF, PEDF, and cancer clinicopathology

Table 1 shows that the positive expression rate of PEDF in CRC was not statistically different in terms of age, gender, tumor size, and tumor location (Figure 5A). But there were statistical differences in the degree of differentiation, depth of invasion, presence or absence of lymph node metastasis, presence or absence of distant metastasis, and clinical stage ($P < 0.05$) (Figure 5C). In the CRC group, the positive expression rate of PEDF was higher in highly differentiated cancers than in medium-low differentiated cancers, higher in carcinomas without serosal invasion than in carcinomas with serosal invasion, higher in cancers without lymph node metastasis than in cancers with lymph node metastasis, and higher in cancers without distant metastasis than in cancers with distant metastasis. The positive expression rate of PEDF in AJCC stage I + II cancer was higher than that in stage III + IV cancer.

In the CRC group, the negative expression rate of VEGF was only 4%, but the positive expression rate was as high as 96%, among which the weak positive (+), medium positive (++) and strong positive (+++) expressions accounted for

Table 1 Clinical features of colorectal cancer in relation to pigment epithelium-derived factors and vascular endothelial growth factors expression

Characteristics	PEDF			VEGF		
	+++ [n (%)]	$\chi^2 =$	P value	+++ [n (%)]	$\chi^2 =$	P value
Age (years)						
< 60	10 (50)	0.000	1.000	5 (25)	0.397	0.529
≥ 60	15 (50)			10 (33.3)		
Gender						
Male	17 (51.5)	0.089	0.765	8 (24.2)	1.532	0.216
Female	8 (47.1)			7 (41.2)		
Tumor site (cm)						
< 5	11 (42.3)	1.282	0.258	6 (23.1)	1.236	0.266
≥ 5	14 (58.3)			9 (37.5)		
Tumor						
Rectum	14 (58.3)	1.810	0.405	5 (20.8)	3.556 ¹	0.193 ¹
Left colon	5 (35.7)			7 (50)		
Right colon	6 (50)			3 (25)		
Tumor differentiation						
Medium-low differentiation	5 (19.2)	20.513	< 0.001	13 (50)	10.317	0.001
High	20 (83.3)			2 (8.3)		
Serous membrane infiltration						
No	13 (68.4)	4.160	0.041	0 (0)	13.134	< 0.001
Yes	12 (38.7)			15 (48.4)		
Lymph node metastasis						
No	17 (65.4)	5.128	0.024	1 (3.8)	17.643	< 0.001
Yes	8 (33.3)			14 (58.3)		
Remote metastasis						
No	22 (61.1)	6.349	0.012	4 (11.1)	21.844 ²	< 0.001 ²
Yes	3 (21.4)			11 (78.6)		
Staging Tumors (AJCC)						
I + II	17 (65.4)	5.128	0.024	1 (3.8)	17.643	< 0.001
III + IV	8 (33.3)			14 (58.3)		

¹Chi-square test; χ^2 =Fisher's exact test. PEDF: Pigment epithelium-derived factors; VEGF: Vascular endothelial growth factors.

14%, 52%, and 30%, respectively. Therefore, we classified negative (-), weak positive (+), and moderate positive (++) expression as low expression, and strong positive (+++) expression as high expression. The statistical results showed that the high expression rate of VEGF in CRC had no statistical difference with age, sex, tumor size, or tumor site (Figure 5B, Table 1). The high expression rate of VEGF in CRC had statistical differences with the degree of differentiation, depth of invasion, presence of lymph node metastasis, presence of distant metastasis, and clinical stage ($P < 0.001$) (Figure 5D, Table 1). In CRC, the high expression rate of VEGF is higher in medium-low differentiated cancers than in highly differentiated cancers, and higher in carcinomas with serosal invasion than in carcinomas without serosal invasion, higher in cancers with lymph node metastasis than in cancers without lymph node metastasis, higher in cancers with distant metastasis than in cancers without distant metastasis, and higher in cancers with clinical stage III+IV than in cancers with stage I + II.

CD31-MVD

The CD31-MVD values of the normal group were 1.012-1.180/HP, and the average microvascular density of each high-

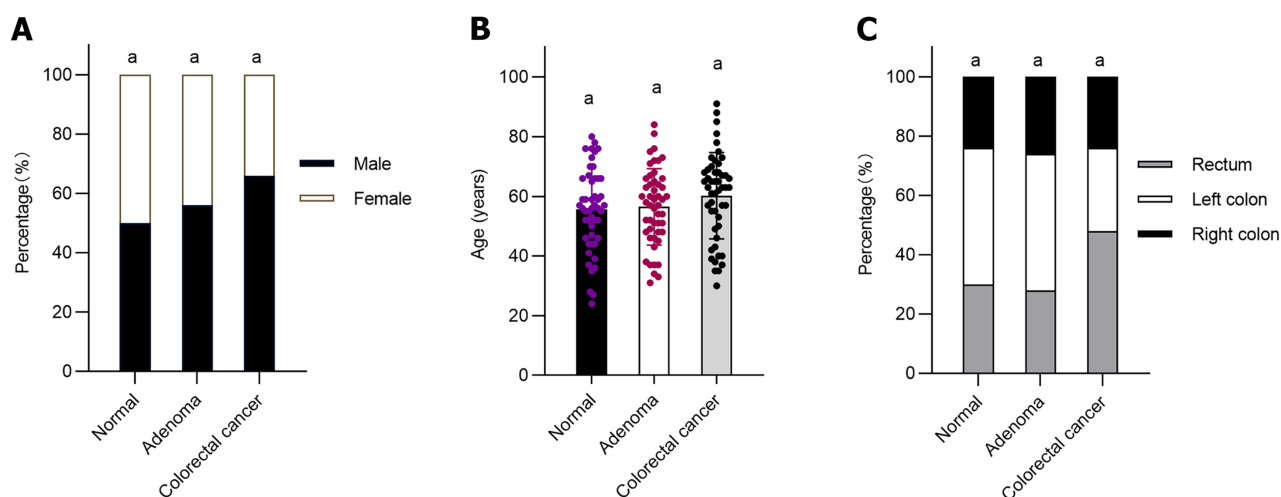


Figure 1 General data of normal control group, adenoma group and colorectal cancer group. A: Three groups compared by gender; B: Three groups compared by age; C: Three groups compared by specimen origin. $n = 50$ (normal control group), $n = 50$ (adenoma group), $n = 50$ (colorectal cancer group). $^aP > 0.05$.

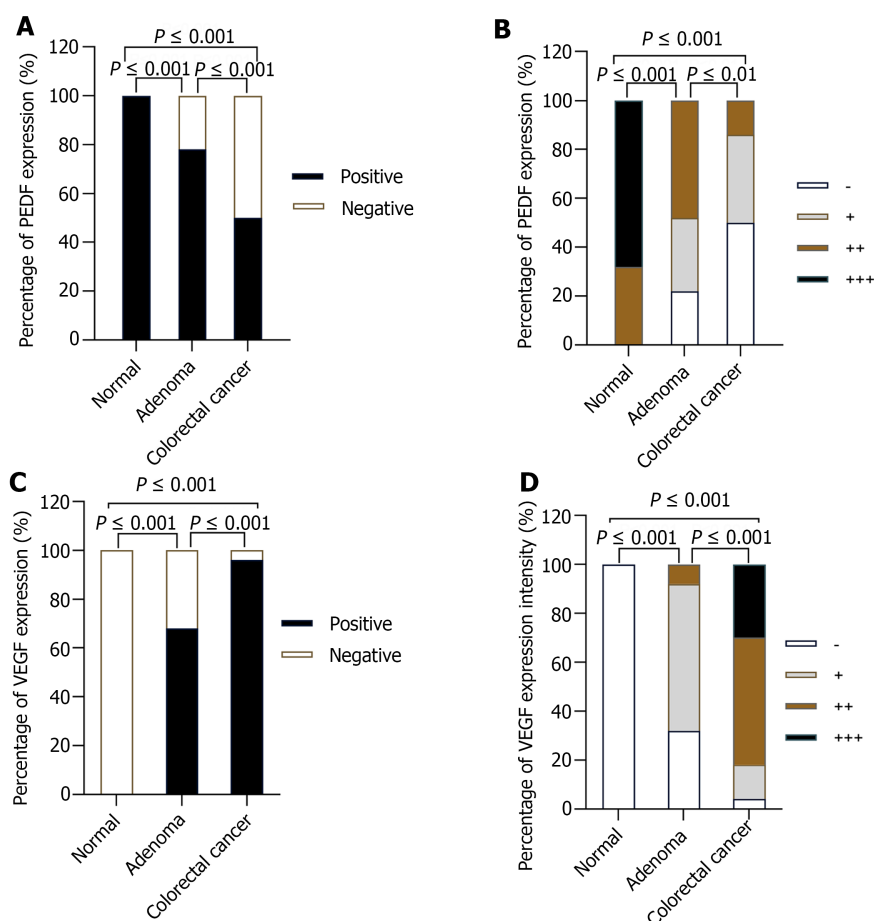


Figure 2 Comparison of positive expression rate and expression intensity of pigment epithelium-derived factors and vascular endothelial growth factors in normal control group, adenoma group and colorectal cancer group. A: Positive expression rate of pigment epithelium-derived factors (PEDF) in the three groups; B: Expression intensity of PEDF in the three groups; C: Positive expression rate of vascular endothelial growth factors (VEGF) in the three groups; D: Expression intensity of VEGF in the three groups. $n = 50$ (normal control group), $n = 50$ (adenoma group), $n = 50$ (colorectal cancer group). PEDF: Pigment epithelium-derived factors; VEGF: Vascular endothelial growth factors.

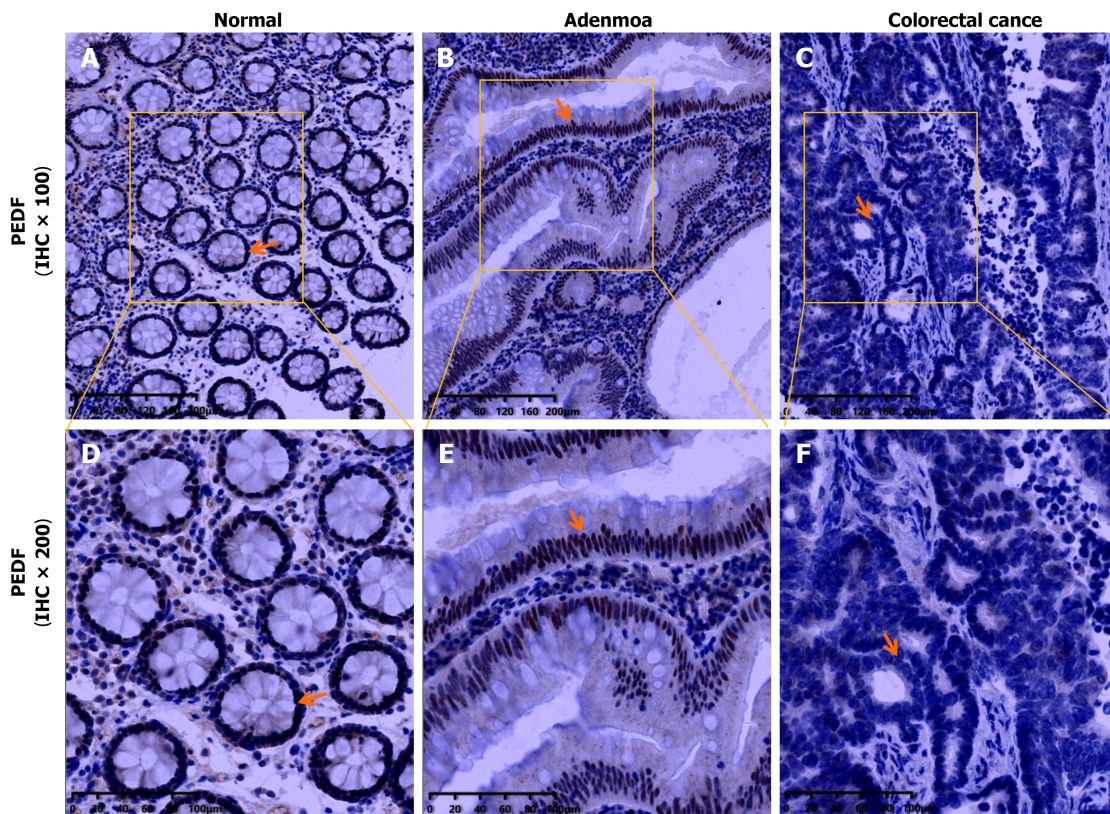


Figure 3 Immunohistochemistry of pigment epithelium-derived factors (PEDF) in three groups. A: Pigment epithelium-derived factors (PEDF) immunohistochemistry (IHC) plot in normal group (IHC \times 100); B: PEDF immunohistochemistry plot in normal group (IHC \times 200). In the normal group, the nuclei of the study cells were brownish yellow, the number of positive cells was more than 75%, and the expression was strongly positive (+++); C: PEDF immunohistochemistry plot in adenoma group (IHC \times 100); D: PEDF immunohistochemistry plot in adenoma group (IHC \times 200). In the adenoma group, the nuclear color was mainly yellow, the number of positive cells was more than 75%, and the expression was moderately positive (++); E: PEDF immunohistochemistry plot in colorectal cancer (CRC) group (IHC \times 100); F: PEDF immunohistochemistry plot in CRC group (IHC \times 200). In the CRC group, the nucleus was almost uncolored, the number of positive cells was 0%, and the expression intensity was negative (-) expression. PEDF: Pigment epithelium-derived factors.

power (200 \times) field was $(1.096 \pm 0.2948)/\text{HP}$. In the adenoma group, the CD31-MVD values were 11.683-14.085/HP, and the average microvascular density was $12.884 \pm 4.2267/\text{HP}$ under each high-power (200 \times) field of view. In the CRC group, the CD31-MVD values ranged from 30.507 to 35.253/HP, and the average microvascular density was $32.88 \pm 8.3488/\text{HP}$ per high-power (200 \times) field of view. There were statistical differences in CD31-MVD values among the normal group, adenoma group, and CRC group ($P < 0.001$) (Figure 6A). In the CRC group, CD31-MVD values were highest, adenoma values were second, and normal values were lowest (Figure 7).

Correlation between PEDF, VEGF and CD31-MVD

The expression intensity of PEDF was statistically significantly different from CD31-MVD value in the adenoma group ($r = -0.601$, $P < 0.001$) (Figure 6B). There was a negative correlation between PEDF expression intensity and CD31-MVD value, and the CD31-MVD value increased with the decrease in PEDF expression. However, the correlation between VEGF expression intensity and CD31-MVD value was not statistically significant ($r = 0.258$, $P = 0.07$) (Figure 6C).

In the CRC group, the expression intensity of PEDF was negatively correlated with the CD31-MVD value ($r = -0.297$, $P = 0.036$), and the expression intensity of PEDF increased with the decrease in PEDF expression (Figure 6E). The correlation between PEDF expression intensity and VEGF expression intensity was also statistically significant ($r = -0.548$, $P < 0.001$) (Figure 6D). The expression intensity of PEDF was negatively correlated with that of VEGF, and the expression intensity of VEGF increased with the decrease in PEDF expression. In addition, the correlation between VEGF expression intensity and CD31-MVD value was also statistically significant ($r = 0.421$, $P = 0.002$) (Figure 6F). The expression intensity of VEGF was positively correlated with the CD31-MVD value, and the CD31-MVD value increased with the increase in VEGF expression.

ROC curve

We analyzed the value of PEDF, VEGF, and PEDF + VEGF in diagnosing CRC using a ROC curve. The AUC of PEDF in the diagnosis of CRC was 0.842, the 95% confidence interval was 0.779-0.940, the sensitivity was 86%, the specificity was 74%, and the best cut-off value was weak positive (+) expression. The AUC of VEGF in the diagnosis of CRC was 0.936, the 95% confidence interval was 0.891-0.981, the sensitivity was 82%, the specificity was 96%, and the best cut-off value was moderate positive (++) expression. The AUC of PEDF + VEGF in the diagnosis of CRC was 0.935, the 95% confidence interval was 0.887-0.984, the sensitivity was 82%, and the specificity was 96%. There was a statistically significant

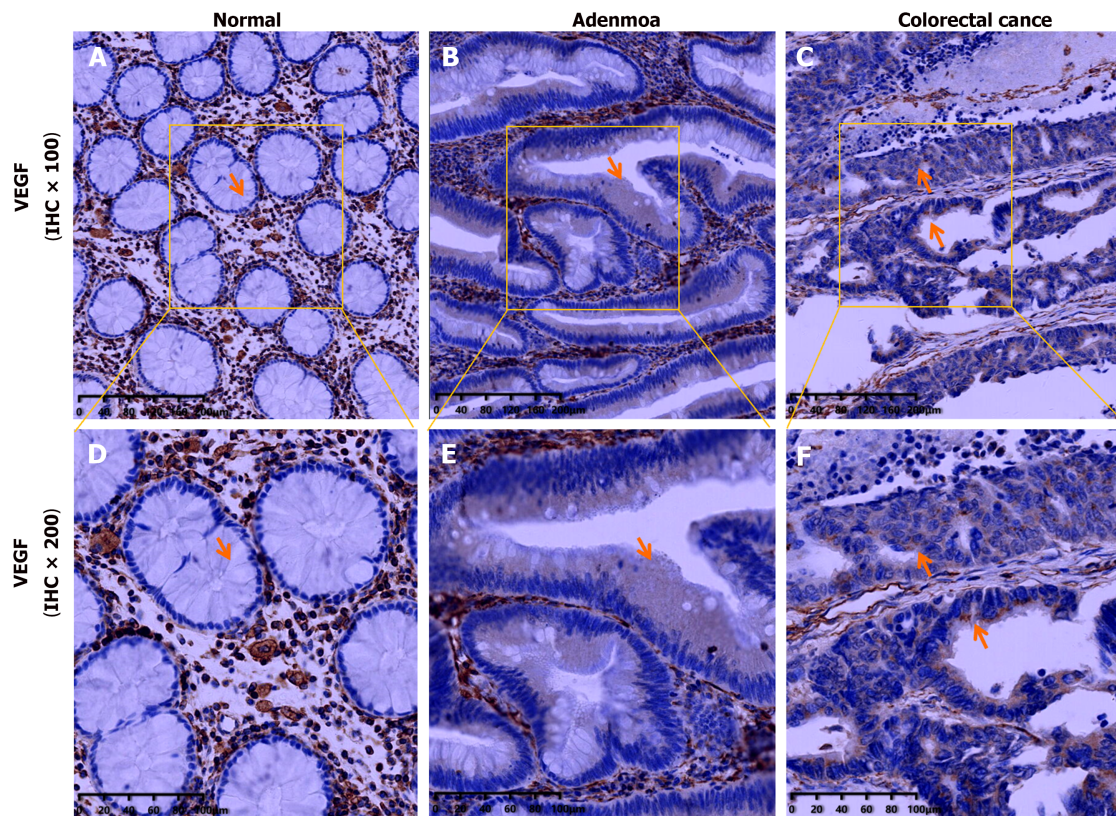


Figure 4 Immunohistochemistry of vascular endothelial growth factors in three groups. A: Vascular endothelial growth factors (VEGF) immunohistochemistry (IHC) plot in normal group (IHC $\times 100$); B: VEGF immunohistochemistry plot in normal group (IHC $\times 200$). In the normal group, the cytoplasm of the study cells was not colored and showed negative (-) expression; C: VEGF immunohistochemistry plot in adenoma group (IHC $\times 100$); D: VEGF immunohistochemistry plot in adenoma group (IHC $\times 200$). In the adenoma group, the cytoplasm was light yellow, the number of positive cells was more than 75%, and the expression was weak positive (+); E: VEGF immunohistochemistry plot in colorectal cancer (CRC) group (IHC $\times 100$); F: VEGF immunohistochemistry plot in CRC group (IHC $\times 200$). In the CRC group, the cytoplasm was expressed in yellow fine particles on the surface of the tumor cell cavity, and the number of positive cells was greater than 75%, showing moderately positive (++) expression. Note: In the normal group, adenoma group and CRC group, the expression of brown or yellow was widely seen in the colorectal stromal cells and vascular endothelial cells, which was used as a positive internal control. VEGF: Vascular endothelial growth factors.

difference in AUC when detecting PEDF, VEGF, and PEDF + VEGF in tissues to diagnose CRC ($P < 0.001$) (Figure 8).

DISCUSSION

This experimental study showed that PEDF was expressed in normal colorectal mucosa, colorectal adenoma tissue, and CRC tissue, and the results of our study were in accordance with the findings of Ji *et al*[47]. At the same time, this study also complements the current research on the difference in the expression of PEDF in colorectal adenoma tissues, normal colorectal mucosa, and CRC tissues. In addition, the positive expression rate and intensity of PEDF in normal colorectal mucosa, adenoma, and cancer tissues gradually decreased during the development of CRC, while that of VEGF was the opposite. The positive expression rate of PEDF and the high expression rate of VEGF were found to be related to the degree of differentiation, depth of invasion, lymph node metastasis, and distant metastasis of CRC, as well as the clinical stage. The positive expression rate of PEDF in well-differentiated carcinoma was higher than that in moderate-poorly differentiated carcinoma, in non-serosal invasion carcinoma was higher than that in serosal invasion carcinomas, in carcinoma without lymph node metastasis was higher than that with lymph node metastasis, in carcinoma without distant metastasis was higher than that with distant metastasis, and in carcinoma at clinical stage I + II was higher than that in stage III + IV carcinoma; however, the high expression rate of VEGF was in contrast. The results of the study are also consistent with that of Harries *et al*[51] and Das *et al*[52]. The results show that PEDF and VEGF are involved in the whole process of the occurrence and development of CRC. The higher the positive expression rate of PEDF and the lower the high expression rate of VEGF, the higher the degree of differentiation, the lower the probability of serosa invasion, the lower the risk of lymph node and distant metastasis, and the better the clinical stage of CRC. Therefore, we can speculate that the expression of PEDF is inhibited in the evolution process of "normal intestinal epithelium \rightarrow adenoma \rightarrow cancer", and it plays an inhibitory role in the development process of malignant transformation of colorectal adenomatous polyps and the progression of CRC. PEDF is a protective factor in the occurrence and development of CRC. However, the clinical stage of CRC with high expression of VEGF is poor, and VEGF is a promoting factor in the progression of CRC. Detection of VEGF expression in CRC may provide valuable clinical staging and prognostic information for CRC patients, which is

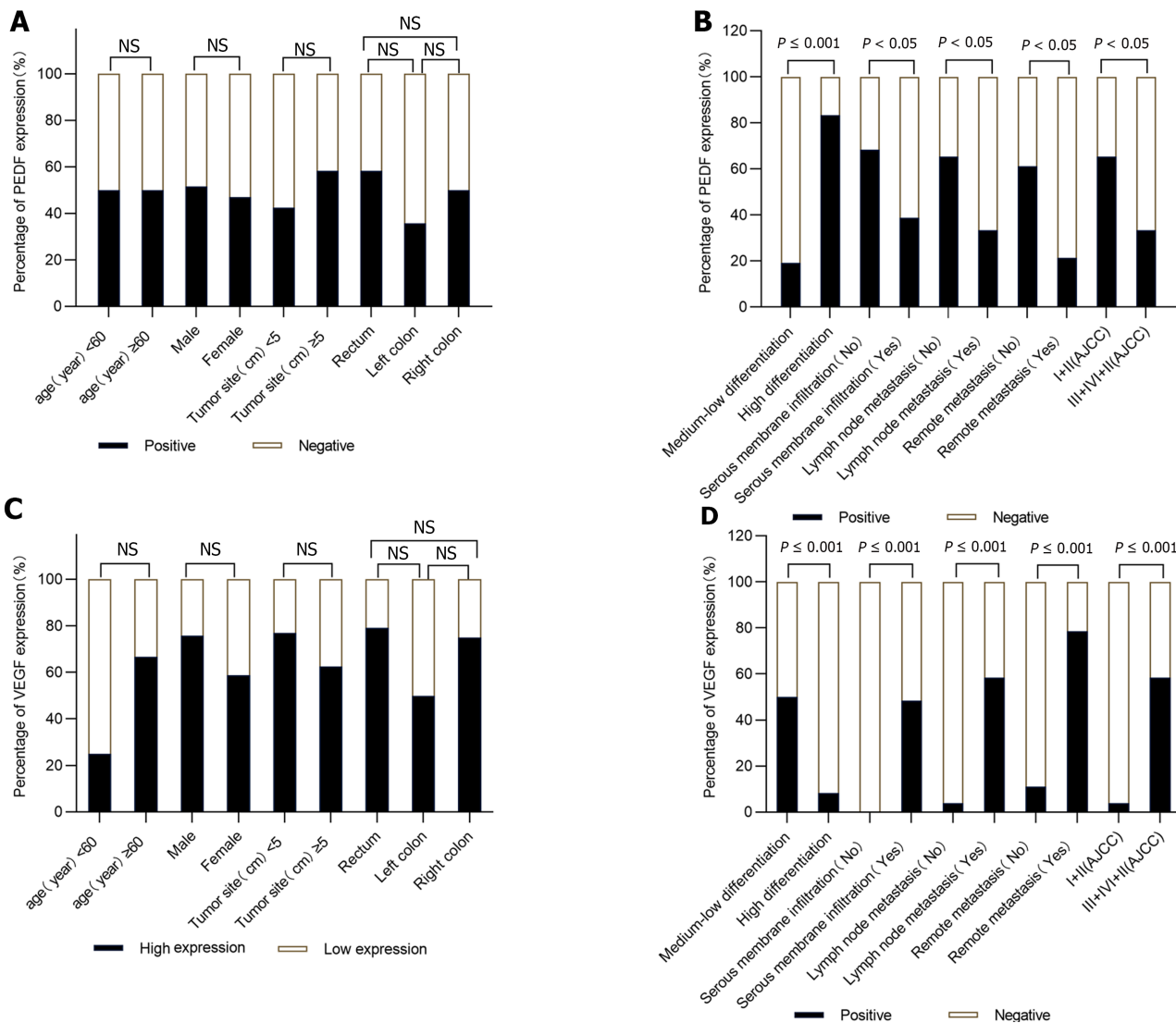


Figure 5 The relationship between the expression of pigment epithelium-derived factors and vascular endothelial growth factors with clinical parameters in colorectal cancer group. A: The relationship between positive expression rate of pigment epithelium-derived factors (PEDF) and age, gender, tumor size, and tumor location in colorectal cancer (CRC) group; B: The relationship between high expression rate of vascular endothelial growth factors (VEGF) and age, gender, tumor size, and tumor location in CRC group; C: The relationship between positive expression rate of PEDF and tumor differentiation, serous membrane infiltration, lymph node metastasis, remote metastasis and staging tumors in CRC group; D: The relationship between high expression rate of VEGF and tumor differentiation, serous membrane infiltration, lymph node metastasis, remote metastasis and staging tumors in CRC group. High expression: +++; Low expression: ~~~; $n = 50$ (CRC group), NS: $P \geq 0.05$. PEDF: Pigment epithelium-derived factors; VEGF: Vascular endothelial growth factors.

also consistent with the results of earlier meta-analysis[53].

Angiogenesis is a multi-step process triggered by a variety of biological signals, involving the activation, migration, tube formation, differentiation and maturation of vascular endothelial cells[54]. Angiogenesis mainly includes sprouting angiogenesis and intussusceptive angiogenesis. The former grows new capillaries from the previous capillaries and then forms new blood vessels. The latter is a novel mode of vessel formation and remodeling that can lead to the formation of new blood vessels by internal division of preexisting capillary plexus[55]. In addition, angiogenesis is very important in different stages of cancer, and angiogenesis may also be a fundamental step in the transformation of tumors from benign to malignant. Since the early 1990s, MVD has been considered one of the indicators for tumor prognosis research[32]. MVD detection of CRC and MVD detection of precancerous diseases can better explore the occurrence and development processes of tumors. In this experimental study, there were statistical differences in CD31-MVD values among the three groups. In each group, CRC showed the highest CD31-MVD value, followed by colorectal adenoma, and normal colorectal tissues showed the lowest. This indicates that there is very little neovascularization in normal colorectal tissue, but new blood vessels have gradually begun to appear in colorectal adenoma, which is a precancerous disease. In the evolution process of "normal intestinal epithelium → adenoma → cancer" of CRC, the microvessel density gradually increases. PLXDC1 and its homolog PLXDC2 are the only two proteins that have been shown to bind extracellular PEDF to the cell surface and to signal PEDF to the cell. They are a complete group of transmembrane proteins that are not only involved in cell-cell and cell-matrix interactions during capillary morphogenesis, but also in the process of capillary morphogenesis. They are also involved in the proliferation and maintenance of neovascular endothelial cells in the fibrovascular membrane[56]. Among them, PLXDC1, also known as tumor endothelial marker 7 (TEM 7), is a

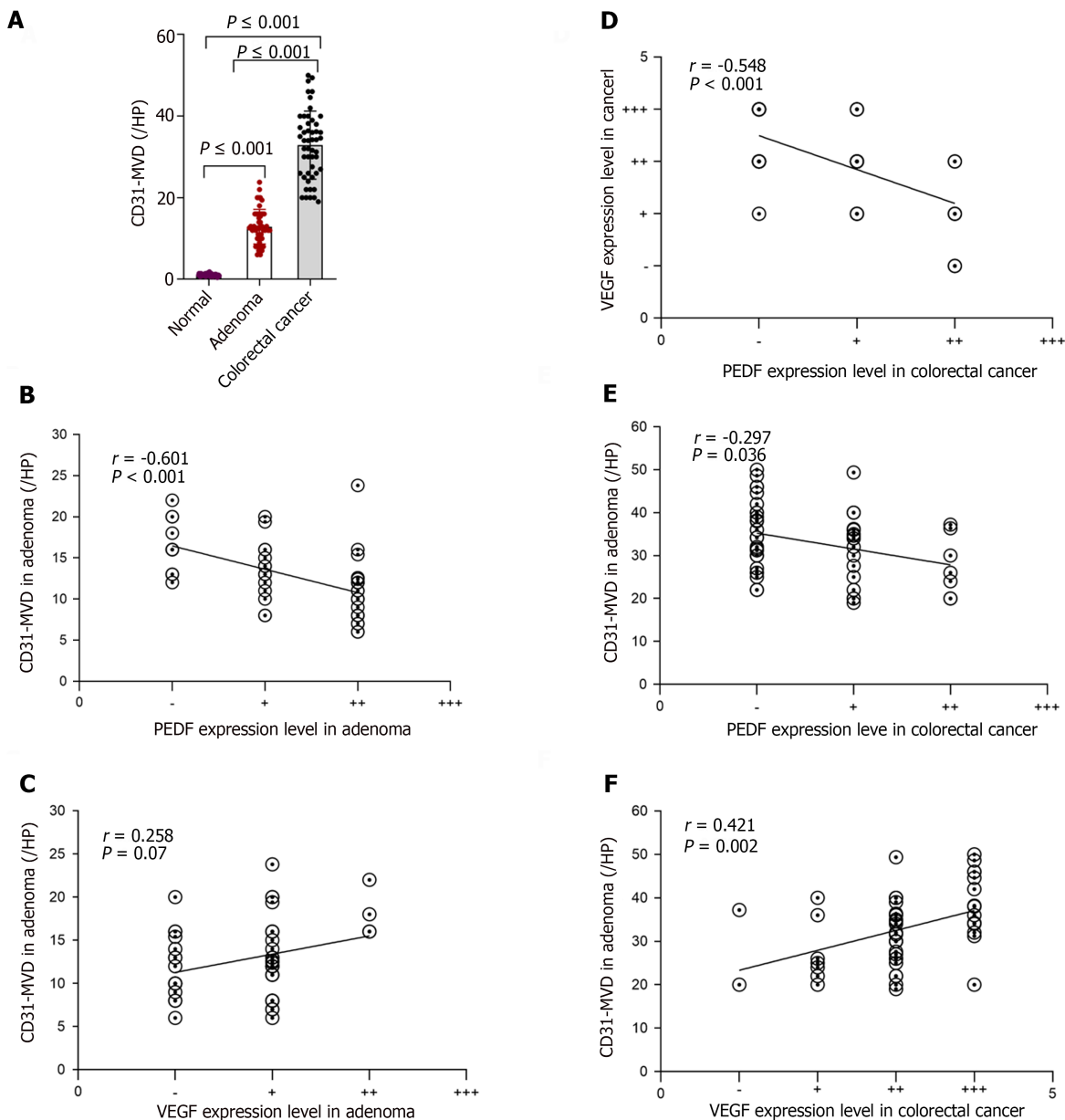


Figure 6 CD31-stained microvessel density values and correlation analysis. A: Difference of CD31-stained microvessel density values (CD31-MVD) value in normal group, adenoma group, and colorectal cancer (CRC) group; B: Correlation between pigment epithelium-derived factors (PEDF) and CD31-MVD value in adenoma group; C: Correlation between vascular endothelial growth factors (VEGF) and CD31-MVD value in adenoma group; D: Correlation between PEDF and VEGF in CRC group; E: CRC group Association between PEDF and CD31-MVD value in CRC; F: Association between VEGF and CD31-MVD value in CRC. CD31-MVD: CD31-stained microvessel density values; PEDF: Pigment epithelium-derived factors; VEGF: Vascular endothelial growth factors.

transmembrane cell indicator protein containing a plexiform protein domain[57]. In a gene expression dataset of endothelial cells isolated from solid tumors, PLXDC 1 was found to be overexpressed in endothelial cells from colon, breast, brain, and ovarian tumors[58]. Bagley *et al*[59] found that TEM-7 was highly enriched in the blood vessels of tumor tissues such as colon cancer, breast cancer, lung cancer, bladder cancer, ovarian cancer, and endometrial cancer, while it was rarely expressed in normal tissues and blood vessels. TEM-7 is a vascular protein related to angiogenesis. In addition, other studies have shown that the mean serum concentration of TEM7 in CRC patients is significantly higher than that in healthy controls, and TEM7 values gradually increase with the development of T, N and M stages. TEM7 serum concentration can be considered as a useful biomarker for detecting CRC patients, monitoring cancer progression and identifying patients with poor survival[60]. PLXDC2 is another receptor of PEDF, which is expressed in a variety of tumors such as hepatocellular carcinoma, gastric cancer, and CRC[61-63]. PLXDC2 receptor-mediated signaling is a direct effect of PEDF on cancer cells[56]. In this experiment, Spearman correlation analysis showed that the expression intensity of PEDF was negatively correlated with the CD31-MVD value in both the colorectal adenoma group and the CRC group, and the CD31-MVD value increased with the decrease in PEDF expression. This suggests that PEDF plays a significant inhibitory role in the early events (adenoma stage) and later events (cancer stage) of CRC. When PEDF is highly expressed, the CD31-MVD value decreases, thereby inhibiting and reducing the formation of new blood vessels. The vascular inhibitory effect of PEDF is involved in the development of CRC. Combined with the above comprehensive

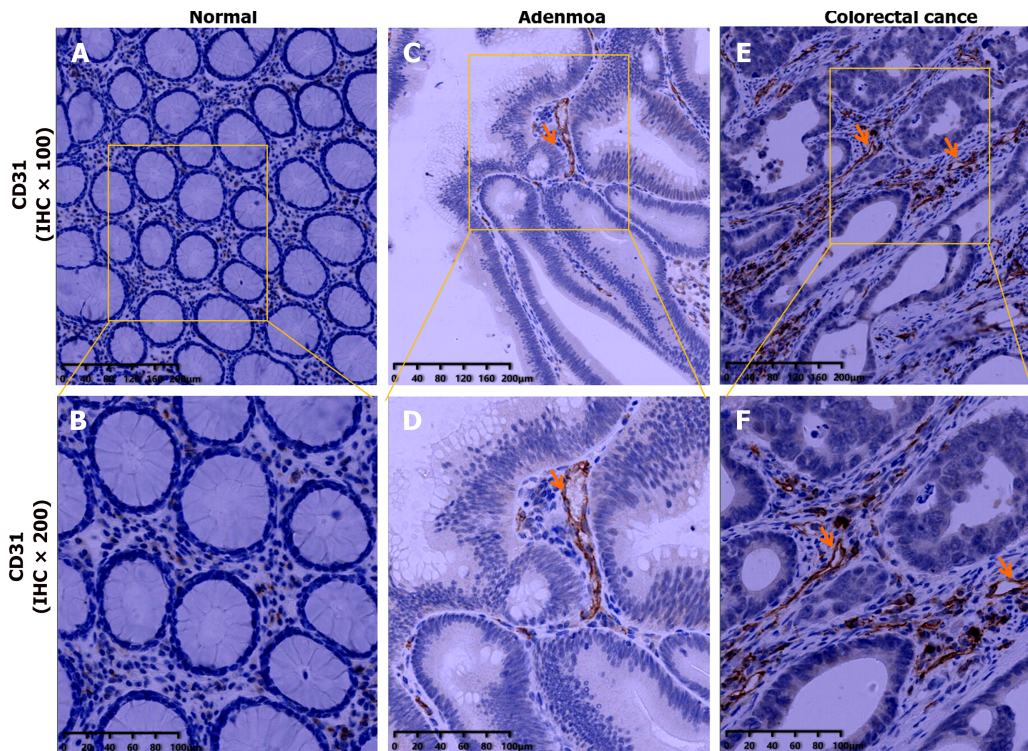


Figure 7 Immunohistochemistry of CD31 in three groups. A: CD31 immunohistochemistry plot in normal group (IHC \times 100); B: CD31 immunohistochemistry plot in normal group (IHC \times 200). In the normal group, no obvious stained vascular endothelial cells or endothelial cell clusters were found; C: CD31 immunohistochemistry plot in adenoma group (IHC \times 100); D: CD31 immunohistochemistry plot in adenoma group (IHC \times 200). In the adenoma group, a few vascular endothelial cells were found to be colored brown; E: CD31 immunohistochemistry plot in colorectal cancer (CRC) group (IHC \times 100); F: CD31 immunohistochemistry plot in CRC group (IHC \times 200). In CRC group, a large number of brown vascular endothelial cells were observed. IHC: Immunohistochemistry.

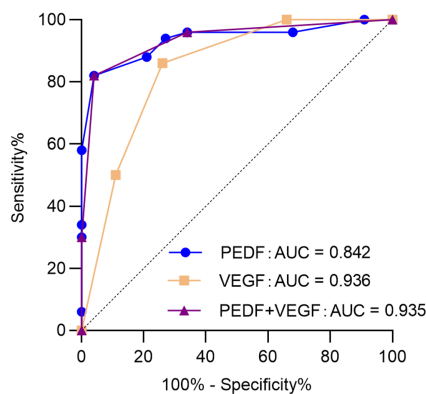


Figure 8 receiver operating characteristic curve of pigment epithelium-derived factors and vascular endothelial growth factors in the diagnosis of colorectal cancer. AUC: Area under the curve; PEDF: Pigment epithelium-derived factors; VEGF: Vascular endothelial growth factors.

analysis of the difference in PEDF expression in the three groups and its correlation with CD31-MVD, we can speculate that PEDF is a regulatory factor in the process of colorectal adenoma carcinogenesis. PEDF may be expected to be a new research target in the exploration of chemopreventive drugs to prevent and delay the carcinogenesis of colorectal adenoma and in the research of targeted drugs for the treatment of CRC.

The VEGF/VEGFR axis is indispensable for vessel angiogenesis and is a key driver of tumor vascularization. VEGF and VEGFR can regulate not only the generation of blood vessels that develop from precursor cells during the early embryonic period, but also the growth of blood vessels that are already present at later stages[64]. At the same time, the experiment also indicated a positive correlation between VEGF expression intensity and MVD in the CRC group, and the CD31-MVD value increased with the increase of VEGF expression. It is in line with the results of the majority of scholars' research[65]. The ratio of PEDF/VEGF finely regulates blood vessel formation, and the balance between the two plays a crucial role in angiogenesis[23,24]. PEDF can induce the expression of Fas ligand (FasL) in endothelial cells, and the apoptosis of endothelial cells can be induced by the binding of FasL to Fas receptor. However, high concentrations of anti-apoptotic proteins are present in normal vascular endothelial cells, which lead to the absence of Fas receptor expression. Thus, neovascular endothelial cells can be selectively inhibited by PEDF while still preserving the pre-existing

vasculature, and PEDF has no effect on normal blood vessel formation[66]. In an *in vitro* model of angiogenesis, the inhibitory effect of PEDF on VEGF-induced angiogenesis in the presence or absence of VEGF is mediated by enhancing the γ -secretase dependent C-terminal cleavage of VEGFR-1, thereby inhibiting VEGF-2-induced angiogenesis. In addition, PEDF regulates the phosphorylation of VEGFR-1, which itself regulates VEGFR-2 signaling. PEDF is a counteracting factor of VEGF and can inhibit VEGF-induced angiogenesis. The proposed underlying mechanisms of the biological effects of PEDF on endothelial cells involve the complex cross-talk between signaling events triggered by both proangiogenic and anti-angiogenic molecules[67]. In our experiment, PEDF and VEGF were correlated with CD31-MVD in the CRC group, indicating that PEDF and VEGF were both involved in the late event of the CRC stage. Furthermore, the correlation analysis revealed a negative relationship between PEDF expression intensity and VEGF expression intensity in the CRC group, and the expression intensity of VEGF decreased with the up regulation of PEDF expression. It is well known that as early as 2004, bevacizumab became the first VEGF-targeted therapy approved by the US Food and Drug Administration to treat metastatic CRC[49], and its effectiveness and safety have been confirmed. Currently, bevacizumab is still used as a first-line treatment drug for metastatic CRC[68]. Based on the result that the expression intensity of PEDF and VEGF is negatively correlated in the CRC group, we boldly speculate that in future targeted drug therapy, up-regulation of PEDF expression indirectly inhibits the expression of VEGF to inhibit tumor angiogenesis, which may provide a new idea for the treating of CRC.

In addition, in this experimental study, it was also found that there was no statistical difference in the correlation between the expression intensity of VEGF and CD31-MVD in the colorectal adenoma group, which was contrary to the results of Wang *et al*[69] in the early research. Wang *et al*[69] used the immunohistochemical method to investigate the correlation between VEGF expression and MDV in 36 cases of adenoma specimens (including 12 cases of tubular adenoma, 12 cases of tubule-villous adenoma, and 12 cases of villous adenoma). The results showed that the MVD value in colorectal adenoma group was positively correlated with the expression intensity of VEGF ($r = 0.640$, $P < 0.01$). It is well known that the risk of canceration in colorectal adenomas increases with histological progression[70], and in contrast, the canceration rate of tubular adenomas is relatively low compared with tubulovillous and villous adenomas. However, in the experimental adenoma group, 37 cases included tubular adenoma, accounting for 74%, while 11 cases were tubulovillous adenoma, accounting for 22%, and 2 cases were villous adenoma, accounting for only 4%. In the experimental adenoma group, tubular adenoma accounted for most. We speculate that the lack of correlation between VEGF expression and MVD in the adenoma group may be due to the imbalance in the proportion of adenomas with various histological features included in the adenoma group, but it may also be speculated that VEGF does not predominate in the angiogenesis of early adenomas. The reasons leading to the inconsistent results of previous studies can be further clarified and confirmed by enlarging the sample size and equalizing the proportion of adenomas with different histological characteristics in the adenoma group.

CONCLUSION

In summary, PEDF and VEGF are both involved in the occurrence and development of CRC during the evolution of the sequence of "normal intestinal epithelium \rightarrow adenoma \rightarrow carcinoma". PEDF is an inhibitory factor of CRC, and VEGF is a promoting factor of CRC. PEDF may be expected to be a new target for early prevention and late treatment of CRC. Up-regulation of PEDF expression and inhibition of VEGF expression may provide new ideas for targeted therapy for CRC.

ARTICLE HIGHLIGHTS

Research background

The morbidity and mortality of colorectal cancer (CRC) are among the highest in the world. When the balance between pigment epithelium-derived factor (PEDF), which inhibits angiogenesis, and vascular endothelial growth factor (VEGF), which stimulates angiogenesis, is broken, it can lead to uncontrolled angiogenesis and promote the occurrence of tumors. Therefore, it is necessary to find more therapeutic targets for early intervention and late treatment of CRC.

Research motivation

The safety and efficacy of targeted drugs targeting VEGF in the treatment of CRC have been confirmed and promoted. PEDF is the anti-VEGF factor. At present, no toxicity caused by PEDF preparation itself has been observed in anti-tumor vascular animal models. It is worth exploring the possibility of PEDF as a new target for early prevention and late treatment of CRC.

Research objectives

Study of the expression and significance of PEDF, VEGF, and CD31-stained microvessel density values (CD31-MVD) in normal colorectal mucosa, adenoma, and CRC.

Research methods

We collected 50 cases of normal intestinal mucosa, 50 cases of colorectal adenoma and 50 cases of colon cancer as normal control group, adenoma group and CRC group, respectively. Immunohistochemical staining was used to detect the

expression of PEDF and VEGF in the three groups, and the differences were analyzed. The relationship between the expression of PEDF and VEGF and the clinicopathological factors of CRC was studied. CD31-MVD was recorded in the three groups, and the correlation between PEDF, VEGF and CD31-MVD in colorectal adenoma group and CRC group was analyzed.

Research results

The positive expression rate and expression intensity of PEDF in normal control group, adenoma group and CRC group gradually decreased, while that of VEGF gradually increased. In the CRC group, the positive expression rate of PEDF decreased with the increase of differentiation degree, invasion depth, lymph node metastasis, distant metastasis and TNM stage. The opposite was observed for VEGF high expression. In the colorectal adenoma group, the expression intensity of PEDF was negatively correlated with CD31-MVD, but there was no significant difference in VEGF expression. PEDF expression was negatively correlated with CD31-MVD and VEGF expression in CRC group. The expression of VEGF was positively correlated with CD31-MVD.

Research conclusions

It is possible that PEDF can be used as a new treatment and prevention target for CRC by upregulating the expression of PEDF while inhibiting the expression of VEGF.

Research perspectives

We will further expand our sample size to equalize the proportion of various types of adenomas in the colorectal adenoma group and the proportion of various pathological types of CRC in the CRC group to further confirm our conclusion.

ACKNOWLEDGEMENTS

In recognition of all the patients who have agreed to participate in this study, as well as the medical staff members and technicians who have provided technical assistance, we would like to express our gratitude.

FOOTNOTES

Author contributions: Wen W proposed and designed the project, provided scientific research funds, and coordinated and contacted various matters related to the pathology department; Zhang YJ, Liu XC and Yang XY collected the pathological specimens; Hu SS, Jiang Y and Yuan J performed the collection of patient data and summarized the experimental data; Yang Y did most of the experiments and wrote the first draft of the paper; Chen FL performed the statistical analysis of the data; all authors read, revised, and agreed to the final manuscript.

Institutional review board statement: The study was approved by the Ethics Committee of the Second People's Hospital of Chengdu.

Informed consent statement: All patients gave informed consent.

Conflict-of-interest statement: The authors declare no competing interests.

Data sharing statement: The data that support the findings of this study are available on request from the corresponding author, upon reasonable request.

STROBE statement: The authors have read the STROBE Statement—checklist of items, and the manuscript was prepared and revised according to the STROBE Statement—checklist of items.

Open-Access: This article is an open-access article that was selected by an in-house editor and fully peer-reviewed by external reviewers. It is distributed in accordance with the Creative Commons Attribution NonCommercial (CC BY-NC 4.0) license, which permits others to distribute, remix, adapt, build upon this work non-commercially, and license their derivative works on different terms, provided the original work is properly cited and the use is non-commercial. See: <https://creativecommons.org/licenses/by-nc/4.0/>

Country/Territory of origin: China

ORCID number: Ye Yang 0000-0002-2434-1382; Wu Wen 0000-0001-6192-132X; Feng-Lin Chen 0000-0002-1210-4523; Ying-Jie Zhang 0000-0002-5033-1217; Xiao-Cong Liu 0000-0002-7282-862X; Xiao-Yan Yang 0009-0004-8357-0523; Shan-Shan Hu 0000-0002-8238-3548; Ye Jiang 0009-0003-8121-5870; Jing Yuan 0009-0004-2614-2549.

S-Editor: Gong ZM

L-Editor: A

P-Editor: Cai YX

REFERENCES

- 1 **Sung H**, Ferlay J, Siegel RL, Laversanne M, Soerjomataram I, Jemal A, Bray F. Global Cancer Statistics 2020: GLOBOCAN Estimates of Incidence and Mortality Worldwide for 36 Cancers in 185 Countries. *CA Cancer J Clin* 2021; **71**: 209-249 [PMID: [33538338](#) DOI: [10.3322/caac.21660](#)]
- 2 **Hagggar FA**, Boushey RP. Colorectal cancer epidemiology: incidence, mortality, survival, and risk factors. *Clin Colon Rectal Surg* 2009; **22**: 191-197 [PMID: [21037809](#) DOI: [10.1055/s-0029-1242458](#)]
- 3 **Morgan E**, Arnold M, Gini A, Lorenzoni V, Cabasag CJ, Laversanne M, Vignat J, Ferlay J, Murphy N, Bray F. Global burden of colorectal cancer in 2020 and 2040: incidence and mortality estimates from GLOBOCAN. *Gut* 2023; **72**: 338-344 [PMID: [36604116](#) DOI: [10.1136/gutjnl-2022-327736](#)]
- 4 **Leslie A**, Carey FA, Pratt NR, Steele RJ. The colorectal adenoma-carcinoma sequence. *Br J Surg* 2002; **89**: 845-860 [PMID: [12081733](#) DOI: [10.1046/j.1365-2168.2002.02120.x](#)]
- 5 **Lepore Signorile M**, Grossi V, Fasano C, Simone C. Colorectal Cancer Chemoprevention: A Dream Coming True? *Int J Mol Sci* 2023; **24** [PMID: [37108756](#) DOI: [10.3390/ijms24087597](#)]
- 6 **Chinese Society of Gastroenterology**; Cancer Collaboration Group of Chinese Society of Gastroenterology; Chinese Medical Association. Chinese consensus on prevention of colorectal neoplasia (2021, Shanghai). *J Dig Dis* 2022; **23**: 58-90 [PMID: [34984819](#) DOI: [10.1111/1751-2980.13079](#)]
- 7 **Li J**, Ma X, Chakravarti D, Shalapour S, DePinho RA. Genetic and biological hallmarks of colorectal cancer. *Genes Dev* 2021; **35**: 787-820 [PMID: [34074695](#) DOI: [10.1101/gad.348226.120](#)]
- 8 **Xi X**, Fu Z, Liu T, Lin Y, Wu W, Li J, Luo M, Zhang B. Establishment and Verification of Scoring System for Colorectal Adenoma Recurrence. *Risk Manag Healthc Policy* 2021; **14**: 4545-4552 [PMID: [34785963](#) DOI: [10.2147/RMHP.S316408](#)]
- 9 **Hao Y**, Wang Y, Qi M, He X, Zhu Y, Hong J. Risk Factors for Recurrent Colorectal Polyps. *Gut Liver* 2020; **14**: 399-411 [PMID: [31547641](#) DOI: [10.5009/gnl19097](#)]
- 10 **Folkman J**. Tumor angiogenesis: therapeutic implications. *N Engl J Med* 1971; **285**: 1182-1186 [PMID: [4938153](#) DOI: [10.1056/nejm197111182852108](#)]
- 11 **Lugano R**, Ramachandran M, Dimberg A. Tumor angiogenesis: causes, consequences, challenges and opportunities. *Cell Mol Life Sci* 2020; **77**: 1745-1770 [PMID: [31690961](#) DOI: [10.1007/s00018-019-03351-7](#)]
- 12 **Leung DW**, Cachianes G, Kuang WJ, Goeddel DV, Ferrara N. Vascular endothelial growth factor is a secreted angiogenic mitogen. *Science* 1989; **246**: 1306-1309 [PMID: [2479986](#) DOI: [10.1126/science.2479986](#)]
- 13 **Ferrara N**. Vascular endothelial growth factor. *Trends Cardiovasc Med* 1993; **3**: 244-250 [PMID: [21244915](#) DOI: [10.1016/1050-1738\(93\)90046-9](#)]
- 14 **Mohamed AH**, Said NM. Immunohistochemical Expression of Fatty Acid Synthase and Vascular Endothelial Growth Factor in Primary Colorectal Cancer: a Clinicopathological Study. *J Gastrointest Cancer* 2019; **50**: 485-492 [PMID: [29681001](#) DOI: [10.1007/s12029-018-0104-5](#)]
- 15 **Balasubramanian S**, Priyatharsini N, Johnson T. Expression of Vascular Endothelial Growth Factor (VEGF) in Colorectal Adenoma and Carcinoma in a Tertiary Care Center. *Cureus* 2022; **14**: e31393 [PMID: [36514651](#) DOI: [10.7759/cureus.31393](#)]
- 16 **Nikolaev AA**, Babkina IV, Gershtein ES, Alferov AA, Delektorskaya VV, Mamedli ZZ, Kushlinskii NE. Prognostic significance of the TNM system criteria, levels of serum insulin-like growth factors and their transport proteins, VEGF and MMP-7 in colorectal cancer. *Klin Lab Diagn* 2021; **66**: 459-464 [PMID: [34388315](#) DOI: [10.51620/0869-2084-2021-66-8-459-464](#)]
- 17 **Mohamed SY**, Mohammed HL, Ibrahim HM, Mohamed EM, Salah M. Role of VEGF, CD105, and CD31 in the Prognosis of Colorectal Cancer Cases. *J Gastrointest Cancer* 2019; **50**: 23-34 [PMID: [29110224](#) DOI: [10.1007/s12029-017-0014-y](#)]
- 18 **Apte RS**, Chen DS, Ferrara N. VEGF in Signaling and Disease: Beyond Discovery and Development. *Cell* 2019; **176**: 1248-1264 [PMID: [30849371](#) DOI: [10.1016/j.cell.2019.01.021](#)]
- 19 **Hur H**, Kim NK, Min BS, Baik SH, Lee KY, Koom WS, Ahn JB, Kim H. Can a biomarker-based scoring system predict pathologic complete response after preoperative chemoradiotherapy for rectal cancer? *Dis Colon Rectum* 2014; **57**: 592-601 [PMID: [24819099](#) DOI: [10.1097/DCR.000000000000109](#)]
- 20 **Shpitz B**, Gochberg S, Neufeld D, Grankin M, Buklan G, Klein E, Bernheim J. Angiogenic switch in earliest stages of human colonic tumorigenesis. *Anticancer Res* 2003; **23**: 5153-5157 [PMID: [14981982](#)]
- 21 **Ruffolo C**, Ferrara F, Trevellin E, Cataldo I, Fornasier C, Pozza A, Campo Dell'Orto M, Angriman I, Dei Tos AP, Bardini R, Massani M, Kotsafti A, Scarpa M. Can Vascular Endothelial Growth Factors and CD34 Expression Implement NICE (Narrow-Band Imaging International Colorectal Endoscopic) Classification in Colorectal Polypoid Lesion Diagnosis? *Eur Surg Res* 2020; **61**: 72-82 [PMID: [33080605](#) DOI: [10.1159/000510266](#)]
- 22 **Wang Y**, Liu X, Quan X, Qin X, Zhou Y, Liu Z, Chao Z, Jia C, Qin H, Zhang H. Pigment epithelium-derived factor and its role in microvascular-related diseases. *Biochimie* 2022; **200**: 153-171 [PMID: [35661748](#) DOI: [10.1016/j.biochi.2022.05.019](#)]
- 23 **Zhu L**, Xie J, Liu Z, Huang Z, Huang M, Yin H, Qi W, Yang Z, Zhou T, Gao G, Zhang J, Yang X. Pigment epithelium-derived factor/vascular endothelial growth factor ratio plays a crucial role in the spontaneous regression of infant hemangioma and in the therapeutic effect of propranolol. *Cancer Sci* 2018; **109**: 1981-1994 [PMID: [29664206](#) DOI: [10.1111/cas.13611](#)]
- 24 **Fan W**, Crawford R, Xiao Y. The ratio of VEGF/PEDF expression in bone marrow mesenchymal stem cells regulates neovascularization. *Differentiation* 2011; **81**: 181-191 [PMID: [21236558](#) DOI: [10.1016/j.diff.2010.12.003](#)]
- 25 **Tombran-Tink J**, Johnson LV. Neuronal differentiation of retinoblastoma cells induced by medium conditioned by human RPE cells. *Invest Ophthalmol Vis Sci* 1989; **30**: 1700-1707 [PMID: [2668219](#)]
- 26 **Steele FR**, Chader GJ, Johnson LV, Tombran-Tink J. Pigment epithelium-derived factor: neurotrophic activity and identification as a member of the serine protease inhibitor gene family. *Proc Natl Acad Sci U S A* 1993; **90**: 1526-1530 [PMID: [8434014](#) DOI: [10.1073/pnas.90.4.1526](#)]
- 27 **Dawson DW**, Volpert OV, Gillis P, Crawford SE, Xu H, Benedict W, Bouck NP. Pigment epithelium-derived factor: a potent inhibitor of angiogenesis. *Science* 1999; **285**: 245-248 [PMID: [10398599](#) DOI: [10.1126/science.285.5425.245](#)]
- 28 **Xu M**, Chen X, Yu Z, Li X. Receptors that bind to PEDF and their therapeutic roles in retinal diseases. *Front Endocrinol (Lausanne)* 2023; **14**: 1116136 [PMID: [37139333](#) DOI: [10.3389/fendo.2023.1116136](#)]
- 29 **Rebutini IT**, Bernardo-Colón A, Nalvarte AI, Becerra SP. Delivery Systems of Retinoprotective Proteins in the Retina. *Int J Mol Sci* 2021; **22** [PMID: [34069505](#) DOI: [10.3390/ijms22105344](#)]

- 30 Crawford SE, Stellmach V, Ranalli M, Huang X, Huang L, Volpert O, De Vries GH, Abramson LP, Bouck N. Pigment epithelium-derived factor (PEDF) in neuroblastoma: a multifunctional mediator of Schwann cell antitumor activity. *J Cell Sci* 2001; **114**: 4421-4428 [PMID: 11792807 DOI: 10.1242/jcs.114.24.4421]
- 31 Smith ND, Schulze-Hoepfner FT, Veliceasa D, Filleul S, Shareef S, Huang L, Huang XM, Volpert OV. Pigment epithelium-derived factor and interleukin-6 control prostate neuroendocrine differentiation *via* feed-forward mechanism. *J Urol* 2008; **179**: 2427-2434 [PMID: 18433784 DOI: 10.1016/j.juro.2008.01.081]
- 32 Tombran-Tink J, Mazuruk K, Rodriguez IR, Chung D, Linker T, Englander E, Chader GJ. Organization, evolutionary conservation, expression and unusual Alu density of the human gene for pigment epithelium-derived factor, a unique neurotrophic serpin. *Mol Vis* 1996; **2**: 11 [PMID: 9238088]
- 33 Xu X, Zhang SS, Barnstable CJ, Tombran-Tink J. Molecular phylogeny of the antiangiogenic and neurotrophic serpin, pigment epithelium derived factor in vertebrates. *BMC Genomics* 2006; **7**: 248 [PMID: 17020603 DOI: 10.1186/1471-2164-7-248]
- 34 Tombran-Tink J, Pawar H, Swaroop A, Rodriguez I, Chader GJ. Localization of the gene for pigment epithelium-derived factor (PEDF) to chromosome 17p13.1 and expression in cultured human retinoblastoma cells. *Genomics* 1994; **19**: 266-272 [PMID: 8188257 DOI: 10.1006/geno.1994.1057]
- 35 Onger ME, Altun G, Yildiran A. Pigment epithelium-derived factor enhances peripheral nerve regeneration through modulating oxidative stress and stem cells: An experimental study. *Anat Rec (Hoboken)* 2023; **306**: 2621-2635 [PMID: 36787348 DOI: 10.1002/ar.25177]
- 36 Zhang C, Yang W, Zhang S, Zhang Y, Liu P, Li X, Zhi W, Yang D, Li M, Lu Y. Pan-cancer analysis of osteogenesis imperfecta causing gene SERPINF1. *Intractable Rare Dis Res* 2022; **11**: 15-24 [PMID: 35261846 DOI: 10.5582/irdr.2021.01138]
- 37 Ma B, Zhou Y, Liu R, Zhang K, Yang T, Hu C, Gao Y, Lan Q, Liu Y, Yang X, Qi H. Pigment epithelium-derived factor (PEDF) plays anti-inflammatory roles in the pathogenesis of dry eye disease. *Ocul Surf* 2021; **20**: 70-85 [PMID: 33412338 DOI: 10.1016/j.jtos.2020.12.007]
- 38 Yang X, Wang L, Zhang Z, Hu J, Liu X, Wen H, Liu M, Zhang X, Dai H, Ni M, Li R, Guo R, Zhang L, Luan X, Lin H, Dong M, Lu H. Ginsenoside Rb(1) Enhances Plaque Stability and Inhibits Adventitial Vasa Vasorum *via* the Modulation of miR-33 and PEDF. *Front Cardiovasc Med* 2021; **8**: 654670 [PMID: 34124194 DOI: 10.3389/fcvm.2021.654670]
- 39 Brook N, Brook E, Dass CR, Chan A, Dharmarajan A. Pigment Epithelium-Derived Factor and Sex Hormone-Responsive Cancers. *Cancers (Basel)* 2020; **12** [PMID: 33238558 DOI: 10.3390/cancers12113483]
- 40 Tsuruhisa S, Matsui T, Koga Y, Sotokawauchi A, Yagi M, Yamagishi SI. Pigment epithelium-derived factor inhibits advanced glycation end product-induced proliferation, VEGF and MMP-9 expression in breast cancer cells *via* interaction with laminin receptor. *Oncol Lett* 2021; **22**: 629 [PMID: 34267821 DOI: 10.3892/ol.2021.12890]
- 41 Miao H, Hui H, Li H, Lin Y, Li D, Luo M, Jiang B, Zhang Y. PEDF inhibits nonsmall cell lung cancer proliferation by suppressing autophagy through downregulation of AMPKULK1 signaling. *Oncol Rep* 2022; **48** [PMID: 36281945 DOI: 10.3892/or.2022.8434]
- 42 Ansari D, Althini C, Ohlsson H, Bauden M, Andersson R. The Role of PEDF in Pancreatic Cancer. *Anticancer Res* 2019; **39**: 3311-3315 [PMID: 31262851 DOI: 10.21873/anticancer.13473]
- 43 Ribaux P, Wuillemin C, Petignat P, Delie F, Cohen M. NANO-SBT-PEDF delivery system: A promising approach against ovarian cancer? *Heliyon* 2023; **9**: e13676 [PMID: 36873150 DOI: 10.1016/j.heliyon.2023.e13676]
- 44 Ferreira DP, Martini SV, Oliveira HA, Silva AL, Shenoy S, Chen D, Simon V, Han E, West NE, Suk JS, Rocco PRM, Peters-Silva H, Morales MM, Cruz FF. Tyrosine-Mutant AAV8 Vector Mediated Efficient and Safe Gene Transfer of Pigment Epithelium-Derived Factor to Mouse Lungs. *Cell Physiol Biochem* 2023; **57**: 331-344 [PMID: 37724045 DOI: 10.33594/000000660]
- 45 Abooshahab R, Al-Salami H, Dass CR. The increasing role of pigment epithelium-derived factor in metastasis: from biological importance to a promising target. *Biochem Pharmacol* 2021; **193**: 114787 [PMID: 34571004 DOI: 10.1016/j.bcp.2021.114787]
- 46 Cheng G, Song C. Association of pigment epithelium derived factor expression with cancer progression and prognosis: a meta-analysis study. *Discov Oncol* 2021; **12**: 61 [PMID: 35201465 DOI: 10.1007/s12672-021-00457-y]
- 47 Ji D, Li M, Zhan T, Yao Y, Shen J, Tian H, Zhang Z, Gu J. Prognostic role of serum AZGP1, PEDF and PRDX2 in colorectal cancer patients. *Carcinogenesis* 2013; **34**: 1265-1272 [PMID: 23393224 DOI: 10.1093/carcin/bgt056]
- 48 Wägsäter D, Löfgren S, Zar N, Hugander A, Dimberg J. Pigment epithelium-derived factor expression in colorectal cancer patients. *Cancer Invest* 2010; **28**: 872-877 [PMID: 20504225 DOI: 10.3109/07357901003735675]
- 49 Hurwitz H, Fehrenbacher L, Novotny W, Cartwright T, Hainsworth J, Heim W, Berlin J, Baron A, Griffing S, Holmgren E, Ferrara N, Fyfe G, Rogers B, Ross R, Kabbinavar F. Bevacizumab plus irinotecan, fluorouracil, and leucovorin for metastatic colorectal cancer. *N Engl J Med* 2004; **350**: 2335-2342 [PMID: 15175435 DOI: 10.1056/NEJMoa032691]
- 50 Deliu IC, Neagoe CD, Beznă M, Genunche-Dumitrescu AV, Toma SC, Ungureanu BS, Uscatu CD, Beznă MC, Lungulescu CV, Pădureanu V, Gheonea DI, Ciurea T, Forțofoiu M. Correlations between endothelial cell markers CD31, CD34 and CD105 in colorectal carcinoma. *Rom J Morphol Embryol* 2016; **57**: 1025-1030 [PMID: 28002519]
- 51 Harries RL, Owen S, Ruge F, Morgan M, Li J, Zhang Z, Harding KG, Torkington J, Jiang WG, Cai J. Impact of pigment epithelium-derived factor on colorectal cancer *in vitro* and *in vivo*. *Oncotarget* 2018; **9**: 19192-19202 [PMID: 29721193 DOI: 10.18632/oncotarget.24953]
- 52 Das SR, Saleh AF, Hossain SA, Jannat HE, Hossain T. Vascular Endothelial Growth Factor Expression in Colorectal Adenocarcinoma of Resected Samples and its Association with Histological Grade and Pathological Stage. *Mymensingh Med J* 2022; **31**: 642-648 [PMID: 35780345]
- 53 Wang Y, Yao X, Ge J, Hu F, Zhao Y. Can vascular endothelial growth factor and microvessel density be used as prognostic biomarkers for colorectal cancer? A systematic review and meta-analysis. *ScientificWorldJournal* 2014; **2014**: 102736 [PMID: 25143961 DOI: 10.1155/2014/102736]
- 54 Park SY, Matte A, Jung Y, Ryu J, Anand WB, Han EY, Liu M, Carbone C, Melisi D, Nagasawa T, Locascio JJ, Lin CP, Silberstein LE, De Franceschi L. Pathologic angiogenesis in the bone marrow of humanized sickle cell mice is reversed by blood transfusion. *Blood* 2020; **135**: 2071-2084 [PMID: 31990287 DOI: 10.1182/blood.2019002227]
- 55 Al-Ostoot FH, Salah S, Khamees HA, Khanum SA. Tumor angiogenesis: Current challenges and therapeutic opportunities. *Cancer Treat Res Commun* 2021; **28**: 100422 [PMID: 34147821 DOI: 10.1016/j.ctarc.2021.100422]
- 56 Cheng G, Zhong M, Kawaguchi R, Kassai M, Al-Ubaidi M, Deng J, Ter-Stepanian M, Sun H. Identification of PLXDC1 and PLXDC2 as the transmembrane receptors for the multifunctional factor PEDF. *Elife* 2014; **3**: e05401 [PMID: 25535841 DOI: 10.7554/eLife.05401]
- 57 Beaty RM, Edwards JB, Boon K, Siu IM, Conway JE, Riggins GJ. PLXDC1 (TEM7) is identified in a genome-wide expression screen of glioblastoma endothelium. *J Neurooncol* 2007; **81**: 241-248 [PMID: 17031559 DOI: 10.1007/s11060-006-9227-9]

- 58 **van Beijnum JR**, Petersen K, Griffioen AW. Tumor endothelium is characterized by a matrix remodeling signature. *Front Biosci (Schol Ed)* 2009; **1**: 216-225 [PMID: [19482697](#) DOI: [10.2741/s21](#)]
- 59 **Bagley RG**, Rouleau C, Weber W, Mehraein K, Smale R, Curiel M, Callahan M, Roy A, Boutin P, St Martin T, Nacht M, Teicher BA. Tumor endothelial marker 7 (TEM-7): a novel target for antiangiogenic therapy. *Microvasc Res* 2011; **82**: 253-262 [PMID: [21958527](#) DOI: [10.1016/j.mvr.2011.09.004](#)]
- 60 **Pietrzyk L**, Wdowiak P. Serum TEM5 and TEM7 concentrations correlate with clinicopathologic features and poor prognosis of colorectal cancer patients. *Adv Med Sci* 2019; **64**: 402-408 [PMID: [31352222](#) DOI: [10.1016/j.advms.2019.07.001](#)]
- 61 **Yamamoto N**, Eguchi A, Hirokawa Y, Ogura S, Sugimoto K, Iwasa M, Watanabe M, Takei Y. Expression Pattern of Plexin Domain Containing 2 in Human Hepatocellular Carcinoma. *Monoclon Antib Immunodiagn Immunother* 2020; **39**: 57-60 [PMID: [32202949](#) DOI: [10.1089/mab.2019.0050](#)]
- 62 **Wu B**, Wang YX, Wang JJ, Xiang DF, Zhang MS, Yan ZX, Wang WY, Miao JY, Lan X, Liu JJ, Li ZY, Li C, Fan JY, Liu JY, Jiang L, Xu SL, Cui YH, Qian F. PLXDC2 enhances invadopodium formation to promote invasion and metastasis of gastric cancer cells *via* interacting with PTP1B. *Clin Exp Metastasis* 2022; **39**: 691-710 [PMID: [35661947](#) DOI: [10.1007/s10585-022-10168-5](#)]
- 63 **Greening DW**, Kapp EA, Ji H, Speed TP, Simpson RJ. Colon tumour secretome: insights into endogenous proteolytic cleavage events in the colon tumour microenvironment. *Biochim Biophys Acta* 2013; **1834**: 2396-2407 [PMID: [23684732](#) DOI: [10.1016/j.bbapap.2013.05.006](#)]
- 64 **Mabeta P**, Steenkamp V. The VEGF/VEGFR Axis Revisited: Implications for Cancer Therapy. *Int J Mol Sci* 2022; **23** [PMID: [36555234](#) DOI: [10.3390/ijms232415585](#)]
- 65 **Kruszyna L**, Murawa D, Jagodziński PP, Osżkinis G, Krasiński Z. The Expression and Prognostic Significance of VEGF and CXCR4 in Gastric Cancer: Correlation with Angiogenesis, Lymphangiogenesis and Progression. *Curr Issues Mol Biol* 2022; **44**: 3075-3088 [PMID: [35877436](#) DOI: [10.3390/cimb44070212](#)]
- 66 **Volpert OV**, Zaichuk T, Zhou W, Reiher F, Ferguson TA, Stuart PM, Amin M, Bouck NP. Inducer-stimulated Fas targets activated endothelium for destruction by anti-angiogenic thrombospondin-1 and pigment epithelium-derived factor. *Nat Med* 2002; **8**: 349-357 [PMID: [11927940](#) DOI: [10.1038/nm0402-349](#)]
- 67 **Cai J**, Jiang WG, Grant MB, Boulton M. Withdrawal: Pigment epithelium-derived factor inhibits angiogenesis *via* regulated intracellular proteolysis of vascular endothelial growth factor receptor 1. *J Biol Chem* 2006; **281**: 3604-3613 [PMID: [16339148](#) DOI: [10.1074/jbc.M507401200](#)]
- 68 **Xie YH**, Chen YX, Fang JY. Comprehensive review of targeted therapy for colorectal cancer. *Signal Transduct Target Ther* 2020; **5**: 22 [PMID: [32296018](#) DOI: [10.1038/s41392-020-0116-z](#)]
- 69 **Wang JS**, Cheng Q, Zhang AL, Guo YF, Dang YM. Expression difference of vascular endothelial growth factor and its relationship with angiogenesis in colorectal adenoma and non-neoplastic polyp. *Xibei Guofang Yixue Zazhi* 2006; **27**: 405-407 [DOI: [10.3969/j.issn.1007-8622.2006.06.002](#)]
- 70 **Song M**, Emilsson L, Bozorg SR, Nguyen LH, Joshi AD, Staller K, Naylor J, Chan AT, Ludvigsson JF. Risk of colorectal cancer incidence and mortality after polypectomy: a Swedish record-linkage study. *Lancet Gastroenterol Hepatol* 2020; **5**: 537-547 [PMID: [32192628](#) DOI: [10.1016/S2468-1253\(20\)30009-1](#)]



Published by **Baishideng Publishing Group Inc**
7041 Koll Center Parkway, Suite 160, Pleasanton, CA 94566, USA

Telephone: +1-925-3991568

E-mail: office@baishideng.com

Help Desk: <https://www.f6publishing.com/helpdesk>

<https://www.wjgnet.com>

