

# World Journal of *Stem Cells*

*World J Stem Cells* 2022 April 26; 14(4): 267-317



## Contents

Monthly Volume 14 Number 4 April 26, 2022

## REVIEW

- 267 Correlation between amino acid metabolism and self-renewal of cancer stem cells: Perspectives in cancer therapy  
*Zhang Q, Li W*

## SYSTEMATIC REVIEWS

- 287 Dental stem cell-conditioned medium for tissue regeneration: Optimization of production and storage  
*Chouaib B, Cuisinier F, Collart-Dutilleul PY*

## CASE REPORT

- 303 Treatment of syringomyelia using uncultured umbilical cord mesenchymal stem cells: A case report and review of literature  
*Ahn H, Lee SY, Jung WJ, Lee KH*

## LETTER TO THE EDITOR

- 310 Downregulation of miRNA-21 and cancer stem cells after chemotherapy results in better outcome in breast cancer patients  
*Dwivedi S, Pareek P, Vishnoi JR, Sharma P, Misra S*
- 314 Skinny people serum factors promote the differentiation of multipotent stem cells into brown adipose tissue  
*Gu YL, Shen W, Li ZP, Zhou B, Lin ZJ, He LP*

**ABOUT COVER**

Editorial Board Member of *World Journal of Stem Cells*, José Bragança, PhD, Associate Professor, Faculty of Medicine and Biomedical Sciences, Algarve BioMedical Centre Research Institute, University of Faro, Campus de Gambelas 8005-139, Portugal. jebraganca@ualg.pt

**AIMS AND SCOPE**

The primary aim of *World Journal of Stem Cells (WJSC, World J Stem Cells)* is to provide scholars and readers from various fields of stem cells with a platform to publish high-quality basic and clinical research articles and communicate their research findings online. *WJSC* publishes articles reporting research results obtained in the field of stem cell biology and regenerative medicine, related to the wide range of stem cells including embryonic stem cells, germline stem cells, tissue-specific stem cells, adult stem cells, mesenchymal stromal cells, induced pluripotent stem cells, embryonal carcinoma stem cells, hemangioblasts, lymphoid progenitor cells, etc.

**INDEXING/ABSTRACTING**

The *WJSC* is now indexed in Science Citation Index Expanded (also known as SciSearch®), Journal Citation Reports/Science Edition, Biological Abstracts, BIOSIS Previews, Scopus, PubMed, and PubMed Central. The 2021 Edition of Journal Citation Reports® cites the 2020 impact factor (IF) for *WJSC* as 5.326; IF without journal self cites: 5.035; 5-year IF: 4.956; Journal Citation Indicator: 0.55; Ranking: 14 among 29 journals in cell and tissue engineering; Quartile category: Q2; Ranking: 72 among 195 journals in cell biology; and Quartile category: Q2. The *WJSC*'s CiteScore for 2020 is 3.1 and Scopus CiteScore rank 2020: Histology is 31/60; Genetics is 205/325; Genetics (clinical) is 64/87; Molecular Biology is 285/382; Cell Biology is 208/279.

**RESPONSIBLE EDITORS FOR THIS ISSUE**

Production Editor: Yan-Liang Zhang; Production Department Director: Xu Guo; Editorial Office Director: Ze-Mao Gong.

**NAME OF JOURNAL**

*World Journal of Stem Cells*

**ISSN**

ISSN 1948-0210 (online)

**LAUNCH DATE**

December 31, 2009

**FREQUENCY**

Monthly

**EDITORS-IN-CHIEF**

Shengwen Calvin Li, Carlo Ventura

**EDITORIAL BOARD MEMBERS**

<https://www.wjnet.com/1948-0210/editorialboard.htm>

**PUBLICATION DATE**

April 26, 2022

**COPYRIGHT**

© 2022 Baishideng Publishing Group Inc

**INSTRUCTIONS TO AUTHORS**

<https://www.wjnet.com/bpg/gerinfo/204>

**GUIDELINES FOR ETHICS DOCUMENTS**

<https://www.wjnet.com/bpg/GerInfo/287>

**GUIDELINES FOR NON-NATIVE SPEAKERS OF ENGLISH**

<https://www.wjnet.com/bpg/gerinfo/240>

**PUBLICATION ETHICS**

<https://www.wjnet.com/bpg/GerInfo/288>

**PUBLICATION MISCONDUCT**

<https://www.wjnet.com/bpg/gerinfo/208>

**ARTICLE PROCESSING CHARGE**

<https://www.wjnet.com/bpg/gerinfo/242>

**STEPS FOR SUBMITTING MANUSCRIPTS**

<https://www.wjnet.com/bpg/GerInfo/239>

**ONLINE SUBMISSION**

<https://www.f6publishing.com>

# Treatment of syringomyelia using uncultured umbilical cord mesenchymal stem cells: A case report and review of literature

Hyunjun Ahn, Sang Yeon Lee, Won-Ju Jung, Kye-Ho Lee

**Specialty type:** Cell and tissue engineering

**Provenance and peer review:** Unsolicited article; Externally peer reviewed.

**Peer-review model:** Single blind

**Peer-review report's scientific quality classification**

Grade A (Excellent): 0  
Grade B (Very good): B, B  
Grade C (Good): C, C  
Grade D (Fair): 0  
Grade E (Poor): 0

**P-Reviewer:** Bagheri-Mohammadi S, Iran; Ke X, China; Naserian S, France

**Received:** December 13, 2021

**Peer-review started:** December 13, 2021

**First decision:** January 30, 2022

**Revised:** February 28, 2022

**Accepted:** March 26, 2022

**Article in press:** March 26, 2022

**Published online:** April 26, 2022



**Hyunjun Ahn, Sang Yeon Lee, Kye-Ho Lee,** Stem Cell Treatment and Research Institute (STRI), bio Beauty and Health Company (bBHC), Seoul 04420, South Korea

**Won-Ju Jung,** Stem Cell Treatment, 97.7 Beauty and Health Clinic, Seoul 04420, South Korea

**Corresponding author:** Kye-Ho Lee, PhD, Stem Cell Treatment and Research Institute (STRI), bio Beauty and Health Company (bBHC), No. 72 UN Village-gil, Yongsan-gu, Seoul 04420, South Korea. [khlee@stc365.com](mailto:khlee@stc365.com)

## Abstract

### BACKGROUND

Syringomyelia is a disease caused by the formation of a cavity inside the spinal cord and is accompanied by such symptoms as pain, paresthesia, and urination and defecation disorders, and in severe cases causes various paralyses. Currently, there are only surgical methods for the treatment of syringomyelia, but these methods carry the possibility of failure, recurrence, and side effects.

### CASE SUMMARY

The patient was a 59-year-old woman who suffered from pain due to syringomyelia. For treatment, the patient received transplant of uncultured umbilical cord-derived mesenchymal stem cells. As intended, the patient's pain was relieved after treatment. Interestingly, an additional benefit was found in that the size of the cavity also decreased. After 2 years from the last treatment, the patient's cavity had almost completely disappeared and her syringomyelia was deemed cured.

### CONCLUSION

Using uncultured umbilical cord-derived mesenchymal stem cells may be a new treatment alternative for syringomyelia.

**Key Words:** Syringomyelia; Umbilical cord mesenchymal stem cells; Cell therapy; Allogenic stem cells; Chiari malformations; Case report

©The Author(s) 2022. Published by Baishideng Publishing Group Inc. All rights reserved.

**Core Tip:** Syringomyelia has no suitable treatment other than surgical methods, but these methods carry the possibility of failure, recurrence, and side effects. In this study, we treated a patient with syringomyelia using uncultured umbilical cord-derived mesenchymal stem cells. This method could be a new treatment alternative for syringomyelia.

**Citation:** Ahn H, Lee SY, Jung WJ, Lee KH. Treatment of syringomyelia using uncultured umbilical cord mesenchymal stem cells: A case report and review of literature. *World J Stem Cells* 2022; 14(4): 303-309

**URL:** <https://www.wjgnet.com/1948-0210/full/v14/i4/303.htm>

**DOI:** <https://dx.doi.org/10.4252/wjsc.v14.i4.303>

## INTRODUCTION

Syringomyelia is a disease in which a cavity composed of fluid similar to cerebrospinal fluid or extracellular fluid is formed inside the spinal cord and gradually expands, thereby damaging the spinal nerves[1-4]. Cerebrospinal fluid is a bodily fluid that surrounds the brain and spinal cord and is known to protect the brain and spinal cord from external shocks and to transport nutrients and waste products [5]. Cerebrospinal fluid is produced in the choroid plexus of the ventricles located inside the brain and circulates in the subarachnoid space around the brain and spinal cord[6]. It is known that a spinal cavity is formed when the circulation of the cerebrospinal fluid is blocked in the subarachnoid space[1-4].

Various diseases can cause syringomyelia to include Chiari malformation, arachnoiditis, scoliosis, spinal tumors, spina bifida, and the like[4,7]. It is also known that syringomyelia can occur in patients with spinal cord injury due to trauma[4,8]. The most common sites for syringomyelia are the cervical and thoracic portions of the spinal cord, and sometimes even the medulla oblongata[1-4]. Symptoms caused by syringomyelia vary, depending on the scope. Patients may experience pain, abnormal sensations, and loss of sensation[4,9]. If the autonomic nervous system is invaded, then abnormal body temperature and defecation and urination disorders may occur[10]. If syringomyelia affects the medulla oblongata, then paralysis and atrophy of the tongue, difficulty swallowing, dysarthria, and facial paralysis may occur[4]. If syringomyelia is not treated, the 10-year survival rate is known to be about 50%[4]. In particular, post-traumatic syringomyelia can range from transient neurological deficits due to minor trauma to complete paralysis of the upper and lower limbs[1,4,8].

To date, surgery has been the only treatment method for syringomyelia[4,11,12]. Surgical treatment for syringomyelia focuses on the cause of the cavity and reducing the pressure of the subarachnoid space, and the shunt is mainly used to draw fluid out from the cavity[13,14]. In the case of Chiari malformation, the subarachnoid space is enlarged with foramen magnum decompression and dura mater plastic surgery, and the cerebellar tonsils that obstruct the flow of cerebrospinal fluid are excised. However, these surgical treatments are suboptimal for the treatment of syringomyelia[15-17]. While this treatment prevents further nerve damage and can be expected to improve symptoms, there is a risk of complications such as bleeding, inflammation, and nerve damage. After surgery, symptoms may continue to worsen or the cavity may become enlarged[17]. Therefore, surgery is usually not performed unless symptoms worsen after the observation period of the patient's progress.

In this study, we transplanted uncultured umbilical cord-derived mesenchymal stem cells (UC-MSCs) for the purpose of alleviating pain in a patient with syringomyelia. At the beginning of treatment, it was expected that this treatment would be effective in relieving pain, but it was not expected that the syringomyelia would be cured. As intended, the patient's disease-related pain gradually decreased. After the stem cell treatment, the patient also experienced an unexpected positive change which was observed during subsequent regular check-ups for follow-up after surgery for the Chiari malformation. First detected as a slight decrease in the patient's cavity size, the shrinkage continued until the cavity had almost completely disappeared at 2 years after the stem cell treatment. Although we could not elucidate the underlying mechanism of this beneficial outcome, we expect that the transplantation of uncultured UC-MSCs may have produced a direct or indirect effect on both her syringomyelia and related Chiari malformation.

## CASE PRESENTATION

### Chief complaints

On May 25, 2016, a 59-year-old woman, suffering from syringomyelia, visited our clinic. The patient had extreme symptoms of pain and dysphonia. The patient reported suffering particularly from pain in the eye, hand, and knee, as well as myalgia and occipital headache.



**History of present illness**

The patient reported having started experiencing neck and hand pain after a fall in 2009, with those pain symptoms having persisted for more than 1 year. In July 2010, the patient was diagnosed with Chiari malformation with syringomyelia. The patient underwent foramen magnum decompression on November 22, 2010, to treat the Chiari malformation and syringomyelia. After surgery, however, the imaging analysis revealed no changes at the C6-T2 level of the spinal cord in the localized syringomyelia (Figure 1A and B). Subsequent magnetic resonance imaging investigations of the extended cervical spine were performed on August 29, 2011 and August 22, 2012, to check changes in the cavity's size (Figure 1C-F). The data showed no significant changes at the C6-T2 level of the spinal cord in the localized cavity compared to imaging findings from 21 mo prior. The patient did not receive any additional treatment related to this disease other than the treatment received at our clinic after surgery.

**History of past illness**

The patient had no specific disease, except for Chiari malformation with syringomyelia.

**Personal and family history**

The patient had no relevant personal and family disease histories.

**Physical examination**

At the time of the first visit, the patient participated in a brief question-and-answer session to confirm the symptoms. The patient's pronunciation was not clear (but understandable) due to dysphonia. The patient also reported experiencing eye, hand, and knee pain, myalgia, and occipital headache at that time.

**Laboratory examinations**

Overall, there were no abnormalities on the routine blood and urine tests but total cholesterol (217 mg/dL; normal range: < 200 mg/dL) and low-density lipoprotein cholesterol (157 mg/dL; normal range: < 130 mg/dL) levels were borderline high.

**Imaging examinations**

Imaging examinations were not performed.

---

**FINAL DIAGNOSIS**

---

The patient was diagnosed with syringomyelia and was suffering from substantial pain and dysphonia.

---

**TREATMENT**

---

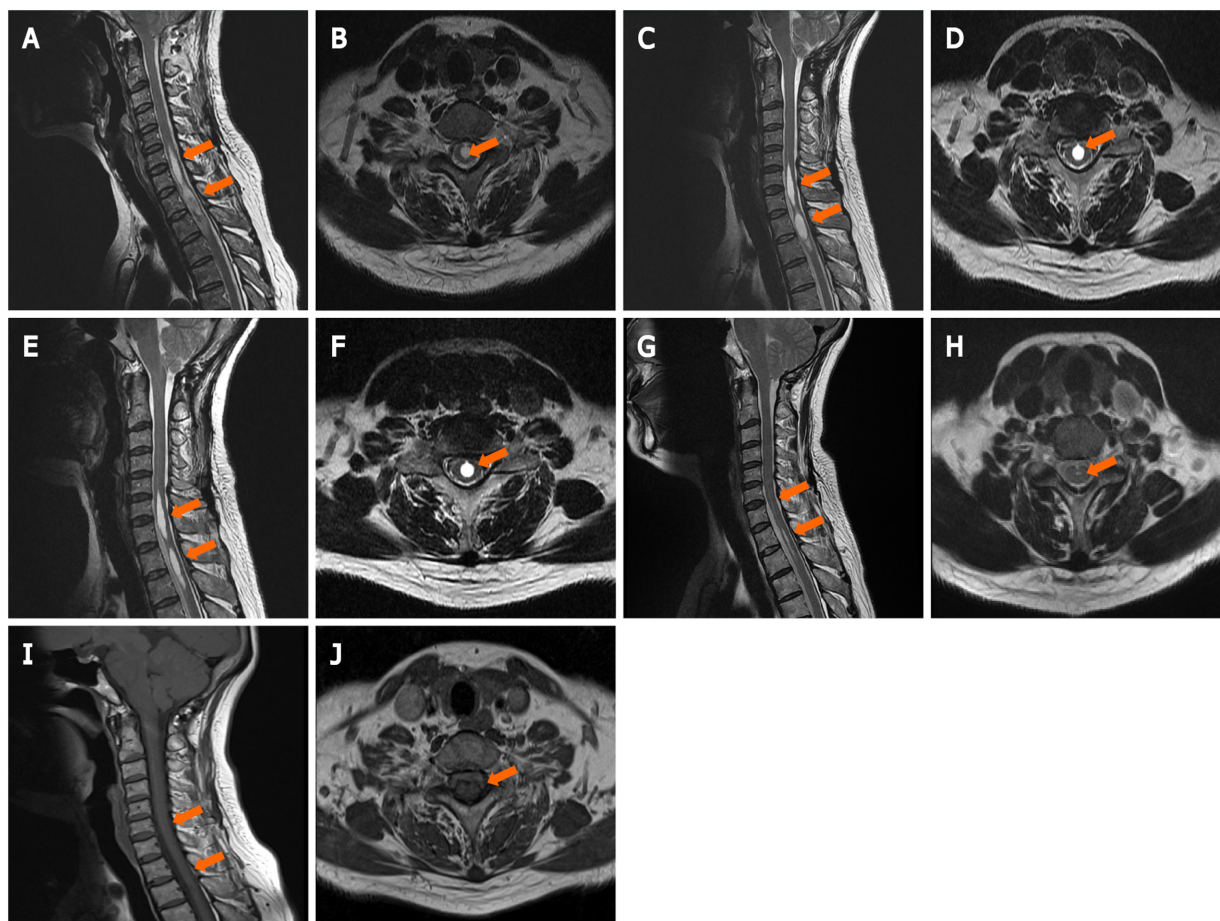
**UC procurement**

UCs were donated by the Obstetrics and Gynecology Department at Lynn Woman's Hospital (Seoul, South Korea). The mothers who had donated the UCs had signed informed consent forms. All UCs were confirmed for safety through various tests of the mothers' blood and urine.

**Isolation and quality evaluation of UC-MSCs**

UC-MSCs were obtained from the donated UCs. The isolation method is as follows[18-21]. The UCs were disinfected with 70% ethanol and washed with 1 × phosphate-buffered saline. Next, three vessels and the amniotic membrane were removed from the UCs. Then, the UC tissues were cut into 2-3 cm pieces and placed into a 50-mL conical tube containing collagenase and hyaluronidase mixture solution. The UC tissues were then cut into smaller pieces using surgical scissors and ground using a disposable tissue grinder. Following, the ground tissues were placed in a 37 °C incubator with 50 mL/L CO<sub>2</sub> for 1 h. After filtration of the solution using a 100-μm filter, the UC-MSCs were harvested by centrifugation of the flow-through. The UC-MSCs were frozen using CryoStor® CS10 (Stemcell Technologies, Cambridge, MA, United States) and then stored at -80 °C for a day. The following day, the frozen cells were stored in liquid nitrogen.

The isolated UC-MSCs were analyzed by the expression level of MSC-specific proteins, such as CD73, CD90, and CD105. A CyFlow® Cube 6 (Sysmex, Lincolnshire, IL, United States) and FCS Express 5 software (De Novo Software, Glendale, CA, United States) were used. We only used cells that met the criteria of CD73 ≥ 70%, CD90 ≥ 90%, and CD105 ≥ 90% as a result of the analysis of the UC-MSCs. The UC-MSCs that were used also passed microbiological tests.



DOI: 10.4252/wjsc.v14.i4.303 Copyright ©The Author(s) 2022.

**Figure 1** Imaging analyses before and after stem cell treatment. A-F: Magnetic resonance imaging scans of the patient before stem cell treatment, from November 26, 2010 (A: Sagittal; B: Transverse), August 29, 2011 (C: Sagittal; D: Transverse) and August 21, 2012 (E: Sagittal; F: Transverse); G-J: Magnetic resonance imaging of the patient after stem cell treatment, from July 18, 2018 (G: Sagittal; H: Transverse) and August 31, 2020 (I: Sagittal; J: Transverse). Orange arrows indicate where the cavity is or was.

### Preparation of injection solution

We prepared  $6 \times 10^7$  cells *per* treatment to transplant into the patient, calculated for  $1 \times 10^6$  cells *per* kg body weight. In order to lower the viscosity of the injection solution, we divided the cell content in half, for two solutions with each containing  $3 \times 10^7$  uncultured UC-MSCs mixed with 10-mL of 0.9% normal saline solution for each.

### Treatment

We chose the intravenous injection method instead of local injection into the painful area as the transplantation method because the patient was experiencing pain throughout the whole body. The 10-mL injection solutions (as above, containing  $3 \times 10^7$  UC-MSCs) were diluted for use by adding to 100 mL of 0.9% normal saline solution. In one treatment, the patient was injected with this 110-mL solution two times. The first 110-mL injection was given over a period of 1-2 h. After a 1 h break, the patient received the second injection. The patient received a total of four treatments over 8 mo. In July 2018, the patient received an additional treatment (Table 1).

## OUTCOME AND FOLLOW-UP

During the treatment period, the patient experienced repeated pain reductions and then recurrences. After receiving the first (May 25, 2016) and second (July 26, 2016) treatments, the effectiveness of the treatment did not last long. The effect of the third treatment (August 9, 2016), however, was maintained for about 5 mo, and on January 13, 2017, the patient received the fourth treatment. The patient maintained the pain-reducing effect for a long period.

After syringopleural foramen magnum decompression for the treatment of Chiari malformation, the patient attended regular check-ups for follow-up after the surgery at the hospital where the surgery had

**Table 1 Transplantation of uncultured umbilical cord-derived mesenchymal stem cells to the patient**

Treatment number	Date	In an injection		As a treatment	
		Cell amount	Volume in mL	Number of injections	Total cell amount
1	May 25, 2016	$3 \times 10^7$	110	2	$6 \times 10^7$
2	July 26, 2016				
3	August 9, 2016				
4	January 13, 2017				
5	July 20, 2018				

been performed. Interestingly, it was confirmed during the regular check-up in July 2018 that the cavity decreased in size (Figure 1G and H). Since the patient did not receive any treatment except for the uncultured UC-MSC transplantation, we considered the possibility that the stem cell treatment induced a reduction of the cavity size. Therefore, in July 2018, the patient received one more treatment. Afterward, the patient's existing symptoms, such as eye, hand, and knee pain, myalgia, occipital headache, and dysphonia, improved significantly. As a result of imaging analysis performed in August 2020, the cavity was almost completely disappeared (Figure 1I and J). Since then, the patient has maintained a significant decrease in pain and dysphonia.

### Report of side effects

The patient had temporary nausea and dizziness after the first treatment. However, these symptoms were not present in the second through fourth treatments. The patient did not report any particular side effects during the follow-up period.

## DISCUSSION

MSCs have a paracrine effect that helps protect and regenerate neuronal cells and promotes the ability for differentiation into neuronal cells[22-24]. Recently, as MSC transplantation has shown therapeutic potential in patients with spinal cord injury, clinical cases using MSC transplantation are increasing[25, 26]. Meanwhile, a Spanish research team reported the first case of MSC transplantation for a patient with post-traumatic syringomyelia in 2017, and the results of the follow-up study were announced in 2018[27,28]. So far, there have been only these two cases of syringomyelia treatment using cell therapy, and two additional studies using a syringomyelia model were reported in 2018 and 2020[29,30]. Although the mechanism of this benefit is not clear, as there are not many studies on MSCs and the treatment of syringomyelia, previous studies have shown that MSC transplantation has potential as an alternative treatment for syringomyelia.

The patient had undergone syringopleural foramen magnum decompression for the treatment of Chiari malformation with syringomyelia in 2010, but the syringomyelia remained. In the medical records issued by the hospital where the patient had been operated on, there was no significant change detected in the size of the cavity before 2014; however, there was a record of a slight decrease in the size of the cavity detected in March 2014. Unfortunately, since we could not secure magnetic resonance imaging (MRI), C-spine data was obtained in March 2014, but this precluded our ability to directly confirm the change in the size of the cavity. In addition, there was no record of syringomyelia in the medical record from March 2014 until May 25, 2016 (the start-day of UC-MSCs treatment). Therefore, based on the medical records and historic MRI C-spine results, we estimated that the patient's cavity size before UC-MSC therapy was similar or slightly reduced compared to that before surgery. After four UC-MSC treatments had been administered over an 8-mo period, the patient showed cavity size that was significantly reduced according to the magnetic resonance imaging findings in 2018. Confirmed by magnetic resonance imaging, the cavity had almost disappeared in 2020.

Because the initial purpose of the UC-MSC-based treatment of this patient was pain relief, our data are insufficient to support the treatment of syringomyelia by MSCs. In particular, the absence of data for the imaging investigations carried out just before the stem cell treatment and the pressure change that occurred due to the reduction of the cavity's size make it difficult to accurately interpret the study results. However, based on our results and findings from previous studies on the effect of MSC transplantation on syringomyelia, it is possible that MSC transplantation therapy plays a positive role in the treatment of syringomyelia patients[27-30]. We, therefore, expect that a future well-controlled and planned large-scale clinical study will provide support for this therapy as a new alternative for syringomyelia, which is particularly important since an appropriate treatment method is currently not available.



## CONCLUSION

In this case study, a patient with syringomyelia was treated by intravenous transplantation of uncultured allogeneic UC-MSCs. Although this study is a case report for a single patient and there is room for interpretation of the data, considering the results of previously reported studies along with it, MSC transplantation may hold promise as a new treatment alternative for syringomyelia.

## FOOTNOTES

**Author contributions:** Ahn H, Lee SY, Jung WJ, and Lee KH designed the report; Ahn H and Jung WJ collected the patient's clinical data; Ahn H, Lee SY, and Jung WJ analyzed the data; Ahn H wrote the manuscript; Lee KH provided professional advice and revised the manuscript; All authors issued final approval for the version to be submitted.

**Informed consent statement:** The patient involved in this study gave her written informed consent authorizing disclosure of her protected health information.

**Conflict-of-interest statement:** All authors have no conflicts of interest to declare.

**CARE Checklist (2016) statement:** The authors have read the CARE Checklist (2016), and the manuscript was prepared and revised according to the CARE Checklist (2016).

**Open-Access:** This article is an open-access article that was selected by an in-house editor and fully peer-reviewed by external reviewers. It is distributed in accordance with the Creative Commons Attribution NonCommercial (CC BY-NC 4.0) license, which permits others to distribute, remix, adapt, build upon this work non-commercially, and license their derivative works on different terms, provided the original work is properly cited and the use is non-commercial. See: <https://creativecommons.org/licenses/by-nc/4.0/>

**Country/Territory of origin:** South Korea

**ORCID number:** Hyunjun Ahn 0000-0002-5550-8325; Sang Yeon Lee 0000-0003-4394-6958; Won-Ju Jung 0000-0002-4966-3118; Kye-Ho Lee 0000-0001-8241-6402.

**S-Editor:** Fan JR

**L-Editor:** A

**P-Editor:** Fan JR

## REFERENCES

- 1 Williams B. On the pathogenesis of syringomyelia: a review. *J R Soc Med* 1980; **73**: 798-806 [PMID: 7017117]
- 2 Williams B. Syringomyelia. *Neurosurg Clin N Am* 1990; **1**: 653-685 [PMID: 2136163]
- 3 Vandertop WP. Syringomyelia. *Neuropediatrics* 2014; **45**: 3-9 [PMID: 24272770 DOI: 10.1055/s-0033-1361921]
- 4 Ko HY, Huh S. Posttraumatic Syringomyelia and Chiari Malformations. In Handbook of Spinal Cord Injuries and Related Disorders. Springer 2021; 211-223 [DOI: 10.1007/978-981-16-3679-0\_12]
- 5 Pollay M. The function and structure of the cerebrospinal fluid outflow system. *Cerebrospinal Fluid Res* 2010; **7**: 9 [PMID: 20565964 DOI: 10.1186/1743-8454-7-9]
- 6 Telano LN, Baker S. Physiology, Cerebral Spinal Fluid. 2021 Jul 9. In: StatPearls [Internet]. Treasure Island (FL): StatPearls Publishing; 2022 Jan- [PMID: 30085549]
- 7 Flint G. Syringomyelia: diagnosis and management. *Pract Neurol* 2021; **21**: 403-411 [PMID: 34433683 DOI: 10.1136/practneurol-2021-002994]
- 8 Pucci GF, Akita J, Berkowitz AL. Clinical-Radiologic Dissociation in Post-traumatic Syringomyelia. *World Neurosurg* 2021; **153**: 9-10 [PMID: 34153481 DOI: 10.1016/j.wneu.2021.06.063]
- 9 Attal N, Parker F, Tadié M, Aghakani N, Bouhassira D. Effects of surgery on the sensory deficits of syringomyelia and predictors of outcome: a long term prospective study. *J Neurol Neurosurg Psychiatry* 2004; **75**: 1025-1030 [PMID: 15201364 DOI: 10.1136/jnnp.2003.026674]
- 10 Masur H, Schulte-Oversohl U, Papke K, Oberwittler C, Vollmer J. Involvement of the autonomic nervous system in patients with syringomyelia--a study with the sympathetic skin response. *Electromyogr Clin Neurophysiol* 1996; **36**: 43-47 [PMID: 8654321]
- 11 Rusbridge C, Greitz D, Iskandar BJ. Syringomyelia: current concepts in pathogenesis, diagnosis, and treatment. *J Vet Intern Med* 2006; **20**: 469-479 [PMID: 16734077 DOI: 10.1892/0891-6640(2006)20]
- 12 Ciaramitaro P, Massimi L, Bertuccio A, Solari A, Farinotti M, Peretta P, Saletti V, Chiapparini L, Barbanera A, Garbossa D, Bolognese P, Brodbelt A, Celada C, Cocito D, Curone M, Devigili G, Erbetta A, Ferraris M, Furlanetto M, Gilanton M, Jallo G, Karadjova M, Klekamp J, Massaro F, Morar S, Parker F, Perrini P, Poca MA, Sahuquillo J, Stoodley M, Talamonti G, Triulzi F, Valentini MC, Visocchi M, Valentini L; International Experts Jury of the Chiari Syringomyelia Consensus

- Conference, Milan, November 11-13, 2019. Diagnosis and treatment of Chiari malformation and syringomyelia in adults: international consensus document. *Neurol Sci* 2022; **43**: 1327-1342 [PMID: [34129128](#) DOI: [10.1007/s10072-021-05347-3](#)]
- 13 **Perrini P**, Anania Y, Cagnazzo F, Benedetto N, Morganti R, Di Carlo DT. Radiological outcome after surgical treatment of syringomyelia-Chiari I complex in adults: a systematic review and meta-analysis. *Neurosurg Rev* 2021; **44**: 177-187 [PMID: [31953784](#) DOI: [10.1007/s10143-020-01239-w](#)]
  - 14 **Padovani R**, Cavallo M, Gaist G. Surgical treatment of syringomyelia: favorable results with syringosubarachnoid shunting. *Surg Neurol* 1989; **32**: 173-180 [PMID: [2475914](#) DOI: [10.1016/0090-3019\(89\)90175-4](#)]
  - 15 **Schuster JM**, Zhang F, Norvell DC, Hermsmeyer JT. Persistent/Recurrent syringomyelia after Chiari decompression-natural history and management strategies: a systematic review. *Evid Based Spine Care J* 2013; **4**: 116-125 [PMID: [24436709](#) DOI: [10.1055/s-0033-1357362](#)]
  - 16 **Goel A**, Desai K. Surgery for syringomyelia: an analysis based on 163 surgical cases. *Acta Neurochir (Wien)* 2000; **142**: 293-301; discussion 301 [PMID: [10819260](#) DOI: [10.1007/s007010050038](#)]
  - 17 **Soleman J**, Bartoli A, Korn A, Constantini S, Roth J. Treatment failure of syringomyelia associated with Chiari I malformation following foramen magnum decompression: how should we proceed? *Neurosurg Rev* 2019; **42**: 705-714 [PMID: [30554294](#) DOI: [10.1007/s10143-018-01066-0](#)]
  - 18 **Tong CK**, Vellasamy S, Tan BC, Abdullah M, Vidyadaran S, Seow HF, Ramasamy R. Generation of mesenchymal stem cell from human umbilical cord tissue using a combination enzymatic and mechanical disassociation method. *Cell Biol Int* 2011; **35**: 221-226 [PMID: [20946106](#) DOI: [10.1042/CBI20100326](#)]
  - 19 **Ahn H**, Lee SY, Jung WJ, Lee KH. Alopecia treatment using minimally manipulated human umbilical cord-derived mesenchymal stem cells: Three case reports and review of literature. *World J Clin Cases* 2021; **9**: 3741-3751 [PMID: [34046478](#) DOI: [10.12998/wjcc.v9.i15.3741](#)]
  - 20 **Ahn H**, Lee SY, Jung WJ, Pi J, Lee KH. Psoriasis treatment using minimally manipulated umbilical cord-derived mesenchymal stem cells: A case report. *World J Clin Cases* 2021; **9**: 6798-6803 [PMID: [34447827](#) DOI: [10.12998/wjcc.v9.i23.6798](#)]
  - 21 **Ahn H**, Lee SY, Jung WJ, Lee KH. Treatment of acute ischemic stroke by minimally manipulated umbilical cord-derived mesenchymal stem cells transplantation: A case report. *World J Stem Cells* 2021; **13**: 1151-1159 [PMID: [34567432](#) DOI: [10.4252/wjsc.v13.i8.1151](#)]
  - 22 **Chang C**, Yan J, Yao Z, Zhang C, Li X, Mao HQ. Effects of Mesenchymal Stem Cell-Derived Paracrine Signals and Their Delivery Strategies. *Adv Healthc Mater* 2021; **10**: e2001689 [PMID: [33433956](#) DOI: [10.1002/adhm.202001689](#)]
  - 23 **Boucherie C**, Hermans E. Adult stem cell therapies for neurological disorders: benefits beyond neuronal replacement? *J Neurosci Res* 2009; **87**: 1509-1521 [PMID: [19115417](#) DOI: [10.1002/jnr.21970](#)]
  - 24 **Lavorato A**, Raimondo S, Boido M, Muratori L, Durante G, Cofano F, Vincitorio F, Petrone S, Titolo P, Tartara F, Vercelli A, Garbossa D. Mesenchymal Stem Cell Treatment Perspectives in Peripheral Nerve Regeneration: Systematic Review. *Int J Mol Sci* 2021; **22** [PMID: [33430035](#) DOI: [10.3390/ijms22020572](#)]
  - 25 **Liau LL**, Looi QH, Chia WC, Subramaniam T, Ng MH, Law JX. Treatment of spinal cord injury with mesenchymal stem cells. *Cell Biosci* 2020; **10**: 112 [PMID: [32983406](#) DOI: [10.1186/s13578-020-00475-3](#)]
  - 26 **Cheng H**, Liu X, Hua R, Dai G, Wang X, Gao J, An Y. Clinical observation of umbilical cord mesenchymal stem cell transplantation in treatment for sequelae of thoracolumbar spinal cord injury. *J Transl Med* 2014; **12**: 253 [PMID: [25209445](#) DOI: [10.1186/s12967-014-0253-7](#)]
  - 27 **Vaquero J**, Hassan R, Fernández C, Rodríguez-Boto G, Zurita M. Cell Therapy as a New Approach to the Treatment of Posttraumatic Syringomyelia. *World Neurosurg* 2017; **107**: 1047.e5-1047.e8 [PMID: [28804041](#) DOI: [10.1016/j.wneu.2017.08.019](#)]
  - 28 **Vaquero J**, Zurita M, Rico MA, Aguayo C, Fernandez C, Rodriguez-Boto G, Marin E, Tapiador N, Sevilla M, Carballido J, Vazquez D, Garcia-Olmo D, Guadalajara H, Leon M, Valverde I; Neurological Cell Therapy Group From Puerta De Hierro-Majadahonda Hospital. Cell therapy with autologous mesenchymal stromal cells in post-traumatic syringomyelia. *Cytotherapy* 2018; **20**: 796-805 [PMID: [29784434](#) DOI: [10.1016/j.jcyt.2018.04.006](#)]
  - 29 **Zhao Z**, Xu W, Xie J, Wang Y, Li T, Zhang Y, Zhao D, Bi N, Shi Z. Bone marrow-derived mesenchymal stem cells (BM-MSCs) inhibit apoptosis of spinal cord cells in a kaolin-induced syringomyelia-associated scoliosis rabbit model. *Int J Clin Exp Pathol* 2018; **11**: 1890-1899 [PMID: [31938295](#)]
  - 30 **Bal E**, Hanalioğlu Ş, Köprü ÇZ, Köse S, Başak AT, Pehlivan SB, Çetinkaya DU, Purali N, Korkusuz P, Bozkurt G. Effect of mesenchymal stem cells therapy in experimental kaolin induced syringomyelia model. *J Neurosurg Sci* 2022; **66**: 40-48 [PMID: [33056946](#) DOI: [10.23736/S0390-5616.20.05026-2](#)]



Published by **Baishideng Publishing Group Inc**  
7041 Koll Center Parkway, Suite 160, Pleasanton, CA 94566, USA

**Telephone:** +1-925-3991568

**E-mail:** [bpgoffice@wjgnet.com](mailto:bpgoffice@wjgnet.com)

**Help Desk:** <https://www.f6publishing.com/helpdesk>

<https://www.wjgnet.com>

