

# World Journal of *Gastrointestinal Endoscopy*

*World J Gastrointest Endosc* 2019 July 16; 11(7): 427-442



**META-ANALYSIS**

- 427 Should a colonoscopy be offered routinely to patients with CT proven acute diverticulitis? A retrospective cohort study and meta-analysis of best available evidence

*Asaad P, Hajibandeh S, Rahm M, Johnston T, Chowdhury S, Bronder C*

**CASE REPORT**

- 438 Endoscopic management of massive rectal bleeding from a Dieulafoy's lesion: Case report

*Pineda-De Paz MR, Rosario-Morel MM, Lopez-Fuentes JG, Waller-Gonzalez LA, Soto-Solis R*

**ABOUT COVER**

Editorial Board Member of *World Journal of Gastrointestinal Endoscopy*, Ziya Anadol, MD, Professor, Surgeon, Department of Surgery, Gazi University School of Medicine, Ankara 06490, Turkey

**AIMS AND SCOPE**

The primary aim of *World Journal of Gastrointestinal Endoscopy* (WJGE, *World J Gastrointest Endosc*) is to provide scholars and readers from various fields of gastrointestinal endoscopy with a platform to publish high-quality basic and clinical research articles and communicate their research findings online.

WJGE mainly publishes articles reporting research results and findings obtained in the field of gastrointestinal endoscopy and covering a wide range of topics including capsule endoscopy, colonoscopy, double-balloon enteroscopy, duodenoscopy, endoscopic retrograde cholangiopancreatography, endosonography, esophagoscopy, gastrointestinal endoscopy, gastroscopy, laparoscopy, natural orifice endoscopic surgery, proctoscopy, and sigmoidoscopy.

**INDEXING/ABSTRACTING**

The WJGE is now abstracted and indexed in Emerging Sources Citation Index (Web of Science), PubMed, PubMed Central, Reference Citation Analysis, China National Knowledge Infrastructure, China Science and Technology Journal Database, and Superstar Journals Database. The 2022 edition of Journal Citation Reports® cites the 2021 Journal Citation Indicator (JCI) for WJGE as 0.33.

**RESPONSIBLE EDITORS FOR THIS ISSUE**

**Production Editor:** Yan-Xia Xing; **Production Department Director:** Yun-Xiaoqian Wu; **Editorial Office Director:** Jin-Li Wang.

**NAME OF JOURNAL**

*World Journal of Gastrointestinal Endoscopy*

**ISSN**

ISSN 1948-5190 (online)

**LAUNCH DATE**

October 15, 2009

**FREQUENCY**

Monthly

**EDITORS-IN-CHIEF**

Anastasios Koulaouzidis, Joo Young Cho, Sang Chul Lee, Bing Hu

**EDITORIAL BOARD MEMBERS**

<https://www.wjgnet.com/1948-5190/editorialboard.htm>

**PUBLICATION DATE**

July 16, 2019

**COPYRIGHT**

© 2022 Baishideng Publishing Group Inc

**INSTRUCTIONS TO AUTHORS**

<https://www.wjgnet.com/bpg/gerinfo/204>

**GUIDELINES FOR ETHICS DOCUMENTS**

<https://www.wjgnet.com/bpg/GerInfo/287>

**GUIDELINES FOR NON-NATIVE SPEAKERS OF ENGLISH**

<https://www.wjgnet.com/bpg/gerinfo/240>

**PUBLICATION ETHICS**

<https://www.wjgnet.com/bpg/GerInfo/288>

**PUBLICATION MISCONDUCT**

<https://www.wjgnet.com/bpg/gerinfo/208>

**ARTICLE PROCESSING CHARGE**

<https://www.wjgnet.com/bpg/gerinfo/242>

**STEPS FOR SUBMITTING MANUSCRIPTS**

<https://www.wjgnet.com/bpg/GerInfo/239>

**ONLINE SUBMISSION**

<https://www.f6publishing.com>



## Endoscopic management of massive rectal bleeding from a Dieulafoy's lesion: Case report

Mario Rene Pineda-De Paz, Massiel Madelin Rosario-Morel, Jose Guadalupe Lopez-Fuentes, Luis Ariel Waller-Gonzalez, Rodrigo Soto-Solis

**Specialty type:** Gastroenterology and hepatology

**P-Reviewer:** Chen CH, Sandhu DS, Vynios D

**Received:** May 10, 2019

**Peer-review started:** May 14, 2019

**First decision:** May 31, 2019

**Revised:** June 5, 2019

**Accepted:** June 20, 2019

**Article in press:** June 21, 2019

**Published online:** July 16, 2019



**Mario Rene Pineda-De Paz, Massiel Madelin Rosario-Morel, Jose Guadalupe Lopez-Fuentes, Luis Ariel Waller-Gonzalez, Rodrigo Soto-Solis,** Department of Endoscopy, National Medical Center November 20<sup>TH</sup>, ISSSTE, Mexico City 03229, Mexico

**Corresponding author:** Rodrigo Soto-Solis, MD, MHA, Adjunct Professor, Department of Endoscopy, National Medical Center November 20<sup>TH</sup>, ISSSTE, 540 Felix Cuevas Avenue, Del Valle, Benito Juarez, Mexico City 03229, Mexico. [rodrigosotomd@hotmail.com](mailto:rodrigosotomd@hotmail.com)

### Abstract

#### BACKGROUND

Rectal Dieulafoy's lesions (DLs) are very rare; however, they can be life threatening when presented with massive hemorrhage.

#### CASE SUMMARY

A 44-year-old female with medical history of chronic renal failure who was on renal replacement therapy presented with lower gastrointestinal hemorrhage. Physical examination revealed signs of hypovolemic shock and massive rectal bleeding. Complete blood count revealed abrupt decrease in hematocrit. After hemodynamic stabilization, an urgent colonoscopy was performed. A rectal DL was diagnosed, and it was successfully treated with two hemoclips. There were no signs of recurrent bleeding at thirty days of follow-up.

#### CONCLUSION

Rectal DLs represent an unusual cause of lower gastrointestinal bleeding. Massive hemorrhage can increase the morbidity and mortality of these patients. Endoscopic management continues to be the reference standard in the diagnosis and therapy of these lesions. Thermal, mechanical (hemoclip or band ligation), or combination therapy (adrenaline injection combined with thermal or mechanical therapy) should be considered the first choice for treatment.

**Key Words:** Dieulafoy's Lesion; Endoscopic hemostasis; Massive rectal bleeding; Case report

©The Author(s) 2019. Published by Baishideng Publishing Group Inc. All rights reserved.

**Core tip:** Rectal Dieulafoy's lesion (DL) represents an unusual cause of lower gastrointestinal bleeding. A 44-year-old female with medical history of chronic renal failure presented massive rectal bleeding. After proper initial management, an urgent colonoscopy was performed. A rectal DL was diagnosed and successfully treated with two hemoclips without recurrence of hemorrhage. Endoscopy is the reference standard for the diagnosis and treatment of these lesions.

**Citation:** Pineda-De Paz MR, Rosario-Morel MM, Lopez-Fuentes JG, Waller-Gonzalez LA, Soto-Solis R. Endoscopic management of massive rectal bleeding from a Dieulafoy's lesion: Case report. *World J Gastrointest Endosc* 2019; 11(7): 438-442

**URL:** <https://www.wjgnet.com/1948-5190/full/v11/i7/438.htm>

**DOI:** <https://dx.doi.org/10.4253/wjge.v11.i7.438>

## INTRODUCTION

Dieulafoy's lesions (DLs) represent less than 5% of all causes of gastrointestinal bleeding. These lesions were initially described as gastric aneurysms by Gallard in 1884, but it was in 1898 when George Dieulafoy, a French surgeon, identified them in three patients as the cause of gastrointestinal bleeding [1]. More than 90% of the lesions are located at the upper gastrointestinal tract and only 2% are found at the rectum [2]. Unlike the proximal lesions, rectal DLs (RDL) usually present hematochezia and/or fresh bleeding. The literature reveals only few case reports of RDL. We report the case of profuse lower gastrointestinal hemorrhage due to a RDL, as well as the proper literature review.

## CASE PRESENTATION

### Chief complaint

A 44-year-old female patient hospitalized in our institution due to a vascular access infection.

### History of present illness

The patient presented profuse rectal bleeding that progressed to hypovolemic shock in four hours.

### Past medical history

Her medical comorbidities included chronic kidney disease on replacement therapy and secondary hypertension. Patient denied any toxic habits.

Her surgical history included two cesarean sections, appendectomy, and living-donor kidney transplant followed by acute rejection. Family history was negative for any gastrointestinal disease.

### Physical examination

On presentation her vital signs were temperature of 36 °C, pulse of 120 bpm, respiratory rate of 20 rpm, blood pressure of 80/50 mmHg, and oxygen saturation of 92%. On general physical examination she looked pale and dehydrated. Abdominal examination revealed non-distended, soft, non-tender abdomen with normal bowel sounds. Rectal examination revealed bright blood with clots. The cardiovascular, pulmonary and neurological examination was unremarkable.

### Laboratory examinations

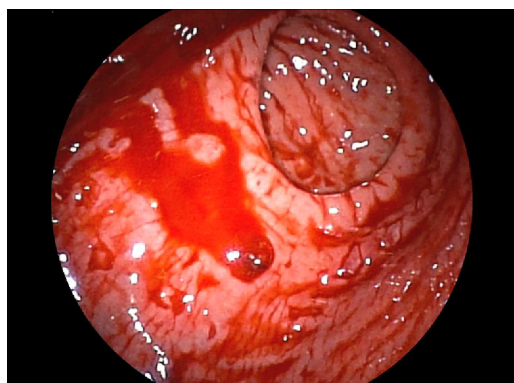
Complete blood count analysis revealed hemoglobin of 6.7 g/dL, normal platelet count (193000/mm<sup>3</sup>), partial thromboplastin time of 42 s (RV 25-33), prothrombin time of 20 s (RV 11-15), and international normalized ratio 1.86.

### Imaging examinations

Urgent colonoscopy findings were active bleeding from small bulgy vessel with minimal surrounding erosion and no ulcerative lesions (Figure 1).

## FINAL DIAGNOSIS

The final diagnosis of the presented case was a RDL.



**Figure 1 Endoscopic appearance of Dieulafoy's lesion.** A small pigmented protuberance with minimal surrounding erosion and no ulcerative lesion.

## TREATMENT

For the management of the hypovolemic shock, proper resuscitation with crystalloids, transfusion of packed red blood cells and vasoactive agents was performed. After hemodynamic stabilization, endoscopic therapy with two hemoclips ([Figure 2](#)) was done.

## OUTCOME AND FOLLOW-UP

Immediate hemostasis was achieved with endoscopic management, and on the fifth day the patient was discharged. There were no signs of recurrent bleeding at thirty days of follow-up.

## DISCUSSION

DLs represent an unusual cause of non-variceal gastrointestinal bleeding, accounting for less than 5% of all cases. More than 90% of these lesions are located at the esophagus, stomach and duodenum; only 2% are found at the rectum. The most relevant histological findings are aneurysm and inflammation, but a biopsy is not usually necessary[2]. The reference standard for diagnosis is endoscopy. Common findings include a small, usually less than 3 mm, protruding pulsatile lesion surrounded by normal mucosa, with or without active bleeding[3].

Unlike the manifestations described in other parts of the digestive tract, RDL usually present with rectorrhagia or hematoquezia. There are previous case reports of profuse rectal bleeding, but most of them didn't evolve to hypovolemic shock as occurred with our patient. A computed tomography angiography was canceled due to hemodynamic instability in the CT-room. This hemodynamic instability can impact in the morbidity and mortality of these patients[4,5].

If technically feasible, the first line of treatment is endoscopic hemostasis. The European Gastrointestinal Endoscopy Society (ESGE) recommends endoscopic hemostasis for DLs, including: thermal coagulation, mechanical hemostasis (hemoclips or band ligation), or combined therapy (diluted adrenaline injection plus contact thermal or mechanical therapy)[6]. These endoscopic hemostasis techniques are safe and have similar outcomes in observational studies. As in other causes of non-variceal bleeding, there is superiority of combined, thermal and mechanical methods over injection monotherapy[6]. Endoscopic treatment achieves an initial hemostasis rate > 93.6% of cases, with a rebleeding rate of 12.1%, including cases of RDL[7,8]. A prospective study demonstrated superiority of mechanical endoscopic treatment with hemoclips or band ligation versus injection with diluted adrenaline[9]. Regarding to the mechanical therapy, there is no differences in endoscopic band ligation *vs* hemoclips. A meta-analysis that included 5 studies, compared endoscopic band ligation (75 patients) versus hemoclips (87 patients) for primary hemostasis of DLs; results didn't find any difference for the primary outcome [0.96 (95%CI: 0.88-0.99) *vs* 0.91 (95%CI: 0.83-0.96), respectively]; there were no differences in rebleeding rates neither [0.06 (95%CI: 0.02-0.15) *vs* 0.17 (95%CI: 0.10-0.28), respectively] [10]. In our patient, there was no rebleeding after the initial effective hemostasis with the placement of two hemoclips. [Table 1](#) shows a summary of endoscopic treatment modalities.

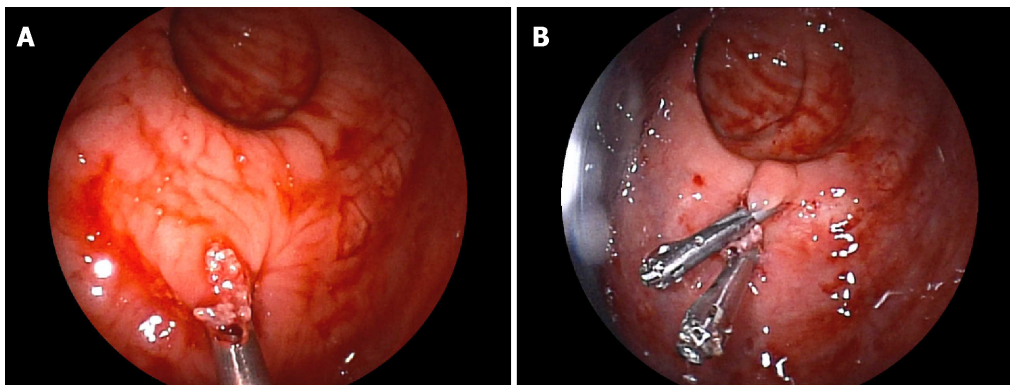
Transcatheter angiographic embolization (TAE) should be the next option in cases that can't be treated endoscopically[6,11]. Surgical resection should be reserved for selected cases that can't be treated with endoscopic or angiographic methods[6,12].



**Table 1** Endoscopic treatment modalities for Dieulafoy's lesion (modified from Nguyen *et al* [7])

| Technique              | Initial hemostasis (%) | Rebleeding (%) | Mortality (%) | Adverse events <sup>1</sup> (%) |
|------------------------|------------------------|----------------|---------------|---------------------------------|
| Thermal                |                        |                |               |                                 |
| Bipolar EC             | 80                     | 13.3           | 0             | 0                               |
| APC                    | 100                    | 3.4            | NA            | 3.4                             |
| Injection              |                        |                |               |                                 |
| Epinephrine            | 88                     | 32.7           | 2.4           | 0                               |
| Mechanical             |                        |                |               |                                 |
| Hemoclip               | 94.7                   | 10.5           | 0.4           | 0.5                             |
| EBL                    | 99.2                   | 5.3            | 0             | 0.8                             |
| Combined               |                        |                |               |                                 |
| Epinephrine + Hemoclip | 98.2                   | 5              | 0             | 0                               |
| Epinephrine + EBL      | 100                    | 0              | 0             | 0                               |

<sup>1</sup>Adverse events: Perforation, hemorrhage. EC: Electrocoagulation; APC: Argon plasma coagulation; NA: Not applicable; EBL: Endoscopic band ligation.

**Figure 2** Endoscopic management of Dieulafoy's lesion. A: Placement of the first hemoclip; B: Placement of a second hemoclip to ensure hemostasis.

## CONCLUSION

Rectal DLs represent a rare cause of lower gastrointestinal bleeding. Massive hemorrhage can increase the morbidity and mortality of these patients. Endoscopic management continues to be the reference standard in the diagnostic and therapeutic approach. Thermal, mechanical (hemoclip or band ligation), or combination therapy (adrenaline injection combined with thermal or mechanical therapy) should be considered the first choice for treatment.

## FOOTNOTES

**Author contributions:** Pineda-De Paz MR, Rosario-Morel MM, Lopez-Fuentes JG and Soto-Solis R contributed to concept and design, literature review, and drafting of the manuscript; Pineda-De Paz MR acquired the data and figures; Pineda-De Paz MR, Rosario-Morel MM, Waller-González LA, and Soto-Solis R revised the manuscript for important intellectual content; all authors had access and approved the last version of the manuscript.

**Informed consent statement:** Informed written consent was obtained from the patient for endoscopic procedures and for the publication of this report.

**Conflict-of-interest statement:** Authors declare no conflict of interest regarding this manuscript.

**Open-Access:** This article is an open-access article which was selected by an in-house editor and fully peer-reviewed by external reviewers. It is distributed in accordance with the Creative Commons Attribution Non Commercial (CC BY-NC 4.0) license, which permits others to distribute, remix, adapt, build upon this work non-commercially, and

license their derivative works on different terms, provided the original work is properly cited and the use is non-commercial. See: <http://creativecommons.org/licenses/by-nc/4.0/>

**ORCID number:** Mario Rene Pineda-De Paz 0000-0002-1546-5041; Massiel Madelin Rosario-Morel 0000-0001-6865-3532; Jose Guadalupe Lopez-Fuentes 0000-0002-9409-9536; Luis Ariel Waller-Gonzalez 0000.0002.6758-6814; Rodrigo Soto-Solis 0000-0002-8559-6397.

**S-Editor:** Ma YJ

**L-Editor:** A

**P-Editor:** Wu YXJ

## REFERENCES

- 1 **Chaer RA**, Helton WS. Dieulafoy's disease. *J Am Coll Surg* 2003; **196**: 290-296 [PMID: 12595057 DOI: 10.1016/S1072-7515(02)01801-X]
- 2 **Lara LF**, Sreenarasimhaiah J, Jiang Tang S, Alonso BB, Roche DC. Localization, efficacy of therapy and outcomes of Dieulafoy's lesions of the GI tract-the UT Southwestern GI Bleed Team experience. *Gastrointest Endosc* 2008; **67**: AB87 [DOI: 10.1016/j.gie.2008.03.063]
- 3 **Lee YT**, Walmsley RS, Leong RW, Sung JJ. Dieulafoy's lesion. *Gastrointest Endosc* 2003; **58**: 236-243 [PMID: 12872092 DOI: 10.1016/mge.2003.328]
- 4 **Tursi A**. Rectal Dieulafoy lesion. *Clin Res Hepatol Gastroenterol* 2017; **41**: 1-2 [PMID: 26186876 DOI: 10.1016/j.clinre.2015.06.006]
- 5 **Kanth R**, Mali P, Roy PK. Outcomes in Dieulafoy's Lesion: A 10-Year Clinical Review. *Dig Dis Sci* 2015; **60**: 2097-2103 [PMID: 25663242 DOI: 10.1007/s10620-015-3568-1]
- 6 **Gralnek IM**, Dumonceau JM, Kuipers EJ, Lanis A, Sanders DS, Kurien M, Rotondano G, Hucl T, Dinis-Ribeiro M, Marmo R, Racz I, Arezzo A, Hoffmann RT, Lesur G, de Franchis R, Aabakken L, Veitch A, Radaelli F, Salgueiro P, Cardoso R, Maia L, Zullo A, Cipolletta L, Hassan C. Diagnosis and management of nonvariceal upper gastrointestinal hemorrhage: European Society of Gastrointestinal Endoscopy (ESGE) Guideline. *Endoscopy* 2015; **47**: a1-46 [PMID: 26417980 DOI: 10.1055/s-0034-1393172]
- 7 **Nguyen DC**, Jackson CS. The Dieulafoy's Lesion: An Update on Evaluation, Diagnosis, and Management. *J Clin Gastroenterol* 2015; **49**: 541-549 [PMID: 25887110 DOI: 10.1097/MCG.0000000000000321]
- 8 **Park JG**, Park JC, Kwon YH, Ahn SY, Jeon SW. Endoscopic Management of Rectal Dieulafoy's Lesion: A Case Series and Optimal Treatment. *Clin Endosc* 2014; **47**: 362-366 [PMID: 25133127 DOI: 10.5946/ce.2014.47.4.362]
- 9 **Chung IK**, Kim EJ, Lee MS, Kim HS, Park SH, Lee MH, Kim SJ, Cho MS. Bleeding Dieulafoy's lesions and the choice of endoscopic method: comparing the hemostatic efficacy of mechanical and injection methods. *Gastrointest Endosc* 2000; **52**: 721-724 [PMID: 11115902]
- 10 **Barakat M**, Hamed A, Shady A, Homsy M, Eskaros S. Endoscopic band ligation versus endoscopic hemoclip placement for Dieulafoy's lesion: a meta-analysis. *Eur J Gastroenterol Hepatol* 2018; **30**: 995-996 [PMID: 30048368 DOI: 10.1097/MEG.0000000000001179]
- 11 **Alshumrani G**, Almuaikel M. Angiographic findings and endovascular embolization in Dieulafoy disease: a case report and literature review. *Diagn Interv Radiol* 2006; **12**: 151-154 [PMID: 16972222 DOI: 10.1067/mag.2000.108040]
- 12 **Dogan U**, Gomceli I, Koc U, Habibi M, Bulbuller N. Rectal dieulafoy lesions: a rare etiology of chronic lower gastrointestinal bleeding. *Case Rep Med* 2014; **2014**: 180230 [PMID: 25349614 DOI: 10.1155/2014/180230]





Published by **Baishideng Publishing Group Inc**  
7041 Koll Center Parkway, Suite 160, Pleasanton, CA 94566, USA

**Telephone:** +1-925-3991568

**E-mail:** [bpgoffice@wjgnet.com](mailto:bpgoffice@wjgnet.com)

**Help Desk:** <https://www.f6publishing.com/helpdesk>

<https://www.wjgnet.com>

