

World Journal of *Gastrointestinal Endoscopy*

World J Gastrointest Endosc 2020 September 16; 12(9): 256-322



EXPERT RECOMMENDATIONS

- 256 Endoscopy during COVID-19 pandemic: An overview of infection control measures and practical application
Teng M, Tang SY, Koh CJ

ORIGINAL ARTICLE

Retrospective Study

- 266 Comparison of the reverse bevel versus Franseen type endoscopic ultrasound needle
Chow CW, Haider SA, Ragnath K, Aithal GP, James MW, Ortiz-Fernandez-Sordo J, Aravinthan AD, Venkatachalapathy SV
- 276 Kyoto classification in patients who developed multiple gastric carcinomas after *Helicobacter pylori* eradication
Sakitani K, Nishizawa T, Toyoshima A, Yoshida S, Matsuno T, Yamada T, Irokawa M, Takahashi Y, Nakai Y, Toyoshima O, Koike K

Observational Study

- 285 Optimization of biliary drainage in inoperable distal malignant strictures
Elshimi E, Morad W, Elshaarawy O, Attia A

CASE REPORT

- 297 Endoscopic approach to gastric remnant outlet obstruction after gastric bypass: A case report
Zarrin A, Sorathia S, Choksi V, Kaplan SR, Kasmin F
- 304 Small invasive colon cancer with adenoma observed by endocytoscopy: A case report
Akimoto Y, Kudo SE, Ichimasa K, Kouyama Y, Misawa M, Hisayuki T, Kudo T, Nemoto T
- 310 Laparoscopy-assisted resection of colorectal cancer with situs inversus totalis: A case report and literature review
Chen W, Liang JL, Ye JW, Luo YX, Huang MJ

LETTER TO THE EDITOR

- 317 Do available data support the widespread adoption of pancreatoscopy guided-lithotripsy?
De Luca L
- 320 Comment on: Should a colonoscopy be offered routinely to patients with CT proven acute diverticulitis? A retrospective cohort study and meta-analysis of best available evidence
Meyer J, Buchs NC, Schiltz B, Liot E, Ris F

ABOUT COVER

Editor-in-Chief of *World Journal of Gastrointestinal Endoscopy*, Dr. Sang Chul Lee is a Professor in the Department of General Surgery of the College of Medicine, Catholic University of Korea and a Colorectal Surgeon at Daejeon St. Mary's Hospital, which is famous for minimally invasive surgery in Korea. His clinical practice specialization in laparoscopic surgery involves a focus in the field of single-port laparoscopic techniques. His standard and routine operation modality is single-port laparoscopic SOLO surgery, with application in a vast spectrum of disease entities and conducted by use of a camera-holder instead of a human assistant. His ongoing research interests are minimally invasive surgery and endoscopic procedures, and for the last several years, he has been performing completely scar-less surgeries. He serves as editorial board member and reviewer for several scientific journals and has published more than 120 peer-reviewed articles. (L-Editor: Filipodia)

AIMS AND SCOPE

The primary aim of *World Journal of Gastrointestinal Endoscopy* (WJGE, *World J Gastrointest Endosc*) is to provide scholars and readers from various fields of gastrointestinal endoscopy with a platform to publish high-quality basic and clinical research articles and communicate their research findings online.

WJGE mainly publishes articles reporting research results and findings obtained in the field of gastrointestinal endoscopy and covering a wide range of topics including capsule endoscopy, colonoscopy, double-balloon enteroscopy, duodenoscopy, endoscopic retrograde cholangiopancreatography, endosonography, esophagoscopy, gastrointestinal endoscopy, gastroscopy, laparoscopy, natural orifice endoscopic surgery, proctoscopy, and sigmoidoscopy.

INDEXING/ABSTRACTING

The WJGE is now abstracted and indexed in Emerging Sources Citation Index (Web of Science), PubMed, PubMed Central, China National Knowledge Infrastructure (CNKI), and Superstar Journals Database.

RESPONSIBLE EDITORS FOR THIS ISSUE

Production Editor: Li-Li Wang; Production Department Director: Yun-Xiaojuan Wu; Editorial Office Director: Jia-Ping Yan.

NAME OF JOURNAL

World Journal of Gastrointestinal Endoscopy

ISSN

ISSN 1948-5190 (online)

LAUNCH DATE

October 15, 2009

FREQUENCY

Monthly

EDITORS-IN-CHIEF

Anastasios Koulaouzidis, Bing Hu, Sang Chul Lee

EDITORIAL BOARD MEMBERS

<https://www.wjgnet.com/1948-5190/editorialboard.htm>

PUBLICATION DATE

September 16, 2020

COPYRIGHT

© 2020 Baishideng Publishing Group Inc

INSTRUCTIONS TO AUTHORS

<https://www.wjgnet.com/bpg/gerinfo/204>

GUIDELINES FOR ETHICS DOCUMENTS

<https://www.wjgnet.com/bpg/GerInfo/287>

GUIDELINES FOR NON-NATIVE SPEAKERS OF ENGLISH

<https://www.wjgnet.com/bpg/gerinfo/240>

PUBLICATION ETHICS

<https://www.wjgnet.com/bpg/GerInfo/288>

PUBLICATION MISCONDUCT

<https://www.wjgnet.com/bpg/gerinfo/208>

ARTICLE PROCESSING CHARGE

<https://www.wjgnet.com/bpg/gerinfo/242>

STEPS FOR SUBMITTING MANUSCRIPTS

<https://www.wjgnet.com/bpg/GerInfo/239>

ONLINE SUBMISSION

<https://www.f6publishing.com>

Observational Study

Optimization of biliary drainage in inoperable distal malignant strictures

Esam Elshimi, Wesam Morad, Omar Elshaarawy, Ahmed Attia

ORCID number: Esam Elshimi 0000-0002-8394-4570; Wesam Morad 0000-0002-3379-9694; Omar Elshaarawy 0000-0002-6945-6204; Ahmed Attia 0000-0003-4578-5537.

Author contributions: Elshimi E, Elshaarawy O and Attia A collected the data and revised the manuscript; Morad W performed the statistical analysis; all authors wrote the manuscript.

Institutional review board

statement: The study was approved by the Institutional Review Board of the National Liver Institute, Menoufia University (IRB number IRB00003413) in April 2015. A consent form was signed by every patient.

Informed consent statement: All study participants, or their legal guardian, provided informed written consent prior to study enrollment.

Conflict-of-interest statement:

There is no conflict of interests for all authors.

Data sharing statement: No additional data are available.

STROBE statement: The authors have read the STROBE Statement-checklist of items, and the manuscript was prepared and

Esam Elshimi, Omar Elshaarawy, Ahmed Attia, Department of Hepatology and Gastroenterology, National Liver Institute, Menoufia University, Shebine Elkom 32111, Egypt

Wesam Morad, Department of Epidemiology and Preventive Medicine, National Liver Institute, Menoufia University, Shebine Elkom 32111, Egypt

Corresponding author: Esam Elshimi, MBChB, MD, MSc, Doctor, Professor, Department of Hepatology and Gastroenterology, National Liver Institute, Menoufia University, Yassin Abdelghaffar Street, Shebine Elkom 32111, Egypt. eelshimi@liver-eg.org

Abstract

BACKGROUND

Given most patients with distal malignant biliary obstruction present in the non-resectable stage, palliative endoscopic biliary drainage with fully covered metal stent (FCMS) or uncovered metal stent (UCMS) is the only available measure to improve patients' quality of life. Half covered metal stent (HCMS) has been recently introduced commercially. The adverse effects and stent function between FCMS and UCMS have been extensively discussed.

AIM

To study the duration of stent patency of HCMS and compare it with FCMS and UCMS to optimize biliary drainage in inoperable patients with distal malignant obstruction. Secondary aims in our study included evaluation of patients' survival and the rates of adverse events for each type of stent.

METHODS

We studied 210 patients and randomized them into three equal groups; HCMS, FCMS and UCMS were inserted endoscopically.

RESULTS

Stent occlusion occurred in (18.6%, 17.1% and 15.7% in HCMS, FCMS and UCMS groups, respectively, $P = 0.9$). Stent migration occurred only in patients with FCMS (8.6% of patients). Cholangitis and cholecystitis occurred in 11.4% and 5.7% of patients, respectively, in FCMS. Tumor growth occurred only in 10 cases among patients with UCMS after a median of 140 d, sludge occurred in nine, seven and one patients in HCMS, FCMS and UCMS, respectively ($P = 0.04$).

CONCLUSION

revised according to the STROBE Statement-checklist of items.

Open-Access: This article is an open-access article that was selected by an in-house editor and fully peer-reviewed by external reviewers. It is distributed in accordance with the Creative Commons Attribution NonCommercial (CC BY-NC 4.0) license, which permits others to distribute, remix, adapt, build upon this work non-commercially, and license their derivative works on different terms, provided the original work is properly cited and the use is non-commercial. See: <http://creativecommons.org/licenses/by-nc/4.0/>

Manuscript source: Invited manuscript

Received: April 9, 2020

Peer-review started: April 9, 2020

First decision: May 26, 2020

Revised: June 3, 2020

Accepted: July 26, 2020

Article in press: July 26, 2020

Published online: September 16, 2020

P-Reviewer: Jaworek JM

S-Editor: Zhang L

L-Editor: Filipodia

P-Editor: Wang LL



Given the prolonged stent functioning time, the use of HCMS is preferred over the use of UCMS and FCMS for optimizing biliary drainage in patients with distal malignant biliary obstruction.

Key Words: Obstructive jaundice; Endoscopic retrograde cholangio-pancreatography; Half covered metal stent; Fully covered and uncovered metal stents

©The Author(s) 2020. Published by Baishideng Publishing Group Inc. All rights reserved.

Core Tip: Given most patients with distal malignant biliary obstruction present in the non-resectable stage, palliative endoscopic biliary drainage with fully covered or uncovered metal stent is the only available measure to improve patients' quality of life. Half covered metal stent has been recently introduced commercially. The adverse effects and stent function between fully covered metal stent and uncovered metal stent have been extensively discussed. Given the prolonged stent functioning time, the use of half covered metal stent is preferred to the use of uncovered metal stent and fully covered metal stent for optimizing biliary drainage in patients with distal inoperable malignant biliary obstruction.

Citation: Elshimi E, Morad W, Elshaarawy O, Attia A. Optimization of biliary drainage in inoperable distal malignant strictures. *World J Gastrointest Endosc* 2020; 12(9): 285-296

URL: <https://www.wjgnet.com/1948-5190/full/v12/i9/285.htm>

DOI: <https://dx.doi.org/10.4253/wjge.v12.i9.285>

INTRODUCTION

Most patients with malignant obstructive jaundice present at the unresectable stage, when the management is restricted only to palliative measures. The common causes of distal malignant biliary strictures are cancer of the head of the pancreas and extra hepatic cholangiocarcinoma. Biliary drainage and decompression by metal stents to improve quality of life^[1] is the therapeutic modality of choice by endoscopic or percutaneous routes, the percutaneous route is generally considered after many failed endoscopic trials^[2] with or without chemo- or radiotherapy. At this stage, the prognosis is dismal, with 5-year survival rates of < 2%^[3,4]. Endoscopic stenting by metal and plastic stents has been used to decompress biliary obstruction with varying success rates. The superiority of metal stents over plastic stents has been demonstrated in many meta-analyses' reports^[5-7]. Metal stents offer better patency and wider caliber than plastic stents and thus there is less need for subsequent endoscopic retrograde cholangio-pancreatography (ERCP) procedure and re-stenting. Moreover, metal stents compared to plastic stents are more cost effective, especially in patients with longer survival, and decrease the number of ERCP procedures in centers with heavy ERCP volume.

Many types of metal stents are commercially available, including covered and uncovered stents. However, it is still questionable which type of stent is more suitable for drainage. The uncovered stents have higher rates of tumor ingrowth with subsequent occlusion and cholangitis (16%-46%)^[8-14], while fully covered stents obviate this disadvantage. In this type, however, the deposition of sludge and bacterial biofilm and tumor overgrowth may lead to occlusion and cholangitis. Stent migration as well as cholecystitis and pancreatitis are more likely to occur with the fully covered type^[14].

Although several meta-analyses have compared both types of stents, no definitive results have been obtained showing the merits of one type over the other type^[15-18]. Recently, another type of metal stent (named half covered metal stent) was introduced to offer the advantages of both types, in which the distal half is covered to obviate tumor ingrowth occurring in uncovered stents and the proximal half is uncovered as a protective character against migration and cholecystitis, which occur as adverse events with covered metal stents^[19,20].

MATERIALS AND METHODS

Patients

This study is a single center three armed prospective randomized study, which was conducted at the National Liver Institute, Egypt, a tertiary referral, government-based, well-equipped center for gastroenterology and liver disease in Egypt, between May 2015 and May 2019.

A committee of endoscopists, interventional radiologists and hepatobiliary surgeons examined 6989 patients and their medical records in obstructive jaundice clinics at the same center for evaluation of medical management plan (Figure 1): 6344 had obstructive jaundice, and 5985 patients underwent ERCP for relieving biliary obstruction. In total, 210 patients were included in the current study under the diagnosis of unresectable malignant extra hepatic biliary obstruction. Resectability was based on clinical findings, imaging and laboratory investigations.

Inclusion criteria were as follows: Patient's age ≥ 18 years; elevated serum bilirubin levels ≥ 1 gm/dL and non-resectability or inoperability based on associated comorbid conditions. All patients signed an Arabic form of written informed consent before ERCP.

We excluded patients with undiagnosed or benign strictures; anatomical changes with previous gastric bypass or patients with duodenal or pyloric strictures not allowing the scope to pass to papilla even after dilatation. We excluded patients with cardiopulmonary co-morbidity, not suitable for general sedation for endoscopy. Patients with previous metal stents after occlusion were also excluded.

Indications of ERCP

ERCP and stenting were considered if there was elevated serum bilirubin and dilatation of a proximal portion of the common bile duct and/or dilated common hepatic duct.

Procedure-related complications

Early or procedure-related complications were defined as adverse events that occurred within 1 mo post-procedure. Serious procedure-related complications were reported when interventions or hospitalization were required^[21,22].

Clinical post-ERCP pancreatitis was considered if the patients developed elevated serum amylase > 3 fold the upper normal limits on the first-day post-ERCP in presence of associated abdominal pain. The severity of pancreatitis was classified as mild, moderate and severe if the patient was hospitalized ≤ 3 d, 4-10 d and > 10 d, respectively. Severe pancreatitis was also considered if the patient was admitted to the intensive care unit and/or if surgical intervention and radiological or endoscopic drainage were required regardless of hospitalization time.

Cholangitis was defined as persistence of jaundice and fever > 38 °C for > 24 h, leukocytosis $> 15,000$ /dL. Cholecystitis was diagnosed when the patients developed positive Murphy's sign and distended gall bladder in sonographer examination^[22].

Follow-up

All studied patients were followed up clinically at day 7, day 14 and day 30 and then after 6 mo post-ERCP. Successful procedure and stent deployment were considered when there was appropriate fluoroscopic positioning of the stent across the stricture in addition to normalization of serum bilirubin or at least a drop of total bilirubin by 30% from the baseline level by day 7 post-procedure.

Thereafter, patients were followed up monthly until death. Telephone follow-up was performed when patients could not return to the hospital, those with poor clinical condition and more than 6 mo after stent placement. In patients with recurrence of jaundice, reassessment of liver function with abdominal ultrasound was performed. When bile duct and intrahepatic biliary radicle dilation were observed during ultrasound or magnetic resonance cholangio-pancreatography examinations, subsequent ERCP was immediately performed.

Randomization

Prior to ERCP procedure, studied patients were randomized for allocation to receive one of three stents: Half covered metal stent (HCMS), fully covered metal stent (FCMS) or uncovered metal stent (UCMS). Using 210 sealed, numbered, opaque envelopes by an endoscopist who did not perform the ERCP, one-third contained a card labeled "HCMS", one-third contained a card labeled "FCMS" and the final one-third contained a designed card labeled "UCMS". The procedure of randomization was

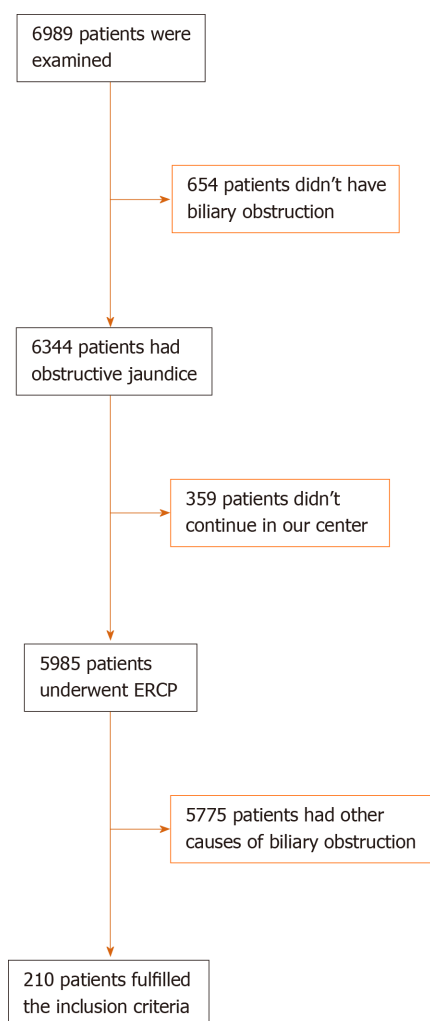


Figure 1 Study flow chart. ERCP: Endoscopic retrograde cholangio-pancreatography.

performed in the endoscopy unit by opening the sealed envelopes consecutively.

Subsequently, data were collected prospectively in previously designed form for data analysis and interpretation.

Ethical approval and consents

This study was conducted according to the Declaration of Helsinki, and the protocol was approved by the ethics committee (for medical research) of Würzburg University and by the Institutional Review Board of the National Liver Institute, Menoufia University (IRB number IRB00003413) in April 2015. A consent form was signed by every patient.

Stent insertion

All stents were inserted endoscopically. After successful cannulation, small papillotomy was performed, and the metal stent was deployed from its delivery system under careful endoscopic and fluoroscopic guidance. Dilatation by balloon or Sohendera dilators was done to determine accurately the desired length and facilitate stent insertion prior to procedure, provided that the distal end of the stent was passed from the papillary orifice. Prophylactic antibiotics were routinely given.

Types of stents: Three types of metal stents were used from Hanarostent (myocardial infarction-tech, Seoul, Korea): (1) HCMS, this stent is made from wires from braided nitinol, and the distal half of stent is coated with a silicone covering membrane, the proximal half is uncovered; (2) FCMS, this stent is similar in structure to HCMS, but it is coated with covering silicone membrane through its entire length; and (3) UCMS, this stent is made from wires from braided nitinol with no covering membrane through its entire length.

Study endpoints

Endpoints of the study were stent patency, complications and patient survival.

Stent dysfunction

According to Ung *et al*^[23], stent dysfunction is considered when the baseline level of serum bilirubin is doubled in addition to increase of serum alkaline phosphatase and/or occurrence of cholangitis. ERCP procedure was repeated in case of stent dysfunction if the general condition of the patient was fair. Stent patency was defined as the time from ERCP and stenting until stent dysfunction or death. Patients with functioning stents were censored until the end of the study or at date of their last follow-up or death.

Analysis

We included 210 patients with inoperable distal malignant biliary obstruction based on the following assumptions: With the power of 80%, $\alpha = 0.05$, and the ratio of exposed to inoperable distal malignant biliary obstruction to those who with inoperable proximal malignant biliary obstruction = 1:2. The required sample size was determined using Epi info software.

Statistical analysis was performed using SPSS Statistics, version 26 (Armonk, NY, United States). A 2-sided *P* value of < 0.05 was considered statistically significant. Simple random sampling and blind analysis were performed. Continuous variables were summarized as mean \pm standard deviation or median (range) for and number (%) for categorical variables. Categorical variables associations were tested using chi-square test. Continuous variables differences were tested among the three groups by parametric test (one-way analysis of variance test) when data were normally distributed or by non-parametric test (Kruskal Wallis test, post-hoc Tamhane test). The cumulative 6 mo and 12 mo survival probabilities were estimated using Kaplan-Meier survival curve, which was used to estimate median duration of each stent patency type. In each group, the log-rank test was used for comparison between the three stent types

RESULTS

Patient characteristics

Between May 2015 and May 2019, 210 patients met our inclusion criteria and were randomized for biliary drainage using HCMS (70 patients), UCMS (70 patients) or FCMS (70 patients).

Patient characteristics and demographic are shown in Table 1. In the studied patients, cancer head of the pancreas represented the most cause of biliary obstruction (67.1%, 68.6% and 65.7%) in HCMS, FCMS and UCMS, respectively. Distal cholangiocarcinoma represented 12.9%, 14.3% and 17.2% in HCMS, FCMS and UCMS, respectively. Gall bladder carcinoma represented 7.1%, 5.7% and 7.1% in HCMS, FCMS and UCMS, respectively, and ampullary carcinoma represented 12.9%, 11.4% and 10% in HCMS, FCMS and UCMS, respectively.

Patients in all groups were matched in regard to age, gender, baseline laboratory investigations and chemotherapy. Successful deployment was achieved in all patients. The operative time (time passed from selective cannulation until the end of procedure) was 4.5 ± 2.5 min, 4 ± 1.5 min and 5 ± 3.5 min in HCMS, FCMS and UCMS, respectively. The X-ray time was 2 ± 1 min, 2 ± 1.5 min and 2 ± 1 min, respectively.

Post-procedure outcomes are shown in Table 2. There was no procedure-related major adverse morbidity or mortality (Figure 1).

During follow-up, stent occlusion occurred in 36 out of 210 patients (18.6%, 17.1% and 15.7% in HCMS, FCMS and UCMS, respectively, $P = 0.9$) (Table 2). Stent migration occurred only in patients with FCMS (8.6% of patients). Cholecystitis, probably due to mechanical obstruction of cystic duct orifice exerted by the stent, was observed in four patients with FCMS. None of the patients developed cholecystitis in the HCMS and UCMS groups. Cholangitis occurred in 5.7% of patients in the FCMS group.

Early post-ERCP complications (within 1 mo)

Regarding procedure-related complications, pancreatitis occurred in 8.6%, 7.1% and 7.1% in HCMS, FCMS and UCM, respectively ($P = 0.93$); all cases were mild. Minor bleeding occurred in 5.7%, 4.3% and 7.1% in HCMS, FCMS and UCM, respectively ($P = 0.77$). Stent dysfunction occurred in six patients (stent migration occurred in one

Table 1 Patient characteristic among different groups

Number	Stent type, <i>n</i> = 70, <i>n</i> (%)			<i>P</i> value
	HCMS	FCMS	UMS	
Gender				0.86
Male	45 (64.3)	46 (65.7)	48 (68.6)	
Female	25 (33.7)	24 (34.3)	22 (31.4)	
Age, median (range)	67 (39-84)	65 (45-82)	64 (42-83)	0.37
Cholecystectomy	16 (22.9)	17 (24.3)	17 (24.3)	0.97
Cause of distal biliary obstruction				0.99
Cancer pancreas	47 (67.1)	48 (68.6)	46 (65.7)	
Distal cholangiocarcinoma	9 (12.9)	10 (14.3)	12 (17.2)	
Gallbladder cancer	5 (7.1)	4 (5.7)	5 (7.1)	
Ampullary cancer	9 (12.9)	8 (11.4)	7 (10.0)	
Laboratory investigations, mean \pm SD				
Serum total bilirubin, mg/dL	15 \pm 8.7	14.5 \pm 5.6	16.1 \pm 7.7	0.43
Serum direct bilirubin, mg/dL	13 \pm 6.4	12.9 \pm 4.1	13.2 \pm 6.8	0.95
SGPT, UI/L	112 \pm 90	110.7 \pm 96.5	120.2 \pm 90.3	0.80
SGOT, UI/L	146 \pm 110.2	129.3 \pm 106.2	142.4 \pm 112.1	0.64
Albumin	4.1 \pm 1.3	3.9 \pm 1.4	3.8 \pm 1.6	0.46
INR	1.3 \pm 0.2	1.2 \pm 0.2	1.2 \pm 0.2	0.94
Imaging				
Liver metastasis	2 (2.9)	1 (1.4)	1 (1.4)	0.78
PVT	1 (1.4)	1 (1.4)	2 (2.9)	0.78
Ascites	1 (1.4)	2 (2.9)	1 (1.4)	0.78
Clinical presentation				
Jaundice	57 (81.4)	55 (78.6)	55 (78.6)	0.89
Pain	34 (48.6)	31 (44.3)	34 (48.6)	0.84
Fever	9 (12.9)	8 (11.4)	9 (12.9)	0.96
Itching	16 (22.9)	15 (21.4)	18 (25.7)	0.83
Anorexia	27 (38.6)	26 (37.1)	20 (28.6)	0.41
Weight loss	44 (62.9)	42 (60.0)	45 (64.3)	0.87
Cholangitis	12 (17.1)	10 (14.3)	13 (18.6)	0.79
Operative time, time passed from selective cannulation till the end of procedure	4.5 \pm 2.5 min	4 \pm 3 min	5 \pm 3.5 min	0.15
X-ray dose, time passed from selective cannulation till the end of procedure	2 \pm 1 min	2 \pm 1.5 min	2 \pm 1 min	NA
Antibiotic				0.87
No	44 (62.9)	42 (60.0)	45 (64.3)	
Yes	26 (37.1)	28 (40.0)	25 (35.7)	
Previous chemotherapy				0.9
No	59 (84.3)	58 (82.9)	57 (81.4)	
Yes	11 (15.7)	12 (17.1)	13 (18.6)	
Radiotherapy				0.36

No	69 (98.6)	70 (100)	68 (97.1)	0.91
Yes	1 (1.4)	0 (0.0)	2 (2.9)	
Post-stenting chemotherapy				
No	55 (78.6)	56 (80.0)	57 (81.4)	
Yes	15 (21.4)	14 (20.0)	13 (19.6)	

HCMS: Half covered metal stent; FCMS: Fully covered metal stent; INR: International standard ratio; PVT: Production verification test; SGOT: Serum glutamic-oxaloacetic transaminase; SGPT: Serum glutamic-pyruvic transaminase; UMS: Uncovered metal stent.

Table 2 Patient outcomes among different groups

	Half and half stents, <i>n</i> (%)	Fully covered stents, <i>n</i> (%)	Un-covered stents, <i>n</i> (%)	<i>P</i> value
Successful deployment	70/70 (100)	70/70 (100)	70 /70 (100)	
Procedure related complications				
Major adverse events and or mortality	0	0	0	00
pancreatitis	6 (8.6)	5 (7.1)	5 (7.1)	0.93
Minor bleeding	4 (5.7)	3 (4.3)	5 (7.1)	0.77
Post-ERCP complications				
Occlusion	13 (18.6)	12 (17.1)	11 (15.7)	0.9
Early stent adverse effect, within 1 mo	1 (1.4)	4 (5.7)	1 (1.4)	0.21
Sludge formation	9 (12.9)	7 (11.1)	1 (1.4)	0.04
Tumor Ingrowth	0 (0.0)	0 (0.0)	10 (14.3)	0.00003
Tumor Overgrowth	4 (5.7)	5 (7.1)	0 (0.0)	0.09
Cholangitis due to stent occlusion	7 (10.0)	8 (11.4)	7 (10.0)	0.95
Cholecystitis	0 (0.0)	4 (5.7)	0 (0.0)	0.02
Migration	0 (0.0)	6 (8.6)	0 (0.0)	0.002
Stent patency in d, median (95%CI)	614 (390.6-780.1)	256.0 (167.5-315.4) ^{1,2}	536 (323.1-743.9)	0.02
Follow-up in d, median (range)	112 (5-613)	109 (7-621)	108 (7-541)	0.82
Overall survival in d, median (95%CI)	129 (96.8-167.1)	114.0 (92.7 -165.4)	119.0 (89.9-160.1)	0.20

¹Tamhane post-hoc *P* value < 0.05 between half and half stents and fully covered stents.

²Tamhane post-hoc *P* value < 0.05 between uncovered stents and fully covered stents. CI: Confidence interval; ERCP: Endoscopic retrograde cholangio-pancreatography.

patient in the FCMS group, cholangitis and stent obstruction occurred in one patient in each group, cholecystitis occurred in two patients in the FCMS group).

Late post-ERCP complications (after 1 mo)

Tumor ingrowth was found in 10 cases among patients with UCMS (six cases associated with cholangitis) after a median of 140 d (range 52-541 d). Tumor overgrowth occurred in four FCMS patients, five patients with HCMS, and none in the UCMS developed tumor overgrowth. Sludge and stent occlusion occurred in nine, seven and one patient in HCMS, CMS and UCMS, respectively, *P* = 0.04).

Table 2 shows follow-up, survival and stent patency (Table 2). Patients' follow-up was 112, 109 and 108 d in HCMS, FCMS and UCMS, respectively. The median survival rates were 129 d 95% confidence interval (CI), 114 d 95%CI and 119 d 95%CI for HCMS, FCMS and UCMS, respectively, *P* = 0.000002). The median rate for stent patency was 614 d at 95%CI, 256 d at 95%CI and 526 d at 95%CI for HCMS, FCMS and UCMS, respectively, (*P* = 0.02) (Figure 2).

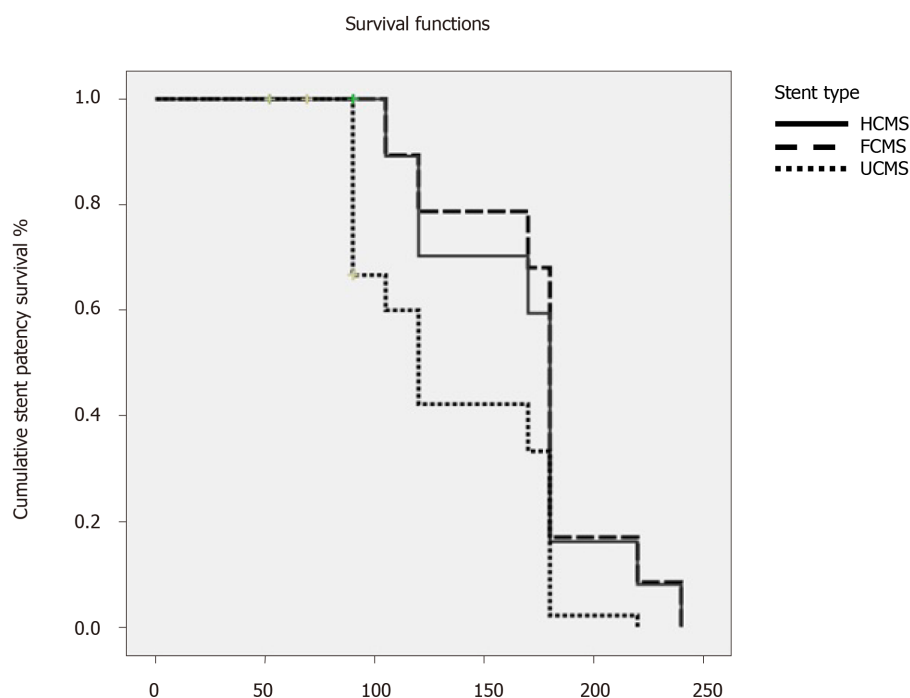


Figure 2 Kaplan Meier survival curve of stent patency with different types of stents. There is statistical significance regarding stent patency survival among the three types of stents, *P* value 0.000002 and log rank (Mantel-Cox) test 28.86, with median duration of stent patency of 170 d in HCMS stent type, 105 d in FCMS stent type and 90 d in UMS stent type. HCMS: Half covered metal stent; FCMS: Fully covered metal stent; UCMS: Uncovered metal stent.

DISCUSSION

The newly designed HCMS was introduced commercially to get the merits of FCMS in terms of stent survival by preventing tumor ingrowth through the covering membrane. At the same time, the uncovered half of HCMS prevents the high rates stent migration and cholecystitis inherent in the FCMS.

We speculate that the technical characteristics of the anti-migration power offered by the proximal uncovered part of the HCMS might play significant roles in prevention of HCMS stent displacement either intra-ductal or distal to the duodenum. Moreover, the commercially available FCMS was characterized by inefficient radial or axial forces in addition to the inefficient covering portion, which may influence stent function or stent survival. To the best of our knowledge, this is the first randomized study comparing the three commercially available metal stents in palliation of non-resectable or inoperable malignant distal biliary strictures.

In our study, successful stent deployment was achieved in all patients, and there were no significant differences among the three types of stents in term of factors of clinical efficacy and serum bilirubin reduction. The early procedure related adverse events (pancreatitis and bleeding) were not significantly different among all groups. Early secondary re-interventions resulting from early stent dysfunction were reported in (one, four and one patients in HCMS, FCMS and UCMS respectively).

Early stent-related adverse events (within 1 mo) were reported in more patients with HCMS than those with FCMS and UCMS insertion. However, HCMS showed significantly better median patency rates than FCMS and UCMS. The main cause of HCMS and FCMS dysfunction was early occlusion with cholangitis due to sludge or overgrowth, while in UCMS, occlusion occurred due to tumor ingrowth. Stent migration was a more added cause for stent dysfunction. In our studied patients, there was no significant difference regarding procedure-related pancreatitis and bleeding among the studied groups.

Stent patency was higher among the HCMS group, given that the migration rate was less in comparison to the other two groups. Cholecystitis occurred more frequently in patients with a covered stent than the other two groups based on mechanical obstruction caused by covering membrane of the FCMS and/or the chemical injury caused by stent membrane.

Several clinical trials have discussed the advantage of each type of previously available stent (FCMS and UCMS). These studies have shown the superiority of FCMS over UCMS in term of stent patency and function in patients with malignant distal

biliary obstruction^[6,7,14,23-29]. Another advantage of covered stents over UCMS is the ease of removability, given its lack of adherence to tumorous tissues.

Since 2011, five meta-analysis studies comparing FCMS and UCMS have been published. However, these studies have evaluated heterogeneous cohorts with retrospective and prospective nature. Moreover, percutaneous and endoscopic approaches of deployments were used^[15,23,30-32].

In an analysis by Saleem *et al*^[30], the patency of FCMS was significantly longer than that of UCMS. Although the stent obstruction was detected at similar a rate in both groups, patients with FCMS tended to develop stent dysfunction later than patents with UCMS^[30,33]. Stent migration was noticed significantly more in another meta-analysis^[31] among patients with FCMS; however, patients experienced no difference in stent patency within the first 6 mo post-procedure. In another three meta-analyses^[15,31,32], there was no reported difference in term of stent patency, patient survival or adverse events between both groups.

In our patients, we designed the current study to apply a closer look and to shed more light on the newly introduced stent. The HCMS has a covering membrane in its distal portion to avoid tumor ingrowth. At the same time, it has the advantage of UCMS in terms of an absence of covering membrane in its proximal part, which allows bile to flow through its mesh from the cystic duct and hence avoidance of cholecystitis associated with FCMS. At the same time, it devotes its proximal portion to anti-migration maintaining efficient axial and radial forces that in turn prevent stent displacement.

In our patients with HCMS insertion, none developed stent migration and tumor ingrowth, similar to patients with UCMS insertion. At the same time, none of them developed stent migration or cholecystitis like patients with UCMS insertion.

The discrepancies between the findings of our study and the findings of aforementioned meta-analyses studies may be due to the use of the newly introduced stent, the heterogeneity in the study designs, degree and level of stricture, the characteristics of tumors that cause biliary stricture and stent configurations and materials.

Aiming to reduce the confounding bias of our findings in correspondence to stent materials, we used three types of stents from the same manufacture. So, our findings may not be generalizable to other types of metal stents. Given the results of our study, we supposed that HCMS stents are the best choice in this group of patients due to the inherent advantages of both types of its characteristics. However, early occlusions of the HCMS and FCMS were noticed due to tumor overgrowth, and these finding were surprising and controversial, when compared with other studies^[15,20,23,30-34]. Conio *et al*^[20] have explained that this overgrowth may be due to a created tissue hyperplasia induced by inflammatory reaction caused by the membrane covering of the stents rather than a true tumor overgrowth. And so, the overgrowth material is principally due to granulation tissue rather than tumorous tissue^[20].

In our study and Lee *et al*^[29], the FCMS patency was not significantly better than UCMS. Notably, stent migration occurred more in patients with FCMS. However, with use of HCMS, the migration was similar to UCMS and less than FCMS. Similar findings regarding the absence of stent migration in patients treated with UCMS were found in previously published studies^[5,23-30,33]. In our patients and in Conio *et al*^[20], the migration rate for FCMS was significantly higher than in other studies^[27,28]. Probably in these trials, the endoscopists used stents with an anti-migration system consisting of a portion of uncovered flares at both ends^[24]. However, Yang *et al*^[15] found no clinical usefulness of the anti-migration design^[15,34].

Mechanical closure of the orifice of cystic and pancreatic ducts by the covering membrane of FCMS resulted in higher rates of post-ERCP cholecystitis and pancreatitis^[14,19,20,24,26]. To avoid post-ERCP pancreatitis with FCMS, Conio *et al*^[20] advised not to place long FCMS. The post-ERCP cholecystitis could be avoided with use of HCMS or UCMS^[20]. However, Isayama *et al*^[14] found that the post-ERCP cholecystitis occurred only in cases with cystic duct invasion rather than with the use of FCMS. In our study, no significant difference was found among the different groups regarding pancreatitis, although Isayama *et al*^[14] found significantly more cases of mild pancreatitis in FCMS *vs* UCMS (8.7% *vs* 1.8%)^[14]. The difference in procedure-related pancreatitis may be due to the routine performance of small papillotomy in our patients to facilitate stent deployment. However, post-ERCP pancreatitis is a multifactorial adverse event.

The present study has many strengths, including its prospective and randomization design, comparison among three types of metal stents, the stent material was from the same manufacture, the relatively large number of included patients and the close follow-up period to assess stent patency and patient's survival.

This study was limited by being a single center study with possible lack of generalizability to other centers. However, this factor is unlikely to compromise the results of our study, based on the relatively large number of included patients and the high volume of ERCP procedure conducted in our center.

The study was also limited by the heterogeneity of included patients regarding the cause of biliary obstruction, the use of pre- and post-procedure anti-cancer therapies in some patients and possible lack of possible generalizability to other types of metal stents from other manufacturers. In addition, quality of life and cost were not assessed.

In conclusion, given the prolonged stent function, in terms of longer patency and decreased rates of migration, cholecystitis and tissue ingrowth, the use of HCMS is preferred over the use of UCMS and FCMS in palliation for distal malignant biliary obstruction. Our results need to be supported by additional studies. Cost and patients' quality of life should be addressed.

ARTICLE HIGHLIGHTS

Research background

Most patients with malignant obstructive jaundice present at the unresectable stage, when the management is restricted only to palliative measures. The common causes of distal malignant biliary strictures are cancer of the head of the pancreas and extrahepatic cholangiocarcinoma. This is mostly treated with metal stent insertion placement for biliary drainage.

Research motivation

Many types of metal stents are commercially available, including covered and uncovered stents. However, it is still questionable which type of stent is more suitable for drainage, and half covered metal stents have been recently introduced.

Research objectives

To study the adverse effects and functionality of the recently introduced half covered metal stents *vs* fully covered and uncovered ones.

Research methods

We studied 210 patients and randomized them into three equal groups to investigate the functionality and performance of the three different types of metal stents which are the newly introduced half covered *vs* fully and uncovered metal stents.

Research results

The half covered metal stents showed no significant difference in the incidence of occlusion while significantly less incidence of migration than uncovered stents. In addition, the half covered stents showed significantly more functioning and patency time.

Research conclusions

The use of half covered metal stent is preferred over the use of uncovered metal stent and fully covered metal stent for optimizing biliary drainage in patients with distal inoperable malignant biliary obstruction.

Research perspectives

Our findings will appeal to endoscopists and promote the use of half covered metal stents for biliary drainage of malignant obstructive jaundice because of the decrease in adverse events and migration and the increase in functioning time.

REFERENCES

- 1 Abraham NS, Barkun JS, Barkun AN. Palliation of malignant biliary obstruction: a prospective trial examining impact on quality of life. *Gastrointest Endosc* 2002; **56**: 835-841 [PMID: 12447294 DOI: 10.1016/S0016-5107(02)70356-8]
- 2 Martin FA. The merck manual of geriatrics, 1st Ed. William B. Abrams, Robert Berkow, Merck Sharp & Dohme, Rahway, NJ, 1990, 1267 pages. *JPEN J Parenter Enteral Nutr* 1992; **16**: 88 [DOI: 10.1177/014860719201600121]
- 3 Cubiella J, Castells A, Fondevila C, Sans M, Sabater L, Navarro S, Fernández-Cruz L. Prognostic factors in

- nonresectable pancreatic adenocarcinoma: a rationale to design therapeutic trials. *Am J Gastroenterol* 1999; **94**: 1271-1278 [PMID: 10235206 DOI: 10.1111/j.1572-0241.1999.01018.x]
- 4 **Speer AG**, Cotton PB, Russell RC, Mason RR, Hatfield AR, Leung JW, MacRae KD, Houghton J, Lennon CA. Randomised trial of endoscopic versus percutaneous stent insertion in malignant obstructive jaundice. *Lancet* 1987; **2**: 57-62 [PMID: 2439854 DOI: 10.1016/S0140-6736(87)92733-4]
 - 5 **Moss AC**, Morris E, Leyden J, MacMathuna P. Malignant distal biliary obstruction: a systematic review and meta-analysis of endoscopic and surgical bypass results. *Cancer Treat Rev* 2007; **33**: 213-221 [PMID: 17157990 DOI: 10.1016/j.ctrv.2006.10.006]
 - 6 **Mendonça EQ**, Bernardo WM, Moura EG, Chaves DM, Kondo A, Pu LZ, Baracat FI. Endoscopic versus surgical treatment of ampullary adenomas: a systematic review and meta-analysis. *Clinics (Sao Paulo)* 2016; **71**: 28-35 [PMID: 26872081 DOI: 10.6061/clinics/2016(01)06]
 - 7 **Sawas T**, Al Halabi S, Parsi MA, Vargo JJ. Self-expandable metal stents versus plastic stents for malignant biliary obstruction: a meta-analysis. *Gastrointest Endosc* 2015; **82**: 256-267.e7 [PMID: 25982849 DOI: 10.1016/j.gie.2015.03.1980]
 - 8 **Dumonceau JM**, Cremer M, Auroux J, Delhay M, Devière J. A comparison of Ultraflex Diamond stents and Wallstents for palliation of distal malignant biliary strictures. *Am J Gastroenterol* 2000; **95**: 670-676 [PMID: 10710055 DOI: 10.1111/j.1572-0241.2000.01844.x]
 - 9 **Ferlitsch A**, Oesterreicher C, Dumonceau JM, Deviere J, Leban T, Born P, Rösch T, Suter W, Binek J, Meyenberger C, Müllner M, Schneider B, Schöfl R. Diamond stents for palliation of malignant bile duct obstruction: a prospective multicenter evaluation. *Endoscopy* 2001; **33**: 645-650 [PMID: 11490378 DOI: 10.1055/s-2001-16214]
 - 10 **Ahmad J**, Siqueira E, Martin J, Slivka A. Effectiveness of the Ultraflex Diamond stent for the palliation of malignant biliary obstruction. *Endoscopy* 2002; **34**: 793-796 [PMID: 12244500 DOI: 10.1055/s-2002-34269]
 - 11 **Shah RJ**, Howell DA, Desilets DJ, Sheth SG, Parsons WG, Okolo P 3rd, Lehman GA, Sherman S, Baillie J, Branch MS, Pleskow D, Chuttani R, Bosco JJ. Multicenter randomized trial of the spiral Z-stent compared with the Wallstent for malignant biliary obstruction. *Gastrointest Endosc* 2003; **57**: 830-836 [PMID: 12776028 DOI: 10.1016/S0016-5107(03)70016-9]
 - 12 **Kaassis M**, Boyer J, Dumas R, Ponchon T, Coumaros D, Delcenserie R, Canard JM, Fritsch J, Rey JF, Burtin P. Plastic or metal stents for malignant stricture of the common bile duct? Results of a randomized prospective study. *Gastrointest Endosc* 2003; **57**: 178-182 [PMID: 12556780 DOI: 10.1067/mge.2003.66]
 - 13 **Knyrim K**, Wagner HJ, Pausch J, Vakil N. A prospective, randomized, controlled trial of metal stents for malignant obstruction of the common bile duct. *Endoscopy* 1993; **25**: 207-212 [PMID: 8519239 DOI: 10.1055/s-2007-1010294]
 - 14 **Isayama H**, Komatsu Y, Tsujino T, Sasahira N, Hirano K, Toda N, Nakai Y, Yamamoto N, Tada M, Yoshida H, Shiratori Y, Kawabe T, Omata M. A prospective randomised study of "covered" versus "uncovered" diamond stents for the management of distal malignant biliary obstruction. *Gut* 2004; **53**: 729-734 [PMID: 15082593 DOI: 10.1136/gut.2003.018945]
 - 15 **Yang Z**, Wu Q, Wang F, Ye X, Qi X, Fan D. A systematic review and meta-analysis of randomized trials and prospective studies comparing covered and bare self-expandable metal stents for the treatment of malignant obstruction in the digestive tract. *Int J Med Sci* 2013; **10**: 825-835 [PMID: 23794946 DOI: 10.7150/ijms.5969]
 - 16 **Moole H**, Bechtold ML, Cashman M, Volmar FH, Dhillon S, Forcione D, Taneja D, Puli SR. Covered versus uncovered self-expandable metal stents for malignant biliary strictures: A meta-analysis and systematic review. *Indian J Gastroenterol* 2016; **35**: 323-330 [PMID: 27566620 DOI: 10.1007/s12664-016-0682-8]
 - 17 **Chen MY**, Lin JW, Zhu HP, Zhang B, Jiang GY, Yan PJ, Cai XJ. Covered Stents versus Uncovered Stents for Unresectable Malignant Biliary Strictures: A Meta-Analysis. *Biomed Res Int* 2016; **2016**: 6408067 [PMID: 27051667 DOI: 10.1155/2016/6408067]
 - 18 **Yang MJ**, Kim JH, Yoo BM, Hwang JC, Yoo JH, Lee KS, Kang JK, Kim SS, Lim SG, Shin SJ, Cheong JY, Lee KM, Lee KJ, Cho SW. Partially covered versus uncovered self-expandable nitinol stents with anti-migration properties for the palliation of malignant distal biliary obstruction: A randomized controlled trial. *Scand J Gastroenterol* 2015; **50**: 1490-1499 [PMID: 26133200 DOI: 10.3109/00365521.2015.1057219]
 - 19 **Tringali A**, Hassan C, Rota M, Rossi M, Mutignani M, Aabakken L. Covered vs. uncovered self-expandable metal stents for malignant distal biliary strictures: a systematic review and meta-analysis. *Endoscopy* 2018; **50**: 631-641 [PMID: 29342491 DOI: 10.1055/s-0043-125062]
 - 20 **Conio M**, Mangiavillano B, Caruso A, Filiberti RA, Baron TH, De Luca L, Signorelli S, Crespi M, Marini M, Ravelli P, Conigliaro R, De Ceglie A. Covered versus uncovered self-expandable metal stent for palliation of primary malignant extrahepatic biliary strictures: a randomized multicenter study. *Gastrointest Endosc* 2018; **88**: 283-291.e3 [PMID: 29653120 DOI: 10.1016/j.gie.2018.03.029]
 - 21 **Cotton PB**, Eisen GM, Aabakken L, Baron TH, Hutter MM, Jacobson BC, Mergener K, Nemcek A Jr, Petersen BT, Petrini JL, Pike IM, Rabeneck L, Romagnuolo J, Vargo JJ. A lexicon for endoscopic adverse events: report of an ASGE workshop. *Gastrointest Endosc* 2010; **71**: 446-454 [PMID: 20189503 DOI: 10.1016/j.gie.2009.10.027]
 - 22 **Cotton PB**, Lehman G, Vennes J, Geenen JE, Russell RC, Meyers WC, Liguory C, Nickl N. Endoscopic sphincterotomy complications and their management: an attempt at consensus. *Gastrointest Endosc* 1991; **37**: 383-393 [PMID: 2070995 DOI: 10.1016/S0016-5107(91)70740-2]
 - 23 **Ung KA**, Stotzer PO, Nilsson A, Gustavsson ML, Johnsson E. Covered and uncovered self-expandable metallic Hanarostents are equally efficacious in the drainage of extrahepatic malignant strictures. Results of a double-blind randomized study. *Scand J Gastroenterol* 2013; **48**: 459-465 [PMID: 23373541 DOI: 10.3109/00365521.2012.758766]
 - 24 **Kitano M**, Yamashita Y, Tanaka K, Konishi H, Yazumi S, Nakai Y, Nishiyama O, Uehara H, Mitoro A, Sanuki T, Takaoka M, Koshitani T, Arisaka Y, Shiba M, Hoki N, Sato H, Sasaki Y, Sato M, Hasegawa K, Kawabata H, Okabe Y, Mukai H. Covered self-expandable metal stents with an anti-migration system improve patency duration without increased complications compared with uncovered stents for distal biliary obstruction caused by pancreatic carcinoma: a randomized multicenter trial. *Am J Gastroenterol* 2013; **108**: 1713-1722 [PMID: 24042190 DOI: 10.1038/ajg.2013.305]

- 25 **Yoon WJ**, Lee JK, Lee KH, Lee WJ, Ryu JK, Kim YT, Yoon YB. A comparison of covered and uncovered Wallstents for the management of distal malignant biliary obstruction. *Gastrointest Endosc* 2006; **63**: 996-1000 [PMID: [16733115](#) DOI: [10.1016/j.gie.2005.11.054](#)]
- 26 **Park DH**, Kim MH, Choi JS, Lee SS, Seo DW, Kim JH, Han J, Kim JC, Choi EK, Lee SK. Covered versus uncovered wallstent for malignant extrahepatic biliary obstruction: a cohort comparative analysis. *Clin Gastroenterol Hepatol* 2006; **4**: 790-796 [PMID: [16716757](#) DOI: [10.1016/j.cgh.2006.03.032](#)]
- 27 **Telford JJ**, Carr-Locke DL, Baron TH, Ponerros JM, Bounds BC, Kelsey PB, Schapiro RH, Huang CS, Lichtenstein DR, Jacobson BC, Saltzman JR, Thompson CC, Forcione DG, Gostout CJ, Brugge WR. A randomized trial comparing uncovered and partially covered self-expandable metal stents in the palliation of distal malignant biliary obstruction. *Gastrointest Endosc* 2010; **72**: 907-914 [PMID: [21034891](#) DOI: [10.1016/j.gie.2010.08.021](#)]
- 28 **Kullman E**, Frozanpor F, Söderlund C, Linder S, Sandström P, Lindhoff-Larsson A, Toth E, Lindell G, Jonas E, Freedman J, Ljungman M, Rudberg C, Ohlin B, Zacharias R, Leijonmarck CE, Teder K, Ringman A, Persson G, Gözen M, Eriksson O. Covered versus uncovered self-expandable nitinol stents in the palliative treatment of malignant distal biliary obstruction: results from a randomized, multicenter study. *Gastrointest Endosc* 2010; **72**: 915-923 [PMID: [21034892](#) DOI: [10.1016/j.gie.2010.07.036](#)]
- 29 **Lee JH**, Krishna SG, Singh A, Ladha HS, Slack RS, Ramireddy S, Raju GS, Davila M, Ross WA. Comparison of the utility of covered metal stents versus uncovered metal stents in the management of malignant biliary strictures in 749 patients. *Gastrointest Endosc* 2013; **78**: 312-324 [PMID: [23591331](#) DOI: [10.1016/j.gie.2013.02.032](#)]
- 30 **Saleem A**, Leggett CL, Murad MH, Baron TH. Meta-analysis of randomized trials comparing the patency of covered and uncovered self-expandable metal stents for palliation of distal malignant bile duct obstruction. *Gastrointest Endosc* 2011; **74**: 321-327.e1-3 [PMID: [21683354](#) DOI: [10.1016/j.gie.2011.03.1249](#)]
- 31 **Li J**, Li T, Sun P, Yu Q, Wang K, Chang W, Song Z, Zheng Q. Covered versus Uncovered Self-Expandable Metal Stents for Managing Malignant Distal Biliary Obstruction: A Meta-Analysis. *PLoS One* 2016; **11**: e0149066 [PMID: [26859673](#) DOI: [10.1371/journal.pone.0149066](#)]
- 32 **Almadi MA**, Barkun AN, Martel M. No benefit of covered vs uncovered self-expandable metal stents in patients with malignant distal biliary obstruction: a meta-analysis. *Clin Gastroenterol Hepatol* 2013; **11**: 27-37.e1 [PMID: [23103324](#) DOI: [10.1016/j.cgh.2012.10.019](#)]
- 33 **Nakai Y**, Isayama H, Wang HP, Rerknimitr R, Khor C, Yasuda I, Kogure H, Moon JH, Lau J, Lakhtakia S, Ratanachu-Ek T, Seo DW, Lee DK, Makmun D, Dy F, Liao WC, Draganov PV, Almadi M, Irisawa A, Katanuma A, Kitano M, Ryozaawa S, Fujisawa T, Wallace MB, Itoi T, Devereaux B. International consensus statements for endoscopic management of distal biliary stricture. *J Gastroenterol Hepatol* 2020; **35**: 967-979 [PMID: [31802537](#) DOI: [10.1111/jgh.14955](#)]
- 34 **Fernandez Y Viesca M**, Arvanitakis M. Early Diagnosis And Management Of Malignant Distal Biliary Obstruction: A Review On Current Recommendations And Guidelines. *Clin Exp Gastroenterol* 2019; **12**: 415-432 [PMID: [31807048](#) DOI: [10.2147/CEG.S195714](#)]



Published by **Baishideng Publishing Group Inc**
7041 Koll Center Parkway, Suite 160, Pleasanton, CA 94566, USA

Telephone: +1-925-3991568

E-mail: bpgoffice@wjgnet.com

Help Desk: <https://www.f6publishing.com/helpdesk>

<https://www.wjgnet.com>

