

# World Journal of *Gastrointestinal Endoscopy*

*World J Gastrointest Endosc* 2020 September 16; 12(9): 256-322



## EXPERT RECOMMENDATIONS

- 256 Endoscopy during COVID-19 pandemic: An overview of infection control measures and practical application  
*Teng M, Tang SY, Koh CJ*

## ORIGINAL ARTICLE

## Retrospective Study

- 266 Comparison of the reverse bevel versus Franseen type endoscopic ultrasound needle  
*Chow CW, Haider SA, Ragnath K, Aithal GP, James MW, Ortiz-Fernandez-Sordo J, Aravinthan AD, Venkatachalapathy SV*
- 276 Kyoto classification in patients who developed multiple gastric carcinomas after *Helicobacter pylori* eradication  
*Sakitani K, Nishizawa T, Toyoshima A, Yoshida S, Matsuno T, Yamada T, Irokawa M, Takahashi Y, Nakai Y, Toyoshima O, Koike K*

## Observational Study

- 285 Optimization of biliary drainage in inoperable distal malignant strictures  
*Elshimi E, Morad W, Elshaarawy O, Attia A*

## CASE REPORT

- 297 Endoscopic approach to gastric remnant outlet obstruction after gastric bypass: A case report  
*Zarrin A, Sorathia S, Choksi V, Kaplan SR, Kasmin F*
- 304 Small invasive colon cancer with adenoma observed by endocytoscopy: A case report  
*Akimoto Y, Kudo SE, Ichimasa K, Kouyama Y, Misawa M, Hisayuki T, Kudo T, Nemoto T*
- 310 Laparoscopy-assisted resection of colorectal cancer with situs inversus totalis: A case report and literature review  
*Chen W, Liang JL, Ye JW, Luo YX, Huang MJ*

## LETTER TO THE EDITOR

- 317 Do available data support the widespread adoption of pancreatoscopy guided-lithotripsy?  
*De Luca L*
- 320 Comment on: Should a colonoscopy be offered routinely to patients with CT proven acute diverticulitis? A retrospective cohort study and meta-analysis of best available evidence  
*Meyer J, Buchs NC, Schiltz B, Liot E, Ris F*

## ABOUT COVER

Editor-in-Chief of *World Journal of Gastrointestinal Endoscopy*, Dr. Sang Chul Lee is a Professor in the Department of General Surgery of the College of Medicine, Catholic University of Korea and a Colorectal Surgeon at Daejeon St. Mary's Hospital, which is famous for minimally invasive surgery in Korea. His clinical practice specialization in laparoscopic surgery involves a focus in the field of single-port laparoscopic techniques. His standard and routine operation modality is single-port laparoscopic SOLO surgery, with application in a vast spectrum of disease entities and conducted by use of a camera-holder instead of a human assistant. His ongoing research interests are minimally invasive surgery and endoscopic procedures, and for the last several years, he has been performing completely scar-less surgeries. He serves as editorial board member and reviewer for several scientific journals and has published more than 120 peer-reviewed articles. (L-Editor: Filipodia)

## AIMS AND SCOPE

The primary aim of *World Journal of Gastrointestinal Endoscopy* (WJGE, *World J Gastrointest Endosc*) is to provide scholars and readers from various fields of gastrointestinal endoscopy with a platform to publish high-quality basic and clinical research articles and communicate their research findings online.

WJGE mainly publishes articles reporting research results and findings obtained in the field of gastrointestinal endoscopy and covering a wide range of topics including capsule endoscopy, colonoscopy, double-balloon enteroscopy, duodenoscopy, endoscopic retrograde cholangiopancreatography, endosonography, esophagoscopy, gastrointestinal endoscopy, gastroscopy, laparoscopy, natural orifice endoscopic surgery, proctoscopy, and sigmoidoscopy.

## INDEXING/ABSTRACTING

The WJGE is now abstracted and indexed in Emerging Sources Citation Index (Web of Science), PubMed, PubMed Central, China National Knowledge Infrastructure (CNKI), and Superstar Journals Database.

## RESPONSIBLE EDITORS FOR THIS ISSUE

Production Editor: Li-Li Wang; Production Department Director: Yun-Xiaojuan Wu; Editorial Office Director: Jia-Ping Yan.

### NAME OF JOURNAL

*World Journal of Gastrointestinal Endoscopy*

### ISSN

ISSN 1948-5190 (online)

### LAUNCH DATE

October 15, 2009

### FREQUENCY

Monthly

### EDITORS-IN-CHIEF

Anastasios Koulaouzidis, Bing Hu, Sang Chul Lee

### EDITORIAL BOARD MEMBERS

<https://www.wjgnet.com/1948-5190/editorialboard.htm>

### PUBLICATION DATE

September 16, 2020

### COPYRIGHT

© 2020 Baishideng Publishing Group Inc

### INSTRUCTIONS TO AUTHORS

<https://www.wjgnet.com/bpg/gerinfo/204>

### GUIDELINES FOR ETHICS DOCUMENTS

<https://www.wjgnet.com/bpg/GerInfo/287>

### GUIDELINES FOR NON-NATIVE SPEAKERS OF ENGLISH

<https://www.wjgnet.com/bpg/gerinfo/240>

### PUBLICATION ETHICS

<https://www.wjgnet.com/bpg/GerInfo/288>

### PUBLICATION MISCONDUCT

<https://www.wjgnet.com/bpg/gerinfo/208>

### ARTICLE PROCESSING CHARGE

<https://www.wjgnet.com/bpg/gerinfo/242>

### STEPS FOR SUBMITTING MANUSCRIPTS

<https://www.wjgnet.com/bpg/GerInfo/239>

### ONLINE SUBMISSION

<https://www.f6publishing.com>



## Laparoscopy-assisted resection of colorectal cancer with situs inversus totalis: A case report and literature review

Wei Chen, Jing-Lin Liang, Jun-Wen Ye, Yan-Xin Luo, Mei-Jin Huang

**ORCID number:** Wei Chen 0000-0002-6444-1724; Jing-Lin Liang 0000-0002-6090-4939; Jun-Wen Ye 0000-0002-9435-7312; Yan-Xin Luo 0000-0002-5200-3997; Mei-Jin Huang 0000-0002-5639-8092.

**Author contributions:** Chen W, Liang JL, Ye JW, Luo YX, and Huang MJ contributed to the study design, data collection, analysis, and interpretation, drafting of the final manuscript, and supervision; all authors approved the final version of the manuscript.

**Informed consent statement:** Informed written consent was obtained from the patient for publication of this report and any accompanying images.

**Conflict-of-interest statement:** The authors declare that they have no conflict of interest.

**CARE Checklist (2016) statement:** The authors have read the CARE Checklist (2016), and the manuscript was prepared and revised according to the CARE Checklist (2016).

**Open-Access:** This article is an open-access article that was selected by an in-house editor and fully peer-reviewed by external reviewers. It is distributed in accordance with the Creative Commons Attribution

Wei Chen, Jing-Lin Liang, Jun-Wen Ye, Yan-Xin Luo, Mei-Jin Huang, Department of Colorectal Surgery, The Six Affiliated Hospital, Sun Yat-sen University, Guangzhou 510655, Guangdong Province, China

**Corresponding author:** Mei-Jin Huang, PhD, Academic Fellow, Doctor, Department of Colorectal Surgery, The Six Affiliated Hospital, Sun Yat-sen University, No. 26 Yuancun Erheng Road, Tianhe District, Guangzhou 510655, Guangdong Province, China. [13924073322@139.com](mailto:13924073322@139.com)

### Abstract

#### BACKGROUND

Situs inversus totalis (SIT) is a rare anomaly in which structures are located opposite to their usual positions. It is not a premalignant condition and the association with colorectal cancer (CRC) is rare. We here report a patient with SIT who underwent laparoscopic radical resection of sigmoid colon cancer, and review the pertinent literature.

#### CASE SUMMARY

A 53-year-old woman presented with CRC and SIT and underwent a complete examination after admission. The patient then underwent laparoscopic radical resection of sigmoid colon cancer and hyperthermic intraperitoneal chemotherapy. The operation duration was 120 min, and no intraoperative complications occurred. The final pathological report showed stage T4aN0M0. Postoperative chemotherapy was administered and no evidence of recurrence was observed during 18 mo of follow-up.

#### CONCLUSION

Surgery in a patient with CRC and SIT can be safely performed on the basis of routine preoperative clinical examination.

**Key Words:** Colorectal cancer; Situs inversus totalis; Hyperthermic intraperitoneal chemotherapy; Case report

©The Author(s) 2020. Published by Baishideng Publishing Group Inc. All rights reserved.

**Core Tip:** Situs inversus totalis is a rare anomaly in which structures are located opposite to

NonCommercial (CC BY-NC 4.0) license, which permits others to distribute, remix, adapt, build upon this work non-commercially, and license their derivative works on different terms, provided the original work is properly cited and the use is non-commercial. See: <http://creativecommons.org/licenses/by-nc/4.0/>

**Manuscript source:** Invited manuscript

**Received:** April 9, 2020

**Peer-review started:** April 9, 2020

**First decision:** June 8, 2020

**Revised:** July 9, 2020

**Accepted:** August 4, 2020

**Article in press:** August 4, 2020

**Published online:** September 16, 2020

**P-Reviewer:** Mitsui K, Suzuki H

**S-Editor:** Zhang L

**L-Editor:** Wang TQ

**P-Editor:** Wang LL



their usual positions. It is not a premalignant condition and the association with colorectal cancer is rare. We here report a case and review the literature. In sum, a 53-year-old woman presented with colorectal cancer and situs inversus totalis and underwent a complete examination after admission. The patient then underwent laparoscopic radical resection of sigmoid colon cancer and hyperthermic intraperitoneal chemotherapy. The final pathological report showed stage T4aN0M0. Postoperative chemotherapy was administered and no evidence of recurrence was observed during 18 mo of follow-up.

**Citation:** Chen W, Liang JL, Ye JW, Luo YX, Huang MJ. Laparoscopy-assisted resection of colorectal cancer with situs inversus totalis: A case report and literature review. *World J Gastrointest Endosc* 2020; 12(9): 310-316

**URL:** <https://www.wjgnet.com/1948-5190/full/v12/i9/310.htm>

**DOI:** <https://dx.doi.org/10.4253/wjge.v12.i9.310>

## INTRODUCTION

Situs inversus totalis (SIT) refers to the complete reversal of unpaired tissues and organs in the thoracic and abdominal cavity. It is an extremely rare congenital disease with an incidence of approximately 1/4000-8000<sup>[1]</sup>. According to statistics, the incidence of intestinal cancer is about 376.3/100000, and patients with intestinal cancer and visceral transposition are even rare. When lesions of internal organs in the reverse position occur, patients are easily misdiagnosed if imaging data are not available. We here report a patient with complete visceral transposition combined with sigmoid colon cancer. To the best of our knowledge, this is the first case report of sigmoid colon cancer associated with SIT in China. We also review the relevant literature and discuss the diagnosis and treatment of this patient.

## CASE PRESENTATION

### Chief complaints

In December 2017, a 53-year-old woman was admitted to our hospital due to lower abdominal discomfort for 1 wk.

### History of present illness

The patient's symptoms started a week ago with recurrent lower abdominal discomfort, which had been worsened the last 24 h.

### History of past illness

The patient had a free previous medical history.

### Physical examination

Initial vital signs were stable, and a systemic review and physical examination revealed nothing of note. However, the apex beat of her heart was located in the fifth intercostal space of the right clavicle midline.

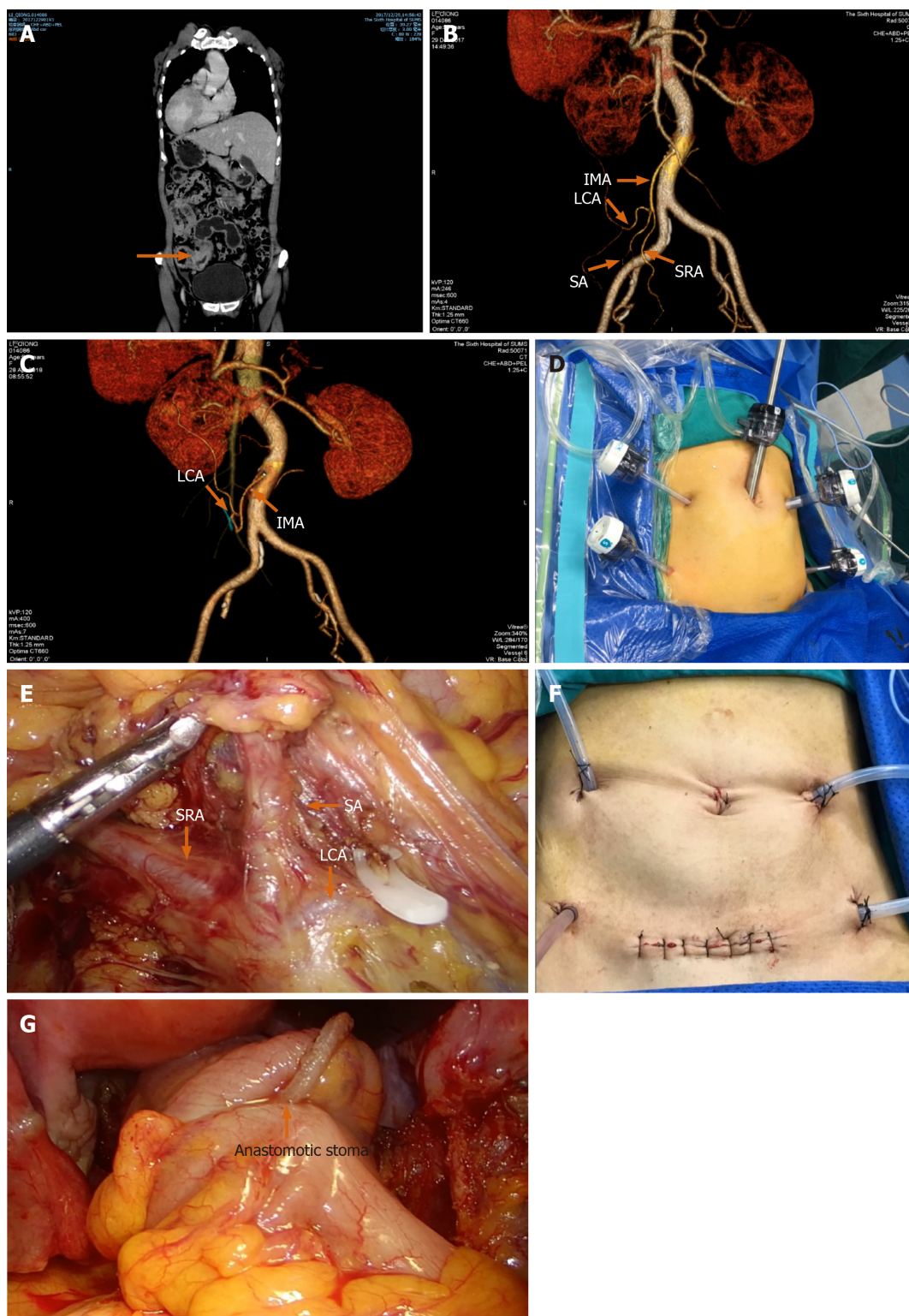
### Laboratory examinations

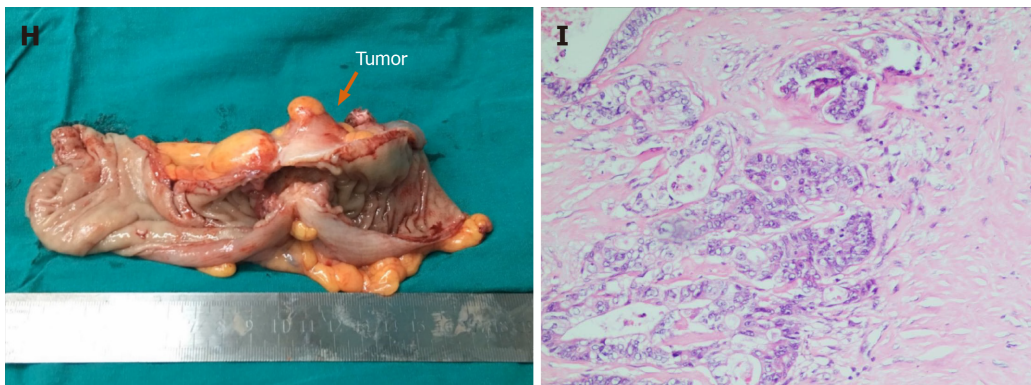
Serum carcinoembryonic antigen level was elevated (68.5 ng/mL; reference range, 0-5.0 ng/mL).

### Imaging examinations

Colonoscopy revealed an obstructing sigmoid mass. Histological examination of the biopsied specimen indicated a moderately differentiated adenocarcinoma. Preoperative thoracic and abdominal enhanced computed tomography showed a complete right-left reversal of the thoracic and abdominal organs, sigmoid colon wall thickening, and the surrounding mesentery scattered with lymph nodes around the primary tumor (Figure 1A). A three-dimensional vascular reconstruction technique was used to observe the anatomy and variation of mesenteric vessels, and the anatomy of the vascular arch was clearly displayed (Figure 1B and C).







**Figure 1 Images of computed tomography, operation, and histopathological examination.** A: Computed tomography showing transposition of the abdominal; B: Three-dimensional reconstruction image of computed tomography angiography showing three branches of the inferior mesenteric artery, left colic artery, sigmoid artery, and superior rectal artery; C: Postoperative three-dimensional reconstruction of computed tomography angiography; D: Sites of trocar placement. A camera was inserted into the subumbilical area through a 12-mm trocar; the 12-mm trocar marked indicates the main operation hole; E: Exposure of each blood vessel during operation; F: The anastomotic stoma; G: Placement of a perfusion tube for hyperthermic intraperitoneal chemotherapy; H: Resected specimen showing a ulcerated mass in sigmoid colon; I: Histopathological examination. IMA: Inferior mesenteric artery; LCA: Left colic artery; SA: Sigmoid artery; SRA: Superior rectal artery.

## FINAL DIAGNOSIS

The final diagnosis was CRC with SIT.

## TREATMENT

On January 5, 2018, under general anesthesia, laparoscopic radical sigmoidectomy was performed and hyperthermic intraperitoneal chemotherapy was administered twice (Figure 1D and G). The surgical method of low ligation in combination with highly selective lymph node dissection was adopted to preserve the left colic artery in order to lower the postoperative incidence of anastomotic fistula. Postoperative pathological staging was T4aN0M0 based on the criteria proposed by the International Union Against Cancer (Figure 1H and I).

## OUTCOME AND FOLLOW-UP

The patient recovered well after surgery, and regular chemotherapy (mFOLFOX6) was performed 8 times. During the regular 18 mo of follow-up, no tumor recurrence was observed and the patient's general condition was good.

## DISCUSSION

We searched the compact disc read-only memory database of Chinese biomedical literature and the PubMed-indexed for MEDLINE search system to retrieve reports on visceral transposition combined with intestinal cancer published from January 2000 to May 2019. The Chinese search terms used were “visceral transposition” and “intestinal cancer”, and the English search terms used were “colorectal cancer” and “situs inversus”. Finally, 2 Chinese articles and 11 English articles were identified (Table 1)<sup>[1-13]</sup>.

Visceral transposition can be divided into complete visceral transposition and partial visceral transposition. Patients with complete visceral transposition are known as “mirror people” and are extremely rare<sup>[14]</sup>. Some patients with visceral transposition often present with other complex malformations. The incidence of visceral transposition varies in different regions. In Japan, the incidence of visceral transposition is 0.125‰ to 0.250‰. Yang *et al*<sup>[15]</sup> reported that the incidence rate was 0.005‰ to 0.010‰ in China. Several reports of the combination of a malignant tumor and SIT, such as cancer of the liver, stomach, lung, and colon, have been described. Only 2 cases of laparoscopy-assisted resection of CRC have been reported in China<sup>[2,3]</sup>.

**Table 1 Summary of cases with complete transposition of viscera combined with intestinal cancer**

Ref.	Publication time	Number of examples	Sex/Age (yr)	Tumor location	Pathological examination	Therapy	Prognosis
Fang <i>et al</i> <sup>[2]</sup>	2014	1	Female/39	Rectum	Moderately differentiated adenocarcinoma	Laparoscopic surgery	Good
Xu <i>et al</i> <sup>[3]</sup>	2018	1	Female/67	Colon ascendens	Medium-poor differentiated adenocarcinoma	Laparoscopic surgery	Good
Takeda <i>et al</i> <sup>[4]</sup>	2018	1	Female/72	Colon sigmoideum	Moderately differentiated adenocarcinoma	Laparoscopic surgery	Good
Sasaki <i>et al</i> <sup>[5]</sup>	2017	1	Female/75	Colon ascendens	Moderately differentiated adenocarcinoma	Laparoscopic surgery	Good
Yaegashi <i>et al</i> <sup>[6]</sup>	2015	1	Female/71	Colon sigmoideum	Well differentiated adenocarcinoma	Laparoscopic surgery	Good
Ito <i>et al</i> <sup>[7]</sup>	2015	2	Female/53; Male/60	Rectum Ascending colon cancer	Moderately differentiated adenocarcinoma	Laparoscopic surgery	Good
Hirano <i>et al</i> <sup>[8]</sup>	2015	1	Male/87	Carcinoma of the cecum	Moderately differentiated adenocarcinoma	Laparoscopic surgery	Good
Sumi <i>et al</i> <sup>[9]</sup>	2013	1	Male/83	Carcinoma of the descending colon	Moderately differentiated adenocarcinoma	Laparoscopic surgery	Good
Kim <i>et al</i> <sup>[10]</sup>	2011	1	Male/63; Female/71	Colon cancer of the hepatic flexure	Moderately differentiated adenocarcinoma	Laparoscopic surgery	Good
Han <i>et al</i> <sup>[11]</sup>	2011	1	Male/63	Ascending colon cancer	Moderately differentiated adenocarcinoma	Laparoscopic surgery	Good
Fujiwara <i>et al</i> <sup>[12]</sup>	2007	1	Female/53	Ascending colon cancer	Moderately differentiated adenocarcinoma	Laparoscopic surgery	Good
Goi <i>et al</i> <sup>[13]</sup>	2003	1	Female/72	Ascending colon cancer	Moderately differentiated adenocarcinoma	Laparoscopic surgery	Good
Viscott <i>et al</i> <sup>[14]</sup>	2011	1	Female/71	Rectal carcinoma gastric cancer	Moderately differentiated adenocarcinoma	Laparoscopic surgery	Good

The patient described here had sigmoid colon cancer and underwent laparoscopic radical surgery and postoperative intraperitoneal hyperthermic perfusion chemotherapy. The procedure was uneventful, and no tumor recurrence was found after 18 mo of follow-up.

To date, the mechanism of visceral translocation is still unclear, and some scholars believe that it is related to fetal ectopic and chromosomal abnormalities during embryonic development<sup>[16]</sup>. Whether internal visceral translocation is related to tumor onset is still inconclusive. Studies have shown that there may be a correlation between internal visceral translocation and tumor onset; however, further research is needed<sup>[17]</sup>. Due to the different pathological types and tumor sites, the clinical manifestations of patients vary, especially in patients with visceral transposition, which is prone to misdiagnosis. Therefore, comprehensive examinations should be completed, such as gastrointestinal endoscopy, computed tomography, and revascularization.

As internal visceral transposition is often accompanied by congenital anatomic abnormalities, surgery can be challenging. The main difficulty is distinguishing the blood vessels. In this case, the main branch vessels supplying the intestine were clearly distinguished by revascularization before surgery, which provided a guarantee for a smooth surgical procedure. In addition, it is necessary to consider the handedness of the surgeon to determine the position of the device, operator, and trocars. Oms and other researchers have found that laparoscopic techniques in visceral transposition patients are more difficult for right-handed surgeons, and are more advantageous for left-handed surgeons<sup>[18]</sup>. The same effect can be achieved by changing the position of the operator during surgery<sup>[6]</sup>.

For the diagnosis and treatment of patients with visceral transposition combined with gastrointestinal cancer, the possibility of visceral inversion should always be considered. The presence of cardiopulmonary disease should be eliminated to ensure a smooth surgical procedure. Relevant imaging examinations should be improved, and if necessary, revascularization should be performed to determine whether there are obvious vascular variations. An understanding of the anatomical location and variation involved in the operation is essential, and research on the surgical approach



and possible problems during surgery should be conducted. Compared with traditional laparotomy, laparoscopic techniques have minimally invasive benefits for patients while also presenting challenges. With the continuous development of technology, there will be a further understanding of the diagnosis and treatment of patients with visceral transposition, especially those with tumor diseases. In addition, because patients with stage T4 are prone to postoperative peritoneal metastasis, hyperthermic intraperitoneal chemotherapy and adjuvant chemotherapy were used to prevent tumor peritoneum relapse<sup>[19]</sup>.

## CONCLUSION

CRC and SIT can be diagnosed according to colonoscopy and imaging examination. Radical resection is the most effective method for treating CRC. A clear diagnosis before surgery can reduce the risk of surgery.

## REFERENCES

- 1 **Iwamura T**, Shibata N, Haraguchi Y, Hisashi Y, Nishikawa T, Yamada H, Hayashi T, Toyoda K. Synchronous double cancer of the stomach and rectum with situs inversus totalis and polysplenia syndrome. *J Clin Gastroenterol* 2001; **33**: 148-153 [PMID: 11468444 DOI: 10.1097/00004836-200108000-00012]
- 2 **Fang JF**, Wei B, Zheng ZH, Lei PR, Wei HB. Laparoscopic surgery for low visceral transposition of rectal cancer. *Zhonghua Weichang Waikexue Zazhi* 2014; **22**: 830-831 [DOI: 10.3760/cma.j.issn.1671-0274.2014.08.024]
- 3 **Xu ZF**, Li JJ, Zhang BG. Diagnosis and treatment of complete visceral transposition combined with intestinal tumors and literature review. *Zhonghua Zhenduanxue Dianzi Zazhi* 2018; **23**: 61-64 [DOI: 10.3877/cma.j.issn.2095-655X.2018.01.013]
- 4 **Takeda T**, Haraguchi N, Yamaguchi A, Uemura M, Miyake M, Miyazaki M, Ikeda M, Sekimoto M. Laparoscopic sigmoidectomy in a case of sigmoid colon cancer with situs inversus totalis. *Asian J Endosc Surg* 2019; **12**: 111-113 [PMID: 29601667 DOI: 10.1111/ases.12483]
- 5 **Sasaki K**, Nozawa H, Kawai K, Hata K, Kiyomatsu T, Tanaka T, Nishikawa T, Otani K, Kaneko M, Emoto S, Murono K, Watanabe T. Laparoscopic hemicolectomy for a patient with situs inversus totalis: A case report. *Int J Surg Case Rep* 2017; **41**: 93-96 [PMID: 29055878 DOI: 10.1016/j.ijscr.2017.10.011]
- 6 **Yaegashi M**, Kimura T, Sakamoto T, Sato T, Kawasaki Y, Otsuka K, Wakabayashi G. Laparoscopic sigmoidectomy for a patient with situs inversus totalis: effect of changing operator position. *Int Surg* 2015; **100**: 638-642 [PMID: 25875545 DOI: 10.9738/INTSURG-D-14-00217.1]
- 7 **Ito T**, Saito M, Kobayashi Y, Chika N, Amano K, Matsuzawa T, Ishiguro T, Fukuchi M, Kumagai Y, Ishibashi K, Kumamoto K, Oki S, Mochiki E, Takenoshita S, Ishida H. [Two Cases of Digestive Organ Cancer in Patients with Situs Inversus Treated with Laparoscopic Surgery]. *Gan To Kagaku Ryoho* 2015; **42**: 2130-2132 [PMID: 26805287]
- 8 **Hirano Y**, Hattori M, Douden K, Hashizume Y. Single-incision laparoscopic surgery for colon cancer in patient with situs inversus totalis: report of a case. *Indian J Surg* 2015; **77**: 26-28 [PMID: 25972634 DOI: 10.1007/s12262-014-1075-9]
- 9 **Sumi Y**, Tomono A, Suzuki S, Kuroda D, Kakeji Y. Laparoscopic hemicolectomy in a patient with situs inversus totalis after open distal gastrectomy. *World J Gastrointest Surg* 2013; **5**: 22-26 [PMID: 23515492 DOI: 10.4240/wjgs.v5.i2.22]
- 10 **Kim HJ**, Choi GS, Park JS, Lim KH, Jang YS, Park SY, Jun SH. Laparoscopic right hemicolectomy with D3 lymph node dissection for a patient with situs inversus totalis: report of a case. *Surg Today* 2011; **41**: 1538-1542 [PMID: 21969158 DOI: 10.1007/s00595-010-4530-7]
- 11 **Han HJ**, Choi SB, Kim CY, Kim WB, Song TJ, Choi SY. Single-incision multiport laparoscopic cholecystectomy for a patient with situs inversus totalis: report of a case. *Surg Today* 2011; **41**: 877-880 [PMID: 21626341 DOI: 10.1007/s00595-010-4387-9]
- 12 **Fujiwara Y**, Fukunaga Y, Higashino M, Tanimura S, Takemura M, Tanaka Y, Osugi H. Laparoscopic hemicolectomy in a patient with situs inversus totalis. *World J Gastroenterol* 2007; **13**: 5035-5037 [PMID: 17854150 DOI: 10.3748/wjg.v13.i37.5035]
- 13 **Goi T**, Kawasaki M, Yamazaki T, Koneri K, Katayama K, Hirose K, Yamaguchi A. Ascending colon cancer with hepatic metastasis and cholecystolithiasis in a patient with situs inversus totalis without any expression of UVRAG mRNA: report of a case. *Surg Today* 2003; **33**: 702-706 [PMID: 12928850 DOI: 10.1007/s00595-002-2567-y]
- 14 **Viscott DS**. Situs inversus totalis. *Dtsch Med Wochenschr* 2011; **136**: 840-843 [DOI: 10.7202/MILMED-D-11-00039]
- 15 **Yang N**, Lu JH, Zhang HB. One case of liver transplantation for visceral total transposition liver cancer and its complications. *Dier Junyi Daxue Xuebao* 2008; **29**: 606-608 [DOI: 10.3321/j.issn:0258-879X.2008.06.008]
- 16 **Elbeshry TM**, Ghnam WM. Retrograde (fundus first) Laparoscopic Cholecystectomy in Situs Inversus Totalis. *Sultan Qaboos Univ Med J* 2012; **12**: 113-115 [PMID: 22375268 DOI: 10.12816/0003097]
- 17 **Haruki T**, Maeta Y, Nakamura S, Sawata T, Shimizu T, Kishi K, Miyasaka S, Maeta H, Morimoto K, Taniguchi I. Advanced cancer with situs inversus totalis associated with KIF3 complex deficiency: report of two cases. *Surg Today* 2010; **40**: 162-166 [PMID: 20107958 DOI: 10.1007/s00595-009-4005-x]
- 18 **Oms LM**, Badia JM. Laparoscopic cholecystectomy in situs inversus totalis: The importance of being left-

- handed. *Surg Endosc* 2003; **17**: 1859-1861 [PMID: [14959744](#) DOI: [10.1007/s00464-003-9051-7](#)]
- 19 **Klaver CEL**, Stam R, Sloothaak DAM, Crezee J, Bemelman WA, Punt CJA, Tanis PJ. Colorectal cancer at high risk of peritoneal metastases: long term outcomes of a pilot study on adjuvant laparoscopic HIPEC and future perspectives. *Oncotarget* 2017; **8**: 51200-51209 [PMID: [28881641](#) DOI: [10.18632/oncotarget.17158](#)]



Published by **Baishideng Publishing Group Inc**  
7041 Koll Center Parkway, Suite 160, Pleasanton, CA 94566, USA

**Telephone:** +1-925-3991568

**E-mail:** [bpgoffice@wjgnet.com](mailto:bpgoffice@wjgnet.com)

**Help Desk:** <https://www.f6publishing.com/helpdesk>

<https://www.wjgnet.com>

