


# World Journal of *Gastrointestinal Endoscopy*

*World J Gastrointest Endosc* 2021 February 16; 13(2): 33-71



**OPINION REVIEW**

- 33 Dilation assisted stone extraction for complex biliary lithiasis: Technical aspects and practical principles  
*Grande G, Cocca S, Bertani H, Caruso A, Pigo' F, Mangiafico S, Russo S, Lupo M, Masciangelo G, Cantu' P, Manta R, Conigliaro R*

**ORIGINAL ARTICLE****Retrospective Study**

- 45 Complication rates in emergent endoscopy for foreign bodies under different sedation modalities: A large single-center retrospective review  
*Cha MH, Sandooja R, Khalid S, Lao N, Lim J, Razik R*

**Observational Study**

- 56 Molecular analysis of pancreatic cystic neoplasm in routine clinical practice  
*Herranz Pérez R, de la Morena López F, Majano Rodríguez PL, Molina Jiménez F, Vega Piris L, Santander Vaquero C*

**ABOUT COVER**

Jin-Ping Lai, MD, PhD, Associate Professor, Department of Pathology, University of Florida College of Medicine, Gainesville, FL 32610, United States. [jinping.x.lai@kp.org](mailto:jinping.x.lai@kp.org)

**AIMS AND SCOPE**

The primary aim of *World Journal of Gastrointestinal Endoscopy* (WJGE, *World J Gastrointest Endosc*) is to provide scholars and readers from various fields of gastrointestinal endoscopy with a platform to publish high-quality basic and clinical research articles and communicate their research findings online.

WJGE mainly publishes articles reporting research results and findings obtained in the field of gastrointestinal endoscopy and covering a wide range of topics including capsule endoscopy, colonoscopy, double-balloon enteroscopy, duodenoscopy, endoscopic retrograde cholangiopancreatography, endosonography, esophagoscopy, gastrointestinal endoscopy, gastroscopy, laparoscopy, natural orifice endoscopic surgery, proctoscopy, and sigmoidoscopy.

**INDEXING/ABSTRACTING**

The WJGE is now abstracted and indexed in Emerging Sources Citation Index (Web of Science), PubMed, PubMed Central, China National Knowledge Infrastructure (CNKI), and Superstar Journals Database.

**RESPONSIBLE EDITORS FOR THIS ISSUE**

Production Editor: *Li-Li Wang*, Production Department Director: *Yun-Xiaojuan Wu*, Editorial Office Director: *Jia-Ping Yan*.

**NAME OF JOURNAL**

*World Journal of Gastrointestinal Endoscopy*

**ISSN**

ISSN 1948-5190 (online)

**LAUNCH DATE**

October 15, 2009

**FREQUENCY**

Monthly

**EDITORS-IN-CHIEF**

Anastasios Koulaouzidis, Bing Hu, Sang Chul Lee

**EDITORIAL BOARD MEMBERS**

<https://www.wjgnet.com/1948-5190/editorialboard.htm>

**PUBLICATION DATE**

February 16, 2021

**COPYRIGHT**

© 2021 Baishideng Publishing Group Inc

**INSTRUCTIONS TO AUTHORS**

<https://www.wjgnet.com/bpg/gerinfo/204>

**GUIDELINES FOR ETHICS DOCUMENTS**

<https://www.wjgnet.com/bpg/gerinfo/287>

**GUIDELINES FOR NON-NATIVE SPEAKERS OF ENGLISH**

<https://www.wjgnet.com/bpg/gerinfo/240>

**PUBLICATION ETHICS**

<https://www.wjgnet.com/bpg/gerinfo/288>

**PUBLICATION MISCONDUCT**

<https://www.wjgnet.com/bpg/gerinfo/208>

**ARTICLE PROCESSING CHARGE**

<https://www.wjgnet.com/bpg/gerinfo/242>

**STEPS FOR SUBMITTING MANUSCRIPTS**

<https://www.wjgnet.com/bpg/gerinfo/239>

**ONLINE SUBMISSION**

<https://www.f6publishing.com>



## Dilation assisted stone extraction for complex biliary lithiasis: Technical aspects and practical principles

Giuseppe Grande, Silvia Cocca, Helga Bertani, Angelo Caruso, Flavia Pigo', Santi Mangiafico, Salvatore Russo, Marinella Lupo, Graziella Masciangelo, Paolo Cantu', Raffaele Manta, Rita Conigliaro

**ORCID number:** Giuseppe Grande 0000-0003-3907-9740; Silvia Cocca 0000-0002-0642-8054; Helga Bertani 0000-0003-0818-7167; Angelo Caruso 0000-0001-5285-1315; Flavia Pigo' 0000-0002-0917-0802; Santi Mangiafico 0000-0003-4760-4162; Salvatore Russo 0000-0001-8537-1852; Marinella Lupo 0000-0002-9209-1389; Graziella Masciangelo 0000-0001-9355-9150; Paolo Cantu' 0000-0003-2381-3162; Raffaele Manta 0000-0002-2168-8372; Rita Conigliaro 0000-0003-3463-7862.

**Author contributions:** Grande G and Conigliaro R conceived and designed the study; Grande G, Caruso A, Bertani H, Manta R, and Mangiafico S equally contributed to each topic of the project; Pigo F, Marocchi M, Cantù P, Russo S, Lupo M, and Masciangelo G contributed to the analytic tools and bibliography research; Grande G and Cocca S analyzed the data and wrote the manuscript; Caruso A and Mangiafico S revised the figures; All authors have read and approved the final manuscript.

**Conflict-of-interest statement:** All authors declare no conflict of interests.

**Open-Access:** This article is an open-access article that was selected by an in-house editor and fully peer-reviewed by external

Giuseppe Grande, Silvia Cocca, Helga Bertani, Angelo Caruso, Flavia Pigo', Santi Mangiafico, Salvatore Russo, Marinella Lupo, Graziella Masciangelo, Rita Conigliaro, Gastroenterology and Digestive Endoscopy Unit, Azienda Ospedaliero Universitaria di Modena, Modena 41126, Italy

Paolo Cantu', Gastroenterology and Endoscopy Unit, Department of Pathophysiology and Transplantation, Fondazione IRCCS Ca' Granda, Ospedale Maggiore Policlinico and Università degli Studi di Milano, Milano 20122, Italy

Raffaele Manta, Gastroenterology and Digestive Endoscopy Unit, General Hospital of Perugia, Perugia 06129, Italy

**Corresponding author:** Giuseppe Grande, MD, Staff Physician, Gastroenterology and Digestive Endoscopy Unit, Azienda Ospedaliero Universitaria di Modena, Via Pietro Giardini 1355, Modena 41126, Italy. [grande.giuseppe@aou.mo.it](mailto:grande.giuseppe@aou.mo.it)

### Abstract

Common bile duct stones are frequently diagnosed worldwide and are one of the main indications for endoscopic retrograde cholangio-pancreatography. Endoscopic sphincterotomy (EST) has been used for the removal of bile duct stones for the past 40 years, providing a wide opening to allow extraction. Up to 15% of patients present with complicated choledocholithiasis. In this context, additional therapeutic approaches have been proposed such as endoscopic mechanical lithotripsy, intraductal or extracorporeal lithotripsy, or endoscopic papillary large balloon dilation (EPLBD). EPLBD combined with EST was introduced in 2003 to facilitate the passage of large or multiple bile duct stones using a balloon greater than 12 mm in diameter. EPLBD without EST was introduced as a simplified technique in 2009. Dilation-assisted stone extraction (DASE) is the combination of two techniques: EPLBD and sub-maximal EST. Several studies have reported this technique as safe and effective in patients with large bile duct stones, without any increased risk of adverse events such as pancreatitis, bleeding, or perforation. Nevertheless, it is difficult to analyze the outcomes of DASE because there are no standard techniques and definitions between studies. The purpose of this paper is to provide technical guidance and specific information about the main issues regarding DASE, based on current literature and daily clinical experience in biliary referral centers.

**Key Words:** Dilation-assisted stone extraction; Endoscopic papillary large balloon dilation;



reviewers. It is distributed in accordance with the Creative Commons Attribution NonCommercial (CC BY-NC 4.0) license, which permits others to distribute, remix, adapt, build upon this work non-commercially, and license their derivative works on different terms, provided the original work is properly cited and the use is non-commercial. See: <http://creativecommons.org/licenses/by-nc/4.0/>

**Manuscript source:** Unsolicited manuscript

**Specialty type:** Gastroenterology and hepatology

**Country/Territory of origin:** Italy

**Peer-review report's scientific quality classification**

Grade A (Excellent): A, A

Grade B (Very good): 0

Grade C (Good): 0

Grade D (Fair): 0

Grade E (Poor): 0

**Received:** September 21, 2020

**Peer-review started:** September 21, 2020

**First decision:** December 11, 2020

**Revised:** December 27, 2020

**Accepted:** January 22, 2021

**Article in press:** January 22, 2021

**Published online:** February 16, 2021

**P-Reviewer:** Cheng KC, Hu B

**S-Editor:** Zhang L

**L-Editor:** Filipodia

**P-Editor:** Wang LL



Macrolithiasis; Difficult choledocholithiasis; Stone treatment; Common bile duct stones; Endoscopic retrograde cholangiopancreatography

©The Author(s) 2021. Published by Baishideng Publishing Group Inc. All rights reserved.

**Core Tip:** This narrative and practical review has been written to clarify some issues and key points regarding the treatment of difficult common bile duct stone using dilation assisted stone extraction technique.

**Citation:** Grande G, Cocca S, Bertani H, Caruso A, Pigo' F, Mangiafico S, Russo S, Lupo M, Masciangelo G, Cantu' P, Manta R, Conigliaro R. Dilation assisted stone extraction for complex biliary lithiasis: Technical aspects and practical principles. *World J Gastrointest Endosc* 2021; 13(2): 33-44

**URL:** <https://www.wjgnet.com/1948-5190/full/v13/i2/33.htm>

**DOI:** <https://dx.doi.org/10.4253/wjge.v13.i2.33>

## INTRODUCTION

Bile duct stones most frequently result from the migration of gallstones from the gallbladder into the biliary tree. Common bile duct (CBD) stones are the main indication for endoscopic retrograde cholangiopancreatography (ERCP), which has transformed bile duct stone removal from a major operation to a minimally invasive procedure. The success rate is from 85% to 95%<sup>[1,2]</sup>. A critical step to obtaining successful stone extraction is to provide an adequate opening for the stones that are to be removed by endoscopic sphincterotomy alone, endoscopic papillary balloon dilation (EPBD) alone, or a combination of both<sup>[1]</sup>. In more than 90% of cases, conventional treatment is based on endoscopic sphincterotomy (EST) with stone extraction using a Fogarty balloon catheter or Dormia-type basket. Difficulties in stone extraction may be due to the stone(s) being too large to pass through the intrapancreatic portion of the bile duct or the biliary sphincterotomy site<sup>[3]</sup>. This could occur in a small number of cases, approximately 5%-10%, in which the conventional treatment is not enough to obtain the complete removal of the stone, known as "complex" lithiasis<sup>[1,4]</sup>. The most complete definition of "complex" lithiasis includes the presence of multiple (10 or more) or large stones (with a diameter  $\geq 15$  mm, called macrolithiasis), anatomical conditions such as strictures, sigmoid-shaped CBD, disproportion between the size of distal bile duct and the stone (difference greater than 2 mm), post-surgical altered anatomy, duodenal stenosis, peri ampullary diverticula (PAD), and difficult access to the major papilla<sup>[1,5]</sup>. In the past, the established approach to fragment "complex lithiasis" was mechanical lithotripsy (ML), a technique introduced and described for the first time in 1985 by Riemann *et al*<sup>[6]</sup>; it requires the use of a large basket to trap the stone, a crank handle is then used to apply tension to the wires and to crush the stone against a metal sheath<sup>[6,7]</sup>. Other commonly used techniques are: Extracorporeal shock wave lithotripsy, cholangioscopy-assisted electrohydraulic or laser lithotripsy, plastic or self-expanding metal stent (SEMS) placement, and endoscopic papillary large balloon dilation (EPLBD) also known as dilation assisted stone extraction (DASE)<sup>[2,3,8,9]</sup>.

Almost all endoscopists who deal with the biliary tract have a clear understanding of the difficulties and frustration resulting from the failure to extract large stones through the papilla, despite maximal EST extended until duodenal fold. The concept behind DASE technique lies in the enlargement of the papillary section to an extent that allows large stones to pass through and out in the duodenum, even without their fragmentation. The first systematic experience of EPLBD was observed in 2003 by Ersoz *et al*<sup>[10]</sup>, who applied this technique in 58 patients in whom endoscopic sphincterotomy and standard basket/balloon extraction were unsuccessful in the removal of CBD stones. EST followed by dilatation of the ampulla and distal bile duct with a large-diameter esophageal/pyloric type pneumatic balloon (10-20 mm) was effective in the clearance of large bile duct stones (15-28 mm) in 95% of patients. The purpose was to allow easy removal of the stones by making the distal bile duct more adaptable and shaped.

Complications occurred in nine patients (15.5%), including cholangitis and mild pancreatitis in 3% of patients and bleeding in 9%<sup>[10]</sup>. Since then, this technique has spread rapidly all over the world, experiencing more or less use, due in part to technical variations, and due to the production of dedicated devices. Global interest in EPLBD procedure was demonstrated by publication of numerous articles, reviews, meta-analyses, randomized controlled trials (RCTs), and guidelines from the main endoscopy associations.

The aim of this paper is to provide technical features and practical advice both from updated literature and daily experience of our biliary referral center, in which more than 25 DASE procedures are performed each year.

## INDICATIONS OF DILATION ASSISTED STONE EXTRACTION

ASGE and ESGE recommend limited sphincterotomy combined with endoscopic papillary large-balloon dilation as the first-line approach to remove difficult CBD stones<sup>[1,2]</sup>. The complete stone clearance rate in all sessions of the DASE procedure ranges from 70% to 97.5%, with an overall complication rate of 12%, based on published clinical series and trials<sup>[2,3,5,11]</sup>. When reviewing the published literature, we need to consider the heterogeneity of the reported data, particularly the dimension of the biliary stones that are being removed and the extension of the biliary sphincterotomy. Many studies, for example, include stones from 10 mm upwards, while others consider only biliary stones wider than 13-15 mm. In the latter group, the efficacy of DASE in the clearance of the biliary tract is higher than EST alone, as shown by an RCT published on 2017. In this study, CBD stone clearance was achieved in 74% of patients in the EST group and in 96.1% of patients in the endoscopic sphincterotomy plus large-balloon dilation group. As reported, EST was complete in both groups and not partial, as usually occurs in the classic DASE technique described<sup>[12]</sup>. Another meta-analysis of 18 studies with 2789 patients showed that the efficacy and safety of DASE was superior to those of EST for the removal of large CBD stones, both across all ERCP sessions (odds ratio [OR]: 2.68) and during the first ERCP session (88% *vs* 79% in the EST group). Moreover, less mechanical lithotripsy and shorter procedure times are needed after DASE to manage large stones, with a significantly lower incidence of adverse events (OR: 0.63)<sup>[13]</sup>. Based on these findings, ESGE and ASGE guidelines published in 2019 recommend sphincterotomy combined with EPLBD as first-line therapy to remove difficult CBD stones<sup>[1,2]</sup>. Another possible use for DASE is the treatment of lithiasis recurrence, previously approached with EST, a scenario in which a further enlargement of the sphincterotomy could be associated with an increased risk of bleeding and perforation<sup>[14]</sup>.

## PROCEDURAL TECHNIQUE

As in standard procedures, before starting with the dilation, a guide wire is placed in the bile duct through the papilla major, under fluoroscopic monitoring, and after cholangiography; then a sphincterotomy is performed over the guide wire. When a physician is considering dilation assisted stone extraction, the extent of the sphincterotomy should not be too limited as the safety of the technique likely depends on at least partially severing the sphincter muscle. At this point, to get a better view of the radiological anatomy of the biliary tree, it is strongly advised to perform a high-pressure cholangiography using a Fogarty catheter, to exclude suspicion of distal bile duct tight stricture before starting with dilation. The best-selling biliary catheters for pneumatic dilation are wire-guided, with a balloon length from 3 to 5.5 cm and variable diameters (10 to 20 mm). They are compatible with 3.2 mm working channel endoscopes and 3.8 mm working channel duodenoscope and have embedded platinum/indium radio-opaque markers to facilitate balloon placement using fluoroscopy. From the DASE technique literature, nuances of the technique, including positioning of the balloon, and duration and size of balloon dilation are still not certain. Some authors recommend positioning the balloon across the papilla leaving more than one-half of its length on the duodenal side, although this advice results primarily from subjective experience. Other authors propose pushing the biliary stones upward before proceeding with the inflation phase, to minimize the risk of traumatic damage caused by their “crushing” between the balloon and the choledocic wall, while others recommend positioning more than one-half of the balloon inside the bile duct to exploit the pneumatic compressive action to break, at least partially, the

biliary stones<sup>[4,15,16]</sup>. These are a few examples of how there is not uniform agreement on the DASE technique in the literature. From our experience, we found that fragmenting the stones or moving them proximally is not fundamental, since the placement of the dilating balloon, even deflated, is enough to do it. Once the balloon is positioned so its midpoint is on the papillary sphincter, it should be inflated with a dilute contrast medium, which allows fluoroscopic monitoring. Gradual and slow inflation under endoscopic and fluoroscopic monitoring is recommended ("step-by-step" technique) to prevent the "watermelon seed" effect. It may be necessary to put either traction or inward pressure on the balloon catheter to maintain its position during inflation. Once the target pressure has been reached, inflation should be maintained for 30-60 s until the balloon waist disappears or better until the stenosis gradually reaches the diameter suitable for the removal of the stones. If there is residual waist formation or extensive longitudinal narrowing of the balloon, even when the maximum pressure target has been reached, it is not recommended to inflate more; at least until checking the papilla to exclude complications. Then, if the initial balloon diameter is felt to be too small, a second inflation using a larger diameter balloon can be performed. It has been reported in the literature that the balloon waist persistence could be caused by scar tissue on the papilla, causing higher incidence of perforation. The gradual application of balloon pressure in patients with long-standing large bile duct stones is suggested to prevent sudden tearing of the ampullary roof reducing the incidence of traumatic wall damage<sup>[4,15,17,18]</sup>. After the dilation phase, a standard retrieval balloon or basket may be used to pull down the stones. At the end, high-pressure cholangiography should be performed to check CBD clearance and exclude complications (Figure 1). Of note, pneumatic dilation is considered a painful procedure and should be performed under deep sedation or general anesthesia.

## SPHINCTEROTOMY YES OR NO?

At the beginning, DASE procedure was performed after a complete EST, to reduce the incidence of acute post ERCP pancreatitis (PEP), a complication reported as being more frequent in patients undergoing EPBD instead of EST alone<sup>[19-21]</sup>. However, data from more recent studies do not seem to confirm this evidence<sup>[17,22,23]</sup>.

In 2009, Jeong *et al*<sup>[24]</sup> showed that large-balloon sphincteroplasty (LBS) without EST is safe in patients with large bile duct stones, although with a lower efficacy; the complete duct clearance by LBS alone without mechanical lithotripsy was achieved in 76.3% of patients, while complete stone retrieval was achieved by LBS alone in the first session in 65.8% of patients<sup>[24]</sup>. The latest trial published by Kogure *et al*<sup>[25]</sup>, involving 171 patients (all over 60-years-old) across 19 Japanese centers, asserts that EPLBD without EST is significantly more effective than EST alone for the removal of large ( $\geq 10$  mm) CBD stones in a single session. No difference in adverse events (AEs) were recorded<sup>[25]</sup>.

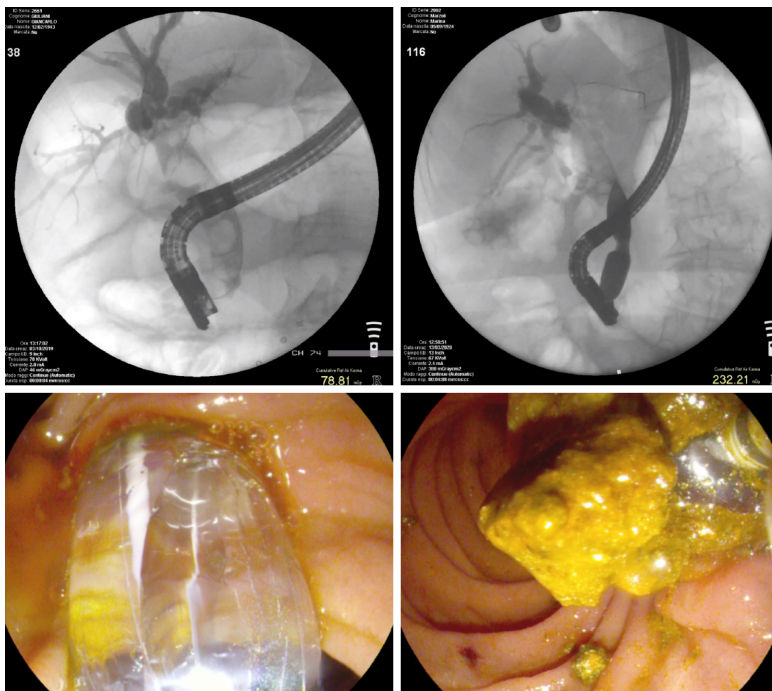
An "intermediate" approach proposed by Kim and colleagues was that pneumatic dilation has to be preceded by a minor (less than half) EST made from the orifice of the papilla proximally but not extended beyond the horizontal fold or the transverse fold of the papilla. The rationale for this approach is that the subsequent pneumatic dilation could spread the tension stress on the biliary side more than on the pancreatic one, reducing risk of PEP as well as bleeding and perforation, whereas the overall success rate was not affected<sup>[26]</sup> (Table 1).

Subsequent studies and meta-analyses have shown contradictory results in terms of efficacy and safety of DASE preceded or not by EST<sup>[4,25,27-29]</sup>. Of note, few studies have investigated Oddi's sphincter (SO) function after EPLBD procedure: Cheon *et al*<sup>[30]</sup> performed endoscopic manometric studies on 86 patients before and after the EBPLD, and found that dilation procedure resulted in significative and prolonged loss of SO function after 1 wk and 1 year, irrespective of the association with or without EST<sup>[30]</sup>. To date, the European, American and Japanese guidelines recommend, among patients with large or difficult-to-remove bile duct stones, to choose limited EST followed by large balloon dilation over EST alone. The approach of EPLBD without EST should be limited to patients with coagulopathies and in those who have previously undergone sphincterotomy<sup>[1,2,31]</sup>.

**Table 1** Main characteristics across different studies of patients underwent to endoscopic large balloon papillary dilation

Ref.	Study design	EPLBD/EST patients, n°	Stone dimension, cut off, mm	EST prior EPLBD	Dilation time after waist disappearance, s	CBD clearance at first session, EPLBD/EST, %	EML, EPLBD/EST, %	AEs, EPLBD/EST, %
Li <i>et al</i> <sup>[51]</sup> , 2018	Retrospective, single center	161-60	≥ 10	Complete	60	98.8/98.3	18/28.3	6.8/6.7
Karsenti <i>et al</i> <sup>[12]</sup> , 2017	Prospective, randomized, multicentric	77-73	≥ 13	Complete	Na	96.1/74	3.9-35.6	8.1-9.3
Kuo <i>et al</i> <sup>[29]</sup> , 2019	Retrospective, single center	58-31	≥ 15	Partial	120	98.3/83.9	3.4-10.4	3.4-12.9
Teoh <i>et al</i> <sup>[33]</sup> , 2013	Prospective, randomized, multicentric	73-78	≥ 13	Partial	30	89-88.8	28.8-46.2	6.8-10.3
Jun Bo <i>et al</i> <sup>[34]</sup> , 2013	Prospective, randomized, single center	63-69	≥ 15	Partial	30	80.9-60.8	7.9-24.6	11.6-7.9
Kogure <i>et al</i> <sup>[25]</sup> , 2020	Prospective, randomized, multicentric	86-85	≥ 12	None	< 10	90.7-78.8	30.2-48.2	9.3-9.4
Our experience (2016-2020)	Retrospective, unpublished	72-83	≥ 15	Complete	30	88-79.1	6.4-5.5	10.3-10

AEs: Adverse events; CBD: Common bile duct; EML: Endoscopic mechanical lithotripsy; EPLBD: Endoscopic papillary large balloon dilation; EST: Endoscopic sphincterotomy.

**Figure 1** Radiologic and endoscopic view of macrolithiasis treated with dilation assisted stone extraction.

## BALLOON DIAMETER AND DILATION TIME

Biliary catheters for pneumatic dilation are wire-guided, with a balloon length from 3 to 5.5 cm and diameters from 10 to 20 mm. The choice of the balloon type and the diameters to be reached must be carefully evaluated by radiological images review pre-ERCP and cholangiography during the procedure. The final diameter of the balloon shouldn't exceed the diameter of the distal bile duct (even in case of larger stone), then it should be gradually and slowly pressurized using contrast medium



injection according to the corresponding atmosphere reported by the manufacturer's instructions, until waist disappearance. Final balloon dilation should be maintained no more than 30-60 s or better until the stenosis gradually gives way. Indeed, in a recent multicentric trial involving 1920 patients, Meng *et al*<sup>[32]</sup> showed that the rate of PEP was significantly higher in the case of dilation time longer than 180 s<sup>[32]</sup>.

Distal CBD stricture or small extrahepatic duct size should be considered contraindications to DASE. Therefore, it is necessary to exclude, beyond any reasonable doubt, the presence of unknown or misdiagnosed pre-papillary tight and uncompressible stricture. For this purpose, it could be useful to acquire cholangiography images from various perspectives moving the radiological arch or the operating bed and checking carefully also the portion of the CBD that usually hides behind the duodenoscope. In a large study, Park *et al*<sup>[15]</sup> analyzed AEs following DASE according to severity and reported that perforation occurred when no obvious distal CBD stricture was identified and when there was discrepancy between distal CBD and balloon diameter. Moreover, the rate of severe-to-fatal AEs was higher when balloons larger than 15 mm were used to dilate the CBD<sup>[18]</sup>.

## CLINICAL AND ECONOMICAL ADVANTAGES OF DASE

Some RCTs have investigated the economic advantages of the DASE technique compared to EST alone. The study of Teoh *et al*<sup>[33]</sup> showed that the cost of hospitalization was significantly lower in the DASE group (\$5025 *vs* \$6005)<sup>[33]</sup>. Another study confirmed this data, showing the duration of admission was significantly shorter in the DASE group (10.5 ± 6.6 d) than in the EST group (14.9 ± 7.8 d)<sup>[34]</sup>. Concerning the average cost of the devices used during endoscopic procedures, Karsenti *et al*<sup>[12]</sup> did not show substantial differences between the DASE group (€449) and the EST alone group (€447)<sup>[12]</sup>. Finally, an observational study by Itoi *et al*<sup>[35]</sup> showed in a group of 101 patients that total procedure time and fluoroscopy time in the DASE group were significantly shorter than those of the EST group (32 and 13 min *vs* 40 and 22 min)<sup>[35]</sup>.

The limitations of most of these data are heterogeneity in cost evaluation and variation in study populations, trial design, and operator techniques; therefore, their clinical impact must be considered with caution.

## COMPLICATIONS

### Bleeding

Literature review shows that DASE-related bleeding is statistically less frequent than occurs in patients treated with EST alone<sup>[13,17]</sup>. This was confirmed in a recent meta-analysis, which highlighted how post-ERCP bleeding is significantly more frequent in patients treated with complete EST compared to DASE (3.4% *vs* 1.9%, *P* = 0.02)<sup>[28]</sup>. Of note, the systematic review by Kim and colleagues published in 2013 showed that bleeding related to maximal EST and papillary large balloon dilatation was slightly higher in respect to patients treated with EST alone, whereas there were no differences between patients treated with papillary dilation combined with partial or no EST<sup>[27]</sup>; these data proved once again that bleeding is strictly related to sphincterotomy and its extension. Many studies have established that liver cirrhosis, uncontrolled coagulopathies, ongoing anti-platelet drugs, stones larger than 16 mm and maximal EST are risk factors for bleeding in patients undergoing to DASE<sup>[2,4,15]</sup>. In case of DASE-related bleeding, hemostasis can be achieved using standard techniques (adrenaline, clips, SEMS) or inflating again the balloon across the papilla up to 60-180 s, in order to obtain vessel compression and stop blood flow<sup>[36-40]</sup>.

### Perforation

Although it has been demonstrated that patients undergoing DASE are not at increased risk of perforation<sup>[15,41]</sup>, a strict and careful radiological evaluation is necessary before and during ERCP procedure. The most serious AE after EPLBD is perforation. Fortunately, this complication is rare, and most cases were described as Stapfer type II (papillary) and type III (bile duct) perforations<sup>[15,42,43]</sup>. Expert opinion and published studies underlie the presence of unrevealed distal CBD stricture as well as the use of balloons larger than 15 mm are associated with an increased risk of perforation<sup>[15,18,42]</sup>. Fluoroscopic evaluation of pre-papillary tract during ERCP could be



extremely tricky. Many factors can mask a short and hidden stricture like the overlapping of endoscope and distal CBD, the inability to obtain a high-pressure cholangiography with Fogarty catheter of the distal CBD tract, and the physiological narrowing of its intrapancreatic tract. To overcome these issues, it may be useful to move the radiological arch to obtain images in different projections, eventually pushing the instrument in long position or inflating the balloon toward the papillary orifice before contrast injection (Figure 2). The incidence of perforation has been reported in patients undergoing DASE ranging from 0.4 to 1.4% [15,40,43]. If the injury is promptly recognized, conservative management should be undertaken placing SEMS (with anti-migration shape) across the leak and naso-biliary drainage, minimizing the contact between bile fluid and the damaged wall.

### Acute pancreatitis

Historically, PEP is considered the most frequent complication in patients undergoing sphincteroplasty (also named endoscopic papillary balloon dilation -EPBD) even more than EST. The most likely explanation is that papillary oedema, due to pneumatic trans-papillary dilation and tissue stress, causes local compartment syndrome and subsequent outflow obstruction of pancreatic fluids. Nevertheless, a systematic review by Liao *et al* [22] showed that only short EPBD duration (< 60 s) was associated with a higher PEP incidence compared with EST (OR: 3.87, 95% confidence interval [CI]: 1.08–13.84), while long (> 60 s) EPBD was not (OR: 1.14, 95%CI: 0.56–2.35) [23]. Also, the latest ESGE guidelines recommend performing EPBD using an 8 mm balloon after limited EST, keeping it inflated for at least 2 min after waist disappearance. Moreover, the placement of pancreatic stent should be considered in case of papillary balloon dilation not preceded by limited EST [23,44]. While severe pancreatitis was an early concern with DASE, afterward the rates have proven to be low; the hypothesis is that the sphincterotomy with partial section of Oddi's muscle fibers on the biliary side, could direct the tension caused by the inflated pneumatic balloon toward the top, reducing tissue stress on pancreatic side [44–46]. Additional PEP prevention should include the use of NSAIDs (*i.e.* rectal Indomethacin) and adequate intravenous fluids administration, especially in those with virgin papilla [11,46]. Prophylactic pancreatic stent should also be placed in selected patients at high risk for PEP, and in case of difficult biliary cannulation or inadvertent guidewire insertion/ opacification of the pancreatic duct [23,44].

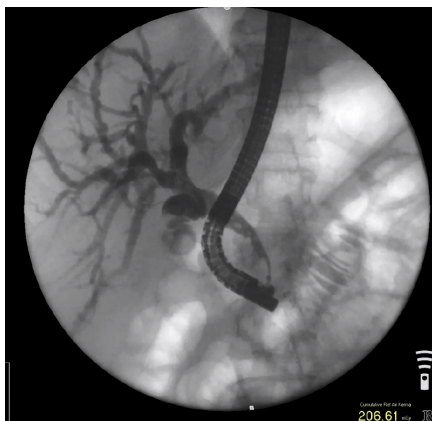
## PARTICULAR CASES

### Paravaterian diverticulum

The presence of PAD, especially when the papilla is located inside or on the edge of it (PAD types I and II), increases the difficulty to perform a wide EST required for stone passage through the papillary orifice. Some factors that limit the extension of biliary sphincterotomy in presence of a PAD are: The duodenal sprain, the dislocation of the papillary sphincter, and the thin diverticular wall. In these cases, DASE has proven to be a safe and effective technique, as reported in a large cohort of patients by Zulli *et al* [47] in which a complete clearance of the biliary tract was obtained in 96% of cases and with mild or moderate complication in 10% [47]. Due to diverticular compression of the distal bile duct, the balloon choice should be carefully done (not greater than diverticular neck in case of PAD type 1) and the balloon should be inflated progressively, under fluoroscopic and endoscopic view, until the first target is reached.

### Altered anatomy

Treatment of choledocolithiasis is challenging in patients with surgically altered anatomy of the bilio-digestive system. A step-by-step approach is necessary for successful endoscopic management of bile duct stones [48]. The most complex phases of ERCP procedure are the intubation to the afferent limb, biliary cannulation, ampullary intervention, and stone extraction. In the case of Billroth II reconstruction, the major papilla (usually located in the reverse position) could be reached using a duodenoscope as first option, then either therapeutic gastroscope, pediatric colonoscope or device-assisted enteroscope as second choices. For biliary sphincterotomy, different techniques could be adopted using rotatable sphinctertome, free hand kindle knife or stent assisted kindle knife, but all these increases the risk of adverse events even in experienced hands. Although data are still limited, some research and patient series report that DASE has proved to be easy, safe and effective,



**Figure 2** Complex lithiasis with common bile duct distal stricture not suitable for dilation assisted stone extraction treatment.

with complication rates comparable to those found in patients with preserved anatomy<sup>[11,49,50]</sup> (Figure 3). DASE treatment has also been used in patients with Roux-en-Y reconstruction; nevertheless, considerable technical expertise is often required especially to reach the papilla of Vater using enteroscopes or laparoscopic assistance<sup>[48]</sup>. Due to the small number of patients studied in this group, there is not enough evidence in the literature to consider DASE procedure the standard practice. This may change in the coming years due to the greater number of Roux-en-Y reconstructions performed after gastric surgery.

## CONCLUSION

Currently, DASE represents the first line technique in the treatment of macrolithiasis of the CBD. Its global effectiveness has been reported as comparable or superior to EST for retrieval of CBD stones. In addition, DASE resulted in a reduced need for mechanical lithotripsy, a lower incidence of morbidity rate, and adverse events. Furthermore, procedural duration and cost in endotherapy devices used for ERCP tends to be significantly lower. This treatment is also reproducible, and does not compromise any further therapeutic attempts. To maximize its effectiveness and to reduce complications, the essential aspects are a careful evaluation of the biliary tree, the choice of the balloon size, and the respect of inflation times.

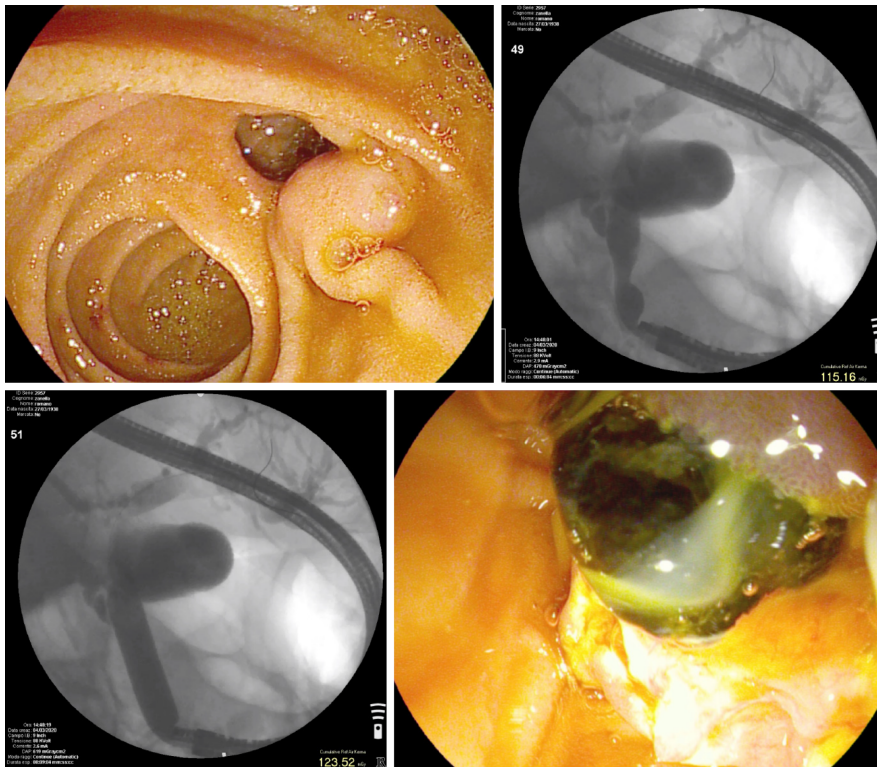


Figure 3 Dilation assisted stone extraction in patient with type II peri-ampullary diverticulum and Billroth-II reconstruction.

## ACKNOWLEDGEMENTS

Acknowledgments and special thanks to Melissa Breunig for the revision of the English text.

## REFERENCES

- 1 **Manes G**, Paspatis G, Aabakken L, Anderloni A, Arvanitakis M, Ah-Soune P, Barthet M, Domagk D, Dumonceau JM, Gigot JF, Hritz I, Karamanolis G, Laghi A, Mariani A, Paraskeva K, Pohl J, Ponchon T, Swahn F, Ter Steege RWF, Tringali A, Vezakis A, Williams EJ, van Hooft JE. Endoscopic management of common bile duct stones: European Society of Gastrointestinal Endoscopy (ESGE) guideline. *Endoscopy* 2019; **51**: 472-491 [PMID: [30943551](#) DOI: [10.1055/a-0862-0346](#)]
- 2 **ASGE Standards of Practice Committee**, Buxbaum JL, Abbas Fehmi SM, Sultan S, Fishman DS, Qumseya BJ, Cortessis VK, Schilperoort H, Kysh L, Matsuoka L, Yachimski P, Agrawal D, Gurudu SR, Jamil LH, Jue TL, Khashab MA, Law JK, Lee JK, Naveed M, Sawhney MS, Thosani N, Yang J, Wani SB. ASGE guideline on the role of endoscopy in the evaluation and management of choledocholithiasis. *Gastrointest Endosc* 2019; **89**: 1075-1105. e15 [PMID: [30979521](#) DOI: [10.1016/j.gie.2018.10.001](#)]
- 3 **Testoni PA**, Mariani A, Aabakken L, Arvanitakis M, Bories E, Costamagna G, Devière J, Dinis-Ribeiro M, Dumonceau JM, Giovannini M, Gyokeres T, Hafner M, Halttunen J, Hassan C, Lopes L, Papanikolaou IS, Tham TC, Tringali A, van Hooft J, Williams EJ. Papillary cannulation and sphincterotomy techniques at ERCP: European Society of Gastrointestinal Endoscopy (ESGE) Clinical Guideline. *Endoscopy* 2016; **48**: 657-683 [PMID: [27299638](#) DOI: [10.1055/s-0042-108641](#)]
- 4 **Haseeb A**, Freeman ML. Endoscopic Papillary Large Balloon Dilation Versus Endoscopic Sphincterotomy for Treatment of Bile Duct Stones. *Curr Treat Options Gastroenterol* 2019; **17**: 221-230 [PMID: [30945095](#) DOI: [10.1007/s11938-019-00234-5](#)]
- 5 **Franzini T**, Moura RN, Bonifácio P, Luz GO, de Souza TF, Dos Santos MEL, Rodela GL, Ide E, Herman P, Montagnini AL, D'Albuquerque LAC, Sakai P, de Moura EGH. Complex biliary stones management: cholangioscopy versus papillary large balloon dilation - a randomized controlled trial. *Endosc Int Open* 2018; **6**: E131-E138 [PMID: [29399609](#) DOI: [10.1055/s-0043-122493](#)]
- 6 **Riemann JF**, Seuberth K, Demling L. Mechanical lithotripsy of common bile duct stones. *Gastrointest Endosc* 1985; **31**: 207-210 [DOI: [10.1016/S0016-5107\(85\)72047-0](#)]
- 7 **Leung JW**, Tu R. Mechanical lithotripsy for large bile duct stones. *Gastrointest Endosc* 2004; **59**: 688-690 [PMID: [15114312](#) DOI: [10.1016/s0016-5107\(04\)00174-9](#)]
- 8 **Kedia P**, Tarnasky PR. Endoscopic Management of Complex Biliary Stone Disease. *Gastrointest*

- Endosc Clin N Am* 2019; **29**: 257-275 [PMID: [30846152](#) DOI: [10.1016/j.giec.2018.11.004](#)]
- 9 **Park CH**, Park SW, Nam E, Jung JH, Jo JH. Comparative efficacy of stents in endoscopic ultrasonography-guided peripancreatic fluid collection drainage: A systematic review and network meta-analysis. *J Gastroenterol Hepatol* 2020; **35**: 941-952 [PMID: [31881097](#) DOI: [10.1111/jgh.14960](#)]
  - 10 **Ersoz G**, Tekesin O, Ozutemiz AO, Gunsar F. Biliary sphincterotomy plus dilation with a large balloon for bile duct stones that are difficult to extract. *Gastrointest Endosc* 2003; **57**: 156-159 [PMID: [12556775](#) DOI: [10.1067/mge.2003.52](#)]
  - 11 **Kim TH**, Kim JH, Seo DW, Lee DK, Reddy ND, Rerknimitr R, Ratanachu-Ek T, Khor CJ, Itoi T, Yasuda I, Isayama H, Lau JY, Wang HP, Chan HH, Hu B, Kozarek RA, Baron TH. International consensus guidelines for endoscopic papillary large-balloon dilation. *Gastrointest Endosc* 2016; **83**: 37-47 [PMID: [26232360](#) DOI: [10.1016/j.gie.2015.06.016](#)]
  - 12 **Karsenti D**, Coron E, Vanbiervliet G, Privat J, Kull E, Bichard P, Perrot B, Quentin V, Duriez A, Cholet F, Subtil C, Duchmann JC, Lefort C, Hudziak H, Koch S, Granval P, Lecleire S, Charachon A, Barange K, Cesbron EM, De Widderspach A, Le Baleur Y, Barthet M, Poincloux L. Complete endoscopic sphincterotomy with vs. without large-balloon dilation for the removal of large bile duct stones: randomized multicenter study. *Endoscopy* 2017; **49**: 968-976 [PMID: [28753698](#) DOI: [10.1055/s-0043-114411](#)]
  - 13 **Dong SQ**, Singh TP, Zhao Q, Li JJ, Wang HL. Sphincterotomy plus balloon dilation versus sphincterotomy alone for choledocholithiasis: a meta-analysis. *Endoscopy* 2019; **51**: 763-771 [PMID: [30786316](#) DOI: [10.1055/a-0848-8271](#)]
  - 14 **Paspatis GA**, Paraskeva K, Vardas E, Papastergiou V, Tavernaraki A, Fragaki M, Theodoropoulou A, Chlouverakis G. Long-term recurrence of bile duct stones after endoscopic papillary large balloon dilation with sphincterotomy: 4-year extended follow-up of a randomized trial. *Surg Endosc* 2017; **31**: 650-655 [PMID: [27317037](#) DOI: [10.1007/s00464-016-5012-9](#)]
  - 15 **Park SJ**, Kim JH, Hwang JC, Kim HG, Lee DH, Jeong S, Cha SW, Cho YD, Kim HJ, Kim JH, Moon JH, Park SH, Itoi T, Isayama H, Kogure H, Lee SJ, Jung KT, Lee HS, Baron TH, Lee DK. Factors predictive of adverse events following endoscopic papillary large balloon dilation: results from a multicenter series. *Dig Dis Sci* 2013; **58**: 1100-1109 [PMID: [23225136](#) DOI: [10.1007/s10620-012-2494-8](#)]
  - 16 **Xu L**, Kyaw MH, Tse YK, Lau JY. Endoscopic sphincterotomy with large balloon dilation versus endoscopic sphincterotomy for bile duct stones: a systematic review and meta-analysis. *Biomed Res Int* 2015; **2015**: 673103 [PMID: [25756050](#) DOI: [10.1155/2015/673103](#)]
  - 17 **Tringali A**, Rota M, Rossi M, Hassan C, Adler DG, Mutignani M. A cumulative meta-analysis of endoscopic papillary balloon dilation versus endoscopic sphincterotomy for removal of common bile duct stones. *Endoscopy* 2019; **51**: 548-559 [PMID: [30727009](#) DOI: [10.1055/a-0818-3638](#)]
  - 18 **Lee GH**, Yang MJ, Kim JH, Hwang JC, Yoo BM, Lee DK, Jang SI, Lee TH, Park SH, Park JS, Jeong S, Lee DH. Balloons larger than 15 mm can increase the risk of adverse events following endoscopic papillary large balloon dilation. *J Gastroenterol Hepatol* 2019; **34**: 1450-1453 [PMID: [31157459](#) DOI: [10.1111/jgh.14749](#)]
  - 19 **Baron TH**, Harewood GC. Endoscopic balloon dilation of the biliary sphincter compared to endoscopic biliary sphincterotomy for removal of common bile duct stones during ERCP: a metaanalysis of randomized, controlled trials. *Am J Gastroenterol* 2004; **99**: 1455-1460 [PMID: [15307859](#) DOI: [10.1111/j.1572-0241.2004.30151.x](#)]
  - 20 **Disario JA**, Freeman ML, Bjorkman DJ, Macmathuna P, Petersen BT, Jaffe PE, Morales TG, Hixson LJ, Sherman S, Lehman GA, Jamal MM, Al-Kawas FH, Khandelwal M, Moore JP, Derfus GA, Jamidar PA, Ramirez FC, Ryan ME, Woods KL, Carr-Locke DL, Alder SC. Endoscopic balloon dilation compared with sphincterotomy for extraction of bile duct stones. *Gastroenterology* 2004; **127**: 1291-1299 [PMID: [15520997](#) DOI: [10.1053/j.gastro.2004.07.017](#)]
  - 21 **Freeman ML**, DiSario JA, Nelson DB, Fennerty MB, Lee JG, Bjorkman DJ, Overby CS, Aas J, Ryan ME, Bochna GS, Shaw MJ, Snady HW, Erickson RV, Moore JP, Roel JP. Risk factors for post-ERCP pancreatitis: a prospective, multicenter study. *Gastrointest Endosc* 2001; **54**: 425-434 [PMID: [11577302](#) DOI: [10.1067/mge.2001.117550](#)]
  - 22 **Liao WC**, Tu YK, Wu MS, Wang HP, Lin JT, Leung JW, Chien KL. Balloon dilation with adequate duration is safer than sphincterotomy for extracting bile duct stones: a systematic review and meta-analyses. *Clin Gastroenterol Hepatol* 2012; **10**: 1101-1109 [PMID: [22642953](#) DOI: [10.1016/j.cgh.2012.05.017](#)]
  - 23 **Testoni PA**, Mariani A, Giussani A, Vailati C, Masci E, Macarri G, Ghezzi L, Familiari L, Giardullo N, Mutignani M, Lombardi G, Talamini G, Spadaccini A, Briglia R, Piazzi L; SEIFRED Group. Risk factors for post-ERCP pancreatitis in high- and low-volume centers and among expert and non-expert operators: a prospective multicenter study. *Am J Gastroenterol* 2010; **105**: 1753-1761 [PMID: [20372116](#) DOI: [10.1038/ajg.2010.136](#)]
  - 24 **Jeong S**, Ki SH, Lee DH, Lee JI, Lee JW, Kwon KS, Kim HG, Shin YW, Kim YS. Endoscopic large-balloon sphincteroplasty without preceding sphincterotomy for the removal of large bile duct stones: a preliminary study. *Gastrointest Endosc* 2009; **70**: 915-922 [PMID: [19647241](#) DOI: [10.1016/j.gie.2009.04.042](#)]
  - 25 **Kogure H**, Kawahata S, Mukai T, Doi S, Iwashita T, Ban T, Ito Y, Kawakami H, Hayashi T, Sasahira N, Kubota K, Togawa O, Kato H, Okabe Y, Matsubara S, Yagioka H, Saito T, Nakai Y, Isayama H. Multicenter randomized trial of endoscopic papillary large balloon dilation without sphincterotomy



- versus endoscopic sphincterotomy for removal of bile duct stones: MARVELOUS trial. *Endoscopy* 2020; **52**: 736-744 [PMID: [32299114](#) DOI: [10.1055/a-1145-3377](#)]
- 26 **Kim TH**, Oh HJ, Lee JY, Sohn YW. Can a small endoscopic sphincterotomy plus a large-balloon dilation reduce the use of mechanical lithotripsy in patients with large bile duct stones? *Surg Endosc* 2011; **25**: 3330-3337 [PMID: [21533521](#) DOI: [10.1007/s00464-011-1720-3](#)]
  - 27 **Kim JH**, Yang MJ, Hwang JC, Yoo BM. Endoscopic papillary large balloon dilation for the removal of bile duct stones. *World J Gastroenterol* 2013; **19**: 8580-8594 [PMID: [24379575](#) DOI: [10.3748/wjg.v19.i46.8580](#)]
  - 28 **de Clemente Junior CC**, Bernardo WM, Franzini TP, Luz GO, Dos Santos MEL, Cohen JM, de Moura DTH, Marinho FRT, Coronel M, Sakai P, de Moura EGH. Comparison between endoscopic sphincterotomy vs endoscopic sphincterotomy associated with balloon dilation for removal of bile duct stones: A systematic review and meta-analysis based on randomized controlled trials. *World J Gastrointest Endosc* 2018; **10**: 130-144 [PMID: [30147845](#) DOI: [10.4253/wjge.v10.i8.130](#)]
  - 29 **Kuo CM**, Chiu YC, Liang CM, Wu CK, Lu LS, Tai WC, Kuo YH, Wu KL, Chuah SK, Kuo CH. The efficacy of limited endoscopic sphincterotomy plus endoscopic papillary large balloon dilation for removal of large bile duct stones. *BMC Gastroenterol* 2019; **19**: 93 [PMID: [31215401](#) DOI: [10.1186/s12876-019-1017-x](#)]
  - 30 **Cheon YK**, Lee TY, Kim SN, Shim CS. Impact of endoscopic papillary large-balloon dilation on sphincter of Oddi function: a prospective randomized study. *Gastrointest Endosc* 2017; **85**: 782-790. e1 [PMID: [27597425](#) DOI: [10.1016/j.gie.2016.08.031](#)]
  - 31 **Itoi T**, Ryozaawa S, Katanuma A, Okabe Y, Kato H, Horaguchi J, Tsuchiya T, Gotoda T, Fujita N, Yasuda K, Igarashi Y, Fujimoto K; Japan Gastroenterological Endoscopy Society. Japan Gastroenterological Endoscopy Society guidelines for endoscopic papillary large balloon dilation. *Dig Endosc* 2018; **30**: 293-309 [PMID: [29411902](#) DOI: [10.1111/den.13029](#)]
  - 32 **Meng W**, Leung JW, Zhang K, Zhou W, Wang Z, Zhang L, Sun H, Xue P, Liu W, Wang Q, Zhang J, Wang X, Wang M, Shao Y, Cai K, Hou S, Li Q, Zhang L, Zhu K, Yue P, Wang H, Zhang M, Sun X, Yang Z, Tao J, Wen Z, Wang Q, Chen B, Shao Q, Zhao M, Zhang R, Jiang T, Liu K, Zhang L, Chen K, Zhu X, Zhang H, Miao L, Wang Z, Li J, Yan X, Wang F, Zhang L, Suzuki A, Tanaka K, Nur U, Weiderpass E, Li X. Optimal dilation time for combined small endoscopic sphincterotomy and balloon dilation for common bile duct stones: a multicentre, single-blinded, randomised controlled trial. *Lancet Gastroenterol Hepatol* 2019; **4**: 425-434 [PMID: [31003961](#) DOI: [10.1016/S2468-1253\(19\)30075-5](#)]
  - 33 **Teoh AY**, Cheung FK, Hu B, Pan YM, Lai LH, Chiu PW, Wong SK, Chan FK, Lau JY. Randomized trial of endoscopic sphincterotomy with balloon dilation versus endoscopic sphincterotomy alone for removal of bile duct stones. *Gastroenterology* 2013; **144**: 341-345. e1 [PMID: [23085096](#) DOI: [10.1053/j.gastro.2012.10.027](#)]
  - 34 **Jun Bo Q**, Li Hua X, Tian Min C, Liu Gen G, Yan Mei Y, Hua Sheng L. Small Endoscopic Sphincterotomy plus Large-Balloon Dilation for Removal of Large Common Bile Duct Stones during ERCP. *Pak J Med Sci* 2013; **29**: 907-912 [PMID: [24353657](#) DOI: [10.12669/pjms.294.3662](#)]
  - 35 **Itoi T**, Itokawa F, Sofuni A, Kurihara T, Tsuchiya T, Ishii K, Tsuji S, Ikeuchi N, Moriyasu F. Endoscopic sphincterotomy combined with large balloon dilation can reduce the procedure time and fluoroscopy time for removal of large bile duct stones. *Am J Gastroenterol* 2009; **104**: 560-565 [PMID: [19174779](#) DOI: [10.1038/ajg.2008.67](#)]
  - 36 **Lee JC**, Moon JH, Choi HJ, Kim DC, Choi MH, Lee TH, Cha SW, Cho YD, Park SH, Kim SJ. Delayed endoscopic papillary large balloon dilation after sphincterotomy for removing large bile duct stones in patients with acute cholangitis. *Dig Dis Sci* 2014; **59**: 1302-1306 [PMID: [24464208](#) DOI: [10.1007/s10620-013-3003-4](#)]
  - 37 **Lee DK**, Jahng JH. Alternative methods in the endoscopic management of difficult common bile duct stones. *Dig Endosc* 2010; **22** Suppl 1: S79-S84 [PMID: [20590778](#) DOI: [10.1111/j.1443-1661.2010.00960.x](#)]
  - 38 **Aujla UI**, Ladep N, Dwyer L, Hood S, Stern N, Sturgess R. Endoscopic papillary large balloon dilatation with sphincterotomy is safe and effective for biliary stone removal independent of timing and size of sphincterotomy. *World J Gastroenterol* 2017; **23**: 8597-8604 [PMID: [29358868](#) DOI: [10.3748/wjg.v23.i48.8597](#)]
  - 39 **Xu XD**, Chen B, Dai JJ, Qian JQ, Xu CF. Minor endoscopic sphincterotomy followed by large balloon dilation for large choledocholith treatment. *World J Gastroenterol* 2017; **23**: 5739-5745 [PMID: [28883699](#) DOI: [10.3748/wjg.v23.i31.5739](#)]
  - 40 **Maruta A**, Iwashita T, Uemura S, Yoshida K, Iwata K, Mukai T, Doi S, Yasuda I, Imai K, Shimizu M. Comparison of late adverse events after endoscopic sphincterotomy versus endoscopic papillary large balloon dilation for common bile duct stones: A propensity score-based cohort analysis. *Dig Endosc* 2018; **30**: 493-500 [PMID: [29399885](#) DOI: [10.1111/den.13031](#)]
  - 41 **Feng Y**, Zhu H, Chen X, Xu S, Cheng W, Ni J, Shi R. Comparison of endoscopic papillary large balloon dilation and endoscopic sphincterotomy for retrieval of choledocholithiasis: a meta-analysis of randomized controlled trials. *J Gastroenterol* 2012; **47**: 655-663 [PMID: [22361862](#) DOI: [10.1007/s00535-012-0528-9](#)]
  - 42 **Stapfer M**, Selby RR, Stain SC, Katkhouda N, Parekh D, Jabbour N, Garry D. Management of duodenal perforation after endoscopic retrograde cholangiopancreatography and sphincterotomy. *Ann Surg* 2000; **232**: 191-198 [PMID: [10903596](#) DOI: [10.1097/0000658-200008000-00007](#)]
  - 43 **Rouquette O**, Bommelaer G, Abergel A, Poincloux L. Large balloon dilation post endoscopic



- sphincterotomy in removal of difficult common bile duct stones: a literature review. *World J Gastroenterol* 2014; **20**: 7760-7766 [PMID: [24976713](#) DOI: [10.3748/wjg.v20.i24.7760](#)]
- 44 **Dumonceau JM**, Kapral C, Aabakken L, Papanikolaou IS, Tringali A, Vanbiervliet G, Beyna T, Dinis-Ribeiro M, Hritz I, Mariani A, Paspatis G, Radaelli F, Lakhtakia S, Veitch AM, van Hooft JE. ERCP-related adverse events: European Society of Gastrointestinal Endoscopy (ESGE) Guideline. *Endoscopy* 2020; **52**: 127-149 [PMID: [31863440](#) DOI: [10.1055/a-1075-4080](#)]
- 45 **Chen JJ**, Wang XM, Liu XQ, Li W, Dong M, Suo ZW, Ding P, Li Y. Risk factors for post-ERCP pancreatitis: a systematic review of clinical trials with a large sample size in the past 10 years. *Eur J Med Res* 2014; **19**: 26 [PMID: [24886445](#) DOI: [10.1186/2047-783X-19-26](#)]
- 46 **Matsubayashi CO**, Ribeiro IB, de Moura DTH, Brunaldi VO, Bernardo WM, Hathorn KE, de Moura EGH. Is Endoscopic Balloon Dilation Still Associated With Higher Rates of Pancreatitis? *Pancreas* 2020; **49**: 158-174 [PMID: [32049951](#) DOI: [10.1097/MPA.0000000000001489](#)]
- 47 **Zulli C**, Grande G, Tontini GE, Labianca O, Geraci G, Sciumè C, Antypas P, Fiocca F, Manes G, Devani M, Manta R, Maurano A. Endoscopic papillary large balloon dilation in patients with large biliary stones and periampullary diverticula: Results of a multicentric series. *Dig Liver Dis* 2018; **50**: 828-832 [PMID: [29709460](#) DOI: [10.1016/j.dld.2018.03.034](#)]
- 48 **Itoi T**, Ishii K, Sofuni A, Itokawa F, Kurihara T, Tsuchiya T, Tsuji S, Ikeuchi N, Umeda J, Tanaka R, Moriyasu F. Large balloon dilatation following endoscopic sphincterotomy using a balloon enteroscope for the bile duct stone extractions in patients with Roux-en-Y anastomosis. *Dig Liver Dis* 2011; **43**: 237-241 [PMID: [20947457](#) DOI: [10.1016/j.dld.2010.09.002](#)]
- 49 **Nakai Y**, Kogure H, Yamada A, Isayama H, Koike K. Endoscopic management of bile duct stones in patients with surgically altered anatomy. *Dig Endosc* 2018; **30** Suppl 1: 67-74 [PMID: [29658650](#) DOI: [10.1111/den.13022](#)]
- 50 **Nakai Y**, Sato T, Hakuta R, Ishigaki K, Saito K, Saito T, Takahara N, Hamada T, Mizuno S, Kogure H, Tada M, Isayama H, Koike K. Management of Difficult Bile Duct Stones by Large Balloon, Cholangioscopy, Enteroscopy and Endosonography. *Gut Liver* 2020; **14**: 297-305 [PMID: [31581389](#) DOI: [10.5009/gnl19157](#)]
- 51 **Li T**, Wen J, Bie L, Gong B. Comparison of the Long-Term Outcomes of Endoscopic Papillary Large Balloon Dilation Alone versus Endoscopic Sphincterotomy for Removal of Bile Duct Stones. *Gastroenterol Res Pract* 2018; **2018**: 6430701 [PMID: [30057600](#) DOI: [10.1155/2018/6430701](#)]



Published by **Baishideng Publishing Group Inc**  
7041 Koll Center Parkway, Suite 160, Pleasanton, CA 94566, USA

**Telephone:** +1-925-3991568

**E-mail:** [bpgoffice@wjgnet.com](mailto:bpgoffice@wjgnet.com)

**Help Desk:** <https://www.f6publishing.com/helpdesk>

<https://www.wjgnet.com>

