

World Journal of *Gastrointestinal Endoscopy*

World J Gastrointest Endosc 2022 October 16; 14(10): 581-656



REVIEW

- 581** Endoscopic palliation of malignant biliary obstruction
Canakis A, Kahaleh M

ORIGINAL ARTICLE

Retrospective Study

- 597** Gastric intestinal metaplasia development in African American predominant United States population
Ahmad AI, Lee A, Caplan C, Wikholm C, Pothoulakis I, Almothafer Z, Raval N, Marshall S, Mishra A, Hodgins N, Kang IG, Chang RK, Dailey Z, Daneshmand A, Kapadia A, Oh JH, Rodriguez B, Sehgal A, Sweeney M, Swisher CB, Childers DF, O'Connor C, Sequeira LM, Cho W

SYSTEMATIC REVIEWS

- 608** Water-jet vs traditional triangular tip knife in peroral endoscopic myotomy for esophageal dysmotility: A systemic review and meta-analysis
Belopolsky Y, Puli SR
- 616** Laparoscopic Janeway gastrostomy as preferred enteral access in specific patient populations: A systematic review and case series
Murray-Ramcharan M, Fonseca Mora MC, Gattorno F, Andrade J

CASE REPORT

- 628** Tracheoesophageal fistulas in coronavirus disease 2019 pandemic: A case report
Gomez Zuleta MA, Gallego Ospina DM, Ruiz OF
- 636** Hemostasis of massive bleeding from esophageal tumor: A case report
Kashintsev AA, Rusanov DS, Antipova MV, Anisimov SV, Granstrem OK, Kokhanenko NY, Medvedev KV, Kutumov EB, Nadeeva AA, Proutski V
- 642** Cronkhite-Canada syndrome: First case report from Egypt and North Africa
Alzamzamy AE, Aboubakr A, Okasha HH, Abdellatef A, Elkholy S, Wahba M, Alboraie M, Elsayed H, Othman MO
- 648** Gastrointestinal histoplasmosis complicating pediatric Crohn disease: A case report and review of literature
Miller CQ, Saeed OAM, Collins K

ABOUT COVER

Editorial Board Member of *World Journal of Gastrointestinal Endoscopy*, Mahesh Kumar Goenka, MD, DM, Director, Institute of Gastrosiences, Apollo Multispeciality Hospitals, Kolkata, 58 Canal Circular Road, Kolkata 700054, India. mkgkolkata@gmail.com

AIMS AND SCOPE

The primary aim of *World Journal of Gastrointestinal Endoscopy* (WJGE, *World J Gastrointest Endosc*) is to provide scholars and readers from various fields of gastrointestinal endoscopy with a platform to publish high-quality basic and clinical research articles and communicate their research findings online.

WJGE mainly publishes articles reporting research results and findings obtained in the field of gastrointestinal endoscopy and covering a wide range of topics including capsule endoscopy, colonoscopy, double-balloon enteroscopy, duodenoscopy, endoscopic retrograde cholangiopancreatography, endosonography, esophagoscopy, gastrointestinal endoscopy, gastroscopy, laparoscopy, natural orifice endoscopic surgery, proctoscopy, and sigmoidoscopy.

INDEXING/ABSTRACTING

The WJGE is now abstracted and indexed in Emerging Sources Citation Index (Web of Science), PubMed, PubMed Central, Reference Citation Analysis, China National Knowledge Infrastructure, China Science and Technology Journal Database, and Superstar Journals Database. The 2022 edition of Journal Citation Reports® cites the 2021 Journal Citation Indicator (JCI) for WJGE as 0.33.

RESPONSIBLE EDITORS FOR THIS ISSUE

Production Editor: Yi-Xuan Cai; Production Department Director: Xu Guo; Editorial Office Director: Jia-Ping Yan.

NAME OF JOURNAL

World Journal of Gastrointestinal Endoscopy

ISSN

ISSN 1948-5190 (online)

LAUNCH DATE

October 15, 2009

FREQUENCY

Monthly

EDITORS-IN-CHIEF

Anastasios Koulaouzidis, Bing Hu, Sang Chul Lee, Joo Young Cho

EDITORIAL BOARD MEMBERS

<https://www.wjgnet.com/1948-5190/editorialboard.htm>

PUBLICATION DATE

October 16, 2022

COPYRIGHT

© 2022 Baishideng Publishing Group Inc

INSTRUCTIONS TO AUTHORS

<https://www.wjgnet.com/bpg/gerinfo/204>

GUIDELINES FOR ETHICS DOCUMENTS

<https://www.wjgnet.com/bpg/gerinfo/287>

GUIDELINES FOR NON-NATIVE SPEAKERS OF ENGLISH

<https://www.wjgnet.com/bpg/gerinfo/240>

PUBLICATION ETHICS

<https://www.wjgnet.com/bpg/gerinfo/288>

PUBLICATION MISCONDUCT

<https://www.wjgnet.com/bpg/gerinfo/208>

ARTICLE PROCESSING CHARGE

<https://www.wjgnet.com/bpg/gerinfo/242>

STEPS FOR SUBMITTING MANUSCRIPTS

<https://www.wjgnet.com/bpg/gerinfo/239>

ONLINE SUBMISSION

<https://www.f6publishing.com>



Cronkhite-Canada syndrome: First case report from Egypt and North Africa

Ahmed Elsayed Alzamzamy, Ashraf Aboubakr, Hussein H Okasha, Abeer Abdellatef, Shaimaa Elkholy, Mahmoud Wahba, Mohamed Alborae, Hussein Elsayed, Mohamed O Othman

Specialty type: Gastroenterology and hepatology

Provenance and peer review:

Unsolicited article; Externally peer reviewed.

Peer-review model: Single blind

Peer-review report's scientific quality classification

Grade A (Excellent): 0
Grade B (Very good): 0
Grade C (Good): C, C
Grade D (Fair): 0
Grade E (Poor): 0

P-Reviewer: Li J, China; Murata K, Japan

Received: June 3, 2022

Peer-review started: June 3, 2022

First decision: June 27, 2022

Revised: July 29, 2022

Accepted: September 13, 2022

Article in press: September 13, 2022

Published online: October 16, 2022



Ahmed Elsayed Alzamzamy, Ashraf Aboubakr, Department of Gastroenterology and Hepatology, Maadi Armed Forces Medical Complex, Military Medical Academy, Cairo 11711, Egypt

Hussein H Okasha, Abeer Abdellatef, Shaimaa Elkholy, Mahmoud Wahba, Department of Internal Medicine, Division of Gastroenterology, Hepatology and Endoscopy, Cairo University, Cairo 11311, Egypt

Mohamed Alborae, Department of Internal Medicine, Al-Azhar University, Cairo 11311, Egypt

Hussein Elsayed, Department of Pathology, Military Medical Academy, Cairo 11711, Egypt

Mohamed O Othman, Department of Internal Medicine, Baylor College of Medicine, Houston, TX 77082, United States

Corresponding author: Ahmed Elsayed Alzamzamy, MD, PhD, Consultant Physician-Scientist, Senior Lecturer, Department of Gastroenterology and Hepatology, Maadi Armed Forces Medical Complex, Military Medical Academy, Maadi Kornich El Nile, Cairo 11728, Egypt. dr_zamzamy@hotmail.com

Abstract

BACKGROUND

Gastrointestinal (GI) polyposis is a rare condition in GI diseases. To date about 500 cases of Cronkhite-Canada syndrome (CCS) have been reported worldwide.

CASE SUMMARY

We report a 60-year-old female patient who presented with dyspepsia, abdominal pain, and weight loss of 1-year duration. Her physical examination showed alopecia and onychodystrophy. Upper endoscopy revealed diffuse markedly thickened gastric mucosa involving the whole stomach with thickened gastric rugae and numerous polypoidal lesions. Histopathological examination showed marked hyperplasia of the foveolar glands with inflammatory cell infiltration. Endoscopic ultrasound showed a significantly hypertrophic mucosa and muscularis mucosa, while the submucosa and the muscularis propria were spared, favouring its benign nature. Colonoscopy showed multiple sessile polyps scattered at different parts of the colon. Histopathological examination revealed tubular adenomatous polyps with low-grade dysplasia. Differential diagnoses included CCS, Menterier disease (MD), other polyposis syndromes, lymphoma, amyloidosis, and gastric malignancies. The presence of alopecia, nail dystrophy, GI polyposis, markedly

thickened gastric mucosa and folds, abdominal pain, weight loss, and marked foveolar gland hyperplasia; all was in favour of CCS. Lymphoma was excluded due to sparing of the muscularis propria. The presence of colonic polyps and antral and duodenal infiltration, and the absence of hypoproteinaemia decreased the possibility for MD.

CONCLUSION

The patient was diagnosed as having CCS.

Key Words: Gastrointestinal polyposis; Thickened gastric mucosa; Cronkhite-Canada syndrome; Case report

©The Author(s) 2022. Published by Baishideng Publishing Group Inc. All rights reserved.

Core Tip: Cronkhite-Canada syndrome (CCS) is a rare acquired polyposis with unknown aetiology. To date about 500 cases have been reported worldwide. We herein report an Egyptian patient with CCS. Most of CCS cases were reported from Japan, and to our knowledge, our case is the first case reported from Egypt and North Africa. Cases presenting with gastrointestinal (GI) polyposis and marked thickened gastric mucosa and folds represent challenging cases and diagnostic dilemmas. The diagnosis was based on history, physical examination, endoscopic findings, and histology. CCS is typically characterized by GI symptoms, such as diarrhea and skin changes (*e.g.*, alopecia, pigmentation, and nail dystrophy), while endoscopic features include diffuse polyps throughout the entire GIT, except for the esophagus. Pathological types of polyps in CCS mainly include inflammatory, hyperplastic, hamartomatous, and/or adenomatous polyps. CCS can be complicated by many diseases and has a malignant tendency with a high mortality rate. Till now, there has been no uniform standard treatment for CCS.

Citation: Alzamzamy AE, Aboubakr A, Okasha HH, Abdellatef A, Elkholy S, Wahba M, Alboraie M, Elsayed H, Othman MO. Cronkhite-Canada syndrome: First case report from Egypt and North Africa. *World J Gastrointest Endosc* 2022; 14(10): 642-647

URL: <https://www.wjgnet.com/1948-5190/full/v14/i10/642.htm>

DOI: <https://dx.doi.org/10.4253/wjge.v14.i10.642>

INTRODUCTION

Cronkhite-Canada syndrome (CCS) is one of the rarest nonhereditary diseases[1], and its exact aetiology is still unknown[2], with around 500 cases having been described in the literature[3]. Most of CCS cases were reported from Japan, and to our knowledge, our case is the first case reported from Egypt and North Africa.

Patient with CCS usually presents with gastrointestinal (GI) symptoms such as abdominal pain, weight loss, and diarrhea, or with other symptoms such as onychodystrophy, alopecia, hyperpigmentation of the skin, and rarely vitiligo[4]. GI polyposis is the main endoscopic feature in CCS, which is commonly non-neoplastic and rather inflammatory, hyperplastic, hamartomatous, and/or adenomatous polyps in nature[5]. Moreover, some CCS cases may develop gastric and colorectal malignancies during the disease course[4].

CASE PRESENTATION

Chief complaints

A 60-year-old female patient presented with dyspepsia, abdominal pain, and weight loss of 1-year duration.

History of present illness

The patient denied other GI or anaemic symptoms. She was a non-smoker and did not drink alcohol.

History of past illness

The patient's past medical history was free apart from prolonged proton-pump inhibitor (PPI) intake.

Personal and family history

There was no family history of gastrointestinal polyposis or colorectal malignancy.

Physical examination

The physical examination was unremarkable apart from alopecia (Figure 1A) and onychodystrophy (Figure 1B).

Laboratory examinations

The patient's laboratory profile was within normal limits including a full complete blood picture (CBC), chemistry, serum albumin, serum calcium, urine analysis, antinuclear antibody (ANA), and IgG-4.

Imaging examinations

Oesophago-gastro-duodenoscopy (OGD) revealed diffuse markedly thickened gastric mucosa involving the whole stomach (fundus, body, and antrum), with thickened and tortuous gastric rugae, and numerous polypoidal lesions (3-10 mm in diameter), with a hyperaemic mucosa, and to a lesser extent down to the duodenal bulb and second part of the duodenum (Figure 2A and B). Multiple conventional biopsies were taken, and polypectomy was done for the large polyps for histopathological examination. Biopsies showed marked hyperplasia and cystic dilation of foveolar glands with inflammatory cell infiltration including eosinophils, hyperplastic polyps, chronic gastritis, and *Helicobacter pylori* (*H. pylori*) infection with no atypia or malignancy (Figure 3). IgG4-immunohistochemistry showed a very faintly positive signal.

Endoscopic ultrasound was done later and showed a significantly hypertrophic mucosa and muscularis mucosa, while the submucosa and the muscularis propria were spared, favouring its benign nature. Wall thickness was up to 8-10 mm (normal wall thickness is up to 4 mm) (Figure 2C).

Colonoscopy showed multiple variable-sized, sessile, and pedunculated polyps (~15), scattered at different parts of the colon. Snaring of the large polyps was done after submucosal injection (Figure 2D and E), and histopathological examination showed typical features of benign juvenile-like and hamartomatous polyps without dysplastic changes, while pathology of other polyps revealed tubular adenomatous polyps with low-grade dysplasia.

Both push enteroscopy and terminal ileoscopy showed no polyposis with a normal mucosa in the 3rd and 4th portions of the duodenum, the proximal jejunum, and the terminal ileum.

Computerized tomography (CT) scan of the abdomen & pelvis with oral and intravenous (IV) contrast revealed mild circumferential mural thickening of the gastric wall.

FINAL DIAGNOSIS

The patient was diagnosed as having CCS.

TREATMENT

The patient started a sequential therapy for *H. pylori* infection with complete eradication, followed by a proton pump inhibitor (40 mg once daily), prednisolone (30 mg/d), and mesalazine (500 mg QID) for 6 mo.

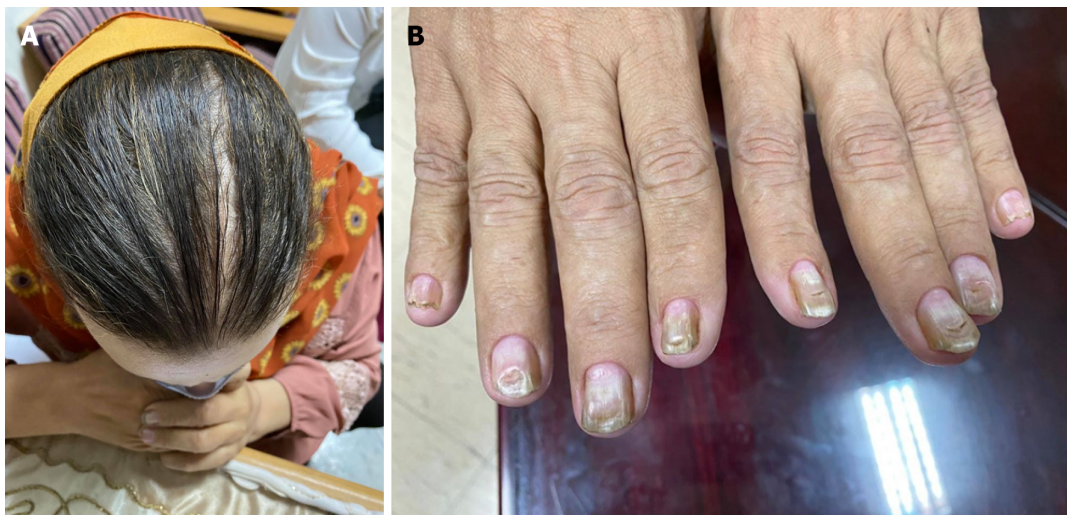DISCUSSION

In our case, the following differential diagnoses were raised and discussed with our gastroenterologists: CCS, MD, other polyposis syndromes (such as familial adenomatous polyposis, Gardner syndrome, juvenile polyposis, Peutz-Jeghers syndrome, and Turcot syndrome), lymphoma, amyloidosis, duodenal gastric heterotopia, and gastric malignancies.

The final diagnosis was based on the medical history, physical examination, endoscopic findings, and the histopathological examination. The presence of anomalies of ectodermal tissues (such as alopecia and nail dystrophy), gastrointestinal polyposis (hamartomatous and adenomatous polyps), markedly thickened gastric mucosa and folds, abdominal pain, weight loss, and marked foveolar gland hyperplasia; all was in favour of the CCS. On the other hand, there was no protein-losing enteropathy, diarrhea, hypoalbuminaemia, or skin pigmentation.

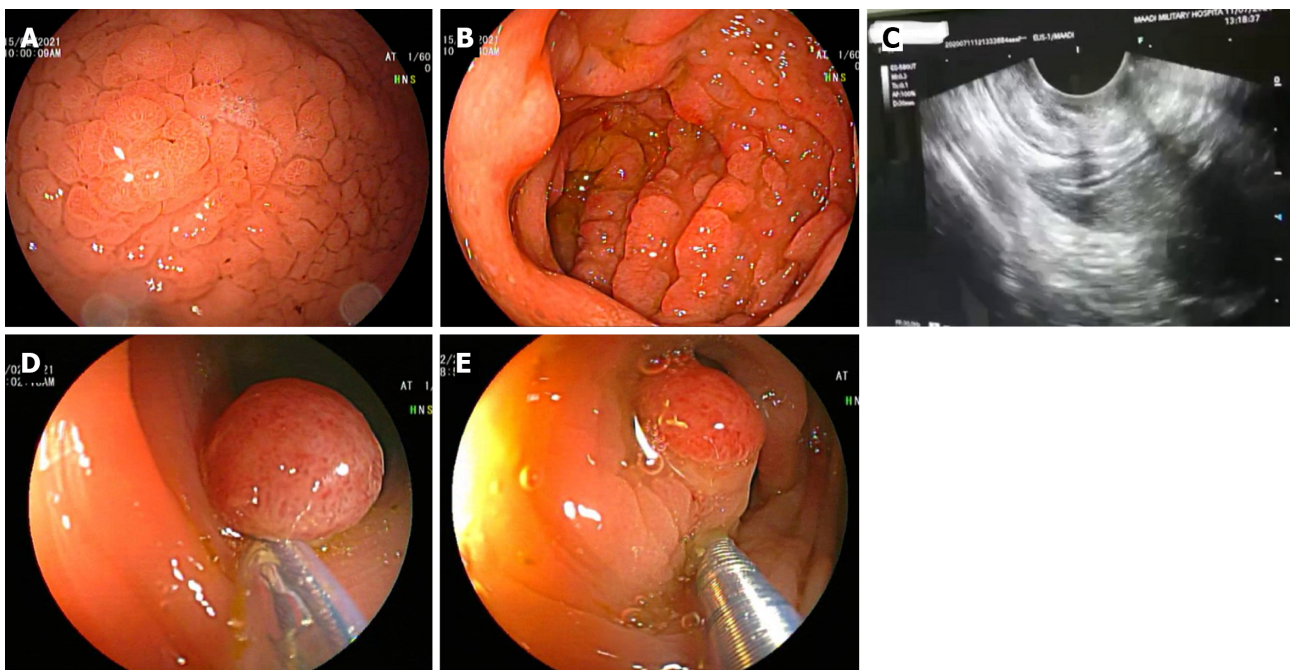
Lymphoma was excluded due to sparing of the muscularis propria. Furthermore, markedly thickened gastric mucosa and folds and the histopathological examination which revealed marked foveolar gland hyperplasia were consistent with MD. In addition, abdominal pain and weight loss are common presentation of MD, but the presence of colonic polyps, and antral and duodenal infiltration, and the absence of hypoproteinaemia decreased the possibility for MD.

The patient started a sequential therapy for *H. pylori* infection with complete eradication, followed by a proton pump inhibitor (40 mg once daily), prednisolone (30 mg/d), and mesalazine (500 mg QID) for 6 mo.



DOI: 10.4253/wjge.v14.i10.642 Copyright ©The Author(s) 2022.

Figure 1 Physical examination. A: Alopecia; B: Onychodystrophy.



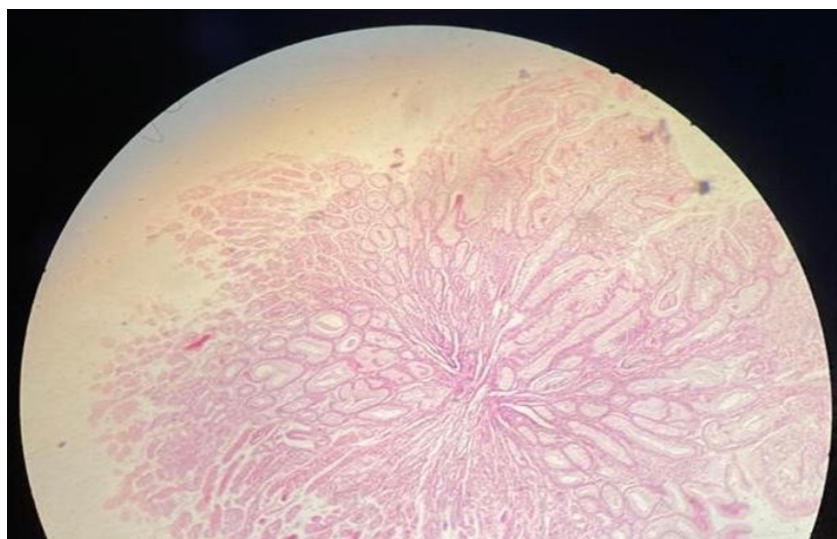
DOI: 10.4253/wjge.v14.i10.642 Copyright ©The Author(s) 2022.

Figure 2 Endoscopy. A and B: Upper endoscopy revealed a diffuse markedly thickened gastric mucosa with numerous polypoid lesions; C: Endoscopic ultrasound revealed a significantly hypertrophic mucosa and muscularis mucosa, but sparing of the submucosa and the muscularis propria; D and E: Colonoscopy showed multiple variable-sized, sessile, and pedunculated polyps, which were removed by snare polypectomy.

Common complications of CCS include anemia, intussusception, rectal prolapse, and GI bleeding, as well as other less common ones such as recurrent severe acute pancreatitis, myelodysplastic syndrome, cecal intussusception, portal thrombosis, membranous glomerulonephritis, and osteoporotic fractures that may result from malabsorption of calcium or prolonged glucocorticoid therapy or both. The most serious complication is malignancy; however, the incidence of CCS-related cancer is estimated to be 5%-25%, especially gastric and colon cancer[6].

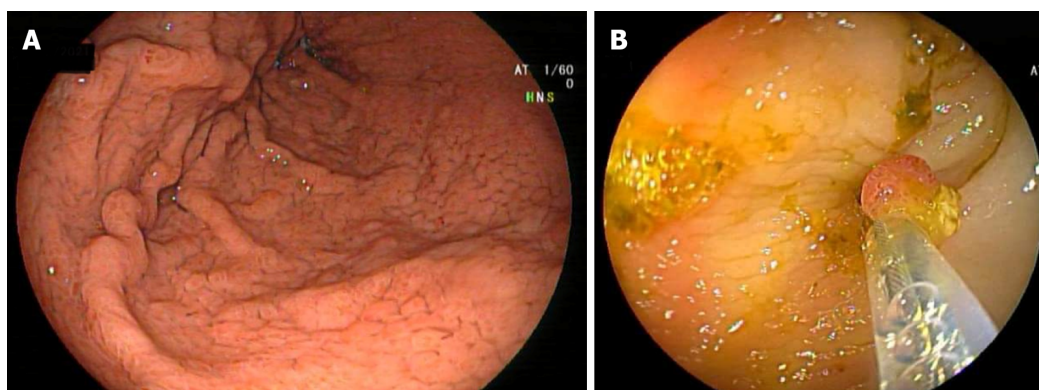
The follow-up endoscopies (OGD and colonoscopy) after 6 and 12 mo of treatment showed significant remission with a reduced number of gastric and colonic polyps and regression of hypertrophic gastric folds (Figure 4). Consequently, the patient's clinical condition was markedly improved, and the prednisolone dose was reduced gradually to 7.5 mg/d, but the mesalazine dose remained the same.

There is a tendency of malignant transformation or coexistence of gastrointestinal malignancies in patients with CCS. Therefore, endoscopic documentation of regression in CCS is important despite the



DOI: 10.4253/wjge.v14.i10.642 Copyright ©The Author(s) 2022.

Figure 3 Histopathological examination showed marked hyperplasia and cystic dilation of foveolar glands with inflammatory cell infiltration including eosinophils, chronic gastritis, and *Helicobacter pylori* infection with no atypia or malignancy.



DOI: 10.4253/wjge.v14.i10.642 Copyright ©The Author(s) 2022.

Figure 4 Follow-up endoscopies after 6 mo and 12 mo of treatment showed significant remission with a reduced number of gastric and colonic polyps and regression of hypertrophic gastric folds. A: Upper endoscopy; B: Colonoscopy.

lower incidence of CCS-related cancer in remission patients. Therefore, the comprehensive endoscopic annual surveillance either *via* chromoendoscopy or directed biopsy from irregular polyps, to exclude pre-cancer lesions before development of invasive carcinoma is mandatory; however, there are still no recommended guidelines to be followed[7].

Nutritional support, electrolytes, and mineral and vitamin supplementation remain the cornerstone in treatment of CCS beside antibiotics and corticosteroids; however, the definitive treatment is still unknown[4,7].

Till now, there is still much that needs to know about this syndrome. In this context, the most important issue is to maintain treatment monitoring and provide appropriate measure to prevent relapse[8].

CONCLUSION

CCS is a form of uncommon, acquired polyposis with obscure aetiology. To date around 500 cases have been reported all over the world. Most of CCS cases were reported from Japan, and to our knowledge, our case is the first case reported from Egypt and North Africa. CCS is generally characterized by GI symptoms, such as diarrhea and skin changes (*e.g.*, alopecia, skin pigmentation, and onychodystrophy), while GI polyposis is the main endoscopic feature in CCS, which is commonly non-neoplastic and mainly include inflammatory, hyperplastic, hamartomatous, and/or adenomatous polyps. CCS has a malignant potential, and some cases may develop gastric and colorectal malignancies during the disease

course. Till now, there is no uniform standard treatment for CCS.

ACKNOWLEDGEMENTS

We would like to acknowledge our hospitals and their workers, nurses, and staff members for all the support and help in this study and throughout our careers.

FOOTNOTES

Author contributions: Alzamzamy A contributed to data acquisition, analysis, and interpretation, all endoscopies, and drafting of the manuscript; Aboubakr A, Okasha H, and Othman M edited the manuscript and supervised the research; Alzamzamy A and Abdelatif A wrote the manuscript; Elsayed H contributed to the histopathology work and result analysis; Elkholy S, Wahba M, and Alboraie M contributed to data acquisition, analysis, and interpretation; all authors approved the final version of the manuscript.

Informed consent statement: Informed written consent was obtained from the patients for the publication of this report and any accompanying images.

Conflict-of-interest statement: The authors declare that they have no conflict of interest.

CARE Checklist (2016) statement: The authors have read the CARE Checklist (2016), and the manuscript was prepared and revised according to the CARE Checklist (2016).

Open-Access: This article is an open-access article that was selected by an in-house editor and fully peer-reviewed by external reviewers. It is distributed in accordance with the Creative Commons Attribution NonCommercial (CC BY-NC 4.0) license, which permits others to distribute, remix, adapt, build upon this work non-commercially, and license their derivative works on different terms, provided the original work is properly cited and the use is non-commercial. See: <https://creativecommons.org/licenses/by-nc/4.0/>

Country/Territory of origin: Egypt

ORCID number: Ahmed Elsayed Alzamzamy 0000-0002-3817-5370; Ashraf Aboubakr 0000-0002-3453-9317; Hussein H Okasha 0000-0002-0815-1394; Abeer Abdellatif 0000-0001-9945-9767; Shaimaa Elkholy 0000-0003-4322-6467; Mohamed O Othman 0000-0002-5888-4334.

Corresponding Author's Membership in Professional Societies: American Society for Gastrointestinal Endoscopy.

S-Editor: Chen YL

L-Editor: Wang TQ

P-Editor: Chen YL

REFERENCES

- 1 Yuan W, Tian L, Ai FY, Liu SJ, Shen SR, Wang XY, Liu F. Cronkhite-Canada syndrome: A case report. *Oncol Lett* 2018; **15**: 8447-8453 [PMID: 29805581 DOI: 10.3892/ol.2018.8409]
- 2 Schulte S, Kütting F, Mertens J, Kaufmann T, Drebbler U, Nierhoff D, Töx U, Steffen HM. Case report of patient with a Cronkhite-Canada syndrome: sustained remission after treatment with corticosteroids and mesalazine. *BMC Gastroenterol* 2019; **19**: 36 [PMID: 30813906 DOI: 10.1186/s12876-019-0944-x]
- 3 Wu ZY, Sang LX, Chang B. Cronkhite-Canada syndrome: from clinical features to treatment. *Gastroenterol Rep (Oxf)* 2020; **8**: 333-342 [PMID: 33163187 DOI: 10.1093/gastro/goaa058]
- 4 Kopáčová M, Urban O, Cyrany J, Laco J, Bureš J, Rejchrt S, Bártovec J, Tachecí I. Cronkhite-Canada syndrome: review of the literature. *Gastroenterol Res Pract* 2013; **2013**: 856873 [PMID: 24369458 DOI: 10.1155/2013/856873]
- 5 Asokkumar R, Mesenas S, Soetikno R. Endoscopic features of Cronkhite-Canada syndrome. *Endoscopy* 2021; **53**: E411-E412 [PMID: 33445199 DOI: 10.1055/a-1333-0796]
- 6 Haghighi S, Noorali S, Mohammad Alizadeh AH. Cronkhite-Canada Syndrome Associated with Metastatic Colon Cancer. *Case Rep Gastroenterol* 2018; **12**: 109-115 [PMID: 29805353 DOI: 10.1159/000479220]
- 7 Liu Y, Zhang L, Yang Y, Peng T. Cronkhite-Canada syndrome: report of a rare case and review of the literature. *J Int Med Res* 2020; **48**: 300060520922427 [PMID: 32459145 DOI: 10.1177/0300060520922427]
- 8 Dharmik P, Mani TM. A case with rare manifestation of Cronkhite-Canada Syndrome with remission after treatment and literature review. *Glob J Medical Clin Case Rep* 2018; **5**: 025-029 [DOI: 10.17352/2455-5282.000065]



Published by **Baishideng Publishing Group Inc**
7041 Koll Center Parkway, Suite 160, Pleasanton, CA 94566, USA

Telephone: +1-925-3991568

E-mail: bpgoffice@wjgnet.com

Help Desk: <https://www.f6publishing.com/helpdesk>

<https://www.wjgnet.com>

