


# World Journal of *Gastrointestinal Endoscopy*

*World J Gastrointest Endosc* 2022 March 16; 14(3): 106-190



### MINIREVIEWS

- 106** Role of intraluminal brachytherapy in palliation of biliary obstruction in cholangiocarcinoma: A brief review  
*Khosla D, Zaheer S, Gupta R, Madan R, Goyal S, Kumar N, Kapoor R*
- 113** Endoscopic management of difficult laterally spreading tumors in colorectum  
*Castillo-Regalado E, Uchima H*

### ORIGINAL ARTICLE

#### Retrospective Cohort Study

- 129** Endoscopic ultrasound-guided through-the-needle microforceps biopsy and needle-based confocal laser-endomicroscopy increase detection of potentially malignant pancreatic cystic lesions: A single-center study  
*Robles-Medrand C, Olmos JJ, Puga-Tejada M, Oleas R, Baquerizo-Burgos J, Arevalo-Mora M, Del Valle Zavala R, Nebel JA, Calle Loffredo D, Pitanga-Lukashok H*

#### Observational Study

- 142** Ergonomics of gastrointestinal endoscopies: Musculoskeletal injury among endoscopy physicians, nurses, and technicians  
*Shah SZ, Rehman ST, Khan A, Hussain MM, Ali M, Sarwar S, Abid S*
- 153** SARS-CoV-2 in inflammatory bowel disease population: Antibodies, disease and correlation with therapy  
*Conti CB, Mainardi E, Soro S, Testa S, De Silvestri A, Drago A, Cereatti F, Grassia R*

### SYSTEMATIC REVIEWS

- 163** Endoscopic management and outcome of non-variceal bleeding in patients with liver cirrhosis: A systematic review  
*Demetiou G, Augoustaki A, Kalaitzakis E*

### CASE REPORT

- 176** Mucosa-associated lymphoid tissue lymphoma in the terminal ileum: A case report  
*de Figueiredo VLP, Ribeiro IB, de Moura DTH, Oliveira CC, de Moura EGH*
- 183** Z-per-oral endoscopic myotomy as definitive prevention of a bleeding ulcer in Zenker's diverticulum: A case report  
*Krutsri C, Hiranyatheeb P, Sumritpradit P, Singhatas P, Choikrua P*

**ABOUT COVER**

Editorial Board Member of *World Journal of Gastrointestinal Endoscopy*, Clement LK Chia, FRCS (Ed), Assistant Professor, Consultant, Department of General Surgery, Khoo Teck Puat Hospital, Singapore 768828, Singapore. chia.clement.lk@ktph.com.sg

**AIMS AND SCOPE**

The primary aim of *World Journal of Gastrointestinal Endoscopy* (WJGE, *World J Gastrointest Endosc*) is to provide scholars and readers from various fields of gastrointestinal endoscopy with a platform to publish high-quality basic and clinical research articles and communicate their research findings online.

WJGE mainly publishes articles reporting research results and findings obtained in the field of gastrointestinal endoscopy and covering a wide range of topics including capsule endoscopy, colonoscopy, double-balloon enteroscopy, duodenoscopy, endoscopic retrograde cholangiopancreatography, endosonography, esophagoscopy, gastrointestinal endoscopy, gastroscopy, laparoscopy, natural orifice endoscopic surgery, proctoscopy, and sigmoidoscopy.

**INDEXING/ABSTRACTING**

The WJGE is now abstracted and indexed in Emerging Sources Citation Index (Web of Science), PubMed, PubMed Central, Reference Citation Analysis, China National Knowledge Infrastructure, China Science and Technology Journal Database, and Superstar Journals Database. The 2021 edition of Journal Citation Reports® cites the 2020 Journal Citation Indicator (JCI) for WJGE as 0.36.

**RESPONSIBLE EDITORS FOR THIS ISSUE**

Production Editor: Rui-Rui Wu, Production Department Director: Xu Guo, Editorial Office Director: Jia-Ping Yan.

**NAME OF JOURNAL**

*World Journal of Gastrointestinal Endoscopy*

**ISSN**

ISSN 1948-5190 (online)

**LAUNCH DATE**

October 15, 2009

**FREQUENCY**

Monthly

**EDITORS-IN-CHIEF**

Anastasios Koulaouzidis, Bing Hu, Sang Chul Lee, Joo Young Cho

**EDITORIAL BOARD MEMBERS**

<https://www.wjgnet.com/1948-5190/editorialboard.htm>

**PUBLICATION DATE**

March 16, 2022

**COPYRIGHT**

© 2022 Baishideng Publishing Group Inc

**INSTRUCTIONS TO AUTHORS**

<https://www.wjgnet.com/bpg/gerinfo/204>

**GUIDELINES FOR ETHICS DOCUMENTS**

<https://www.wjgnet.com/bpg/GerInfo/287>

**GUIDELINES FOR NON-NATIVE SPEAKERS OF ENGLISH**

<https://www.wjgnet.com/bpg/gerinfo/240>

**PUBLICATION ETHICS**

<https://www.wjgnet.com/bpg/GerInfo/288>

**PUBLICATION MISCONDUCT**

<https://www.wjgnet.com/bpg/gerinfo/208>

**ARTICLE PROCESSING CHARGE**

<https://www.wjgnet.com/bpg/gerinfo/242>

**STEPS FOR SUBMITTING MANUSCRIPTS**

<https://www.wjgnet.com/bpg/GerInfo/239>

**ONLINE SUBMISSION**

<https://www.f6publishing.com>



## Mucosa-associated lymphoid tissue lymphoma in the terminal ileum: A case report

Vitor Lauer Pimenta de Figueiredo, Igor Braga Ribeiro, Diogo Turiani Hourneaux de Moura, Cristiano Claudino Oliveira, Eduardo Guimarães Hourneaux de Moura

**Specialty type:** Gastroenterology and hepatology

**Provenance and peer review:**

Unsolicited article; Externally peer reviewed.

**Peer-review model:** Single blind

**Peer-review report's scientific quality classification**

Grade A (Excellent): 0

Grade B (Very good): B

Grade C (Good): C

Grade D (Fair): D, D

Grade E (Poor): 0

**P-Reviewer:** Batyrbekov K, Jin ZD, Chi T

**Received:** July 31, 2021

**Peer-review started:** July 31, 2021

**First decision:** September 29, 2021

**Revised:** October 5, 2021

**Accepted:** February 10, 2022

**Article in press:** February 10, 2022

**Published online:** March 16, 2022



**Vitor Lauer Pimenta de Figueiredo**, Faculdade de Medicina, Universidade de São Paulo, São Paulo 05403-010, Brazil

**Igor Braga Ribeiro, Diogo Turiani Hourneaux de Moura, Cristiano Claudino Oliveira, Eduardo Guimarães Hourneaux de Moura**, Unidade Morumbi-Rede D'Or, Hospital São Luiz, São Paulo 05605-050, Brazil

**Igor Braga Ribeiro, Diogo Turiani Hourneaux de Moura, Eduardo Guimarães Hourneaux de Moura**, Departamento de Gastroenterologia, Faculdade de Medicina, Universidade de São Paulo, Serviço de Endoscopia Gastrointestinal do Hospital das Clínicas HCFMUSP, São Paulo 05403-000, Brazil

**Corresponding author:** Igor Braga Ribeiro, MD, Doctor, Research Assistant, Research Scientist, Surgeon, Unidade Morumbi-Rede D'Or, Hospital São Luiz, Rua Engenheiro Oscar Americano, 840-Jardim Guedala, São Paulo 05605-050, Brazil. [igorbraga1@gmail.com](mailto:igorbraga1@gmail.com)

### Abstract

#### BACKGROUND

The lymphoma of the mucosa-associated lymphoid tissue (MALT) is predominantly found in the stomach. The few cases reported in the literature of MALT lymphomas affecting the ileum are in patients who are already symptomatic and with clear advanced endoscopic findings. We present the first case of an asymptomatic female patient who underwent colonoscopy as a routine examination with the findings of an ulcer in the distal ileum region, which histopathological examination and associated immunohistochemistry revealed the diagnosis of MALT lymphoma.

#### CASE SUMMARY

A 57-year-old asymptomatic female patient underwent a colonoscopy exam for screening. The examination revealed an ulcer of medium depth with well-defined borders covered by a thin layer of fibrin and a halo of hyperemia in the distal ileum portion. Findings are nonspecific but may signal infections by viruses, protozoa, and parasites or inflammatory diseases such as Crohn's disease. Biopsies of the ulcer were taken. The anatomopathological result revealed an atypical diffuse lymphocytic infiltrate of small cells with a characteristic cytoplasmic halo of marginal zone cells. The immunohistochemical study was performed and the results demonstrated a negative neoplastic infiltrate for the



expression of cyclin D1 and cytokeratin AE1/AE3 and a positive for BCL60 in the germinal center. The test also revealed CD10 positivity in the glandular epithelium and germinal center of a reactive follicle with dual-labeling of CD20 and CD3 demonstrating the B lymphocyte nature of the neoplastic infiltrate. In BCL2 protein labeling, the neoplastic infiltrate is strongly positive with a negative germinal center. The findings are consistent with immunophenotype B non-Hodgkin's lymphoma, better classified as extranodal MALT. The patient was treated with chemotherapy and showed complete regression of the disease, as evidenced by colonoscopy performed after treatment.

### CONCLUSION

MALT lymphomas in the terminal ileum are extremely rare and only 4 cases have been reported in the literature. Given the low sensitivity and specificity of endoscopic images in these cases, the pathology can be confused with other important differential diagnoses such as inflammatory diseases or infectious diseases and which makes the biopsy important, even in asymptomatic patients, paired with anatomopathological analysis and immunohistochemistry which is the gold standard for correct diagnosis.

**Key Words:** Mucosa-associated lymphoid tissue lymphoma; Ileum; Colonoscopy; Diagnosis; Biopsy; Case report

©The Author(s) 2022. Published by Baishideng Publishing Group Inc. All rights reserved.

**Core Tip:** Mucosa-associated lymphoid tissue (MALT) lymphoma is predominantly found in the stomach. Only a few cases of MALT lymphomas affecting the ileum have been published in the literature and these patients already had clear symptoms and endoscopic findings. We present a rare case of MALT lymphoma in the terminal ileum in an asymptomatic patient who underwent the examination for age screening.

**Citation:** de Figueiredo VLP, Ribeiro IB, de Moura DTH, Oliveira CC, de Moura EGH. Mucosa-associated lymphoid tissue lymphoma in the terminal ileum: A case report. *World J Gastrointest Endosc* 2022; 14(3): 176-182

**URL:** <https://www.wjgnet.com/1948-5190/full/v14/i3/176.htm>

**DOI:** <https://dx.doi.org/10.4253/wjge.v14.i3.176>

## INTRODUCTION

Mucosa-associated lymphoid tissue (MALT) lymphoma is a low-grade B-cell neoplasm of the extranodal marginal zone characterized by a lymphoid infiltrate in the mucous layer of hollow organs and glandular tissues[1,2]. The gastrointestinal tract is involved in about 50% of the cases[2,3] with the stomach accounting for 85% of all cases and strongly related to the presence and infection by *Helicobacter pylori* (*H. pylori*)[1,4]. Other, less usual regions can also be affected, such as salivary glands, lungs (14%), head and neck (15%), ocular attachments (12%) and skin (11%)[5].

MALT lymphomas in the ileum are extremely rare and few cases have been reported in the literature [5-9]. In these, all patients had already presented with an advanced degree of involvement with notable symptoms and with lesions dispersed throughout the ileocecal region[5,6].

This is the first reported case of a terminal ileum MALT lymphoma in an asymptomatic patient reported in the literature.

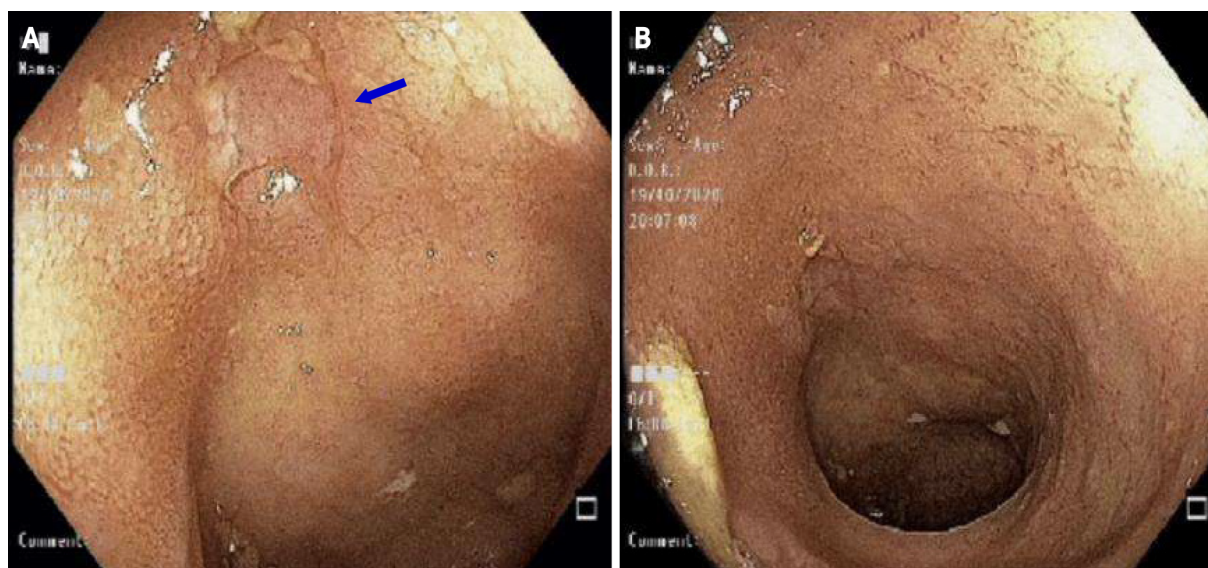
## CASE PRESENTATION

### Chief complaints

Asymptomatic.

### History of present illness

A 57-year-old asymptomatic female patient underwent a colonoscopy exam for screening. The examination revealed an ulcer of medium depth with well-defined borders covered by a thin layer of fibrin and a halo of hyperemia in the distal ileum portion (Figure 1). Findings are nonspecific but may signal infections by viruses, protozoa and parasites or inflammatory diseases such as Crohn's disease.



DOI: 10.4253/wjge.v14.i3.176 Copyright ©The Author(s) 2022.

**Figure 1 Colonoscopy exam.** A: Ulcer in the terminal ileum; B: Mild ulcer in terminal ileum.

Biopsies of the ulcer were taken.

The anatomopathological result revealed an atypical diffuse lymphocytic infiltrate of small cells with a characteristic cytoplasmic halo of marginal zone cells. The infiltrate presented with nodular and poorly delimited areas with dissection of collagen fibers and the muscular layer of the mucosa. There was no clear distinction regarding germinal centers. Signs of cellular atypia were also observed with enlarged nuclei. In the most superficial portion there was focal erosion, epithelial reactivity and eosinophilia (above 15 *per* high-power field) (Figure 2). No granulomas were found and there were no signs of infection by parasitic agents. An immunohistochemical study was requested to investigate lymphoproliferative disease.

The immunohistochemical study was performed by the EnVision FLEX Visualization System kit AGILENT (DAKO) method, which the results demonstrated a negative neoplastic infiltrate for the expression of cyclin D1 (Figure 2B) and cytokeratin AE1/AE3 (Figure 2C) and positive for BCL6 in the germinal center (Figure 2D). The test also revealed CD10 positivity in the glandular epithelium and germinal center of a reactive follicle (Figure 3A and B) with dual labeling of CD20 and CD3 demonstrating the B lymphocyte nature of the neoplastic infiltrate (Figure 3C and D). In BCL2 protein labeling, the neoplastic infiltrate is strongly positive with a negative germinal center (Figure 3E and F).

## FINAL DIAGNOSIS

The findings are consistent with immunophenotype B non-Hodgkin's lymphoma, better classified as extranodal MALT. The identification of lymphoid proliferation with atypical limits in a nodular and infiltrative pattern with foci of epithelial aggression was crucial for the diagnosis. Since MALT lymphomas are always negative for BCL6 and CD10 and positive for BCL2 with a negative germinal center, it was possible to rule out the differential diagnosis of follicular lymphoma.

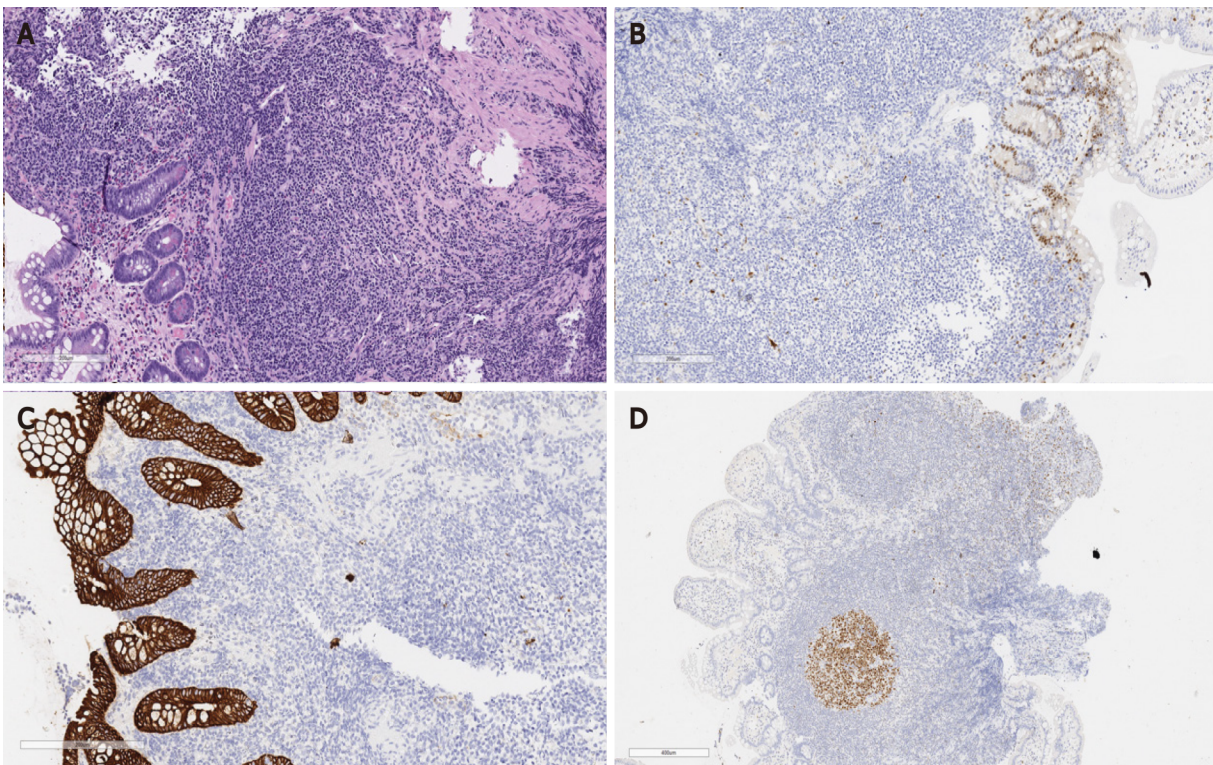
## TREATMENT

The patient was referred to the oncology team and treated with chemotherapy.

## OUTCOME AND FOLLOW-UP

Upon completion of treatment, the patient showed complete regression of the disease as evidenced by colonoscopy performed after treatment (Figure 4).





DOI: 10.4253/wjge.v14.i3.176 Copyright ©The Author(s) 2022.

**Figure 2 Biopsy of terminal ileum showing.** A: Hematoxylin & eosin-dense lymphocytic infiltrate composed of small cells, with a cytoplasmic halo, characteristic of cells in the marginal zone; B: Cyclin D1-Negative neoplastic infiltrate for protein expression of cyclin D1. Observe the positive control in the glandular epithelium; C: Cytokeratin cocktail AE1/AE3-negative neoplastic infiltrate for protein expression of cytokeratin. Observe the positive control in the glandular epithelium; D: BCL6-Protein label for BCL60. Note the negativity of the neoplastic infiltrate, and the positive internal controls in the germinal center of a reactional follicle.

## DISCUSSION

Extranodal marginal zone lymphoma (MALT lymphoma) is characterized by the proliferation of small B lymphocytes[10]. The stomach is the most common site of involvement where the main etiology is *H. pylori* infection[1]. In these cases, the endoscopic findings are varied and involve polyps, ulcerations, erythematous lesions, nodules and other non-specific findings[11]. Extranodal marginal zone lymphomas that affect the ileum region are extremely rare and only a few cases have been reported in the literature[5-9]. None of the previous studies showed *H. pylori* infections so the etiology of the disease remains unknown.

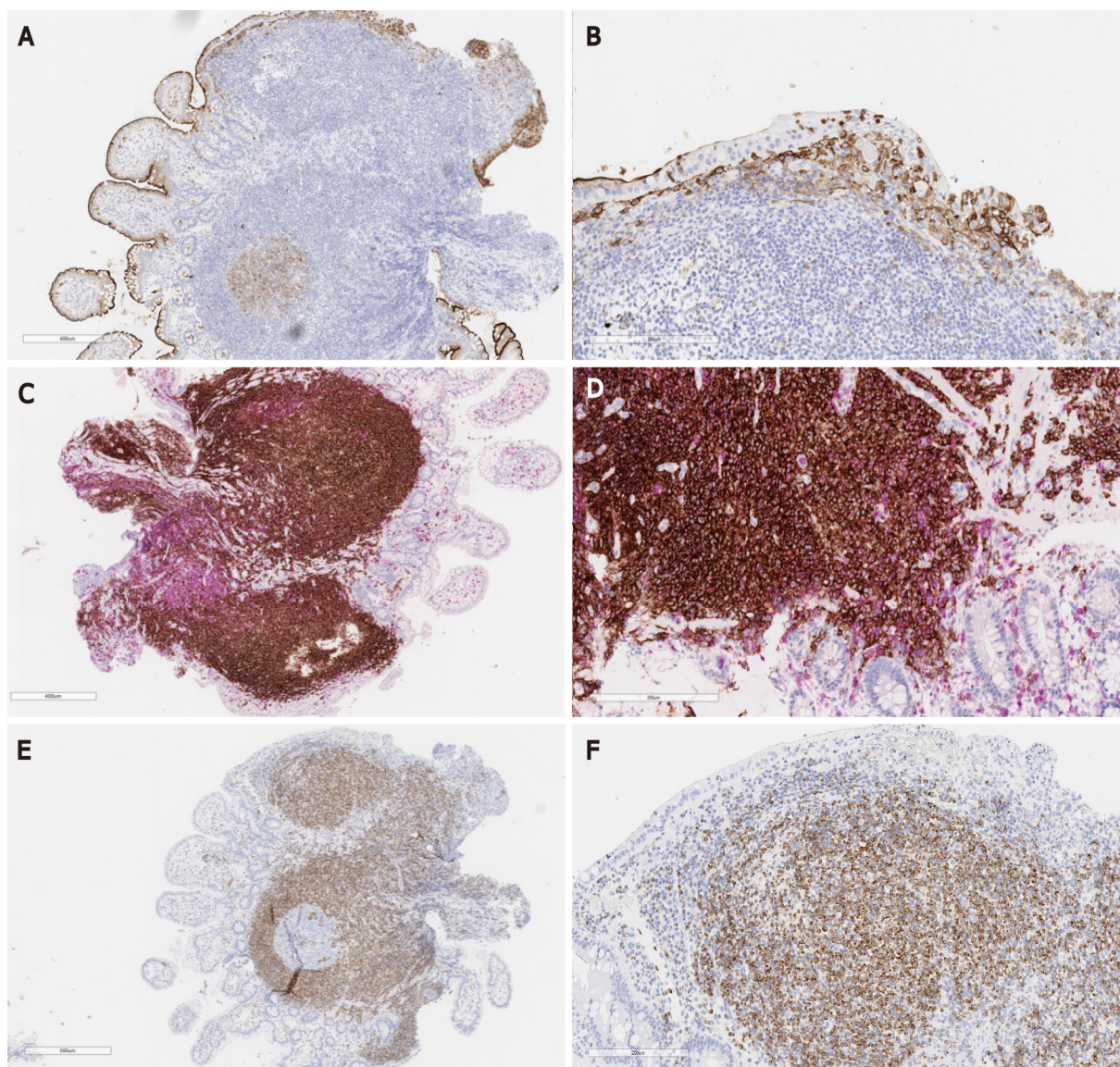
Endoscopic findings of primary small bowel lymphoma can be classified into 5 patterns: Mucosal fold thickening; nodular pattern, defined by the presence of nodules and micronodules of variable sizes; infiltrative pattern, where the bowel wall is immobile, not distended by insufflation, and firm over forceps; ulcerative pattern with ulcers of variable sizes and depths, and mosaic pattern[12].

Among the four cases published in the literature on ileum MALT lymphomas, all presented endoscopic findings with multiple protuberances: Two[5,7] cases with ulcerations and two[6,8] cases with smooth mucosa. In one case, the presence of a single mass in the intestine was demonstrated without erosions in the mucosa[6].

The treatment of MALT lymphoma is initially made with the eradication of *H. pylori*, in cases with involvement of the bacteria. If there is no concomitant *H. pylori* infection or no tumor remission after *H. pylori* treatment, radiotherapy, chemotherapy, or immunotherapy with anti-CD20 monoclonal antibodies should be considered. Radiotherapy has an excellent prognosis when used in cases where the disease is localized. In the presence of disseminated or more advanced disease, the use of radiotherapy or immunotherapy is indicated. Treatment must be individualized according to the stage of the disease and symptoms, as well as the patient's preference[13]. Although MALT lymphoma has a favorable prognosis and is responsive to systematic therapy, especially when identified early, when patients are symptomatic, unfortunately they already have a more advanced degree of involvement.

Terada[5] reported the case of a 34-year-old patient with abdominal pain and melena whose colonoscopy revealed multiple nodules and ulcers scattered throughout the ileum. Endoscopic images were suggestive of ileitis, mesenchymal tumor, or lymphoma.





DOI: 10.4253/wjge.v14.i3.176 Copyright ©The Author(s) 2022.

**Figure 3 Terminal ileum biopsy showing.** A: Protein labeling for CD10. Note the negativity of the neoplastic infiltrate, and the positive internal controls of the glandular epithelium and germinal center of a reactional follicle; B: Protein labeling for CD10. Note the negativity of the neoplastic infiltrate and the positive internal controls of the glandular epithelium; C and D: Double labeling of CD20 (brown) and CD3 (red) demonstrating the nature of B lymphocytes of the neoplastic infiltrate. Note that T cells border the neoplastic infiltrate and preferably the epithelium, attesting to its reaction nature; E: Protein labeling for BCL2. Note that the neoplastic infiltrate expresses strongly and the internal negative control in the germinal center of a reactional follicle; F: Strong protein labeling of the neoplastic infiltrate for BCL2

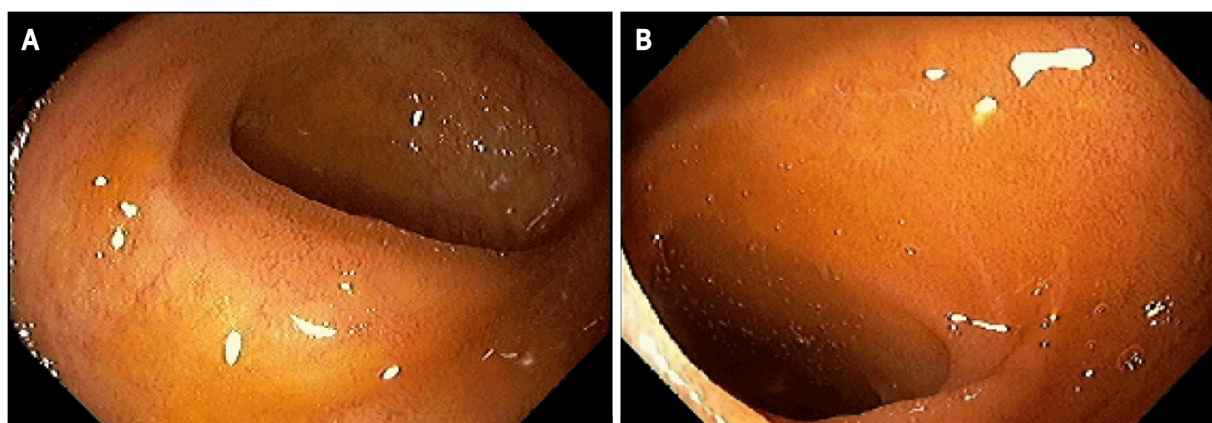
Hasegawa *et al*[6] described two cases of oligosymptomatic patients with abdominal pain being a common symptom. Colonoscopy in the first case found multiple whitish nodules in the region close to the ileocecal valve, which had a smooth and polished appearance. In the second case, a colonoscopy revealed an ileocecal valve with an enlarged, soft appearance and areas of enanthema.

Makino *et al*[7] discussed a case of a patient with initial complaints of postprandial epigastric pain. Colonoscopy examination revealed multiple protruding lesions in the terminal ileum with an erosive surface covered by swollen mucosa.

In the report by Ohashi *et al*[8] colonoscopy identified multiple polyposis lesions in the terminal ileum with an absence of villi.

In all cases, biopsy with histological evaluation concurrently with immunohistochemical analysis was crucial for the diagnosis of MALT lymphoma.

The uniqueness of the case presented in this study is due to the fact that the patient was asymptomatic and her endoscopic findings had a more discrete and nonspecific pattern compared to other studies which made the diagnosis even more challenging.



DOI: 10.4253/wjge.v14.i3.176 Copyright ©The Author(s) 2022.

**Figure 4 Colonoscopy after treatment.** A: Disease-free mucosa; B: Ulcer-free terminal ileum.

## CONCLUSION

Given the low sensitivity and specificity of endoscopic images in these cases the pathology can be confused with other important differential diagnoses such as inflammatory diseases (such as Crohn's disease) or infectious diseases, which makes the biopsy, even in asymptomatic patients, with anatomopathological analysis and performing immunohistochemistry, the gold standard for correct diagnosis [14].

## FOOTNOTES

**Author contributions:** de Figueiredo VLP, Ribeiro IB, and de Moura EGH performed the data curation; Ribeiro IB and de Moura DTH contributed to the formal analysis; Ribeiro IB and de Moura EGH performed the investigation; de Moura EGH contributed to the supervision; de Figueiredo VLP and Ribeiro IB contributed to the writing of the original draft; Ribeiro IB contributed to the writing of the review and editing.

**Informed consent statement:** The work described has been conducted in accordance with the Code of Ethics of the World Medical Association (Declaration of Helsinki). Informed consent for publication of this case was obtained from the patient's daughter (witnessed by two physicians).

**Conflict-of-interest statement:** All other authors declare that they have no conflict of interest.

**CARE Checklist (2016) statement:** The authors have read the CARE Checklist (2016), and the manuscript was prepared and revised according to the CARE Checklist (2016).

**Open-Access:** This article is an open-access article that was selected by an in-house editor and fully peer-reviewed by external reviewers. It is distributed in accordance with the Creative Commons Attribution NonCommercial (CC BY-NC 4.0) license, which permits others to distribute, remix, adapt, build upon this work non-commercially, and license their derivative works on different terms, provided the original work is properly cited and the use is non-commercial. See: <http://creativecommons.org/licenses/by-nc/4.0/>

**Country/Territory of origin:** Brazil

**ORCID number:** Vitor Lauer Pimenta de Figueiredo 0000-0001-7304-8222; Igor Braga Ribeiro 0000-0003-1844-8973; Diogo Turiani Hourneaux de Moura 0000-0002-7446-0355; Cristiano Claudino Oliveira 0000-0001-6682-5230; Eduardo Guimarães Hourneaux de Moura 0000-0003-1215-5731.

**S-Editor:** Fan JR

**L-Editor:** Filipodia

**P-Editor:** Fan JR

## REFERENCES

- 1 Violeta Filip P, Cuciureanu D, Sorina Diaconu L, Maria Vladareanu A, Silvia Pop C. MALT lymphoma: epidemiology, clinical diagnosis and treatment. *J Med Life* 2018; 11: 187-193 [PMID: 30364585 DOI: 10.25122/jml-2018-0035]



- 2 **Vetro C**, Romano A, Amico I, Conticello C, Motta G, Figuera A, Chiarenza A, Di Raimondo C, Giulietti G, Bonanno G, Palumbo GA, Di Raimondo F. Endoscopic features of gastro-intestinal lymphomas: from diagnosis to follow-up. *World J Gastroenterol* 2014; **20**: 12993-13005 [PMID: [25278693](#) DOI: [10.3748/wjg.v20.i36.12993](#)]
- 3 **Oh SY**, Kim WS, Kim JS, Kim SJ, Lee S, Lee DH, Won JH, Hwang IG, Kim MK, Lee SI, Chae YS, Yang DH, Kang HJ, Choi CW, Park J, Kim HJ, Kwon JH, Lee HS, Lee GW, Eom HS, Kwak JY, Lee WS, Suh C. Multiple mucosa-associated lymphoid tissue organs involving marginal zone B cell lymphoma: organ-specific relationships and the prognostic factors. Consortium for improving survival of lymphoma study. *Int J Hematol* 2010; **92**: 510-517 [PMID: [20838958](#) DOI: [10.1007/s12185-010-0680-z](#)]
- 4 **De Miranda Neto AA**, Marques SB, Baba ER, Yamazaki K, Ribeiro IB, De Moura EGH. Extensive squamous metaplasia of the stomach. *Arq Gastroenterol* 2020; **57**: 335-336 [PMID: [32813817](#) DOI: [10.1590/s0004-2803.202000000-62](#)]
- 5 **Terada T**. Extranodal marginal zone lymphoma of mucosa-associated lymphoid tissue (MALT lymphoma) of the ileum in a 35-year-old Japanese woman. *Int J Clin Exp Pathol* 2013; **6**: 951-956 [PMID: [23638229](#)]
- 6 **Hasegawa N**, Tsuboi Y, Kato K, Yamada K, Morita K, Kuroiwa M, Ito H, Matsushima T, Ono K, Oshiro M. Endoscopic diagnosis of ileocecal mucosa-associated lymphoid tissue lymphoma. *Gastrointest Endosc* 1999; **50**: 115-117 [PMID: [10385738](#) DOI: [10.1016/S0016-5107\(99\)70360-3](#)]
- 7 **Makino Y**, Suzuki H, Nishizawa T, Kameyama K, Hisamatsu T, Imaeda H, Mukai M, Hibi T. Ileal Mucosa-Associated Lymphoid Tissue (MALT) Lymphoma with a Large-Cell Component That Regressed Spontaneously. *Gut Liver* 2010; **4**: 117-121 [PMID: [20479924](#) DOI: [10.5009/gnl.2010.4.1.117](#)]
- 8 **Ohashi S**, Yazumi S, Watanabe N, Matsumoto S, Fukui T, Nishio A, Chiba T. Education and imaging. Gastrointestinal: MALT lymphoma of the terminal ileum. *J Gastroenterol Hepatol* 2006; **21**: 1495 [PMID: [16911702](#) DOI: [10.1111/j.1440-1746.2006.04634.x](#)]
- 9 **Matsumoto Y**, Matsumoto T, Nakamura S, Kawasaki A, Aso M, Aoyagi K, Sadoshima S, Onoyama K, Fujishima M. Primary ileal plasmacytoma arising in mixed low- and high-grade B-cell lymphoma of mucosa-associated lymphoid tissue type. *Abdom Imaging* 2000; **25**: 139-141 [PMID: [10675454](#) DOI: [10.1007/s002619910033](#)]
- 10 **Palo S**, Biligi DS. A Unique Presentation of Primary Intestinal MALT Lymphoma as Multiple Lymphomatous Polyposis. *J Clin Diagn Res* 2016; **10**: ED16-ED18 [PMID: [27190819](#) DOI: [10.7860/JCDR/2016/17861.7607](#)]
- 11 **Ahmad A**, Govil Y, Frank BB. Gastric mucosa-associated lymphoid tissue lymphoma. *Am J Gastroenterol* 2003; **98**: 975-986 [PMID: [12809817](#) DOI: [10.1111/j.1572-0241.2003.07424.x](#)]
- 12 **Halphen M**, Najjar T, Jaafoura H, Cammoun M, Tufrafi G. Diagnostic value of upper intestinal fiber endoscopy in primary small intestinal lymphoma. A prospective study by the Tunisian-French Intestinal Lymphoma Group. *Cancer* 1986; **58**: 2140-2145 [PMID: [3756829](#) DOI: [10.1002/1097-0142\(19861101\)58:9<2140::AID-CNCR2820580930>3.0.CO;2-P](#)]
- 13 **Gong EJ**, Choi KD. [Diagnosis and Treatment of Gastric Mucosa-associated Lymphoid Tissue Lymphoma]. *Korean J Gastroenterol* 2019; **74**: 304-313 [PMID: [31870136](#) DOI: [10.4166/kjg.2019.74.6.304](#)]
- 14 **Park BS**, Lee SH. Endoscopic features aiding the diagnosis of gastric mucosa-associated lymphoid tissue lymphoma. *Yeungnam Univ J Med* 2019; **36**: 85-91 [PMID: [31620618](#) DOI: [10.12701/yujm.2019.00136](#)]





Published by **Baishideng Publishing Group Inc**  
7041 Koll Center Parkway, Suite 160, Pleasanton, CA 94566, USA

**Telephone:** +1-925-3991568

**E-mail:** [bpgoffice@wjgnet.com](mailto:bpgoffice@wjgnet.com)

**Help Desk:** <https://www.f6publishing.com/helpdesk>

<https://www.wjgnet.com>

