

World Journal of *Gastrointestinal Endoscopy*

World J Gastrointest Endosc 2022 June 16; 14(6): 354-415



MINIREVIEWS

- 354 Role of endoscopic ultrasound in vascular interventions: Where are we now?
Fugazza A, Khalaf K, Colombo M, Carrara S, Spadaccini M, Koleth G, Troncone E, Maselli R, Repici A, Anderloni A

ORIGINAL ARTICLE

Retrospective Study

- 367 Pediatric endoscopy across multiple clinical settings: Efficiency and adverse events
Crawford E, Sabe R, Sferra TJ, Apperson-Hansen C, Khalili AS
- 376 Endoscopic ultrasound diagnostic gain over computed tomography and magnetic resonance cholangiopancreatography in defining etiology of idiopathic acute pancreatitis
Mazza S, Elvo B, Conti CB, Drago A, Verga MC, Soro S, De Silvestri A, Cereatti F, Grassia R
- 387 Change point analysis validation of the learning curve in laparoscopic colorectal surgery: Experience from a non-structured training setting
Perivoliotis K, Baloyiannis I, Mamaloudis I, Volakakis G, Valaroutsos A, Tzovaras G

Observational Study

- 402 Role of endoscopic ultrasound and cyst fluid tumor markers in diagnosis of pancreatic cystic lesions
Okasha HH, Abdellatef A, Elkholy S, Mogawer MS, Yosry A, Elserafy M, Medhat E, Khalaf H, Fouad M, Elbaz T, Ramadan A, Behiry ME, Y William K, Habib G, Kaddah M, Abdel-Hamid H, Abou-Elmagd A, Galal A, Abbas WA, Altonbary AY, El-Ansary M, Abdou AE, Haggag H, Abdallah TA, Elfeki MA, Faheem HA, Khattab HM, El-Ansary M, Beshir S, El-Nady M

ABOUT COVER

Editor-in-Chief of *World Journal of Gastrointestinal Endoscopy*, Joo Young Cho, MD, PhD, Chairman, Director, Full Professor, Senior Editor, Department of Gastroenterology, Cha Gangnam Medical Center, Cha University College of Medicine, Seoul 06135, South Korea. cjy6695@naver.com

AIMS AND SCOPE

The primary aim of *World Journal of Gastrointestinal Endoscopy* (WJGE, *World J Gastrointest Endosc*) is to provide scholars and readers from various fields of gastrointestinal endoscopy with a platform to publish high-quality basic and clinical research articles and communicate their research findings online.

WJGE mainly publishes articles reporting research results and findings obtained in the field of gastrointestinal endoscopy and covering a wide range of topics including capsule endoscopy, colonoscopy, double-balloon enteroscopy, duodenoscopy, endoscopic retrograde cholangiopancreatography, endosonography, esophagoscopy, gastrointestinal endoscopy, gastroscopy, laparoscopy, natural orifice endoscopic surgery, proctoscopy, and sigmoidoscopy.

INDEXING/ABSTRACTING

The WJGE is now abstracted and indexed in Emerging Sources Citation Index (Web of Science), PubMed, PubMed Central, Reference Citation Analysis, China National Knowledge Infrastructure, China Science and Technology Journal Database, and Superstar Journals Database. The 2022 edition of Journal Citation Reports® cites the 2021 Journal Citation Indicator (JCI) for WJGE as 0.33.

RESPONSIBLE EDITORS FOR THIS ISSUE

Production Editor: Yi-Xuan Cai; Production Department Director: Xu Guo; Editorial Office Director: Jia-Ping Yan.

NAME OF JOURNAL

World Journal of Gastrointestinal Endoscopy

ISSN

ISSN 1948-5190 (online)

LAUNCH DATE

October 15, 2009

FREQUENCY

Monthly

EDITORS-IN-CHIEF

Anastasios Koulaouzidis, Bing Hu, Sang Chul Lee, Joo Young Cho

EDITORIAL BOARD MEMBERS

<https://www.wjgnet.com/1948-5190/editorialboard.htm>

PUBLICATION DATE

June 16, 2022

COPYRIGHT

© 2022 Baishideng Publishing Group Inc

INSTRUCTIONS TO AUTHORS

<https://www.wjgnet.com/bpg/gerinfo/204>

GUIDELINES FOR ETHICS DOCUMENTS

<https://www.wjgnet.com/bpg/GerInfo/287>

GUIDELINES FOR NON-NATIVE SPEAKERS OF ENGLISH

<https://www.wjgnet.com/bpg/gerinfo/240>

PUBLICATION ETHICS

<https://www.wjgnet.com/bpg/GerInfo/288>

PUBLICATION MISCONDUCT

<https://www.wjgnet.com/bpg/gerinfo/208>

ARTICLE PROCESSING CHARGE

<https://www.wjgnet.com/bpg/gerinfo/242>

STEPS FOR SUBMITTING MANUSCRIPTS

<https://www.wjgnet.com/bpg/GerInfo/239>

ONLINE SUBMISSION

<https://www.f6publishing.com>



Retrospective Study

Endoscopic ultrasound diagnostic gain over computed tomography and magnetic resonance cholangiopancreatography in defining etiology of idiopathic acute pancreatitis

Stefano Mazza, Biagio Elvo, Clara Benedetta Conti, Andrea Drago, Maria Chiara Verga, Sara Soro, Annalisa De Silvestri, Fabrizio Cereatti, Roberto Grassia

Specialty type: Gastroenterology and hepatology

Provenance and peer review: Invited article; Externally peer reviewed.

Peer-review model: Single blind

Peer-review report's scientific quality classification

Grade A (Excellent): 0
Grade B (Very good): B, B
Grade C (Good): C, C, C
Grade D (Fair): D
Grade E (Poor): 0

P-Reviewer: Alali AA, Kuwait; Jin ZD, China; Kobayashi K, Japan
A-Editor: Zhu JQ, China

Received: January 28, 2022

Peer-review started: January 28, 2022

First decision: April 10, 2022

Revised: April 23, 2022

Accepted: May 22, 2022

Article in press: May 22, 2022

Published online: June 16, 2022



Stefano Mazza, Andrea Drago, Maria Chiara Verga, Sara Soro, Roberto Grassia, Gastroenterology and Digestive Endoscopy Unit, ASST Cremona, Cremona 26100, Italy

Biagio Elvo, Gastroenterology and Endoscopy Unit, Federico II University, Napoli 80131, Italy

Clara Benedetta Conti, Interventional Endoscopy Unit, ASST Monza, Monza 20900, Italy

Annalisa De Silvestri, Biometry and Clinical Epidemiology, Scientific Direction, IRCCS San Matteo Hospital Foundation, Pavia 27100, Italy

Fabrizio Cereatti, Department of Gastroenterology and Digestive Endoscopy, Castelli Hospital, Ariccia (Rm) 00040, Italy

Corresponding author: Stefano Mazza, MD, Doctor, Gastroenterology and Digestive Endoscopy Unit, ASST Cremona, Viale Concordia, 1, Cremona 26100, Italy. stem311089@gmail.com

Abstract

BACKGROUND

About 10%-30% of acute pancreatitis remain idiopathic (IAP) even after clinical and imaging tests, including abdominal ultrasound (US), contrast-enhanced computed tomography (CECT) and magnetic resonance cholangiopancreatography (MRCP). This is a relevant issue, as up to 20% of patients with IAP have recurrent episodes and 26% of them develop chronic pancreatitis. Few data are available on the role of EUS in clarifying the etiology of IAP after failure of one or more cross-sectional techniques.

AIM

To evaluate the diagnostic gain after failure of one or more previous cross-sectional exams.

METHODS

We retrospectively collected data about consecutive patients with AP and at least one negative test between US, CECT and MRCP, who underwent linear EUS between January 2017 and December 2020. We investigated the EUS diagnostic yield and the EUS diagnostic gain over different combinations of these cross-

sectional imaging techniques for the etiologic diagnosis of AP. Types and frequency of EUS diagnosis were also analyzed, and EUS diagnosis was compared with the clinical parameters. After EUS, patients were followed-up for a median of 31.5 mo to detect cases of pancreatitis recurrence.

RESULTS

We enrolled 81 patients (63% males, mean age 61 ± 18 , 23% with previous cholecystectomy, 17% with recurrent pancreatitis). Overall EUS diagnostic yield for AP etiological diagnosis was 79% (20% lithiasis, 31% acute on chronic pancreatitis, 14% pancreatic solid or cystic lesions, 5% pancreas divisum, 5% autoimmune pancreatitis, 5% ductal abnormalities), while 21% remained idiopathic. US, CECT and MRCP, taken alone or in combination, led to AP etiological diagnosis in 16 (20%) patients; among the remaining 65 patients, 49 (75%) obtained a diagnosis at EUS, with an overall EUS diagnostic gain of 61%. Sixty-eight patients had negative US; among them, EUS allowed etiological diagnosis in 59 (87%). Sixty-three patients had a negative CECT; among them, 47 (74%) obtained diagnosis with EUS. Twenty-four had a negative MRCP; among them, 20 (83%) had EUS diagnosis. Twenty-one had negative CT + MRCP, of which 17 (81%) had EUS diagnosis, with a EUS diagnostic gain of 63%. Patients with biliary etiology and without previous cholecystectomy had higher median values of alanine aminotransferase (154 *vs* 25, $P = 0.010$), aspartate aminotransferase (95 *vs* 29, $P = 0.018$), direct bilirubin (1.2 *vs* 0.6, $P = 0.015$), gamma-glutamyl transpeptidase (180 *vs* 48, $P = 0.006$) and alkaline phosphatase (150 *vs* 72, $P = 0.015$). Chronic pancreatitis diagnosis was more frequent in patients with recurrent pancreatitis at baseline (82% *vs* 21%, $P < 0.001$). During the follow-up, AP recurred in 3 patients, one of which remained idiopathic.

CONCLUSION

EUS is a good test to define AP etiology. It showed a 63% diagnostic gain over CECT + MRCP. In suitable patients, EUS should always be performed in cases of IAP. Further prospective studies are needed.

Key Words: Endoscopic ultrasound; Idiopathic acute pancreatitis; Diagnostic gain; Computed tomography; Magnetic resonance cholangiopancreatography

©The Author(s) 2022. Published by Baishideng Publishing Group Inc. All rights reserved.

Core Tip: Acute pancreatitis (AP) is a common and potentially severe disease. Imaging techniques allow an etiological diagnosis in most cases. However, about 20% of cases remain idiopathic, with negative consequences on patients' outcomes. Endoscopic ultrasound (EUS) has emerged as a valid technique for the assessment of AP etiology. We share our experience with EUS in the identification of idiopathic AP etiology, after failure of one or more cross-sectional imaging techniques. We found a superiority of EUS over the standard cross-sectional imaging techniques. We therefore suggest the use of EUS to define idiopathic AP etiology in all suitable patients.

Citation: Mazza S, Elvo B, Conti CB, Drago A, Verga MC, Soro S, De Silvestri A, Cereatti F, Grassia R. Endoscopic ultrasound diagnostic gain over computed tomography and magnetic resonance cholangiopancreatography in defining etiology of idiopathic acute pancreatitis. *World J Gastrointest Endosc* 2022; 14(6): 376-386

URL: <https://www.wjgnet.com/1948-5190/full/v14/i6/376.htm>

DOI: <https://dx.doi.org/10.4253/wjge.v14.i6.376>

INTRODUCTION

Acute pancreatitis (AP) is an inflammatory disorder characterized by the abnormal activation of digestive enzymes within the pancreatic gland. AP leads to the acute injury of the pancreas and may involve remote organs and systems. AP is one of the most common causes of hospitalization in the United States and Europe[1]. In most cases (about 80%), the prognosis is rapidly favorable[2]. Nevertheless, acute necrotizing pancreatitis may develop in up to 20% of cases, and it is associated with significant rates of early organ failure (38%), need for intervention (38%) and death (15%)[3].

The most common AP etiologies are common bile duct stones and alcohol abuse, accounting for about 60%-70% of all the cases[4]. Other etiologies include functional or anatomic lesions (pancreas divisum, pancreatic duct strictures/tumors, ampullary stenosis or sphincter of Oddi dysfunction), drugs, metabolic causes (hypertriglyceridemia, hypercalcemia), autoimmune disease, mechanical injury (*e.g.*, blunt abdominal trauma, postoperative), infections, ischemia, hereditary conditions and toxins[5].

AP etiology can be found in most cases by combining cross-sectional abdominal imaging techniques, such as ultrasound (US), contrast-enhanced computed tomography (CECT) and magnetic resonance cholangiopancreatography (MRCP). However, 10%-30% of AP remains idiopathic (IAP) after clinical, laboratory and imaging tests[6,7]. This is a relevant issue, as 20% of patients with IAP have recurrent episodes, and 20%-30% of them develop chronic pancreatitis[6]. In recent years, endoscopic US (EUS) has emerged as a useful tool for the etiological diagnosis of AP. A recent systematic review and meta-analysis demonstrated that EUS is able to identify a potential etiology in the majority of patients with IAP[8].

EUS has shown high diagnostic accuracy for the identification of microlithiasis missed at CECT scan or MRCP[9,10]. Moreover, in a smaller but relevant percentage of cases, EUS detected small pancreatic or ampullary lesions that were not identified at CECT or magnetic resonance imaging[11-13]. To date, few data are available about the role of EUS after failure of multiple cross-sectional imaging techniques and specifically evaluating the diagnostic gain of EUS in this setting. The present study aimed to evaluate the role of EUS in the assessment of IAP etiology when US, CECT and MRCP failed.

MATERIALS AND METHODS

Study population and data collection

We performed a retrospective, single-center study. We analyzed a database of consecutive adult patients prospectively enrolled between January 2017 and December 2020 to the Ospedale Maggiore of Cremona with a diagnosis of AP. The diagnosis of AP was made when 2 of 3 of the following criteria were met: abdominal pain consistent with pancreatitis; increased serum amylase or lipase levels, by at least 3 times the upper normal of limit; and characteristic findings on conventional radiologic methods (transabdominal US and/or CECT scan). MRCP was performed as a second-line technique after a negative US and/or CECT.

A thorough medical history and complete blood tests were collected for each patient at the clinical presentation. For final inclusion in the study analyses, the following criteria were ruled out: (1) History of alcohol or other toxic substance abuse; (2) Recent abdominal trauma; (3) Medications potentially related to AP; (4) Metabolic disorder like hypertriglyceridemia (≥ 1000 mg/dL) or hypercalcemia; (5) Clear etiology of AP identified at US, CECT or MRCP, without the need for further investigations; and (6) In the case of recurrent pancreatitis (*i.e.* ≥ 2 episodes of AP), a genetic cause was ruled out by testing for *CFTR*, *SPINK-1* and *PRSS1* mutations.

Therefore, the patients included in final analysis were those diagnosed with idiopathic acute pancreatitis (IAP), according to the American College of Gastroenterology guidelines[14].

All patients included in the study had undergone EUS after at least one US, CECT or MRCP test. Specifically, EUS was performed after a negative cross-sectional technique to investigate the AP etiology and after a positive exam to confirm a suspected diagnosis, to better characterize a lesion or to obtain biopsies.

After EUS examination, patients were followed up for at least 12 mo (median 31.5 mo, range 12-55), and recurrent episodes of acute pancreatitis were recorded.

The primary aim of the study was to evaluate the diagnostic gain of EUS in the identification of IAP etiology after failure of one or more previous cross-sectional exams. The secondary aims were: to assess the overall EUS diagnostic yield for IAP etiology; to compare the baseline clinical features with the IAP diagnosis; and to analyze the frequency and types of AP recurrence during the follow-up.

Endoscopic ultrasound

EUS examination was performed by 2 experienced operators (≥ 250 exams per year) using a linear echoendoscope (Pentax Medical EG3870UTK and EG38-J10UT), after informed consent had been obtained, with the patient in a left-side position under conscious sedation. EUS was mainly performed during admission after the acute phase of pancreatitis was clinically resolved, unless conditions such as persistent biliary obstruction required earlier evaluation. EUS was performed as an outpatient procedure in cases of mild pancreatitis with early patient discharge.

The examination was considered diagnostic with the following findings: biliary stones, criteria for chronic pancreatitis, presence of solid or cystic pancreatic lesions, pancreatobiliary duct abnormality, pancreas divisum, and features of autoimmune pancreatitis.

In detail: (1) Biliary etiology was diagnosed if stones or microlithiasis/biliary sludge were seen inside the gallbladder or the common bile duct. Biliary stones were defined as hyperechoic structures with an acoustic shadow, microlithiasis was defined as hyperechoic structures of 3 mm or less in diameter, and biliary sludge was defined as a hyperechoic material without an acoustic shadow[15]; (2) Chronic

pancreatitis was defined according to the Rosemont criteria[16]; (3) Duct abnormality was diagnosed if a long pancreatobiliary junction (> 15 mm) was identified[17]; (4) Pancreas divisum was described in the presence of a dominant dorsal duct with or without evidence of communication between the ventral and dorsal ducts, or if the main pancreatic duct could not be traced from the major papilla[18]; (5) Solid or cystic pancreatic lesions were considered as the cause of AP if obstruction of the pancreatic duct was seen at EUS examination; and (6) The diagnosis of autoimmune pancreatitis was made when parenchymal or ductal features were seen (*e.g.*, diffuse pancreas enlargement with delayed enhancement), and the International Consensus Diagnostic Criteria were met[19].

Statistical analysis

The categorical variables were described as absolute frequency and percentage. The continuous variables with normal distribution were described as mean \pm SD, whereas the continuous variables without normal distribution were given as median and range. Mann-Whitney test and ² or Fisher's exact tests were used to associate baseline clinical and biochemical variables with biliary pancreatitis. Diagnostic yield of EUS was calculated as the overall percentage of etiological diagnosis obtained through EUS examination. EUS diagnostic gain was calculated as the percentage of additional diagnoses obtained at EUS over the total number of patients undergoing US, CECT and/or MRCP. All the analyses were carried out by computer software IBM SPSS Statistics (release 25; IBM Corporation, United States).

RESULTS

Between March 2017 and December 2020, a total of 81 patients underwent EUS for IAP (38% female, mean age at enrollment 61 ± 18 years). Fifteen (23%) patients had previous cholecystectomy, whereas 49 (77%) had an intact gallbladder. First episode of AP was the indication of EUS in 52 (81%) patients, while 12 (19%) patients had recurrent pancreatitis (58% with one episode, 42% with 2 or more episodes). The median time interval between patient admission and EUS was 5 d (range, 2-27). All patients' demographic and clinical characteristics are summarized in Table 1.

Diagnostic yield of EUS and types of diagnosis

Overall, EUS led to an etiological diagnosis in 64 (79%) of the 81 patients. The diagnoses were as follows: 16 gallstone diseases, 25 acute on chronic pancreatitis, 4 pancreas divisum, 4 pancreatic duct anomalies, 11 solid or cystic lesions (4 pancreatic carcinomas with a maximum diameter of 15, 18, 20 and 24 mm; 2 ampullary adenomas of 8 and 13 mm; 5 branch-duct intraductal papillary mucinous neoplasms with high-risk stigmata or worrisome features) and 4 with criteria of autoimmune conditions. Example images of the main diagnosis obtained by EUS are shown in Figure 1. All patients underwent EUS and at least one exam with US, CECT and MRCP. The three cross-sectional techniques, alone or in combination, led to AP etiological diagnosis in 16 (20%) of the 81 patients. All diagnoses were confirmed at the following EUS. Among the remaining 65 patients, 49 (75%) obtained a diagnosis at EUS, with an overall EUS diagnostic gain of 61%.

US and EUS: Seventy-two (89%) patients underwent US, which allowed an etiological diagnosis in 4 (6%) cases. Among the 68 patients with a negative US, EUS allowed an etiological diagnosis in 59 (87%): 14 biliary pancreatitis, 25 acute on chronic pancreatitis, 2 pancreas divisum, 4 pancreatic duct anomalies, 10 solid or cystic lesions and 4 autoimmune conditions.

CECT and EUS: CECT scan was performed in 72 patients (89%), 9 of which (13%) resulted with an etiological diagnosis. Forty-seven (74%) out of the 63 patients with negative CECT obtained an etiological diagnosis at EUS: 10 lithiasis, 18 acute on chronic, 4 pancreas divisum, 4 duct anomalies, 9 solid/cystic lesions and 2 autoimmune pancreatitis.

MRCP and EUS: MRCP was performed in 32 patients, among which 8 (24%) obtained an etiological diagnosis. EUS allowed a diagnosis in 20 (83%) of the 24 patients with negative MRCP: 4 biliary etiology, 9 acute on chronic pancreatitis, 1 pancreas divisum, 1 pancreatic duct anomaly, 4 solid or cystic lesions and 1 autoimmune pancreatitis.

Diagnostic gain of EUS in cases of previous negative exams

US + CECT: A combination of US and CECT was performed in 63 patients (78%); of the 54 patients with missed diagnosis at both US and CECT, 45 (83%) received a diagnosis at EUS: 10 biliary etiology, 17 acute on chronic pancreatitis, 3 pancreas divisum, 4 pancreatic duct anomalies, 8 solid or cystic lesions and 3 autoimmune conditions. EUS diagnostic gain over US + CECT was 71%.

US + MRCP: A combination of US and MRCP was performed in 31 patients (38%); of the 23 US + MRCP missed diagnosis, 20 (87%) were identified at EUS: 4 biliary etiology, 9 acute flares on chronic pancreatitis, 1 pancreas divisum, 1 pancreatic duct anomalies, 4 solid or cystic lesions and 1 inflammatory-

Table 1 Demographic and clinical features of the 64 patients analyzed

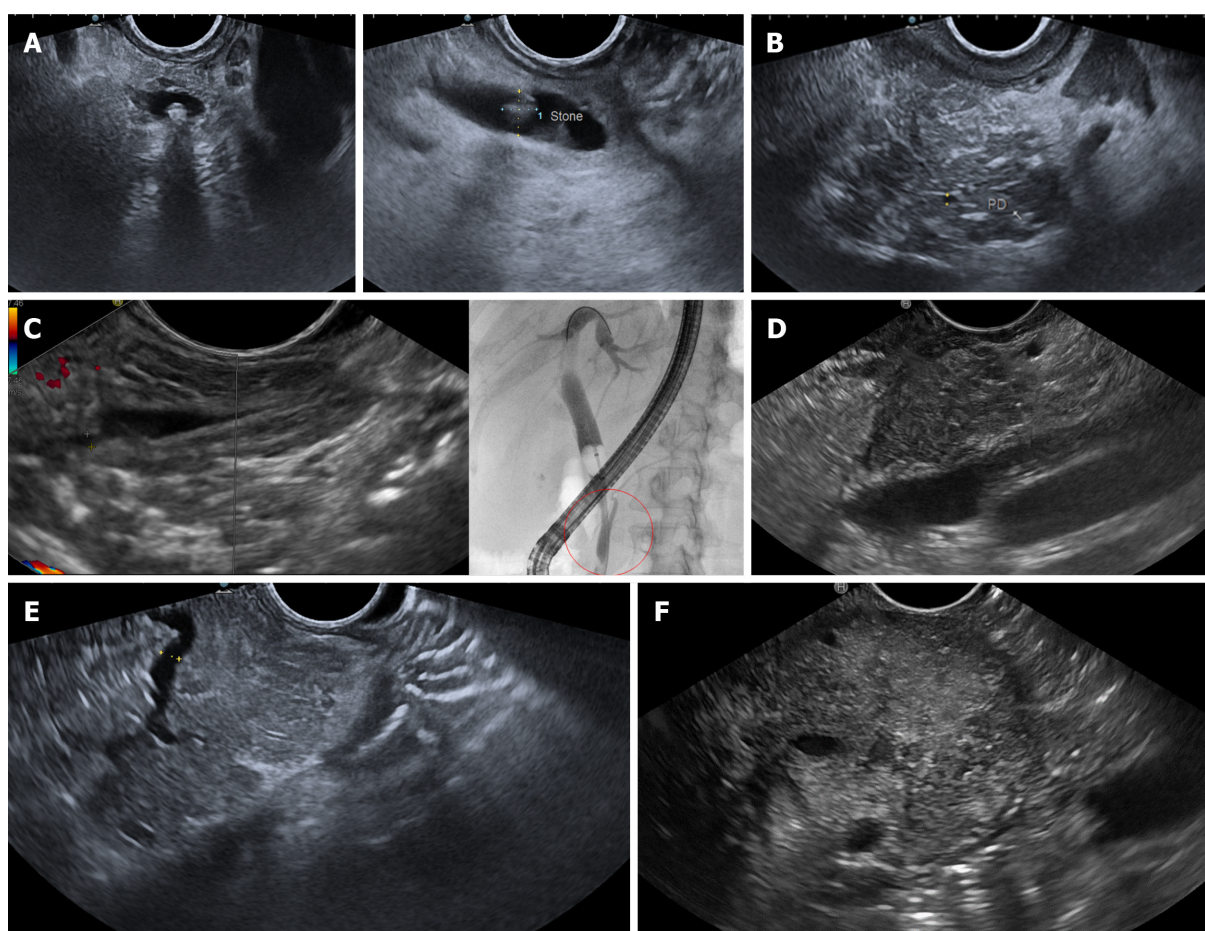
Parameter	n = 81	EUS diagnosis, n = 64	Missed EUS diagnosis, n = 17	P value
Male, n (%)	51 (63)	43 (67)	8 (46)	0.208
Age at enrollment, mean \pm SD, yr	61 \pm 18	62 \pm 18	59 \pm 16	
Previous cholecystectomy, n (%)	19 (23)	18 (28)	0	0.028
Recurrent pancreatitis, n (%)	14 (17)	14 (22)	0	0.101
One episode, n (%)	7 (9)			
≥ 2 episodes, n (%)	6 (7)			
Amylase, median (range)	468 (107-4988)	465 (123-4988)	500 (107-4753)	0.861
Lipase, median (range)	777 (87-23840)	774 (87-23840)	780 (96-12800)	0.914
Gamma-glutamyl transpeptidase, median (range)	70 (9-1665)	70 (9-1665)	125 (11-640)	0.707
Alkaline phosphatase, median (range)	78 (32877)	78 (32-877)	90 (32-185)	0.707
Direct bilirubin, median (range)	0.7 (0.2-8.5)	0.4 (0.2-3)	0.7 (0.2-8.5)	0.933
Alanine aminotransferase, median (range)	34 (6-793)	34 (6-793)	33 (7-596)	0.488
Aspartate aminotransferase, median (range)	38 (11-704)	34 (11-704)	33 (15-301)	0.732
Abdominal US, n (%)	72 (89)	63 (98)	9 (54)	< 0.001
Abdominal CECT, n (%)	72 (89)	56 (88)	16 (94)	1.000
MRCP, n (%)	32 (39)	28 (44)	4 (24)	0.220
EUS findings, n (%)		NA	NA	NA
Normal (final IAP diagnosis)	17 (21)			
Biliary	16 (20)			
Microlithiasis / biliary sludge	9 (11)			
Acute on chronic pancreatitis	25 (31)			
Solid or cystic lesions	11 (14)			
Pancreatic adenocarcinoma	4 (5)			
Ampullary adenoma	2 (3)			
BD-IPMN with high-risk stigmata or worrisome features	5 (6)			
Pancreas divisum	4 (5)			
Ductal anomaly	4 (5)			
Autoimmune criteria	4 (5)			

BD-IPMN: Branch-duct intraductal papillary mucinous neoplasms; CECT: Contrast enhanced computed tomography; IAP: Idiopathic acute pancreatitis; MRCP: Magnetic resonance cholangiopancreatography; SD: Standard deviation; US: Ultrasound; EUS: Endoscopic ultrasound; NA: Not available.

autoimmune condition. EUS diagnostic gain over US + MRCP was 65%.

CECT + MRCP: CECT and MRCP were both performed in 27 patients; of the 21 CECT + MRCP missed diagnoses, 17 (81%) were identified at EUS: 3 gallstone disease, 7 acute on chronic pancreatitis, 1 pancreas divisum, 1 pancreatic duct anomalies, 4 solid or cystic lesions and 1 autoimmune condition. EUS diagnostic gain over CECT + MRCP was 63%.

US + CECT + MRCP: Finally, 25 patients (31%) received all 3 cross-sectional techniques, without obtaining the AP etiological diagnosis in 19 cases; among them, EUS allowed a diagnosis in 17 (89%) cases: 3 gallstone disease, 7 acute on chronic pancreatitis, 1 pancreas divisum, 1 pancreatic duct anomalies, 4 solid or cystic lesions and 1 autoimmune condition. EUS diagnostic gain over US + CECT + MRCP was 68%.



DOI: 10.4253/wjge.v14.i6.376 Copyright ©The Author(s) 2022.

Figure 1 Illustrative images of the main etiological diagnoses of acute pancreatitis obtained by endoscopic ultrasound. A: Choledocholithiasis: endoscopic ultrasound (EUS) images of a small (3-4 mm) shadowing stone located in the distal common bile duct, obtained from the bulb (on the left) and descending duodenum (on the right) stations; B: Early chronic pancreatitis: EUS image showed a lobular pancreatic parenchyma with hyperechoic strands and foci, with hyperechoic margins of the Wirsung's duct, all of which are minor criteria for chronic pancreatitis; C: Anomalous pancreaticobiliary junction: EUS image from the descending duodenum showed the confluence of Wirsung's duct and common bile duct into a long (15 mm) common channel (on the left). The anomaly was then confirmed by retrograde cholangiopancreatography (on the right), also showing lithiasis of the distal part of the common channel; D: Pancreatic lesion: EUS image of a small (15 mm) solid lesion located in the pancreatic head; the lesion appeared hypoechoic and with irregular / infiltrating margins and comes close to the portal venous confluence. Histology confirmed a pancreatic adenocarcinoma; E: Pancreas divisum: EUS image from the descending duodenum showed a dominant dorsal pancreatic duct (PD), draining in the minor papilla; F: Autoimmune pancreatitis: EUS image showed a diffuse hypoechoic pancreatic enlargement, with hypoechoic parenchymal margins, at the level of the body (clearly visible the splenic vessels on the left). After contrast enhancement, the pancreas showed homogeneous early hypervascularization. Histology obtained by fine-needle biopsy revealed inflammatory infiltrates, excluding cancer.

The percentage of types of EUS diagnosis after the different exam combinations are shown in [Table 2](#).

Correlation between IAP diagnosis and clinical parameters

All patients without etiological diagnosis at EUS had no previous cholecystectomy compared to 28% with EUS diagnosis ($P = 0.028$). Patients with a final diagnosis of biliary pancreatitis had higher baseline median values of alanine aminotransferase (median value 154 *vs* 25, $P = 0.010$), aspartate aminotransferase (median value 95 *vs* 29, $P = 0.018$), direct bilirubin (median value 1.2 *vs* 0.6, $P = 0.015$), gamma-glutamyl transpeptidase (median value 180 *vs* 48, $P = 0.006$) and alkaline phosphatase (median value 150 *vs* 72, $P = 0.015$) compared to patients with non-biliary diagnosis. After differentiating between patients with or without previous cholecystectomy, these associations were maintained only for the non-cholecystectomy group. Noteworthy, when differentiating between first-episode and recurrent pancreatitis, chronic pancreatitis was the diagnosis at EUS in 21% and 82% of cases, respectively, a difference that was statistically significant ($P < 0.001$).

Etiology-based therapeutic intervention and follow-up data

During the follow-up, 12 out of the 16 patients diagnosed with biliary pancreatitis had evidence of choledocholithiasis; all of them underwent successful stone removal by endoscopic retrograde cholangiopancreatography (ERCP). Five out of the 25 patients with chronic pancreatitis underwent ERCP with pancreatic sphincterotomy (5/5) and pancreatic duct stenting (2/5) because of the evidence of

Table 2 Frequencies of acute pancreatitis etiologies at endoscopic ultrasound according to the type of previous negative exam/s

Type of AP etiology at EUS	Type of previous negative exam/s						
	US	CECT	MRCP	US + CECT	US + MRCP	CECT + MRCP	US + CECT + MRCP
Biliary; microlithiasis/biliary sludge	20%; 10%	16%; 5%	17%; 17%	19%; 7%	18%; 18%	14%; 14%	16%; 16%
Acute on chronic	37%	29%	38%	32%	39%	33%	37%
Solid or cystic lesions	15%	14%	17%	15%	18%	19%	21%
Pancreas divisum	3%	6%	4%	5%	4%	5%	5%
Anomalous pancreaticobiliary junction	6%	6%	4%	7%	4%	5%	5%
Autoimmune criteria	6%	3%	4%	5%	4%	5%	5%
Idiopathic	13%	26%	16%	17%	3%	9%	11%

AP: Acute pancreatitis; CECT: Contrast enhanced computed tomography; EUS: Endoscopic Ultrasound; MRCP: Magnetic resonance cholangiopancreatography; US: Ultrasound.

Wirsung's duct stenosis. Among the 11 patients with solid or cystic lesions as the cause of IAP, 4 were treated surgically, while the others were evaluated for a neoadjuvant or palliative approach. The 4 patients with features of autoimmune pancreatitis began steroid therapy with a good response.

During the follow-up time, a further episode of acute pancreatitis was observed in 3 patients (3.7%). Genetic tests for *CFTR*, *SPINK-1* and *PRSS1* mutations tested negative. All patients underwent EUS at recurrence. Two of these already had an EUS diagnosis of pancreas divisum and anomalous pancreaticobiliary junction that were confirmed. The other had been initially diagnosed as idiopathic pancreatitis, which remained idiopathic even after the EUS examination performed after recurrence.

DISCUSSION

Our study investigated the role of EUS in the etiological diagnosis of IAP. Overall, the diagnostic yield of EUS for the identification of AP etiology was 80%, with 20% of patients with a final IAP diagnosis, which is in line with previous literature data[20,21]. This result is in keeping with two previous published meta-analyses reporting that EUS can detect a cause in most patients with IAP[8,22]. We found a high diagnostic gain of EUS after all combinations of previous negative cross-sectional techniques; interestingly, diagnostic gain remained remarkably high even after the combination of CECT and MRCP. This result supports EUS as the technique of choice after a negative CECT if the patient is suitable for endoscopic examination, while MRCP could be reserved for patients at elevated risk for invasive procedures.

The most common etiologies identified at EUS were lithiasis, acute on chronic pancreatitis and solid or cystic lesions. All the lithiasis identified at EUS after MRCP were microlithiasis/biliary sludge of gallbladder or common bile duct compared with about half after CECT; this finding confirms the superiority of EUS over MRCP in the identification of lithiasis of small size, as reported previously[9,21-24]. An increase in transaminases is known to have a high positive predictive value for gallstone pancreatitis[25]. Interestingly, in our study, patients with biliary pancreatitis showed higher levels of liver enzymes as compared to other types of diagnosis but only in the group without previous cholecystectomy, while patients with previous cholecystectomy showed similar median values of liver enzymes. This result seems to identify patients without prior cholecystectomy and with increased transaminases as those at greatest risk of biliary pancreatitis and suggests that these patients could benefit from EUS as the first diagnostic test, eventually followed by ERCP in the same session if the diagnosis is confirmed[26-28].

Chronic pancreatitis was the most frequent diagnosis overall, with similar frequencies after all combinations of previous cross-sectional imaging techniques. This data is in line with the current evidence that EUS has the highest diagnostic performance in the identification of chronic pancreatitis features[29,30]. This is especially true in the setting of early chronic pancreatitis where thanks to the high resolution, EUS may detect subtle parenchymal and ductal changes such as irregular ductal contour, side branch ectasia ≥ 1 mm and parenchymal lobularity, which are minor diagnostic criteria according to the Rosemont criteria[31-34]. When differentiating between single episode or recurrent pancreatitis at baseline, diagnosis of chronic pancreatitis was much more frequent in patients with recurrent forms; this result supports the use of EUS as the first diagnostic technique for the identification of AP etiology in this subgroup of patients.

Regarding solid lesions, all pancreatic carcinomas missed at CECT were 25 mm or less in size. This data agrees with previous evidence showing a superiority of EUS over CECT for the diagnosis of small pancreatic lesions[35-38]. Interestingly, the percentage of solid lesions identified at EUS was similar in groups with or without previous MRCP, suggesting that this technique does not improve the ability to diagnose small pancreatic lesions. The identification of solid pancreatic lesions, as well as cholelithiasis or choledocholithiasis, not seen at previous examinations is of paramount importance since it significantly changes the patient management and particularly the referral to surgery or ERCP. This is especially true for small pancreatic cancers, which may be suitable for curative treatment. Most cystic lesions were instead diagnosed after US and/or CECT failure. Indeed, as already demonstrated, MRCP and EUS have comparable diagnostic accuracy for the assessment of cystic lesions[39], although EUS can better identify some high-risk or worrisome features such as enhancing mural nodules or thickened or enhancing cyst walls[40].

Pancreatic duct anomalies, including pancreas divisum and anomalous pancreaticobiliary junction, were diagnosed at EUS in about 10% of cases. This percentage was the same even after the combination of CECT and MRCP, corroborating a high sensitivity of EUS in obtaining a detailed study of the distal portion of the pancreatic duct, as already reported in the literature[41,42]. In the meta-analysis by Wan *et al*[22], EUS and MRCP were equally effective in identifying pancreas divisum, while MRCP after secretin stimulation was superior to both techniques. However, due to increased costs and practical issues, secretin-enhanced MRCP has failed to gain widespread United States use across radiology practices[43] and is not routinely performed in our center.

Incidence of further AP episodes during the follow-up was low (3%) and related to non-modifiable causes (one idiopathic form and one pancreatic duct anomaly). The endoscopic treatment of all choledocholithiasis, followed by cholecystectomy when necessary, and of chronic pancreatitis when indicated may have contributed to reducing the risk of pancreatitis recurrence.

The strengths of the study were the homogeneity of the population, the availability of detailed clinical information and the availability of a long follow-up period after the treatment approach. The main limitations were the small sample size and the retrospective nature of the study, with the need of prospective, multicentric studies in order to delineate a diagnostic algorithm that optimizes the use of EUS in AP.

CONCLUSION

In conclusion, our study supports the role of EUS as the technique of choice in IAP after failure of one or more cross-sectional techniques including CECT and MRCP. We suggest the use of EUS as the first-level technique in patients presenting with increased liver enzymes and with no previous cholecystectomy and in the setting of recurrent pancreatitis. Given its high diagnostic yield, we also propose EUS as the first-line investigation in all suitable patients presenting with IAP. Finally, larger and prospective studies investigating not only the diagnostic but also the prognostic value of EUS in IAP are needed.

ARTICLE HIGHLIGHTS

Research background

Idiopathic acute pancreatitis (IAP) is a common condition and represents a diagnostic challenge because up to 20% of patients with IAP have recurrent episodes and may evolve to chronic pancreatitis. Endoscopic ultrasound (EUS) is highly effective in the etiological diagnosis of IAP, even after failure of a previous imaging technique. A significant proportion of AP remains idiopathic even after multiple imaging techniques, mainly including abdominal US, contrast-enhanced computed tomography (CECT) and magnetic resonance cholangiopancreatography (MRCP).

Research motivation

The role of EUS in IAP has been established by multiple studies, including meta-analyses. However, limited data are currently available about the diagnostic gain of EUS in cases of failure of multiple previous imaging techniques.

Research objectives

The primary aim of the study was to evaluate the diagnostic gain of EUS after failure of US, CECT and MRCP and particularly after different combination of these techniques. The secondary aims were to assess the overall EUS diagnostic yield in IAP, to associate the baseline clinical features with the specific IAP diagnosis and to analyze the frequency and types of AP recurrence during the follow-up.

Research methods

We performed a retrospective, single-center study. We enrolled all consecutive adult patients undergoing EUS for IAP over a 3-year period at the Ospedale Maggiore of Cremona. IAP was defined when a clear etiology could not be identified after a thorough medical history, complete blood tests and after performing at least one US, CECT or MRCP exam. The EUS diagnostic gain was calculated as the percentage of additional diagnoses obtained at EUS over the total number of patients undergoing US, CECT and/or MRCP.

Research results

Overall EUS diagnostic yield was 79%, with 21% of AP remaining idiopathic. This percentage is in line with the current literature. Gallstone disease and chronic pancreatitis were the most frequent diagnoses (20% and 31%, respectively). The EUS diagnostic gain over the associations of CECT + MRCP and US + CECT + MRCP was 63% and 68%, respectively. This is a relevant result that confirms the superiority of EUS in the etiological diagnosis of IAP, particularly in detecting microlithiasis and early signs of chronic pancreatitis. In patients without a previous cholecystectomy and with a final diagnosis of biliary pancreatitis, higher baseline median values of liver enzymes were found. Moreover, in patients with recurrent pancreatitis, chronic pancreatitis was the diagnosis in 82% of cases. These results suggest a high efficacy of EUS in the etiological diagnosis of IAP in patients without previous cholecystectomy and with recurrent pancreatitis. During a median follow-up of 31.5 mo, an additional episode of pancreatitis was observed in 3.7% of patients.

Research conclusions

EUS has a high diagnostic yield in IAP. About two-thirds of patients with IAP without etiological diagnosis with various combinations of US, CECT and MRCP received a diagnosis at EUS. This finding confirms the superiority of EUS over these techniques and proposes EUS as the investigation of first choice in all suitable patients. EUS shows the highest diagnostic gain in the setting of increased liver enzymes with no previous cholecystectomy and in the setting of recurrent pancreatitis.

Research perspectives

The role of EUS in the etiological diagnosis of IAP has been established by multiple studies including meta-analyses. Our study provided additional data supporting the high diagnostic gain of EUS in cases of failure of multiple previous imaging techniques. Future research should focus on the prognostic value of EUS in the setting of IAP, since patient management may change following the EUS diagnosis. Large multicentric and prospective studies addressing this issue are needed.

FOOTNOTES

Author contributions: All authors contributed to literature search and data collect; Mazza S, Elvo B and Grassia R wrote the paper; Mazza S and De Silvestri A performed the statistical analysis; Conti CB, Drago A, Verga MC, Soro S and Cereatti F critically revised the paper and contributed to the final version of the manuscript.

Institutional review board statement: Approval by Ethics Committee of our Center was not required because of the retrospective nature of the study.

Informed consent statement: Patients were not required to give informed consent to the study because the analysis used anonymous clinical data that were obtained after each patient agreed to treatment by written consent.

Conflict-of-interest statement: All authors have no financial relationships to disclose.

Data sharing statement: No additional data are available.

Open-Access: This article is an open-access article that was selected by an in-house editor and fully peer-reviewed by external reviewers. It is distributed in accordance with the Creative Commons Attribution NonCommercial (CC BY-NC 4.0) license, which permits others to distribute, remix, adapt, build upon this work non-commercially, and license their derivative works on different terms, provided the original work is properly cited and the use is non-commercial. See: <https://creativecommons.org/licenses/by-nc/4.0/>

Country/Territory of origin: Italy

ORCID number: Stefano Mazza 0000-0002-9068-3209; Biagio Elvo 0000-0001-5695-0310; Clara Benedetta Conti 0000-0001-9774-2374; Andrea Drago 0000-0002-9777-8665; Maria Chiara Verga 0000-0001-6871-1229; Sara Soro 0000-0002-4802-8403; Annalisa De Silvestri 0000-0003-3128-8441; Fabrizio Cereatti 0000-0003-0628-4473; Roberto Grassia 0000-0003-4491-4050.

S-Editor: Wang LL

L-Editor: Filipodia

P-Editor: Wang LL

REFERENCES

- Petrov MS, Yadav D. Global epidemiology and holistic prevention of pancreatitis. *Nat Rev Gastroenterol Hepatol* 2019; **16**: 175-184 [PMID: 30482911 DOI: 10.1038/s41575-018-0087-5]
- Singh VK, Bollen TL, Wu BU, Repas K, Maurer R, Yu S, Morte KJ, Conwell DL, Banks PA. An assessment of the severity of interstitial pancreatitis. *Clin Gastroenterol Hepatol* 2011; **9**: 1098-1103 [PMID: 21893128 DOI: 10.1016/j.cgh.2011.08.026]
- van Santvoort HC, Bakker OJ, Bollen TL, Besselink MG, Ahmed Ali U, Schrijver AM, Boermeester MA, van Goor H, Dejong CH, van Eijck CH, van Ramshorst B, Schaapherder AF, van der Harst E, Hofker S, Nieuwenhuijs VB, Brink MA, Kruij PM, Manusama ER, van der Schelling GP, Karsten T, Hesselink EJ, van Laarhoven CJ, Rosman C, Bosscha K, de Wit RJ, Houdijk AP, Cuesta MA, Wahab PJ, Gooszen HG; Dutch Pancreatitis Study Group. A conservative and minimally invasive approach to necrotizing pancreatitis improves outcome. *Gastroenterology* 2011; **141**: 1254-1263 [PMID: 21741922 DOI: 10.1053/j.gastro.2011.06.073]
- Boxhoorn L, Voermans RP, Bouwense SA, Bruno MJ, Verdonk RC, Boermeester MA, van Santvoort HC, Besselink MG. Acute pancreatitis. *Lancet* 2020; **396**: 726-734 [PMID: 32891214 DOI: 10.1016/S0140-6736(20)31310-6]
- Guda NM, Trikudanathan G, Freeman ML. Idiopathic recurrent acute pancreatitis. *Lancet Gastroenterol Hepatol* 2018; **3**: 720-728 [PMID: 30215363 DOI: 10.1016/S2468-1253(18)30211-5]
- Levy MJ, Geenen JE. Idiopathic acute recurrent pancreatitis. *Am J Gastroenterol* 2001; **96**: 2540-2555 [PMID: 11569674 DOI: 10.1111/j.1572-0241.2001.04098.x]
- Steinberg W, Tenner S. Acute pancreatitis. *N Engl J Med* 1994; **330**: 1198-1210 [PMID: 7811319 DOI: 10.1056/NEJM199404283301706]
- Umans DS, Ranguti CK, Sperna Weiland CJ, Timmerhuis HC, Bouwense SAW, Fockens P, Besselink MG, Verdonk RC, van Hooft JE; Dutch Pancreatitis Study Group. Endoscopic ultrasonography can detect a cause in the majority of patients with idiopathic acute pancreatitis: a systematic review and meta-analysis. *Endoscopy* 2020; **52**: 955-964 [PMID: 32557477 DOI: 10.1055/a-1183-3370]
- Kondo S, Isayama H, Akahane M, Toda N, Sasahira N, Nakai Y, Yamamoto N, Hirano K, Komatsu Y, Tada M, Yoshida H, Kawabe T, Ohtomo K, Omata M. Detection of common bile duct stones: comparison between endoscopic ultrasonography, magnetic resonance cholangiography, and helical-computed-tomographic cholangiography. *Eur J Radiol* 2005; **54**: 271-275 [PMID: 15837409 DOI: 10.1016/j.ejrad.2004.07.007]
- Smith I, Ramesh J, Kyanam Kabir Baig KR, Mönkemüller K, Wilcox CM. Emerging Role of Endoscopic Ultrasound in the Diagnostic Evaluation of Idiopathic Pancreatitis. *Am J Med Sci* 2015; **350**: 229-234 [PMID: 26252794 DOI: 10.1097/MAJ.0000000000000541]
- Valverde-López F, Ortega-Suazo EJ, Wilcox CM, Fernandez-Cano MC, Martínez-Cara JG, Redondo-Cerezo E. Endoscopic ultrasound as a diagnostic and predictive tool in idiopathic acute pancreatitis. *Ann Gastroenterol* 2020; **33**: 305-312 [PMID: 32382235 DOI: 10.20524/aog.2020.0464]
- Tepox-Padrón A, Bernal-Mendez RA, Duarte-Medrano G, Romano-Munive AF, Mairena-Valle M, Ramírez-Luna MÁ, Marroquin-Reyes JD, Uscanga L, Chan C, Domínguez-Rosado I, Hernández-Calleros J, Peláez-Luna M, Tellez-Avila F. Utility of endoscopic ultrasound in idiopathic acute recurrent pancreatitis. *BMJ Open Gastroenterol* 2021; **8** [PMID: 33402380 DOI: 10.1136/bmjgast-2020-000538]
- Somani P, Sunkara T, Sharma M. Role of endoscopic ultrasound in idiopathic pancreatitis. *World J Gastroenterol* 2017; **23**: 6952-6961 [PMID: 29097868 DOI: 10.3748/wjg.v23.i38.6952]
- Tenner S, Baillie J, DeWitt J, Vege SS, Gastroenterology ACo. American College of Gastroenterology guideline: management of acute pancreatitis. *Am J Gastroenterol* 2013; **108**: 1400-1415 [DOI: 10.1038/ajg.2013.218]
- Diehl AK, Holleman DR Jr, Chapman JB, Schwesinger WH, Kurtin WE. Gallstone size and risk of pancreatitis. *Arch Intern Med* 1997; **157**: 1674-1678 [PMID: 9250228]
- Catalano MF, Sahai A, Levy M, Romagnuolo J, Wiersema M, Brugge W, et al EUS-based criteria for the diagnosis of chronic pancreatitis: the Rosemont classification. *Gastrointest Endosc* 2009; **69**: 1251-1261 [DOI: 10.1016/j.gie.2008.07.043]
- Vila JJ. Endoscopic ultrasonography and idiopathic acute pancreatitis. *World J Gastrointest Endosc* 2010; **2**: 107-111 [PMID: 21160725 DOI: 10.4253/wjge.v2.i4.107]
- Lai R, Freeman ML, Cass OW, Mallory S. Accurate diagnosis of pancreas divisum by linear-array endoscopic ultrasonography. *Endoscopy* 2004; **36**: 705-709 [PMID: 15280976 DOI: 10.1055/s-2004-825663]
- Shimosegawa T, Chari ST, Frulloni L, Kamisawa T, Kawa S, Mino-Kenudson M, Kim MH, Klöppel G, Lerch MM, Löhr M, Notohara K, Okazaki K, Schneider A, Zhang L; International Association of Pancreatology. International consensus diagnostic criteria for autoimmune pancreatitis: guidelines of the International Association of Pancreatology. *Pancreas* 2011; **40**: 352-358 [PMID: 21412117 DOI: 10.1097/MPA.0b013e3182142fd2]
- Norton SA, Alderson D. Endoscopic ultrasonography in the evaluation of idiopathic acute pancreatitis. *Br J Surg* 2000; **87**: 1650-1655 [PMID: 11122178 DOI: 10.1046/j.1365-2168.2000.01587.x]
- Vila JJ, Vicuña M, Irisarri R, de la Higuera BG, Ruiz-Clavijo D, Rodríguez-Gutiérrez C, Urman JM, Bolado F, Jiménez FJ, Arin A. Diagnostic yield and reliability of endoscopic ultrasonography in patients with idiopathic acute pancreatitis. *Scand J Gastroenterol* 2010; **45**: 375-381 [PMID: 20034361 DOI: 10.3109/00365520903508894]
- Wan J, Ouyang Y, Yu C, Yang X, Xia L, Lu N. Comparison of EUS with MRCP in idiopathic acute pancreatitis: a systematic review and meta-analysis. *Gastrointest Endosc* 2018; **87**: 1180-1188.e9 [PMID: 29225082 DOI: 10.1016/j.gie.2017.11.028]

- 23 **Ortega AR**, Gómez-Rodríguez R, Romero M, Fernández-Zapardiel S, Céspedes MeM, Carrobbles JM. Prospective comparison of endoscopic ultrasonography and magnetic resonance cholangiopancreatography in the etiological diagnosis of "idiopathic" acute pancreatitis. *Pancreas* 2011; **40**: 289-294 [DOI: [10.1097/mpa.0b013e318201654a](https://doi.org/10.1097/mpa.0b013e318201654a)]
- 24 **Meeralam Y**, Al-Shammari K, Yaghoobi M. Diagnostic accuracy of EUS compared with MRCP in detecting choledocholithiasis: a meta-analysis of diagnostic test accuracy in head-to-head studies. *Gastrointest Endosc* 2017; **86**: 986-993 [PMID: [28645544](https://pubmed.ncbi.nlm.nih.gov/28645544/) DOI: [10.1016/j.gie.2017.06.009](https://doi.org/10.1016/j.gie.2017.06.009)]
- 25 **Whitcomb DC**. Clinical practice. Acute pancreatitis. *N Engl J Med* 2006; **354**: 2142-2150 [PMID: [16707751](https://pubmed.ncbi.nlm.nih.gov/16707751/) DOI: [10.1056/NEJMcp054958](https://doi.org/10.1056/NEJMcp054958)]
- 26 **Vila JJ**, Kutz M, Goñi S, Ostiz M, Amorena E, Prieto C, et al Endoscopic and anesthetic feasibility of EUS and ERCP combined in a single session vs two different sessions. *World J Gastrointest Endosc* 2011; **3**: 57-61 [DOI: [10.4253/wjge.v3.i3.57](https://doi.org/10.4253/wjge.v3.i3.57)]
- 27 **Benjaminov F**, Stein A, Lichtman G, Pomeranz I, Konikoff FM. Consecutive vs separate sessions of endoscopic ultrasound (EUS) and endoscopic retrograde cholangiopancreatography (ERCP) for symptomatic choledocholithiasis. *Surg Endosc* 2013; **27**: 2117-2121 [PMID: [23389062](https://pubmed.ncbi.nlm.nih.gov/23389062/) DOI: [10.1007/s00464-012-2720-7](https://doi.org/10.1007/s00464-012-2720-7)]
- 28 **Fabbri C**, Polifemo AM, Luigiano C, Cennamo V, Fuccio L, Billi P, Maimone A, Ghersi S, Macchia S, Mwangemi C, Consolo P, Zirilli A, Eusebi LH, D'Imperio N. Single session vs separate session endoscopic ultrasonography plus endoscopic retrograde cholangiography in patients with low to moderate risk for choledocholithiasis. *J Gastroenterol Hepatol* 2009; **24**: 1107-1112 [PMID: [19638088](https://pubmed.ncbi.nlm.nih.gov/19638088/) DOI: [10.1111/j.1440-1746.2009.05828.x](https://doi.org/10.1111/j.1440-1746.2009.05828.x)]
- 29 **Issa Y**, Kempeneers MA, van Santvoort HC, Bollen TL, Bipat S, Boermeester MA. Diagnostic performance of imaging modalities in chronic pancreatitis: a systematic review and meta-analysis. *Eur Radiol* 2017; **27**: 3820-3844 [PMID: [28130609](https://pubmed.ncbi.nlm.nih.gov/28130609/) DOI: [10.1007/s00330-016-4720-9](https://doi.org/10.1007/s00330-016-4720-9)]
- 30 **Pungpapong S**, Wallace MB, Woodward TA, Noh KW, Raimondo M. Accuracy of endoscopic ultrasonography and magnetic resonance cholangiopancreatography for the diagnosis of chronic pancreatitis: a prospective comparison study. *J Clin Gastroenterol* 2007; **41**: 88-93 [DOI: [10.1097/mcg.0b013e31802dfde6](https://doi.org/10.1097/mcg.0b013e31802dfde6)]
- 31 **Stevens T**, Parsi MA. Endoscopic ultrasound for the diagnosis of chronic pancreatitis. *World J Gastroenterol* 2010; **16**: 2841-2850 [DOI: [10.3748/wjg.v16.i23.2841](https://doi.org/10.3748/wjg.v16.i23.2841)]
- 32 **Takasaki Y**, Ishii S, Fujisawa T, Ushio M, Takahashi S, Yamagata W, Ito K, Suzuki A, Ochiai K, Tomishima K, Saito H, Isayama H. Endoscopic Ultrasonography Findings of Early and Suspected Early Chronic Pancreatitis. *Diagnostics (Basel)* 2020; **10** [PMID: [33261170](https://pubmed.ncbi.nlm.nih.gov/33261170/) DOI: [10.3390/diagnostics10121018](https://doi.org/10.3390/diagnostics10121018)]
- 33 **Dominguez-Munoz JE**, Drewes AM, Lindkvist B, Ewald N, Czako L, Rosendahl J, Löhr JM; HaPanEU/UEG Working Group. Recommendations from the United European Gastroenterology evidence-based guidelines for the diagnosis and therapy of chronic pancreatitis. *Pancreatol* 2018; **18**: 847-854 [PMID: [30344091](https://pubmed.ncbi.nlm.nih.gov/30344091/) DOI: [10.1016/j.pan.2018.09.016](https://doi.org/10.1016/j.pan.2018.09.016)]
- 34 **Kamat R**, Gupta P, Rana S. Imaging in chronic pancreatitis: State of the art review. *Indian J Radiol Imaging* 2019; **29**: 201-210 [PMID: [31367093](https://pubmed.ncbi.nlm.nih.gov/31367093/) DOI: [10.4103/ijri.IJRI_484_18](https://doi.org/10.4103/ijri.IJRI_484_18)]
- 35 **DeWitt J**, Devereaux B, Chriswell M, McGreevy K, Howard T, Imperiale TF, Ciaccia D, Lane KA, Maglinte D, Kopecky K, LeBlanc J, McHenry L, Madura J, Aisen A, Cramer H, Cummings O, Sherman S. Comparison of endoscopic ultrasonography and multidetector computed tomography for detecting and staging pancreatic cancer. *Ann Intern Med* 2004; **141**: 753-763 [PMID: [15545675](https://pubmed.ncbi.nlm.nih.gov/15545675/) DOI: [10.7326/0003-4819-141-10-200411160-00006](https://doi.org/10.7326/0003-4819-141-10-200411160-00006)]
- 36 **Michl P**, Pauls S, Gress TM. Evidence-based diagnosis and staging of pancreatic cancer. *Best Pract Res Clin Gastroenterol* 2006; **20**: 227-251 [PMID: [16549326](https://pubmed.ncbi.nlm.nih.gov/16549326/) DOI: [10.1016/j.bpg.2005.10.005](https://doi.org/10.1016/j.bpg.2005.10.005)]
- 37 **Yasuda K**, Mukai H, Nakajima M. Endoscopic ultrasonography diagnosis of pancreatic cancer. *Gastrointest Endosc Clin N Am* 1995; **5**: 699-712 [PMID: [8535618](https://pubmed.ncbi.nlm.nih.gov/8535618/)]
- 38 **Bronstein YL**, Loyer EM, Kaur H, Choi H, David C, DuBrow RA, Broemeling LD, Cleary KR, Charnsangavej C. Detection of small pancreatic tumors with multiphasic helical CT. *AJR Am J Roentgenol* 2004; **182**: 619-623 [PMID: [14975959](https://pubmed.ncbi.nlm.nih.gov/14975959/) DOI: [10.2214/ajr.182.3.1820619](https://doi.org/10.2214/ajr.182.3.1820619)]
- 39 **Kim YC**, Choi JY, Chung YE, Bang S, Kim MJ, Park MS, Kim KW. Comparison of MRI and endoscopic ultrasound in the characterization of pancreatic cystic lesions. *AJR Am J Roentgenol* 2010; **195**: 947-952 [PMID: [20858823](https://pubmed.ncbi.nlm.nih.gov/20858823/) DOI: [10.2214/AJR.09.3985](https://doi.org/10.2214/AJR.09.3985)]
- 40 **Lu X**, Zhang S, Ma C, Peng C, Lv Y, Zou X. The diagnostic value of EUS in pancreatic cystic neoplasms compared with CT and MRI. *Endosc Ultrasound* 2015; **4**: 324-329 [PMID: [26643701](https://pubmed.ncbi.nlm.nih.gov/26643701/) DOI: [10.4103/2303-9027.170425](https://doi.org/10.4103/2303-9027.170425)]
- 41 **Shen Z**, Munker S, Zhou B, Li L, Yu C, Li Y. The Accuracies of Diagnosing Pancreas Divisum by Magnetic Resonance Cholangiopancreatography and Endoscopic Ultrasound: A Systematic Review and Meta-analysis. *Sci Rep* 2016; **6**: 35389 [PMID: [27734952](https://pubmed.ncbi.nlm.nih.gov/27734952/) DOI: [10.1038/srep35389](https://doi.org/10.1038/srep35389)]
- 42 **Kushnir VM**, Wani SB, Fowler K, Menias C, Varma R, Narra V, et al Sensitivity of endoscopic ultrasound, multidetector computed tomography, and magnetic resonance cholangiopancreatography in the diagnosis of pancreas divisum: a tertiary center experience. *Pancreas* 2013; **42**: 436-441 [DOI: [10.1097/mpa.0b013e31826c711a](https://doi.org/10.1097/mpa.0b013e31826c711a)]
- 43 **Swensson J**, Zaheer A, Conwell D, Sandrasegaran K, Manfredi R, Tirkes T. Secretin-Enhanced MRCP: How and Why-*AJR Expert Panel Narrative Review*. *AJR Am J Roentgenol* 2021; **216**: 1139-1149 [PMID: [33263419](https://pubmed.ncbi.nlm.nih.gov/33263419/) DOI: [10.2214/AJR.20.24857](https://doi.org/10.2214/AJR.20.24857)]



Published by **Baishideng Publishing Group Inc**
7041 Koll Center Parkway, Suite 160, Pleasanton, CA 94566, USA

Telephone: +1-925-3991568

E-mail: bpgoffice@wjgnet.com

Help Desk: <https://www.f6publishing.com/helpdesk>

<https://www.wjgnet.com>

