

World Journal of *Gastrointestinal Endoscopy*

World J Gastrointest Endosc 2022 June 16; 14(6): 354-415



MINIREVIEWS

- 354 Role of endoscopic ultrasound in vascular interventions: Where are we now?
Fugazza A, Khalaf K, Colombo M, Carrara S, Spadaccini M, Koleth G, Troncone E, Maselli R, Repici A, Anderloni A

ORIGINAL ARTICLE**Retrospective Study**

- 367 Pediatric endoscopy across multiple clinical settings: Efficiency and adverse events
Crawford E, Sabe R, Sferra TJ, Apperson-Hansen C, Khalili AS
- 376 Endoscopic ultrasound diagnostic gain over computed tomography and magnetic resonance cholangiopancreatography in defining etiology of idiopathic acute pancreatitis
Mazza S, Elvo B, Conti CB, Drago A, Verga MC, Soro S, De Silvestri A, Cereatti F, Grassia R
- 387 Change point analysis validation of the learning curve in laparoscopic colorectal surgery: Experience from a non-structured training setting
Perivoliotis K, Baloyiannis I, Mamaloudis I, Volakakis G, Valaroutsos A, Tzovaras G

Observational Study

- 402 Role of endoscopic ultrasound and cyst fluid tumor markers in diagnosis of pancreatic cystic lesions
Okasha HH, Abdellatef A, Elkholy S, Mogawer MS, Yosry A, Elserafy M, Medhat E, Khalaf H, Fouad M, Elbaz T, Ramadan A, Behiry ME, Y William K, Habib G, Kaddah M, Abdel-Hamid H, Abou-Elmagd A, Galal A, Abbas WA, Altonbary AY, El-Ansary M, Abdou AE, Haggag H, Abdallah TA, Elfeki MA, Faheem HA, Khattab HM, El-Ansary M, Beshir S, El-Nady M

ABOUT COVER

Editor-in-Chief of *World Journal of Gastrointestinal Endoscopy*, Joo Young Cho, MD, PhD, Chairman, Director, Full Professor, Senior Editor, Department of Gastroenterology, Cha Gangnam Medical Center, Cha University College of Medicine, Seoul 06135, South Korea. cjy6695@naver.com

AIMS AND SCOPE

The primary aim of *World Journal of Gastrointestinal Endoscopy* (WJGE, *World J Gastrointest Endosc*) is to provide scholars and readers from various fields of gastrointestinal endoscopy with a platform to publish high-quality basic and clinical research articles and communicate their research findings online.

WJGE mainly publishes articles reporting research results and findings obtained in the field of gastrointestinal endoscopy and covering a wide range of topics including capsule endoscopy, colonoscopy, double-balloon enteroscopy, duodenoscopy, endoscopic retrograde cholangiopancreatography, endosonography, esophagoscopy, gastrointestinal endoscopy, gastroscopy, laparoscopy, natural orifice endoscopic surgery, proctoscopy, and sigmoidoscopy.

INDEXING/ABSTRACTING

The WJGE is now abstracted and indexed in Emerging Sources Citation Index (Web of Science), PubMed, PubMed Central, Reference Citation Analysis, China National Knowledge Infrastructure, China Science and Technology Journal Database, and Superstar Journals Database. The 2022 edition of Journal Citation Reports® cites the 2021 Journal Citation Indicator (JCI) for WJGE as 0.33.

RESPONSIBLE EDITORS FOR THIS ISSUE

Production Editor: Yi-Xuan Cai; Production Department Director: Xu Guo; Editorial Office Director: Jia-Ping Yan.

NAME OF JOURNAL

World Journal of Gastrointestinal Endoscopy

ISSN

ISSN 1948-5190 (online)

LAUNCH DATE

October 15, 2009

FREQUENCY

Monthly

EDITORS-IN-CHIEF

Sang Chul Lee, Bing Hu, Anastasios Koulaouzidis, Joo Young Cho

EDITORIAL BOARD MEMBERS

<https://www.wjgnet.com/1948-5190/editorialboard.htm>

PUBLICATION DATE

June 16, 2022

COPYRIGHT

© 2022 Baishideng Publishing Group Inc

INSTRUCTIONS TO AUTHORS

<https://www.wjgnet.com/bpg/gerinfo/204>

GUIDELINES FOR ETHICS DOCUMENTS

<https://www.wjgnet.com/bpg/gerinfo/287>

GUIDELINES FOR NON-NATIVE SPEAKERS OF ENGLISH

<https://www.wjgnet.com/bpg/gerinfo/240>

PUBLICATION ETHICS

<https://www.wjgnet.com/bpg/gerinfo/288>

PUBLICATION MISCONDUCT

<https://www.wjgnet.com/bpg/gerinfo/208>

ARTICLE PROCESSING CHARGE

<https://www.wjgnet.com/bpg/gerinfo/242>

STEPS FOR SUBMITTING MANUSCRIPTS

<https://www.wjgnet.com/bpg/gerinfo/239>

ONLINE SUBMISSION

<https://www.f6publishing.com>



Observational Study

Role of endoscopic ultrasound and cyst fluid tumor markers in diagnosis of pancreatic cystic lesions

Hussein Hassan Okasha, Abeer Abdellatef, Shaimaa Elkholy, Mohamad-Sherif Mogawer, Ayman Yosry, Magdy Elserafy, Eman Medhat, Hanaa Khalaf, Magdy Fouad, Tamer Elbaz, Ahmed Ramadan, Mervat E Behiry, Kerolis Y William, Ghada Habib, Mona Kaddah, Haitham Abdel-Hamid, Amr Abou-Elmagd, Ahmed Galal, Wael A Abbas, Ahmed Youssef Altonbary, Mahmoud El-Ansary, Aml E Abdou, Hani Haggag, Tarek Ali Abdallah, Mohamed A Elfeki, Heba Ahmed Faheem, Hani M Khattab, Mervat El-Ansary, Safia Beshir, Mohamed El-Nady

Specialty type: Medicine, general and internal

Provenance and peer review: Invited article; Externally peer reviewed.

Peer-review model: Single blind

Peer-review report's scientific quality classification

Grade A (Excellent): 0
Grade B (Very good): B
Grade C (Good): 0
Grade D (Fair): D, D
Grade E (Poor): 0

P-Reviewer: Jin ZD, China; Paiella S, Italy; Poddymova AV, Russia

Received: October 22, 2021

Peer-review started: October 22, 2021

First decision: November 15, 2021

Revised: November 28, 2021

Accepted: May 5, 2022

Article in press: May 5, 2022

Published online: June 16, 2022



Hussein Hassan Okasha, Abeer Abdellatef, Shaimaa Elkholy, Mohamad-Sherif Mogawer, Kerolis Y William, Hani Haggag, Mohamed El-Nady, Department of Internal Medicine and Hepatogastroenterology, Kasr Al-Aini Hospitals, Cairo University, Kasr Al-Aini Hospitals, Cairo University, Cairo 11451, Egypt

Ayman Yosry, Magdy Elserafy, Eman Medhat, Tamer Elbaz, Ahmed Ramadan, Ghada Habib, Mona Kaddah, Department of Endemic Diseases, Cairo University, Cairo 11451, Egypt

Hanaa Khalaf, Magdy Fouad, Haitham Abdel-Hamid, Department of Tropical Medicine and Gastroenterology, Minia University, Minia 61511, Egypt

Mervat E Behiry, Department of Internal Medicine, Kasr Al-Aini Hospitals, Cairo University, Cairo 11562, Egypt

Amr Abou-Elmagd, Department of Gastroenterology, Armed forces College of Medicine, Cairo 11451, Egypt

Ahmed Galal, Endoscopy and Internal Medicine Consultant at Dr/Ahmed Galal Endoscopy Center, Alexandria 35516, Egypt

Wael A Abbas, Department of Internal Medicine, Faculty of Medicine, Assuit University, Assuit 71111, Egypt

Ahmed Youssef Altonbary, Department of Gastroenterology and Hepatology, Mansoura University, Mansoura 35511, Egypt

Mahmoud El-Ansary, Department of Gastroenterology and Hepatology, Theodor Bilharz Research Institute, Cairo 11451, Egypt

Aml E Abdou, Department of Microbiology and Immunology, Faculty of Medicine for girls Al-Azhar University, Cairo 11451, Egypt

Tarek Ali Abdallah, Heba Ahmed Faheem, Department of Internal Medicine, Faculty of Medicine, Ain shams University, Cairo 11451, Egypt

Mohamed A Elfeki, Department of Internal Medicine, Bani-suef University, Bani-suef, Bani-suef 62511, Egypt

Hani M Khattab, Department of Pathology, Faculty of Medicine, Cairo University, Cairo 11451, Egypt

Mervat El-Ansary, Department of Clinical Pathology, Faculty of Medicine, Cairo University, Cairo 11451, Egypt

Safia Beshir, Department of Environmental Medicine & Clinical Pathology, National Research Centre, Cairo 11451, Egypt

Corresponding author: Abeer Abdellatef, MD, Lecturer, Department of Internal Medicine and Hepatogastroenterology, Kasr Al-Aini Hospitals, Cairo University, Kasr Al-Aini Hospitals, Cairo University, PO 11451, Kasr Al-Aini Street, Cairo 11451, Egypt. beero4a@yahoo.com

Abstract

BACKGROUND

Pancreatic cystic lesions (PCLs) are common in clinical practice. The accurate classification and diagnosis of these lesions are crucial to avoid unnecessary treatment of benign lesions and missed opportunities for early treatment of potentially malignant lesions.

AIM

To evaluate the role of cyst fluid analysis of different tumor markers such as cancer antigens [*e.g.*, cancer antigen (CA)19-9, CA72-4], carcinoembryonic antigen (CEA), serine protease inhibitor Kazal-type 1 (SPINK1), interleukin 1 beta (IL1-β), vascular endothelial growth factor A (VEGF-A), and prostaglandin E2 (PGE2)], amylase, and mucin stain in diagnosing pancreatic cysts and differentiating malignant from benign lesions.

METHODS

This study included 76 patients diagnosed with PCLs using different imaging modalities. All patients underwent endoscopic ultrasound (EUS) and EUS-fine needle aspiration (EUS-FNA) for characterization and sampling of different PCLs.

RESULTS

The mean age of studied patients was 47.4 ± 11.4 years, with a slight female predominance (59.2%). Mucin stain showed high statistical significance in predicting malignancy with a sensitivity of 87.1% and specificity of 95.56%. It also showed a positive predictive value and negative predictive value of 93.1% and 91.49%, respectively ($P < 0.001$). We found that positive mucin stain, cyst fluid glucose, SPINK1, amylase, and CEA levels had high statistical significance ($P < 0.0001$). In contrast, IL-1β, CA 72-4, VEGF-A, VEGFR2, and PGE2 did not show any statistical significance. Univariate regression analysis for prediction of malignancy in PCLs showed a statistically significant positive correlation with mural nodules, lymph nodes, cyst diameter, mucin stain, and cyst fluid CEA. Meanwhile, logistic multivariable regression analysis proved that mural nodules, mucin stain, and SPINK1 were independent predictors of malignancy in cystic pancreatic lesions.

CONCLUSION

EUS examination of cyst morphology with cytopathological analysis and cyst fluid analysis could improve the differentiation between malignant and benign pancreatic cysts. Also, CEA, glucose, and SPINK1 could be used as promising markers to predict malignant pancreatic cysts.

Key Words: Pancreatic cystic neoplasm; Mucinous cystic neoplasm; Intraductal papillary mucinous neoplasm; Mucin stain; Amylase

©The Author(s) 2022. Published by Baishideng Publishing Group Inc. All rights reserved.

Core Tip: Nowadays, the awareness of pancreatic cystic lesions has become an essential issue, especially with the increased incidence of asymptomatic pancreatic cysts in the general population. Therefore, the proper diagnosis, meticulous differentiation, and staging of these pancreatic cystic lesions are crucial for proper management and avoiding unnecessary treatment of benign lesions and missing early treatment of the malignant/pre-malignant lesions. Endoscopic ultrasound examination of cyst morphology with cytopathological and chemical analysis and cyst fluid analysis could improve the diagnostic capability. Also, many developed markers are valuable for predicting a malignant pancreatic cyst.

Citation: Okasha HH, Abdellatef A, Elkholy S, Mogawer MS, Yosry A, Elserafy M, Medhat E, Khalaf H, Fouad M, Elbaz T, Ramadan A, Behiry ME, Y William K, Habib G, Kaddah M, Abdel-Hamid H, Abou-Elmagd A, Galal A, Abbas WA, Altonbary AY, El-Ansary M, Abdou AE, Haggag H, Abdallah TA, Elfeki MA, Faheem HA, Khattab HM, El-Ansary M, Beshir S, El-Nady M. Role of endoscopic ultrasound and cyst fluid tumor markers in diagnosis of pancreatic cystic lesions. *World J Gastrointest Endosc* 2022; 14(6): 402-415

URL: <https://www.wjgnet.com/1948-5190/full/v14/i6/402.htm>

DOI: <https://dx.doi.org/10.4253/wjge.v14.i6.402>

INTRODUCTION

Pancreatic cystic lesions (PCLs) are not rare; they vary from a simple benign cyst to a highly malignant one[1]. Awareness of these lesions has increased in recent years, especially with the increased incidence of asymptomatic pancreatic cysts in the general population primarily due to improved detection by different advanced imaging modalities[2,3]. Therefore, the proper diagnosis, meticulous differentiation, and staging of these PCLs are crucial for proper management and avoiding unnecessary treatment of benign lesions and missing early treatment of the malignant/pre-malignant lesions[4,5].

Endoscopic ultrasound (EUS) has become an indispensable tool for diagnosing many pancreatic lesions; it has a benefit for better evaluation of number, location, dimensions, wall thickness, and the content of pancreatic cysts. Also, it is crucial in distinguishing the internal septae and solid areas within the cysts[6].

The morphological features of PCLs are not independent factors in differentiating malignant from nonmalignant lesions. The combination of both EUS-fine needle aspiration (EUS-FNA) findings with cystic fluid tumor marker analysis, along with clinical, radiologic, histologic, genetic, and molecular characteristics, enhances the diagnostic accuracy for PCLs and helps to construct a novel model in the era of PCL diagnosis[4].

Currently, many tumor markers, both in the serum and in pancreatic cyst fluid (CF), have been widely studied as a tool for distinguishing mucinous/malignant and non-mucinous pancreatic cystic lesions, such as carcinoembryonic antigen (CEA), cancer antigen (CA)19-9, CA125, CA15-3, and CA72-4 [7].

MATERIALS AND METHODS

Study design and aims

In this single tertiary referral center prospective study, the samples were collected and stored, and then all markers were detected in the same specimens in the same time. The study aimed primarily to evaluate the role of cyst fluid amylase and tumor markers such as CA 19-9, CEA, serine protease inhibitor Kazal-type 1 (SPINK1), IL1- β , CA 72-4, vascular endothelial growth factor A (VEGF-A), and prostaglandin E2 (PGE2) in addition to mucin stain in diagnosing pancreatic cysts and differentiating malignant from benign lesions.

Patients and recruitment

This prospective study was conducted on 76 patients diagnosed with PCLs using different imaging modalities such as computed tomography (CT), EUS, abdominal ultrasound, or magnetic resonance imaging (MRI). The candidates were recruited over 3 years from the Gastroenterology, Endoscopy, and Hepatology Unit, Internal Medicine Department, Kasr Al-Ainy, Cairo University. Fluid analysis was performed for CA 19-9, CA 72-4, CEA, VEGF-1, SPINK-1, IL1-b, PGE2, amylase, mucin stain, and cytopathology. We compared these data with the final diagnosis based on histopathology after surgical resection, positive cytopathology (positive for malignancy), and a long period of follow-up of the patients for at least 18 mo.

All patients underwent EUS examination for cyst characterization and sampling of the cystic lesions. All included patients were above 18 years of age. Patients included in this study were diagnosed with

large pancreatic cysts (larger than 3 cm), suspicious intraductal papillary mucinous neoplasm (IPMN), or pancreatic duct dilatation proved by magnetic resonance cholangiopancreatography. However, patients with small cysts (less than 1 cm), calculous cholecystitis, a potential risk for anesthesia, or a bleeding tendency (international normalized ratio > 1.5, or severe thrombocytopenia, with platelet count < 50000/mm³) and patients who refused to participate were excluded from the study. Also, those who missed the follow-up were ruled out from the study. Our institution's Research Ethical Committee approved the study, and all patients gave their informed written consent before inclusion in the study, according to the ethical guidelines of the 1975 Declaration of Helsinki.

Examination procedure

All the patients, after thorough full history taking and clinical examination, were subjected to: (1) EUS examination using a linear Echoendoscope PENTAX EG3870UTK (HOYA Corporation, PENTAX Life Care Division, Showanomori Technology Center, Tokyo, Japan) connected to an ultrasound unit Hitachi AVIUS machine (Hitachi Medical Systems, Tokyo, Japan). All examinations were performed under deep sedation with IV propofol. For EUS-FNA, we used the Cook 19G and 22G needles (Echotip; Wilson-Cook, Winston Salem, NC). Prophylactic ceftriaxone (1 gm) was administered before the procedure; (2) characterization of the PCLs. All the characteristics of the PCLs were documented, including localization, number, dimensions, wall thickness, presence of septations or mural nodules, calcification, lymph nodes, and cystic dilatation of the main pancreatic duct. The color, transparency, and viscosity of the CF were also recorded; and (3) evacuation of the cystic fluid entirely with a single needle pass. Aspirated material inside the needle was spread over dry slides. Also, a proportion of the fluid sample (at least 2 mL) was sent for cytopathological examination, including mucin staining using alcian blue stain. At least 5 mL of cyst fluid was analyzed for CEA, SPINK1, IL1- β , CA 72-4, VEGF-A, PGE2, and CA-19-9 using two-site immunoassays (Beckman Coulter). Amylase was measured by the enzymatic colorimetric assay on a modular system (Roche).

Cysts were considered malignant when any of the following is present: (1) Cytopathological detection of malignancy; (2) presence of metastasis in the absence of other concomitant malignancies; (3) presence of mural nodules that progress in size within 6 mo; and (4) postoperative pathological diagnosis of malignancy if available. Cysts were considered benign when proved negative for malignancy by cytopathological examination and follow-up for 18 mo without increasing its size, the appearance of mural nodules or metastasis, or occurrence of obstructive jaundice.

The overall complication rate of EUS-FNA in the prospective series ranges from 0% to 2.5% [8]. Such complications include pain, infection, bleeding, acute pancreatitis, perforation of the esophagus or duodenum, bile peritonitis, and seeding of tumorous cells along the needle track [9]. Therefore, a prophylactic antibiotic in the form of 1 gm IM or slow IV third-generation cephalosporin was administered 6 h before the procedure. No major complications occurred in our series. However, self-limiting intracystic bleeding occurred in one patient, and mild pain occurred in three patients. All patients were discharged on the same day, and no hospital admission was needed.

Statistical analysis

Data management and analysis were performed using Statistical Package for Social Sciences v. 25. Numerical data are summarized using the mean and standard deviation, median, or range, as appropriate. Categorical data are summarized as numbers and percentages. Estimates of the frequency were calculated using the numbers and percentages. Numerical data were explored for normality using the Kolmogorov-Smirnov test and the Shapiro-Wilk test. To measure the association between variables: (1) Chi-square or Fisher's tests were used to compare independent groups concerning categorical data; (2) kappa statistics were computed to test the agreement between categorical variables. Their values ranged from zero to one; (3) the Mann-Whitney *U* test implemented comparisons between two groups for non-normally distributed numeric variables; and (4) *P* value ≤ 0.05 was considered significant.

RESULTS

This study included 76 patients [31 males (40.8%) and 45 females (59.2%)] with a mean age of 47.4 ± 11.4 years (Table 1).

EUS evaluation showed that most patients had a unilocular cyst (40 patients, 52.6%), while 36 patients (47.4%) had a multilocular cyst. Mural nodules were found in 24 patients (31.6%). In addition, most cysts had thin walls (77.6%) and clear contents (78.9%). Calcifications and lymph nodes were not found in 92.1% and 82.9% of patients, respectively. The pancreatic duct was dilated in 10 patients (13.2%) (Table 2).

Pancreatic cysts were diagnosed as being malignant/potentially malignant or benign in 38.2% and 61.8% of patients, respectively. Malignant cysts included mucinous cystadenocarcinoma (14.5%) (Figure 1A) and pancreatic adenocarcinoma (5.3%). On the other hand, potentially malignant cysts included IPMN with low (7.9%) and high-grade dysplasia (13.2%) and mucinous cystadenoma. Benign cysts included serous and mucinous cystic neoplasms (17.1%), pseudocysts (39.5%) (Figure 1B), and

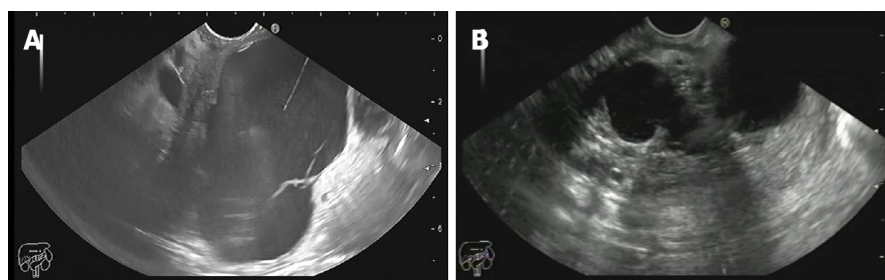
Table 1 Descriptive data of included patients

Gender	Number	Percent (%)
Male	31	40.80%
Female	45	59.20%
Total	76	100%

Table 2 Endoscopic ultrasound findings of studied patients

EUS finding		Number	Percent (%)
Loculation	Unilocular	40	0.526
	Multilocular	36	0.474
Mural nodules	No	52	0.684
	Yes	24	0.316
Wall	Thin Wall	59	0.776
	Thick Wall	17	0.224
Content	Clear	60	0.789
	Turbid	16	0.211
Calcification	No	70	0.921
	Yes	6	0.079
LNs	No	63	0.829
	Yes	13	0.171
Pancreatic duct dilation	No	66	0.868
	Yes	10	0.132

EUS: Endoscopic ultrasound.



DOI: 10.4253/wjge.v14.i6.402 Copyright ©The Author(s) 2022.

Figure 1 Pancreatic body mucinous cystadenoma. A: Pancreatic body mucinous cystadenoma; B: Bilocular inflammatory pseudocyst in the gastric body.

cystic lymphangioma (1.3%) (Table 3).

Evaluating PCLs using mucin stain to differentiate between mucinous and non-mucinous pancreatic cystic lesions showed a sensitivity of 100%, specificity of 94%, and accuracy of 96.04% (Table 4). Also, we found that there was high statistical significance for mucin stain in predicting malignancies with a sensitivity of 87.1%, specificity of 95.56%, positive predictive value (PPV) of 93.1%, and negative predictive value (NPV) of 91.49% (P value < 0.001) (Table 5).

The median CF CEA level was 90 (8.39- 2750) ng/mL. Also, the median CF SPINK1 level was 0.56 (0.35-0.97) ng/mL, and the median CF glucose level was 50 mg/dL (Table 6). When we categorized the CF level of CEA above and below 192 ng/mL, the malignant/potentially malignant cysts were more likely to have a CEA level above 192 ng/mL (P = 0.001), as shown in Table 7.

As shown in Table 6, CF CEA level and CF amylase were significantly higher in malignant/potentially malignant cysts than in benign cysts with a median of 15.8 *vs* 6.4 and 130.5 *vs* 3060 (P = 0.004

Table 3 Final diagnosis

Final diagnosis	Number	Percent (%)
Pancreatic pseudocyst	30	39.5
Pancreatic pseudocyst with WOPN	1	1.3
Serous cystadenoma	13	17.1
Mucinous cystadenoma	11	14.5
IPMN (high grade dysplasia)	10	13.2
IPMN (low grade dysplasia)	6	7.9
Pancreatic adenocarcinoma	4	5.3
Cystic lymphangioma	1	1.3
Total	76	100

IPMN: Intraductal papillary mucinous neoplasm; WOPN: Walled-off pancreatic necrosis.

Table 4 Mucin stain in detecting mucinous from non-mucinous pancreatic cystic lesions

Statistic	Value	95%CI
Sensitivity	100%	86.77% to 100%
Specificity	94%	83.45% to 98.75%
Positive likelihood ratio	16.67	5.56 to 49.93
Negative likelihood ratio	0	
Disease prevalence	34.21%	23.71% to 45.99%
Positive predictive value	89.66%	74.31% to 96.29%
Negative predictive value	100%	
Accuracy	96.05%	88.89% to 99.18%

Table 5 Mucin stain in detecting benign from malignant pancreatic cystic lesions

Statistic	Value	95%CI
Sensitivity	87.10%	70.17% to 96.37%
Specificity	95.56%	84.85% to 99.46%
Positive likelihood ratio	19.60	5.02 to 76.47
Negative likelihood ratio	0.14	0.05 to 0.34
Disease prevalence	40.79%	29.65% to 52.67%
Positive predictive value	93.10%	77.58% to 98.14%
Negative predictive value	91.49%	81.12% to 96.41%
Accuracy	92.11%	83.60% to 97.05%

and 0.034, respectively). Also, CF amylase and CF CEA showed statistical significance in predicting malignancy ($P = 0.028$ and < 0.001 , respectively). Furthermore, the SPINK1 level in CF was significantly higher in malignant/potentially malignant cysts compared to benign ones (0.91 *vs* 0.47, $P = 0.001$). Meanwhile, glucose was markedly consumed in malignant/potentially malignant cysts than in benign cysts (21.5 *vs* 68.5, $P = 0.0001$) (Table 7).

Comparing different CF markers in predicting malignant PCLs among the studied patients revealed that positive Mucin stain, CF glucose, SPINK1, amylase, and CEA showed high statistical significance ($P < 0.0001$, 0.0001, 0.001, 0.034, and 0.004, respectively). However, IL1- β , CA 72-4, VEGF-A, VEGFR2, and PGE2 did not show any statistical significance (Table 8).

Table 6 Cyst fluid carcinoembryonic antigen, serine protease inhibitor Kazal-type 1, and glucose level in studied patients

Biochemical test	Median (IQR)	Range
CEA (ng/ml)	90 (8.78- 1560)	(5-100000)
SPINK1 (ng/ml)	0.56 (0.35-0.97)	(0.1-2.32)
Glucose (mg/ dl)	50 (10-84)	(2-171)

IQR: Interquartile range.

Table 7 Cystic fluid analysis of malignant/potentially and benign cysts

Variable	Benign group(n = 45)	Malignant group(n = 31)	P value
Mucin stain positivity	2 (4.4%)	27 (87.1%)	< 0.0001
Number (%)			
Glucose (mg/ dl)	21.5 (4-45)	68.5 (47-87)	0.0001
median (IQR)			
IL1b (pg/mL)	0.37 (0.58)	0.34 (0.45)	0.845
(median, IQR)			
CA 72-4 (U/ mL)	6.36 (9.7)	7.4 (7.6)	0.323
(median, IQR)			
VEGF-A (pg/ ml)	707.8 (1056)	736.9 (2262)	0.866
(median, IQR)			
VEGFR2 (pg/ ml)	2.5 (5.3)	1.3 (3)	0.281
(median, IQR)			
SPINK1 (ng/ml)	0.91 (0.41-1.45)	0.47 (0.3-0.72)	0.001
median (IQR)			
PGE2 (pg/ ml)	307.2 (131)	409.7 (176)	0.121
(median, IQR)			
CF amylase (U/ L)	130.5 (353)	3060 (5191)	0.034
(median, IQR)			
CF CEA (ng/ ml)	6.4 (234)	15.8 (2532)	0.004
(median, IQR)			
CEA (> 192 ng/ mL)	15	5	0.001

CEA: Carcinoembryonic antigen; CF: Cyst fluid; IQR: Interquartile range; VEGFR2: Vascular endothelial growth factor receptor 2; SPINK1: Serine protease inhibitor Kazal-type 1.

Univariate regression analysis showed a statistically significant association between malignancy in PCLs and mural nodules, lymph nodes, cyst diameter, mucin stain, CF CEA, SPINK1, and CEA level > 192 ng/ mL. In comparison, multivariable regression analysis proved that mural nodules, mucin stain, SPINK1, and CEA level > 192 ng/ mL were independent predictors of malignancy in cystic pancreatic lesions (Table 9).

Receiver operating characteristic (ROC) curves were constructed to assess the diagnostic accuracy of CF CEA, SPINK1, IL1- β , CA 72-4, VEGF-A, PGE2, and CA-19-9 in predicting malignant cysts. It revealed that the area under the curve was comparable for CEA, glucose, and SPINK1 (0.75, 0.76, and 0.72, respectively) (Figures 2A-C).

The sensitivity of EUS diagnosis in detecting malignant and premalignant pancreatic cysts was 66.7%, while 69.2% for the specificity, 60% PPV, and 75% NPV with an overall accuracy of 68.2% (Table 10).

Out of 76 patients, two patients died. Both patients had pancreatic adenocarcinoma. Most of the patients showed a stationary course (40 patients, 52.6%), and only three patients (3.9%) ran a regressive

Table 8 Value of different variables in predicting malignancy

Variable	Criterion	Specificity	Sensitivity	PPV	NPV	P value	AUC
Age	> 35	0.244	1	0.4745	1	0.605	0.534
Mucin stain		0.9556	0.871	0.931	0.9149	< 0.001	0.913
Glucose (mg/dL)	≤ 42	0.7353	0.8478				0.76
IL1b (pg/mL)	< 1.13	0.209	0.9	0.4363	0.7464	0.761	0.521
CA 72-4 (U/mL)	> 4.3138	0.467	0.677	0.4657	0.678	0.32	0.567
VEGF-A (pg/mL)	> 1221.7	0.844	0.29	0.561	0.634	0.87	0.511
VEGFR2 (pg/ml)	> 6.601	0.933	0.29	0.7482	0.657	0.301	0.573
SPINK1 (µg/L)	≥ 0.58	0.6533	0.7059	0.708	0.623		0.72
PGE2 (pg/ml)	> 311.77	0.556	0.8	0.5529	0.802	0.102	0.683
CF amylase (U/L)	> 270	0.71	0.711	0.629	0.781	0.028	0.644
CF CEA (ng/ml)	> 8	0.742	0.689	0.622	0.795	< 0.001	0.761

CA: Cancer antigen; CF: Cyst fluid; VEGFR2: Vascular endothelial growth factor receptor 2; PPV: Positive predictive value; NPV: Negative predictive value.

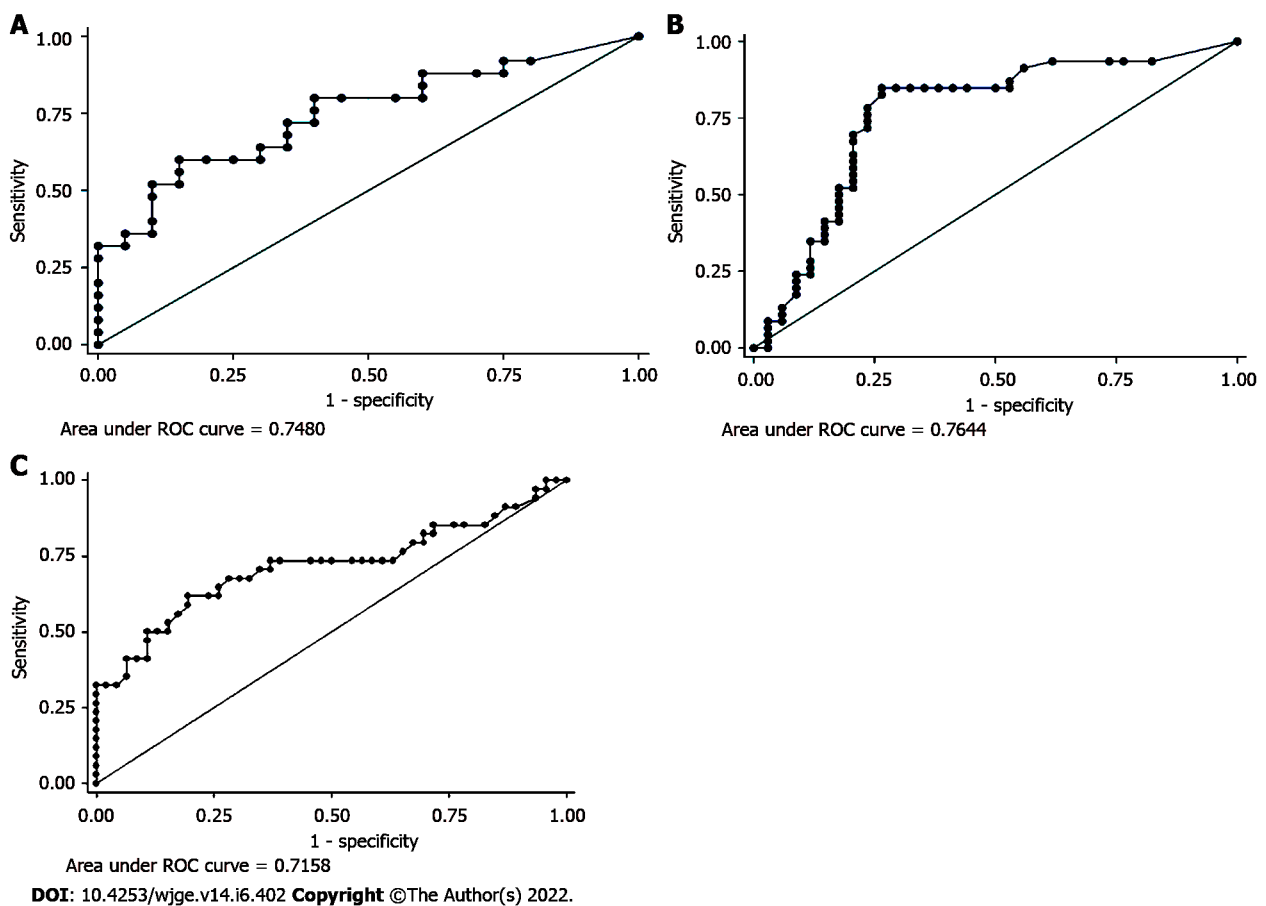


Figure 2 Receiver operating characteristic curve analysis. A: Cyst fluid carcinoembryonic antigen level; B: Glucose level in cyst fluid; C: Cyst fluid serine protease inhibitor Kazal-type 1 level. ROC: Receiver operating characteristic.

course, as demonstrated in Table 11. Two patients with inflammatory pseudocyst underwent a percutaneous pig-tail insertion; one of them was complicated by abscess formation and proceeded to surgery. Most of the patients required no intervention (56 patients, 73.7%). However, some patients were referred to surgeries (17 patients, 22.4%), and only one patient underwent cystogastrostomy, as demonstrated in Table 12.

Table 9 Logistic regression analysis for predictors of malignancy in cystic pancreatic lesions

Variable	Univariate analysis		Multivariate analysis	
	OR (95%CI)	P value	OR (95%CI)	P value
Age	1.06 (0.97-1.06)	0.4312		
Mural nodules	6.6 (2.3- 19.3)	0.0006	5.7 (1.37-24.6)	0.0172
Wall thickness	1.39 (0.47-4.124)	0.5514		
LN's	11.82 (2.4-58.4)	0.0024	0.14 (0.006-3.3)	0.2219
Content	0.59 (0.18-1.923)	0.3851		
Loculation	1.1 (0.43-2.68)	0.8826		
Calcification	1.5 (0.28-7.97)	0.6342		
Shortest Diameter	0.965 (0.94-0.99)	0.0189	1.06 (0.92-1.22)	0.4044
Longest Diameter	0.971(0.95-0.99)	0.0112	0.913 (0.81- 1.03)	0.1326
Mucin Stain	145 (24.8-847.2)	< 0.0001	82.4 (12.1-561)	< 0.0001
Glucose	0.97 (0.96-0.99)	> 0.001	0.99 (0.97-1.01)	0.48
IL1b (pg/mL)	0.91 (0.702-1.18)	0.496		
CA 72-4	1.02 (0.98-1.053)	0.3017		
VEGF-A	1.0001(0.99-1.0005)	0.5782		
VEGFR2	1.14 (0.99-1.318)	0.0782		
SPINK1	9.09 (2.62-31.59)	0.001	23.65 (3.10-180.62)	0.002
PGE2 (pg/mL)	1.01 (0.999-1.02)	0.0798		
CF Amylase	1 (1-1)	0.8593		
CF CEA	1.0003 (1.0001-1.0005)	0.0152	1.0001 (0.99-1.0006)	0.5978
CEA > 192 (ng/mL)	6.47 (2.05-20.42)	0.001	14.12 (2.39-83.22)	0.003

OR: Odds ratio; CI: Confidence interval; LN's: Lymph-nodes; CF: Cyst fluid; CA: Cancer antigen; CEA: Carcinoembryonic antigen; SPINK1: Serine protease inhibitor Kazal-type 1; IL1-β: Interleukin 1 beta; CA 72-4: Human cancer antigen 72-4; VEGF-A: Vascular endothelial growth factor A; VEGFR2: Vascular endothelial growth factor receptor 2, PGE2: Prostaglandin E2.

Table 10 Performance of EUS diagnosis for malignant/premalignant and benign cysts

Statistic	Value	95%CI
Sensitivity	0.6667	40.99% to 86.66%
Specificity	0.6923	48.21% to 85.67%
Positive predictive value	0.6	43.60% to 74.42%
Negative predictive value	0.75	59.79% to 85.82%
Accuracy	0.6818	52.42% to 81.39%

DISCUSSION

There are great challenges in diagnosing and managing PCLs that have become a common problem faced by many physicians and surgeons[10]. Some PCLs have a malignant potential with a significant risk of developing invasive cancer[11]. Therefore, the accurate classification and diagnosis of pancreatic cysts provide a potential for preventing and early detection of pancreatic cancer. On the other hand, misdiagnosis or unnecessary surgeries may lead to high cost and harm to the patients[10].

Unfortunately, imaging modalities such as CT and MRI have insufficient sensitivity and specificity to characterize PCLs and provide a suboptimal classification and diagnosis due to poor interobserver variability[12].

Table 11 Follow-up data of studied patients

Follow-up	Stationary	Regressive	No-recurrence	Progressive	Died
Pancreatic pseudocyst (<i>n</i> = 30)	27 (35.5%)	3 (3.9%)	0	0	0
Pancreatic pseudocyst with WOPN (<i>n</i> = 1)	0	0	1 (1.3%)	0	0
Serous cystadenoma (<i>n</i> = 13)	12 (15.7%)	0	1 (1.3%)	0	0
Mucinous cystadenoma (<i>n</i> = 10)	9	0	1 (1.3%)	0	0
Mucinous cystadenocarcinoma (<i>n</i> = 1)	0	0	0	1	0
IPMN (high grade dysplasia) (<i>n</i> = 10)	3	0	7	0	0
IPMN (low grade dysplasia) (<i>n</i> = 6)	6	0	0	0	0
Pancreatic adenocarcinoma (<i>n</i> = 4)	0	0	2 (2.6%)	0	2 (2.6%)
Cystic lymphangioma (<i>n</i> = 1)	1 (1.3%)	0	0	0	0
Total (<i>n</i> = 76)	40 (52.6%)	3 (3.9%)	5 (6.5%)	0	2 (2.6%)

Table 12 Intervention required for studied patients

Intervention required	No	Surgery	Pig-tail drainage	Cysto-gastrostomy
Pancreatic pseudocyst (<i>n</i> = 30)	26 (34.2%)	1 (1.3%)	2 (2.6%)	1 (1.3%)
Pancreatic pseudocyst with WOPN (<i>n</i> = 1)	0	1 (1.3%)	0	0
Serous cystadenoma (<i>n</i> = 13)	12 (15.8%)	1 (1.3%)	0	0
Mucinous cystadenoma (<i>n</i> = 10)	9 (11.7%)	1 (1.3%)	0	0
Mucinous cystadenocarcinoma (<i>n</i> = 1)	1 (1.3%)	0	0	0
IPMN (high grade dysplasia) (<i>n</i> = 10)	1 (1.3%)	9 (11.8%)	0	0
IPMN (low grade dysplasia) (<i>n</i> = 6)	6 (7.9%)	0	0	0
Pancreatic adenocarcinoma (<i>n</i> = 4)	0	4 (5.2%)	0	0
Cystic lymphangioma (<i>n</i> = 1)	1 (1.3%)	0	0	0
Total (<i>n</i> = 76)	56 (73.7%)	17 (22.4%)	2 (2.6%)	1 (1.3%)

EUS is considered the most sensitive tool in delineating the pancreatic cyst characteristics with the capacity to identify the presence of mural nodules and solid components[13]. Also, it has a benefit in enabling EUS-FNA for cytology[14]. Nonetheless, cytology still has a limited diagnostic yield with a pooled sensitivity of 63% and specificity of 88%[15].

Owing to the limited diagnostic accuracy for different pancreatic cysts with the current diagnostic modalities, analysis of the pancreatic CF obtained *via* EUS-FNA could improve the diagnostic accuracy for pancreatic cysts and help determine the malignant potentiality. Therefore, there is still a growing research interest in discovering and validating novel CF biomarkers that may improve diagnostic accuracy. The present study was designed to determine the role of CF amylase and tumor markers such as CA 19-9, CEA, SPINK1, IL1- β , CA 72-4, VEGF-A, and PGE2 in addition to mucin stain in diagnosing pancreatic cysts and differentiating malignant from benign lesions.

The presence of solid components inside the cyst on imaging could be a significant predictor of malignancy, as reported in many studies[16-18]. Also, we found that the presence of mural nodules was highly predictive of malignancy in univariate and multivariate logistic regression analysis ($P = 0.0006$ and 0.0172 , respectively) along with cyst diameter ($P = 0.0189$ for shortest diameter and 0.0112 for longest diameter) and lymph node enlargement ($P = 0.0024$).

In a study conducted by Okasha *et al*[19] analyzing the CF amylase of 44 patients, they concluded that pancreatic CF amylase level could differentiate between malignant/potentially malignant and benign cysts with a sensitivity of 58%, specificity of 75%, PPV of 73%, NPV of 60%, and accuracy of 66%.

In our study, CF CEA level and CF amylase were significantly higher in malignant/potentially malignant cysts than in benign cysts ($P = 0.004$ and 0.034 , respectively). This finding agrees with other studies stating that pancreatic CF CEA offers the best diagnostic performance than any other single test, especially in differentiating mucinous and non-mucinous cysts[20].

A large multi-institutional study conducted on 1861 patients reported that CEA > 192 ng/mL could differentiate mucinous from non-mucinous cysts with an accuracy of 77%[21]. Their findings are in

concordance with our study that reported that the malignant/potentially malignant cysts had CEA levels above 192 ng/mL ($P = 0.001$).

In CF, positive mucin stain was significantly more frequent in malignant cysts (87.1%) ($P < 0.0001$). Twenty-seven cysts were positive for mucin stain, with a sensitivity of 87.1% and specificity of 95.56% in differentiating benign from malignant PCLS. Also, mucin staining differentiates mucinous from non-mucinous cysts with a sensitivity and specificity of 100% and 94%, respectively. The results in the current study were more compatible with an Egyptian study by Okasha and his colleagues. They showed that pancreatic CF positive mucin stain was 85% sensitive and 95% specific in detecting mucinous or non-mucinous pancreatic cysts with a 92% PPV, 91% NPV, and 91% accuracy. Also, positive mucin staining was 63% sensitive and 97% specific in differentiating malignant/potentially malignant from benign pancreatic cysts with a PPV of 96%, NPV of 72%, and overall accuracy of 80%. This outcome is in concordance with a recent study by Okasha and his colleagues that showed that a CF positive mucin stain has a sensitivity of 85.5% and specificity of 86.1% for detecting mucinous cystic neoplasm with a 72.3% PPV, 93.3% NPV, and 85.9% accuracy[4]. Many studies also reported that the mucin staining could be complementary to cyst CEA levels and cytology, and when one out of three was found to be positive, this increases the sensitivity to 92% and specificity to 52%, as in a study conducted by Morris-Stiff *et al*[22].

In our study, CF glucose was markedly consumed in malignant/potentially malignant cysts than in benign cysts (21.5 *vs* 68.5, $P = 0.0001$). Since glucose is a simple and cheap biomarker, it could be used as a marker for differentiation between benign and malignant pancreatic cysts with a relatively low cost [23-25].

In 2004, Raty *et al*[26] were the first to evaluate the role of CF SPINK1 in differentiating potentially malignant from benign cysts. They reported that the SPINK1 level was higher in malignant/potentially malignant than in benign cystic pancreatic lesions (1609 ± 418 *vs* 46 ± 21 ug/L; $P = 0.0001$). These findings matched our study that showed that SPINK1 level was higher in malignant/potentially malignant cysts than in benign ones (0.91 *vs* 0.47, $P = 0.001$) with a sensitivity and specificity of 70.59% and 65.33%, respectively (Table 8).

In our study, mural nodules, cyst diameter, lymph node enlargement, mucin stain, CF CEA, SPINK1, and glucose measurements in CF were highly predictive of malignancy in univariate analysis. In comparison, only mural nodules, mucin stain, and SPINK1 were highly predictive of malignancy in multivariate analysis.

Of all these markers measured in CF, CEA, glucose, and SPINK1 were independent predictors of malignancy, suggesting that these markers could help differentiate potentially malignant cysts from benign cysts.

The analysis of recent markers - not investigated in this study - such as CF DNA is recommended for future research because it might add more diagnostic value in differentiating benign from malignant cysts.

CONCLUSION

Conclusion

EUS examination of cyst morphology with cytopathological and chemical analysis and CF analysis could improve the differentiation between malignant and benign pancreatic cysts. Also, CEA, glucose, and SPINK1 are valuable markers for predicting a malignant pancreatic cyst.

Recommendations

Further studies addressing new markers are recommended, which will provide a panel of laboratory data to recognize the malignant and potentially malignant lesions to establish a standard protocol for diagnosis and management. Also, CF DNA is considered a potential diagnostic agent with particular possible use in differentiating between benign and malignant cysts. Further investigation regarding this biomarker is recommended.

ARTICLE HIGHLIGHTS

Research background

Nowadays, the awareness of pancreatic cystic lesions has become an essential issue, especially with the increased incidence of asymptomatic pancreatic cysts in the general population. Therefore, the proper diagnosis, meticulous differentiation, and staging of these pancreatic cystic lesions (PCLs) are crucial for proper management and avoiding unnecessary treatment of benign lesions and missing early treatment of the malignant/pre-malignant lesions. Endoscopic ultrasound (EUS) examination of cyst morphology with cytopathological and chemical analysis and cyst fluid analysis could improve the diagnostic capability. Also, many developed markers are valuable for predicting a malignant pancreatic cyst.

Research motivation

EUS examination of cyst morphology with cytopathological and chemical analysis and cyst fluid analysis could improve the differentiation between malignant and benign pancreatic cysts. Also, carcinoembryonic antigen (CEA), glucose, and the serine protease inhibitor Kazal-type 1 (SPINK1) are valuable markers for predicting a malignant pancreatic cyst.

Research objectives

To evaluate the role of cyst fluid analysis of different tumor markers such as cancer antigens (*e.g.*, CA19-9 and CA72-4), carcinoembryonic antigen (CEA), SPINK1, interleukin 1 beta (IL-1 β), vascular endothelial growth factor A (VEGF-A), prostaglandin E2 (PGE2), amylase, and mucin stain in diagnosing pancreatic cysts and differentiating malignant from benign lesions.

Research methods

This study included 76 patients diagnosed with PCLs using different imaging modalities. All patients underwent EUS and EUS-FNA for characterization and sampling of different PCLs.

Research results

The mean age of studied patients was 47.4 ± 11.4 years, with a slight female predominance (59.2%). Mucin stain showed high statistical significance in predicting malignancy with a sensitivity of 87.1% and specificity of 95.56%. It also showed a positive predictive value and negative predictive value of 93.1% and 91.49%, respectively ($P < 0.001$). We found that positive mucin stain, cyst fluid glucose, SPINK1, amylase, and CEA levels had high statistical significance ($P < 0.0001$). In contrast, IL-1 β , CA 72-4, VEGF-A, VEGFR2, and PGE2 did not show any statistical significance. Univariate regression analysis for prediction of malignancy in PCLs showed a statistically significant positive correlation with mural nodules, lymph nodes, cyst diameter, mucin stain, and cyst fluid CEA. Meanwhile, logistic multivariable regression analysis proved that mural nodules, mucin stain, and SPINK1 were independent predictors of malignancy in PCLs.

Research conclusions

EUS examination of cyst morphology with cytopathological analysis and cyst fluid analysis could improve the differentiation between malignant and benign pancreatic cysts. Also, CEA, glucose, and SPINK1 could be used as promising markers to predict malignant pancreatic cysts.

Research perspectives

Further studies addressing new markers are recommended, which will provide a panel of laboratory data to recognize the malignant and potentially malignant lesions to establish a standard protocol for diagnosis and management. Also, cyst fluid DNA is considered a potential diagnostic agent with particular possible use in differentiating between benign and malignant cysts. Further investigation regarding this biomarker is recommended.

ACKNOWLEDGEMENTS

We would like to acknowledge our great Kasr Al Ainy Hospital, and its workers, nurses, and staff members, for all the support and help in this study and throughout our careers.

FOOTNOTES

Author contributions: El-Nady M, Abeer Awad, Shaimaa El-Kholy, and Abdel-Hamid H were involved equally in writing the manuscript; Elbaz T, Ramadan A, Behiry ME, Y William K, Habib G, Kaddah M, Abou-ElMagd A, Abbas WA, Altonbary AY, El-Ansary M, Abdou AE, Haggag H, Abdellah TA, Elfeki MA, and Faheem HA were involved equally in collecting the data; Mogawer MS, Yosry A, Elserafy M, Medhat E, Khalaf H, Fouad M, Ahmed M Shalaby, Galal A, Khattab HM, El-Ansary M, and Beshir S were involved equally in reading and revising the manuscript; Okasha HH revised and approved the final manuscript; all authors have read and approved the final manuscript.

Institutional review board statement: Our institution's Research Ethical Committee approved the study, and all patients gave their informed written consent before inclusion in the study, according to the ethical guidelines of the 1975 Declaration of Helsinki.

Conflict-of-interest statement: No conflict of interest exists.

Data sharing statement: No additional data are available.

Open-Access: This article is an open-access article that was selected by an in-house editor and fully peer-reviewed by

external reviewers. It is distributed in accordance with the Creative Commons Attribution NonCommercial (CC BY-NC 4.0) license, which permits others to distribute, remix, adapt, build upon this work non-commercially, and license their derivative works on different terms, provided the original work is properly cited and the use is non-commercial. See: <https://creativecommons.org/licenses/by-nc/4.0/>

Country/Territory of origin: Egypt

ORCID number: Hussein Hassan Okasha 0000-0002-0815-1394; Abeer Abdellatef 0000-0001-9945-9767; Shaimaa Elkholy 0000-0003-4322-6467; Mohamad-Sherif Mogawer 0000-0003-1083-2153; Ayman Yosry 0000-0002-4084-2320; Magdy Elserafy 0000-0002-2760-5347; Eman Medhat 0000-0002-2680-0079; Hanaa Khalaf 0000-0002-3388-7635; Magdy Fouad 0000-0001-8056-5581; Tamer Elbaz 0000-0003-0816-9575; Ahmed Ramadan 0000-0002-8164-2472; Mervat E Behiry 0000-0002-3718-7994; Kerolis Y William 0000-0001-7591-8949; Ghada Habib 0000-0002-1738-5782; Mona Kaddah 0000-0002-1124-1710; Haitham Abdel-Hamid 0000-0002-6363-6271; Amr Abou-Elmagd 0000-0002-9406-7868; Ahmed Galal 0000-0002-6852-369; Wael A Abbas 0000-0001-5554-8207; Ahmed Youssef Altonbary 0000-0001-8850-9829; Mahmoud El-Ansary 0000-0001-9974-0727; Aml E Abdou 0000-0003-0715-3408; Hani Haggag 0000-0003-4209-1943; Tarek Ali Abdellah 0000-0002-3608-9671; Mohamed A Elfeki 0000-0001-8979-8650; Heba Ahmed Faheem 0000-0002-2163-3339; Hani M Khattab 0000-0001-5145-6081; Mervat El-Ansary 0000-0002-7996-2995; Safia Bbeshir 0000-0002-3360-923X; Mohamed El-Nady 0000-0003-1304-3547.

S-Editor: Ma YJ

L-Editor: Wang TQ

P-Editor: Ma YJ

REFERENCES

- 1 **Basturk O**, Coban I, Adsay NV. Pancreatic cysts: pathologic classification, differential diagnosis, and clinical implications. *Arch Pathol Lab Med* 2009; **133**: 423-438 [PMID: 19260748 DOI: 10.5858/133.3.423]
- 2 **Jani N**, Bani Hani M, Schulick RD, Hruban RH, Cunningham SC. Diagnosis and management of cystic lesions of the pancreas. *Diagn Ther Endosc* 2011; **2011**: 478913 [PMID: 21904442 DOI: 10.1155/2011/478913]
- 3 **Laffan TA**, Horton KM, Klein AP, Berlanstein B, Siegelman SS, Kawamoto S, Johnson PT, Fishman EK, Hruban RH. Prevalence of unsuspected pancreatic cysts on MDCT. *AJR Am J Roentgenol* 2008; **191**: 802-807 [PMID: 18716113 DOI: 10.2214/AJR.07.3340]
- 4 **Okasha H**, E Behiry M, Ramadan N, Ezzat R, Yamany A, El-Kholi S, Ahmed G. Endoscopic ultrasound-guided fine needle aspiration in diagnosis of cystic pancreatic lesions. *Arab J Gastroenterol* 2019; **20**: 86-90 [PMID: 31182342 DOI: 10.1016/j.ajg.2019.05.008]
- 5 **Boot C**. A review of pancreatic cyst fluid analysis in the differential diagnosis of pancreatic cyst lesions. *Ann Clin Biochem* 2014; **51**: 151-166 [PMID: 24097809 DOI: 10.1177/0004563213503819]
- 6 **Koito K**, Namieno T, Nagakawa T, Shyonai T, Hirokawa N, Morita K. Solitary cystic tumor of the pancreas: EUS-pathologic correlation. *Gastrointest Endosc* 1997; **45**(3): 268-276 [DOI: 10.1016/s0016-5107(97)70269-4]
- 7 **Sperti C**, Pasquali C, Guolo P, Polverosi R, Liessi G, Pedrazzoli S. Serum tumor markers and cyst fluid analysis are useful for the diagnosis of pancreatic cystic tumors. *Cancer* 1996; **78**: 237-243 [PMID: 8673998 DOI: 10.1002/(SICI)1097-0142(19960715)78:2<237::AID-CNCR8>3.0.CO;2-I]
- 8 **Lee KS**, Sekhar A, Rofsky NM, Pedrosa I. Prevalence of incidental pancreatic cysts in the adult population on MR imaging. *Am J Gastroenterol* 2010; **105**: 2079-2084 [PMID: 20354507 DOI: 10.1038/ajg.2010.122]
- 9 **Polkowski M**, Larghi A, Weynand B, Boustière C, Giovannini M, Pujol B, Dumonceau JM; European Society of Gastrointestinal Endoscopy (ESGE). Learning, techniques, and complications of endoscopic ultrasound (EUS)-guided sampling in gastroenterology: European Society of Gastrointestinal Endoscopy (ESGE) Technical Guideline. *Endoscopy* 2012; **44**: 190-206 [PMID: 22180307 DOI: 10.1055/s-0031-1291543]
- 10 **Lennon AM**, Canto MI. Pancreatic Cysts - Part 2: Should We Be Less Cyst Centric? *Pancreas* 2017; **46**: 745-750 [PMID: 28609361 DOI: 10.1097/MPA.0000000000000841]
- 11 **Matthaei H**, Schulick RD, Hruban RH, Maitra A. Cystic precursors to invasive pancreatic cancer. *Nat Rev Gastroenterol Hepatol* 2011; **8**: 141-150 [PMID: 21383670 DOI: 10.1038/nrgastro.2011.2]
- 12 **Machicado JD**, Koay EJ, Krishna SG. Radiomics for the Diagnosis and Differentiation of Pancreatic Cystic Lesions. *Diagnostics (Basel)* 2020; **10** [PMID: 32708348 DOI: 10.3390/diagnostics10070505]
- 13 **Brugge WR**. The use of EUS to diagnose cystic neoplasms of the pancreas. *Gastrointest Endosc* 2009; **69**: S203-S209 [PMID: 19179158 DOI: 10.1016/j.gie.2008.12.029]
- 14 **Barresi L**, Tarantino I, Granata A, Curcio G, Traina M. Pancreatic cystic lesions: How endoscopic ultrasound morphology and endoscopic ultrasound fine needle aspiration help unlock the diagnostic puzzle. *World J Gastrointest Endosc* 2012; **4**: 247-259 [PMID: 22720127 DOI: 10.4253/wjge.v4.i6.247]
- 15 **Thiruvengadam N**, Park WG. Systematic Review of Pancreatic Cyst Fluid Biomarkers: The Path Forward. *Clin Transl Gastroenterol* 2015; **6**: e88 [PMID: 26065716 DOI: 10.1038/ctg.2015.17]
- 16 **Lee CJ**, Scheiman J, Anderson MA, Hines OJ, Reber HA, Farrell J, Kochman ML, Foley PJ, Drebin J, Oh YS, Ginsberg G, Ahmad N, Merchant NB, Isbell J, Parikh AA, Stokes JB, Bauer T, Adams RB, Simeone DM. Risk of malignancy in resected cystic tumors of the pancreas < or =3 cm in size: is it safe to observe asymptomatic patients? *J Gastrointest Surg* 2008; **12**: 234-242 [PMID: 18040749 DOI: 10.1007/s11605-007-0381-y]
- 17 **Sarr MG**, Carpenter HA, Prabhakar LP, Orchard TF, Hughes S, van Heerden JA, DiMaggio EP. Clinical and pathologic

- correlation of 84 mucinous cystic neoplasms of the pancreas: can one reliably differentiate benign from malignant (or premalignant) neoplasms? *Ann Surg* 2000; **231**: 205-212 [PMID: [10674612](#) DOI: [10.1097/0000658-200002000-00009](#)]
- 18 **Sahani DV**, Saokar A, Hahn PF, Brugge WR, Fernandez-Del Castillo C. Pancreatic cysts 3 cm or smaller: how aggressive should treatment be? *Radiology* 2006; **238**: 912-919 [PMID: [16439566](#) DOI: [10.1148/radiol.2382041806](#)]
 - 19 **Okasha HH**, Ashry M, Imam HM, Ezzat R, Naguib M, Farag AH, Gemeie EH, Khattab HM. Role of endoscopic ultrasound-guided fine needle aspiration and ultrasound-guided fine-needle aspiration in diagnosis of cystic pancreatic lesions. *Endosc Ultrasound* 2015; **4**: 132-136 [PMID: [26020048](#) DOI: [10.4103/2303-9027.156742](#)]
 - 20 **Brugge WR**, Lewandrowski K, Lee-Lewandrowski E, Centeno BA, Szydio T, Regan S, del Castillo CF, Warshaw AL. Diagnosis of pancreatic cystic neoplasms: a report of the cooperative pancreatic cyst study. *Gastroenterology* 2004; **126**: 1330-1336 [PMID: [15131794](#) DOI: [10.1053/j.gastro.2004.02.013](#)]
 - 21 **Gaddam S**, Ge PS, Keach JW, Mullady D, Fukami N, Edmundowicz SA, Azar RR, Shah RJ, Murad FM, Kushnir VM, Watson RR, Ghassemi KF, Sedarat A, Komanduri S, Jaiyeola DM, Brauer BC, Yen RD, Amateau SK, Hosford L, Hollander T, Donahue TR, Schulick RD, Edil BH, McCarter M, Gajdos C, Attwell A, Muthusamy VR, Early DS, Wani S. Suboptimal accuracy of carcinoembryonic antigen in differentiation of mucinous and nonmucinous pancreatic cysts: results of a large multicenter study. *Gastrointest Endosc* 2015; **82**: 1060-1069 [PMID: [26077458](#) DOI: [10.1016/j.gie.2015.04.040](#)]
 - 22 **Morris-Stiff G**, Lentz G, Chalikonda S, Johnson M, Biscotti C, Stevens T, Matthew Walsh R. Pancreatic cyst aspiration analysis for cystic neoplasms: mucin or carcinoembryonic antigen--which is better? *Surgery* 2010; **148**: 638-44; discussion 644 [PMID: [20797749](#) DOI: [10.1016/j.surg.2010.07.023](#)]
 - 23 **Park WG**, Wu M, Bowen R, Zheng M, Fitch WL, Pai RK, Wodziak D, Visser BC, Poultsides GA, Norton JA, Banerjee S, Chen AM, Friedland S, Scott BA, Pasricha PJ, Lowe AW, Peltz G. Metabolomic-derived novel cyst fluid biomarkers for pancreatic cysts: glucose and kynurenine. *Gastrointest Endosc* 2013; **78**: 295-302.e2 [PMID: [23566642](#) DOI: [10.1016/j.gie.2013.02.037](#)]
 - 24 **Zikos T**, Pham K, Bowen R, Chen AM, Banerjee S, Friedland S, Dua MM, Norton JA, Poultsides GA, Visser BC, Park WG. Cyst Fluid Glucose is Rapidly Feasible and Accurate in Diagnosing Mucinous Pancreatic Cysts. *Am J Gastroenterol* 2015; **110**: 909-914 [PMID: [25986360](#) DOI: [10.1038/ajg.2015.148](#)]
 - 25 **Carr RA**, Yip-Schneider MT, Simpson RE, Dolejs S, Schneider JG, Wu H, Ceppa EP, Park W, Schmidt CM. Pancreatic cyst fluid glucose: rapid, inexpensive, and accurate diagnosis of mucinous pancreatic cysts. *Surgery* 2018; **163**: 600-605 [PMID: [29241991](#) DOI: [10.1016/j.surg.2017.09.051](#)]
 - 26 **Räty S**, Sand J, Alfthan H, Haglund C, Nordback I. Cyst fluid tumor-associated trypsin inhibitor may be helpful in the differentiation of cystic pancreatic lesions. *J Gastrointest Surg* 2004; **8**: 569-574 [PMID: [15239993](#) DOI: [10.1016/j.gassur.2004.01.005](#)]



Published by **Baishideng Publishing Group Inc**
7041 Koll Center Parkway, Suite 160, Pleasanton, CA 94566, USA

Telephone: +1-925-3991568

E-mail: bpgoffice@wjgnet.com

Help Desk: <https://www.f6publishing.com/helpdesk>

<https://www.wjgnet.com>

