

# World Journal of *Gastrointestinal Endoscopy*

*World J Gastrointest Endosc* 2022 July 16; 14(7): 416-473



## ORIGINAL ARTICLE

## Retrospective Study

- 416 Safety of endoscopy in patients undergoing treatments with antiangiogenic agents: A 5-year retrospective review

*Azam M, Hudgi A, Uy PP, Makhija J, Yap JEL*

## Randomized Clinical Trial

- 424 Feasibility of endoscopic papillary large balloon dilation to remove difficult stones in patients with nondilated distal bile ducts

*Pereira Lima JC, Moresco GS, Sanmartin IDA, Contin I, Pereira-Lima G, Watte G, Altmayer S, Oliveira dos Santos CE*

## SYSTEMATIC REVIEWS

- 434 Role of balloon enteroscopy for obscure gastrointestinal bleeding in those with surgically altered anatomy: A systematic review

*Aryan M, Colvin T, Ahmed AM, Kyanam Kabir Baig KR, Peter S*

- 443 Quality of life after surgical and endoscopic management of severe acute pancreatitis: A systematic review

*Psaltis E, Varghese C, Pandanaboyana S, Nayar M*

## CASE REPORT

- 455 Solitary pancreatic metastasis from squamous cell lung carcinoma: A case report and review of literature

*Rais K, El Eulj O, El Moutaoukil N, Kamaoui I, Bennani A, Kharrasse G, Zazour A, Khannoussi W, Ismaili Z*

## LETTER TO THE EDITOR

- 467 Multimodal treatments of "gallstone cholangiopancreatitis"

*Vanella S, Baiamonte M, Crafa F*

- 471 Texture and color enhancement imaging for detecting colorectal adenomas: Good, but not good enough

*Wang Y, Sun CY, Scott L, Wu DD, Chen X*

**ABOUT COVER**

Editorial Board Member of *World Journal of Gastrointestinal Endoscopy*, Moinak Sen Sarma, MD, DM, Associate Professor, Department of Pediatric Gastroenterology, Sanjay Gandhi Postgraduate Institute of Medical Sciences, Lucknow 226014, India. moinaksen@gmail.com

**AIMS AND SCOPE**

The primary aim of *World Journal of Gastrointestinal Endoscopy* (WJGE, *World J Gastrointest Endosc*) is to provide scholars and readers from various fields of gastrointestinal endoscopy with a platform to publish high-quality basic and clinical research articles and communicate their research findings online.

WJGE mainly publishes articles reporting research results and findings obtained in the field of gastrointestinal endoscopy and covering a wide range of topics including capsule endoscopy, colonoscopy, double-balloon enteroscopy, duodenoscopy, endoscopic retrograde cholangiopancreatography, endosonography, esophagoscopy, gastrointestinal endoscopy, gastroscopy, laparoscopy, natural orifice endoscopic surgery, proctoscopy, and sigmoidoscopy.

**INDEXING/ABSTRACTING**

The WJGE is now abstracted and indexed in Emerging Sources Citation Index (Web of Science), PubMed, PubMed Central, Reference Citation Analysis, China National Knowledge Infrastructure, China Science and Technology Journal Database, and Superstar Journals Database. The 2022 edition of Journal Citation Reports® cites the 2021 Journal Citation Indicator (JCI) for WJGE as 0.33.

**RESPONSIBLE EDITORS FOR THIS ISSUE**

Production Editor: Yi-Xuan Cai; Production Department Director: Xu Guo; Editorial Office Director: Jia-Ping Yan.

**NAME OF JOURNAL**

*World Journal of Gastrointestinal Endoscopy*

**ISSN**

ISSN 1948-5190 (online)

**LAUNCH DATE**

October 15, 2009

**FREQUENCY**

Monthly

**EDITORS-IN-CHIEF**

Anastasios Koulaouzidis, Bing Hu, Sang Chul Lee, Joo Young Cho

**EDITORIAL BOARD MEMBERS**

<https://www.wjgnet.com/1948-5190/editorialboard.htm>

**PUBLICATION DATE**

July 16, 2022

**COPYRIGHT**

© 2022 Baishideng Publishing Group Inc

**INSTRUCTIONS TO AUTHORS**

<https://www.wjgnet.com/bpg/gerinfo/204>

**GUIDELINES FOR ETHICS DOCUMENTS**

<https://www.wjgnet.com/bpg/gerinfo/287>

**GUIDELINES FOR NON-NATIVE SPEAKERS OF ENGLISH**

<https://www.wjgnet.com/bpg/gerinfo/240>

**PUBLICATION ETHICS**

<https://www.wjgnet.com/bpg/gerinfo/288>

**PUBLICATION MISCONDUCT**

<https://www.wjgnet.com/bpg/gerinfo/208>

**ARTICLE PROCESSING CHARGE**

<https://www.wjgnet.com/bpg/gerinfo/242>

**STEPS FOR SUBMITTING MANUSCRIPTS**

<https://www.wjgnet.com/bpg/gerinfo/239>

**ONLINE SUBMISSION**

<https://www.f6publishing.com>



## Solitary pancreatic metastasis from squamous cell lung carcinoma: A case report and review of literature

Kaouthar Rais, Oumayma El Eulj, Najoua El Moutaoukil, Imane Kamaoui, Amal Bennani, Ghizlane Kharrasse, Abdelkrim Zazour, Wafaa Khannoussi, Zahi Ismaili

**Specialty type:** Gastroenterology and hepatology

**Provenance and peer review:**

Unsolicited article; Externally peer reviewed.

**Peer-review model:** Single blind

**Peer-review report's scientific quality classification**

Grade A (Excellent): 0

Grade B (Very good): 0

Grade C (Good): C

Grade D (Fair): D

Grade E (Poor): 0

**P-Reviewer:** Hu B, China; Li T, China

**Received:** April 6, 2022

**Peer-review started:** April 6, 2022

**First decision:** April 28, 2022

**Revised:** May 18, 2022

**Accepted:** June 15, 2022

**Article in press:** June 15, 2022

**Published online:** July 16, 2022



**Kaouthar Rais, Oumayma El Eulj, Najoua El Moutaoukil, Ghizlane Kharrasse, Abdelkrim Zazour, Wafaa Khannoussi, Zahi Ismaili,** Department of Hepatogastroenterology, Mohammed VI University Hospital Center, Digestive Disease Research Laboratory, Medical School, Mohammed I University, Oujda 60000, Morocco

**Imane Kamaoui,** Department of Radiology, Mohammed VI University Hospital Center, Digestive Disease Research Laboratory, Medical School, Mohammed I University, Oujda 60000, Morocco

**Amal Bennani,** Department of Anatomic-Pathology, Mohammed VI University Hospital Center, Digestive Disease Research Laboratory, Medical School, Mohammed I University, Oujda 60000, Morocco

**Corresponding author:** Kaouthar Rais, MD, Doctor, Department of Hepatogastroenterology, Mohammed VI University Hospital Center, Digestive Disease Research Laboratory, Medical School, Mohammed I University, BP 4806 Oujda University 60049, Oujda 60000, Morocco. [kaoutar.rais@gmail.com](mailto:kaoutar.rais@gmail.com)

### Abstract

#### BACKGROUND

Pancreatic metastases from squamous cell lung carcinoma (SCLC) are unusual. These lesions are often asymptomatic and detected incidentally or during follow-up investigations, occasionally several years after removal of the primary tumor.

#### CASE SUMMARY

A 56-year-old male with SCLC developed jaundice 1 mo after the cancer diagnosis. An abdominal computed tomography (CT) scan showed a mass in the pancreatic head with distention of both intra- and extrahepatic biliary ducts. Endoscopic retrograde cholangiopancreatography and sphincterotomy were performed first, culminating with plastic biliary stent placement. Cytological examination of the pancreatic mass sample collected by fine-needle aspiration (FNA) under endoscopic ultrasound (EUS) guidance revealed the presence of malignant cells compatible with well-differentiated squamous cell carcinoma. After liver function normalized, chemotherapy was initiated with carboplatin and paclitaxel; however, 4 d later, the patient presented dysphagia. Cervico-thoraco-abdominal CT showed tracheoesophageal fistula and stent migration. After replacement with a 10 cm/10 mm uncovered metallic biliary stent and treatment



of the tracheoesophageal fistula with a fully covered esophageal stent, the patient was able to start oral feeding progressively. He died 9 mo after the initial diagnosis.

### CONCLUSION

The diagnosis of pancreatic metastasis from SCLC is challenging for clinicians. EUS-FNA is the primary exam for confirmatory diagnosis.

**Key Words:** Squamous cell lung carcinoma; Pancreatic metastasis; Jaundice; Esotracheal fistula; Ultrasound endoscopy; Case report

©The Author(s) 2022. Published by Baishideng Publishing Group Inc. All rights reserved.

**Core Tip:** The pancreatic metastasis of squamous lung carcinoma is a rare disease. There are a few cases in the literature that discuss the modality of diagnosis and the treatment of pancreatic metastasis. In this manuscript, we report our experience in the management of this case and the malignant tracheoesophageal fistula as a rare complication of squamous lung carcinoma.

**Citation:** Rais K, El Eulj O, El Moutaoukil N, Kamaoui I, Bennani A, Kharrasse G, Zazour A, Khannoussi W, Ismaili Z. Solitary pancreatic metastasis from squamous cell lung carcinoma: A case report and review of literature. *World J Gastrointest Endosc* 2022; 14(7): 455-466

**URL:** <https://www.wjgnet.com/1948-5190/full/v14/i7/455.htm>

**DOI:** <https://dx.doi.org/10.4253/wjge.v14.i7.455>

## INTRODUCTION

Pancreatic tumors generally have a poor prognosis, and pancreatic cancer ranks as the fourth deadliest type of cancer among men and women[1]. Pancreatic metastases are rare[2]. Their prevalence is estimated at approximately 1%-5%[3]. Renal, lung, colorectal and breast tumors are the main primary tumor sites responsible for pancreatic metastases[2]. We report a case of squamous cell lung carcinoma with pancreatic metastasis in a 56-year-old male patient.

## CASE PRESENTATION

### Chief complaints

A 56-year-old male presented to the emergency room with complaints of cholestatic jaundice associated with pancreatic epigastralgia and deterioration of his general condition.

### History of present illness

The patient reported that his symptoms had started 1 mo prior.

### History of past illness

Three months before admission to our department, he had been diagnosed with and followed up for a left hilar lung squamous cell carcinoma, which had been discovered by bronchoscopy with transbronchial biopsy of the lung mass.

### Personal and family history

The patient self-reported being a 52 pack-year smoker, he had no family history.

### Physical examination

The patient had obvious jaundice. The patient was afebrile but had epigastric tenderness.

### Laboratory examinations

Blood tests showed a disturbance of liver function based on the following findings: total bilirubin, 5.2 mg/dL (normal range: 0.3-1.9 mg/dL); direct bilirubin, 4.1 mg/dL (normal range: 0-0.3 mg/dL); gamma glutamyl transferase, 1088 UI/L (normal range: 12-64 UI/L); alkaline phosphatase, 450 UI/L (normal range: 40-150 UI/L); aspartate aminotransferase, 102 UI/L (normal range: 5-34 UI/L); alanine aminotransferase, 220 UI/L (normal range: 0-55 UI/L); and carbohydrate antigen (CA) 19-9, 40 U/mL

(normal range: 0-33 U/mL).

### **Imaging examinations**

Computed tomographic scanning revealed a tumoral hilar left process, dilation of the intrahepatic bile duct, 11 mm main bile duct and 4 mm Wirsung duct along with a 33 mm × 45 mm pseudotumoral mass of the pancreatic head (Figure 1A and B).

### **Endoscopic examinations**

Endoscopic retrograde cholangiopancreatography was performed and showed dilation of the main bile duct (16 mm) among a stricture (extending to 25 mm) located under the cystic duct. Minimal sphincterotomy was performed, and a plastic stent (10 Fr/7 cm) was placed (Figure 1C). Good drainage was ensured. Histological examination of cytological brushing showed atypical cells, namely, category II of Papanicolaou. The patient's jaundice regressed following these procedures, and his hepatic function blood parameters improved.

### **First multidisciplinary expert consultation**

A multidisciplinary consultation meeting was held. The clinicians decided to begin chemotherapy for lung squamous cell carcinoma.

### **Treatment**

The patient received carboplatin and 80 mg/m<sup>2</sup> paclitaxel every week; however, the treatment was stopped at the 4<sup>th</sup> week due to poor therapeutic tolerance.

### **Outcome**

Over the 4-d period after treatment cessation, the patient developed total aphagia associated with dysphonia. He also developed stage 4 New York Heart Association dyspnea and was deemed to be undernourished (nutritional risk index of 64). His performance status was 3. A computed tomography arterial portography scan showed a locally advanced left hilar mass invading the left main bronchus and fistulating into a paraseptal formation with intimate contact within the esophageal wall (Figure 2A). The imaging examination also showed left lobar broncho-alveolitis and a cephalic pancreatic tumor invading the second duodenum and the antropylic portion with dilation of upstream biliary ducts and no pneumobilia. Esophagogastroduodenoscopy showed a tracheoesophageal fistula located 30 cm from the dental arches that easily crossed (Figure 2B). A biliary stent was observed to partially migrate into the duodenum. EUS showed a 4-cm cephalic pancreatic mass invading the second portion of the duodenum (Figure 3A). Fine-needle (22-G) aspiration of the pancreatic mass was performed and confirmed the presence of a carcinomatous proliferation containing nests and large tumoral polygonal cells with atypical voluminous irregular nuclei surrounded by eosinophils. Focal tumoral necrosis was also present, leading us to conclude that the mass was a well-differentiated keratinizing squamous cell carcinoma. Immunohistochemical examination of the mass showed expression of cytokeratin 5/6 (Figure 3B). On the other hand, the cells did not express TTF1. The final histological report confirmed a poorly differentiated squamous cell lung carcinoma located in the pancreas. To address the migrated biliary stent and to ensure definitive and permanent biliary drainage before treating the tracheoesophageal fistula, endoscopic retrograde cholangiopancreatography was performed first with placement of an uncovered metallic stent measuring 10 cm/10 mm (Figure 4A).

---

## **MULTIDISCIPLINARY EXPERT CONSULTATION**

---

Moulay Zahi Ismaili, Professor and Chief, Department of Hepato-Gastroenterology, Mohammed VI University Hospital Center.

Mohamed Bouziane, Professor and Chief, Department of General Surgery, Mohammed VI University Hospital Center.

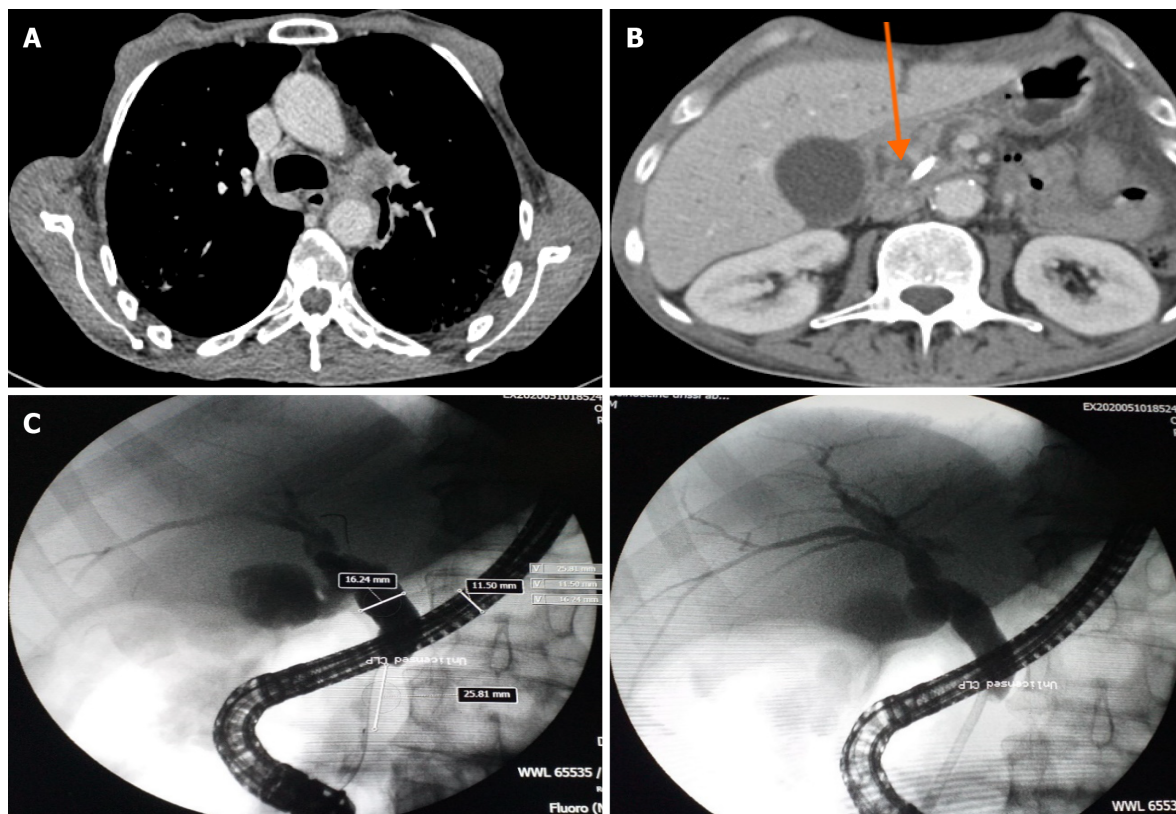
Tijani Harroudi, Professor and Chief, Department of Surgical Oncology, Mohammed VI University Hospital Center.

Ghizlane Kharrasse, Professor of Hepato-Gastroenterology, Department of Hepato-Gastroenterology, Mohammed VI University Hospital Center.

Wafaa Khannoussi, Professor of Hepato-Gastroenterology, Department of Hepato-Gastroenterology, Mohammed VI University Hospital Center.

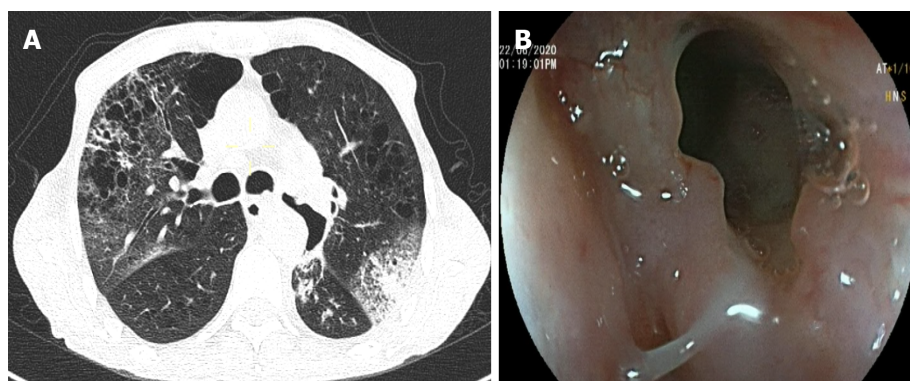
Abdelkrim Zazour, Assistant Professor of Hepato-Gastroenterology, Department of Hepato-Gastroenterology, Mohammed VI University Hospital Center.

The patient's case was rediscussed in multidisciplinary consultation meetings. The decision was made to retain the diagnosis, and a treatment plan was formulated accordingly (detailed below).



DOI: 10.4253/wjge.v14.i7.455 Copyright ©The Author(s) 2022.

**Figure 1** Imaging and endoscopic images of lung cancer and pancreatic mass. A: Computed tomography scan of the left hilar mass (arrow); B: Computed tomography scan of the mass on the head of the pancreas measuring 4.0 cm × 3.8 cm (arrow); C: Microscopic images showed dilatation of the main bile duct upstream of a very tight stenosis of the cystic duct at 25 mm with insertion of a plastic biliary stent.



DOI: 10.4253/wjge.v14.i7.455 Copyright ©The Author(s) 2022.

**Figure 2** Tracheoesophageal fistula. A: Computed tomography scan showed left lobar broncho-alveolitis; B: Upper gastrointestinal endoscopy showed a tracheoesophageal fistulae.

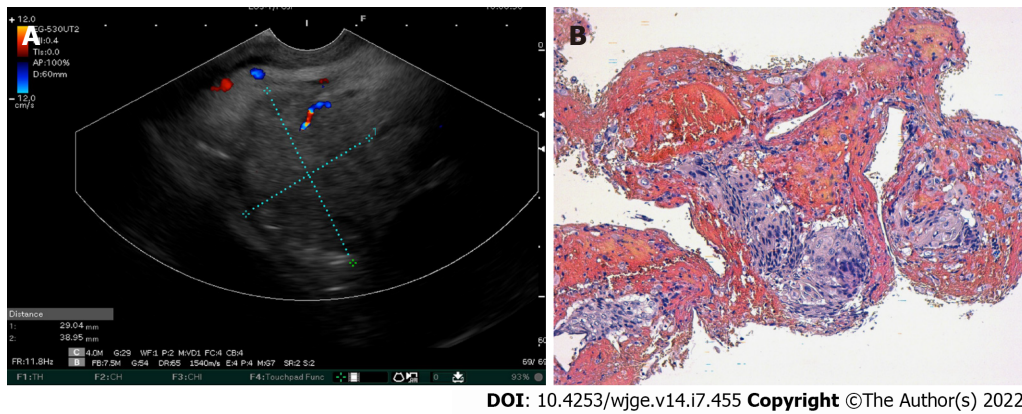
## FINAL DIAGNOSIS

Pancreatic metastasis of squamous cell lung carcinoma, stage IV.

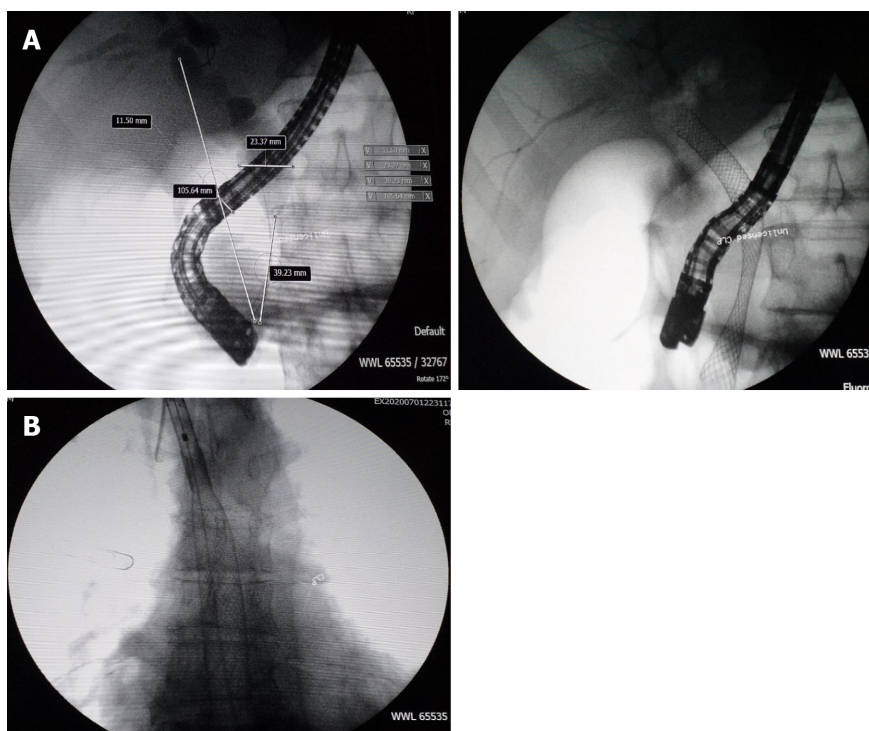
## TREATMENT

A fully covered metallic esophageal stent was placed as a palliative treatment for the tracheoesophageal fistula. Then, a 12-cm stent was placed, the proximal end of which was 24 cm from the dental arches (Figure 4B).





**Figure 3 Images of endoscopic ultrasound and histological analysis of the pancreatic mass.** A: Linear endoscopic ultrasound showed a pancreatic head tumor; B: Microphotography showing a proliferation with an easily recognizable squamous differentiation, including apparent intercellular bridges and minimal pleomorphism. Hematoxylin-eosin stain ( $\times 200$ ).



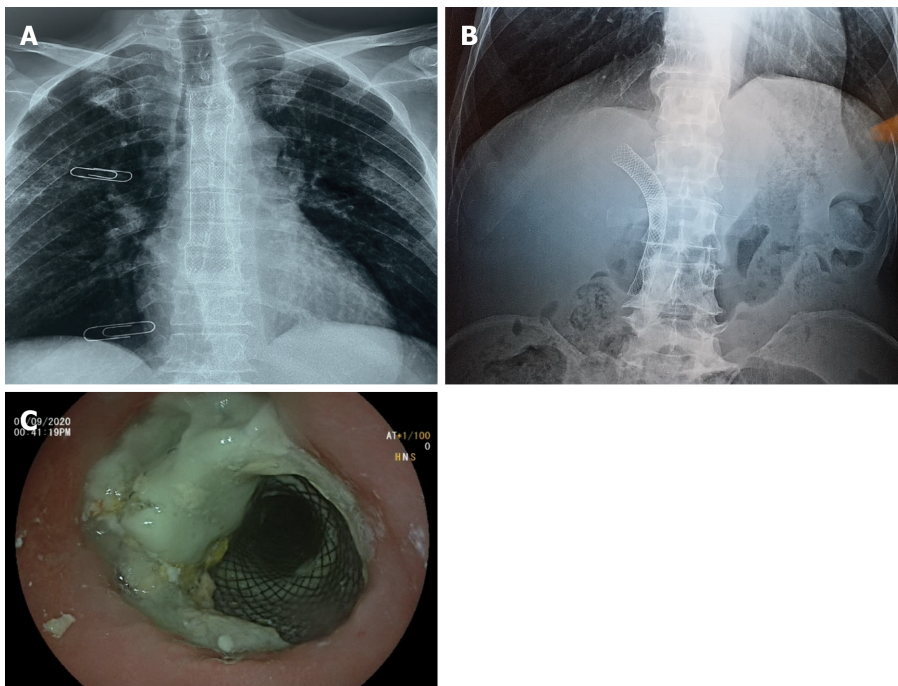
**Figure 4 Placement of metallic biliary stent and esophageal stent.** A: An uncovered metallic biliary stent; B: Microscopic image of the fully-covered esophageal stent.

## OUTCOME AND FOLLOW-UP

During the following 3 mo, the patient was able to gradually start oral alimentation of a mixed-food diet. However, he lost 5 kg of body weight, and his general state was significantly altered. Thus, palliative chemotherapy was not initiated. Two months later, imaging monitoring using thoracic and abdominal X-rays showed a good position of the esophageal and biliary stents (Figure 5A and 5B), which was confirmed by upper digestive endoscopy (Figure 5C). The patient died 9 mo after the diagnosis.

## DISCUSSION

References for this review were identified through searches of the PubMed, Cochrane and Scopus databases using the following Medical Subject Heading terms: (squamous cell lung carcinoma) AND



DOI: 10.4253/wjge.v14.i7.455 Copyright ©The Author(s) 2022.

**Figure 5 Chest X-ray and endoscopic images of stents position.** A: Position of the esophageal prosthesis; B: Abdomen without preparation showed the position of the biliary metallic stent; C: Covered esophageal stent with food stasis.

(pancreatic metastasis). Only English-language journals were considered, and only full papers were included. A total of 201 studies were initially identified. After reviewing the abstracts, 14 articles were identified with topical relevance (*i.e.*, pancreatic metastasis of a squamous cell lung carcinoma). Reference lists of the selected studies were checked (cross-referenced), but no additional studies were identified (Figure 6). We followed the Preferred Reporting Items for Systematic reviews and Meta-analysis guidelines for this literature review. Only 23 cases of squamous cell lung carcinoma with pancreatic metastasis were reported in the literature at the time of this review. The mean age of the reported patients was 61.5 years, and 92.3% of the patients were male. The most common symptom was jaundice (55.6%) followed by epigastric pain (44.6%). One patient (11.2%) was asymptomatic. Pancreatic metastasis was located in the head of the pancreas in 60% of the patients and was located equally in the body, tail and uncinate process in the remaining patients. EUS benefitted 50% of the patients. Among these patients, 3 patients underwent EUS with fine-needle aspiration (FNA), and 2 patients underwent EUS with fine-needle biopsy (Table 1). The diagnosis of pancreatic metastasis due to squamous cell lung carcinoma was established by EUS in 4 patients, by surgery in 3 patients, by percutaneous FNA of the pancreatic tumor in 1 patient, and upon autopsy in 4 patients. Three patients were treated with biliary drainage. Seven patients received chemotherapy. Two patients received surgical treatment for pancreatic metastasis. The follow-up period for reported patients varied between a few days and 1 year, with the latter noted for 1 patient who was treated with surgery and adjuvant chemotherapy[4] (Table 1).

Lung cancer has a very high rate of morbidity and mortality. In 2018, the World Health Organization reported that lung cancer was responsible for 11.6% of new cancer cases and 18.4% of cancer-related deaths[5]. In total, 20% of non-small-cell lung cancers are classified as squamous cell carcinoma[6]. It has been reported that 40% of cases are already metastatic at diagnosis[7], and the 5-year survival rate is estimated to be only 3.6%[6]. The most common metastatic sites include the bones, lungs, brain, liver and adrenal glands[8]. Pancreatic metastasis is rare, representing only 2% of pancreatic tumors[9]. Primary tumors known to metastasize to the pancreas include renal (25%-48%), lung (15%), breast (8%), colorectal (7%), and bone and melanoma (5%)[9,10]. Through the autopsy of 103 cases of patients with pancreatic metastasis, Nakamura *et al*[11] determined that metastatic dissemination to the pancreas occurred either *via* lymphatic (28%), vascular (27%), lymphatic and vascular (19%) or direct invasion (18%) routes. The authors also assumed that the majority of patients with primary lung cancer (66%) had pancreatic metastasis through vascular dissemination. In another report, the most frequent lung cancer histological type with pancreatic metastasis was cited as small cell carcinoma (10%) followed by large cell carcinoma, squamous cell carcinoma (1.1%), and anaplastic bronchial carcinoma[12]. Frequently, pancreatic metastasis is asymptomatic (> 50%) and discovered accidentally through extension and control assessment[13]. It may be expressed by diverse and nonspecific clinical situations, such as asthenia, weight loss, abdominal pain, jaundice, nausea, or vomiting. Pancreatic metastasis can



Table 1 Summary of the literature review of squamous cell lung carcinoma with pancreatic metastasis

Ref.	Yr	Setting	Number	Age in yr	Sex	Symptoms	Imaging	Endoscopy +/- FNA	Diagnostic means	Treatment	Follow-up	Overall survival	Status at time of publication
Zhou <i>et al</i> [29]	2020	China	1	63	M	Epigastric pain with jaundice	Hyperintense mass measuring 4.5 cm in the pancreatic head	No	Surgery of the pancreatic mass	Whipple procedure	UNK	UNK	UNK
Stoupis <i>et al</i> [30]	2020	Greece	1	60	F	Fatigue, cough and hemoptysis, loss of appetite and 10-kg weight loss	Increased 2-deoxy-2-[F-18] fluoro-D-glucose uptake in the right lung and pancreatic tail	Yes	EUS-FNB of the pancreatic mass using a 22-gauge needle	7 cycles of anti-PD-L1 antibody pembrolizumab	UNK	UNK	Alive
Wang <i>et al</i> [4]	2020	China	1	57	M	Asymptomatic	PET-CT scan showed pancreatic metastasis (1 yr after diagnosis of squamous cell lung carcinoma)	No	Laparoscopic radical pancreatic body tail and splenectomy	4 cycles of gemcitabine (1000 mg/m <sup>2</sup> ) plus cisplatin (65 mg/m <sup>2</sup> ) due to progression of the lung mass and the appearance of a tumor in the head of the pancreas. He received 3 cycles of pembrolizumab (2 mg/kg)	1 yr	21.1 mo	Dead
Ishikawa <i>et al</i> [31]	2017	Canada	1	70	M	Abdominal pain and weight loss	3.8 cm hypodense mass in the pancreatic body with lymphadenopathy in the left supraclavicular region and a 3-cm lung mass posterior to the left main stem bronchus	Yes	EUS-FNB of these two lesions with a 25-G needle	Palliative chemotherapy	UNK	UNK	UNK
Fujii <i>et al</i> [32]	2015	Japan	1	70	M	High fever and jaundice 6 mo after left lung inferior lobe resection	Low contrast-enhanced mass with relatively clear border and a size of 40 mm × 33 mm in the head of the pancreas	Yes	FNA <i>via</i> a transgastric approach with linear EUS	5 cycles of carboplatin plus weekly paclitaxel	226 d	UNK	Dead
Dewanwala <i>et al</i> [33]	2012	United States	1	65	M	Dyspnea and recurrent cough	Left hilar mass with an incidental well-defined mass involving the uncinate process of the pancreas measuring 3.7 cm × 2.2 cm	Yes	Pylorus-preserving pancreaticoduodenectomy	Carboplatin plus gemcitabine and completed 5 cycles	17 mo	UNK	Dead
Layfield <i>et al</i> [34]	2010	United States	1	UNK	M	UNK	UNK	Yes	EUS + FNA of the pancreatic mass	UNK	UNK	UNK	UNK
Liratzopoulos <i>et al</i> [23]	2006	Greece	1	53	M	Jaundice, loss of appetite, nausea and mild abdominal pain	CT scan: carcinoma of the lower lobe of the right lung, a tumor in the pancreatic head measuring 4.0 cm × 4.1 cm × 3.5 cm, dilatation of the biliary tract and multiple enlarged lymph nodes in the cervical area, the mediastinum and the abdomen	No	A percutaneous FNA of the pancreatic tumor under CT guidance	Cholecystojejunostomy + dissection of lymph node near the pancreas	19 d	UNK	Dead

Mesa <i>et al</i> [35]	2004	United States	2	UNK	UNK	UNK	Mass in the head of the pancreas measuring 3.6 cm and a lung tumor	Yes	EUS-FNA of the pancreatic mass	UNK	UNK	UNK	UNK
Volkan <i>et al</i> [36]	2004	United States	5 of 109 autopsy cases	UNK	UNK	UNK	UNK	UNK	Autopsy	UNK	UNK	UNK	Dead
Tetsuya <i>et al</i> [37]	2003	Japan	1	69	M	Jaundice	Lung tumor with hilar and mediastinal lymph node swelling and solitary pancreatic head tumor measuring 3 cm	No	Autopsy	Endoscopic nasobiliary drainage and stent drainage therapy prior to chemotherapy using gemcitabine	4 mo	UNK	Dead
Moazzam <i>et al</i> [38]	2002	United States	1	54	M	Anorexia, abdominal pain and jaundice	Mass in right upper lung lobe and mass in the head of pancreas	No	Biopsy of the right upper lobe lung mass	Biliary drainage + carboplatin and paclitaxel	UNK	UNK	Alive: good clinical and radiographic response
Nakamura <i>et al</i> [11]	2001	Japan	3 of 103 autopsy cases	UNK	UNK	UNK	UNK	UNK	Autopsy	UNK	UNK	UNK	Dead
Matsukuma <i>et al</i> [39]	1997	Japan	3	55	M	UNK	UNK	No	Autopsy	UNK	UNK	UNK	Dead
				64	M								
				58	M								

CT: Computed tomography; EUS: Endoscopic ultrasound; F: Female; FNA: Fine-needle aspiration; FNB: Fine-needle biopsy; M: Male; PD-L1: Programmed death ligand 1; PET: Positron emission tomography; UNK: Unknown.

manifest as upper gastrointestinal bleeding or acute pancreatitis, which were reported in 3 cases[14] and 13 cases[12], respectively. According to Deluzio *et al*[15], 59% of patients with pancreatic metastasis had gastrointestinal symptoms, mostly represented by jaundice and abdominal pain. Jaundice is explained by the obstruction of extrahepatic biliary ducts by pancreatic metastasis, which is essentially observed in small cell lung cancer[16]. The diagnosis of pancreatic metastasis and the differentiation of primary and metastatic tumors represent significant challenges. Pancreatic metastasis shows varied enhancement when imaged. Klein *et al*[17] reported that 76% of pancreatic metastases showed greater vascular enhancement than normal pancreatic parenchyma or primary pancreatic tumors, which is explained by the richness of metastatic vascularization. EUS is the main exam for pancreatic lesions and their locoregional extension. The sensitivity of EUS is estimated at 100% for tumors < 2 cm, whereas the sensitivity values of ultrasound and abdominal scan are 60% and 50%, respectively[16]. A retrospective study by El Hajj *et al*[10] included 49 patients with pancreatic metastasis and found that the lesions were hypoechoic in 80% of patients, hyperechoic in 4% of patients, mixed in 4% of patients, and anechoic in 2% of patients. Regular boundaries were observed in 55% of cases. To confirm the diagnosis, cytological analysis was used in 63% of cases, whereas immunohistochemical analysis was added to the former technique in 33% of these cases. Dewitt *et al*[18] demonstrated that EUS-FNA confirmed the diagnosis of pancreatic metastasis in all patients with a secondary pancreatic tumor. They also deduced that the only ultrasound data that could differentiate between primary and secondary pancreatic tumors involved the

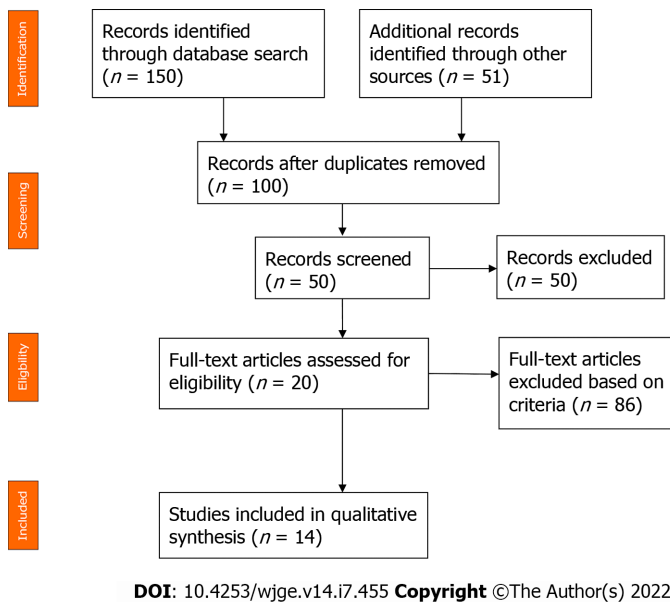


Figure 6 Flow diagram of the literature review of squamous cell lung carcinoma with pancreatic metastasis.

lesion margins. Margins were well defined when the tumor was secondary (46% *vs* 4%) and irregular in 94% of primary pancreatic tumors (94% *vs* 54%) ( $P < 0.0001$ ). However, no significant differences were noted between primary and metastatic pancreatic tumors regarding tumor number, size, location, or echogenicity parameters. For metastatic lung cancer, therapeutic care consists of palliative chemotherapy and biliary drainage when the tumor compresses the biliary ducts. According to the National Comprehensive Cancer Network guidelines, metastatic squamous cell carcinoma treatment depends on the patient's performance status[19]. These options should be discussed during the multidisciplinary expert consultation. Regimens of pembrolizumab, carboplatin and paclitaxel or pembrolizumab, carboplatin, paclitaxel and albumin are used as the first-line treatment for patients whose performance status is 0 to 1. When the performance status is 2, carboplatin, paclitaxel and albumin or carboplatin and gemcitabine or carboplatin and paclitaxel are the recommended therapeutic options. Our patient had a performance status of 2, indicating that he should be treated with carboplatin and paclitaxel. However, this treatment was stopped due to intolerance. Recently, many scientific publications have discussed the surgical treatment of oligometastatic lung cancer in the pancreas. Kageyama *et al*[3] reported a unique case of a 67-year-old patient who had lung cancer with a pancreatic metastasis that was randomly discovered during follow-up tests 6 years after the primary tumor diagnosis. The patient underwent a distal pancreatectomy and ganglion dissection, which led to survival at 5 years without any recurrence. Ida *et al*[20] showed a longer survival of 8 years in a 70-year-old male patient with metastatic squamous cell lung carcinoma who underwent a total pancreatectomy and a resection of the portal vein. According to a Japanese retrospective study that evaluated global survival in patients receiving a surgical operation for pancreatic metastasis, 6 of the 9 patients survived for more than 23.5 mo. However, patients with longer survival times had pancreatic tumors secondary to renal cancer[21]. Generally, pancreatic metastasis of squamous cell lung carcinoma is discovered at an advanced stage[22], and only 2% of the tumors are resectable[23], revealing why surgical treatment is rarely utilized. Moreover, this case is unusual given the presence of a malignant tracheoesophageal fistula as a rare complication of squamous cell lung carcinoma. Malignant tracheoesophageal or bronchoesophageal fistula develops in 5%-15% of patients with esophageal cancer, and only 0.2% of lung malignancies have been reported to cause esophageal pulmonary fistulae[24]. In patients with prior lung or esophageal cancer, the presence of symptoms, such as dysphagia, recurrent pneumonia or treatment-resistant pneumonia, should raise concern as to whether an underlying fistula is present. If not detected early or left untreated, the fistulae may lead to pneumonitis and lung abscesses that cause sepsis, acute respiratory distress syndrome, and death. In addition, without treatment, the median survival may be 1-6 wk[25]. There is no cure for malignant tracheoesophageal fistulae, and palliative procedures, such as esophageal stenting, esophageal exclusion, esophageal bypass or surgical repair with fistula resection, may prolong survival and provide immediate symptom relief. Based on a comparative study of the survival time and quality of life of patients who received different treatments for tracheoesophageal fistulae, self-expandable stenting did not significantly prolong the survival time of patients but did remarkably improve health-related quality of life[26]. The European Society of Gastrointestinal Endoscopy recommends esophageal self-expandable metallic stent placement as the preferred treatment for sealing malignant tracheoesophageal fistulae[27]. However, the reported success rates of esophageal stent placement vary from 70% to 100%. In addition, some complications may occur,

such as stent migration, bleeding, granulation formation, foreign body sensation, and secondary fistulae, all of which have been reported as late complications of stenting[24]. In our case, the malignant tracheoesophageal fistula was successfully treated by an fully covered esophageal metallic stent. Unfortunately, our patient died 6 mo after the diagnosis of pancreatic metastasis. This was not surprising because stage IV squamous cell lung carcinoma with pancreatic metastasis has a poor prognosis in general with an average reported survival of 8.7 mo after diagnosis[28].

## CONCLUSION

Squamous cell lung carcinoma with pancreatic metastasis is rare, and its diagnosis represents a challenge for clinicians. Radiological, endoscopic and anatomopathological methods are needed for an accurate diagnosis. EUS-FNA is the ideal procedure to diagnose pancreatic metastasis. This disease has a poor prognosis because it is generally detected at an advanced stage. Thus, the treatment is typically palliative.

## ACKNOWLEDGEMENTS

I am grateful to all of those with whom I have had the pleasure to work during this and other related projects. Each of the members of Hepato-Gastroenterology Department has provided me extensive personal and professional guidance and taught me a great deal about both scientific research and life in general.

## FOOTNOTES

**Author contributions:** Rais K and El Eulj O reviewed the literature and contributed to writing of the manuscript; El Moutaoukil N collected the patient's clinical data; Zazour A, Khannoussi W and Ismaili MZ contributed in performing endoscopic retrograde cholangiopancreatography and endoscopic ultrasound + fine-needle aspiration and correcting the manuscript for important intellectual content; Kharrasse G participated in the multidisciplinary consultation meetings and in confirmation of the patient's diagnosis; Kamaoui I interpreted the imaging findings; Bennani A analyzed the biopsies of the pancreatic mass; all authors read and approved the manuscript.

**Informed consent statement:** Informed written consent was obtained from the patient for publication of this report and any accompanying images.

**Conflict-of-interest statement:** All authors declare they have no conflicts of interest.

**CARE Checklist (2016) statement:** The authors have read the CARE Checklist (2016), and the manuscript was prepared and revised according to the CARE Checklist (2016).

**Open-Access:** This article is an open-access article that was selected by an in-house editor and fully peer-reviewed by external reviewers. It is distributed in accordance with the Creative Commons Attribution NonCommercial (CC BY-NC 4.0) license, which permits others to distribute, remix, adapt, build upon this work non-commercially, and license their derivative works on different terms, provided the original work is properly cited and the use is non-commercial. See: <https://creativecommons.org/licenses/by-nc/4.0/>

**Country/Territory of origin:** Morocco

**ORCID number:** Kaouthar Rais 0000-0002-9896-3336; Oumayma El Eulj 0000-0002-8545-8832.

**S-Editor:** Wang LL

**L-Editor:** A

**P-Editor:** Wang LL

## REFERENCES

- 1 **Tempero MA**, Malafa MP, Al-Hawary M, Behrman SW, Benson AB, Cardin DB, Chiorean EG, Chung V, Czito B, Del Chiaro M, Dillhoff M, Donahue TR, Dotan E, Ferrone CR, Fountzilas C, Hardacre J, Hawkins WG, Klute K, Ko AH, Kunstman JW, LoConte N, Lowy AM, Moravek C, Nakakura EK, Narang AK, Obando J, Polanco PM, Reddy S, Reynold M, Scaife C, Shen J, Vollmer C, Wolff RA, Wolpin BM, Lynn B, George GV. Pancreatic Adenocarcinoma, Version 2.2021, NCCN Clinical Practice Guidelines in Oncology. *J Natl Compr Canc Netw* 2021; **19**: 439-457 [PMID: 33845462 DOI: 10.6004/jnccn.2021.0017]

- 2 **Bush A**, Humes R, Young P. Colon Cancer Metastatic to the Pancreas Presenting as of Diabetic Ketoacidosis. *ACG Case Rep J* 2020; 7: e00455 [PMID: 33134401 DOI: 10.14309/crj.0000000000000455]
- 3 **Kageyama Y**, Yamaguchi R, Watanabe S, Aizu K, Sato F, Fujieda H, Yamada M, Toyoda Y, Iwata T. A long-term survival case after resection of the pancreatic metastasis from lung cancer. *Int J Surg Case Rep* 2019; 61: 222-225 [PMID: 31377549 DOI: 10.1016/j.ijscr.2019.07.060]
- 4 **Wang W**, Huang C, Wu S, Liu Z, Liu L, Li L, Li S. Abscopal effect induced by modulated radiation therapy and pembrolizumab in a patient with pancreatic metastatic lung squamous cell carcinoma. *Thorac Cancer* 2020; 11: 2014-2017 [PMID: 32391640 DOI: 10.1111/1759-7714.13427]
- 5 **Namayandeh SM**, Khazaei Z, Lari Najafi M, Goodarzi E, Moslem A. GLOBAL Leukemia in Children 0-14 Statistics 2018, Incidence and Mortality and Human Development Index (HDI): GLOBOCAN Sources and Methods. *Asian Pac J Cancer Prev* 2020; 21: 1487-1494 [PMID: 32458660 DOI: 10.31557/apjcp.2020.21.5.1487]
- 6 **Dela Cruz CS**, Tanoue LT, Matthay RA. Lung cancer: epidemiology, etiology, and prevention. *Clin Chest Med* 2011; 32: 605-644 [PMID: 22054876 DOI: 10.1016/j.ccm.2011.09.001.Lung]
- 7 **Xu Z**, Yang Q, Chen X, Zheng L, Zhang L, Yu Y, Chen M, You Q, Sun J. Clinical associations and prognostic value of site-specific metastases in non-small cell lung cancer: A population-based study. *Oncol Lett* 2019; 17: 5590-5600 [PMID: 31186781 DOI: 10.3892/ol.2019.10225]
- 8 **Tamura T**, Kurishima K, Nakazawa K, Kagohashi K, Ishikawa H, Satoh H, Hizawa N. Specific organ metastases and survival in metastatic non-small-cell lung cancer. *Mol Clin Oncol* 2015; 3: 217-221 [PMID: 25469298 DOI: 10.3892/mco.2014.410]
- 9 **Dar FS**, Mukherjee S, Bhattacharya S. Surgery for secondary tumors of the pancreas. *HPB (Oxford)* 2008; 10: 498-500 [PMID: 19088939 DOI: 10.1080/13651820802356598]
- 10 **El Hajj II**, LeBlanc JK, Sherman S, Al-Haddad MA, Cote GA, McHenry L, DeWitt JM. Endoscopic ultrasound-guided biopsy of pancreatic metastases: a large single-center experience. *Pancreas* 2013; 42: 524-530 [PMID: 23146924 DOI: 10.1097/mpa.0b013e31826b3acf]
- 11 **Nakamura E**, Shimizu M, Itoh T, Manabe T. Secondary tumors of the pancreas: clinicopathological study of 103 autopsy cases of Japanese patients. *Pathol Int* 2001; 51: 686-690 [PMID: 11696171 DOI: 10.1046/j.1440-1827.2001.01258.x]
- 12 **Woo JS**, Joo KR, Woo YS, Jang JY, Chang YW, Lee J 2nd, Chang R. Pancreatitis from metastatic small cell lung cancer successful treatment with endoscopic intrapancreatic stenting. *Korean J Intern Med* 2006; 21: 256-261 [PMID: 17249510 DOI: 10.3904/kjim.2006.21.4.256]
- 13 **Zerbi A**, Pecorelli N. Pancreatic metastases: An increasing clinical entity. *World J Gastrointest Surg* 2010; 2: 255-259 [PMID: 21160884 DOI: 10.4240/wjgs.v2.i8.255]
- 14 **Zheng Y**, Gao Q, Fang W, Xu N, Zhou J. Gastrointestinal bleeding due to pancreatic metastasis of non-small cell lung cancer: A report of two cases and a literature review. *Oncol Lett* 2015; 9: 2041-2045 [PMID: 26137009 DOI: 10.3892/ol.2015.3035]
- 15 **DeLuzio MR**, Moores C, Dhamija A, Wang Z, Cha C, Boffa DJ, Dettterbeck FC, Kim AW. Resection of oligometastatic lung cancer to the pancreas may yield a survival benefit in select patients--a systematic review. *Pancreatolgy* 2015; 15: 456-462 [PMID: 25900320 DOI: 10.1016/j.pan.2015.03.014]
- 16 **Chaudhari D**, Khanna A, Goenka P, Young M. Lung carcinoma presenting as an obstructive jaundice: case series with literature review. *J Gastrointest Cancer* 2014; 45 Suppl 1: 66-70 [PMID: 23999821 DOI: 10.1007/s12029-013-9545-z]
- 17 **Klein KA**, Stephens DH, Welch TJ. CT characteristics of metastatic disease of the pancreas. *Radiographics* 1998; 18: 369-378 [PMID: 9536484 DOI: 10.1148/radiographics.18.2.9536484]
- 18 **DeWitt J**, Jowell P, Leblanc J, McHenry L, McGreevy K, Cramer H, Volmar K, Sherman S, Gress F. EUS-guided FNA of pancreatic metastases: a multicenter experience. *Gastrointest Endosc* 2005; 61: 689-696 [PMID: 15855973 DOI: 10.1016/s0016-5107(05)00287-7]
- 19 **Ettinger DS**, Wood DE, Aggarwal C, Aisner DL, Akerley W, Bauman JR, Bharat A, Bruno DS, Chang JY, Chirieac LR, D'Amico TA, Dilling TJ, Dobelbower M, Gettinger S, Govindan R, Gubens MA, Hennon M, Horn L, Lackner RP, Lanuti M, Leal TA, Lin J, Loo BW Jr, Martins RG, Otterson GA, Patel SP, Reckamp KL, Riely GJ, Schild SE, Shapiro TA, Stevenson J, Swanson SJ, Tauer KW, Yang SC, Gregory K; OCN, Hughes M. NCCN Guidelines Insights: Non-Small Cell Lung Cancer, Version 1.2020. *J Natl Compr Canc Netw* 2019; 17: 1464-1472 [PMID: 31805526 DOI: 10.6004/jnccn.2019.0059]
- 20 **Toshiharu IDA**, Masafumi YOSHIDA KN and KI. An eight-year survivor after the resection of a metastatic pancreatic tumor of pulmonary carcinoma. *J JPN surg Assoc* 2006 [DOI: 10.3919/jjsa.67.1894]
- 21 **Yagi T**, Hashimoto D, Taki K, Yamamura K, Chikamoto A, Ohmuraya M, Beppu T, Baba H. Surgery for metastatic tumors of the pancreas. *Surg Case Rep* 2017; 3: 31 [PMID: 28214950 DOI: 10.1186/s40792-017-0308-0]
- 22 **Machairas N**, Paspala A, Schizas D, Ntomi V, Moris D, Tsilimigras DI, Misiakos EP, Machairas A. Metastatic squamous cell carcinoma to the pancreas: Report of an extremely rare case. *Mol Clin Oncol* 2019; 10: 144-146 [PMID: 30655990 DOI: 10.3892/mco.2018.1756]
- 23 **Liratzopoulos N**, Efremidou EI, Papageorgiou MS, Romanidis K, Minopoulos GJ, Manolas KJ. Extrahepatic biliary obstruction due to a solitary pancreatic metastasis of squamous cell lung carcinoma. Case report. *J Gastrointest Liver Dis* 2006; 15: 73-75 [PMID: 16680238]
- 24 **Buemi L**, Stefanelli S, Bichard P, Luscher M, Becker M. Esophageal pulmonary fistula - a rare complication of radiation therapy: a case report. *J Med Case Rep* 2018; 12: 116 [PMID: 29716653 DOI: 10.1186/s13256-018-1658-3]
- 25 **Sebastian J**, Kirankumar VS, Pappachan JM, Zachariah SA, Radha TR, Sujathan P. Multifactorial dysphagia complicated by esophago-bronchial fistula. *J Cancer Res Ther* 2007; 3: 108-110 [PMID: 17998735 DOI: 10.4103/0973-1482.34691]
- 26 **Hu Y**, Zhao YF, Chen LQ, Zhu ZJ, Liu LX, Wang Y, Kou YL. Comparative study of different treatments for malignant tracheoesophageal/bronchoesophageal fistulae. *Dis Esophagus* 2009; 22: 526-531 [PMID: 19302211 DOI: 10.1111/j.1442-2050.2009.00950.x]
- 27 **Spaander MC**, Baron TH, Siersema PD, Fuccio L, Schumacher B, Escorsell A, Garcia-Pagán JC, Dumonceau JM, Conio M, de Ceglie A, Skowronek J, Nordmark M, Seufferlein T, Van Gossum A, Hassan C, Repici A, Bruno MJ. Esophageal



- stenting for benign and malignant disease: European Society of Gastrointestinal Endoscopy (ESGE) Clinical Guideline. *Endoscopy* 2016; **48**: 939-948 [PMID: 27626318 DOI: 10.1055/s-0042-114210]
- 28 **Roland CF**, van Heerden JA. Nonpancreatic primary tumors with metastasis to the pancreas. *Surg Gynecol Obstet* 1989; **168**: 345-347 [PMID: 2928909]
- 29 **Zhou W**, Dong H, Dong A. Isolated Pancreatic Metastasis From Squamous Cell Lung Cancer Mimicking Primary Pancreatic Ductal Adenocarcinoma on FDG PET/CT. *Clin Nucl Med* 2020; **45**: 420-422 [PMID: 32149802 DOI: 10.1097/RLU.0000000000002986]
- 30 **Stoupis I**, Voudoukis E, Mastorakis E, Kazamias G, Ieromonachou P, Pappas C. A Rare Pancreatic Tail Metastasis from Squamous Cell Lung Carcinoma Diagnosed by EUS-FNB and a Small Review of the Literature. *GE Port J Gastroenterol* 2020; **27**: 29-32 [PMID: 31970237 DOI: 10.1159/000497387]
- 31 **Ishikawa T**, Hirooka Y, Teman CJ, Goto H, Belletrutti PJ. An Unusual Case of Pancreatic Metastasis from Squamous Cell Carcinoma of the Lung Diagnosed by EUS-Guided Fine Needle Biopsy. *Case Rep Gastrointest Med* 2017; **2017**: 3212056 [PMID: 28596924 DOI: 10.1155/2017/3212056]
- 32 **Fujii M**, Watanabe K, Kataoka M, Nose S, Shiode J. A case of a pancreatic tumor that was diagnosed as metastasis from lung cancer by endoscopic ultrasound-guided fine needle aspiration. *J Med Ultrason (2001)* 2015; **42**: 405-408 [PMID: 26576794 DOI: 10.1007/s10396-015-0614-8]
- 33 **Dewanwala A**, Kotowski A, LeVea CM, Ma WW. Secondary Tumors of the Pancreas: Case Report and a Single-Center Experience. *J Gastrointest Cancer* 2012; **43** Suppl 1: S117-S124 [PMID: 21909632 DOI: 10.1007/s12029-011-9317-6]
- 34 **Layfield LJ**, Hirschowitz SL, Adler DG. Metastatic disease to the pancreas documented by endoscopic ultrasound guided fine-needle aspiration: a seven-year experience. *Diagn Cytopathol* 2012; **40**: 228-233 [PMID: 22334524 DOI: 10.1002/dc.21564]
- 35 **Mesa H**, Stelow EB, Stanley MW, Mallery S, Lai R, Bardales RH. Diagnosis of nonprimary pancreatic neoplasms by endoscopic ultrasound-guided fine-needle aspiration. *Diagn Cytopathol* 2004; **31**: 313-318 [PMID: 15468134 DOI: 10.1002/dc.20142]
- 36 **Adsay NV**, Andea A, Basturk O, Kilinc N, Nassar H, Cheng JD. Secondary tumors of the pancreas: an analysis of a surgical and autopsy database and review of the literature. *Virchows Arch* 2004; **444**: 527-535 [PMID: 15057558 DOI: 10.1007/s00428-004-0987-3]
- 37 **Kubota T**, Ikezoe T, Harada R, Nakata H, Kobayashi M, Taguchi H. Pancreatic metastasis from lung cancer: report of an autopsy case. *Nihon Kokyuki Gakkai Zasshi* 2003; **41**: 917-921 [PMID: 14727556]
- 38 **Moazzam N**, Mir A, Potti A. Pancreatic metastasis and extrahepatic biliary obstruction in squamous cell lung carcinoma. *Med Oncol* 2002; **19**: 273-276 [PMID: 12512922 DOI: 10.1385/mo:19:4:273]
- 39 **Matsukuma S**, Suda K, Abe H, Ogata S, Wada R. Metastatic cancer involving pancreatic duct epithelium and its mimicry of primary pancreatic cancer. *Histopathology* 1997; **30**: 208-213 [PMID: 9088948 DOI: 10.1046/j.1365-2559.1997.d01-604.x]



Published by **Baishideng Publishing Group Inc**  
7041 Koll Center Parkway, Suite 160, Pleasanton, CA 94566, USA

**Telephone:** +1-925-3991568

**E-mail:** [bpgoffice@wjgnet.com](mailto:bpgoffice@wjgnet.com)

**Help Desk:** <https://www.f6publishing.com/helpdesk>

<https://www.wjgnet.com>

