

World Journal of *Gastrointestinal Endoscopy*

World J Gastrointest Endosc 2022 September 16; 14(9): 512-580



MINIREVIEWS

- 512** Simulation-based mastery learning in gastrointestinal endoscopy training
Maulahela H, Annisa NG, Konstantin T, Syam AF, Soetikno R

ORIGINAL ARTICLE

Case Control Study

- 524** Endoscopic ultrasound elastography for malignant pancreatic masses and associated lymph nodes: Critical evaluation of strain ratio cutoff value
Puga-Tejada M, Del Valle R, Oleas R, Egas-Izquierdo M, Arevalo-Mora M, Baquerizo-Burgos J, Ospina J, Soria-Alcivar M, Pitanga-Lukashok H, Robles-Medrande C

Retrospective Study

- 536** Screening for hilar biliary invasion in ampullary cancer patients
Takagi T, Sugimoto M, Suzuki R, Konno N, Asama H, Sato Y, Irie H, Nakamura J, Takasumi M, Hashimoto M, Kato T, Kobashi R, Yanagita T, Hashimoto Y, Marubashi S, Hikichi T, Ohira H

- 547** Endoscopic therapy using a self-expandable metallic stent with an anti-migration system for postorthotopic liver transplantation anastomotic biliary stricture
Pinheiro LW, Martins FP, De Paulo GA, Contini MLC, Ferrari AP, Della Libera E

Observational Study

- 555** Clinical profile, diagnostic yield, and procedural outcomes of single balloon enteroscopy: A tertiary care hospital experience
Inam M, Karim MM, Tariq U, Ismail FW

Prospective Study

- 564** Role of endoscopic ultrasound in evaluation of patients with missed common bile duct stones
Eissa M, Okasha HH, Abbasy M, Khamis AK, Abdellatef A, Rady MA

CASE REPORT

- 575** Isolated esophageal tuberculosis: A case report
Diallo I, Touré O, Sarr ES, Sow A, Ndiaye B, Diawara PS, Dial CM, Mbengue A, Fall F

ABOUT COVER

Editorial Board Member of *World Journal of Gastrointestinal Endoscopy*, Giuseppe Di Buono, MD, PhD, Doctor, Lecturer, Research Assistant Professor, Department of Surgical, Oncological and Oral Sciences, University of Palermo, Palermo 90127, Italy. giuseppe.dibuono@unipa.it

AIMS AND SCOPE

The primary aim of *World Journal of Gastrointestinal Endoscopy* (WJGE, *World J Gastrointest Endosc*) is to provide scholars and readers from various fields of gastrointestinal endoscopy with a platform to publish high-quality basic and clinical research articles and communicate their research findings online.

WJGE mainly publishes articles reporting research results and findings obtained in the field of gastrointestinal endoscopy and covering a wide range of topics including capsule endoscopy, colonoscopy, double-balloon enteroscopy, duodenoscopy, endoscopic retrograde cholangiopancreatography, endosonography, esophagoscopy, gastrointestinal endoscopy, gastroscopy, laparoscopy, natural orifice endoscopic surgery, proctoscopy, and sigmoidoscopy.

INDEXING/ABSTRACTING

The WJGE is now abstracted and indexed in Emerging Sources Citation Index (Web of Science), PubMed, PubMed Central, Reference Citation Analysis, China National Knowledge Infrastructure, China Science and Technology Journal Database, and Superstar Journals Database. The 2022 edition of Journal Citation Reports® cites the 2021 Journal Citation Indicator (JCI) for WJGE as 0.33.

RESPONSIBLE EDITORS FOR THIS ISSUE

Production Editor: Yi-Xuan Cai; Production Department Director: Xu Guo; Editorial Office Director: Jia-Ping Yan.

NAME OF JOURNAL

World Journal of Gastrointestinal Endoscopy

ISSN

ISSN 1948-5190 (online)

LAUNCH DATE

October 15, 2009

FREQUENCY

Monthly

EDITORS-IN-CHIEF

Anastasios Koulaouzidis, Bing Hu, Sang Chul Lee, Joo Young Cho

EDITORIAL BOARD MEMBERS

<https://www.wjgnet.com/1948-5190/editorialboard.htm>

PUBLICATION DATE

September 16, 2022

COPYRIGHT

© 2022 Baishideng Publishing Group Inc

INSTRUCTIONS TO AUTHORS

<https://www.wjgnet.com/bpg/gerinfo/204>

GUIDELINES FOR ETHICS DOCUMENTS

<https://www.wjgnet.com/bpg/GerInfo/287>

GUIDELINES FOR NON-NATIVE SPEAKERS OF ENGLISH

<https://www.wjgnet.com/bpg/gerinfo/240>

PUBLICATION ETHICS

<https://www.wjgnet.com/bpg/GerInfo/288>

PUBLICATION MISCONDUCT

<https://www.wjgnet.com/bpg/gerinfo/208>

ARTICLE PROCESSING CHARGE

<https://www.wjgnet.com/bpg/gerinfo/242>

STEPS FOR SUBMITTING MANUSCRIPTS

<https://www.wjgnet.com/bpg/GerInfo/239>

ONLINE SUBMISSION

<https://www.f6publishing.com>



Retrospective Study

Endoscopic therapy using a self-expandable metallic stent with an anti-migration system for postorthotopic liver transplantation anastomotic biliary stricture

Larissa Wermelinger Pinheiro, Fernanda Prata Martins, Gustavo Andrade De Paulo, Mônica Lúcia Campos Contini, Angelo Paulo Ferrari, Ermelindo Della Libera

Specialty type: Gastroenterology and hepatology

Provenance and peer review:

Unsolicited article; Externally peer reviewed.

Peer-review model: Single blind

Peer-review report's scientific quality classification

Grade A (Excellent): 0
Grade B (Very good): 0
Grade C (Good): C, C
Grade D (Fair): D
Grade E (Poor): 0

P-Reviewer: Ferrarese A, Italy;
Lynch EN, Italy

Received: February 3, 2022

Peer-review started: February 3, 2022

First decision: April 12, 2022

Revised: April 19, 2022

Accepted: August 6, 2022

Article in press: August 6, 2022

Published online: September 16, 2022



Larissa Wermelinger Pinheiro, Angelo Paulo Ferrari, Ermelindo Della Libera, Department of Gastroenterology, Federal University of São Paulo/Escola Paulista de Medicina, São Paulo 04023-900, Brazil

Fernanda Prata Martins, Gustavo Andrade De Paulo, Mônica Lúcia Campos Contini, Angelo Paulo Ferrari, Ermelindo Della Libera, Department of Endoscopy Unit, Hosp Israelita Albert Einstein, São Paulo 04042033, Brazil

Corresponding author: Ermelindo Della Libera, MD, PhD, Adjunct Associate Professor, Department of Endoscopy Unit, Hosp Israelita Albert Einstein, Rua Ruggero Fsano, s/n - Pavilhão Vick e Joseph Safra - Piso I3 - Morumbi - SP, São Paulo 04026001, Brazil.
edellaliberajr@uol.com.br

Abstract

BACKGROUND

Endoscopic therapy using multiple plastic stents (MPSs) is the standard therapy for postorthotopic liver transplantation (p-OLT) anastomotic biliary stricture (AB-S). However, this approach demands repeated procedures. Recent studies using fully covered self-expandable metallic stents (FCSEMS) have shown encouraging results, but migration occurs in 10% to 40% of cases. The objective of this retrospective study was to evaluate the efficacy of endoscopic treatment using FCSEMS with an anti-migration system (Am-FCSEMS) in patients with p-OLT ABS.

AIM

To evaluate the efficacy of endoscopic treatment using an Am-FCSEMS in patients with p-OLT ABS.

METHODS

This study was conducted in a private tertiary care centre in São Paulo, Brazil and was approved by our institution's Human Research Committee. From April 2018 to October 2020, regardless of previous endoscopic treatment (MPS or FCSEMS), 17 patients with p-OLT ABS and indications for endoscopic therapy were included in this study. The exclusion criteria were pregnancy, nonanastomotic

biliary or hilar stricture, hepatic artery stenosis/thrombosis, isolated biliary fistulae, a distance shorter than 2 cm from the stricture to the hepatic hilum, and patient refusal. The primary end-point was the efficacy of p-OLT ABS endoscopic treatment using an Am-FCSEMS that re-mained in place for a 12-mo period. Biliary sphincterotomy was performed in patients with native papilla, and an Am-FCSEMS (10 mm in final diameter and 60 or 80 mm in length) was placed (Hanarostent™ MI Tech, Co). Balloon stricture dilation was performed only if necessary to introduce the stent.

RESULTS

Three patients were excluded due to loss to follow-up before stent removal. Among the 14 patients included and followed, 7 were women, and the average age was 56 years (range: 28-76). The average period of Am-FCSEMS placement was 362 ± 109 d. Technical success occurred in all 14 patients (100%). There were no cases of distal stent migration. Complete resolution of the stricture occurred in 13/14 patients (92.85%). Adverse events occurred in 3/14 patients (21.42%): 2 patients with mild acute pancreatitis (14.28%) and 1 patient (7.14%) with stent dysfunction (occlusion by biliary sludge and stones, which was treated endoscopically without the need for stent removal). No deaths occurred related to therapy. All stents were removed using foreign body forceps or snares without difficulty. After Am-FCSEMS removal, all 13 patients who had ABS resolution were followed-up for an average of 411 ± 172 d, and there was no stricture recurrence or need for further endoscopic therapy.

CONCLUSION

In this retrospective study, endoscopy therapy using an Am-FCSEMS for p-OLT ABS was safe and effective, with a high stricture re-resolution rate that was probably due to the absence of stent migration.

Key Words: Liver transplantation; Endoscopy; Endoscopic retrograde cholangiopancreatography; Biliary strictures; Self-expandable metallic biliary stents

©The Author(s) 2022. Published by Baishideng Publishing Group Inc. All rights reserved.

Core Tip: This retrospective study evaluated the efficacy of endoscopic treatment using an anti-migration fully covered self-expandable metallic stents (Am-FCSEMS) in patients with postorthotopic liver transplantation (p-OLT) anastomotic biliary stricture (ABS). Technical success occurred in all patients (100%). Stricture resolution occurred in 13/14 patients (92.85%). Adverse events occurred in 3/14 patients (21.42%). There were no cases of distal stent migration. After Am-FCSEMS removal, all 13 patients who had ABS resolution were followed-up for an average of 411 d, and there was no stricture recurrence or need for further endoscopic therapy. Endoscopic therapy using an Am-FCSEMS for p-OLT ABS is safe and effective, with a high stricture resolution rate, probably due to the absence of stent migration.

Citation: Pinheiro LW, Martins FP, De Paulo GA, Contini MLC, Ferrari AP, Della Libera E. Endoscopic therapy using a self-expandable metallic stent with an anti-migration system for postorthotopic liver transplantation anastomotic biliary stricture. *World J Gastrointest Endosc* 2022; 14(9): 547-554

URL: <https://www.wjgnet.com/1948-5190/full/v14/i9/547.htm>

DOI: <https://dx.doi.org/10.4253/wjge.v14.i9.547>

INTRODUCTION

Biliary tract lesions are common postoperative adverse events (AEs) after orthotopic liver transplantation (OLT). Anastomotic biliary strictures (ABSs) occur most frequently and are responsible for approximately 40% of all complications after OLT[1-4].

Endoscopic balloon dilation followed by placement of side-by-side multiple plastic stents (MPSs) in repeated procedures every 3-4 mo, up to 12 mo, is the standard treatment for ABS. This treatment strategy has a high success rate, ranging from 70% to 100%[1,5].

Despite such a high success rate, this strategy demands repeated procedures[1,6-9]. Recent studies using fully covered self-expandable metallic stents (FCSEMS) have shown encouraging results, with resolution rates similar to those observed with the MPS strategy[5,7,10]. However, a high FCSEMS migration rate of between 10% and 40% has been reported, which is a possible limitation for its use[5-7, 10].

We hypothesized that a FCSEMS with an anti-migration system (Am-FCSEMS) could be an alternative for postorthotopic-OLT (p-OLT) ABS treatment. Recently, a study with promising results compared the use of an Am-FCSEMS with other types of conventional metallic stents in regards to the p-OLT ABS resolution rate and their respective migration rates[11].

The objective of this study was to evaluate the efficacy of endoscopic treatment using an Am-FCSEMS in patients with p-OLT ABS.

MATERIALS AND METHODS

This study was conducted at Hospital Israelita Albert Einstein (HIAE), São Paulo, Brazil. HIAE is a private tertiary care referral centre where approximately 150 OLTs are performed yearly.

Patients

From April 2018 to October 2020, 17 patients between 18 and 76 years of age diagnosed with p-OLT ABS who were referred to the endoscopy unit were considered for inclusion in this retrospective study, regardless of previous endoscopic treatment (MPS or FCSEMS). The exclusion criteria were pregnancy, nonanastomotic biliary or hilar stricture, hepatic artery stenosis/thrombosis, isolated biliary fistulae, and patient refusal. To avoid the risk of biliary intrahepatic duct occlusion secondary to stent placement, a distance shorter than 2 cm from the stricture to the hepatic hilum was also considered an exclusion criterion.

This study was conducted in accordance with the World Medical Association Declaration of Helsinki Ethical Principles for Medical Research Involving Human Subjects and was approved by our institution's Human Research Committee. The patients provided written informed consent prior to inclusion in the study.

Procedures

Endoscopic retrograde cholangiopancreatography (ERCP) was performed using a therapeutic video duodenoscope (TJF-180 Olympus Optical Co., Ltd., Tokyo, Japan) with patients under monitored anaesthesia. After selective biliary cannulation, cholangiography was performed for the evaluation and characterization of biliary stricture, followed by the passage of a guidewire. After positioning the guidewire, biliary sphincterotomy was performed in patients with native papilla, and an Am-FCSEMS (10 mm in final diameter and 60 or 80 mm in length, BCT Hanarostent™ M.I. Tech, Co.) was placed (Figure 1A and B). Balloon dilation of the stricture was performed only if necessary to introduce the stent. According to the physician's choice, the length of the stent was determined during cholangiography to place the proximal end between the stricture and the hepatic hilum and the distal end in the duodenum. Patients were followed up for clinical signs of biliary obstruction and scheduled to have the stent removed after 12 mo if no complications occurred.

Endpoints

The primary study endpoint was the efficacy of the endoscopic treatment of p-OLT ABS using an Am-FCSEMS for a 12-mo period. Efficacy was evaluated based on ABS resolution. After stent removal, the biliary stricture was considered resolved if there was no stricture observed on cholangiography or a minimum stricture that allowed the passage of a 12-mm inflated extractor balloon without difficulty. Secondary endpoints were technical success (defined as stent placement), adverse effects related to ERCP (bleeding or pancreatitis), and stent dysfunction (migration or obstruction).

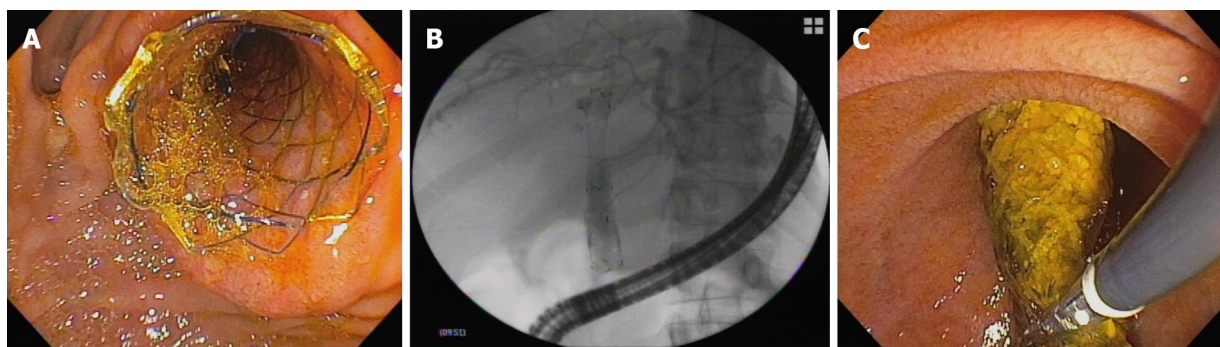
RESULTS

A total of 17 patients were included. Three patients were excluded due to loss to follow-up before stent removal (12 mo) (Figure 2). The average age of the 14 patients included and followed was 56 years (range: 28-76); 7 women had an average age of 42 ± 11.2 years, and 7 men had an average age of 69 ± 5.8 years. Patient characteristics are shown in Table 1. Among the 14 patients, 8 (57.14%) had already undergone treatment with FCSEMS and/or MPSs, but endoscopic management was considered unsuccessful, with an average number of procedures before inclusion in this study of 2.25 ± 1.04 (range: 1-4). The other 6 patients (42.85%) received an Am-FCSEMS as the first treatment. Regardless of previous treatment, the average interval from p-OLT to the first ERCP was 116 wk (range: 4-570). The average duration of placement of an Am-FCSEMS in this study was 362 ± 109 d (range: 226-609). The length of stent placement was 6 cm in 8 patients and 8 cm in 6 patients. Technical success (stent placement) occurred in all 14 patients (100%). The clinical follow-up after stent removal was 411 ± 172 d (range: 55-692). All stents were removed using foreign body forceps or snares without any technical difficulty (Figure 1C).

Table 1 Demographics of patients and baseline characteristics

Overall patient characteristics	Results
No. of patients, <i>n</i>	14
Gender, female sex, <i>n</i> (%)	7 (50)
Age (yr), mean (range)	56 (28-76)
Cause of liver transplant: <i>n</i>	
HBV	2
HBV + HCV	1
Alcohol	3
Cryptogenic	2
NASH	1
Autoimmune hepatitis	2
Primary biliary cirrhosis	1
Familial amyloidosis	1
Primary hyperoxaluria	1
Presence of HCC: <i>n</i>	4
Time from OLT to ERCP (wk)	
mean \pm SD	116 \pm 156
Median	45
Range	4-570
Patients with previous endoscopic treatment before Am-FCSEMS, <i>n</i> (%)	8 (57.14)
Procedures before Am-FCSEMS (mean)	2.25
Patients with no previous endoscopic treatment, <i>n</i> (%)	6 (42.86)

HBV: Hepatitis B virus; HCV: Hepatitis C virus; NASH: Nonalcoholic steatohepatitis; HCC: Hepatocellular carcinoma; ERCP: Endoscopic retrograde cholangiopancreatography; Am-FCSEMS: Fully covered self-expandable metal stents with anti-migration flaps.



DOI: 10.4253/wjge.v14.i9.547 Copyright ©The Author(s) 2022.

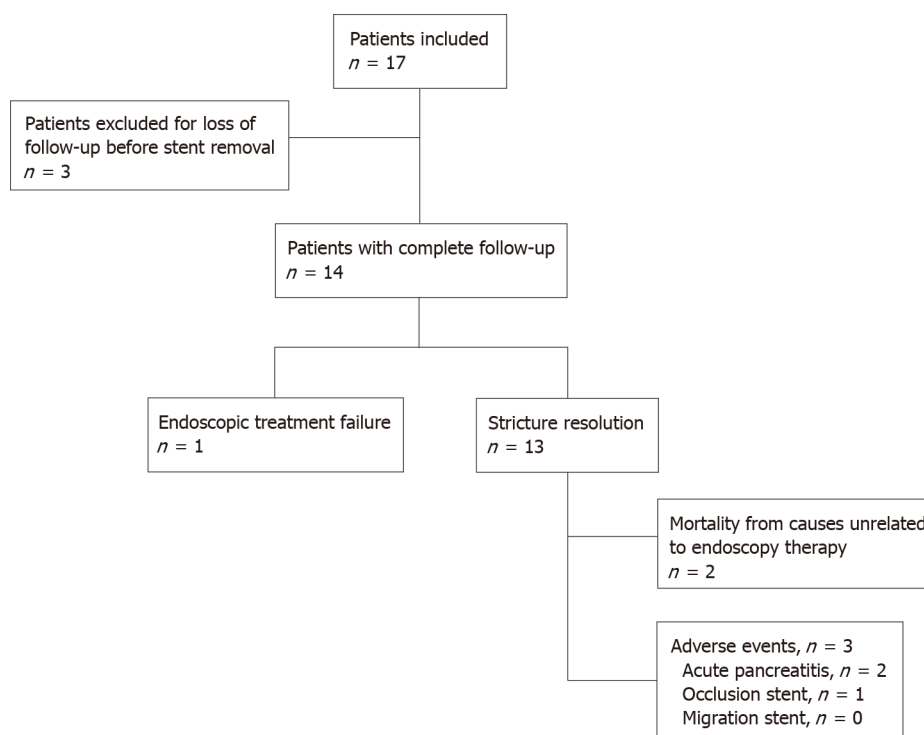
Figure 1 Images of the fully covered self-expandable metallic stent with an anti-migration system or flaps. A: Endoscopic view of the stent; B: Radiographic view of the stent in the biliary tract; C: Removal of the stent.

Complete resolution of the stricture occurred in 13/14 patients (92.85%). Only 1 patient (7.14%) experienced endoscopic treatment failure after 338 d with the stent in place, which was determined by cholangiography as persistence of stricture. This patient was referred for endoscopic treatment using MPSs for a longer period. AEs occurred in 3 out of 14 patients (21.42%). There were 2 patients (14.28%) with mild acute pancreatitis and 1 patient (7.14%) with stent dysfunction (occlusion by biliary sludge and stones with cholangitis), which was treated endoscopically without the need for stent removal. There was no distal migration of the stent in any patient (Table 2). There was no mortality related to ERCP and/or endoscopic therapy with the stent. After removal of the Am-FCSEMS, all 13 patients who

Table 2 Overall results

Overall results	
No. of patients, <i>n</i>	14
Technical success, <i>n</i> (%)	14 (100)
Stricture resolution, <i>n</i> (%)	13 (92.85)
Treatment failure, <i>n</i> (%)	1 (7.14)
Mean ALT before stent (U/L)	144
Mean ALT at the end of follow-up (U/L)	16
Mean total bilirubin before stent (mg/dL)	1.88
Mean total bilirubin at the end of follow-up (mg/dL)	0.49
Stricture recurrence, <i>n</i>	0
Stent migration	0
Other complications, <i>n</i> (%)	3 (21.42)
Acute pancreatitis	2 (14.28)
Stent occlusion	1 (7.14)
Mean follow-up after stent removal (d)	411 ± 172

ALT: Alanine aminotransferase.



DOI: 10.4253/wjge.v14.i9.547 Copyright ©The Author(s) 2022.

Figure 2 Flowchart of the selection of patients in the study.

had ABS resolution were followed-up (411 ± 172 d), and there was no need for further endoscopic therapy or stricture recurrence. Two patients died from causes unrelated to endoscopy therapy.

DISCUSSION

Our present study shows that p-OLT ABS treatment with an Am-FCSEMS is effective and safe, with a stricture resolution rate of 92.85%, which is comparable to the results of other studies involving MPSs[5, 9,12] and FCSEMSs[5,7,13]. In our study, the average time between liver transplantation and endoscopy therapy for ABS was lengthy (116 wk), which may have impacted the results and thus, is a possible limitation of this study[3,6,8]. Nevertheless, our results were comparable with those of other studies that used this anti-migration stent model[11].

The longer stent maintenance period (12 mo) in our study in relation to other studies with metallic stents[2,7] and the absence of migration possibly related to the antimigration mechanism may have contributed to the favourable result observed in our patients.

The technical success rate of 100% in this series, which is comparable to that in other studies[6,12,14], demonstrates the applicability of this technique. No patients experienced distal migration of the stent. As described in previous studies, the main disadvantage of using FCSEMS is the high migration rate of up to 37.5%[10,12,14,15]. It is possible that treatment with an Am-FCSEMS may present better results due to the lower risk of migration and longer stent patency. Although in our study assessment of costs was not an included objective, it is possible that since this stent has a lower migration rate its use could result in a lower number of procedures and thus lower costs, but this hypothesis should be verified in future controlled studies.

The AEs observed with ERCP-related therapy and/or stenting were mild pancreatitis and delayed stent obstruction. All patients in whom the stent was placed underwent biliary sphincterotomy, and mild acute pancreatitis was related to the ERCP procedure in 2 out of the 14 patients (14.2%). Despite this higher rate of complications compared to that in the literature[5-7,13], these patients underwent successful clinical treatment. Stent dysfunction (obstruction) occurred late and was caused by biliary sludge or stones, with jaundice and cholangitis occurring in only one patient (7.1%). This complication and its endoscopic treatment with or without stent replacement is described in the literature[5,6]. This patient was treated with antibiotics and endoscopy without the need for stent replacement.

No complications occurred during stent removal. In this study, no serious complications or deaths related to endoscopic treatment were reported. The average follow-up of patients who had stricture resolution after removal of the metallic stent was 411 d. There was no ABS recurrence during follow-up. This positive result may be related to the prolonged maintenance of the metallic stent, which was longer than 6 mo[2,5].

Considering the treatment of patients with p-OLT ABS, the use of FCSEMSs may be an interesting alternative in relation to MPS therapy, considering FCSEMS placement presents comparable results with fewer ERCP procedures[4,5,7,10]. However, spontaneous stent migration may be a limitation of FCSEMS placement[10,12,14].

This retrospective study has some limitations, such as a small sample size from a single centre. Another limiting point for this study is the lack of a control group. However, our results showed that treatment with Am-FCSEMS can be an alternative for patients with p-OLT ABS. Therefore, prospective and comparative studies should be encouraged to evaluate the efficacy of endoscopic treatment using Am-FCSEMS versus MPSs. Nevertheless, we present similar results for the resolution of ABS compared to those in other studies using MPSs and FCSEMSs as well as a recent study using an Am-FCSEMS. In this series, the advantage of treatment using an Am-FCSEMS in relation to treatment with MPSs was the need for only two ERCP procedures over 12 mo, while the advantage in relation to FCSEMS therapy was the absence of migration.

CONCLUSION

In conclusion, in this retrospective study, endoscopy therapy using an Am-FCSEMS or flaps for p-OLT ABS is safe and effective, with the stricture's high-resolution rate probably being due to the absence of stent migration.

ARTICLE HIGHLIGHTS

Research background

Endoscopic therapy using multiple plastic stents is the standard therapy for postorthotopic liver transplantation (p-OLT) anastomotic biliary stricture (ABS). However, this approach demands repeated procedures. Recent studies using fully covered self-expandable metallic stents (FCSEMS) have shown encouraging results, but migration occurs in 10% to 40% of cases. We hypothesized that a FCSEMS with an anti-migration system (Am-FCSEMS) could be an alternative for treatment in patients with p-OLT ABS.

Research motivation

The efficacy of treatment using an Am-FCSEMS for p-OLT ABS is not yet well established. The outcomes of endoscopic treatment using this type of stent have become clinically relevant.

Research objectives

This study aimed to evaluate the efficacy of endoscopic treatment using an Am-FCSEMS in patients with p-OLT ABS.

Research methods

This study was conducted in a private tertiary care centre in São Paulo, Brazil. From April 2018 to October 2020, patients with p-OLT ABS and indications for endoscopic therapy were included in this study, and an Am-FCSEMS (10 mm in final diameter and 60 or 80 mm in length) was placed (Hanarostent MI Tech, Co).

Research results

Technical success occurred in all 14 patients (100%). There were no cases of distal stent migration. Complete resolution of the stricture occurred in 13/14 patients (92.85%). Adverse events occurred in 3/14 patients (21.42%): 2 patients with mild acute pancreatitis and 1 patient with stent dysfunction (occlusion). No deaths occurred related to therapy. After Am-FCSEMS removal, all 13 patients who had ABS resolution were followed-up for an average of 411 ± 172 d, and there was no stricture recurrence or need for further endoscopic therapy.

Research conclusions

Endoscopy therapy using an Am-FCSEMS for p-OLT ABS is safe and effective, with the stricture's high-resolution rate probably being due to the absence of stent migration.

Research perspectives

This study shows that treatment using Am-FCSEMS has a high rate of stenosis resolution, probably due to the absence of stent migration, and may result in a lower number of procedures.

FOOTNOTES

Author contributions: Pinheiro LW, Martins FP, Contini MLC, and De Paulo GA contributed to the data acquisition; Pinheiro LW, De Paulo GA, Ferrari AP, and Della Libera E contributed to the data analysis and interpretation; Pinheiro LW contributed to the elaboration of article draft; Martins FP and Contini MLC contributed to the elaboration and review of article draft, critical review for important intellectual content; De Paulo GA contributed to the critical review of final paper for important intellectual content; Ferrari AP and Della Libera E contributed to the critical review and approval of the final submitted version.

Institutional review board statement: This retrospective study was approved by the Institution's Human Research Committee of Hospital Israelita Albert Einstein (No. 37755020.3.0000.0071).

Informed consent statement: All study participants, or their legal guardian, provided informed written consent.

Data sharing statement: No additional data are available.

Open-Access: This article is an open-access article that was selected by an in-house editor and fully peer-reviewed by external reviewers. It is distributed in accordance with the Creative Commons Attribution NonCommercial (CC BY-NC 4.0) licence, which permits others to distribute, remix, adapt, and build upon this work noncommercially and licence their derivative works on different terms, provided the original work is properly cited and the use is noncommercial. See <https://creativecommons.org/licenses/by-nc/4.0/>

Country/Territory of origin: Brazil

ORCID number: Larissa Wermelinger Pinheiro 0000-0003-2272-4715; Fernanda Prata Martins 0000-0002-7017-9910; Gustavo Andrade De Paulo 0000-0002-7926-9373; Mônica Lúcia Campos Contini 0000-0002-1532-787X; Angelo Paulo Ferrari 0000-0002-7062-288X; Ermelindo Della Libera 0000-0002-1098-7975.

S-Editor: Yan JP

L-Editor: A

P-Editor: Yan JP

REFERENCES

- 1 **Williams ED**, Draganov PV. Endoscopic management of biliary strictures after liver transplantation. *World J Gastroenterol* 2009; **15**: 3725-3733 [PMID: [19673012](#) DOI: [10.3748/wjg.15.3725](#)]
- 2 **Thuluvath PJ**, Pfau PR, Kimmey MB, Ginsberg GG. Biliary complications after liver transplantation: the role of endoscopy. *Endoscopy* 2005; **37**: 857-863 [PMID: [16116539](#) DOI: [10.1055/s-2005-870192](#)]
- 3 **Pascher A**, Neuhaus P. Biliary complications after deceased-donor orthotopic liver transplantation. *J Hepatobiliary Pancreat Surg* 2006; **13**: 487-496 [PMID: [17139421](#) DOI: [10.1007/s00534-005-1083-z](#)]
- 4 **Ryu CH**, Lee SK. Biliary strictures after liver transplantation. *Gut Liver* 2011; **5**: 133-142 [PMID: [21814591](#) DOI: [10.5009/gnl.2011.5.2.133](#)]
- 5 **Coté GA**, Slivka A, Tarnasky P, Mullady DK, Elmunzer BJ, Elta G, Fogel E, Lehman G, McHenry L, Romagnuolo J, Menon S, Siddiqui UD, Watkins J, Lynch S, Denski C, Xu H, Sherman S. Effect of Covered Metallic Stents Compared With Plastic Stents on Benign Biliary Stricture Resolution: A Randomized Clinical Trial. *JAMA* 2016; **315**: 1250-1257 [PMID: [27002446](#) DOI: [10.1001/jama.2016.2619](#)]
- 6 **Devière J**, Nageshwar Reddy D, Püspök A, Ponchon T, Bruno MJ, Bourke MJ, Neuhaus H, Roy A, González-Huix Lladó F, Barkun AN, Kortan PP, Navarrete C, Peetermans J, Blero D, Lakhtakia S, Dolak W, Lepilliez V, Poley JW, Tringali A, Costamagna G; Benign Biliary Stenoses Working Group. Successful management of benign biliary strictures with fully covered self-expanding metal stents. *Gastroenterology* 2014; **147**: 385-95; quiz e15 [PMID: [24801350](#) DOI: [10.1053/j.gastro.2014.04.043](#)]
- 7 **Martins FP**, De Paulo GA, Contini MLC, Ferrari AP. Metal versus plastic stents for anastomotic biliary strictures after liver transplantation: a randomized controlled trial. *Gastrointest Endosc* 2018; **87**: 131.e1-131.e13 [PMID: [28455159](#) DOI: [10.1016/j.gie.2017.04.013](#)]
- 8 **Sharma S**, Gurakar A, Jabbour N. Biliary strictures following liver transplantation: past, present and preventive strategies. *Liver Transpl* 2008; **14**: 759-769 [PMID: [18508368](#) DOI: [10.1002/lt.21509](#)]
- 9 **Krok KL**, Cárdenas A, Thuluvath PJ. Endoscopic management of biliary complications after liver transplantation. *Clin Liver Dis* 2010; **14**: 359-371 [PMID: [20682241](#) DOI: [10.1016/j.cld.2010.03.008](#)]
- 10 **Jiménez-Pérez M**, Melgar Simón JM, Durán Campos A, González Grande R, Rodrigo López JM, Manteca González R. Endoscopic Management of Post-Liver Transplantation Biliary Strictures With the Use of Fully Covered Metallic Stents. *Transplant Proc* 2016; **48**: 2510-2514 [PMID: [27742337](#) DOI: [10.1016/j.transproceed.2016.09.008](#)]
- 11 **Bordaça B**, Perdigao F, Leblanc S, Barret M, Duchmann JC, Guillaumot MA, Chaussade S, Scatton O, Prat F. Clinical efficacy of anti-migration features in fully covered metallic stents for anastomotic biliary strictures after liver transplantation: comparison of conventional and anti-migration stents. *Gastrointest Endosc* 2018; **88**: 655-664 [PMID: [30003877](#) DOI: [10.1016/j.gie.2018.06.035](#)]
- 12 **García-Pajares F**, Sánchez-Antolín G, Pelayo SL, Gómez de la Cuesta S, Herranz Bachiller MT, Pérez-Miranda M, de La Serna C, Vallecillo Sande MA, Alcaide N, Llamas RV, Pacheco D, Caro-Patón A. Covered metal stents for the treatment of biliary complications after orthotopic liver transplantation. *Transplant Proc* 2010; **42**: 2966-2969 [PMID: [20970584](#) DOI: [10.1016/j.transproceed.2010.07.084](#)]
- 13 **Kahaleh M**, Behm B, Clarke BW, Brock A, Shami VM, De La Rue SA, Sundaram V, Tokar J, Adams RB, Yeaton P. Temporary placement of covered self-expandable metal stents in benign biliary strictures: a new paradigm? *Gastrointest Endosc* 2008; **67**: 446-454 [PMID: [18294506](#) DOI: [10.1016/j.gie.2007.06.057](#)]
- 14 **Traina M**, Tarantino I, Barresi L, Volpes R, Gruttadauria S, Petridis I, Gridelli B. Efficacy and safety of fully covered self-expandable metallic stents in biliary complications after liver transplantation: a preliminary study. *Liver Transpl* 2009; **15**: 1493-1498 [PMID: [19877248](#) DOI: [10.1002/lt.21886](#)]
- 15 **Tarantino I**, Traina M, Mocciano F, Barresi L, Curcio G, Di Pisa M, Granata A, Volpes R, Gridelli B. Fully covered metallic stents in biliary stenosis after orthotopic liver transplantation. *Endoscopy* 2012; **44**: 246-250 [PMID: [22354824](#) DOI: [10.1055/s-0031-1291465](#)]



Published by **Baishideng Publishing Group Inc**
7041 Koll Center Parkway, Suite 160, Pleasanton, CA 94566, USA

Telephone: +1-925-3991568

E-mail: bpgoffice@wjgnet.com

Help Desk: <https://www.f6publishing.com/helpdesk>

<https://www.wjgnet.com>

