

World Journal of *Gastrointestinal Endoscopy*

World J Gastrointest Endosc 2023 January 16; 15(1): 1-18



MINIREVIEWS

- 1 Gastric cancer in 2022: Is there still a role for endoscopic ultrasound?

Rossi G, Petrone MC, Healey AJ, Arcidiacono PG

CASE REPORT

- 10 Upper gastrointestinal bleeding as an unusual manifestation of localized Ménétrier's disease with an underlying lipoma: A case report

Kmiecik M, Walczak A, Samborski P, Paszkowski J, Dobrowolska A, Karczewski J, Swora-Cwynar E

ABOUT COVER

Editorial Board Member of *World Journal of Gastrointestinal Endoscopy*, Amosy E M'Koma, MD, MSc, PhD, Academic Editor, Consultant Physician-Scientist, Professor, Department of Biochemistry, Cancer Biology, Neuroscience and Pharmacology, Meharry Medical College School of Medicine and Vanderbilt University Medical Center, Nashville, TN 37208-3501, United States. amkoma@mmc.edu

AIMS AND SCOPE

The primary aim of *World Journal of Gastrointestinal Endoscopy* (WJGE, *World J Gastrointest Endosc*) is to provide scholars and readers from various fields of gastrointestinal endoscopy with a platform to publish high-quality basic and clinical research articles and communicate their research findings online.

WJGE mainly publishes articles reporting research results and findings obtained in the field of gastrointestinal endoscopy and covering a wide range of topics including capsule endoscopy, colonoscopy, double-balloon enteroscopy, duodenoscopy, endoscopic retrograde cholangiopancreatography, endosonography, esophagoscopy, gastrointestinal endoscopy, gastroscopy, laparoscopy, natural orifice endoscopic surgery, proctoscopy, and sigmoidoscopy.

INDEXING/ABSTRACTING

The WJGE is now abstracted and indexed in Emerging Sources Citation Index (Web of Science), PubMed, PubMed Central, Reference Citation Analysis, China National Knowledge Infrastructure, China Science and Technology Journal Database, and Superstar Journals Database. The 2022 edition of Journal Citation Reports® cites the 2021 Journal Citation Indicator (JCI) for WJGE as 0.33.

RESPONSIBLE EDITORS FOR THIS ISSUE

Production Editor: Yi-Xuan Cai; Production Department Director: Xu Guo; Editorial Office Director: Yun-Xiao Jiao Wu.

NAME OF JOURNAL

World Journal of Gastrointestinal Endoscopy

ISSN

ISSN 1948-5190 (online)

LAUNCH DATE

October 15, 2009

FREQUENCY

Monthly

EDITORS-IN-CHIEF

Anastasios Koulaouzidis, Bing Hu, Sang Chul Lee, Joo Young Cho

EDITORIAL BOARD MEMBERS

<https://www.wjgnet.com/1948-5190/editorialboard.htm>

PUBLICATION DATE

January 16, 2023

COPYRIGHT

© 2023 Baishideng Publishing Group Inc

INSTRUCTIONS TO AUTHORS

<https://www.wjgnet.com/bpg/gerinfo/204>

GUIDELINES FOR ETHICS DOCUMENTS

<https://www.wjgnet.com/bpg/GerInfo/287>

GUIDELINES FOR NON-NATIVE SPEAKERS OF ENGLISH

<https://www.wjgnet.com/bpg/gerinfo/240>

PUBLICATION ETHICS

<https://www.wjgnet.com/bpg/GerInfo/288>

PUBLICATION MISCONDUCT

<https://www.wjgnet.com/bpg/gerinfo/208>

ARTICLE PROCESSING CHARGE

<https://www.wjgnet.com/bpg/gerinfo/242>

STEPS FOR SUBMITTING MANUSCRIPTS

<https://www.wjgnet.com/bpg/GerInfo/239>

ONLINE SUBMISSION

<https://www.f6publishing.com>



Gastric cancer in 2022: Is there still a role for endoscopic ultrasound?

Gemma Rossi, Maria Chiara Petrone, Andrew J Healey, Paolo Giorgio Arcidiacono

Specialty type: Gastroenterology and hepatology

Provenance and peer review: Invited article; Externally peer reviewed.

Peer-review model: Single blind

Peer-review report's scientific quality classification

Grade A (Excellent): 0
Grade B (Very good): B
Grade C (Good): C
Grade D (Fair): D
Grade E (Poor): 0

P-Reviewer: Imai Y, Japan; Yuan X, China

Received: October 3, 2022

Peer-review started: October 3, 2022

First decision: November 2, 2022

Revised: November 7, 2022

Accepted: December 21, 2022

Article in press: December 21, 2022

Published online: January 16, 2023



Gemma Rossi, Maria Chiara Petrone, Paolo Giorgio Arcidiacono, Pancreato-Biliary Endoscopy and Endosonography Division, Pancreas Translational and Clinical Research Center, San Raffaele Scientific Institute IRCCS, Vita Salute San Raffaele University, Milan 20132, Italy

Andrew J Healey, Department of Clinical Surgery, University of Edinburgh, Royal Infirmary of Edinburgh, Edinburgh EH16 4SA, United Kingdom

Corresponding author: Gemma Rossi, MD, Consultant Physician-Scientist, Pancreato-Biliary Endoscopy and Endosonography Division, Pancreas Translational and Clinical Research Center, San Raffaele Scientific Institute IRCCS, Vita Salute San Raffaele University, Olgettina Str. 60, Milan 20132, Italy. rossi.gemma@hsr.it

Abstract

Gastric cancer (GC) represents the fourth leading cause of cancer death worldwide and many factors can influence its development (diet, geographic area, genetic, Helicobacter pylori or Epstein-Barr virus infections). High quality endoscopy represents the modality of choice for GC diagnosis. The correct morphologic classification during a high-resolution endoscopy is fundamental for oncologic diagnosis, staging and therapeutic decisions. Since its initial introduction in clinical practice the endoscopic ultrasound (EUS) has been considered a valuable tool for tumor (T-) and lymph nodes (N-) staging also in GC, in order to establish the best therapeutic strategy for the patient (e.g., upfront surgery vs neoadjuvant treatments). EUS tools as elastography, Doppler and contrast administration can improve diagnosis mainly in case of malignant lymph node evaluation. EUS has a marginal role in disease staging but has a fundamental role in case of a pre-endoscopic resection management and in the new era of endoscopic mucosal resection or submucosal dissection as minimally invasive surgery. Diagnosis and locoregional staging of GC with EUS are a method of inarguable value for the assessment of gastric wall involvement and presence of infiltrated paragastric lymph nodes. EUS can also have a role in disease restaging in those patients who have undergone neoadjuvant treatment. EUS can also have a role in the advanced phases of the disease, in facilitating palliative, minimally-invasive treatments, such as gastroenterostomy or biliary drainages. This review intends to discuss the modern role of EUS in GC topic.

Key Words: Gastric cancer; Endoscopic ultrasound; Endoscopic resection; Neoadjuvant chemotherapy; Therapeutic endoscopic ultrasound

Core Tip: Since its initial introduction in clinical practice endoscopic ultrasound has been considered a valuable tool for tumor and lymph nodes staging of gastric cancer, in order to establish the best therapeutic strategy for the patient. Moreover, in this new era of endoscopic mucosal resection or submucosal dissection and minimally invasive surgery, endoscopic ultrasound is increasingly important for early gastric cancer staging and therapeutic decision making and it can also have a role in the advanced phases of the disease, in facilitating palliative, minimally-invasive treatments.

Citation: Rossi G, Petrone MC, Healey AJ, Arcidiacono PG. Gastric cancer in 2022: Is there still a role for endoscopic ultrasound? *World J Gastrointest Endosc* 2023; 15(1): 1-9

URL: <https://www.wjgnet.com/1948-5190/full/v15/i1/1.htm>

DOI: <https://dx.doi.org/10.4253/wjge.v15.i1.1>

INTRODUCTION

Gastric cancer (GC) represents the fourth leading cause of cancer death worldwide with a median survival less than 12 mo in advanced disease[1], and a global incidence that has decreased in the last few decades due to lifestyle improvement.

The incidence of GC is greater in men and certain geographic areas and many factors can influence its development, both environmental and genetic[2]. Risk factors for the development of GC are numerous. A significant impact on GC incidence is patient dietary habits (certain foods, alcohol consumption), smoking history, family history and *Helicobacter pylori* or Epstein-Barr virus infections[3].

Outcomes are favorable if cancer precursors are detected early and a high quality endoscopy represents the modality of choice for diagnosis in this phase. Moreover, GC morphologic classification at endoscopy is fundamental for oncologic diagnosis, staging and therapeutic decision making[4]. Furthermore, accurate clinical classification is important in determining cancer prognosis.

There are several options for GC treatment, however an accurate preoperative diagnosis is important to select the appropriate therapeutic decision. Endoscopic resection represents an option in early phases of disease and at the other end of the disease spectrum, neoadjuvant treatment indications have been expanded in locally-advanced cancers.

Several Classifications distinguish the tumor extension, histologic features or morphologic appearance at endoscopy.

CLASSIFICATIONS

Staging

The American Joint Committee on Cancer and the Union for International Cancer Control published their last edition of cancer staging systems in 2017 with Tumor Node Metastasis (TNM) system, employed for GC clinical and pathologic staging. TNM system represents cancer extension: T is tumor depth in the gastric wall, N the number of regional lymph nodes involved and M the presence of distant metastasis[5,6], as represented in Table 1.

According to TNM staging an early GC (EGC) is defined as a lesion limited to the gastric mucosa or submucosa (T1 at TNM staging) irrespective of lymph nodes spread. An advanced cancer is a lesion invading the muscularis propria of the gastric wall or a cancer going beyond it[7]. The scope to resect with a minimally-invasive endoscopic resection in EGCs has increased and the specific evaluation of all the gastric layers with a highly-sensitive method such as endoscopic ultrasound (EUS) is central to deciding the best resection approach following the cancer extension (T).

In the new classification, if the tumor with its epicenter is located >2 cm from esophagogastric junction (EGJ) or it is located within 2 cm from EGJ but not involving the junction itself, this is considered as a gastric tumor. By proxy, the tumor with its epicenter located within 2 cm of EGJ involving the junction itself, this is considered as an esophageal tumor[8].

Morphology

High-definition video-endoscopes have facilitated the detection and diagnosis of GC and enable the treatment of early phase EGCs with a minimal-invasive endoscopic resection in selected patients. The importance of endoscopic manoeuvres during the diagnostic tumor process is relevant, as washing off by water injection through the endoscopic channel the adherent mucus on gastric mucosa, aspirating

Table 1 Tumor Nodes Metastasis (TNM) staging 8th Edition

| TNM staging | |
|-------------|--|
| T | |
| TX | Primary tumour cannot be assessed |
| T0 | No evidence of primary tumour |
| Tis | Carcinoma <i>in situ</i> |
| T1a | Tumour invades lamina propria or muscularis mucosae |
| T1b | Tumour invades submucosa |
| T2 | Tumour invades muscularis propria |
| T3 | Tumour penetrates subserosal tissue without invasion of visceral peritoneum or adjacent structures |
| T4a | Tumour penetrates serosa (visceral peritoneum) |
| T4b | Tumour directly invades adjacent organs or structures |
| N | |
| NX | Regional lymph nodes(s) cannot be assessed |
| N0 | No regional lymph node metastases |

TNM staging: Tumor nodes metastasis staging.

gastric secretions present in the cavity and controlling the amount of the air insufflated. EGC diagnosis is mainly based on the two important endoscopic findings: A well-demarcated lesion and an irregularity in the surface in terms of color or gland pattern[9].

The morphologic growth pattern of GC is defined by Borrmann classification, which classified the tumor as polypoid (lesion type I), fungating (lesion type II), ulcerated (lesion type III) or infiltrative (lesion type IV)/invasive cancer. Furthermore, early lesions are also macroscopically classified as lesions type 0 as an extension of Borrmann classification and EGCs are further classified according to morphologic extension as protruded (type 0 and type I), slightly elevated (called type 0-IIa), flat (type 0-IIb), slightly depressed (type 0-IIc) and excavated (type 0-III), with mixture types also possible.

Concerning superficial cancers, in 2003 the Paris classification (Figure 1) for macroscopic gastrointestinal superficial lesions was introduced. This classification distinguished the differences between type 0-I and type 0-IIa lesions according to a tumor height of 2.5 mm[10], and it distinguished the submucosal (SM)1 and SM2 tumors on the basis of the depth of submucosal invasion > 500 µm[11].

Histological GC diagnosis is based on the endoscopic biopsies with forceps, however global endoscopic evaluation is fundamental in this phase of diagnosis. Parameters as shapes, colors and ulcerations reflect tumor invasiveness and are useful also during the next step in oncological management.

Histology

Several histological classifications have been employed and the older Lauren histologic classification has been traditionally used in Western world[12]. This classification distinguishes the “intestinal type” characterized by glandular structures (intestinal metaplasia) comprising well differentiated columnar epithelial cells from the “diffuse type” characterized by pangastric infiltration by poorly cohesive clusters or solitary mucin-rich cells (called “signet ring cells”). Transmural extension through lymphatic invasion can produce a gastric wall thickening without causing a mass effect (so called “plastic linitis”). The intestinal-type GC can involve more often the distal part of the stomach and it is closely related to an environmental (*Helicobacter pylori*) and a specific-diet exposure. The diffuse-type GC interests people at a younger age and it carries a poorer prognosis.

The World Health Organization fifth tumors classification issued in 2019 is probably the most detailed classification system, describing apart from stomach adenocarcinomas, also other types of gastric tumors with decreased incidence[13,14]. The present classification has distinguished every single histologic type of GC (recently including also micropapillary carcinoma, gastric adenocarcinoma of the fundic gland type and undifferentiated carcinoma). Concerning gastric adenocarcinoma the common histologic subtypes described (as well as in fourth edition) are: The tubular, papillary, poorly cohesive, mucinous and mixed-type adenocarcinoma. Of these, tubular and papillary adenocarcinoma are graded as follows: low grade (well or moderately differentiated) and high grade (poorly differentiated). As new information, a molecular classification was introduced also in GC investigating: The Epstein-Barr virus-positive type, the microsatellite instability presence (the genomically stable type and chromosomally

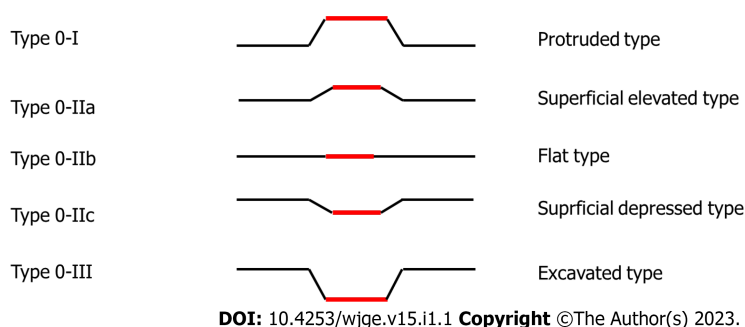


Figure 1 Paris Classification of early gastric cancer.

unstable type) and a large part of this classification were dedicated to precancerous lesions illustration (gastric dysplasia and adenomas).

EUS

History

EUS is a well-established procedure that was introduced almost 40 years ago in clinical practice, combining the endoscopic view with the ultrasound evaluation of target anatomic structures[15]. With the introduction in the early 1990s of the linear echoendoscopes, EUS gained the ability to safely guide in “real time” a targeted biopsy of tissue with EUS-guided fine needle aspiration (FNA)[16]. During the last years EUS has become also an increasingly therapeutic modality including applications in the treatment of the advanced phases of neoplastic diseases.

Many improvements in echoendoscopes and processor technology have been made during the last decade, as well as many ultrasound tools and endoscopic devices have become integral in GC patient management.

Method

EUS equipment consist of an ultrasound processor connected to an echoendoscope, with an ultrasound transducer attached at the distal tip of the instrument. The endoscope in return is connected to a standard video processor, permitting the endoscopic visualization: The complete system allows for simultaneous endoscopic and ultrasound imaging. Echoendoscopes work at variable frequencies, the most common ranging between 5 and 12 MHz: Higher frequencies allow a better resolution, but limit ultrasound beam penetration.

There are two types of echoendoscopes, radial and linear[17]. Radial transducers are used only for diagnostic purposes and they have individual piezoelectric elements of transducer around the distal tip in a 360° radial-array, producing an ultrasound image in a plane perpendicular to the long axis of the echoendoscope. Linear EUS scopes allow the real-time tissue sampling of targeted lesions and they can produce an ultrasound image in a parallel plane to the long axis of the scope (usually with a sector width between 100° and 180°). Different centers’ expertise drive the choice in using either radial or linear EUS scopes, but the use of a linear scope permits synchronous staging and tissue/Lymph node sampling.

Different brands of ultrasound processors are available on the market, all with incorporated additional imaging software including Power Doppler, tissue elastography and contrast-enhanced EUS (CE-EUS). All these tools complete the diagnostic phase of staging, particularly in lymph node evaluation in GC.

Ultrasound Tools

Ultrasound elastography reports a measurement of tissue stiffness, evaluating EUS changes on the image before and after the application of a determined pressure exerted by the probe. This is based on the hypothesis that a not-pathological tissue is soft, and it deforms more than a malignant tissue which results more stiff. In GC the elastography plays a key role in lymph nodes characterization, differentiating benign *vs* malignant ones with different techniques: The qualitative or the semi-quantitative elastography[18]. Qualitative elastography differentiates the lesions according to their elasticity score on a color map but it can represent a subjective evaluation, extremely operator-dependent. “Strain ratio” and “strain histogram” elastography represent semi-quantitative and more objective techniques, resulting in a numerical ratio of “regions of interest or “ROI” (lesion ROI/normal tissue ROI) or through the strain histogram permitting a graphical representation (histogram) of pixels color distribution of lesion/lymph node stiffness.

In earlier phases Color Doppler ultrasound improved the ability to differentiate malignant lymph nodes by displaying macro-vessels architecture. Inflammatory lymph nodes are more vascularized, without changes in the hilar vessel architecture. Metastatic lymph nodes present peripheral or mixed vascularity and lose the hilar vascularization[19]. Color Doppler ultrasound can also guide the needle trajectory during biopsies avoiding bigger vessels and preventing bleedings. CE-EUS imaging is also a useful tool for malignant lymph nodes diagnosis. It works with the direct intravenous administration of a new second generation contrast (sulphur hexafluoride) followed by 10-20 mL of saline generating microbubbles in the vessels with a diameter of 0.1-0.4 mm.

EUS-Needles

An advantage of EUS in GC is to biopsy mainly suspected malignant lymph nodes in order to improve N staging in high-selected cases. Usually, the ultrasound evaluation is enough to establish the malignant nature of suspected enlarged lymph nodes, but EUS-FNA represents a valid tool in selected and discussed cases (by a multidisciplinary team) if biopsy can change the therapeutic management of the patient. In case of EUS-biopsy different needles are disposable on the market, with different tips morphologies, stylet materials and flexibility of the body. The choice of the correct needle is usually related to a preference of the ultrasonographer, the availability of rapid on-site evaluation in the reference hospital and the target tissue to sample. Two big types of needles are available, for cytology and histology, respectively FNA and fine needle biopsy (FNB). FNB needles are fundamental in case of subsequent molecular studies as in case of metastatic lymph-nodes. Needles sizes used in lymph nodes sampling are 19, 20, 22, 25 Gauge (G). The European Society of Gastrointestinal Endoscopy Guidelines recommend the use of 25 G or 22 G needle in case of solid masses or lymph nodes sampling, with an equally recommendation between FNA and FNB needles[20]. However, when a tissue core is the primary aim the society suggests the employment of larger needles calibers as 19 G FNA or FNB needles or 22 G FNB needles.

EUS ROLE IN STAGING PHASE

The traditional use of EUS use is during the diagnostic process of GC staging, in particular to detect tumor extension in the gastric wall (T) and the presence of pathologic lymph nodes (N) in the evaluable stations. Early stages of GC can be treated by endoscopic submucosal dissection (ESD), endoscopic mucosal resection (EMR) or laparoscopic surgery, whereas the intermediate stages need a neoadjuvant chemotherapy to improve long term prognosis results after the subsequent surgery[21]. Therefore, the evaluation of tumor depth invasion and the presence of malignant lymph nodes are the cornerstones of therapeutic management and decisions and EUS can be useful in this process.

EUS can have a role also to assess the presence of a metastatic disease during the ultrasound evaluation, for example visualizing hepatic secondary lesions in the visible liver segments (I, II, III, IV) during EUS examination. Hepatic hilum lesions or lymph nodes can also be visualized and sampled being as standard of care also in biliary and pancreatic diseases.

Early phases of disease: pre endoscopic resection EUS evaluation in EGC

EUS distinguishes the distinct wall layers of gastrointestinal tract: superficial mucosa or lumen interface (M), muscularis mucosal layer or deep mucosa, submucosal layer, muscularis propria and finally serosa. Thus, EUS is useful to establish tumor depth penetration and following T state according to TNM classification. Tumor extension in gastric wall is fundamental to establish the correct lesion treatment.

EUS is a reliable modality for determining indications of less-invasive endoscopic resection for early GC[22,23]. Two resection technics are used to endoscopically remove EGCs: EMR and ESD. Compared to EMR the ESD technique is associated with higher “en-bloc” resection rates, higher R0 resections and a lower cancer recurrences but it is also associated with longer procedures in terms of time and higher perforation risks[24,25]. ESD is performed for these reasons in expert hands and high-volume centers, with the availability of a multidisciplinary team of specialists.

Moreover, the choice of endoscopic resection method depends on tumor size (ESD should be selected in case of tumor size greater than one centimeter) and different factors can influence the risk of malignant lymph node presence[26-29]. Different scenarios can be noticed in case of endoscopic curative resection: (1) Endoscopic resection is mostly curative in case of a poorly differentiated or diffuse cancer subtype confined to the mucosal layer, non-ulcerated and with a size ≤ 2 cm, but gastrectomy must be discussed within a multidisciplinary team; (2) In case of a well-differentiated cancer the endoscopic resection is considered as curative for lesions T1 SM1 (with the depth of invasion of the submucosal layer < 500 μ m), possibly ulcerated and less than 3 cm in size; and (3) Well-differentiated cancers, not ulcerated and confined to the mucosal layer can be resected by ESD irrespective of size.

Accuracy of EUS in evaluating EGC invasion depth was described by various study, with a high grade of variability and an accuracy rate between 64.8% and 92%[30-35].

In 2019 a meta-analysis of 17 articles and 4525 lesions showed a moderate value for depth invasion evaluation in EGC with a sensitivity of 87% and specificity of 67%. Overall over-staging rate of mucosa (M) or SM1 and SM2 by EUS was 13.31% and 32.8% respectively, while the overall under-staging rate of SM2 was 29.7% [36]. Meta-analysis concluded that EUS has demonstrated a moderate diagnostic value for depth of invasion assessment in EGC remarking the attention by the endoscopists to the endoscopic factors affecting EUS accuracy in EGC: invasion depth, like the shape, size and differentiation of lesions. In this way the endoscopic evaluation before EUS staging is crucial to define tumor malignancy.

Finally, the endoscopic resection (particularly ESD) should be done by expert endoscopists, and the expertise of the endosonographer is fundamental to establish the extension of the tumor in gastric wall with the best sensitive way. Radial EUS-scope is widely used, however linear EUS-scope is widely used due to the opportunity to perform biopsies through the operative channel of the instrument. Lan *et al* [37] described a comparison of EUS accuracy in EGC staging with radial and linear echoendoscopes in balanced groups, concluding that linear EUS is more accurate to establish SM involvement and therapeutic decision in suspected EGCs compared with radial echoendoscopes. More in detail, diagnostic accuracy was much higher for patients who underwent linear EUS compared with radial EUS (90.9% *vs* 69.2%, $P = 0.024$). Sensitivity was 92.3% linear EUS and 90.9% for radial EUS. Specificity was 90.0% in linear EUS group, while the specificity was 60.7% in radial group. Univariate analysis showed that the type of echoendoscope was an associated risk factor (OR 0.225) of incorrect T1b staging in EGC patients.

Advanced lesions: surgery/neoadjuvant treatment

As in case of other cancers in the last decade a significant positive impact of neoadjuvant treatment on locally advanced GC was seen. Although TOTAL STOMACH RESECTION remains the only potentially curative strategy in locally advanced disease the current available evidences suggest that neoadjuvant treatment improves overall survival, disease-free survival reducing the local recurrence rates in GC [38-42].

Neoadjuvant treatment is indicated in lesions extending to or beyond the muscularis propria (T2) and/or in presence of malignant EUS-visible lymph nodes (N+): stages IB-IIIc.

Therefore, the distinction between T1 or T2-T4 and N+ or N- results of paramount importance to decide therapeutic approach and EUS is an excellent method in addition to standard imaging exams in GC staging. Effectively EUS showed a good accuracy (> 90%) in various studies in establish T stage, less accurate in case of N staging, although previous studies have shown excellent accuracy of EUS in N staging [43-47].

Costa *et al* [48] investigated EUS accuracy in the selection of patients with gastric adenocarcinoma for neoadjuvant therapy (T2 and/or N+). Authors demonstrated an accuracy of 0.86, with a sensitivity and specificity of 88.5% and 83.1%, respectively. Accuracy was more effective in case of proximal and intestinal-type lesions.

Advanced disease: EUS therapeutic role

During the last decade EUS is rapidly evolving from a diagnostic into a therapeutic procedure, due to the possibility to easily access to adjacent structures with a minimally invasive approach. In particular, the increase and the availability of dedicated devices for therapeutic EUS use has driven this process. Numerous therapeutic procedures can be performed under EUS-guidance, such as drainages (pancreatic fluid collections, biliary system after ERCP failure, gallbladder for acute cholecystitis in high-risk surgical patients) or gastroenteral-anastomosis. This was also facilitated by the introduction of dedicated lumen-apposing metal stents in clinical practice [49,50].

Therapeutic EUS in GC can have a role for biliary drainage in patients with obstructive jaundice and an advanced cancer or a post-resected disease in case of disease relapse. The efficacy of EUS-guided biliary drainage (EUS-BD) was already demonstrated, with a higher technical success rate respect to percutaneous procedure (96.7% *vs* 88.9%) and fewer adverse events [51].

A late complication of GC could be also the malignant gastric outlet obstruction. Recently ESGE guidelines of therapeutic EUS suggested to perform EUS-guided gastroenterostomy in an expert setting for malignant gastric outlet obstruction, as an alternative to enteral stenting or surgery [49].

Data on long-term efficacy and safety of these relatively new therapeutic EUS-guided procedures will come from randomized multicenter controlled trials in order to create specific flow-chart of treatment.

CONCLUSION

EUS in 2022 remains an important procedure in the context of GC staging, particularly before EGC endoscopic resection, to evaluate T or confirm N state but it can have a role also in confirmation the locally advanced disease in selected patients. EUS-guided therapeutic procedures are becoming useful to offer a minimally-invasive therapy to patients with advanced disease also in GC but larger datasets are needed in order to standardize clinical indications. Multidisciplinary teams and expertise of clinicians are crucial in the management of this disease.

FOOTNOTES

Author contributions: Rossi G substantially contributed to conception and design of the study, acquisition of data, or analysis and interpretation of data, drafted the article or made critical revisions related to important intellectual content of the manuscript; Petrone MC and Healey A drafted the article or making critical revisions related to important intellectual content of the manuscript; Arcidiacono PG finally approved of the version of the article to be published; all authors have read and approve the final manuscript.

Conflict-of-interest statement: The authors have not conflict-of-interest to declare.

Open-Access: This article is an open-access article that was selected by an in-house editor and fully peer-reviewed by external reviewers. It is distributed in accordance with the Creative Commons Attribution NonCommercial (CC BY-NC 4.0) license, which permits others to distribute, remix, adapt, build upon this work non-commercially, and license their derivative works on different terms, provided the original work is properly cited and the use is non-commercial. See: <https://creativecommons.org/licenses/by-nc/4.0/>

Country/Territory of origin: Italy

ORCID number: Gemma Rossi 0000-0003-4071-8247; Maria Chiara Petrone 0000-0002-1045-209X; Paolo Giorgio Arcidiacono 0000-0001-6692-7720.

S-Editor: Chang KL

L-Editor: A

P-Editor: Chang KL

REFERENCES

- 1 **Zhang XY, Zhang PY.** Gastric cancer: somatic genetics as a guide to therapy. *J Med Genet* 2017; **54**: 305-312 [PMID: 27609016 DOI: 10.1136/jmedgenet-2016-104171]
- 2 **Yusefi AR, Bagheri Lankarani K, Bastani P, Radinmanesh M, Kavosi Z.** Risk Factors for Gastric Cancer: A Systematic Review. *Asian Pac J Cancer Prev* 2018; **19**: 591-603 [PMID: 29579788 DOI: 10.22034/APJCP.2018.19.3.591]
- 3 **Machlowska J, Baj J, Sitarz M, Maciejewski R, Sitarz R.** Gastric Cancer: Epidemiology, Risk Factors, Classification, Genomic Characteristics and Treatment Strategies. *Int J Mol Sci* 2020; **21** [PMID: 32512697 DOI: 10.3390/ijms21114012]
- 4 **El Abiad R, Gerke H.** Gastric cancer: endoscopic diagnosis and staging. *Surg Oncol Clin N Am* 2012; **21**: 1-19 [PMID: 22098828 DOI: 10.1016/j.soc.2011.09.002]
- 5 **Brierley JD, Gospodarowicz MK, Witteking C, eds.** TNM Classification of Malignant Tumours. 8th ed. Oxford; Hoboken: John Wiley & Sons; 2017
- 6 **Amin MB, Edge SB, Greene FL, et al, eds.** AJCC Cancer Staging Manual, 8th ed. New York: Springer; 2017
- 7 **Murakami T.** Pathomorphological diagnosis. Definition and gross classification of early gastric cancer. *Gann Monogr Cancer Res* 1971; **11**: 53
- 8 **Kumagai K, Sano T.** Revised points and disputed matters in the eighth edition of the TNM staging system for gastric cancer. *Jpn J Clin Oncol* 2021; **51**: 1024-1027 [PMID: 33987661 DOI: 10.1093/jjco/hyab069]
- 9 **Yao K.** The endoscopic diagnosis of early gastric cancer. *Ann Gastroenterol* 2013; **26**: 11-22 [PMID: 24714327]
- 10 **The Paris endoscopic classification of superficial neoplastic lesions: esophagus, stomach, and colon: November 30 to December 1, 2002.** *Gastrointest Endosc* 2003; **58**: S3-43 [PMID: 14652541 DOI: 10.1016/s0016-5107(03)02159-x]
- 11 **Endoscopic Classification Review Group.** Update on the paris classification of superficial neoplastic lesions in the digestive tract. *Endoscopy* 2005; **37**: 570-578 [PMID: 15933932 DOI: 10.1055/s-2005-861352]
- 12 **LAUREN P.** THE TWO HISTOLOGICAL MAIN TYPES OF GASTRIC CARCINOMA: DIFFUSE AND SO-CALLED INTESTINAL-TYPE CARCINOMA. AN ATTEMPT AT A HISTO-CLINICAL CLASSIFICATION. *Acta Pathol Microbiol Scand* 1965; **64**: 31-49 [PMID: 14320675 DOI: 10.1111/apm.1965.64.1.31]
- 13 **Nagtegaal ID, Odze RD, Klimstra D, Paradis V, Rugge M, Schirmacher P, Washington KM, Carneiro F, Cree IA; WHO Classification of Tumours Editorial Board.** The 2019 WHO classification of tumours of the digestive system. *Histopathology* 2020; **76**: 182-188 [PMID: 31433515 DOI: 10.1111/his.13975]
- 14 **Kushima R.** The updated WHO classification of digestive system tumours-gastric adenocarcinoma and dysplasia. *Pathologie* 2022; **43**: 8-15 [PMID: 34807275 DOI: 10.1007/s00292-021-01023-7]
- 15 **Hisanaga K, Hisanaga A, Nagata K, Ichie Y.** High speed rotating scanner for transgastric sonography. *AJR Am J Roentgenol* 1980; **135**: 627-629 [PMID: 6773394 DOI: 10.2214/ajr.135.3.627]
- 16 **Vilmann P, Jacobsen GK, Henriksen FW, Hancke S.** Endoscopic ultrasonography with guided fine needle aspiration biopsy in pancreatic disease. *Gastrointest Endosc* 1992; **38**: 172-173 [PMID: 1568614 DOI: 10.1016/s0016-5107(92)70385-x]
- 17 **ASGE Technology Committee, Murad FM, Komanduri S, Abu Dayyeh BK, Chauhan SS, Enestvedt BK, Fujii-Lau LL, Konda V, Maple JT, Pannala R, Thosani NC, Banerjee S.** Echoendoscopes. *Gastrointest Endosc* 2015; **82**: 189-202 [PMID: 26077457 DOI: 10.1016/j.gie.2015.02.017]
- 18 **Iglesias-Garcia J, Lindkvist B, Lariño-Noia J, Domínguez-Muñoz JE.** Endoscopic ultrasound elastography. *Endosc Ultrasound* 2012; **1**: 8-16 [PMID: 24949330 DOI: 10.7178/eus.01.003]
- 19 **Hocke M, Ignee A, Dietrich C.** Role of contrast-enhanced endoscopic ultrasound in lymph nodes. *Endosc Ultrasound*

- 2017; **6**: 4-11 [PMID: [28218194](#) DOI: [10.4103/2303-9027.190929](#)]
- 20 **Polkowski M**, Jenssen C, Kaye P, Carrara S, Deprez P, Gines A, Fernández-Esparrach G, Eisendrath P, Aithal GP, Arcidiacono P, Barthet M, Bastos P, Fornelli A, Napoleone B, Iglesias-Garcia J, Seicean A, Larghi A, Hassan C, van Hooft JE, Dumonceau JM. Technical aspects of endoscopic ultrasound (EUS)-guided sampling in gastroenterology: European Society of Gastrointestinal Endoscopy (ESGE) Technical Guideline - March 2017. *Endoscopy* 2017; **49**: 989-1006 [PMID: [28898917](#) DOI: [10.1055/s-0043-119219](#)]
- 21 **Mehmedović A**, Mesihović R, Saray A, Vanis N. Gastric cancer staging: EUS and CT. *Med Arch* 2014; **68**: 34-36 [PMID: [24783909](#) DOI: [10.5455/medarch.2014.68.34-36](#)]
- 22 **Sanomura Y**, Oka S, Tanaka S, Noda I, Higashiyama M, Imagawa H, Shishido T, Yoshida S, Hiyama T, Arihiro K, Chayama K. Clinical validity of endoscopic submucosal dissection for submucosal invasive gastric cancer: a single-center study. *Gastric Cancer* 2012; **15**: 97-105 [PMID: [21785925](#) DOI: [10.1007/s10120-011-0076-7](#)]
- 23 **Oka S**, Tanaka S, Higashiyama M, Numata N, Sanomura Y, Yoshida S, Arihiro K, Chayama K. Clinical validity of the expanded criteria for endoscopic resection of undifferentiated-type early gastric cancer based on long-term outcomes. *Surg Endosc* 2014; **28**: 639-647 [PMID: [24114514](#) DOI: [10.1007/s00464-013-3222-y](#)]
- 24 **Facciorusso A**, Antonino M, Di Maso M, Muscatiello N. Endoscopic submucosal dissection vs endoscopic mucosal resection for early gastric cancer: A meta-analysis. *World J Gastrointest Endosc* 2014; **6**: 555-563 [PMID: [25400870](#) DOI: [10.4253/wjge.v6.i11.555](#)]
- 25 **Pimentel-Nunes P**, Mourão F, Veloso N, Afonso LP, Jácome M, Moreira-Dias L, Dinis-Ribeiro M. Long-term follow-up after endoscopic resection of gastric superficial neoplastic lesions in Portugal. *Endoscopy* 2014; **46**: 933-940 [PMID: [25019970](#) DOI: [10.1055/s-0034-1377348](#)]
- 26 **Pimentel-Nunes P**, Dinis-Ribeiro M, Ponchon T, Repici A, Vieth M, De Ceglie A, Amato A, Berr F, Bhandari P, Bialek A, Conio M, Haringsma J, Langner C, Meisner S, Messmann H, Morino M, Neuhaus H, Piesseaux H, Rugge M, Saunders BP, Robaszekiewicz M, Seewald S, Kashin S, Dumonceau JM, Hassan C, Deprez PH. Endoscopic submucosal dissection: European Society of Gastrointestinal Endoscopy (ESGE) Guideline. *Endoscopy* 2015; **47**: 829-854 [PMID: [26317585](#) DOI: [10.1055/s-0034-1392882](#)]
- 27 **Japanese Gastric Cancer Association**. Japanese gastric cancer treatment guidelines 2010 (ver. 3). *Gastric Cancer* 2011; **14**: 113-123 [PMID: [21573742](#) DOI: [10.1007/s10120-011-0042-4](#)]
- 28 **Gotoda T**, Iwasaki M, Kusano C, Seewald S, Oda I. Endoscopic resection of early gastric cancer treated by guideline and expanded National Cancer Centre criteria. *Br J Surg* 2010; **97**: 868-871 [PMID: [20301163](#) DOI: [10.1002/bjs.7033](#)]
- 29 **Gotoda T**, Yanagisawa A, Sasako M, Ono H, Nakanishi Y, Shimoda T, Kato Y. Incidence of lymph node metastasis from early gastric cancer: estimation with a large number of cases at two large centers. *Gastric Cancer* 2000; **3**: 219-225 [PMID: [11984739](#) DOI: [10.1007/pl00011720](#)]
- 30 **Ferlay J**, Soerjomataram I, Dikshit R, Eser S, Mathers C, Rebelo M, Parkin DM, Forman D, Bray F. Cancer incidence and mortality worldwide: sources, methods and major patterns in GLOBOCAN 2012. *Int J Cancer* 2015; **136**: E359-E386 [PMID: [25220842](#) DOI: [10.1002/ijc.29210](#)]
- 31 **Ono H**, Kondo H, Gotoda T, Shirao K, Yamaguchi H, Saito D, Hosokawa K, Shimoda T, Yoshida S. Endoscopic mucosal resection for treatment of early gastric cancer. *Gut* 2001; **48**: 225-229 [PMID: [11156645](#) DOI: [10.1136/gut.48.2.225](#)]
- 32 **Akashi K**, Yanai H, Nishikawa J, Satake M, Fukagawa Y, Okamoto T, Sakaida I. Ulcerous change decreases the accuracy of endoscopic ultrasonography diagnosis for the invasive depth of early gastric cancer. *Int J Gastrointest Cancer* 2006; **37**: 133-138 [PMID: [18080789](#) DOI: [10.1007/s12029-007-9004-9](#)]
- 33 **Kim JH**, Song KS, Youn YH, Lee YC, Cheon JH, Song SY, Chung JB. Clinicopathologic factors influence accurate endosonographic assessment for early gastric cancer. *Gastrointest Endosc* 2007; **66**: 901-908 [PMID: [17963876](#) DOI: [10.1016/j.gie.2007.06.012](#)]
- 34 **Nakamura T**, Tajika M, Kawai H, Yokoi T, Yatabe Y, Nakamura S. Is endoscopic ultrasonography (EUS) needed for deciding the indication for endoscopic submucosal dissection (ESD) of early gastric carcinoma? *Stomach Intestine* 2005; **40**: 779-790
- 35 **Sano T**, Okuyama Y, Kobori O, Shimizu T, Morioka Y. "Early gastric cancer," Endoscopic diagnosis of depth of invasion. *Digest Dis Sci* 1990; **35**: 1340-1344
- 36 **Shi D**, Xi XX. Factors Affecting the Accuracy of Endoscopic Ultrasonography in the Diagnosis of Early Gastric Cancer Invasion Depth: A Meta-analysis. *Gastroenterol Res Pract* 2019; **2019**: 8241381 [PMID: [31933632](#) DOI: [10.1155/2019/8241381](#)]
- 37 **Lan Z**, Hu H, Mandip R, Zhu W, Guo W, Wen J, Xie F, Qiao W, Venkata A, Huang Y, Liu S, Li Y. Linear-array endoscopic ultrasound improves the accuracy of preoperative submucosal invasion prediction in suspected early gastric cancer compared with radial endoscopic ultrasound: A prospective cohort study. *J Gastroenterol Hepatol* 2020; **35**: 118-123 [PMID: [31379013](#) DOI: [10.1111/jgh.14819](#)]
- 38 **Serrano OK**, Huang K, Ng N, Yang J, Friedmann P, Libutti SK, Kennedy TJ. Correlation between preoperative endoscopic ultrasound and surgical pathology staging of gastric adenocarcinoma: A single institution retrospective review. *J Surg Oncol* 2016; **113**: 42-45 [PMID: [26784562](#) DOI: [10.1002/jso.24098](#)]
- 39 **Cunningham D**, Allum WH, Stenning SP, Thompson JN, Van de Velde CJ, Nicolson M, Scarffe JH, Locks FJ, Falk SJ, Iveson TJ, Smith DB, Langley RE, Verma M, Weeden S, Chua YJ, MAGIC Trial Participants. Perioperative chemotherapy vs surgery alone for resectable gastroesophageal cancer. *N Engl J Med* 2006; **355**: 11-20 [PMID: [16822992](#) DOI: [10.1056/NEJMoa055531](#)]
- 40 **Ychou M**, Boige V, Pignon JP, Conroy T, Bouché O, Lebreton G, Ducourtieux M, Bedenne L, Fabre JM, Saint-Aubert B, Genève J, Lasser P, Rougier P. Perioperative chemotherapy compared with surgery alone for resectable gastroesophageal adenocarcinoma: an FNCLCC and FFCO multicenter phase III trial. *J Clin Oncol* 2011; **29**: 1715-1721 [PMID: [21444866](#) DOI: [10.1200/JCO.2010.33.0597](#)]
- 41 **van Hagen P**, Hulshof MC, van Lanschot JJ, Steyerberg EW, van Berge Henegouwen MI, Wijnhoven BP, Richel DJ, Nieuwenhuijzen GA, Hospers GA, Bonenkamp JJ, Cuesta MA, Blaisse RJ, Busch OR, ten Kate FJ, Creemers GJ, Punt CJ, Plukker JT, Verheul HM, Spillenaar Bilgen EJ, van Dekken H, van der Sangen MJ, Rozema T, Biermann K, Beukema JC,

- Piet AH, van Rij CM, Reinders JG, Tilanus HW, van der Gaast A; CROSS Group. Preoperative chemoradiotherapy for esophageal or junctional cancer. *N Engl J Med* 2012; **366**: 2074-2084 [PMID: [22646630](#) DOI: [10.1056/NEJMoa1112088](#)]
- 42 **Yoshikawa T**, Tanabe K, Nishikawa K, Ito Y, Matsui T, Kimura Y, Hirabayashi N, Mikata S, Iwahashi M, Fukushima R, Takiguchi N, Miyashiro I, Morita S, Miyashita Y, Tsuburaya A, Sakamoto J. Induction of a pathological complete response by four courses of neoadjuvant chemotherapy for gastric cancer: early results of the randomized phase II COMPASS trial. *Ann Surg Oncol* 2014; **21**: 213-219 [PMID: [23838904](#) DOI: [10.1245/s10434-013-3055-x](#)]
- 43 **Spolverato G**, Ejaz A, Kim Y, Squires MH, Poultsides GA, Fields RC, Schmidt C, Weber SM, Votanopoulos K, Maithel SK, Pawlik TM. Use of endoscopic ultrasound in the preoperative staging of gastric cancer: a multi-institutional study of the US gastric cancer collaborative. *J Am Coll Surg* 2015; **220**: 48-56 [PMID: [25283742](#) DOI: [10.1016/j.jamcollsurg.2014.06.023](#)]
- 44 **Mocellin S**, Marchet A, Nitti D. EUS for the staging of gastric cancer: a meta-analysis. *Gastrointest Endosc* 2011; **73**: 1122-1134 [PMID: [21444080](#) DOI: [10.1016/j.gie.2011.01.030](#)]
- 45 **Cardoso R**, Coburn N, Seevaratnam R, Sutradhar R, Lourenco LG, Mahar A, Law C, Yong E, Tinmouth J. A systematic review and meta-analysis of the utility of EUS for preoperative staging for gastric cancer. *Gastric Cancer* 2012; **15** Suppl 1: S19-S26 [PMID: [22237654](#) DOI: [10.1007/s10120-011-0115-4](#)]
- 46 **Mocellin S**, Pasquali S. Diagnostic accuracy of endoscopic ultrasonography (EUS) for the preoperative locoregional staging of primary gastric cancer. *Cochrane Database Syst Rev* 2015; **2015**: CD009944 [PMID: [25914908](#) DOI: [10.1002/14651858.CD009944.pub2](#)]
- 47 **Pei Q**, Wang L, Pan J, Ling T, Lv Y, Zou X. Endoscopic ultrasonography for staging depth of invasion in early gastric cancer: A meta-analysis. *J Gastroenterol Hepatol* 2015; **30**: 1566-1573 [PMID: [26094975](#) DOI: [10.1111/jgh.13014](#)]
- 48 **Costa JM**, Gonçalves B, Miguel Gomes M, Fernandes D, Gonçalves R, Soares JB. Accuracy of endoscopic ultrasound in gastric adenocarcinoma patient selection for neoadjuvant therapy. *United European Gastroenterol J* 2019; **7**: 278-286 [PMID: [31081829](#) DOI: [10.1177/2050640618818942](#)]
- 49 **van der Merwe SW**, van Wanrooij RLJ, Bronswijk M, Everett S, Lakhtakia S, Rimbas M, Hucl T, Kunda R, Badaoui A, Law R, Arcidiacono PG, Larghi A, Giovannini M, Khashab MA, Binmoeller KF, Barthet M, Perez-Miranda M, van Hooft JE. Therapeutic endoscopic ultrasound: European Society of Gastrointestinal Endoscopy (ESGE) Guideline. *Endoscopy* 2022; **54**: 185-205 [PMID: [34937098](#) DOI: [10.1055/a-1717-1391](#)]
- 50 **Rizzatti G**, Larghi A. [Therapeutic endoscopic ultrasound: current indications and future perspectives.]. *Recenti Prog Med* 2021; **112**: 54-57 [PMID: [33512359](#) DOI: [10.1701/3525.35124](#)]
- 51 **Ogura T**, Okuda A, Miyano A, Imanishi M, Nishioka N, Yamada M, Yamada T, Kamiyama R, Masuda D, Higuchi K. EUS-guided vs percutaneous biliary access in patients with obstructive jaundice due to gastric cancer. *Dig Liver Dis* 2019; **51**: 247-252 [PMID: [30327252](#) DOI: [10.1016/j.dld.2018.09.015](#)]



Published by **Baishideng Publishing Group Inc**
7041 Koll Center Parkway, Suite 160, Pleasanton, CA 94566, USA

Telephone: +1-925-3991568

E-mail: bpgoffice@wjgnet.com

Help Desk: <https://www.f6publishing.com/helpdesk>

<https://www.wjgnet.com>

