

# World Journal of *Gastrointestinal Endoscopy*

*World J Gastrointest Endosc* 2023 November 16; 15(11): 634-680



## MINIREVIEWS

- 634 Endoscopic ultrasound guided gastroenterostomy: Technical details updates, clinical outcomes, and adverse events

Wang J, Hu JL, Sun SY

## ORIGINAL ARTICLE

## Retrospective Cohort Study

- 641 Endoscopic retrograde cholangiopancreatography-related early perforations: A study of effects of procedure duration, complexity, and endoscopist experience

Aloysius M, Goyal H, Nikumbh T, Shah NJ, Hammoud GM, Mutha P, Joseph-Talreja M, John S, Aswath G, Wadhwa V, Thosani N

- 649 Nomogram to predict gas-related complications during transoral endoscopic resection of upper gastrointestinal submucosal lesions

Yang J, Chen ZG, Yi XL, Chen J, Chen L

## Basic Study

- 658 Animal experimental study on magnetic anchor technique-assisted endoscopic submucosal dissection of early gastric cancer

Pan M, Zhang MM, Zhao L, Lyu Y, Yan XP

## CASE REPORT

- 666 Hybrid laparo-endoscopic access: New approach to surgical treatment for giant fibrovascular polyp of esophagus: A case report and review of literature

Dzhantukhanova S, Avetisyan LG, Badakhova A, Starkov Y, Glotov A

- 676 General anesthesia with endotracheal intubation ensures the quick removal of magnetic foreign bodies: A case report

Tian QF, Zhao AX, Du N, Wang ZJ, Ma LL, Men FL

**ABOUT COVER**

Editorial Board Member of *World Journal of Gastrointestinal Endoscopy*, Istvan Hritz, MD, PhD, Associate Professor, Doctor, First Department of Surgery and Interventional Gastroenterology, Semmelweis University, Budapest 1082, Hungary. [istvan.hritz@gmail.com](mailto:istvan.hritz@gmail.com)

**AIMS AND SCOPE**

The primary aim of *World Journal of Gastrointestinal Endoscopy* (WJGE, *World J Gastrointest Endosc*) is to provide scholars and readers from various fields of gastrointestinal endoscopy with a platform to publish high-quality basic and clinical research articles and communicate their research findings online.

WJGE mainly publishes articles reporting research results and findings obtained in the field of gastrointestinal endoscopy and covering a wide range of topics including capsule endoscopy, colonoscopy, double-balloon enteroscopy, duodenoscopy, endoscopic retrograde cholangiopancreatography, endosonography, esophagoscopy, gastrointestinal endoscopy, gastroscopy, laparoscopy, natural orifice endoscopic surgery, proctoscopy, and sigmoidoscopy.

**INDEXING/ABSTRACTING**

The WJGE is now abstracted and indexed in Emerging Sources Citation Index (Web of Science), PubMed, PubMed Central, Reference Citation Analysis, China National Knowledge Infrastructure, China Science and Technology Journal Database, and Superstar Journals Database. The 2023 Edition of Journal Citation Reports® cites the 2022 impact factor (IF) for WJGE as 2.0; IF without journal self cites: 1.9; 5-year IF: 3.3; Journal Citation Indicator: 0.28.

**RESPONSIBLE EDITORS FOR THIS ISSUE**

Production Editor: Yi-Xuan Cai; Production Department Director: Xu Guo; Editorial Office Director: Jia-Ping Yan.

**NAME OF JOURNAL**

*World Journal of Gastrointestinal Endoscopy*

**ISSN**

ISSN 1948-5190 (online)

**LAUNCH DATE**

October 15, 2009

**FREQUENCY**

Monthly

**EDITORS-IN-CHIEF**

Anastasios Koulaouzidis, Bing Hu, Sang Chul Lee, Joo Young Cho

**EDITORIAL BOARD MEMBERS**

<https://www.wjgnet.com/1948-5190/editorialboard.htm>

**PUBLICATION DATE**

November 16, 2023

**COPYRIGHT**

© 2023 Baishideng Publishing Group Inc

**INSTRUCTIONS TO AUTHORS**

<https://www.wjgnet.com/bpg/gerinfo/204>

**GUIDELINES FOR ETHICS DOCUMENTS**

<https://www.wjgnet.com/bpg/GerInfo/287>

**GUIDELINES FOR NON-NATIVE SPEAKERS OF ENGLISH**

<https://www.wjgnet.com/bpg/gerinfo/240>

**PUBLICATION ETHICS**

<https://www.wjgnet.com/bpg/GerInfo/288>

**PUBLICATION MISCONDUCT**

<https://www.wjgnet.com/bpg/gerinfo/208>

**ARTICLE PROCESSING CHARGE**

<https://www.wjgnet.com/bpg/gerinfo/242>

**STEPS FOR SUBMITTING MANUSCRIPTS**

<https://www.wjgnet.com/bpg/GerInfo/239>

**ONLINE SUBMISSION**

<https://www.f6publishing.com>



Retrospective Cohort Study

# Nomogram to predict gas-related complications during transoral endoscopic resection of upper gastrointestinal submucosal lesions

Jia Yang, Zhi-Guo Chen, Xing-Lin Yi, Jing Chen, Lei Chen

**Specialty type:** Gastroenterology and hepatology

**Provenance and peer review:**

Unsolicited article; Externally peer reviewed.

**Peer-review model:** Single blind

**Peer-review report's scientific quality classification**

Grade A (Excellent): 0

Grade B (Very good): 0

Grade C (Good): C

Grade D (Fair): 0

Grade E (Poor): 0

**P-Reviewer:** Cho JY, South Korea

**Received:** September 5, 2023

**Peer-review started:** September 5, 2023

**First decision:** September 13, 2023

**Revised:** September 21, 2023

**Accepted:** October 16, 2023

**Article in press:** October 16, 2023

**Published online:** November 16, 2023



**Jia Yang, Zhi-Guo Chen, Jing Chen, Lei Chen,** Department of Gastroenterology, The First Affiliated Hospital (Southwest Hospital) to Third Military Medical University (Army Medical University), Chongqing 400038, China

**Xing-Lin Yi,** Department of Pulmonology, The First Affiliated Hospital (Southwest Hospital) to Third Military Medical University (Army Medical University), Chongqing 400038, China

**Corresponding author:** Lei Chen, MD, PhD, Professor, Department of Gastroenterology, The First Affiliated Hospital (Southwest Hospital) to Third Military Medical University (Army Medical University), Gaotanyan Street, Shapingba District, Chongqing 400038, China.  
[chenlei\\_1977603@126.com](mailto:chenlei_1977603@126.com)

## Abstract

### BACKGROUND

Gas-related complications present a potential risk during transoral endoscopic resection of upper gastrointestinal submucosal lesions. Therefore, the identification of risk factors associated with these complications is essential.

### AIM

To develop a nomogram to predict risk of gas-related complications following transoral endoscopic resection of the upper gastrointestinal submucosal lesions.

### METHODS

We collected patient data from the First Affiliated Hospital of the Army Medical University. Patients were randomly allocated to training and validation cohorts. Risk factors for gas-related complications were identified in the training cohort using univariate and multivariate analyses. We then constructed a nomogram and evaluated its predictive performance based on the area under the curve, decision curve analysis, and Hosmer-Lemeshow tests.

### RESULTS

Gas-related complications developed in 39 of 353 patients who underwent transoral endoscopy at our institution. Diabetes, lesion origin, surgical resection method, and surgical duration were incorporated into the final nomogram. The predictive capability of the nomogram was excellent, with area under the curve values of 0.841 and 0.906 for the training and validation cohorts, respectively.

### CONCLUSION



The ability of our four-variable nomogram to efficiently predict gas-related complications during transoral endoscopic resection enhanced postoperative assessments and surgical outcomes.

**Key Words:** Complications; Endoscopy; Upper gastrointestinal tract; Nomogram; Forecasting

©The Author(s) 2023. Published by Baishideng Publishing Group Inc. All rights reserved.

**Core Tip:** This is a retrospective study to create a nomogram that efficiently evaluates the risk of gas-related complications in patients undergoing transoral endoscopic resection of upper gastrointestinal submucosal lesions. Our study excluded upper gastrointestinal malignancies and explored risk factors for gas-related complications during transoral endoscopic resection. Predictive models were developed based on diabetes status, lesion origin layer, operative resection technique, and duration of the operation.

**Citation:** Yang J, Chen ZG, Yi XL, Chen J, Chen L. Nomogram to predict gas-related complications during transoral endoscopic resection of upper gastrointestinal submucosal lesions. *World J Gastrointest Endosc* 2023; 15(11): 649-657

**URL:** <https://www.wjgnet.com/1948-5190/full/v15/i11/649.htm>

**DOI:** <https://dx.doi.org/10.4253/wjge.v15.i11.649>

## INTRODUCTION

Submucosal gastrointestinal lesions, often referred to as subepithelial gastrointestinal lesions (SELs)[1], encompass a range of submucosal stromal tumors, leiomyomas, lipomas, and schwannomas. They also include non-neoplastic lesions such as heterotopic pancreas and cysts[2]. The incidence of SEL in the general population ranges between 0.76%-1.7% [3, 4]. Although most lesions are benign[5] and frequently identified during health screens due to abdominal discomfort, vomiting, acid reflux, or anemia, some carry risks of bleeding, obstruction, and potential malignant transformation over time[6]. Hence, treatment approaches must be individualized.

The application of minimally invasive endoscopic techniques has recently increased along with enhanced operative skills among endoscopists. This has resulted in an uptick in the number of gastrointestinal submucosal lesions that are treated endoscopically[7,8]. The repertoire of endoscopic interventions includes high-frequency electrocoagulation resection, endoscopic mucosal resection (EMR), endoscopic submucosal excavation (ESE), endoscopic submucosal dissection (ESD), submucosal tunnelling endoscopic resection (STER), and endoscopic full-thickness resection (EFTR).

Despite many advantages, all endoscopic procedures run the risk of potential complications. A significant proportion of these complications involve the unintended escape of gas outside the digestive tract wall, resulting in gas-related complications such as subcutaneous emphysema, pneumothorax, pneumomediastinum, and pneumoperitoneum. Studies have designated such complications as critical issues in endoscopic surgery because they lead to extended hospital stays and increased socioeconomic burdens on patients[9]. Consequently, we aimed to identify risk factors associated with gas-related complications during transoral endoscopic resection and to develop and validate a clinically useful nomogram.

## MATERIALS AND METHODS

### Patients

The First Affiliated Hospital Ethics Committee of the Army Medical University approved the study [Approval ID: (B) KY2023006], and all patients provided written informed consent.

This study included 353 patients [male, 163 (46.2%); female, 190 (53.8%); mean age, 48.12 ± 0.55 year; range, 17-76 year] who underwent transoral endoscopic resection of upper gastrointestinal submucosal lesions at the First Affiliated Hospital of the Army Medical University between July 2012 and June 2022. We randomized the patients into training ( $n = 247$ ) and validation ( $n = 106$ ) cohorts in a 7:3 ratio using R software version 4.1.2 (Foundation for Statistical Computing, Vienna, Austria).

The inclusion criteria comprised histologically confirmed diagnosis of upper gastrointestinal submucosal lesions, preoperative endoscopic ultrasonography (EUS) findings indicating the lesion origin layer, and having undergone transoral endoscopic resection at our institution. The exclusion criteria comprised intolerance to general anesthesia, intraoperative emergencies that halted the procedure, or undergoing concurrent endoscopic procedures. The patients were endotracheally intubated after general anesthesia and were grouped according to the presence or absence of gas-related complications.

### Diagnostic criteria

We characterized subcutaneous emphysema as the finding of gas in subcutaneous tissues. Pneumothorax results from ruptures in the visceral or parietal pleura, leading to air entering the pleural space. Pneumomediastinum arises due to air

leaking into the mediastinal space. Pneumoperitoneum can arise from gut perforation or gas entering the peritoneum *via* the diaphragmatic foramina. Our diagnosis of gas-related complications relied on clinical findings, and computed tomography or postoperative radiographic images acquired within 24 h. We treated subcutaneous emphysema and pneumomediastinum conservatively[10]. Thoracic drainage, laparotomy, perforation repair, or surgical treatment were considered to alleviate pronounced symptoms.

### Data collection

Clinical data comprised age, gender, body mass index, underlying conditions (diabetes, hypertension), disease duration, medical history, and EUS findings. Surgical data comprised the histological category of the lesion, lesion size, surgical duration, and resection method. We categorized the surgical duration as < 1, 1-2, or > 2 h and lesion size based on the largest lesion diameter as ≤ 2.0 or > 2.0 cm. The categories of histological lesions were leiomyomas, stromal tumors, schwannomas, heterotopic pancreas, cysts, and lipomas. The muscle layers where lesions originated were classified as non-intrinsic or intrinsic.

### Instruments and equipment

Procedures involved the use of an Olympus Q260-J gastroscope (Olympus Optical Co. Ltd., Tokyo, Japan), a high-frequency electrogenic generator (Erbe Elektromedizin GmbH, Tübingen, Germany) a range of specialized knives, titanium clamps, biopsy forceps, loopers, ligatures, and disposable endoscopic syringes. Patients undergoing transoral endoscopic resection were insufflated with CO<sub>2</sub> at pressure of 1 MPa.

### Statistical methods

All data were statistically analyzed using R (version 4.1.2) and SPSS version 26.0 (IBM Corp., Armonk, NY, United States) software. Continuous data are presented as means ± SD and were compared between cohorts using ANOVA or *t* test. Categorical data are presented as frequencies and ratios (%) with a comparative approach using Fisher exact, and  $\chi^2$  tests. We considered that values with *P* < 0.05 were statistically significant. Variables with a univariate analysis *P* < 0.05 were also included in the training cohort. We screened variables and identified factors influencing gas-related complications in transoral endoscopic resection using least absolute shrinkage and selection operator (LASSO) regression. These factors served as predictor variables to calculate risk scores and construct a nomogram. We plotted the receiver operating characteristic curves for the nomogram in the training and validation cohorts and calculated the area under the curve (AUC). We evaluated the predictive power of our model using calibration curves, decision curve analysis, and the Hosmer-Lemeshow test.

## RESULTS

### Patient characteristics

Gas-related complications arose in 39 (11.05%) of 353 patients, comprising 22 (6.20%) with subcutaneous emphysema and pneumomediastinum, 20 (5.67%) with pneumoperitoneum, and 4 (1.13%) with pneumothorax. **Supplementary Table 1** shows the baseline demographics and characteristics of the patients. Symptoms that were mild in 29 patients with gas-related complications independently resolved within 3-5 d. Ten patients underwent thoracic drainage and perforation repair. Among these complications, 163 and 190 originated from the non-intrinsic and intrinsic muscular layers, respectively.

### Univariate and multifactorial findings

Univariate analysis revealed that histological type, lesion layer of origin, diabetes, lesion size, surgical duration, and resection method significantly influenced the development of gas-related complications (**Table 1**). The LASSO regression analysis selected the resection method, surgical duration, diabetes, and lesion layer of origin as independent risk factors for gas-related complications during surgery in the training cohort (**Figure 1**). We then constructed a model based on these variables (**Figure 2**). The risk scores of patients were calculated by summing the scores of each item. The sum total scores predicted the likelihood of gas-related complications.

### Nomogram validation

The training and validation cohorts yielded AUCs of 0.841 [95% confidence interval (CI): 0.774-0.908; **Figure 3A**] and 0.906 (95%CI: 0.845-0.966; **Figure 3B**), respectively. The discriminatory power of the model was excellent with a C-index of > 0.800 for both cohorts. Hosmer-Lemeshow tests demonstrated a good model fit, with *P* = 0.36 and 0.31 for the training and validation cohorts, respectively. The clinical decision curves derived from the model had a wide range of relative thresholds (5%-100%) and robust clinical applicability (**Supplementary Figures 1 and 2**), indicating that the model holds strong predictive validity.

**Table 1 Univariate and multivariate analyses of factors influencing gas-related complications**

Variables	Univariate		Multivariate	
	OR (95%CI)	P value	OR (95%CI)	P value
Sex	1.087 (0.512-2.310)	0.827		
Age	1.009 (0.975-1.045)	0.598		
Hypertension	0.267 (0.035-2.045)	0.203		
Diabetes	8.306 (1.135-60.774)	0.037	11.043 (0.921-132.452)	0.058
Medical history	1.032 (0.476-2.236)	0.936		
Histological type		0.019		
Largest lesion diameter	3.120 (1.483-6.565)	0.003		
Lesion origin layer	5.011 (1.855-13.534)	0.001	1.774 (0.583-5.394)	0.028
Resection method		< 0.001		< 0.001
Electrocoagulation	11.326 (3.025-42.403)		10.296 (2.714-39.059)	
Full-thickness	24.615 (6.802-89.074)		23.167 (6.367-84.295)	
Surgical duration	2.828 (1.823-4.387)	< 0.001	2.085 (1.290-3.370)	0.029

OR: Odds ratio; CI: Confidence interval; NI: Not included in multivariate analysis.

## DISCUSSION

### Gastrointestinal tract submucosal lesions

The rise of gastroscopy has led to increased rates of detecting submucosal lesions in the gastrointestinal tract during health examinations. Symptoms of these lesions are linked to their size and location. While most lesions are benign, they still carry risk of malignancy[11]. The American Society for Gastrointestinal Endoscopy and the National Comprehensive Cancer Network guidelines suggest endoscopic monitoring for asymptomatic lesions < 2 cm in diameter[12]. However, larger lesions, or those causing significant symptoms, require immediate intervention.

### Transoral endoscopic resection techniques

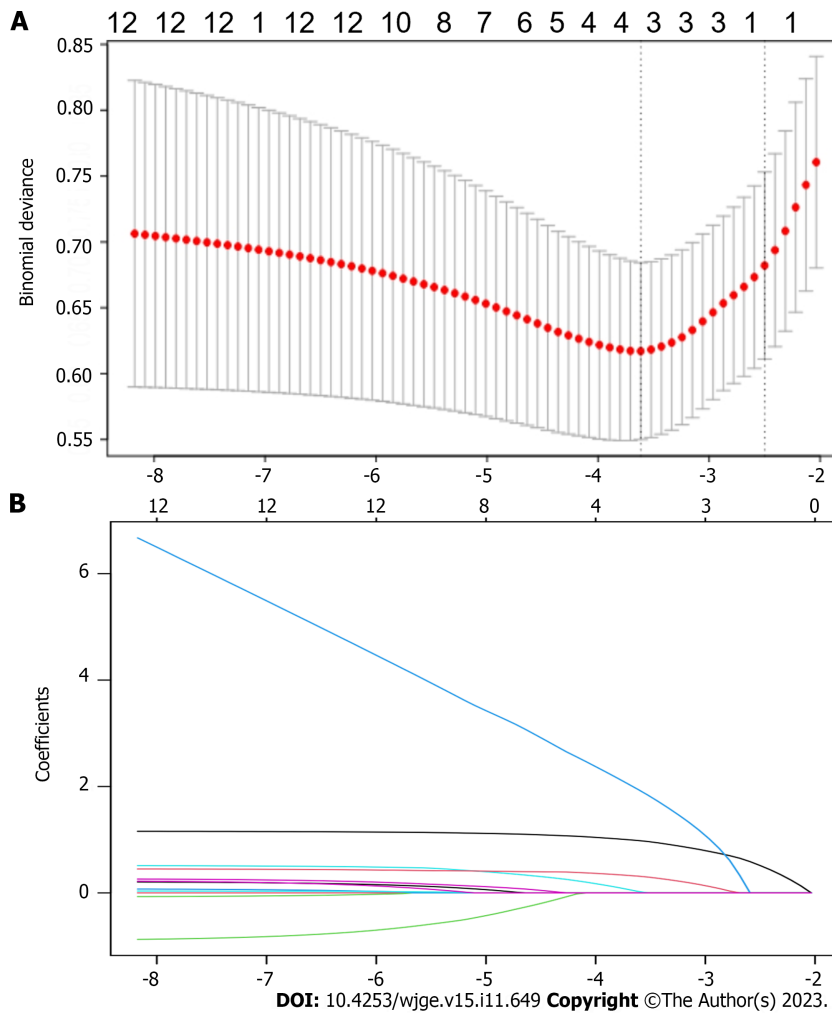
The techniques of transoral endoscopic resection include high-frequency electrocoagulation, ESE, EMR, ESD, STER, and EFTR. High-frequency electrocoagulation resection is routinely applied in clinical practice due to its safety and simplicity. Although technically challenging[13], ESD is preferred for lesions originating from the superficial intrinsic muscular layer. It can also boost overall resection rates and decrease local recurrence rates compared with EMR[14]. A significantly higher incidence of perforation after ESD compared with EMR has been identified (3.6% *vs* 1.2%)[15]. STER is an extension of peroral endoscopic myotomy[16] that is typically used to resect lesions derived from the lamina propria of the esophagus or the cardia, or located in the body of the distal stomach[17]. Compared with ESD, STER helps to preserve the normal mucosal epithelium overlying the lesion surface that reduces the likelihood of gastrointestinal perforation to some extent[18]. One retrospective cohort study found overall STER and ESE resection rates of 70.2% and 67.5% respectively[19].

### Role of EUS in diagnosing lesions

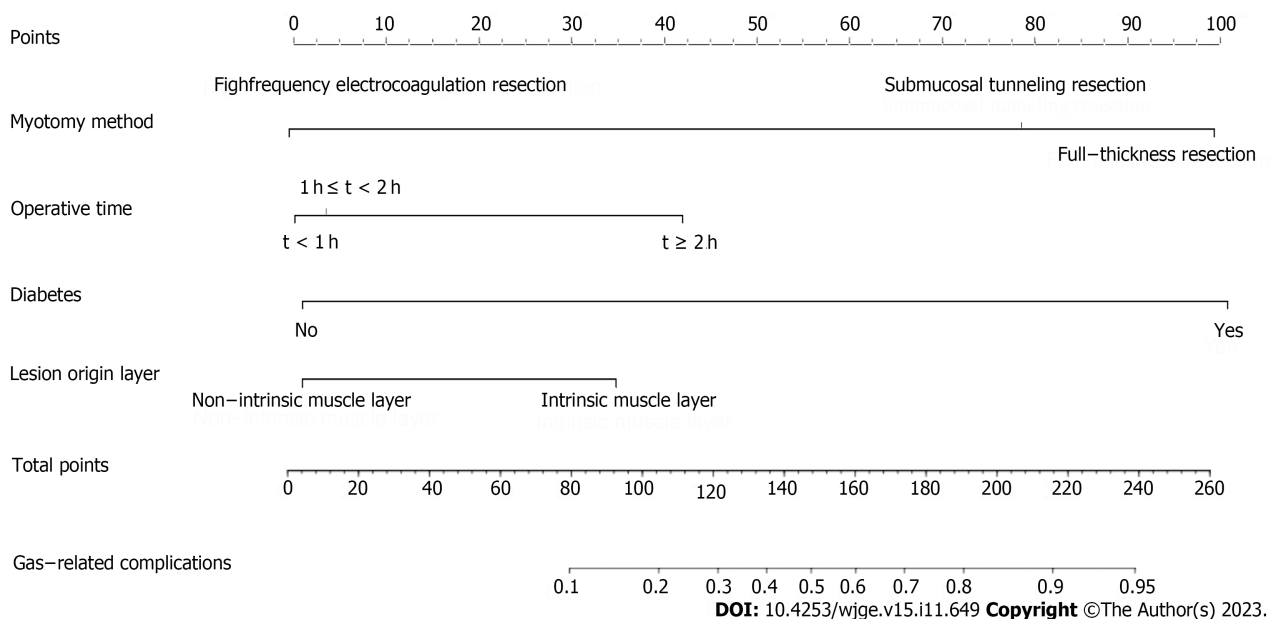
EUS is instrumental for diagnosing and localizing lesions; it uses a high-frequency probe and is frequently used to detect submucosal lesions in the gastrointestinal tract[20,21]. The layered structure of the upper gastrointestinal tract wall can be robustly visualized on EUS images[22], which helps to identifying the origins of lesions[23]. Distinct types of lesions with different ultrasonographic features can be discriminated by EUS[24-26]. Hence, EUS plays a pivotal role in directing the choice of endoscopic treatment.

### Postoperative complications

Complications after transoral endoscopic resection are common, and those that are gas-related are the most frequent[27]. These specific issues arise due to the accumulation of gases in tunnels. During surgery, gas can leak continuously into the mediastinum, subcutaneous space, and thoracic or abdominal cavity due to the integrity of the digestive tract wall being disrupted. Being absorbed 150-fold faster than air in the digestive tract, CO<sub>2</sub> can be eliminated through the pulmonary circulation, significantly reducing the occurrence of gas-related complications, air embolism, and other complications[28-30]. Insufflation with CO<sub>2</sub> effectively diminishes patient discomfort and pain[31-33]. However, rapid CO<sub>2</sub> absorption by the gastrointestinal tract, excessive surgical durations and injections of gas that exceed mucosal absorption capacity can still lead to gas-related complications. This was corroborated by our previous findings[34].

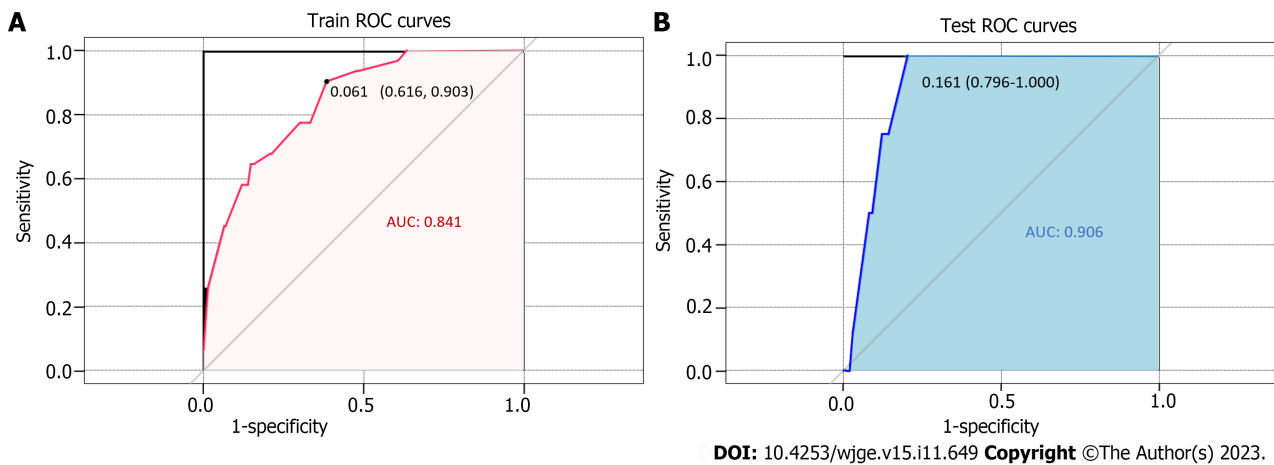


**Figure 1** Variable selection using least absolute shrinkage and selection operator binary logistic regression model. A: The selection of the optimum value of the parameter  $\lambda$  in the Lasso regression model via the cross-validation method; B: The variation characteristics of the variable coefficients.



**Figure 2** Nomogram of predicted likelihood of gas-related complications.





**Figure 3 Receiver operating characteristic curves and respective areas of prediction model.** A: Training group; B: Validation group. AUC: Area under the curve.

The probability of gas-related complications during transoral endoscopic resection significantly varies based on the surgical method of resection. Full-thickness resection inherently risks gastrointestinal tract perforation. Gas-related complications can arise if the gastrointestinal wall is not repaired during the procedure. Submucosal tunnelling resection that removes the mass by creating a tunnel between the mucosa and the submucosa is less likely to have gas-related complications compared with full-thickness resections. However, submucosal tunnelling is susceptible to gas-related complications when the plasma layer is damaged. Leaving the mucosal epithelium on the perforated surface intact and maintaining a distance from the tunnel opening can prevent gas-related complications if the tunnel opening is closed promptly. The present study did not find any gas-related complications due to high-frequency electrocoagulation resection.

Patients with diabetes mellitus (DM) often have compromised immunity. Prolonged hyperglycemia can harm the nervous system and slow peristalsis in the gastrointestinal tract. Prolonged hyperglycemia can also cause microangiopathy, that significantly slows blood flow to the gastric mucosa and weakens its defense mechanism. Anxiety and prolonged tension in some patients can result in sympathetic excitation and vasoconstriction of the gastrointestinal tract, further diminishing mucosal circulation. This can decrease the defensive function of the gastrointestinal mucosa and increase the incidence of gas-related complications during surgery[35].

Therefore, our nomogram can help to screen patients at elevated risk of gas-related complications. Controlling blood glucose levels, reducing surgical durations, and selecting the most appropriate method of surgical resection might positively affect the prognosis of high-risk patients.

However, our study has some limitations. We primarily relied on retrospective data that might not account for all factors such as infection with *Helicobacter pylori* that might be associated with gas-related complications. Furthermore, the data were sourced from a single center with a limited patient cohort. Prospective studies with larger patient cohorts at several institutions are crucial to enhance the predictive capacity of our model. External validation or future prospective trials might help to determine the applicability and generalizability of our model and guide the preoperative management of high-risk patients.

## CONCLUSION

Our nomogram incorporating surgical duration, method of surgical resection, DM, and the lesion layer of origin had excellent predictive efficacy. Its practical application in clinical settings can serve as a valuable guide for endoscopists.

## ARTICLE HIGHLIGHTS

### Research background

With the popularity of endoscopy, more and more digestive tract lesions have been discovered. Some of these lesions affect the quality of life of patients, and are potentially fatal. Oral endoscopic resection is becoming the main treatment.

### Research motivation

Gas-related complications are inevitable in endoscopic resection. The occurrence of gas-related complications during surgery may increase a patient's burden and prolong their hospital stay.

**Research objectives**

The risk factors of gas-related complications were analyzed, and a corresponding prediction model was established.

**Research methods**

The variables were screened by univariate and multivariate analysis.

**Research results**

Univariate analysis showed statistically significant differences in histological type, lesion layer of origin, diabetes, lesion size, surgical duration, and resection method. Diabetes, lesion origin, surgical resection method, and surgical duration were incorporated into the final nomogram.

**Research conclusions**

Our nomogram had excellent predictive efficacy.

**Research perspectives**

We hope to conduct a multi-center study with a larger sample size for verification in the future.

---

**ACKNOWLEDGEMENTS**

---

The authors sincerely appreciate all the patients who contributed to our study.

---

**FOOTNOTES**

---

**Author contributions:** Chen L conceived and designed this study; Yang J and Chen ZG collected and analyzed patient data; Yang J and Yi XL drafted and completed the manuscript; Yang J, Chen ZG, and Chen J prepared the tables and figures; and all authors are accountable for interpreting the data and revising the manuscript.

**Supported by** Gan/University Talent Pool Cultivation Fund, No. XZ-2019-505-017.

**Institutional review board statement:** The First Affiliated Hospital Ethics Committee of the Army Medical University approved the study [Approval ID: (B) KY2023006].

**Informed consent statement:** All patients provided written informed consent.

**Conflict-of-interest statement:** All the authors report no relevant conflicts of interest for this article.

**Data sharing statement:** The data supporting the results of this study are available from the corresponding author upon reasonable request.

**STROBE statement:** The authors have read the STROBE Statement-checklist of items, and the manuscript was prepared and revised according to the STROBE Statement-checklist of items.

**Open-Access:** This article is an open-access article that was selected by an in-house editor and fully peer-reviewed by external reviewers. It is distributed in accordance with the Creative Commons Attribution NonCommercial (CC BY-NC 4.0) license, which permits others to distribute, remix, adapt, build upon this work non-commercially, and license their derivative works on different terms, provided the original work is properly cited and the use is non-commercial. See: <https://creativecommons.org/licenses/by-nc/4.0/>

**Country/Territory of origin:** China

**ORCID number:** Jia Yang 0000-0003-4357-0241; Zhi-Guo Chen 0009-0004-3257-863X; Xing-Lin Yi 0000-0001-9675-9043; Jing Chen 0009-0004-9029-6008; Lei Chen 0000-0002-1400-0728.

**S-Editor:** Wang JJ

**L-Editor:** A

**P-Editor:** Cai YX

---

**REFERENCES**

---

- 1 McCarty TR, Ryou M. Endoscopic diagnosis and management of gastric subepithelial lesions. *Curr Opin Gastroenterol* 2020; **36**: 530-537 [PMID: 32889821 DOI: 10.1097/MOG.0000000000000674]
- 2 Chiu PWY, Yip HC, Chan SM, Ng SKK, Teoh AYB, Ng EKW. Endoscopic full-thickness resection (EFTR) compared to submucosal tunnel

- endoscopic resection (STER) for treatment of gastric gastrointestinal stromal tumors. *Endosc Int Open* 2023; **11**: E179-E186 [PMID: 36845271 DOI: 10.1055/a-1972-3409]
- 3 Lee JH, Lee HL, Ahn YW, Lee KN, Jun DW, Lee OY, Han DS, Yoon BC, Choi HS. Prevalence of Gastric Subepithelial Tumors in Korea: A Single Center Experience. *Korean J Gastroenterol* 2015; **66**: 274-276 [PMID: 26586350 DOI: 10.4166/kjg.2015.66.5.274]
- 4 Lim YJ, Son HJ, Lee JS, Byun YH, Suh HJ, Rhee PL, Kim JJ, Rhee JC. Clinical course of subepithelial lesions detected on upper gastrointestinal endoscopy. *World J Gastroenterol* 2010; **16**: 439-444 [PMID: 20101768 DOI: 10.3748/wjg.v16.i4.439]
- 5 Longcroft-Wheaton G, Bhandari P. Endoscopic resection of submucosal tumors. *Expert Rev Gastroenterol Hepatol* 2015; **9**: 659-669 [PMID: 25634074 DOI: 10.1586/17474124.2015.1003366]
- 6 Lv XH, Wang CH, Xie Y. Efficacy and safety of submucosal tunneling endoscopic resection for upper gastrointestinal submucosal tumors: a systematic review and meta-analysis. *Surg Endosc* 2017; **31**: 49-63 [PMID: 27287907 DOI: 10.1007/s00464-016-4978-7]
- 7 Huang K, Zhao X, Chen X, Gao Y, Yu J, Wu L. Analysis of Digestive Endoscopic Results During COVID-19. *J Transl Int Med* 2021; **9**: 38-42 [PMID: 33850800 DOI: 10.2478/jtim-2021-0006]
- 8 Wang J, Zhao Y, Li P, Zhang S. Advances in The Application of Regenerative Medicine in Prevention of Post-endoscopic Submucosal Dissection for Esophageal Stenosis. *J Transl Int Med* 2022; **10**: 28-35 [PMID: 35702182 DOI: 10.2478/jtim-2022-0011]
- 9 Kim M, Jeon SW, Cho KB, Park KS, Kim ES, Park CK, Seo HE, Chung YJ, Kwon JG, Jung JT, Kim EY, Jang BI, Lee SH, Kim KO, Yang CH; Daegu-Kyungpook Gastrointestinal Study Group (DGSG). Predictive risk factors of perforation in gastric endoscopic submucosal dissection for early gastric cancer: a large, multicenter study. *Surg Endosc* 2013; **27**: 1372-1378 [PMID: 23239296 DOI: 10.1007/s00464-012-2618-4]
- 10 Tay YBE, Loh WS. Extensive subcutaneous emphysema, pneumomediastinum, and pneumorrhachis following third molar surgery. *Int J Oral Maxillofac Surg* 2018; **47**: 1609-1612 [PMID: 29752202 DOI: 10.1016/j.ijom.2018.04.023]
- 11 Moon JS. Role of Endoscopic Ultrasonography in Guiding Treatment Plans for Upper Gastrointestinal Subepithelial Tumors. *Clin Endosc* 2016; **49**: 220-225 [PMID: 27209643 DOI: 10.5946/ce.2016.047]
- 12 Pimentel-Nunes P, Dinis-Ribeiro M, Ponchon T, Repici A, Vieth M, De Ceglie A, Amato A, Berr F, Bhandari P, Bialek A, Conio M, Haringsma J, Langner C, Meisner S, Messmann H, Morino M, Neuhaus H, Piessevaux H, Rugge M, Saunders BP, Robaszekiewicz M, Seewald S, Kashin S, Dumonceau JM, Hassan C, Deprez PH. Endoscopic submucosal dissection: European Society of Gastrointestinal Endoscopy (ESGE) Guideline. *Endoscopy* 2015; **47**: 829-854 [PMID: 26317585 DOI: 10.1055/s-0034-1392882]
- 13 Higuchi K, Katagiri A, Nakatani S, Kikuchi K, Fujiwara T, Gocho T, Inoki K, Konda K, Yamamura F, Yoshida H. Risk Factors Indicating Difficulty During Gastric Endoscopic Submucosal Dissection for Inexperienced Endoscopists: A Retrospective Study. *Cureus* 2022; **14**: e32713 [PMID: 36686130 DOI: 10.7759/cureus.32713]
- 14 Zhao Y, Wang C. Long-Term Clinical Efficacy and Perioperative Safety of Endoscopic Submucosal Dissection versus Endoscopic Mucosal Resection for Early Gastric Cancer: An Updated Meta-Analysis. *Biomed Res Int* 2018; **2018**: 3152346 [PMID: 29568748 DOI: 10.1155/2018/3152346]
- 15 Oda I, Saito D, Tada M, Iishi H, Tanabe S, Oyama T, Doi T, Otani Y, Fujisaki J, Ajioka Y, Hamada T, Inoue H, Gotoda T, Yoshida S. A multicenter retrospective study of endoscopic resection for early gastric cancer. *Gastric Cancer* 2006; **9**: 262-270 [PMID: 17235627 DOI: 10.1007/s10120-006-0389-0]
- 16 Tan Y, Huo J, Liu D. Current status of submucosal tunneling endoscopic resection for gastrointestinal submucosal tumors originating from the muscularis propria layer. *Oncol Lett* 2017; **14**: 5085-5090 [PMID: 29142595 DOI: 10.3892/ol.2017.6869]
- 17 Liu BR, Song JT. Submucosal Tunneling Endoscopic Resection (STER) and Other Novel Applications of Submucosal Tunneling in Humans. *Gastrointest Endosc Clin N Am* 2016; **26**: 271-282 [PMID: 27036897 DOI: 10.1016/j.giec.2015.12.003]
- 18 Kim TW, Kim GH, Park DY, Ahn S, Lim W, Lee BE, Song GA. Endoscopic resection for duodenal subepithelial tumors: a single-center experience. *Surg Endosc* 2017; **31**: 1936-1946 [PMID: 27553800 DOI: 10.1007/s00464-016-5200-7]
- 19 Du C, Chai N, Linghu E, Gao Y, Li Z, Li L, Zhai Y, Lu Z, Meng J, Tang P. Treatment of cardiac submucosal tumors originating from the muscularis propria layer: submucosal tunneling endoscopic resection versus endoscopic submucosal excavation. *Surg Endosc* 2018; **32**: 4543-4551 [PMID: 29766300 DOI: 10.1007/s00464-018-6206-0]
- 20 Asai H, Furukawa K, Miyahara R, Funasaka K, Furune S, Nakamura M, Kawashima H, Ishigami M, Hirooka Y, Fujishiro M. Feasibility of endoscopic ultrasonography using a 60-MHz ultrasound miniature probe in the upper gastrointestinal tract. *J Med Ultrason (2001)* 2022; **49**: 61-69 [PMID: 34826014 DOI: 10.1007/s10396-021-01172-5]
- 21 Kamata K, Kurita A, Yasukawa S, Chiba Y, Nebiki H, Asada M, Yasuda H, Shiomi H, Ogura T, Takaoka M, Hoki N, Ashida R, Shigekawa M, Yanagisawa A, Kudo M, Kitano M. Utility of a 20G needle with a core trap in EUS-guided fine-needle biopsy for gastric submucosal tumors: A multicentric prospective trial. *Endosc Ultrasound* 2021; **10**: 134-140 [PMID: 33586688 DOI: 10.4103/EUS-D-20-00171]
- 22 Muto M. Endoscopic diagnostic strategy of superficial esophageal squamous cell carcinoma. *Dig Endosc* 2013; **25** Suppl 1: 1-6 [PMID: 23406378 DOI: 10.1111/den.12025]
- 23 Karaca C, Turner BG, Cizginer S, Forcione D, Brugge W. Accuracy of EUS in the evaluation of small gastric subepithelial lesions. *Gastrointest Endosc* 2010; **71**: 722-727 [PMID: 20171632 DOI: 10.1016/j.gie.2009.10.019]
- 24 Azuma M, Kusano C, Gotoda T. Diagnostic potential of endoscopic ultrasonography-elastography for gastric submucosal tumors. *Dig Endosc* 2015; **27** Suppl 1: 23 [PMID: 25556630 DOI: 10.1111/den.12429]
- 25 Li S, Gao M, Tao L, Luo G, Gao Q, Qian K, Deng L. Clusters of malignant cysts in the gastric submucosal layer (with video). *Endosc Ultrasound* 2022; **11**: 518-519 [PMID: 36537391 DOI: 10.4103/EUS-D-21-00133]
- 26 Reinecke J, Amanzada A, Elger F, Ghadimi M, Neesse A. A rare cause of upper gastrointestinal bleeding from a submucosal tumor. *Endosc Ultrasound* 2021; **10**: 75-76 [PMID: 33402553 DOI: 10.4103/eus.eus\_75\_20]
- 27 Oka S, Tanaka S, Kaneko I, Mouri R, Hirata M, Kawamura T, Yoshihara M, Chayama K. Advantage of endoscopic submucosal dissection compared with EMR for early gastric cancer. *Gastrointest Endosc* 2006; **64**: 877-883 [PMID: 17140890 DOI: 10.1016/j.gie.2006.03.932]
- 28 Yasumasa K, Nakajima K, Endo S, Ito T, Matsuda H, Nishida T. Carbon dioxide insufflation attenuates parietal blood flow obstruction in distended colon: potential advantages of carbon dioxide insufflated colonoscopy. *Surg Endosc* 2006; **20**: 587-594 [PMID: 16437273 DOI: 10.1007/s00464-005-0252-0]
- 29 Xu MD, Cai MY, Zhou PH, Qin XY, Zhong YS, Chen WF, Hu JW, Zhang YQ, Ma LL, Qin WZ, Yao LQ. Submucosal tunneling endoscopic resection: a new technique for treating upper GI submucosal tumors originating from the muscularis propria layer (with videos). *Gastrointest Endosc* 2012; **75**: 195-199 [PMID: 22056087 DOI: 10.1016/j.gie.2011.08.018]

- 30 **Hirai F**, Beppu T, Nishimura T, Takatsu N, Ashizuka S, Seki T, Hisabe T, Nagahama T, Yao K, Matsui T, Nakashima R, Inada N, Tajiri E, Mitsuru H, Shigematsu H. Carbon dioxide insufflation compared with air insufflation in double-balloon enteroscopy: a prospective, randomized, double-blind trial. *Gastrointest Endosc* 2011; **73**: 743-749 [PMID: [21237455](#) DOI: [10.1016/j.gie.2010.10.003](#)]
- 31 **Dellon ES**, Hawk JS, Grimm IS, Shaheen NJ. The use of carbon dioxide for insufflation during GI endoscopy: a systematic review. *Gastrointest Endosc* 2009; **69**: 843-849 [PMID: [19152906](#) DOI: [10.1016/j.gie.2008.05.067](#)]
- 32 **Yamano HO**, Yoshikawa K, Kimura T, Yamamoto E, Harada E, Kudou T, Katou R, Hayashi Y, Satou K. Carbon dioxide insufflation for colonoscopy: evaluation of gas volume, abdominal pain, examination time and transcutaneous partial CO<sub>2</sub> pressure. *J Gastroenterol* 2010; **45**: 1235-1240 [PMID: [20635100](#) DOI: [10.1007/s00535-010-0286-5](#)]
- 33 **Suzuki T**, Minami H, Komatsu T, Masuda R, Kobayashi Y, Sakamoto A, Sato Y, Inoue H, Serada K. Prolonged carbon dioxide insufflation under general anesthesia for endoscopic submucosal dissection. *Endoscopy* 2010; **42**: 1021-1029 [PMID: [21120775](#) DOI: [10.1055/s-0030-1255969](#)]
- 34 **Lee IL**, Wu CS, Tung SY, Lin PY, Shen CH, Wei KL, Chang TS. Endoscopic submucosal dissection for early gastric cancers: experience from a new endoscopic center in Taiwan. *J Clin Gastroenterol* 2008; **42**: 42-47 [PMID: [18097288](#) DOI: [10.1097/01.mcg.0000225696.54498.ff](#)]
- 35 **Zhang S**, Wen J, Du M, Liu Y, Zhang L, Chu X, Xue Z. Diabetes is an independent risk factor for delayed perforation after foreign bodies impacted in esophagus in adults. *United European Gastroenterol J* 2018; **6**: 1136-1143 [DOI: [10.1177/2050640618784344](#)]



Published by **Baishideng Publishing Group Inc**  
7041 Koll Center Parkway, Suite 160, Pleasanton, CA 94566, USA

**Telephone:** +1-925-3991568

**E-mail:** [bpgoffice@wjgnet.com](mailto:bpgoffice@wjgnet.com)

**Help Desk:** <https://www.f6publishing.com/helpdesk>

<https://www.wjgnet.com>

