

World Journal of *Gastrointestinal Endoscopy*

World J Gastrointest Endosc 2023 November 16; 15(11): 634-680



MINIREVIEWS

- 634 Endoscopic ultrasound guided gastroenterostomy: Technical details updates, clinical outcomes, and adverse events

Wang J, Hu JL, Sun SY

ORIGINAL ARTICLE

Retrospective Cohort Study

- 641 Endoscopic retrograde cholangiopancreatography-related early perforations: A study of effects of procedure duration, complexity, and endoscopist experience

Aloysius M, Goyal H, Nikumbh T, Shah NJ, Hammoud GM, Mutha P, Joseph-Talreja M, John S, Aswath G, Wadhwa V, Thosani N

- 649 Nomogram to predict gas-related complications during transoral endoscopic resection of upper gastrointestinal submucosal lesions

Yang J, Chen ZG, Yi XL, Chen J, Chen L

Basic Study

- 658 Animal experimental study on magnetic anchor technique-assisted endoscopic submucosal dissection of early gastric cancer

Pan M, Zhang MM, Zhao L, Lyu Y, Yan XP

CASE REPORT

- 666 Hybrid laparo-endoscopic access: New approach to surgical treatment for giant fibrovascular polyp of esophagus: A case report and review of literature

Dzhantukhanova S, Avetisyan LG, Badakhova A, Starkov Y, Glotov A

- 676 General anesthesia with endotracheal intubation ensures the quick removal of magnetic foreign bodies: A case report

Tian QF, Zhao AX, Du N, Wang ZJ, Ma LL, Men FL

ABOUT COVER

Editorial Board Member of *World Journal of Gastrointestinal Endoscopy*, Istvan Hritz, MD, PhD, Associate Professor, Doctor, First Department of Surgery and Interventional Gastroenterology, Semmelweis University, Budapest 1082, Hungary. istvan.hritz@gmail.com

AIMS AND SCOPE

The primary aim of *World Journal of Gastrointestinal Endoscopy* (WJGE, *World J Gastrointest Endosc*) is to provide scholars and readers from various fields of gastrointestinal endoscopy with a platform to publish high-quality basic and clinical research articles and communicate their research findings online.

WJGE mainly publishes articles reporting research results and findings obtained in the field of gastrointestinal endoscopy and covering a wide range of topics including capsule endoscopy, colonoscopy, double-balloon enteroscopy, duodenoscopy, endoscopic retrograde cholangiopancreatography, endosonography, esophagoscopy, gastrointestinal endoscopy, gastroscopy, laparoscopy, natural orifice endoscopic surgery, proctoscopy, and sigmoidoscopy.

INDEXING/ABSTRACTING

The WJGE is now abstracted and indexed in Emerging Sources Citation Index (Web of Science), PubMed, PubMed Central, Reference Citation Analysis, China National Knowledge Infrastructure, China Science and Technology Journal Database, and Superstar Journals Database. The 2023 Edition of Journal Citation Reports® cites the 2022 impact factor (IF) for WJGE as 2.0; IF without journal self cites: 1.9; 5-year IF: 3.3; Journal Citation Indicator: 0.28.

RESPONSIBLE EDITORS FOR THIS ISSUE

Production Editor: Yi-Xuan Cai; Production Department Director: Xu Guo; Editorial Office Director: Jia-Ping Yan.

NAME OF JOURNAL

World Journal of Gastrointestinal Endoscopy

ISSN

ISSN 1948-5190 (online)

LAUNCH DATE

October 15, 2009

FREQUENCY

Monthly

EDITORS-IN-CHIEF

Anastasios Koulaouzidis, Bing Hu, Sang Chul Lee, Joo Young Cho

EDITORIAL BOARD MEMBERS

<https://www.wjgnet.com/1948-5190/editorialboard.htm>

PUBLICATION DATE

November 16, 2023

COPYRIGHT

© 2023 Baishideng Publishing Group Inc

INSTRUCTIONS TO AUTHORS

<https://www.wjgnet.com/bpg/gerinfo/204>

GUIDELINES FOR ETHICS DOCUMENTS

<https://www.wjgnet.com/bpg/GerInfo/287>

GUIDELINES FOR NON-NATIVE SPEAKERS OF ENGLISH

<https://www.wjgnet.com/bpg/gerinfo/240>

PUBLICATION ETHICS

<https://www.wjgnet.com/bpg/GerInfo/288>

PUBLICATION MISCONDUCT

<https://www.wjgnet.com/bpg/gerinfo/208>

ARTICLE PROCESSING CHARGE

<https://www.wjgnet.com/bpg/gerinfo/242>

STEPS FOR SUBMITTING MANUSCRIPTS

<https://www.wjgnet.com/bpg/GerInfo/239>

ONLINE SUBMISSION

<https://www.f6publishing.com>



Basic Study

Animal experimental study on magnetic anchor technique-assisted endoscopic submucosal dissection of early gastric cancer

Min Pan, Miao-Miao Zhang, Lin Zhao, Yi Lyu, Xiao-Peng Yan

Specialty type: Gastroenterology and hepatology

Provenance and peer review:

Unsolicited article; Externally peer reviewed.

Peer-review model: Single blind

Peer-review report's scientific quality classification

Grade A (Excellent): 0

Grade B (Very good): 0

Grade C (Good): C, C

Grade D (Fair): 0

Grade E (Poor): E

P-Reviewer: De Luca L, Italy;

Mohamed SY, Egypt; Neri V, Italy

Received: August 12, 2023

Peer-review started: August 12, 2023

First decision: October 8, 2023

Revised: October 16, 2023

Accepted: October 26, 2023

Article in press: October 26, 2023

Published online: November 16, 2023



Min Pan, Miao-Miao Zhang, Lin Zhao, Yi Lyu, Xiao-Peng Yan, Department of Hepatobiliary Surgery, The First Affiliated Hospital of Xi'an Jiaotong University, Xi'an 710061, Shaanxi Province, China

Min Pan, Department of Thoracic Surgery, The First Affiliated Hospital of Xi'an Jiaotong University, Xi'an 710061, Shaanxi Province, China

Miao-Miao Zhang, Yi Lyu, Xiao-Peng Yan, National Local Joint Engineering Research Center for Precision Surgery & Regenerative Medicine, The First Affiliated Hospital of Xi'an Jiaotong University, Xi'an 710061, Shaanxi Province, China

Lin Zhao, Zonglian College, Xi'an Jiaotong University, Xi'an 710061, Shaanxi Province, China

Corresponding author: Xiao-Peng Yan, MD, PhD, Assistant Professor, Associate Research Scientist, Chief Doctor, Department of Hepatobiliary Surgery, The First Affiliated Hospital of Xi'an Jiaotong University, No. 277 West Yanta Road, Xi'an 710061, Shaanxi Province, China. yanxiaopeng9966@163.com

Abstract

BACKGROUND

Gastric cancer (GC) has high morbidity and mortality. Moreover, because GC has no typical symptoms in the early stages, most cases are already in the advanced stages by the time the symptoms appear, thus resulting in poor prognosis and a low survival rate. Endoscopic submucosal dissection (ESD) can realize the early detection and diagnosis of GC and become the main surgical method for early GC. However, ESD has a steep learning curve and high technical skill requirements for endoscopists, which is not conducive to its widespread implementation and advancement. Therefore, a series of auxiliary techniques have been derived.

AIM

To evaluate the safety and efficacy of magnetic anchor technique (MAT)-assisted ESD in early GC.

METHODS

This was an *ex vivo* animal experiment. The experimental models were the isolated stomachs of pigs, which were divided into two groups, namely the study group ($n = 6$) with MAT-assisted ESD and the control group ($n = 6$) with traditional ESD. Comparing the total surgical time, incidence of surgical complica-

ations, complete mucosal resection rate, specimen size, and the scores of endoscopist's satisfaction with the procedure reflected their feelings about convenience during the surgical procedure between the two groups. The magnetic anchor device for auxiliary ESD in the study group comprised three parts, an anchor magnet (AM), a target magnet (TM), and a soft tissue clip. Under gastroscopic guidance, the soft tissue clip and the TM were delivered to the pre-marked mucosal lesion through the gastroscopic operating hole. The soft tissue clip and the TM were connected by a thin wire through the TM tail structure. The soft tissue clip was released by manipulating the operating handle of the soft tissue clip in a way that the soft tissue clip and the TM were fixed to the lesion mucosa. *In vitro*, ESD is aided by maneuvering the AM such that the mucosal dissection surface is exposed.

RESULTS

The total surgical time was shorter in the study group than in the control group (26.57 ± 0.19 vs 29.97 ± 0.28 , $P < 0.001$), and the scores of endoscopist's satisfaction with the procedure were higher in the study group than in the control group (9.53 ± 0.10 vs 8.00 ± 0.22 , $P < 0.001$). During the operation in the study group, there was no detachment of the soft tissue clip and TM and no mucosal tearing. The magnetic force between the AM and TM provided good mucosal exposure and sufficient tissue tension for ESD. The mucosal lesion was completely peeled off, and the operation was successful. There were no significant differences in the incidence of surgical complications (100% vs 83.3%), complete mucosal resection rate (100% vs 66.7%, $P = 0.439$), and specimen size (2.44 ± 0.04 cm vs 2.49 ± 0.02 , $P = 0.328$) between the two groups.

CONCLUSION

MAT-ESD is safe and effective for early GC. It provides a preliminary basis for subsequent internal animal experiments and clinical research.

Key Words: Endoscopic submucosal dissection; Gastric cancer; Digestive disease; Magnetic anchor technique; Magnetic surgery; Magnetic anchor device

©The Author(s) 2023. Published by Baishideng Publishing Group Inc. All rights reserved.

Core Tip: Endoscopic submucosal dissection (ESD) is helpful in the early detection and treatment of gastric cancer but has a long learning curve. Magnetic anchor technique (MAT) was used to shorten the total surgical time and improve the endoscopist's satisfaction with the surgical procedure by providing good mucosal exposure and sufficient tissue tension for ESD. MAT shows advantages over other assistive technologies, such as the flexibility to change the magnitude and direction of traction. This method shows great auxiliary potential in ESD and has good prospects for clinical application.

Citation: Pan M, Zhang MM, Zhao L, Lyu Y, Yan XP. Animal experimental study on magnetic anchor technique-assisted endoscopic submucosal dissection of early gastric cancer. *World J Gastrointest Endosc* 2023; 15(11): 658-665

URL: <https://www.wjgnet.com/1948-5190/full/v15/i11/658.htm>

DOI: <https://dx.doi.org/10.4253/wjge.v15.i11.658>

INTRODUCTION

Cancer continues to be an immense threat to human health and exerts a huge medical and economic burden. In 2020, there were more than 1 million new cases of gastric cancer (GC) and an estimated 769000 deaths (equivalent to 1 in 13 deaths globally). GC has the fifth-highest incidence and the fourth-highest mortality of all cancers worldwide[1]. Due to its large population, China accounts for approximately 44% of GC cases worldwide, and in 2020, GC in China had an adjusted incidence rate of 20.6/100000 individuals[2]. GC is usually at an advanced stage by the time the symptoms appear, which leads to a poor prognosis. Although the 5-year survival rate for advanced GC is 10%, the 5-year survival rate for early GC can be as high as 85%[3]. Therefore, it is possible to carry out population-based screening in high-risk areas or high-risk groups to achieve early detection, diagnosis, and treatment of GC, thus reducing the burden of GC on public health. The use of endoscopy screening in high-risk groups can reportedly significantly reduce GC mortality[4,5]. At present, the 5-year survival rates of GC in Japan and South Korea are relatively high at 60.3% and 68.9%, respectively [6]. These rates are attributed to the effectiveness of large-scale endoscopic screening programs, which help identify a higher proportion of early GC cases at the time of screening[7,8].

The primary treatment option for early GC is endoscopic therapy, which includes endoscopic mucosal resection (EMR) and endoscopic submucosal dissection (ESD)[9,10]. ESD is developed on the basis of EMR and is used for dissecting large tumor lesions that are not suitable for EMR[11]. Compared with EMR, ESD has higher en bloc resection rates (90.2 vs 51.7%), higher histologic complete resection rates (82.1 vs 42.2%), and lower recurrence rates (0.65% vs 6.05%)[12]. However, ESD is not like traditional surgery, and as the surgeon's hand cannot enter the alimentary canal lumen, it is difficult to obtain sufficient tension and good field. These challenges result in a long operation time, high risk of adverse

events, and high incidence of postoperative complications (bleeding and perforation)[13]. Therefore, to circumvent these challenges and avoid these complications, many assistive technologies have been developed[13], such as the clip-with-line method[14], pulley method[15,16], sheath traction method[17,18], external forceps method[19,20], double scope method[21], the S-O clip[22,23], ring thread countertraction[24], multiloop technique[25], double clip and rubber band traction[26], clip band technique[27], pocket creation method with a traction device[28], and clip-flap method[29]. However, these auxiliary techniques have some disadvantages, such as inflexibility in changing the magnitude of the traction force, a single direction of the traction force, and inability to resect any lesion regardless of its location.

Magnetic anchor technique (MAT)-assisted ESD is a new type of assistive technology with some potential advantages, such as control over traction direction and traction size. It was first proposed by Kobayashi *et al*[30] in 2004. The magnetic anchor system includes internal and external magnetic components. The outer magnetic assembly is usually a permanent magnet, and the inner magnetic assembly includes an inner magnet and a tissue clip[31]. MAT-ESD has been successfully applied to various thoracoscopy and laparoscopy procedures, such as laparoscopic cholecystectomy[32] and thoracoscopic lobectomy[33]. The application of this technique reduces surgical trauma and interference between surgical instruments, thus improving the exposure of the surgical field and the operability of the surgery[31]. Therefore, in this study, we explored the safety and feasibility of MAT-ESD in early GC in an *in vitro* porcine model using the self-designed magnetic anchor device.

MATERIALS AND METHODS

Magnetic anchor device

The self-designed magnetic anchor device made by Shaanxi Jinshan Electric Co., Ltd. comprises three parts (Figure 1): The anchor magnet (AM), the target magnet (TM), and the soft tissue clip. The AM is a cylinder made of the Nd-Fe-B permanent magnet material, and the surface is protected by nickel plating. To avoid interference from other ferromagnetic objects during use, the AM cylinder is covered with a 5-mm U-shaped resin shell. The AM is located outside the body and is used to pull the TM. The AM is 140-mm high and has a base diameter of 50 mm and a surface field strength of 6000 GS. The TM is also made of the Nd-Fe-B permanent magnet material. The TM is divided into a cylindrical magnetic core and a permalloy shell. The surface is coated with nickel or titanium nitride. The TM is sent into the digestive tract through the gastroscopic biopsy hole. To adapt to the size of the digestive tract, the magnetic core is a cylinder with a height of 5.5 mm and a bottom diameter of 4 mm, and the surface field strength is 3000 GS. In addition, the permalloy tail has a circular hole structure with a diameter of 1 mm for connection with soft tissue clips. The soft tissue clip is processed by the Micro-Tech (Nanjing) Co., Ltd. It can be connected to the tail end structure of the TM through a thin wire, and the TM can be fixed to the lesion mucosa.

Animals

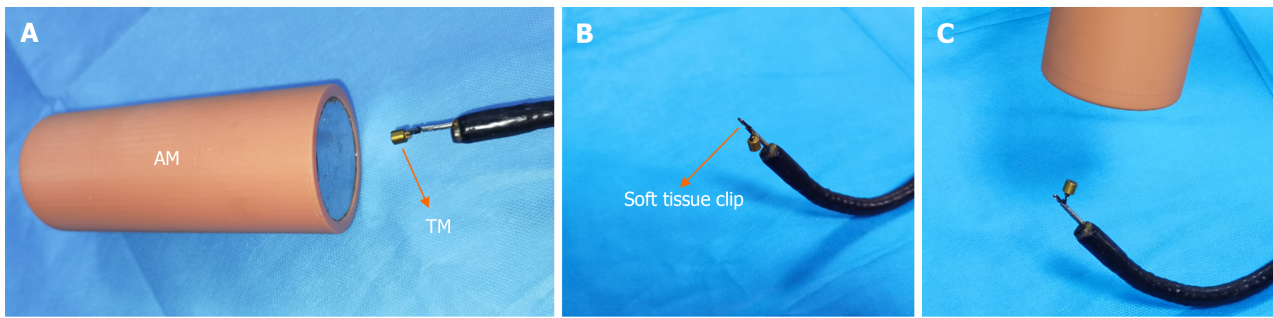
This *ex vivo* experiment involved two groups: The study group (MAT-ESD) and the control group (traditional ESD). The pigs were obtained from the Experimental Animal Center of Xi'an Jiaotong University. The animal protocol was designed to minimize pain or discomfort to the animals. The isolated pigs' stomachs were obtained from euthanized pigs; euthanasia was performed by an intravenous overdose of sodium pentobarbital (60 mg/kg) after the end of other experimental projects by our team. We used stomachs isolated from 12 Bama miniature pigs, with 6 pigs (3 males and 3 females) in the study group and the other 6 pigs (3 males and 3 females) in the control group. The sex of the animal was not a factor in data analyses. A total of 6 endoscopists completed the surgery for both groups. The experimental protocol was approved by the laboratory animal care committee of Xi'an Jiaotong University (approval NO. XJTULAC2019-1006) and was in accordance with the ethical standards for experimental animals of Xi'an Jiaotong University. All animal experiments complied with the ARRIVE guidelines and were carried out in accordance with the National Institutes of Health Guide for the Care and Use of Laboratory Animals (Eighth edition, 2011).

Surgical procedure in the study group

On the basis of the end of other animal experiments, the isolated pig stomachs were obtained, and about 5 cm of the esophagus and duodenal stump was retained. First, the duodenal stump was clamped with intestinal forceps, and then, a gastroscope was inserted from the esophageal stump to inflate and observe the airtightness of the stomach and the integrity of the mucosa (Figure 2A). Second, the mucosal lesion to be resected was marked by electrocautery under gastroscopic guidance (Figure 2B). Third, the TM was fixed to the mucosal lesion by a soft tissue clip. The soft tissue clip was inserted through the operation hole of the gastroscope, and the TM was connected to the soft tissue clip with a thin wire; however, the TM did not affect the opening and closing of the soft tissue clip (Figure 2C). Finally, the magnetic force between TM and AM was used to expose the mucosal dissection surface and maintain tissue tension. The AM was gradually brought close to the stomach *in vitro*, and the state of the TM was observed using the endoscope (Figure 2D). The TM was seen to be pulled toward the AM, and at the same time, the soft tissue clip was driven to lift the lesion mucosa. The position of the AM was adjusted according to the operation requirements, and the pulling direction and strength of the mucosal lesion were flexibly changed until the lesion was completely removed (Figure 2E and F).

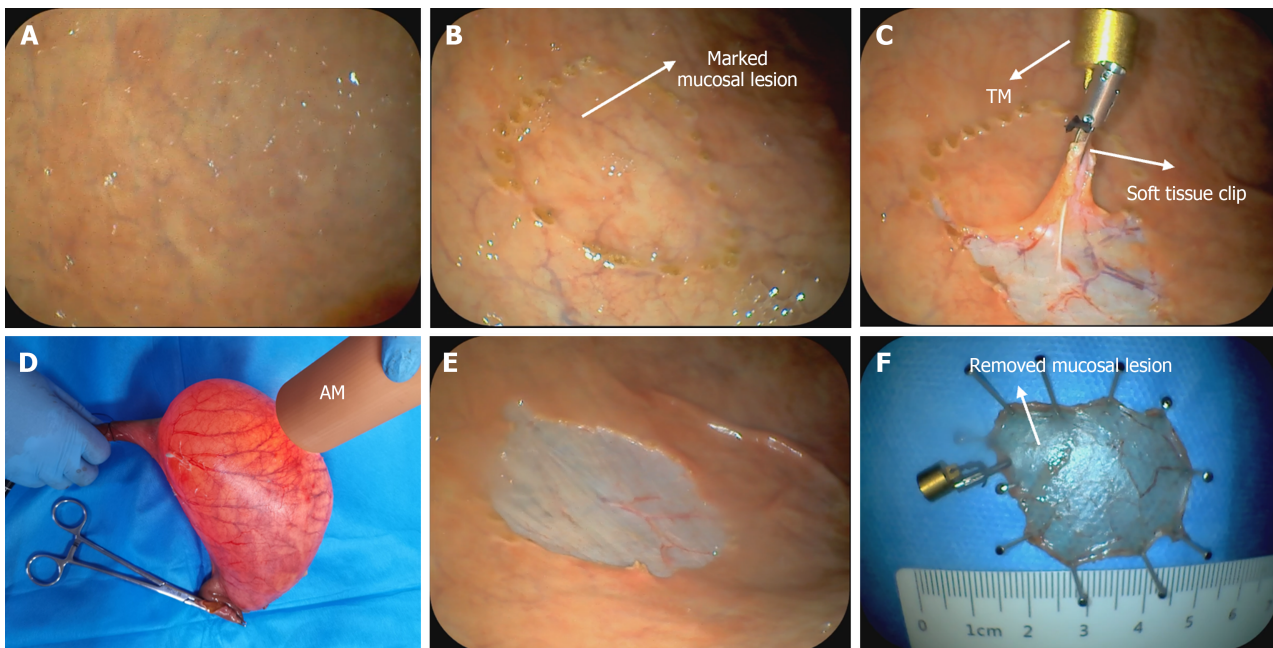
Statistical analysis

The statistical methods of this study were reviewed by Xiao-Peng Yan from the first affiliated hospital of Xi'an Jiaotong University before the submission. The quantitative data that were consistent with the normal distribution were expressed



DOI: 10.4253/wjge.v15.i11.658 Copyright ©The Author(s) 2023.

Figure 1 Magnetic anchor device. A: The anchor magnet (AM) and target magnet (TM); B: The soft tissue clip; C: The connection between the TM and soft tissue clip, and the magnetic force between the AM and TM. AM: anchor magnetic; TM: target magnetic.



DOI: 10.4253/wjge.v15.i11.658 Copyright ©The Author(s) 2023.

Figure 2 Magnetic anchor technique-assisted endoscopic submucosal dissection operation process. A: The isolated stomach was examined using a gastroscope; B: The mucosal lesion to be resected was marked by electrocautery under gastroscopic guidance; C: The target magnet (TM) and the soft tissue clip were connected and placed in the gastric lumen and the soft tissue clips clamped the mucosa; D: Anchor magnet (AM) was placed outside the stomach. Under the attraction of the AM, the TM hangs in the stomach cavity and pulls the mucosa; E and F: The mucosal lesion has been stripped.

as mean \pm SD. Two-group mean comparison was performed using the independent *t*-test. Non-normally distributed data were expressed as the median (interquartile interval). The nonparametric test was used for comparisons between the two groups. Qualitative data were expressed as the number of actual cases (proportion, %), and its comparisons were drawn using the χ^2 test. Statistical analysis was performed using IBM SPSS Statistics version 26.0 (IBM Corp., Armonk, NY), with $P < 0.05$ indicating statistical significance.

RESULTS

According to Table 1, the mean total surgical time was 26.57 min in the study group and 29.97 min in the control group. With the assistance of MAT, the total surgical time was greatly reduced and the endoscopist's surgical satisfaction scores were improved (9.53 *vs* 8.00, $P < 0.001$). By clamping the duodenal stump, the isolated stomach was made airtight, and the mucosa was intact. In the study group, after the mucosal lesion was successfully marked, the gastroscope, the TM, and the soft tissue clip were smoothly entered into the stomach through the digestive tract and advanced until the lesion was reached. During the entire operation, the soft tissue clip was tightly connected with the TM to avoid falling off or separation, and the TM did not affect the opening, closing, and release of the soft tissue clip. Furthermore, surgical instruments, except the AM and TM, were not disturbed by the magnetic force. By changing the position of the AM, the pulling direction and pulling force of the soft tissue clip could be easily changed, the mucosal dissection surface was well

Table 1 Comparison between the study group and control group

	Study group (n = 6)	Control group (n = 6)	P value
Total surgical time (min)	26.57 ± 0.19	29.97 ± 0.28	< 0.001
Incidence of surgical complications ¹ (%)	100	83.3	-
Complete mucosal resection rate (%)	100	66.7	0.439
Specimen size (diameter, cm)	2.44 ± 0.04	2.49 ± 0.02	0.328
Endoscopist's satisfaction with the procedure ² (score)	9.53 ± 0.10	8.00 ± 0.22	< 0.001

¹Incidence of surgical complications include bleeding and perforation.

²Endoscopist's surgical satisfaction scores which ranged from 0 to 10 reflect their feelings about convenience with the surgical procedure. Higher scores indicate better satisfaction.

exposed, and sufficient tension was maintained. In addition, the soft tissue clip did not fall off and the mucosa was not torn. The marked mucosal lesions were completely stripped without any complications, but there was one case of perforation and two cases of incompletely stripped marked mucosal lesions in the control group. The diameters of specimen sizes did not significantly differ between the two groups (2.44 *vs* 2.49, *P* > 0.05; Table 1).

DISCUSSION

Our results emphasize the safety and efficacy MAT-ESD in early GC. Six operations were successfully completed, and in all of these operations, the mucosal lesion was completely peeled off without tearing of the mucosa or detachment of the TM and soft tissue clip.

The MAT belongs to the category of magnetic surgery. It is currently an auxiliary technique for ESD with great application prospects. The MAT primarily uses the magnetic force between the magnets, and this helps overcome the disadvantage of ESD being difficult to operate and also gives the endoscope operator a “third hand”. The magnetic materials used in the magnetic anchor system are primarily electromagnets and permanent magnets[34]. For electromagnets, the intensity of the magnetic field can be controlled by changing the amount of electricity. However, they are large and bulky, making it challenging to use them in the narrow digestive tract. Conversely, high-performance permanent magnets are based on compounds with excellent intrinsic magnetic properties and optimized microstructure and alloy composition. At present, the most powerful permanent magnet materials are RE-TM intermetallic alloys, which derive their exceptional magnetic properties from the favorable combination of rare earth metals (RE = Nd, Pr, and Sm) with transition metals (TM = Fe and Co); specifically, magnets based on (Nd, Pr)₂Fe₁₄B and Sm₂(Co, Cu, Fe, Zr)₁₇ are particularly good permanent magnets[35]. In addition, considering the low corrosion resistance of neodymium magnets, which is of particular concern in the acidic environment of the stomach, and the possibility of interference of the magnetic field with other surgical instruments, the shielding material used must be inert to the human body and unobstructed to the magnetic field, such as titanium alloys, ring oxygen resin, or a copper-based alloy (with additional coating)[34].

The TM used in previous studies is a simple magnetic ring[36-38], whereas our TM uses permanent magnets (Nd-Fe-B) and a permalloy shell to shield the impact of magnetic fields on surgical instruments and people, thus enhancing the attraction between the AM and TM. Finally, the size of the TM was optimized considering the size of the digestive tract and the physiological environment, and the tail suspension structure was designed for connection with the soft tissue clip considering both the characteristics of the digestive tract and magnetic requirements.

The main disadvantage of this experiment is that it was an external experiment, and the findings may differ in an internal animal experiment or a clinical study. However, we were unable to assess the risk of postoperative complications, such as bleeding, perforation, and strictures. Second, because the abdominal thickness in human beings differs from that in pigs, our findings cannot help predict the effect of abdominal wall thickness when this technique is applied to humans. Third, because the mucosal lesion is marked by the experimenter and is subjective, it was not possible to evaluate the influence of surgery on the size and location of the lesion.

However, MAT has shown great clinical potential when used as an auxiliary technique for ESD. The results of this study show that MAT-ESD is safe and effective. This study lays a solid foundation for the next animal experiment and clinical study and provides a preliminary foundation for the accuracy and optimization of the magnetic anchor device.

CONCLUSION

The safety and efficacy of MAT-ESD have been demonstrated in early GC, albeit only in external animal experiments. However, MAT shows advantages over other assistive technologies, such as flexibility to change the magnitude and direction of traction. This method shows great auxiliary potential in ESD and has good prospects for clinical application.

ARTICLE HIGHLIGHTS

Research background

Gastric cancer (GC) has high morbidity and mortality, which are already in the advanced stages when diagnosed, resulting in poor prognosis and a low survival rate. Endoscopic submucosal dissection (ESD) has become the main surgical method for early GC, improving the detection and therapy of GC. However, endoscopists are limited by some deficiencies of ESD, such as the steep learning curve and high technical skill requirements. Therefore, an assistant technique, the magnetic anchor technique (MAT), has been invented to improve the procedure of ESD.

Research motivation

ESD has become the standard therapy for early GC, but it still has the space for improvement. There are some assisted techniques, such as the clip-with-line method, pulley method, sheath traction method, and external forceps method, improving the endoscopists' feeling of operation. However, recent assisted techniques also have trouble controlling and maintaining tissue tension. Our own designed assisted technique, MAT, are objective to solve the mentioned problems above.

Research objectives

This study aims to evaluate the safety and efficacy of MAT-assisted ESD in early GC.

Research methods

This was an *ex vivo* animal experiment. The experimental models were the isolated stomachs of pigs, which were divided into two groups, namely the study group ($n = 6$) with MAT-assisted ESD and the control group ($n = 6$) with traditional ESD. The magnetic anchor device for assisting ESD in the study group comprised three parts, an anchor magnet (AM), a target magnet (TM), and a soft tissue clip. The soft tissue clip and the TM, which were connected by a thin wire through the TM tail structure, were delivered to the pre-marked mucosal lesion through the gastroscopic operating hole under gastroscopic guidance. Then, the soft tissue clip was released by manipulating the operating handle of the soft tissue clip in a way that the soft tissue clip and the TM were fixed to the lesion mucosa. *In vitro*, ESD is aided by maneuvering the AM such that the mucosal dissection surface is exposed. Finally, Comparing the total surgical time, incidence of surgical complications, complete mucosal resection rate, specimen size, and the scores of endoscopist's satisfaction with the procedure reflected their feelings about convenience during the surgical procedure between the two groups.

Research results

All operations were successfully completed. The total surgical time was shorter in the study group than in the control group (26.57 ± 0.19 vs 29.97 ± 0.28 , $P < 0.001$), and during the operation in the study group, and there were no significant differences in the incidence of surgical complications (100% vs 83.3%), complete mucosal resection rate (100% vs 66.7%, $P = 0.439$), and specimen size (2.44 ± 0.04 cm vs 2.49 ± 0.02 , $P = 0.328$) between the two groups. In the study group, there was no detachment of the soft tissue clip and TM and no mucosal tearing. The magnetic force between the AM and TM provided good mucosal exposure and sufficient tissue tension for ESD. Therefore, the scores of endoscopist's satisfaction with the procedure were higher in the study group than in the control group (9.53 ± 0.10 vs 8.00 ± 0.22 , $P < 0.001$).

Research conclusions

MAT-ESD is safe and effective for early GC.

Research perspectives

This *ex vivo* experiment provides a rudimentary for subsequent internal animal experiments and clinical research. With the accumulation of operational experience, this technique has broad clinical prospects.

ACKNOWLEDGEMENTS

We appreciated all individuals who participate in or help with this research.

FOOTNOTES

Author contributions: Lyu Y and Yan XP conceived and designed the study; Pan M and Zhang MM performed the research and acquired the data; Zhao L wrote the manuscript; Pan M and Zhang MM revised the manuscript; Lyu Y and Yan XP examined the final manuscript; All authors read and approved the final manuscript.

Supported by the Key Research & Development Program-Social Development of Shaanxi Province of China, No. 2021SF-163; and the Innovation Capability Support Plan of Shaanxi Province of China, No. 2020KJXX-022.

Institutional review board statement: The study was reviewed and approved by the laboratory animal care committee of Xi'an Jiaotong

University.

Institutional animal care and use committee statement: All animal experiments conformed to the internationally accepted principles for the laboratory animal care committee of Xi'an Jiaotong University (approval NO. XJTULAC2019-1006) and was in accordance with the ethical standards for experimental animals of Xi'an Jiaotong University.

Conflict-of-interest statement: All authors have nothing to disclose.

Data sharing statement: No additional data are available.

ARRIVE guidelines statement: The authors have read the ARRIVE guidelines, and the manuscript was prepared and revised according to the ARRIVE guidelines.

Open-Access: This article is an open-access article that was selected by an in-house editor and fully peer-reviewed by external reviewers. It is distributed in accordance with the Creative Commons Attribution NonCommercial (CC BY-NC 4.0) license, which permits others to distribute, remix, adapt, build upon this work non-commercially, and license their derivative works on different terms, provided the original work is properly cited and the use is non-commercial. See: <https://creativecommons.org/licenses/by-nc/4.0/>

Country/Territory of origin: China

ORCID number: Min Pan 0000-0003-3381-3676; Miao-Miao Zhang 0000-0001-5679-7061; Lin Zhao 0009-0001-0776-0358; Yi Lyu 0000-0003-3636-6664; Xiao-Peng Yan 0000-0002-0335-829X.

S-Editor: Lin C

L-Editor: A

P-Editor: Cai YX

REFERENCES

- 1 Sung H, Ferlay J, Siegel RL, Laversanne M, Soerjomataram I, Jemal A, Bray F. Global Cancer Statistics 2020: GLOBOCAN Estimates of Incidence and Mortality Worldwide for 36 Cancers in 185 Countries. *CA Cancer J Clin* 2021; **71**: 209-249 [PMID: 33538338 DOI: 10.3322/caac.21660]
- 2 International Agency for Research on Cancer: Cancer Today. Available from: <https://gco.iarc.fr/today/home> [DOI: 10.4135/9781412963855.n637]
- 3 Yang L, Ying X, Liu S, Lyu G, Xu Z, Zhang X, Li H, Li Q, Wang N, Ji J. Gastric cancer: Epidemiology, risk factors and prevention strategies. *Chin J Cancer Res* 2020; **32**: 695-704 [PMID: 33446993 DOI: 10.21147/j.issn.1000-9604.2020.06.03]
- 4 Zhang X, Li M, Chen S, Hu J, Guo Q, Liu R, Zheng H, Jin Z, Yuan Y, Xi Y, Hua B. Endoscopic Screening in Asian Countries Is Associated With Reduced Gastric Cancer Mortality: A Meta-analysis and Systematic Review. *Gastroenterology* 2018; **155**: 347-354.e9 [PMID: 29723507 DOI: 10.1053/j.gastro.2018.04.026]
- 5 Chen R, Liu Y, Song G, Li B, Zhao D, Hua Z, Wang X, Li J, Hao C, Zhang L, Liu S, Wang J, Zhou J, Zhang Y, Li Y, Feng X, Li L, Dong Z, Wei W, Wang G. Effectiveness of one-time endoscopic screening programme in prevention of upper gastrointestinal cancer in China: a multicentre population-based cohort study. *Gut* 2021; **70**: 251-260 [PMID: 32241902 DOI: 10.1136/gutjnl-2019-320200]
- 6 Allemani C, Matsuda T, Di Carlo V, Harewood R, Matz M, Nikšić M, Bonaventure A, Valkov M, Johnson CJ, Estève J, Ogunbiyi OJ, Azevedo E Silva G, Chen WQ, Eser S, Engholm G, Stiller CA, Monnereau A, Woods RR, Visser O, Lim GH, Aitken J, Weir HK, Coleman MP; CONCORD Working Group. Global surveillance of trends in cancer survival 2000-14 (CONCORD-3): analysis of individual records for 37 513 025 patients diagnosed with one of 18 cancers from 322 population-based registries in 71 countries. *Lancet* 2018; **391**: 1023-1075 [PMID: 29395269 DOI: 10.1016/S0140-6736(17)33326-3]
- 7 Kim Y, Jun JK, Choi KS, Lee HY, Park EC. Overview of the National Cancer screening programme and the cancer screening status in Korea. *Asian Pac J Cancer Prev* 2011; **12**: 725-730 [PMID: 21627372]
- 8 Hamashima C; Systematic Review Group and Guideline Development Group for Gastric Cancer Screening Guidelines. Update version of the Japanese Guidelines for Gastric Cancer Screening. *Jpn J Clin Oncol* 2018; **48**: 673-683 [PMID: 29889263 DOI: 10.1093/jjco/hyy077]
- 9 Wang FH, Zhang XT, Li YF, Tang L, Qu XJ, Ying JE, Zhang J, Sun LY, Lin RB, Qiu H, Wang C, Qiu MZ, Cai MY, Wu Q, Liu H, Guan WL, Zhou AP, Zhang YJ, Liu TS, Bi F, Yuan XL, Rao SX, Xin Y, Sheng WQ, Xu HM, Li GX, Ji JF, Zhou ZW, Liang H, Zhang YQ, Jin J, Shen L, Li J, Xu RH. The Chinese Society of Clinical Oncology (CSCO): Clinical guidelines for the diagnosis and treatment of gastric cancer, 2021. *Cancer Commun (Lond)* 2021; **41**: 747-795 [PMID: 34197702 DOI: 10.1002/cac2.12193]
- 10 Ono H, Yao K, Fujishiro M, Oda I, Uedo N, Nimura S, Yahagi N, Iishi H, Oka M, Ajioka Y, Fujimoto K. Guidelines for endoscopic submucosal dissection and endoscopic mucosal resection for early gastric cancer (second edition). *Dig Endosc* 2021; **33**: 4-20 [PMID: 33107115 DOI: 10.1111/den.13883]
- 11 Nishizawa T, Yahagi N. Endoscopic mucosal resection and endoscopic submucosal dissection: technique and new directions. *Curr Opin Gastroenterol* 2017; **33**: 315-319 [PMID: 28704212 DOI: 10.1097/MOG.0000000000000388]
- 12 Facciorusso A, Antonino M, Di Maso M, Muscatiello N. Endoscopic submucosal dissection vs endoscopic mucosal resection for early gastric cancer: A meta-analysis. *World J Gastrointest Endosc* 2014; **6**: 555-563 [PMID: 25400870 DOI: 10.4253/wjge.v6.i11.555]
- 13 Nagata M. Advances in traction methods for endoscopic submucosal dissection: What is the best traction method and traction direction? *World J Gastroenterol* 2022; **28**: 1-22 [PMID: 35125817 DOI: 10.3748/wjg.v28.i1.1]
- 14 Oyama T. Counter traction makes endoscopic submucosal dissection easier. *Clin Endosc* 2012; **45**: 375-378 [PMID: 23251884 DOI: 10.5946/ce.2012.45.4.375]

- 15 **Aihara H**, Kumar N, Ryou M, Abidi W, Ryan MB, Thompson CC. Facilitating endoscopic submucosal dissection: the suture-pulley method significantly improves procedure time and minimizes technical difficulty compared with conventional technique: an ex vivo study (with video). *Gastrointest Endosc* 2014; **80**: 495-502 [PMID: 24679655 DOI: 10.1016/j.gie.2014.01.050]
- 16 **Ge PS**, Thompson CC, Jirapinyo P, Aihara H. Suture pulley countertraction method reduces procedure time and technical demand of endoscopic submucosal dissection among novice endoscopists learning endoscopic submucosal dissection: a prospective randomized ex vivo study. *Gastrointest Endosc* 2019; **89**: 177-184 [PMID: 30148993 DOI: 10.1016/j.gie.2018.08.032]
- 17 **Yamada S**, Doyama H, Ota R, Takeda Y, Tsuji K, Tsuji S, Yoshida N. Impact of the clip and snare method using the prelooping technique for colorectal endoscopic submucosal dissection. *Endoscopy* 2016; **48**: 281-285 [PMID: 26517845 DOI: 10.1055/s-0034-1393241]
- 18 **Kaku H**, Toyonaga T, Tanaka S, Takihara H, Baba S, Tsubouchi E, Ikeda Y, Orita H, Nakamoto M, Horikawa Y, Chiba H, Ban H, Furumoto Y, Morita R, Kodama Y. Endoscopic Submucosal Dissection Using EndoTrac, a Novel Traction Device. *Digestion* 2021; **102**: 714-721 [PMID: 33352560 DOI: 10.1159/000511731]
- 19 **Imaeda H**, Iwao Y, Ogata H, Ichikawa H, Mori M, Hosoe N, Masaoka T, Nakashita M, Suzuki H, Inoue N, Aiura K, Nagata H, Kumai K, Hibi T. A new technique for endoscopic submucosal dissection for early gastric cancer using an external grasping forceps. *Endoscopy* 2006; **38**: 1007-1010 [PMID: 16673308 DOI: 10.1055/s-2006-925264]
- 20 **Imaeda H**, Hosoe N, Ida Y, Nakamizo H, Kashiwagi K, Kanai T, Iwao Y, Hibi T, Ogata H. Novel technique of endoscopic submucosal dissection by using external forceps for early rectal cancer (with videos). *Gastrointest Endosc* 2012; **75**: 1253-1257 [PMID: 22624814 DOI: 10.1016/j.gie.2012.02.018]
- 21 **Uraoka T**, Ishikawa S, Kato J, Higashi R, Suzuki H, Kaji E, Kuriyama M, Saito S, Akita M, Hori K, Harada K, Ishiyama S, Shiode J, Kawahara Y, Yamamoto K. Advantages of using thin endoscope-assisted endoscopic submucosal dissection technique for large colorectal tumors. *Dig Endosc* 2010; **22**: 186-191 [PMID: 20642607 DOI: 10.1111/j.1443-1661.2010.00992.x]
- 22 **Sakamoto N**, Osada T, Shibuya T, Beppu K, Matsumoto K, Shimada Y, Konno A, Kurosawa A, Nagahara A, Ohkusa T, Ogihara T, Watanabe S. The facilitation of a new traction device (S-O clip) assisting endoscopic submucosal dissection for superficial colorectal neoplasms. *Endoscopy* 2008; **40** Suppl 2: E94-E95 [PMID: 19085712 DOI: 10.1055/s-2007-995603]
- 23 **Sakamoto N**, Osada T, Shibuya T, Beppu K, Matsumoto K, Mori H, Kawabe M, Nagahara A, Otaka M, Ogihara T, Watanabe S. Endoscopic submucosal dissection of large colorectal tumors by using a novel spring-action S-O clip for traction (with video). *Gastrointest Endosc* 2009; **69**: 1370-1374 [PMID: 19403131 DOI: 10.1016/j.gie.2008.12.245]
- 24 **Mori H**, Kobara H, Nishiyama N, Fujihara S, Matsunaga T, Masaki T. Novel effective and repeatedly available ring-thread counter traction for safer colorectal endoscopic submucosal dissection. *Surg Endosc* 2017; **31**: 3040-3047 [PMID: 27858210 DOI: 10.1007/s00464-016-5326-7]
- 25 **Sudo G**, Tanuma T, Suzuki Y, Nakase H. Multiloop method for traction during colorectal endoscopic submucosal dissection. *VideoGIE* 2019; **4**: 11-13 [PMID: 30623150 DOI: 10.1016/j.vgie.2018.10.002]
- 26 **Jacques J**, Charissoux A, Bordillon P, Legros R, Rivory J, Hervieu V, Albouys J, Guyot A, Ponchon T, Sautereau D, Kerever S, Pioche M. High proficiency of colonic endoscopic submucosal dissection in Europe thanks to countertraction strategy using a double clip and rubber band. *Endosc Int Open* 2019; **7**: E1166-E1174 [PMID: 31475236 DOI: 10.1055/a-0965-8531]
- 27 **Ge PS**, Aihara H. A novel clip-band traction device to facilitate colorectal endoscopic submucosal dissection and defect closure. *VideoGIE* 2020; **5**: 180-186 [PMID: 32426563 DOI: 10.1016/j.vgie.2020.01.012]
- 28 **Ide D**, Saito S, Chino A, Ohya TR. Submucosal pocket creation using a traction device in colorectal endoscopic submucosal dissection. *Ann Gastroenterol* 2018; **31**: 380 [PMID: 29720866 DOI: 10.20524/aog.2018.0258]
- 29 **Yamamoto K**, Hayashi S, Saiki H, Indo N, Nakabori T, Yamamoto M, Shibuya M, Nishida T, Ichiba M, Inada M. Endoscopic submucosal dissection for large superficial colorectal tumors using the "clip-flap method". *Endoscopy* 2015; **47**: 262-265 [PMID: 25412089 DOI: 10.1055/s-0034-1390739]
- 30 **Kobayashi T**, Gotohda T, Tamakawa K, Ueda H, Kakizoe T. Magnetic anchor for more effective endoscopic mucosal resection. *Jpn J Clin Oncol* 2004; **34**: 118-123 [PMID: 15078906 DOI: 10.1093/jjco/hyh025]
- 31 **Bai JG**, Wang Y, Zhang Y, Lv Y; Scientific Committee of the Third International Conference of Magnetic Surgery. Expert consensus on the application of the magnetic anchoring and traction technique in thoracoscopic and laparoscopic surgery. *Hepatobiliary Pancreat Dis Int* 2022; **21**: 7-9 [PMID: 34289952 DOI: 10.1016/j.hbpd.2021.06.007]
- 32 **Rivas H**, Robles I, Riquelme F, Vivanco M, Jiménez J, Marinkovic B, Uribe M. Magnetic Surgery: Results From First Prospective Clinical Trial in 50 Patients. *Ann Surg* 2018; **267**: 88-93 [PMID: 27759614 DOI: 10.1097/SLA.0000000000002045]
- 33 **Gonzalez-Rivas D**. Unisurgeon' uniportal video-assisted thoracoscopic surgery lobectomy. *J Vis Surg* 2017; **3**: 163 [PMID: 29302439 DOI: 10.21037/jovs.2017.10.07]
- 34 **Kobiela J**, Grymek S, Wojanowska M, Lubniewski M, Makarewicz W, Dobrowolski S, Lachiński AJ, Sledziński Z. Magnetic instrumentation and other applications of magnets in NOTES. *Wideochir Inne Tech Maloinwazyjne* 2012; **7**: 67-73 [PMID: 23256005 DOI: 10.5114/wiitm.2011.25665]
- 35 **Goll D**, Kronmüller H. High-performance permanent magnets. *Naturwissenschaften* 2000; **87**: 423-438 [PMID: 11129942 DOI: 10.1007/s001140050755]
- 36 **Matsuzaki I**, Hattori M, Hirose K, Esaki M, Yoshikawa M, Yokoi T, Kobayashi M, Miyahara R, Hirooka Y, Goto H. Magnetic anchor-guided endoscopic submucosal dissection for gastric lesions (with video). *Gastrointest Endosc* 2018; **87**: 1576-1580 [PMID: 29352971 DOI: 10.1016/j.gie.2018.01.015]
- 37 **Matsuzaki I**, Miyahara R, Hirooka Y, Funasaka K, Furukawa K, Ohno E, Nakamura M, Kawashima H, Maeda O, Watanabe O, Ando T, Kobayashi M, Goto H. Simplified magnetic anchor-guided endoscopic submucosal dissection in dogs (with videos). *Gastrointest Endosc* 2014; **80**: 712-716 [PMID: 25085334 DOI: 10.1016/j.gie.2014.05.334]
- 38 **Gotoda T**, Oda I, Tamakawa K, Ueda H, Kobayashi T, Kakizoe T. Prospective clinical trial of magnetic-anchor-guided endoscopic submucosal dissection for large early gastric cancer (with videos). *Gastrointest Endosc* 2009; **69**: 10-15 [PMID: 18599053 DOI: 10.1016/j.gie.2008.03.1127]



Published by **Baishideng Publishing Group Inc**
7041 Koll Center Parkway, Suite 160, Pleasanton, CA 94566, USA

Telephone: +1-925-3991568

E-mail: bpgoffice@wjgnet.com

Help Desk: <https://www.f6publishing.com/helpdesk>

<https://www.wjgnet.com>

