

World Journal of *Gastrointestinal Endoscopy*

World J Gastrointest Endosc 2023 April 16; 15(4): 195-318



REVIEW

- 195 Endoscopic luminal stenting: Current applications and future perspectives
Moutzoukis M, Argyriou K, Kapsoritakis A, Christodoulou D
- 216 Endoscopic ultrasound-guided vascular interventions: An expanding paradigm
Dhar J, Samanta J

MINIREVIEWS

- 240 Update on diagnosis and treatment of early signet-ring cell gastric carcinoma: A literature review
Tang YH, Ren LL, Mao T
- 248 Endoscopic resection of non-ampullary duodenal adenomas: Is cold snaring the promised land?
Alfarone L, Spadaccini M, Franchellucci G, Khalaf K, Massimi D, De Marco A, Ferretti S, Poletti V, Facciorusso A, Maselli R, Fugazza A, Colombo M, Capogreco A, Carrara S, Hassan C, Repici A
- 259 Two traction methods that can facilitate esophageal endoscopic submucosal dissection
Nagata M
- 265 Device-assisted traction methods in colorectal endoscopic submucosal dissection and options for difficult cases
Nagata M

ORIGINAL ARTICLE

Retrospective Cohort Study

- 273 Role of endoscopic ultrasound in the characterization of solid pseudopapillary neoplasm of the pancreas
Pawlak KM, Tehami N, Maher B, Asif S, Rawal KK, Balaban DV, Tag-Adeen M, Ghalim F, Abbas WA, Ghoneem E, Ragab K, El-Ansary M, Kadir S, Amin S, Siau K, Wiechowska-Kozłowska A, Mönkemüller K, Abdelfatah D, Abdellatef A, Lakhtakia S, Okasha HH
- 285 Relationships of hospitalization outcomes and timing to endoscopy in non-variceal upper gastrointestinal bleeding: A nationwide analysis
Weissman S, Aziz M, Bangolo AI, Ehrlich D, Forlemu A, Willie A, Gangwani MK, Waqar D, Terefe H, Singh A, Gonzalez DMC, Sajja J, Emiroglu FL, Dinko N, Mohamed A, Fallorina MA, Kosoy D, Shenoy A, Nanavati A, Feuerstein JD, Tabibian JH
- 297 Causes of gastrointestinal bleeding in children based on endoscopic evaluation at a tertiary care center in Bahrain
Isa HM, Alkharsi FA, Ebrahim HA, Walwil KJ, Diab JA, Alkowari NM

Retrospective Study

- 309** Outcomes of colon self-expandable metal stents for malignant *vs* benign indications at a tertiary care center and review of literature

Walayat S, Johannes AJ, Benson M, Nelsen E, Akhter A, Kennedy G, Soni A, Reichelderfer M, Pfau P, Gopal D

ABOUT COVER

Editorial Board Member of *World Journal of Gastrointestinal Endoscopy*, Naoki Hosoe, FACC, MD, PhD, Associate Professor, Center for Diagnostic and Therapeutic Endoscopy, Keio University School of Medicine, Tokyo 160-8582, Japan. nhosoe@z5.keio.jp

AIMS AND SCOPE

The primary aim of *World Journal of Gastrointestinal Endoscopy* (WJGE, *World J Gastrointest Endosc*) is to provide scholars and readers from various fields of gastrointestinal endoscopy with a platform to publish high-quality basic and clinical research articles and communicate their research findings online.

WJGE mainly publishes articles reporting research results and findings obtained in the field of gastrointestinal endoscopy and covering a wide range of topics including capsule endoscopy, colonoscopy, double-balloon enteroscopy, duodenoscopy, endoscopic retrograde cholangiopancreatography, endosonography, esophagoscopy, gastrointestinal endoscopy, gastroscopy, laparoscopy, natural orifice endoscopic surgery, proctoscopy, and sigmoidoscopy.

INDEXING/ABSTRACTING

The WJGE is now abstracted and indexed in Emerging Sources Citation Index (Web of Science), PubMed, PubMed Central, Reference Citation Analysis, China National Knowledge Infrastructure, China Science and Technology Journal Database, and Superstar Journals Database. The 2022 edition of Journal Citation Reports® cites the 2021 Journal Citation Indicator (JCI) for WJGE as 0.33.

RESPONSIBLE EDITORS FOR THIS ISSUE

Production Editor: Yi-Xuan Cai; Production Department Director: Xu Guo; Editorial Office Director: Jia-Ping Yan.

NAME OF JOURNAL

World Journal of Gastrointestinal Endoscopy

ISSN

ISSN 1948-5190 (online)

LAUNCH DATE

October 15, 2009

FREQUENCY

Monthly

EDITORS-IN-CHIEF

Anastasios Koulaouzidis, Bing Hu, Sang Chul Lee, Joo Young Cho

EDITORIAL BOARD MEMBERS

<https://www.wjgnet.com/1948-5190/editorialboard.htm>

PUBLICATION DATE

April 16, 2023

COPYRIGHT

© 2023 Baishideng Publishing Group Inc

INSTRUCTIONS TO AUTHORS

<https://www.wjgnet.com/bpg/gerinfo/204>

GUIDELINES FOR ETHICS DOCUMENTS

<https://www.wjgnet.com/bpg/GerInfo/287>

GUIDELINES FOR NON-NATIVE SPEAKERS OF ENGLISH

<https://www.wjgnet.com/bpg/gerinfo/240>

PUBLICATION ETHICS

<https://www.wjgnet.com/bpg/GerInfo/288>

PUBLICATION MISCONDUCT

<https://www.wjgnet.com/bpg/gerinfo/208>

ARTICLE PROCESSING CHARGE

<https://www.wjgnet.com/bpg/gerinfo/242>

STEPS FOR SUBMITTING MANUSCRIPTS

<https://www.wjgnet.com/bpg/GerInfo/239>

ONLINE SUBMISSION

<https://www.f6publishing.com>



Endoscopic ultrasound-guided vascular interventions: An expanding paradigm

Jahnvi Dhar, Jayanta Samanta

Specialty type: Gastroenterology and Hepatology

Provenance and peer review:

Invited article; Externally peer reviewed.

Peer-review model: Single blind

Peer-review report's scientific quality classification

Grade A (Excellent): 0
Grade B (Very good): B, B
Grade C (Good): 0
Grade D (Fair): 0
Grade E (Poor): 0

P-Reviewer: Nakamura K, Japan;
Reihani H, Iran

Received: November 17, 2022

Peer-review started: November 17, 2022

First decision: December 26, 2022

Revised: January 9, 2023

Accepted: March 15, 2023

Article in press: March 15, 2023

Published online: April 16, 2023



Jahnvi Dhar, Gastroenterology, Sohana Multispeciality Hospital, Mohali 140308, India

Jayanta Samanta, Gastroenterology, Post Graduate Institute of Medical Education and Research, Chandigarh 160012, India

Corresponding author: Jayanta Samanta, MD, Associate Professor, Gastroenterology, Post Graduate Institute of Medical Education and Research, PGIMER, Sector-12, Chandigarh 160012, India. dj_samanta@yahoo.co.in

Abstract

Endoscopic ultrasound (EUS) has expanded its arena from a mere diagnostic modality to an essential therapeutic tool in managing gastrointestinal (GI) diseases. The proximity of the GI tract to the vascular structures in the mediastinum and the abdomen has facilitated the growth of EUS in the field of vascular interventions. EUS provides important clinical and anatomical information related to the vessels' size, appearance and location. Its excellent spatial resolution, use of colour doppler with or without contrast enhancement and ability to provide images "real-time" helps in precision while intervening vascular structures. Additionally, structures such as venous collaterals or varices can be dealt with optimally using EUS. EUS-guided vascular therapy with coil and glue combination has revolutionized the management of portal hypertension. It also helps to avoid radiation exposure in addition to being minimally invasive. These advantages have led EUS to become an upcoming modality to complement traditional interventional radiology in the field of vascular interventions. EUS-guided portal vein (PV) access and therapy is a new kid on the block. EUS-guided portal pressure gradient measurement, injecting chemotherapy in PV and intrahepatic portosystemic shunt has expanded the horizons of endo-hepatology. Lastly, EUS has also forayed into cardiac interventions allowing pericardial fluid aspiration and tumour biopsy with experimental data on access to valvular apparatus. Herein, we provide a comprehensive review of the expanding paradigm of EUS-guided vascular interventions in GI bleeding, portal vein access and its related therapeutic interventions, cardiac access, and therapy. A synopsis of all the technical details involving each procedure and the available data has been tabulated, and the future trends in this area have been highlighted.

Key Words: Gastrointestinal bleeding; Vascular intervention; Gastric varices; Pseudoaneurysm; Portal vein; Portal pressure gradient measurement

Core Tip: Therapeutic endoscopic ultrasound (EUS) has rapidly expanded into the field of vascular interventions. Published literature has shown that EUS-guided endovascular therapy is safe and scores over conventional endoscopic techniques achieving high obliteration rates with minimum re-intervention in variceal bleeding. EUS currently acts as a “rescue therapy” in cases of re-bleed or refractory bleeding from non-variceal sources, especially a pseudoaneurysm. In addition, portal vein access, portal pressure gradient measurement, and variceal assessment with liver biopsy have shown that EUS can act as a “one-stop-shop” for “Endo-hepatology”. This ever-expanding role of EUS-related vascular interventions has been thoroughly detailed in this comprehensive review.

Citation: Dhar J, Samanta J. Endoscopic ultrasound-guided vascular interventions: An expanding paradigm. *World J Gastrointest Endosc* 2023; 15(4): 216-239

URL: <https://www.wjgnet.com/1948-5190/full/v15/i4/216.htm>

DOI: <https://dx.doi.org/10.4253/wjge.v15.i4.216>

INTRODUCTION

Therapeutic endoscopic ultrasound (EUS) procedures have come a long way using curvilinear array echo-endoscopes and various accessories. EUS, with its high spatial and contrast resolution, is constantly evolving and is currently one of the most commonly used minimally invasive techniques for diagnosing and managing various gastrointestinal (GI) disorders. The proximity of the GI tract to various vascular structures in the mediastinum and abdomen has allowed EUS to play a significant role in the field of vascular interventions. The necessity of developing a minimally invasive as well as a radiation-free alternative to interventional radiology (IR) or surgery has further strengthened its growth. The advantage of visualizing vascular structures in “real-time” has enabled access and delivery of targeted therapy[1]. EUS-guided vascular therapy has been found extremely useful in cases of variceal bleeding. EUS-guided injection of sclerosants, cyanoacrylate glue (CYA), thrombin, gelatin sponge and deployment of coils in gastric varices (GV) is safer and more effective over traditional endoscopic glue injection in terms of lower adverse events and reintervention rates.

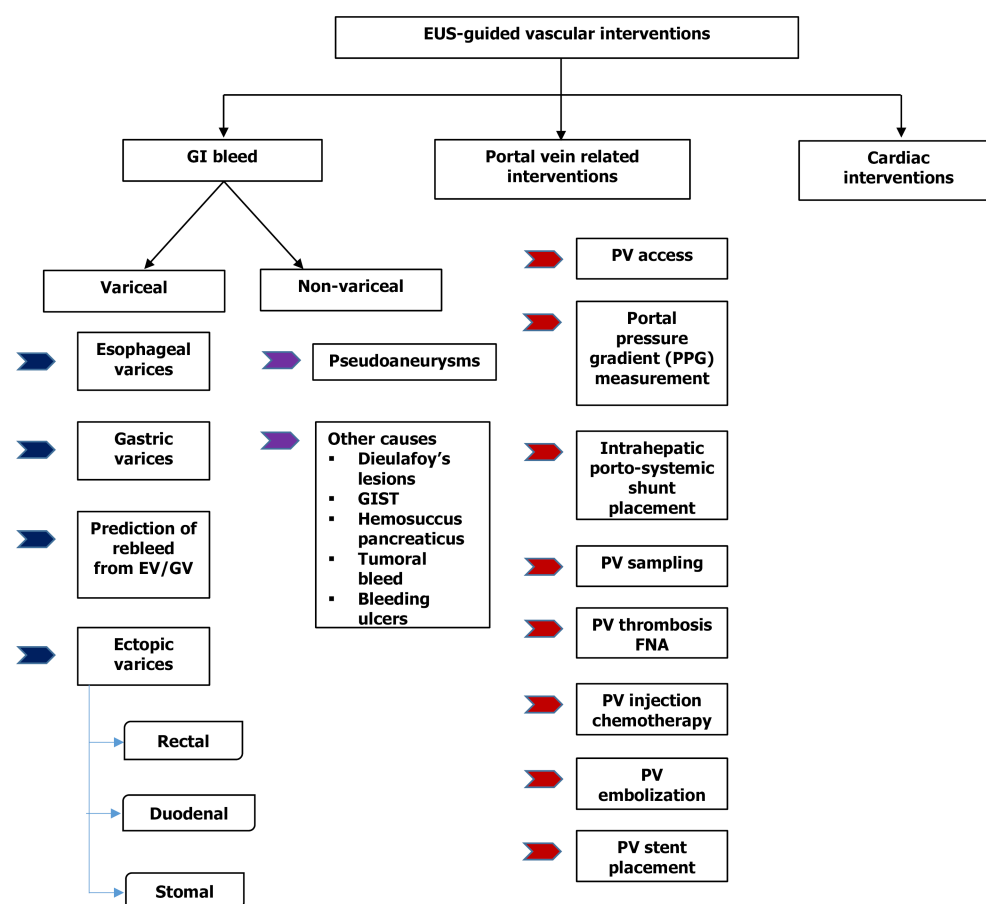
Furthermore, EUS-guided portal vein (PV) access has opened the doors to experimental and clinical studies on portal pressure gradient (PPG) measurement, injection of chemotherapy, PV thrombus fine needle aspiration (FNA), and intrahepatic portosystemic shunt placement. This gamut of therapeutic options, combining EUS guided PPG (EUS-PPG) with variceal therapy and liver biopsy in a single session, represents an attractive option in the expanding field of “endo-hepatology”[2]. Therefore, this review focuses on elucidating the role of EUS-guided vascular interventions (Figures 1 and 2), a synopsis of the various available techniques, data on their safety and efficacy, and future advancements in this domain.

LITERATURE SEARCH

A detailed strategy, as outlined in Supplementary material, was performed in PubMed and Embase. All studies pertaining to applications of endoscopic ultrasound (EUS) in the field of vascular interventions (for example case series, review articles and clinical studies) were reviewed. Topics concerning GI bleeding (both variceal and non-variceal), PV-related interventions and cardiac access with therapy were looked into. Non-English language literature was excluded. EUS-guided liver biopsy and other aspects of Endo-hepatology are beyond this review’s scope and have been excluded.

EUS-GUIDED MANAGEMENT OF VARICEAL BLEED

GI bleeding secondary to gastro-esophageal varices is a well-known but one of the most lethal complications of portal hypertension (PHTN)[3,4]. The annual bleeding rate has been reported to be around 5%-15%, with a 20% 6-wk mortality rate[5]. In half of the cases, bleeding stops spontaneously but has a re-bleeding rate of 30%-40%[3,6]. The standard treatment options for gastro-esophageal varices have been conventional endoscopic band ligation (EBL) or CYA glue injection. For refractory bleed, transjugular intrahepatic portosystemic shunt (TIPS) and balloon-occluded retrograde transvenous obliteration (BRTO) are other options[7]. EUS-guided management of varices has recently become an additional tool



DOI: 10.4253/wjge.v15.i4.216 Copyright ©The Author(s) 2023.

Figure 1 Flowchart of various endoscopic ultrasound guided vascular interventions. EUS: Endoscopic ultrasound; GI: Gastrointestinal; EV: Esophageal varices; GV: Gastric varices; GIST: Gastrointestinal stromal tumour; PV: Portal vein; FNA: Fine needle aspiration.

in the armamentarium. EUS offers theoretical as well as practical advantages over the conventional techniques such as: (1) It helps to identify the actual size as well as the number of varices for precise vascular therapy; (2) It can locate feeders, perforators or shunts; (3) Enables real-time puncture of the varices under vision; (4) One need not have to “see” the endoscopic image while delivering targeted therapy. This is especially useful in cases of active bleed or when there are contents in the fundus, and (5) Objective obliteration of the varices can be confirmed by lack of flow in “real-time”.

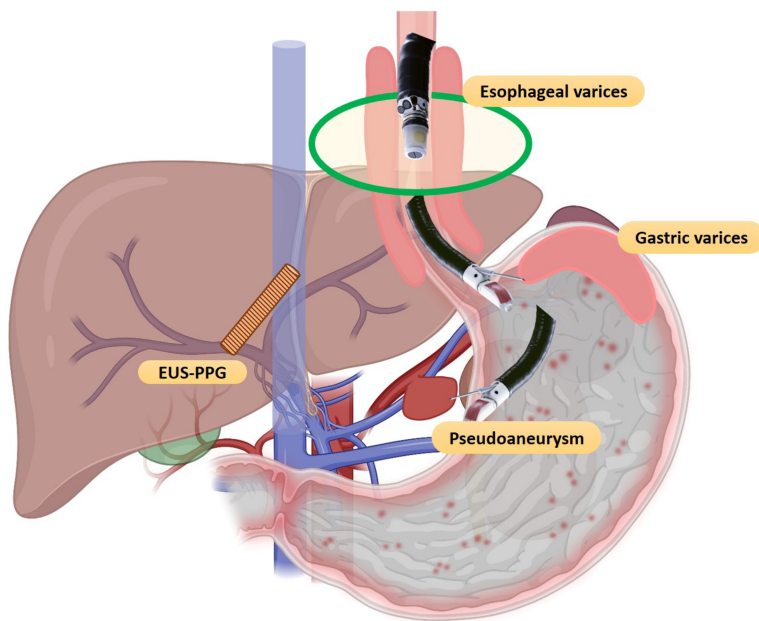
Esophageal varices

EBL has been the first line of management for both primary and secondary prophylaxis of esophageal varices (EV)[4,8]. But high re-bleeding rates have been reported (15%-65%)[9,10], probably as a result of failure to obliterate the perforators or paraesophageal vessels that feed the EV[11,12]. Anecdotal case series exist on the use of EUS for EV management.

Existing literature: Lahoti *et al*[13] first described EUS-guide sclerotherapy for EV obliteration in 5 patients. Sodium morrhuate (sclerosant) was used to inject the perforators and feeder vessels until flow was obliterated using colour doppler, with no re-bleeding on a 15-mo follow-up period. One case had developed esophageal stricture, which was responsive to balloon dilatation. The only randomized controlled trial (RCT) comparing endoscopic *vs* EUS-guided sclerotherapy showed that there was no difference in the mean number of sessions needed for complete obliteration (4.3 *vs* 4.1) and re-bleeding rates (16.7% *vs* 4.2%). However, collaterals noted on EUS post-therapy were lower in the EUS arm (33.3% *vs* 0%)[14].

While EBL is still the preferred option, more data will be needed to define the role of EUS for EV management algorithms in clinical practice.

Future trends: Recently, a “jelly-filling” method has been found superior to the traditional water-filling method for EV visualization using EUS. The image quality score was significantly higher but with a longer procedure time using the former technique[15].



DOI: 10.4253/wjge.v15.i4.216 Copyright ©The Author(s) 2023.

Figure 2 Spectrum of endoscopic ultrasound-guided vascular interventions. EUS-PPG: Endoscopic ultrasound-portal pressure gradient.

GV

While EV account for a majority of the cases of GI bleeding in cirrhosis, GV can account for 20%-25% of them, with re-bleeding rates amounting to 65% in 2 years. Although GV bleeds less frequently, they are usually associated with an increased risk of uncontrolled bleeding, re-bleeding, more transfusion requirements and higher mortality. Described as per Sarin's classification, varices along cardia (GOV2) or isolated GV in the fundus (IGV1) are the most difficult to treat[3,4,16]. Therefore, both endoscopic sclerotherapy and EBL are discouraged for GV. While the former leads to an unusually high incidence of adverse events (37%-53%) like ulceration, re-bleeding, or perforation, the latter is difficult to execute due to thick musculature of the gastric wall leading to possible catastrophic post-banding bleed[17,18].

Thus, the first line of therapy for managing bleeding GV is the endoscopic injection of acrylate polymers such as CYA under direct vision. First described by Soehendra *et al*[19] in 1986, this technique has success rates of 58%-100% with re-bleeding of 40%-65%. This technique, however, has its own set of complications, including the risk of systemic embolization, bleeding from needle site ulcers, peritonitis, needle impaction, scope damage and even death. On the other hand, EUS-guided management has some advantages over conventional glue injection, *i.e.*, (1) Higher detection rate (6 times) over conventional endoscopy, as GV is located deep in the submucosa and commonly mistaken as thick gastric folds [20,21]; and (2) avoidance of inadvertent para-variceal injection (in up to 60%)[22].

The technique of EUS-guided GV management: The most commonly used method is a combination of coil and CYA glue, as outlined in Table 1[2] and Figure 3.

Existing literature: The options for EUS-guided GV therapy include: CYA glue, coils alone, a coil with glue combination, gelatin sponge and thrombin.

EUS-guided glue injection only: In their pilot study, Romero-Castro *et al*[23] evaluated the efficacy of CYA glue with lipiodol mixture in 5 cases of bleeding GV using a 22-G needle. Complete obliteration was achieved in all with no re-bleeding or complications.

EUS-guided coil injection only: A life-threatening complication of CYA injection is systemic embolization, the most common location being the lungs[24]. Coils can be used as an alternative to glue injection to mitigate this risk. Coils are made of a stainless-steel alloy with radially extending synthetic fibres that induce clot formation and hemostasis. The coils are usually 2-15 mm in length, and the loops are 2-20 mm in diameter. The choice of size would depend on the diameter of the varix.

The first report by Romero-Castro *et al*[25] demonstrated its efficacy in 4 cases. Complete obliteration was achieved in 75% of patients. Furthermore, the same group compared the EUS-guided coil (11 patients) *vs* CYA (19 cases). Though the obliteration rates were similar (91% *vs* 95%), the coil group needed fewer endoscopy sessions and had lower adverse event rates (9.1% *vs* 58%)[26].

EUS-guided coil with glue combination: This combination is based on the concept that use of coil with glue: (1) Achieves higher variceal obliteration rates with better hemostasis control; (2) decreases the amount of CYA needed; and (3) provides a framework or scaffold to hold the CYA glue within the varix, thus mitigating the risk of embolization. The largest data by Bhat *et al*[27] evaluated it in 152 cases of GV. The mean number of coils and glue used was 1.4 and 2 mL, respectively. On follow-up, complete

Table 1 Steps of endoscopic ultrasound-guided management (coil and glue combination) of Gastric varices

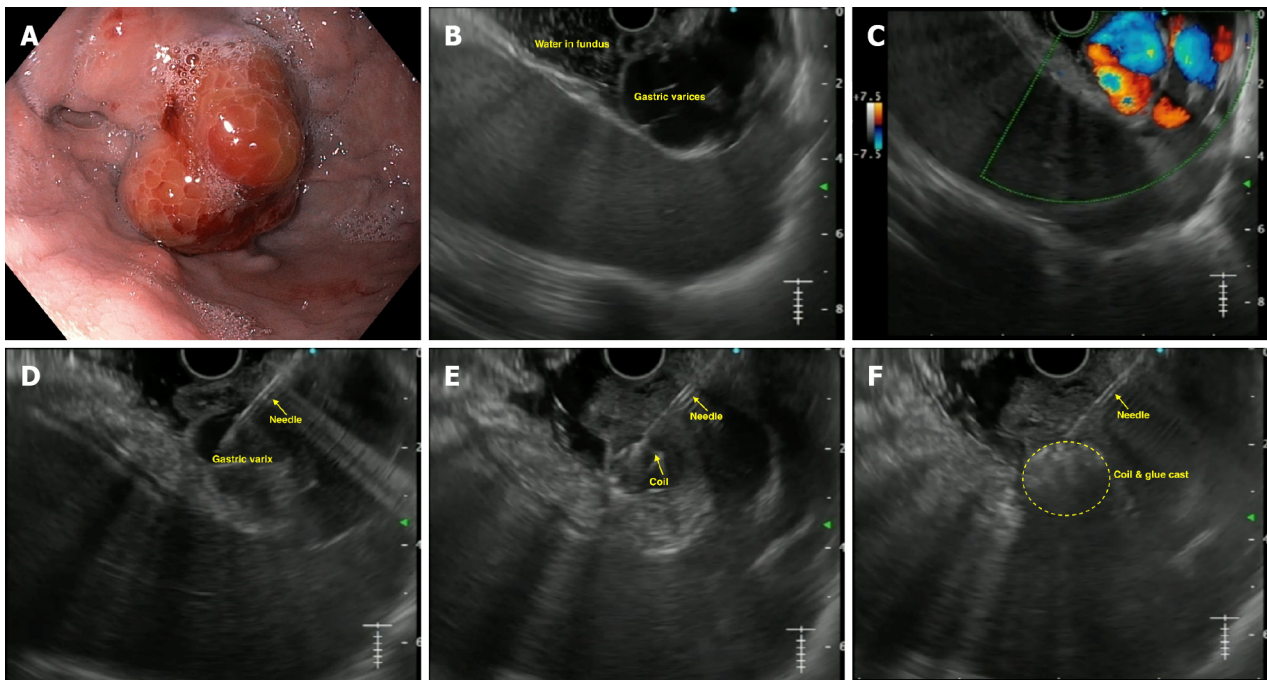
EUS-guided management of gastric varices using coil and glue combination
Pre-procedure requirements
All procedures are done under the cover of pre/peri-procedural antibiotics
Patient is usually kept fasting for 4-6 h before the procedure
Adequate resuscitation of the patient, in case of active bleeding is ensured, prior to the procedure
Informed consent prior to the procedure
What is needed prior to the procedure
Linear echoendoscope with at least a 3.7 mm working channel
Needle size: depends on the choice of the endoscopist; for > 10 mm coils, we need 0.035" coil (19-G needle); can also use 0.018" coil (22-G needle)
Diameter of the coils: 1.2-1.5 times the largest diameter of varix
Number of coils: depends on size of the varix
Amount of glue: depends on the size of the varix; but usually 2-4 mL is sufficient
Technical aspects
A proper diagnostic EUS is performed
The echoendoscope is usually positioned either in the distal esophagus or the gastric fundus
Saline is filled intra-luminally in the fundus to let the varices "float". This enables a good acoustic coupling for better visualization of the gastric varices
Adequate examination of the fundus, the intramural varices and the feeder vessels is carried out
The approach can be trans-esophageal or trans-gastric, wherein the trans-esophageal route is given preference
Aim is to obliterate the intramucosal part of the varix
EUS-guided coil and glue embolization is usually performed using a 22-G/19-G (gauge) FNA needle
The size of the coil is determined by the short axis of the diameter of the varix
After puncture of the varix, blood is aspirated to confirm the location. This is followed by flushing of the needle with saline
The coils are then deployed into the varix using the stylet as a pusher. Once the coils are deployed, flushing of the needle is done with normal saline
After coil deployment, 1-2 mL of cyanoacrylate glue is injected followed by rapid flushing with saline
Once, the varix is obliterated, visualized by absence of flow on colour Doppler, the sheath of the needle is advanced beyond the endoscope tip for 2-3 cm before withdrawing the scope. This avoids contact of glue with the endoscope tip
Post procedure
The patients are kept under observation for 12 h
Repeat EUS can be done after 2 d to look for residual varices
Follow-up EUS to be performed at 1- and 3-mo intervals

EUS: Endoscopic ultrasound; FNA: Fine needle aspiration; G: Gauge.

obliteration was achieved in 93% of cases. Furthermore, mild post-procedure pain was seen in 3% of cases, with only one case of embolization. This data strongly supports the use of combination therapy for GVs. Recently, Kouanda *et al*[28] demonstrated its effectiveness in primary prophylaxis, with an obliteration rate of 96.7% with 2.5% re-bleed rates. A recent RCT and a meta-analysis have confirmed the superiority of EUS-guided coil with glue as the best modality for tackling GV[29,30].

Comparison of EUS-coil with CYA *vs* endoscopic glue injection: Limited data exist (retrospective and one RCT) comparing EUS combination therapy *vs* conventional endoscopic glue injection[31-34]. Robles-Medranda *et al*[31] compared the cost-effectiveness of the two procedures and found EUS therapy to be better.

The author's experience of the largest multicenter study involving four centers to evaluate the effectiveness of EUS combination therapy (52 cases) *vs* endoscopic therapy (118 patients) showed that the EUS arm required a lower number of sessions for complete obliteration (1 *vs* 2), lower re-bleeding rates (15.4% *vs* 31.3%) and lower post-procedure abdominal pain (0% *vs* 13.9%)[34]. Currently, an RCT is recruiting patients for EUS-guided coil and glue *vs* endoscopic CYA therapy for GV[35].



DOI: 10.4253/wjge.v15.i4.216 Copyright ©The Author(s) 2023.

Figure 3 Endoscopic ultrasound-guided coil and glue injection for gastric varices. A: Endoscopic image of gastric varix; B: Endoscopic ultrasound image of gastric varix; C: Colour Doppler showing flow in the varix; D: Puncture of the varix with 19-G needle; E: Coil being deployed in the varix; F: Glue injected leading to coil-glue cast with varix obliteration.

Newer therapies: Isolated case series exists on the utilization of thrombin, a coil with an absorbable gelatin sponge and ethanolamine oleate, with good results[36-38].

Various studies published on EUS-guided vascular interventions in GV have been tabulated in Table 2[39-47]. Published literature strongly supports using EUS-guided vascular therapy for managing GV for primary and secondary prophylaxis. The combination strategy has definite advantages and may be preferred over conventional CYA therapy in certain situations.

Future trends: Zhang *et al*[48] described a novel technique that can be incorporated into the EUS-hepatology toolbox. They described partial splenic embolization with endoscopic CYA for GV in cases with underlying hypersplenism with excellent results post-procedure.

Prediction of variceal re-bleed using EUS

EUS along with Doppler detects EV and GV with higher sensitivity, as compared to upper GI endoscopy, which helps in assessing the risk of bleeding, pre-procedure evaluation and predicting recurrence.

Predicting the risk of bleeding: The presence of hematocystic spots usually correlate with increased risk of esophageal variceal rupture. They can be identified as “saccular aneurysm” on EUS[49].

Preoperative evaluation: EUS-doppler can diagnose collateral veins, peri and para esophageal veins, and the perforators found adjacent to or outside the esophageal wall in patients with EV. The presence of the former is a strong indicator of a future occurrence of a re-bleed[50,51]. Intravariceal pressure can also be recorded in animal models by Miller *et al*[52] using a non-invasive EUS-based 20-MHz ultrasound transducer in a latex balloon catheter sheath.

Predicting recurrent bleed: The main factor predicting re-bleed for EV is the diameter of the paraesophageal vessels. Paraesophageal diameter before or after EVL is a better recurrence predictor (cut-off of 6.3 mm and 4 mm, respectively, having 60% and 70.6% sensitivity)[53]. Additionally, the velocity of hepatofugal blood flow in the left gastric vein and the branching pattern are associated with variceal recurrence after endoscopic treatments[54]. A cut-off of 0.45 cm² on digital image analysis using EUS (which identifies distal esophageal cross-sectional area) has 83% sensitive in predicting the risk of re-bleeding[55]. EUS has also been shown to objectively assess response to propranolol to determine variceal recurrence post-EBL[56].

Ectopic varices

Ectopic varices account for 1%-5% of cases of variceal bleeding. However, the management of ectopic

Table 2 Existing literature on endoscopic ultrasound-guided vascular interventions for gastric varices

Ref.	Cases	Treatment used in EUS	EUS needle size	Number of coils (EUS only)	Use of Glue/others (mL) (EUS/endoscopic therapy)	Number of sessions (EUS/endoscopic)	Technical success (%)	Clinical success (%)	Adverse events (overall) (%)	Reintervention rates (%)	Rebleeding rates (%)	All-cause mortality (%)
Studies on only EUS-guided Glue injection												
Lee <i>et al</i> [39], 2000	54	CYA (0.5 mL) with lipiodol (0.7 mL)	-	-	3 (1-8)	2.2 ± 1.7	52/54 (96.3%)	43/54 (79.6%)	22/54 (40.7%)	-	19/54 (35.2%)	28/54 (51.9%)
Romero-Castro <i>et al</i> [23], 2007	5	CYA-lipiodol (1 mL; 1:1)	22-G	-	1.6 (1-2)	2 cases: 1 each; 3 cases: 2 each	100%	100%	None	-	None	20%
Gubler and Bauerfeind [40], 2014	40	CYA-lipiodol (1 mL; 1:1)	22-G	-	1.9 (1-10)	1.4 (1-7)	40/40 (100%)	36/36 (100%)	2/40 (5%)	6/40 (15%)	-	6/40 (15%)
Studies on only EUS-guided coil injection												
Romero-Castro <i>et al</i> [25], 2010	4	Coils	19-G	Each case: 22; 7; 3; 2	-	-	100%	3/4 (75%)	None	-	None	25%
Khoury <i>et al</i> [41], 2018	10	Coils	19-G	4.5 (mean)	-	2.8 (mean)	100%	complete (20%); near-complete (50%)	5 cases (minimal self-limited bleeding); 1 case needing blood transfusion	30% (3/10)	1 case (10%)	None
Studies on only EUS-guided coil + glue injection												
Binmoeller <i>et al</i> [42], 2011	30	Coil + 1 mL CYA	19-G	-	1.4 (1-4)	1	30/30 (100%)	23/24 (95.8%)	None	1/30 (3.3%)	4/24 (16/6%)	1/30 (3.3%)
Bhat <i>et al</i> [27], 2015	152	Coil + 1 mL CYA	19/22-G	1.4 (1-4)	2 (0.5-6)	-	151/152 (99.3%)	93/100 (93%)	9/124 (7%)	7/125 (5.6%)	20/125 (16%)	3/151 (1.98%)
Koziel <i>et al</i> [43], 2019	16	Coil + CYA (1:1 with lipiodol)	19-G	Total 21; mean 1.7 (1-3)	2 (1-9)	-	15/16 (94%)	Overall, 12/15 (75%) [coil+CYA (11/12 [92%]; only CYA [0%]]	6/16 (37.5%)	5/16 (31.3%)	1/16 (6.25%)	None
Robles-Medrand <i>et al</i> [44], 2019	30	Coil + CYA	19-G	2 (1-3)	1.8 (1.2-2.4 mL)	Mean 1.1	100%	96.6%	2 cases (6.7%)	3/27 (11.1%)	5 (16.7%)	4/30 (13.3%)
Kouanda <i>et al</i> [28], 2021	80	Coil + CYA	-	1.5 (1-3)	2 (0.5-5) mL	Mean 1.4	100%	60/62 (96.7%)	4 (4.9%)		6 (7.5%)	17 (21.3%)

Comparison of different treatment modalities for GV management												
Romero-Castro <i>et al</i> [26], 2013	30	EUS-Coil (11) <i>vs</i> EUS-CYA (19)	19/22-G	5.8 (2-13) (overall 64 coils)	1.5 (1-3) (overall 29 mL)	Overall, 1.4 ± 0.1 (14 <i>vs</i> 29)	Overall, 27/30 (90%); 10/11 (90.9%) <i>vs</i> 17/19 (89.5%)	Overall, 29/30 (96.7%); 10/11 (90.9%) <i>vs</i> 19/19 (100%)	Overall, 12/30 (40%); 1/11 (9.1%) <i>vs</i> 11/19 (57.9%)	2/11 (18.1%) <i>vs</i> 9/19 (47.3%)	None (0 <i>vs</i> 0)	Overall, 6/30 (20%)
Bick <i>et al</i> [45], 2018	104	EUS-CYA (64) <i>vs</i> endoscopic CYA (40)	19/22-G	-	2 (0.8) <i>vs</i> 3.3 (1.3) mL	1 session (79% <i>vs</i> 75%); 2 sessions (21% <i>vs</i> 17.5%); 3 sessions (0% <i>vs</i> 7.5%)	100% <i>vs</i> 100%	49/64 (79%) <i>vs</i> 30/40 (75%)	13/64 (20.3%) <i>vs</i> 7/40 (17.5%)	-	5/57 (8.8%) <i>vs</i> 9/38 (23.7%)	-
Mukkada <i>et al</i> [32], 2018	81	EUS-coil +/- CYA (30) <i>vs</i> endoscopic CYA (51)	19-G	2.36 (mean) (total 71)	2 (1-10 mL) in 15 cases <i>vs</i> 3 ± 1.5 ml	Overall [42 <i>vs</i> 77]	100% <i>vs</i> 100%	8/20 (40%) <i>vs</i> (NA)	0% <i>vs</i> 0%	12/30 (40%) <i>vs</i> 26/51 (51%)	6/30 (20%) <i>vs</i> 26/51 (51%)	3/30 (10%) <i>vs</i> 2/51 (4%)
Robles-Medrand <i>et al</i> [29], 2019	60	EUS-coil + CYA (30) <i>vs</i> EUS-coil (30)	19-G	2 (1-3) <i>vs</i> 3 (1-7)	1.8 (1.2-2.4) <i>vs</i> -	-	100% <i>vs</i> 100%	30/30 (100%) <i>vs</i> 27/30 (90%)	2 (6.7%) <i>vs</i> 1 (3.3%)	5 (16.7%) <i>vs</i> 12 (40%)	1 (3.3%) <i>vs</i> 6 (20%)	9/30 (30%) <i>vs</i> 8/30 (26.7%)
Lôbo MRA <i>et al</i> [33], 2019	32	EUS-coil + CYA (16) <i>vs</i> endoscopic CYA (16)	19-G	Total 21	1.4 ± 0.74 <i>vs</i> 3.07 ± 1.94	Overall, 20 <i>vs</i> 18	100% <i>vs</i> 100%	11 (73.3%) <i>vs</i> 12 (75%)	8 (50%) <i>vs</i> 10 (62.5%)	4/15 (26.7%) <i>vs</i> 4/16 (25%)	2 (12.5%) <i>vs</i> 2 (12.5%)	0 (0%) <i>vs</i> 2 (12.5%)
Bazarbashi <i>et al</i> [46], 2020	40	EUS-coil + AGS (10) <i>vs</i> EUS/endoscopic CYA/histocryl (30)	19/22-G	8 ± 2.9	1.7 ± 2.9	-	10/10 (100%) <i>vs</i> 29/30 (96.7%)	100% <i>vs</i> 87%	1/10 (10%) <i>vs</i> 5/30 (20%)	1/10 (10%) <i>vs</i> 17/20 (56%)	0% <i>vs</i> 38%	1/10 (10%) <i>vs</i> 5/30 (16.6%)
Robles-Medrand <i>et al</i> [31], 2021	36	EUS-coil + CYA (17) <i>vs</i> endoscopic CYA (19)	19-G	0 <i>vs</i> 2 (1-3)	1.8 (1.2-2.4) <i>vs</i> 1.8 (0.6-6.6)	1 <i>vs</i> 1 (1-4)	17/17 (100%) <i>vs</i> 16/19 (84.2%)	-	2/17 (11.8%) <i>vs</i> 3/19 (15.8%)	-	0 <i>vs</i> 3/19 (15.8%)	-
Seven <i>et al</i> [47], 2022	28	EUS-coil (19) <i>vs</i> EUS-coil + CYA (9)	19-G	5 (3-9) <i>vs</i> 5 (3-9)	-	1 <i>vs</i> 1	19/19 (100%) <i>vs</i> 9/9 (100%)	19/19 (100%) <i>vs</i> 8/9 (88.9%)	1/19 (5.3%) <i>vs</i> 1/9 (11.1%)	1/19 (5.3%) <i>vs</i> 0/9 (0%)	1/19 (5.3%) <i>vs</i> 22.2%	6/28 (21.42%)
Samanta <i>et al</i> [34], 2022 (Author's centre)	170	EUS-coil+CYA (52) <i>vs</i> endoscopic CYA (118)	19-G	Median 2	2 (1) <i>vs</i> 2 (1) mL	1 (0) <i>vs</i> 2 (2)	52 (100%) <i>vs</i> 117 (99.2%)	-	0% <i>vs</i> 13.9%	7 (13.5%) <i>vs</i> 58 (49.6%)	8 (15.4%) <i>vs</i> 36 (31.3%)	-
Studies on EUS-guided treatment of GV using agents other than glue												
Frost and Hebbar [36], 2017	8	Thrombin (1000 IU/5 mL; 2500 IU/5 mL)	22-G	-	For active bleeder: mean 7250 IU; for elective: mean 2520 IU	1 for each case	100% overall	Overall, 75% (active bleeder: 67%; elective cases: 80%)	None	None	None	1 case
Bazarbashi <i>et al</i> [37], 2019	10	Coil + AGS	19/22-G	8 ± 2.9	AGS: 2.5 ± 0.7	1 each	100%	9/9 (100%)	None	None	1/10 (10%)	None
Irisawa <i>et al</i> [38], 2020	8	Coil + sclerosant [EO]	19-G	5.6 ± 2.9	EO: 7.8 ± 6.7 mL	1.9 ± 1	100%	7/8 (87.5%)	None	-	-	-

EUS: Endoscopic ultrasound; G: Gauge; CYA: Cyanoacrylate; AGS: Absorbable gelatin sponge; EO: Ethanolamine oleate; IU: International units.

varices holds a diagnostic challenge because of the diverse clinical presentation and lack of defined gui

Duodenal varices: Duodenal varices (DV) is extremely rare (0.4% cases). They are isolated in the submucosa and are easily missed on routine EGD. EUS plays an important role in determining the exact site, size, and location necessitating targeted therapy. Unfortunately, few case reports exist on using EUS-guided vascular therapy for DV[59-61] (Figure 4).

Rectal varices: Rectal varices (RV) has been reported in up to 44%-89% of cases of cirrhosis[62,63]. Due to their 'deep submucosal' nature, EUS has a higher sensitivity in identifying them over endoscopy (75% *vs* 43.3%), including perirectal collateral veins and perforators[64,65]. Multiple case reports have been published using EUS for RV management[66,67].

Parastomal varices: Bleeding stomal varices account for only 5% of bleeding ectopic varices (1%-5% of all cases)[57]. EUS-guided angiotherapy can be used as an alternative in managing such cases[68,69]. The author's center has experience performing EUS-coil with glue injection for parastomal varices in a cirrhotic patient ineligible for TIPS[70] (Figure 5).

Choledochal varices: The first case of ectopic variceal bleeding was reported in a case of anastomotic choledochal varices[71]. They are rare, and EUS may help diagnose such cases. EUS mini probe can identify pericholedochal varices in patients with extrahepatic venous obstruction and help differentiate from biliary stones or sludge (Figure 6).

Table 3 summarizes published literature on EUS-guided angiotherapy for ectopic variceal bleeding [72-79].

EUS-guided angiotherapy has theoretical benefits for variceal bleeding over the standard of care, primarily for GV. EUS offers additional benefits as a "rescue" modality for refractory/unsuccessfully treated cases. This management modality may be considered in the management algorithm of variceal bleed, albeit only in expert centers with adequate backup.

EUS-GUIDED MANAGEMENT OF NON-VARICEAL GI BLEED

Treatment of non-variceal bleed (NVB) entails the standard use of well-established therapies categorized into injection (epinephrine), mechanical (clip/EBL) or thermal (argon plasma coagulation) or hemostatic agents[80-82]. Despite this, 10%-24% of cases re-bleed or are refractory to the standard treatment modalities. In these cases, EUS-guided angiotherapy can be beneficial by helping in directly visualizing the bleeding vessel, its feeders or perforators and help in targeted therapy. Currently, the role of EUS for the management of NVB is more of a rescue therapy. However, a recent systematic review reported a favourable outcome of EUS-guided therapy in 91.4% of cases[83]. In addition, EUS-angiotherapy is feasible and safe for managing Dieulafoy's lesion, bleeding ulcer or tumour, GI stromal tumour (GIST) and sometimes, visceral artery pseudoaneurysms (PsA).

Visceral artery pseudoaneurysms

PsA is a rare vascular complication noted in various conditions, more commonly in acute or chronic pancreatitis, with an incidence of 0.05% and 0.03%, respectively. The splenic artery is the most common vessel involved (37.7%). The most frequent line of management is IR-guided endovascular therapy[84, 85]. However, EUS-guided angiotherapy can be an exciting alternative to manage such cases. The proximity of PsA of splenic vessels or gastroduodenal artery to the GI wall enables them to be targeted and obliterated. Various agents like coil, CYA glue, a coil with glue combination and thrombin have been used.

The technique of performing EUS-guided angiotherapy in PsA: The technical details have been highlighted in Table 4.

Existing literature: Case reports: The use of thrombin in PsA was first described by Roach *et al*[86], wherein thrombin (500 IU, 1 mL) was injected in a PsA arising from a superior mesenteric artery under EUS guidance with no re-bleeding at 42 wk of follow-up. The use of CYA glue with lipiodol was described by Gonzalez *et al*[87], wherein a splenic artery PsA was tackled, and there was no re-bleed on a 2-mo follow-up. Similarly, the first use of coil was described by Robb *et al*[88] in superior mesenteric artery PsA using multiple Nester coils, achieving complete obliteration in one session. Rai *et al*[89] used coil with CYA glue combination in a 3 cm splenic artery PsA in a single sitting with no re-bleed in 1 mo. Giant PsA (> 5 cm) have also been reported to have been managed with EUS-angiotherapy. The author's center reported a 6.5 cm splenic artery PsA using a coil and glue combination in 2 sessions achieving complete obliteration[90]. The case reports have been outlined in Supplementary Table 1.

Case series: Only 5 case series (> 3 cases) have been reported, mainly from the Indian subcontinent and have been tabulated in Table 5. Three of them have utilized thrombin, while two have used coil with glue[91-95]. The author's centre has reported the largest series of 16 cases of visceral artery PsA in 15 patients. The median size of the PSA was 2.8 cm (0.9-9.7 cm). A median of 2 coils (1-8) and 2 mL of CYA (1-5 mL) was used. Complete obliteration in the first session was achieved in 15 PSA (93.8 %)[95]

Table 3 Published literature on the use of endoscopic ultrasound-guided vascular interventions in ectopic varices

Ref.	Cases	Underlying diagnosis	Age/sex	Size of varix	Any prior therapy given	EUS therapy (agent used)	EUS needle used	Coils	Glue	Post procedure EUS findings	Follow-up duration	Comments
Duodenal varices												
So <i>et al</i> [60], 2016	1	PC/EHPVO	65/F	2 cm	-	Coil	19-G FNA	3	-	Color Doppler: cessation of blood flow	10 mo	No bleeding on F/U
Kimura <i>et al</i> [61], 2017	1	PC	76/F	-	-	CYA glue	22-G FNA	-	0.5 mL (3 sessions)	-(f/u CT: shows extinction of contrast enhancement in DV)	6 mo	No bleeding on F/U
Kinzel <i>et al</i> [72], 2014	1	Cirrhosis (Child C)	31/M	10 mm	Endoscopic ethanolamine oleate	Coil + CYA glue	19-G (for coil) + 22-G (for glue) FNA	1	2 mL	Near complete thrombosis of varix	3 mo	No bleeding on F/U
Fujii-Lau <i>et al</i> [73], 2016	3	PVT; SMV-T; SMV-T	57/M; 46/F; 62/F	-; -; -	Glue; -; Clip + coil (IR)	Coil; Coil; Coil + CYA glue	22-G FNA (for all)	4; 4; 8	-; -; 2 mL	dec. flow; dec. flow; no flow	30 mo; 12 mo; 6 mo	No bleeding on F/U (all cases)
Bahdi <i>et al</i> [74], 2020	1	Cirrhosis	41/M	-	None	Coil + CYA glue	22-G FNA	8	2 mL	-	-	-
Rectal varices												
Messallam <i>et al</i> [66], 2014	1	Cryptogenic cirrhosis	78/M	45 × 12 mm	None	Coil + CYA glue	19-G FNA	2	4 mL	No flow	12 wk	No bleeding on F/U
Sharma <i>et al</i> [67], 2010	1	PHTN	68/M	2.2 mm	None	Histocryl glue	-	-	1 mL	Decreased flow	6 mo	No bleeding on F/U
Mukkada <i>et al</i> [75], 2017	1	PHTN	65/M	5.9 mm	Endoscopic sclerotherapy (tetradecyl sulphate 16 mL; CYA glue)	Coil	19-G FNA	2	-	No flow	-	-
Bazarbashi <i>et al</i> [76], 2020	1	Cirrhosis	71/M	4 mm	None	Coil	19-G FNA	1	-	No flow	6 mo	No bleeding on F/U
Philips <i>et al</i> [77], 2017	1	Cirrhosis	48/M	-	None	Coil + CYA glue	22-G FNA	1	1 mL	No flow	1 mo	No bleeding on F/U
Weilert <i>et al</i> [78], 2012	1	Cirrhosis	60/F	> 3 cm	None	Coil + CYA glue	19-G FNA	5	4 mL	No flow	12 mo	No bleeding on F/U
Jana <i>et al</i> [79], 2017	1	Hepatitis C/PHTN	54/M	-	None	Coil + CYA glue	22-G FNA	3	0.8 mL	No flow	1 mo	No bleeding on F/U
Stomal varices												

Tabibian <i>et al</i> [68], 2016	1	Cirrhosis PSC/post colectomy for UC	70/F	5 mm	Somatostatin/topical silver nitrate	Coil	22-G FNA	6	-	No flow	9 mo	No bleeding on F/U
Tsynman <i>et al</i> [69], 2014	1	UC/post colectomy/cirrhosis	74/F	-	TIPS	CYA glue with lipiodol	22-G FNA	-	0.5 mL	No flow	8 mo	No bleeding on F/U
Samanta <i>et al</i> [70], 2022	1	Alcohol cirrhosis/tubercular cocoon/ileostomy	52/M	-	Endoscopic glue injection	Coil + CYA glue	19-G FNA	2	4 mL	No flow	6 mo	No bleeding on F/U
Choledochal varices												
Levy <i>et al</i> [71], 2008	1	CP/post total pancreatectomy	50/F	14 mm	-	Coil	22-G FNA	5	-	No flow	1 mo	No bleeding on F/u
Fujii-Lau <i>et al</i> [73], 2016	5	Cirrhosis; SMV-T; PVT; PHTN; PVT	61/M; 56/M; 27/M; 71/M; 50/F	-; -; -; -; -	None; None; None; None; None	Coil; Coil; Coil; Coil; Coil	22-G FNA (for all)	7; 9; 4; 5; 5	-; -; -; -; -	dec. flow; dec. flow; dec. flow; dec. flow; dec. flow	24 mo; 37 mo; 26 mo; 1 mo; 87 mo	Recurrent bleed in 3 cases; one case died due to underlying disease

EUS: Endoscopic ultrasound; PC: Pancreatic cancer; EHPVO: Extrahepatic portal vein obstruction; F: Female; M: Male; G: Gauge; FNA: Fine needle aspiration; F/U: Follow-up; CT: Computed tomography; DV: Duodenal varices; CYA: Cyanoacrylate; PVT: Portal vein thrombosis; SMV-T: Superior mesenteric vein thrombosis; IR: Interventional radiology; Dec.: Decreased; PHTN: Portal hypertension; PSC: Primary sclerosing cholangitis; UC: Ulcerative colitis; TIPS: Transjugular intrahepatic portosystemic shunt; CP: Chronic pancreatitis

(Figure 7).

Other causes of NVB (Dieulafoy's/bleeding tumors)

Anecdotal reports have been published on using EUS-guided angiotherapy to manage NVB (Supplementary Table 2). In 1996, the first report used EUS-guided epinephrine/polidocanol injection for managing bleeding dieulafoy's lesion [96] (Figure 8). Levy *et al* [97] reported a series of 5 refractory NVBs, including dieulafoy's lesion, hemosuccus pancreaticus, duodenal ulcer and GIST. The largest data of EUS-guided therapy reported to date involves a cohort of 17 cases using various agents. On a median 12-mo follow-up, 15/17 (88%) patients had no re-bleed [98].

The data on EUS-guided vascular interventions for NVB is limited and comparative studies are needed to establish its role in therapeutic algorithms. However, EUS-guided angiotherapy may be considered a second-line "rescue" treatment, especially in refractory/re-bleeding cases. The feasibility and safety data are encouraging, though larger multicentre data is required to define its role further.

EUS-GUIDED PV-RELATED INTERVENTIONS

PV dynamics are crucial for decision-making in chronic liver disease and PHTN cases. EUS-guided PV access is a viable option with a probable advantage over the percutaneous route owing to the relative difficulty experienced in the latter in patients with obesity, ascites, and overlying distended bowel [99]. In addition, there are various potential clinical applications of EUS-guided PV access that include angiography, measurement of the PPG, EUS-guided TIPS, and PV sampling for evaluation in GI cancer

Table 4 Steps for endoscopic ultrasound-guided management of visceral artery pseudoaneurysm

EUS-guided angioembolization of visceral artery pseudoaneurysm
Pre-procedure requirements
All procedures are done under the cover of pre/peri-procedural antibiotics
Patient is usually kept fasting for 4-6 h before the procedure
Adequate resuscitation of the patient, in case of active bleeding is ensured, prior to the procedure
Informed consent prior to the procedure
What is needed prior to the procedure
Linear echoendoscope with at least a 3.7 mm working channel
Needle size: depends on the choice of the endoscopist; usually a 19-G needle is used with 0.035" coil. However, a 22-G needle with 0.018" coils may be used
Diameter of the coils: Smaller than the shortest diameter of the PsA
Number of coils: depends on size of the PsA
Amount of glue: depends on the size of the PsA
Technical aspects
A proper diagnostic EUS is performed
The echoendoscope is positioned optimally for a stable PsA access
Optimum examination of the PsA, the feeding vessel and the anatomy is delineated
The approach should always be through parenchyma, either pancreatic or hepatic. Bare puncture of the PsA without supporting parenchyma should not be performed
EUS-guided coil and glue embolization is usually performed using a 22-G/19-G (gauge) FNA needle
The size of the coil is determined by the short axis of the diameter of the PsA
After puncture of the varix, blood is aspirated to confirm the location. This is followed by flushing of the needle with saline. The pressure is high in the aneurysm, hence care should be taken to avoid creeping of blood along the hollow of the needle and causing needle block
The coils are then deployed into the varix using the stylet as a pusher. Packing with coils slows the flow inside the PsA, which can be visualized and further requirement of coils is assessed. Once the coils are deployed, flushing of the needle is done with normal saline
After coil deployment, cyanoacrylate glue is injected using the coils as scaffold
Once, the PsA is obliterated, visualized by absence of flow on colour Doppler, the sheath of the needle is advanced beyond the endoscope tip for 2-3 cm before withdrawing the scope. This avoids contact of glue with the endoscope tip
Post procedure
The patients are kept under observation for 12 h
Post embolization X-ray would help visualize the coils and also look for complications
Repeat EUS can be done after 48 hrs. to look for residual flow
Cross-sectional imaging is usually done after 72 h. to document success of therapy
Follow-up EUS may be performed at 1-mo

G: Gauge; PsA: Pseudoaneurysm; EUS: Endoscopic ultrasound; FNA: Fine needle aspiration.

[1,99].

EUS-guided portal vein access

Access to the PV can be achieved on EUS *via* both, trans-gastric or trans-duodenal route. However, the most frequently targeted site is the intrahepatic PV through the hepatic parenchyma[1,2,99].

The technique: PV puncture is done using the standard EUS-FNA needle after confirming with colour doppler and pulse-wave verification. Some important points for consideration are: (1) 25-G needle is the least traumatic; (2) trans-gastric, trans-hepatic route on EUS is safer than accessing from duodenum; and (3) use of CO₂ as a contrast agent is better than iodine, as it allows better visualization of needle as well as easier administration using small-caliber FNA needle. Following the puncture of PV, the needle is slightly withdrawn and the tract is monitored using colour-Doppler for any bleeding episodes. If positive signal is reported, the needle is kept in place until the bleeding has stopped[100].

Table 5 Published case series on endoscopic ultrasound-guided angiotherapy for arterial pseudoaneurysm

S.No.	Ref.	Cases	Age/sex	Chief complaints	Artery involved	PSA size (mm)	EUS needle used	Embolization agent used	EUS sessions needed	Technical/clinical success	Complications	Follow up and comments
1	Gamanagatti <i>et al</i> [91], 2015	3	56/M; 45/M; 30/M	Upper GI bleed (all 3)	GDA; Splenic; Splenic	-	22-G	Thrombin (500 IU, 300 IU, 400 IU)	1 each	Yes/yes	None	Imaging F/U: complete obliteration; no bleeding at 1 mo F/U
2	Jhajharia <i>et al</i> [92], 2018	3	43/M; 25/M; 55/M	Pain abdomen; hematemesis; Malena (respectively)	GDA; Right hepatic; splenic	40 × 50; 30 × 22 × 27; 15 × 13	22-G	Thrombin (1000 IU; 1000 IU; 500 IU)	1 each	Yes/yes	None	F/U at 1.5 years, 1 year and 3 mo: no bleeding (respectively)
3	Rai <i>et al</i> [93], 2018	6	Median 36.7 years (19-60); 5 men	3 asymptomatic; 3 upper GI bleed	All Splenic artery PSA	25-65 (range)	19-G	Coils (size 8, 14, 16; number 1-5) and glue (1-2 mL)	3 cases needed 2 EUS sessions (size > 4 cm)	Yes/yes (all cases)	None	EUS (4 wk) and CT (3 mo): complete obliteration
4	Maharshi <i>et al</i> [94], 2020	8	Median 34 years (27-58); all males	Malena (100%); hematemesis (75%)	Splenic (5); left hepatic (2); GDA (1)	Median 29 × 26 (range 18 × 19 – 40 × 50)	22-G	Thrombin (200-500 IU)	1	Yes/87.5% clinical success (7/8 cases)	2 cases post procedural pain	EUS (1 and 3 mo) and CT (1 mo): complete obliteration; only 1 case with PSA > 5 cm needed second EUS session after 6 wk
5	Samanta <i>et al</i> [95], 2022	16 PsA (in 15 patients)	Median 44 (17-56); males 14 (93.3%)	Malena/incidental/ PCD bleed	Splenic (12); GDA (4)	Median 2.8 (0.9-9.7 cm)	19-G	Coils (median 1[1-8] with CYA glue (median 2 [1-5 mL])	1 session in 15 (93.8%)	Yes/yes	One case had splenic infarct (managed conservatively)	Follow-up at 6 mo: no rebleed; one case developed recurrent PsA at a site separate from first PsA (managed again with EUS)

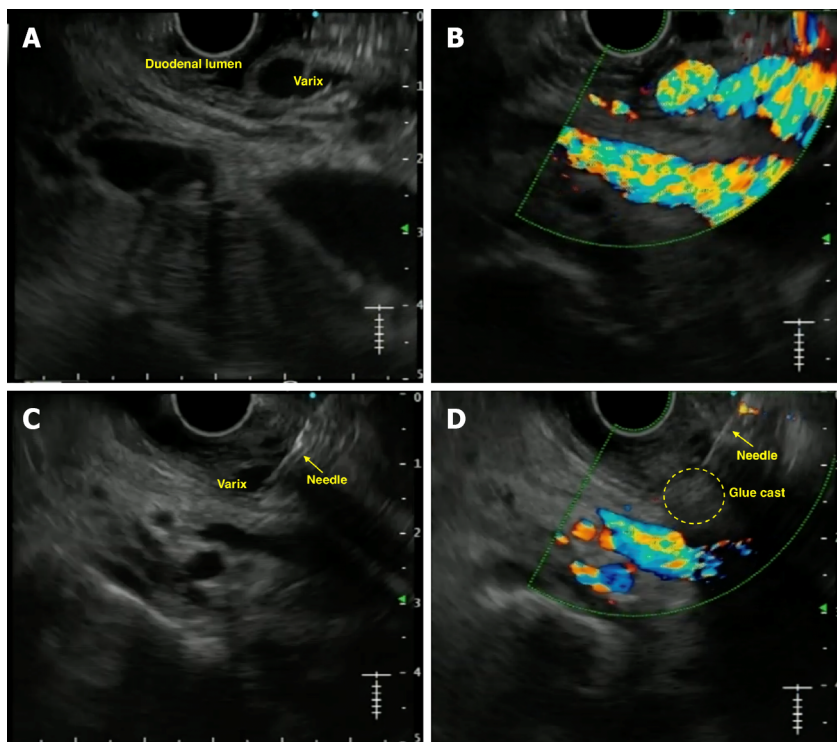
PsA: Pseudoaneurysm; EUS: Endoscopic ultrasound; F/U: Follow-up; IU: International units; GDA: Gastroduodenal artery; PCD: Percutaneous catheter drainage; CYA: Cyanoacrylate glue; GI: Gastrointestinal; CT: Computed tomography.

Existing literature in animal models: Lai *et al*[101] proved the technical feasibility of the procedure by reporting the first case of PV access in 2004 using EUS guidance wherein extrahepatic PV was accessed using 22-G FNA needle, *via* duodenum, in 21 swine models. Subsequently, Magno *et al*[102] performed PV angiography in 2007 in 5 pigs, demonstrating that the 25-G needle showed no signs of injury. Subsequently, Giday *et al*[100,103] performed trans-hepatic PV access using a 25-G FNA needle under CO₂ insufflation. Portal pressure measurements were also taken, indicating it to be technically feasible (Supplementary Table 3).

Once it is established that EUS-guided PV access is feasible, it paves the path for further interventions such as PPG measurement, PV sampling and even EUS-guided intrahepatic portosystemic shunt.

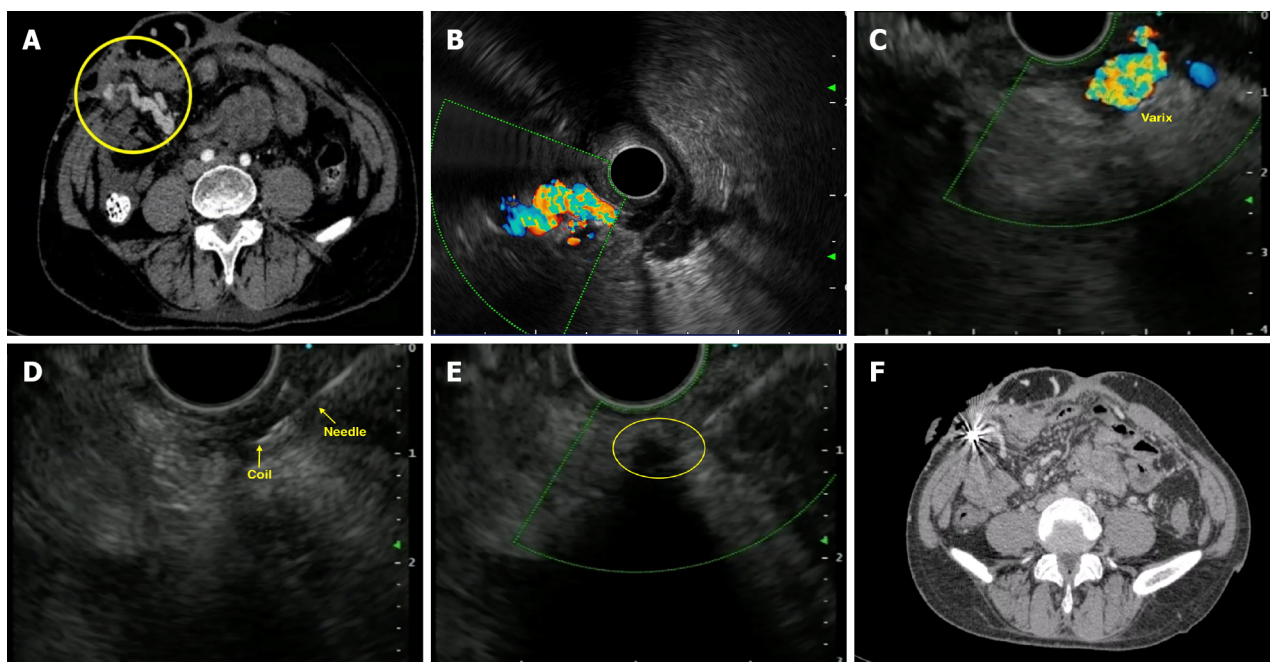
EUS-PPG measurement

PPG measurement has been shown to correlate with the prognosis and complications of cirrhosis. In addition, PPG ≥ 10 mmHg and ≥ 12 mmHg are associated with the development of EV and bleeding,



DOI: 10.4253/wjge.v15.i4.216 Copyright ©The Author(s) 2023.

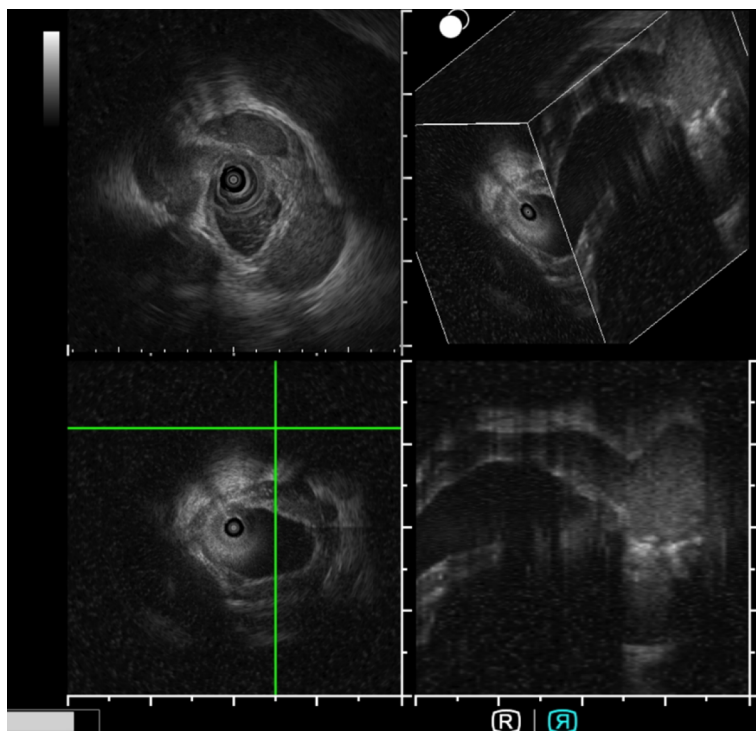
Figure 4 Endoscopic ultrasound-guided vascular therapy for duodenal varix. A: Endoscopic ultrasound image of duodenal varix; B: Colour Doppler showing flow in the varix; C: Puncture of the varix with 19-G needle; D: Obliteration of the varix noted on Doppler flow.



DOI: 10.4253/wjge.v15.i4.216 Copyright ©The Author(s) 2023.

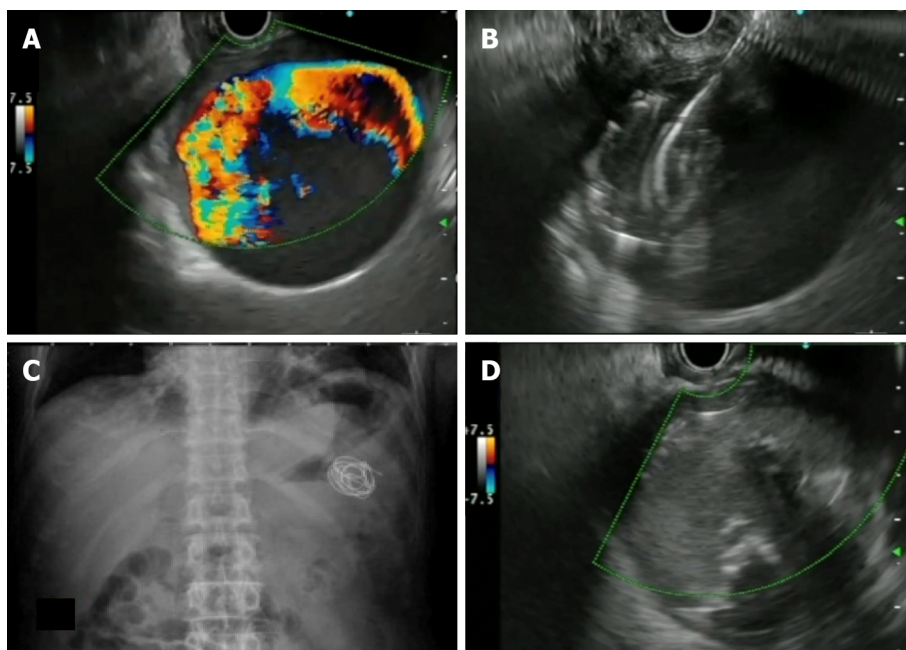
Figure 5 Endoscopic ultrasound-guided vascular therapy for parastomal varices. A: Contrast enhanced computed tomography (CT) showing parastomal varices; B: Radial endoscopic ultrasound (EUS) image demonstrating the parastomal varices; C: Linear EUS image of the varices; D: Puncture of the varix with coil deployment; E: Obliteration of the varix with coil-glue cast; F: Post-intervention CT showing coil artifacts with obliteration of varices.

respectively. Currently, the standard practice is to measure hepatic venous pressure gradient (HVPG) *via* the percutaneous route. But, both direct PV access and HVPG measurement have high complication rates[104]. Moreover, HVPG correlated poorly with presinusoidal PHTN. Hence, the concept of EUS-PPG arose to overcome these difficulties, with the added benefit of assessment of varices and liver biopsy in the same setting, if required.



DOI: 10.4253/wjge.v15.i4.216 Copyright ©The Author(s) 2023.

Figure 6 Intraductal ultrasound for pericholedochal varices. Intraductal ultrasound using endoscopic ultrasound miniprobe (UM-DG20-31R IDUS probe, Olympus, Japan) for imaging in a case of portal cavernoma cholangiopathy with 3D reconstruction.



DOI: 10.4253/wjge.v15.i4.216 Copyright ©The Author(s) 2023.

Figure 7 Endoscopic ultrasound-guided vascular therapy for pseudoaneurysm. A: Giant splenic artery pseudoaneurysm with Doppler flow; B: Puncture of the pseudoaneurysm with 19-G needle and deployment of coils; C: Abdominal X-ray showing deployed coils; D: Endoscopic ultrasound image of obliterated pseudoaneurysm after coil and glue injection.

The technique of the procedure: This has been highlighted in Table 6[105].

Existing literature and future trends: The first clinical report of the use of EUS-PPG was given by Fujii-Lau *et al*[106], wherein a 27-year-old man with recurrent GI bleed (post EUS-coil insertion in duodenal vessels) underwent this procedure. The first large-scale study in 28 cases was done by Huang *et al*[105],

Table 6 Technique for assessing endoscopic ultrasound-guided portal pressure gradient**Procedural steps for measuring EUS-PPG**

The measurement of PPG *via* EUS requires 4 components: 25-G FNA needle, non-compressible tubing, a compact digital manometer, and heparinized saline. The tubing is connected by a luer lock to the distal port and heparinized saline is connected the proximal port of the manometer

With the patient supine, the manometer is placed at the patient's midaxillary line

The HV measurement is conducted first, in which middle HV is targeted most often (larger calibre and better alignment with the needle trajectory). Then PV measurement is taken (umbilical portion of left PV is the target)

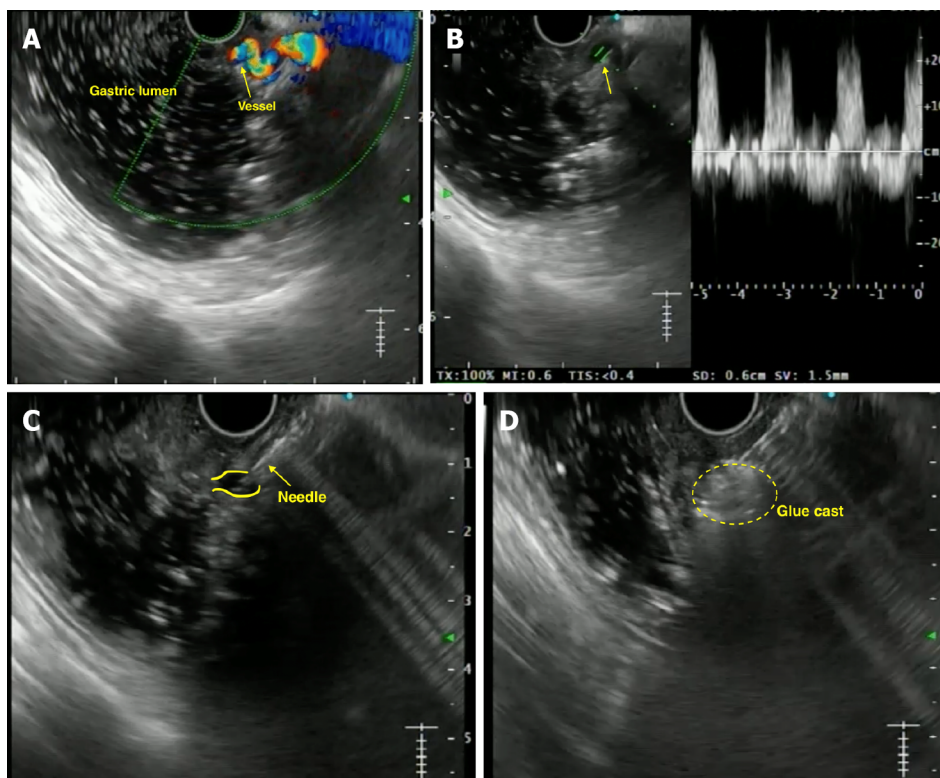
Doppler flow is used to confirm the typical multiphasic waveform of hepatic venous flow and typical venous hum of the portal venous flow

Trans-gastric trans-hepatic route is taken for HV and PV puncture

Needle is flushed with heparinized saline (1 mL). The steadiest reading at equilibrium is recorded. Three measurements are taken and their mean is calculated (both HV and PV pressures)

The FNA needle is slowly withdrawn from the vein into the liver parenchyma and then back into the needle sheath with Doppler flow on to ensure there is no flow within the needle tract

EUS: Endoscopic ultrasound; PPG: Portal pressure gradient; G: Gauge; FNA: Fine needle aspiration; PV: Portal vein; HV: Hepatic vein.



DOI: 10.4253/wjge.v15.i4.216 Copyright ©The Author(s) 2023.

Figure 8 Endoscopic ultrasound-guided vascular therapy for dieulafoy's lesion. A: Endoscopic ultrasound image showing the culprit tortuous vessel coursing up to the mucosa; B: Power Doppler showing the flow pattern; C: Puncture of the vessel with a 22-G needle; D: Obliteration of the flow with formation of glue cast.

using a 25-G FNA needle with 100% technical success and no adverse events. PPG correlated with varices, thrombocytopenia, and notable clinical evidence of cirrhosis. Zhang *et al*[107] demonstrated its use in patients with acute or subacute PHTN, with an excellent correlation between EUS-PPG and HVP ($r = 0.923$). Acting as a “one-stop-shop”, performing EUS-PPG with EUS-liver biopsy in the same sitting has shown to be technically feasible in a study of 24 cases, with good correlation with the non-invasive markers of fibrosis[108]. Table 7 highlights the published literature on the use of EUS-PPG[105-111].

EUS-guided trans-jugular intrahepatic portosystemic shunt

The benefits of trans-jugular intrahepatic portosystemic shunt (TIPS), as a pre-emptive or rescue

Table 7 Published literature (human studies) on the use of endoscopic ultrasound-guided portal pressure measurement

Ref.	Year	Number of cases	Approach	EUS-FNA needle	Technical success	Complications	Correlation between EUS and trans-hepatic PVP measurement
Fujii-Lau <i>et al</i> [106]	2014	1	Trans-gastric	22-G	1	None	PPG 1 mmHg (excellent correlation with HVPG)
Huang <i>et al</i> [105]	2017	28	-	25-G	25/25 cases	None	Excellent correlation with varices ($P = 0.0002$), PHG ($P = 0.007$), and thrombocytopenia ($P = 0.036$); few of them also underwent liver biopsy in same setting
Zhang <i>et al</i> [107]	2020	12	-	22-G	11/12 cases (91.7%)	None	$R = 0.923$
Shah <i>et al</i> [109]	2021	1	Trans-gastric	25-G	1	None	NA (same session EUS-liver biopsy was done)
Hajifathalian <i>et al</i> [108]	2021	24	Trans-gastric	25-G	23/24 (96%) patients also underwent EUS-liver biopsy (IS: 24/24 [100%])	One case of mild abdominal pain (resolved with analgesics)	NA; excellent correlation with fibrosis-4 score ($P = 0.026$) and transient elastography ($P = 0.011$)
Choi <i>et al</i> [110]	2022	83	Trans-gastric	25-G	100%; 71 cases underwent EUS-liver biopsy	No major events; minor abdominal pain (8 [9.6%] cases)	Correlation with clinical features of cirrhosis (9.46 vs 3.61 mmHg, $P < 0.0001$), EV/GV (13.88 vs 4.34 mmHg, $P < 0.0001$), and thrombocytopenia (9.25 vs 4.71 mmHg, $P = 0.0022$)
Choi <i>et al</i> [111]	2022	64	Trans-gastric	25-G	100% (concurrent EUS-LB in 43/64 [67.2%])	1 case (EUS-PPG alone); 5 cases (EUS-PPG + EUS-LB both)	EUS-PPG > 5 mmHg correlated with EUS-liver biopsy fibrosis stage ≥ 3 [LR 27] ($P = 0.004$)

EUS: Endoscopic ultrasound; PPG: Portal pressure gradient; FNA: Fine needle aspiration; PVP: Portal venous pressure; G: Gauge; LB: Liver biopsy; EV: Esophageal varices; GV: Gastric varices; LR: Likelihood ratio; NA: Not available; PH: Portal hypertensive gastropathy.

procedure in cases of variceal bleeding or refractory ascites has been well established. Buscaglia *et al* [112] described the first case of EUS-TIPS in a live porcine model in 2009, wherein after sequential puncture of HV and PV, a metal stent was inserted with the distal end in PV and proximal end in HV with no complications on follow-up in 2 wk. Similarly, Binmoeller *et al* [113] and Schulman *et al* [114] have reported similar results in porcine models using lumen-apposing metal stent (LAMS). Poincloux *et al* [115] reported the largest series of 21 porcine models showing a technical success of 91% with 14.2% morbidity. EUS-guided TIPS is still in the pre-clinical stages, and many technical issues must be resolved before embarking on human trials.

EUS-guided PV sampling

“Liquid biopsy” for hepatobiliary malignancies is gaining popularity. The PV has been shown to harbour circulating tumour cells (CTCs) for the primary tumour, forerunners of future metastasis of solid organ cancers. This signifies tumor signature and can help in prognostication and also can be used for organoid formation for future studies. The first human study was reported by Catenacci *et al* [116] wherein CTCs were detected in 100% of cases of PV and 4/18 (22.2%) cases from peripheral blood. Zhang *et al* [117] reported that CTCs are more in PV than peripheral blood (97% vs 87%; 10 vs 6 cells per 5 mL). Further studies are needed to standardize this technique.

EUS-guided FNA of portal vein thrombosis

The presence of malignant PV thrombosis (PVT) is a poor prognostic sign and precludes curative resection. Usually, imaging (ultrasound/computed tomography) can help differentiate bland and malignant PVT, but definitive confirmation would require sampling. Performing the latter *via* the percutaneous route is difficult and may lead to serious vascular and biliary injury. This can be overcome by EUS-guided PV access. Trans-duodenal approach to extrahepatic PV using a 25-G FNA needle yields excellent results. Various case reports have been published on using EUS-FNA of PVT, especially in cases of hepatocellular carcinoma [118–122]. Rustagi *et al* [118] showed that in 17 patients, EUS-FNA of remote malignant thrombi upstaged the diagnosis by 37.5% and converted 25% to an unresectable stage. This underlines using EUS-FNA of PV thrombus as a cancer staging modality.

EUS-guided PV injection of chemotherapy

Systemic palliative or trans-arterial chemotherapy for diffuse liver metastasis is fraught with problems like suboptimal hepatic tissue levels and the possibility of secondary sclerosing cholangitis. However,

Faigel *et al*[123,124] first reported the technical feasibility of EUS-guided PV injection of chemotherapy (EPIC) using drug-eluting microbeads and nanoparticle in 24 swine models. Although further studies are warranted, this study proved the feasibility of EPIC in an animal model.

EUS-guided PV embolization

Preoperative PV embolization (PVE) before liver resection has been practiced *via* IR[125]. In addition, preliminary studies in an animal model by Matthes *et al*[126] using EUS-guided ethylene-vinyl alcohol copolymer leading to PVE have been reported. Recently, Park *et al*[127] reported technical success of 88.9% and 87.5%, respectively, with coil and CYA glue embolization in 9 swine models with no evidence of organ damage. Although further studies are needed, this technique does show promise for future application.

EUS-guided PV stent placement

The PV-stenting (for occlusion/thrombosis) is usually carried out by the percutaneous route (USG-guided catheter-directed thrombolysis). The use of EUS has opened up avenues of PV access and subsequent stent placement. This was first reported by Park *et al*[128] in 6 swine models, using uncovered stents, with 100% technical success.

EUS-GUIDED CARDIAC INTERVENTIONS

The proximity of the posterior mediastinum to the esophagus has allowed EUS easy access to the heart and associated vascular structures. Like trans-esophageal echocardiography, EUS is technically feasible in animal models to sample the coronaries, atria, ventricles, and valvular apparatus. Fritscher-Ravens *et al*[129] demonstrated radiofrequency ablation of the aortic valve, pericardial fluid aspiration, and atrial mass biopsy in swine models with no major adverse events. Most isolated case reports exist on EUS-biopsy of intracardiac/pericardial tumours[130-132]. EUS-aspiration of pericardial fluid has been performed with no reported arrhythmias[133]. Even EUS-guided thrombolysis of pulmonary artery and mesenteric thrombi has been reported. Under EUS guidance, Tenecteplase was injected into the thrombus using a 25-G needle[134].

While the reports are exciting, these are anecdotal cases, and more data is warranted in the future to establish the safety and efficacy of such interventions.

CONCLUSION

EUS-guided vascular intervention is gradually becoming a promising new technique for managing vascular complications around the GI tract as a salvage and/or primary modality. While comprehensive data has established its safety and efficacy in managing conditions such as GV and measurement of PPG, its role for other applications such as management of visceral artery pseudoaneurysms and PV access for various therapies needs further validation. Nevertheless, proper selection of cases, adequate precautions and optimum backup can make EUS-guided angiotherapy an essential tool in the endoscopist's armamentarium.

FOOTNOTES

Author contributions: Dhar J contributed to conception and design, data acquisition and analysis draft of the article; Samanta J contributed to conception and design, data interpretation, critical revision and intellectual content of the draft; all authors have read and approved the final manuscript.

Conflict-of-interest statement: All the authors declare no potential conflicts of interest.

Open-Access: This article is an open-access article that was selected by an in-house editor and fully peer-reviewed by external reviewers. It is distributed in accordance with the Creative Commons Attribution NonCommercial (CC BY-NC 4.0) license, which permits others to distribute, remix, adapt, build upon this work non-commercially, and license their derivative works on different terms, provided the original work is properly cited and the use is non-commercial. See: <https://creativecommons.org/licenses/by-nc/4.0/>

Country/Territory of origin: India

ORCID number: Jahnvi Dhar 0000-0002-6929-4276; Jayanta Samanta 0000-0002-9277-5086.

S-Editor: Chang KL

L-Editor: A

P-Editor: Chang KL

REFERENCES

- 1 Levy I, Binmoeller KF. EUS-guided vascular interventions. *Endosc Ultrasound* 2018; **7**: 228-235 [PMID: 30117484 DOI: 10.4103/eus.eus_32_18]
- 2 Dhar J, Samanta J. Role of endoscopic ultrasound in the field of hepatology: Recent advances and future trends. *World J Hepatol* 2021; **13**: 1459-1483 [PMID: 34904024 DOI: 10.4254/wjh.v13.i11.1459]
- 3 Sarin SK, Lahoti D, Saxena SP, Murthy NS, Makwana UK. Prevalence, classification and natural history of gastric varices: a long-term follow-up study in 568 portal hypertension patients. *Hepatology* 1992; **16**: 1343-1349 [PMID: 1446890 DOI: 10.1002/hep.1840160607]
- 4 Garcia-Tsao G, Abraldes JG, Berzigotti A, Bosch J. Portal hypertensive bleeding in cirrhosis: Risk stratification, diagnosis, and management: 2016 practice guidance by the American Association for the study of liver diseases. *Hepatology* 2017; **65**: 310-335 [PMID: 27786365 DOI: 10.1002/hep.28906]
- 5 Carbonell N, Pauwels A, Serfaty L, Fourdan O, Lévy VG, Poupon R. Improved survival after variceal bleeding in patients with cirrhosis over the past two decades. *Hepatology* 2004; **40**: 652-659 [PMID: 15349904 DOI: 10.1002/hep.20339]
- 6 Oleas R, Robles-Medrand C. Insights into the role of endoscopic ultrasound-guided vascular therapy. *Ther Adv Gastrointest Endosc* 2019; **12**: 2631774519878282 [PMID: 31633107 DOI: 10.1177/2631774519878282]
- 7 Saad WE, Darcy MD. Transjugular Intrahepatic Portosystemic Shunt (TIPS) vs Balloon-occluded Retrograde Transvenous Obliteration (BRTO) for the Management of Gastric Varices. *Semin Intervent Radiol* 2011; **28**: 339-349 [PMID: 22942552 DOI: 10.1055/s-0031-1284461]
- 8 European Association for the Study of the Liver. EASL Clinical Practice Guidelines for the management of patients with decompensated cirrhosis. *J Hepatol* 2018; **69**: 406-460 [PMID: 29653741 DOI: 10.1016/j.jhep.2018.03.024]
- 9 Krige JE, Bornman PC, Goldberg PA, Terblanche J. Variceal rebleeding and recurrence after endoscopic injection sclerotherapy: a prospective evaluation in 204 patients. *Arch Surg* 2000; **135**: 1315-1322 [PMID: 11074888 DOI: 10.1001/archsurg.135.11.1315]
- 10 Hou MC, Lin HC, Lee FY, Chang FY, Lee SD. Recurrence of esophageal varices following endoscopic treatment and its impact on rebleeding: comparison of sclerotherapy and ligation. *J Hepatol* 2000; **32**: 202-208 [PMID: 10707859 DOI: 10.1016/s0168-8278(00)80064-1]
- 11 Irisawa A, Obara K, Bhutani MS, Saito A, Shishido H, Shibukawa G, Takagi T, Yamamoto G, Seino O, Shishido F, Kasukawa R, Sato Y. Role of para-esophageal collateral veins in patients with portal hypertension based on the results of endoscopic ultrasonography and liver scintigraphy analysis. *J Gastroenterol Hepatol* 2003; **18**: 309-314 [PMID: 12603532 DOI: 10.1046/j.1440-1746.2003.02956.x]
- 12 Irisawa A, Saito A, Obara K, Shibukawa G, Takagi T, Shishido H, Sakamoto H, Sato Y, Kasukawa R. Endoscopic recurrence of esophageal varices is associated with the specific EUS abnormalities: severe periesophageal collateral veins and large perforating veins. *Gastrointest Endosc* 2001; **53**: 77-84 [PMID: 11154493 DOI: 10.1067/mge.2001.108479]
- 13 Lahoti S, Catalano MF, Alcocer E, Hogan WJ, Geenen JE. Obliteration of esophageal varices using EUS-guided sclerotherapy with color Doppler. *Gastrointest Endosc* 2000; **51**: 331-333 [PMID: 10699783 DOI: 10.1016/s0016-5107(00)70363-4]
- 14 de Paulo GA, Ardengh JC, Nakao FS, Ferrari AP. Treatment of esophageal varices: a randomized controlled trial comparing endoscopic sclerotherapy and EUS-guided sclerotherapy of esophageal collateral veins. *Gastrointest Endosc* 2006; **63**: 396-402; quiz 463 [PMID: 16500386 DOI: 10.1016/j.gie.2005.10.039]
- 15 Kato T, Hikichi T, Nakamura J, Takasumi M, Hashimoto M, Kobashi R, Yanagita T, Takagi T, Suzuki R, Sugimoto M, Sato Y, Irie H, Okubo Y, Kobayakawa M, Ohira H. Usefulness of Endoscopic Ultrasound with the Jelly-Filling Method for Esophageal Varices. *Diagnostics (Basel)* 2021; **11** [PMID: 34574067 DOI: 10.3390/diagnostics11091726]
- 16 Ryan BM, Stockbrugger RW, Ryan JM. A pathophysiologic, gastroenterologic, and radiologic approach to the management of gastric varices. *Gastroenterology* 2004; **126**: 1175-1189 [PMID: 15057756 DOI: 10.1053/j.gastro.2004.01.058]
- 17 Trudeau W, Prindiville T. Endoscopic injection sclerosis in bleeding gastric varices. *Gastrointest Endosc* 1986; **32**: 264-268 [PMID: 3488937 DOI: 10.1016/s0016-5107(86)71843-9]
- 18 Ríos Castellanos E, Seron P, Gisbert JP, Bonfill Cosp X. Endoscopic injection of cyanoacrylate glue vs other endoscopic procedures for acute bleeding gastric varices in people with portal hypertension. *Cochrane Database Syst Rev* 2015; CD010180 [PMID: 25966446 DOI: 10.1002/14651858.CD010180.pub2]
- 19 Soehendra N, Nam VC, Grimm H, Kempeneers I. Endoscopic obliteration of large esophagogastric varices with bucrylate. *Endoscopy* 1986; **18**: 25-26 [PMID: 3512261 DOI: 10.1055/s-2007-1013014]
- 20 Boustière C, Dumas O, Jouffre C, Letard JC, Patouillard B, Etaix JP, Barthélémy C, Audigier JC. Endoscopic ultrasonography classification of gastric varices in patients with cirrhosis. Comparison with endoscopic findings. *J Hepatol* 1993; **19**: 268-272 [PMID: 8301060 DOI: 10.1016/s0168-8278(05)80581-1]
- 21 Iwase H, Suga S, Morise K, Kuroiwa A, Yamaguchi T, Horiuchi Y. Color Doppler endoscopic ultrasonography for the evaluation of gastric varices and endoscopic obliteration with cyanoacrylate glue. *Gastrointest Endosc* 1995; **41**: 150-154 [PMID: 7721004 DOI: 10.1016/s0016-5107(05)80599-1]
- 22 Sarin SK, Kumar A. Sclerosants for variceal sclerotherapy: a critical appraisal. *Am J Gastroenterol* 1990; **85**: 641-649 [PMID: 2191592]
- 23 Romero-Castro R, Pellicer-Bautista FJ, Jimenez-Saenz M, Marcos-Sanchez F, Caunedo-Alvarez A, Ortiz-Moyano C, Gomez-Parra M, Herreras-Gutierrez JM. EUS-guided injection of cyanoacrylate in perforating feeding veins in gastric

- varices: results in 5 cases. *Gastrointest Endosc* 2007; **66**: 402-407 [PMID: 17643723 DOI: 10.1016/j.gie.2007.03.008]
- 24 **Cameron R**, Binmoeller KF. Cyanoacrylate applications in the GI tract. *Gastrointest Endosc* 2013; **77**: 846-857 [PMID: 23540441 DOI: 10.1016/j.gie.2013.01.028]
 - 25 **Romero-Castro R**, Pellicer-Bautista F, Giovannini M, Marcos-Sánchez F, Caparros-Escudero C, Jiménez-Sáenz M, Gomez-Parra M, Arenzana-Seisdedos A, Leria-Yebenes V, Herreras-Gutiérrez JM. Endoscopic ultrasound (EUS)-guided coil embolization therapy in gastric varices. *Endoscopy* 2010; **42** Suppl 2: E35-E36 [PMID: 20073010 DOI: 10.1055/s-0029-1215261]
 - 26 **Romero-Castro R**, Ellrichmann M, Ortiz-Moyano C, Subtil-Inigo JC, Junquera-Florez F, Gornals JB, Repiso-Ortega A, Vila-Costas J, Marcos-Sanchez F, Muñoz-Navas M, Romero-Gomez M, Brullet-Benedi E, Romero-Vazquez J, Caunedo-Alvarez A, Pellicer-Bautista F, Herreras-Gutierrez JM, Fritscher-Ravens A. EUS-guided coil vs cyanoacrylate therapy for the treatment of gastric varices: a multicenter study (with videos). *Gastrointest Endosc* 2013; **78**: 711-721 [PMID: 23891417 DOI: 10.1016/j.gie.2013.05.009]
 - 27 **Bhat YM**, Weilert F, Fredrick RT, Kane SD, Shah JN, Hamerski CM, Binmoeller KF. EUS-guided treatment of gastric fundal varices with combined injection of coils and cyanoacrylate glue: a large U.S. experience over 6 years (with video). *Gastrointest Endosc* 2016; **83**: 1164-1172 [PMID: 26452992 DOI: 10.1016/j.gie.2015.09.040]
 - 28 **Kouanda A**, Binmoeller K, Hamerski C, Nett A, Bernabe J, Shah J, Bhat Y, Watson R. Safety and efficacy of EUS-guided coil and glue injection for the primary prophylaxis of gastric variceal hemorrhage. *Gastrointest Endosc* 2021; **94**: 291-296 [PMID: 33539908 DOI: 10.1016/j.gie.2021.01.025]
 - 29 **Robles-Medranda C**, Oleas R, Valero M, Puga-Tejada M, Baquerizo-Burgos J, Ospina J, Pitanga-Lukashok H. Endoscopic ultrasonography-guided deployment of embolization coils and cyanoacrylate injection in gastric varices vs coiling alone: a randomized trial. *Endoscopy* 2020; **52**: 268-275 [PMID: 32126576 DOI: 10.1055/a-1123-9054]
 - 30 **McCarty TR**, Bazarbashi AN, Hathorn KE, Thompson CC, Ryou M. Combination therapy vs monotherapy for EUS-guided management of gastric varices: A systematic review and meta-analysis. *Endosc Ultrasound* 2020; **9**: 6-15 [PMID: 31417066 DOI: 10.4103/eus.eus_37_19]
 - 31 **Robles-Medranda C**, Nebel JA, Puga-Tejada M, Oleas R, Baquerizo-Burgos J, Ospina-Arboleda J, Valero M, Pitanga-Lukashok H. Cost-effectiveness of endoscopic ultrasound-guided coils plus cyanoacrylate injection compared to endoscopic cyanoacrylate injection in the management of gastric varices. *World J Gastrointest Endosc* 2021; **13**: 13-23 [PMID: 33520103 DOI: 10.4253/wjge.v13.i1.13]
 - 32 **Mukkada RJ**, Antony R, Chooracken MJ, Francis JV, Chettupuzha AP, Mathew PG, Augustine P, Koshy A. Endoscopic ultrasound-guided coil or glue injection in post-cyanoacrylate gastric variceal re-bleed. *Indian J Gastroenterol* 2018; **37**: 153-159 [PMID: 29629510 DOI: 10.1007/s12664-018-0844-y]
 - 33 **Lôbo MRA**, Chaves DM, DE Moura DTH, Ribeiro IB, Ikari E, DE Moura EGH. Safety and efficacy of EUS-guided coil plus cyanoacrylate versus conventional cyanoacrylate technique in the treatment of gastric varices: a randomized controlled trial. *Arq Gastroenterol* 2019; **56**: 99-105 [PMID: 31141079 DOI: 10.1590/S0004-2803.201900000-08]
 - 34 **Samanta J**, Nabi Z, Facciorusso A, Dhar J, Akbar W, Birda CL, Mangiavillano B, Auriemma F, Lakhtakia S, Kochhar R, Duvvur NR. EUS-guided treatment of gastric fundal varices with coil and glue injection is safe and fares better than endoscopic glue injection: an international mutli-centre experience. *Gastrointest Endosc* 2022; **95**: AB518-AB519 [DOI: 10.1016/j.gie.2022.04.1323]
 - 35 **Ramchandani M**. Safety and efficacy of endoscopic conventional cyanoacrylate glue vs EUS-guided coil plus cyanoacrylate technique in the treatment of gastric varices: a randomized controlled trial (glue) (NCT05038319). Available from: <https://clinicaltrials.gov/ct2/show/NCT05038319>
 - 36 **Frost JW**, Hebbar S. EUS-guided thrombin injection for management of gastric fundal varices. *Endosc Int Open* 2018; **6**: E664-E668 [PMID: 29868631 DOI: 10.1055/a-0599-0440]
 - 37 **Bazarbashi AN**, Wang TJ, Thompson CC, Ryou M. Endoscopic ultrasound-guided treatment of gastric varices with coil embolization and absorbable hemostatic gelatin sponge: a novel alternative to cyanoacrylate. *Endosc Int Open* 2020; **8**: E221-E227 [PMID: 32010757 DOI: 10.1055/a-1027-6708]
 - 38 **Irisawa A**, Shibukawa G, Hoshi K, Yamabe A, Sato A, Maki T, Yoshida Y, Yamamoto S, Obara K. Endoscopic ultrasound-guided coil deployment with sclerotherapy for isolated gastric varices: Case series of feasibility, safety, and long-term follow-up. *Dig Endosc* 2020; **32**: 1100-1104 [PMID: 32147871 DOI: 10.1111/den.13666]
 - 39 **Lee YT**, Chan FK, Ng EK, Leung VK, Law KB, Yung MY, Chung SC, Sung JJ. EUS-guided injection of cyanoacrylate for bleeding gastric varices. *Gastrointest Endosc* 2000; **52**: 168-174 [PMID: 10922086 DOI: 10.1067/mge.2000.107911]
 - 40 **Gubler C**, Bauerfeind P. Safe and successful endoscopic initial treatment and long-term eradication of gastric varices by endoscopic ultrasound-guided Histoacryl (N-butyl-2-cyanoacrylate) injection. *Scand J Gastroenterol* 2014; **49**: 1136-1142 [PMID: 24947448 DOI: 10.3109/00365521.2014.929171]
 - 41 **Khoury T**, Massarwa M, Daher S, Benson AA, Hazou W, Israeli E, Jacob H, Epstein J, Safadi R. Endoscopic Ultrasound-Guided Angiotherapy for Gastric Varices: A Single Center Experience. *Hepatol Commun* 2019; **3**: 207-212 [PMID: 30766958 DOI: 10.1002/hep4.1289]
 - 42 **Binmoeller KF**, Weilert F, Shah JN, Kim J. EUS-guided transesophageal treatment of gastric fundal varices with combined coiling and cyanoacrylate glue injection (with videos). *Gastrointest Endosc* 2011; **74**: 1019-1025 [PMID: 21889139 DOI: 10.1016/j.gie.2011.06.030]
 - 43 **Koziel S**, Pawlak K, Błaszczyk Ł, Jagielski M, Wiechowska-Kozłowska A. Endoscopic Ultrasound-Guided Treatment of Gastric Varices Using Coils and Cyanoacrylate Glue Injections: Results after 1 Year of Experience. *J Clin Med* 2019; **8** [PMID: 31731504 DOI: 10.3390/jcm8111786]
 - 44 **Robles-Medranda C**, Valero M, Nebel JA, de Brito Junior SR, Puga-Tejada M, Ospina J, Muñoz-Jurado G, Pitanga-Lukashok H. Endoscopic-ultrasound-guided coil and cyanoacrylate embolization for gastric varices and the roles of endoscopic Doppler and endosonographic varicealography in vascular targeting. *Dig Endosc* 2019; **31**: 283-290 [PMID: 30449033 DOI: 10.1111/den.13305]
 - 45 **Bick BL**, Al-Haddad M, Liangpunsakul S, Ghabril MS, DeWitt JM. EUS-guided fine needle injection is superior to direct endoscopic injection of 2-octyl cyanoacrylate for the treatment of gastric variceal bleeding. *Surg Endosc* 2019; **33**: 1837-

- 1845 [PMID: 30259158 DOI: 10.1007/s00464-018-6462-z]
- 46 **Bazarbashi AN**, Wang TJ, Jirapinyo P, Thompson CC, Ryou M. Endoscopic Ultrasound-Guided Coil Embolization With Absorbable Gelatin Sponge Appears Superior to Traditional Cyanoacrylate Injection for the Treatment of Gastric Varices. *Clin Transl Gastroenterol* 2020; **11**: e00175 [PMID: 32677809 DOI: 10.14309/ctg.0000000000000175]
 - 47 **Seven G**, Musayeva G, Seven OO, Herdan E, Ince AT, Senturk H. Comparison of endoscopic ultrasound-guided coil deployment with and without cyanoacrylate injection for gastric varices. *Arab J Gastroenterol* 2022; **23**: 115-119 [PMID: 35525707 DOI: 10.1016/j.ajg.2022.04.004]
 - 48 **Zhang ZG**, Li Z, Yang Y, Cheng B, Yan W, Yuan Y, Chen M, Hou W, Yang M, Chen Q. Hemodynamic effect through a novel endoscopic intervention in management of varices and hypersplenism (with video). *Gastrointest Endosc* 2022; **95**: 172-183.e2 [PMID: 34224735 DOI: 10.1016/j.gie.2021.06.029]
 - 49 **Schiano TD**, Adrain AL, Vega KJ, Liu JB, Black M, Miller LS. High-resolution endoluminal sonography assessment of the hematoctytic spots of esophageal varices. *Gastrointest Endosc* 1999; **49**: 424-427 [PMID: 10202053 DOI: 10.1016/s0016-5107(99)70037-4]
 - 50 **Caletti G**, Brocchi E, Baraldini M, Ferrari A, Gibilaro M, Barbara L. Assessment of portal hypertension by endoscopic ultrasonography. *Gastrointest Endosc* 1990; **36**: S21-S27 [PMID: 2184082 DOI: 10.1016/s0016-5107(90)71011-5]
 - 51 **Wiechowska-Kozłowska A**, Zasada K, Milkiewicz M, Milkiewicz P. Correlation between Endosonographic and Doppler Ultrasound Features of Portal Hypertension in Patients with Cirrhosis. *Gastroenterol Res Pract* 2012; **2012**: 395345 [PMID: 22114590 DOI: 10.1155/2012/395345]
 - 52 **Miller ES**, Kim JK, Gandehok J, Hara M, Dai Q, Malik A, Miller A, Miller L. A new device for measuring esophageal variceal pressure. *Gastrointest Endosc* 2002; **56**: 284-291 [PMID: 12145614 DOI: 10.1016/s0016-5107(02)70195-8]
 - 53 **Carneiro FO**, Retes FA, Matuguma SE, Albers DV, Chaves DM, Dos Santos ME, Herman P, Chaib E, Sakai P, Carneiro D, Albuquerque LA, Maluf Filho F. Role of EUS evaluation after endoscopic eradication of esophageal varices with band ligation. *Gastrointest Endosc* 2016; **84**: 400-407 [PMID: 26905936 DOI: 10.1016/j.gie.2016.02.006]
 - 54 **Kuramochi A**, Imazu H, Kakutani H, Uchiyama Y, Hino S, Urashima M. Color Doppler endoscopic ultrasonography in identifying groups at a high-risk of recurrence of esophageal varices after endoscopic treatment. *J Gastroenterol* 2007; **42**: 219-224 [PMID: 17380280 DOI: 10.1007/s00535-006-1992-x]
 - 55 **Miller L**, Banson FL, Bazir K, Korimilli A, Liu Ji, Dewan R, Wolfson M, Panganamamula KV, Carrasquillo J, Schwartz J, Chaker AE, Black M. Risk of esophageal variceal bleeding based on endoscopic ultrasound evaluation of the sum of esophageal variceal cross-sectional surface area. *Am J Gastroenterol* 2003; **98**: 454-459 [PMID: 12591068 DOI: 10.1111/j.1572-0241.2003.07224.x]
 - 56 **Liao WC**, Chen PH, Hou MC, Chang CJ, Su CW, Lin HC, Lee FY. Endoscopic ultrasonography assessment of para-esophageal varices predicts efficacy of propranolol in preventing recurrence of esophageal varices. *J Gastroenterol* 2015; **50**: 342-349 [PMID: 24908097 DOI: 10.1007/s00535-014-0970-y]
 - 57 **Sarin SK**, Kumar CKN. Ectopic varices. *Clin Liver Dis (Hoboken)* 2012; **1**: 167-172 [PMID: 31186880 DOI: 10.1002/cld.95]
 - 58 **Watanabe N**, Toyonaga A, Kojima S, Takashimizu S, Oho K, Kokubu S, Nakamura K, Hasumi A, Murashima N, Tajiri T. Current status of ectopic varices in Japan: Results of a survey by the Japan Society for Portal Hypertension. *Hepatol Res* 2010; **40**: 763-776 [PMID: 20649816 DOI: 10.1111/j.1872-034X.2010.00690.x]
 - 59 **Lienhart I**, Lesne A, Couchonnal E, Rivory J, Sosa-Valencia L, Ponchon T, Pioche M. Massive duodenal variceal bleed: endoscopic ultrasonography of ruptured varix and successful endoscopic clipping treatment. *Endoscopy* 2016; **48** Suppl 1 UCTN: E80-E81 [PMID: 26951472 DOI: 10.1055/s-0042-102959]
 - 60 **So H**, Park do H, Jung K, Ko HK. Successful Endoscopic Ultrasound-Guided Coil Embolization For Severe Duodenal Bleeding. *Am J Gastroenterol* 2016; **111**: 925 [PMID: 27356819 DOI: 10.1038/ajg.2016.73]
 - 61 **Kimura G**, Hashimoto Y, Ikeda M. Successful obliteration of bleeding duodenal varices by EUS-guided injection of N-butyl-2-cyanoacrylate. *VideoGIE* 2017; **2**: 317-319 [PMID: 30027135 DOI: 10.1016/j.vgie.2017.08.001]
 - 62 **Hosking SW**, Smart HL, Johnson AG, Triger DR. Anorectal varices, haemorrhoids, and portal hypertension. *Lancet* 1989; **1**: 349-352 [PMID: 2563507 DOI: 10.1016/s0140-6736(89)91724-8]
 - 63 **Chawla Y**, Dilawari JB. Anorectal varices--their frequency in cirrhotic and non-cirrhotic portal hypertension. *Gut* 1991; **32**: 309-311 [PMID: 2013427 DOI: 10.1136/gut.32.3.309]
 - 64 **Dhiman RK**, Saraswat VA, Choudhuri G, Sharma BC, Pandey R, Naik SR. Endosonographic, endoscopic, and histologic evaluation of alterations in the rectal venous system in patients with portal hypertension. *Gastrointest Endosc* 1999; **49**: 218-227 [PMID: 9925702 DOI: 10.1016/s0016-5107(99)70490-6]
 - 65 **Dhiman RK**, Choudhuri G, Saraswat VA, Mukhopadhyay DK, Khan EM, Pandey R, Naik SR. Endoscopic ultrasonographic evaluation of the rectum in cirrhotic portal hypertension. *Gastrointest Endosc* 1993; **39**: 635-640 [PMID: 8224684 DOI: 10.1016/s0016-5107(93)70214-x]
 - 66 **Messallam AA**, Kumbhari V, Saxena P, Azola AM, Kalloo AN, Khashab MA. Large bleeding rectal varices treated with endoscopic ultrasound-guided coiling and cyanoacrylate injection. *Endoscopy* 2014; **46** Suppl 1 UCTN: E28-E29 [PMID: 24523167 DOI: 10.1055/s-0033-1359136]
 - 67 **Sharma M**, Somasundaram A. Massive lower GI bleed from an endoscopically inevident rectal varices: diagnosis and management by EUS (with videos). *Gastrointest Endosc* 2010; **72**: 1106-1108 [PMID: 20579995 DOI: 10.1016/j.gie.2010.02.054]
 - 68 **Tabibian JH**, Abu Dayyeh BK, Gores GJ, Levy MJ. A novel, minimally invasive technique for management of peristomal varices. *Hepatology* 2016; **63**: 1398-1400 [PMID: 26044445 DOI: 10.1002/hep.27925]
 - 69 **Tsynman DN**, DeCross AJ, Maliakkal B, Ciufo N, Ullah A, Kaul V. Novel use of EUS to successfully treat bleeding parastomal varices with N-butyl-2-cyanoacrylate. *Gastrointest Endosc* 2014; **79**: 1007-8; discussion 1008 [PMID: 24556054 DOI: 10.1016/j.gie.2014.01.004]
 - 70 **Samanta J**, Dhar J, Bharath P, Kumar A, Bhujade H, Gupta P, Kochhar R. Bleeding parastomal varices: endoscopic ultrasound to the rescue. *Endoscopy* 2022; **54**: OP279V [DOI: 10.1055/s-0042-1744842]
 - 71 **Levy MJ**, Wong Kee Song LM, Kendrick ML, Misra S, Gostout CJ. EUS-guided coil embolization for refractory ectopic

- variceal bleeding (with videos). *Gastrointest Endosc* 2008; **67**: 572-574 [PMID: [17997404](#) DOI: [10.1016/j.gie.2007.06.063](#)]
- 72 **Kinzel J**, Pichetshote N, Dredar S, Aslanian H, Nagar A. Bleeding from a duodenal varix: a unique case of variceal hemostasis achieved using EUS-guided placement of an embolization coil and cyanoacrylate. *J Clin Gastroenterol* 2014; **48**: 362-364 [PMID: [24518801](#) DOI: [10.1097/MCG.0000000000000004](#)]
 - 73 **Fujii-Lau LL**, Law R, Wong Kee Song LM, Gostout CJ, Kamath PS, Levy MJ. Endoscopic ultrasound (EUS)-guided coil injection therapy of esophagogastric and ectopic varices. *Surg Endosc* 2016; **30**: 1396-1404 [PMID: [26139494](#) DOI: [10.1007/s00464-015-4342-3](#)]
 - 74 **Bahdi F**, George R, Patel K. EUS-guided coiling and cyanoacrylate injection of ectopic duodenal varices. *VideoGIE* 2021; **6**: 35-37 [PMID: [33490754](#) DOI: [10.1016/j.vgie.2020.09.007](#)]
 - 75 **Mukkada RJ**, Mathew PG, Francis Jose V, Paul Chettupuzha A, Antony R, Koshy A. EUS-guided coiling of rectal varices. *VideoGIE* 2017; **2**: 208-210 [PMID: [30175307](#) DOI: [10.1016/j.vgie.2017.05.005](#)]
 - 76 **Bazarbashi AN**, Thompson CC, Ryou M. Targeting the perforator vein: EUS-guided coil embolization for the treatment of bleeding rectal varices. *VideoGIE* 2020; **5**: 434-436 [PMID: [32954109](#) DOI: [10.1016/j.vgie.2020.05.008](#)]
 - 77 **Philips CA**, Augustine P. Endoscopic Ultrasound-Guided Management of Bleeding Rectal Varices. *ACG Case Rep J* 2017; **4**: e101 [PMID: [28879206](#) DOI: [10.14309/crj.2017.101](#)]
 - 78 **Weilert F**, Shah JN, Marson FP, Binmoeller KF. EUS-guided coil and glue for bleeding rectal varix. *Gastrointest Endosc* 2012; **76**: 915-916 [PMID: [22172480](#) DOI: [10.1016/j.gie.2011.09.027](#)]
 - 79 **Jana T**, Mistry T, Singhal S. Endoscopic ultrasound-guided hemostasis of rectal varices. *Endoscopy* 2017; **49**: E136-E137 [PMID: [28329883](#) DOI: [10.1055/s-0043-104521](#)]
 - 80 **Lin HJ**, Hsieh YH, Tseng GY, Perng CL, Chang FY, Lee SD. A prospective, randomized trial of large- vs small-volume endoscopic injection of epinephrine for peptic ulcer bleeding. *Gastrointest Endosc* 2002; **55**: 615-619 [PMID: [11979239](#) DOI: [10.1067/mge.2002.123271](#)]
 - 81 **Kanai M**, Hamada A, Endo Y, Takeda Y, Yamakawa M, Nishikawa H, Torii A. Efficacy of argon plasma coagulation in nonvariceal upper gastrointestinal bleeding. *Endoscopy* 2004; **36**: 1085-1088 [PMID: [15578299](#) DOI: [10.1055/s-2004-826033](#)]
 - 82 **Han C**, Ling X, Liu J, Lin R, Ding Z. Management of non-variceal upper gastrointestinal bleeding: role of endoscopic ultrasound-guided treatments. *Therap Adv Gastroenterol* 2022; **15**: 17562848211056148 [PMID: [35126666](#) DOI: [10.1177/17562848211056148](#)]
 - 83 **De Angelis CG**, Cortegoso Valdivia P, Rizza S, Venezia L, Rizzi F, Gesualdo M, Saracco GM, Pellicano R. Endoscopic Ultrasound-Guided Treatments for Non-Variceal Upper GI Bleeding: A Review of the Literature. *J Clin Med* 2020; **9** [PMID: [32245209](#) DOI: [10.3390/jcm9030866](#)]
 - 84 **Mallick B**, Malik S, Gupta P, Gorski U, Kochhar S, Gupta V, Yadav TD, Dhaka N, Sinha SK, Kochhar R. Arterial pseudoaneurysms in acute and chronic pancreatitis: Clinical profile and outcome. *JGH Open* 2019; **3**: 126-132 [PMID: [31061887](#) DOI: [10.1002/jgh3.12116](#)]
 - 85 **Sagar S**, Soundarajan R, Gupta P, Praveen Kumar M, Samanta J, Sharma V, Kochhar R. Efficacy of endovascular embolization of arterial pseudoaneurysms in pancreatitis: A systematic review and meta-analysis. *Pancreatol* 2021; **21**: 46-58 [PMID: [33303372](#) DOI: [10.1016/j.pan.2020.11.017](#)]
 - 86 **Roach H**, Roberts SA, Salter R, Williams IM, Wood AM. Endoscopic ultrasound-guided thrombin injection for the treatment of pancreatic pseudoaneurysm. *Endoscopy* 2005; **37**: 876-878 [PMID: [16116543](#) DOI: [10.1055/s-2005-870201](#)]
 - 87 **Gonzalez JM**, Ezzedine S, Vitton V, Grimaud JC, Barthet M. Endoscopic ultrasound treatment of vascular complications in acute pancreatitis. *Endoscopy* 2009; **41**: 721-724 [PMID: [19670142](#) DOI: [10.1055/s-0029-1214874](#)]
 - 88 **Robb PM**, Yeaton P, Bishop T, Wessinger J. Endoscopic Ultrasound Guided Embolization of a Pancreatic Pseudoaneurysm. *Gastroenterology Res* 2012; **5**: 239-241 [PMID: [27785215](#) DOI: [10.4021/gr500w](#)]
 - 89 **Rai P**, Bhera B, Sharma M. First report of successful treatment of splenic artery pseudoaneurysm with endoscopic ultrasound-guided coil and glue. *Endoscopy* 2017; **49**: E179-E180 [PMID: [28558403](#) DOI: [10.1055/s-0043-109790](#)]
 - 90 **Shah J**, Samanta J, Muktesh G, Kumar N, Gupta P, Kumar KH, Kochhar R. Primary EUS-guided therapy of a giant visceral artery pseudoaneurysm: Expanding horizons (with video). *Endosc Ultrasound* 2021; **10**: 307-308 [PMID: [33586691](#) DOI: [10.4103/EUS-D-20-00210](#)]
 - 91 **Gamanagatti S**, Thingujam U, Garg P, Nongthombam S, Dash NR. Endoscopic ultrasound guided thrombin injection of angiographically occult pancreatitis associated visceral artery pseudoaneurysms: Case series. *World J Gastrointest Endosc* 2015; **7**: 1107-1113 [PMID: [26421108](#) DOI: [10.4253/wjge.v7.i13.1107](#)]
 - 92 **Jhajharia A**, Wanjari S, Ashdhir P, Sharma D, Pokharna R, Nijhawan S. Endoscopic ultrasound-guided thrombin injection for management of visceral artery pseudoaneurysm: A novel approach. *Indian J Gastroenterol* 2018; **37**: 271-275 [PMID: [29971689](#) DOI: [10.1007/s12664-018-0865-6](#)]
 - 93 **Rai P**, Kc H, Goel A, Aggarwal R, Sharma M. Endoscopic ultrasound-guided coil and glue for treatment of splenic artery pseudo-aneurysm: new kid on the block! *Endosc Int Open* 2018; **6**: E821-E825 [PMID: [29978000](#) DOI: [10.1055/a-0608-4402](#)]
 - 94 **Maharshi S**, Sharma SS, Sharma D, Sapra B, Nijhawan S. Endoscopic ultrasound-guided thrombin injection, a management approach for visceral artery pseudoaneurysms. *Endosc Int Open* 2020; **8**: E407-E412 [PMID: [32118114](#) DOI: [10.1055/a-1070-9168](#)]
 - 95 **Samanta J**, Dhar J, Birda CL, Mandavdhare HS, Gupta P, Gorski U, Kumar KH, Gupta V, Kochhar R. Endoscopic ultrasound-guided angiotherapy using coil and cyanoacrylate glue for the management of visceral artery pseudoaneurysms in patients of pancreatitis: a safe and effective technique. *Endoscopy* 2022; **54**: OP269 [DOI: [10.1055/s-0042-1744832](#)]
 - 96 **Fockens P**, Meenan J, van Dullemen HM, Bolwerk CJ, Tytgat GN. Dieulafoy's disease: endosonographic detection and endosonography-guided treatment. *Gastrointest Endosc* 1996; **44**: 437-442 [PMID: [8905365](#) DOI: [10.1016/s0016-5107\(96\)70096-2](#)]
 - 97 **Levy MJ**, Wong Kee Song LM, Farnell MB, Misra S, Sarr MG, Gostout CJ. Endoscopic ultrasound (EUS)-guided angiotherapy of refractory gastrointestinal bleeding. *Am J Gastroenterol* 2008; **103**: 352-359 [PMID: [17986314](#) DOI: [10.1016/j.amjgastro.2007.06.063](#)]

- 10.1111/j.1572-0241.2007.01616.x]
- 98 **Law R**, Fujii-Lau L, Wong Kee Song LM, Gostout CJ, Kamath PS, Abu Dayyeh BK, Gleeson FC, Rajan E, Topazian MD, Levy MJ. Efficacy of endoscopic ultrasound-guided hemostatic interventions for resistant nonvariceal bleeding. *Clin Gastroenterol Hepatol* 2015; **13**: 808-12.e1 [PMID: 25245627 DOI: 10.1016/j.cgh.2014.09.030]
 - 99 **Samarasena JB**, Chang KJ. Endoscopic Ultrasound-Guided Interventions for the Measurement and Treatment of Portal Hypertension. *Gastrointest Endosc Clin N Am* 2019; **29**: 311-320 [PMID: 30846155 DOI: 10.1016/j.gie.2018.12.004]
 - 100 **Giday SA**, Clarke JO, Buscaglia JM, Shin EJ, Ko CW, Magno P, Kantsevoy SV. EUS-guided portal vein catheterization: a promising novel approach for portal angiography and portal vein pressure measurements. *Gastrointest Endosc* 2008; **67**: 338-342 [PMID: 18226699 DOI: 10.1016/j.gie.2007.08.037]
 - 101 **Lai L**, Poneros J, Santilli J, Brugge W. EUS-guided portal vein catheterization and pressure measurement in an animal model: a pilot study of feasibility. *Gastrointest Endosc* 2004; **59**: 280-283 [PMID: 14745408 DOI: 10.1016/s0016-5107(03)02544-6]
 - 102 **Magno P**, Ko CW, Buscaglia JM, Giday SA, Jagannath SB, Clarke JO, Shin EJ, Kantsevoy SV. EUS-guided angiography: a novel approach to diagnostic and therapeutic interventions in the vascular system. *Gastrointest Endosc* 2007; **66**: 587-591 [PMID: 17725951 DOI: 10.1016/j.gie.2007.01.011]
 - 103 **Giday SA**, Ko CW, Clarke JO, Shin EJ, Magno P, Jagannath SB, Buscaglia JM, Kantsevoy SV. EUS-guided portal vein carbon dioxide angiography: a pilot study in a porcine model. *Gastrointest Endosc* 2007; **66**: 814-819 [PMID: 17905028 DOI: 10.1016/j.gie.2007.05.056]
 - 104 **D'Amico G**, Garcia-Pagan JC, Luca A, Bosch J. Hepatic vein pressure gradient reduction and prevention of variceal bleeding in cirrhosis: a systematic review. *Gastroenterology* 2006; **131**: 1611-1624 [PMID: 17101332 DOI: 10.1053/j.gastro.2006.09.013]
 - 105 **Huang JY**, Samarasena JB, Tsujino T, Lee J, Hu KQ, McLaren CE, Chen WP, Chang KJ. EUS-guided portal pressure gradient measurement with a simple novel device: a human pilot study. *Gastrointest Endosc* 2017; **85**: 996-1001 [PMID: 27693644 DOI: 10.1016/j.gie.2016.09.026]
 - 106 **Fujii-Lau LL**, Leise MD, Kamath PS, Gleeson FC, Levy MJ. Endoscopic ultrasound-guided portal-systemic pressure gradient measurement. *Endoscopy* 2014; **46** Suppl 1 UCTN: E654-E656 [PMID: 25526410 DOI: 10.1055/s-0034-1390845]
 - 107 **Zhang W**, Peng C, Zhang S, Huang S, Shen S, Xu G, Zhang F, Xiao J, Zhang M, Zhuge Y, Wang L, Zou X, Lv Y. EUS-guided portal pressure gradient measurement in patients with acute or subacute portal hypertension. *Gastrointest Endosc* 2021; **93**: 565-572 [PMID: 32615178 DOI: 10.1016/j.gie.2020.06.065]
 - 108 **Hajifathalian K**, Westerveld D, Kaplan A, Dawod E, Herr A, Ianelli M, Saggese A, Kumar S, Fortune BE, Sharaiha RZ. Simultaneous EUS-guided portosystemic pressure measurement and liver biopsy sampling correlate with clinically meaningful outcomes. *Gastrointest Endosc* 2022; **95**: 703-710 [PMID: 34890694 DOI: 10.1016/j.gie.2021.11.037]
 - 109 **Shah SL**, Dawod Q, Kumar S, Fortune B, Sharaiha RZ. "One stop" liver-focused endoscopy: EUS-guided portal pressure gradient measurement technique. *VideoGIE* 2020; **5**: 658-659 [PMID: 33319134 DOI: 10.1016/j.vgie.2020.08.006]
 - 110 **Choi AY**, Kolb J, Shah S, Chahine A, Hashimoto R, Patel A, Tsujino T, Huang J, Hu KQ, Chang K, Samarasena JB. Endoscopic ultrasound-guided portal pressure gradient with liver biopsy: 6 years of endo-hepatology in practice. *J Gastroenterol Hepatol* 2022; **37**: 1373-1379 [PMID: 35513894 DOI: 10.1111/jgh.15875]
 - 111 **Choi AY**, Chang KJ, Samarasena JB, Lee JG, Li X, Guo W, Chandan VS, Hu KQ. Endoscopic Ultrasound-Guided Porto-systemic Pressure Gradient Measurement Correlates with Histological Hepatic Fibrosis. *Dig Dis Sci* 2022; **67**: 5685-5692 [PMID: 35279787 DOI: 10.1007/s10620-022-07418-7]
 - 112 **Buscaglia JM**, Dray X, Shin EJ, Magno P, Chmura KM, Surti VC, Dillon TE, Ducharme RW, Donatelli G, Thuluvath PJ, Giday SA, Kantsevoy SV. A new alternative for a transjugular intrahepatic portosystemic shunt: EUS-guided creation of an intrahepatic portosystemic shunt (with video). *Gastrointest Endosc* 2009; **69**: 941-947 [PMID: 19327481 DOI: 10.1016/j.gie.2008.09.051]
 - 113 **Binmoeller KF**, Shah JN. Sa1428 EUS-guided transgastric intrahepatic portosystemic shunt using the axios stent. *Gastrointest Endosc* 2011; **73**: AB167 [DOI: 10.1016/j.gie.2011.03.162]
 - 114 **Schulman AR**, Ryou M, Aihara H, Abidi W, Chiang A, Jirapinyo P, Sakr A, Ajeje E, Ryan MB, Thompson CC. EUS-guided intrahepatic portosystemic shunt with direct portal pressure measurements: a novel alternative to transjugular intrahepatic portosystemic shunting. *Gastrointest Endosc* 2017; **85**: 243-247 [PMID: 27468858 DOI: 10.1016/j.gie.2016.07.041]
 - 115 **Poincloux L**, Chabrot P, Mulliez A, Genes J, Boyer L, Abergel A. Interventional endoscopic ultrasound: A new promising way for intrahepatic portosystemic shunt with portal pressure gradient. *Endosc Ultrasound* 2017; **6**: 394-401 [PMID: 29251274 DOI: 10.4103/eus.eus.42_17]
 - 116 **Catenacci DV**, Chapman CG, Xu P, Koons A, Konda VJ, Siddiqui UD, Waxman I. Acquisition of Portal Venous Circulating Tumor Cells From Patients With Pancreaticobiliary Cancers by Endoscopic Ultrasound. *Gastroenterology* 2015; **149**: 1794-1803.e4 [PMID: 26341722 DOI: 10.1053/j.gastro.2015.08.050]
 - 117 **Zhang Y**, Su H, Wang H, Xu C, Zhou S, Zhao J, Shen S, Xu G, Wang L, Zou X, Zhang S, Lv Y. Endoscopic Ultrasound-Guided Acquisition of Portal Venous Circulating Tumor Cells as a Potential Diagnostic and Prognostic Tool for Pancreatic Cancer. *Cancer Manag Res* 2021; **13**: 7649-7661 [PMID: 34675662 DOI: 10.2147/CMAR.S330473]
 - 118 **Rustagi T**, Gleeson FC, Chari ST, Abu Dayyeh BK, Farnell MB, Iyer PG, Kendrick ML, Pearson RK, Petersen BT, Rajan E, Topazian MD, Truty MJ, Vege SS, Wang KK, Levy MJ. Remote malignant intravascular thrombi: EUS-guided FNA diagnosis and impact on cancer staging. *Gastrointest Endosc* 2017; **86**: 150-155 [PMID: 27773725 DOI: 10.1016/j.gie.2016.10.025]
 - 119 **Lai R**, Stephens V, Bardales R. Diagnosis and staging of hepatocellular carcinoma by EUS-FNA of a portal vein thrombus. *Gastrointest Endosc* 2004; **59**: 574-577 [PMID: 15044903 DOI: 10.1016/s0016-5107(04)00007-0]
 - 120 **Storch I**, Gomez C, Contreras F, Schiff E, Ribeiro A. Hepatocellular carcinoma (HCC) with portal vein invasion, masquerading as pancreatic mass, diagnosed by endoscopic ultrasound-guided fine needle aspiration (EUS-FNA). *Dig Dis Sci* 2007; **52**: 789-791 [PMID: 17268833 DOI: 10.1007/s10620-006-9325-8]

- 121 **Michael H**, Lenza C, Gupta M, Katz DS. Endoscopic Ultrasound -guided Fine-Needle Aspiration of a Portal Vein Thrombus to Aid in the Diagnosis and Staging of Hepatocellular Carcinoma. *Gastroenterol Hepatol (N Y)* 2011; **7**: 124-129 [PMID: [21475421](#)]
- 122 **Moreno M**, Gimeno-García AZ, Corriente MM, Nicolás-Pérez D, Brito-García A, García-Castro C, Quintero E. EUS-FNA of a portal vein thrombosis in a patient with a hidden hepatocellular carcinoma: confirmation technique after contrast-enhanced ultrasound. *Endoscopy* 2014; **46** Suppl 1 UCTN: E590-E591 [PMID: [25502254](#) DOI: [10.1055/s-0034-1390734](#)]
- 123 **Faigel DO**, Lake DF, Landreth TL, Kelman CC, Marler RJ. EUS-guided portal injection chemotherapy for treatment of hepatic metastases: feasibility in the acute porcine model. *Gastrointest Endosc* 2016; **83**: 444-446 [PMID: [26358330](#) DOI: [10.1016/j.gie.2015.08.064](#)]
- 124 **Faigel D**, Lake D, Landreth T, Kelman C, Marler R. Endoscopic ultrasonography-guided portal injection chemotherapy for hepatic metastases. *Endosc Ultrasound* 2014; **3**: S1 [PMID: [26425503](#)]
- 125 **Loffroy R**, Favelier S, Chevallier O, Estivalet L, Genson PY, Pottecher P, Gehin S, Krausé D, Cercueil JP. Preoperative portal vein embolization in liver cancer: indications, techniques and outcomes. *Quant Imaging Med Surg* 2015; **5**: 730-739 [PMID: [26682142](#) DOI: [10.3978/j.issn.2223-4292.2015.10.04](#)]
- 126 **Matthes K**, Sahani D, Holalkere NS, Mino-Kenudson M, Brugge WR. Feasibility of endoscopic ultrasound-guided portal vein embolization with Enteryx. *Acta Gastroenterol Belg* 2005; **68**: 412-415 [PMID: [16432991](#)]
- 127 **Park TY**, Seo DW, Kang HJ, Song TJ, Park DH, Lee SS, Lee SK, Kim MH. Feasibility and safety of EUS-guided selective portal vein embolization with a coil and cyanoacrylate in a live porcine model. *Endosc Ultrasound* 2018; **7**: 389-394 [PMID: [30246708](#) DOI: [10.4103/eus.eus_18_18](#)]
- 128 **Park TY**, Seo DW, Kang HJ, Cho MK, Song TJ, Park DH, Lee SS, Lee SK, Kim MH. Endoscopic ultrasonography-guided placement of a transhepatic portal vein stent in a live porcine model. *Endosc Ultrasound* 2016; **5**: 315-319 [PMID: [27803904](#) DOI: [10.4103/2303-9027.191611](#)]
- 129 **Fritscher-Ravens A**, Ganbari A, Mosse CA, Swain P, Koehler P, Patel K. Transesophageal endoscopic ultrasound-guided access to the heart. *Endoscopy* 2007; **39**: 385-389 [PMID: [17516342](#) DOI: [10.1055/s-2007-966440](#)]
- 130 **Romero-Castro R**, Rios-Martin JJ, Gallego-Garcia de Vinuesa P, Castro-Fernandez AJ, Marques-Asin FJ, Caparros-Escudero C, Pellicer-Bautista F, Herrerias-Gutierrez JM. Pericardial tumor diagnosed by EUS-guided FNA (with video). *Gastrointest Endosc* 2009; **69**: 562-563 [PMID: [19152882](#) DOI: [10.1016/j.gie.2008.09.038](#)]
- 131 **Haja A**, Lakhtakia S, Sekaran A, Reddy P, Shah S, Pratap A, Reddy N. Cardiac sarcoma diagnosed with EUS-FNB. *Endosc Int Open* 2021; **9**: E152-E153 [PMID: [33532552](#) DOI: [10.1055/a-1268-7675](#)]
- 132 **Gornals JB**, de la Hera M, de Albert M, Claver E, Catala I. EUS cardiac puncture-guided right atrial tumor. *Gastrointest Endosc* 2015; **82**: 165 [PMID: [25887722](#) DOI: [10.1016/j.gie.2015.01.046](#)]
- 133 **Larghi A**, Stobinski M, Galasso D, Amato A, Familiari P, Costamagna G. EUS-guided drainage of a pericardial cyst: closer to the heart (with video). *Gastrointest Endosc* 2009; **70**: 1273-1274 [PMID: [19608180](#) DOI: [10.1016/j.gie.2009.05.006](#)]
- 134 **Somani P**, Talele R, Sharma M. Endoscopic Ultrasound-Guided Thrombolysis of Pulmonary Artery Thrombus and Mesenteric Vein Thrombus. *Am J Gastroenterol* 2019; **114**: 379 [PMID: [30840604](#) DOI: [10.14309/ajg.000000000000139](#)]



Published by **Baishideng Publishing Group Inc**
7041 Koll Center Parkway, Suite 160, Pleasanton, CA 94566, USA

Telephone: +1-925-3991568

E-mail: bpgoffice@wjgnet.com

Help Desk: <https://www.f6publishing.com/helpdesk>

<https://www.wjgnet.com>

