

# World Journal of *Gastrointestinal Endoscopy*

*World J Gastrointest Endosc* 2023 July 16; 15(7): 491-517



**MINIREVIEWS**

- 491 Strategies to manage the difficult colonoscopy  
*Wei MT, Friedland S*
- 496 Review of oral and pharyngolaryngeal benign lesions detected during esophagogastroduodenoscopy  
*Iwamuro M, Hamada K, Kawano S, Kawahara Y, Otsuka M*

**SYSTEMATIC REVIEWS**

- 510 Candy cane syndrome: A systematic review  
*Rio-Tinto R, Canena J, Devière J*

**ABOUT COVER**

Editorial Board Member of *World Journal of Gastrointestinal Endoscopy*, José Celso Ardengh, FASGE, MD, MSc, PhD, Associate Professor, Endoscopy Service, Hospital Moriah, São Paulo 04611-000, Brazil. jcelso@uol.com.br

**AIMS AND SCOPE**

The primary aim of *World Journal of Gastrointestinal Endoscopy* (WJGE, *World J Gastrointest Endosc*) is to provide scholars and readers from various fields of gastrointestinal endoscopy with a platform to publish high-quality basic and clinical research articles and communicate their research findings online.

WJGE mainly publishes articles reporting research results and findings obtained in the field of gastrointestinal endoscopy and covering a wide range of topics including capsule endoscopy, colonoscopy, double-balloon enteroscopy, duodenoscopy, endoscopic retrograde cholangiopancreatography, endosonography, esophagoscopy, gastrointestinal endoscopy, gastroscopy, laparoscopy, natural orifice endoscopic surgery, proctoscopy, and sigmoidoscopy.

**INDEXING/ABSTRACTING**

The WJGE is now abstracted and indexed in Emerging Sources Citation Index (Web of Science), PubMed, PubMed Central, Reference Citation Analysis, China National Knowledge Infrastructure, China Science and Technology Journal Database, and Superstar Journals Database. The 2023 Edition of Journal Citation Reports® cites the 2022 impact factor (IF) for WJGE as 2.0; IF without journal self cites: 1.9; 5-year IF: 3.3; Journal Citation Indicator: 0.28.

**RESPONSIBLE EDITORS FOR THIS ISSUE**

**Production Editor:** Yi-Xuan Cai; **Production Department Director:** Xu Guo; **Editorial Office Director:** Jia-Ping Yan.

**NAME OF JOURNAL**

*World Journal of Gastrointestinal Endoscopy*

**ISSN**

ISSN 1948-5190 (online)

**LAUNCH DATE**

October 15, 2009

**FREQUENCY**

Monthly

**EDITORS-IN-CHIEF**

Anastasios Koulaouzidis, Bing Hu, Sang Chul Lee, Joo Young Cho

**EDITORIAL BOARD MEMBERS**

<https://www.wjgnet.com/1948-5190/editorialboard.htm>

**PUBLICATION DATE**

July 16, 2023

**COPYRIGHT**

© 2023 Baishideng Publishing Group Inc

**INSTRUCTIONS TO AUTHORS**

<https://www.wjgnet.com/bpg/gerinfo/204>

**GUIDELINES FOR ETHICS DOCUMENTS**

<https://www.wjgnet.com/bpg/gerinfo/287>

**GUIDELINES FOR NON-NATIVE SPEAKERS OF ENGLISH**

<https://www.wjgnet.com/bpg/gerinfo/240>

**PUBLICATION ETHICS**

<https://www.wjgnet.com/bpg/gerinfo/288>

**PUBLICATION MISCONDUCT**

<https://www.wjgnet.com/bpg/gerinfo/208>

**ARTICLE PROCESSING CHARGE**

<https://www.wjgnet.com/bpg/gerinfo/242>

**STEPS FOR SUBMITTING MANUSCRIPTS**

<https://www.wjgnet.com/bpg/gerinfo/239>

**ONLINE SUBMISSION**

<https://www.f6publishing.com>



## Candy cane syndrome: A systematic review

Ricardo Rio-Tinto, Jorge Canena, Jacques Devière

**Specialty type:** Gastroenterology and hepatology

**Provenance and peer review:** Unsolicited article; Externally peer reviewed.

**Peer-review model:** Single blind

**Peer-review report's scientific quality classification**

Grade A (Excellent): 0  
Grade B (Very good): 0  
Grade C (Good): C, C  
Grade D (Fair): 0  
Grade E (Poor): 0

**P-Reviewer:** Ghannam WM, Egypt; Gupta R, India

**Received:** April 11, 2023

**Peer-review started:** April 11, 2023

**First decision:** May 19, 2023

**Revised:** May 30, 2023

**Accepted:** June 9, 2023

**Article in press:** June 9, 2023

**Published online:** July 16, 2023



**Ricardo Rio-Tinto, Jacques Devière**, Digestive Oncology Unit, Champalimaud Foundation, Lisbon 1600, Lisbon, Portugal

**Jorge Canena**, Centro de Gastreenterologia, Hospital CUF Tejo - Nova Medical School/Faculdade de Ciências Médicas da UNL, Lisbon 1600, Lisbon, Portugal

**Jorge Canena**, Serviço de Gastreenterologia, Hospital Amadora-Sintra, Amadora 1600, Lisbon, Portugal

**Jorge Canena**, Serviço de Gastreenterologia, Hospital de Santo António dos Capuchos - CHLC, Lisbon 1600, Lisbon, Portugal

**Jorge Canena**, Cintesis - Center for Health Technology and Services Research, Universidade do Minho, Braga 1600, Braga, Portugal

**Jacques Devière**, Department of Gastroenterology, Hepatopancreatology, and Digestive Oncology, Erasme Hospital - Université Libre de Bruxelles, Brussels 1050, Brussels, Belgium

**Corresponding author:** Ricardo Rio-Tinto, MD, Consultant Physician-Scientist, Digestive Oncology Unit, Champalimaud Foundation, Avenida Brasília, Lisbon 1600, Lisbon, Portugal. [ricardo.riotinto@fundacaochampalimaud.pt](mailto:ricardo.riotinto@fundacaochampalimaud.pt)

### Abstract

#### BACKGROUND

Candy cane syndrome (CCS) is a condition that occurs following gastrectomy or gastric bypass. CCS remains underrecognized, yet its prevalence is likely to rise due to the obesity epidemic and increased use of bariatric surgery. No previous literature review on this subject has been published.

#### AIM

To collate the current knowledge on CCS.

#### METHODS

A literature search was conducted with PubMed and Google Scholar for studies from May 2007, until March 2023. The bibliographies of the retrieved articles were manually searched for additional relevant articles.

#### RESULTS

Twenty-one articles were identified (135 patients). Abdominal pain, nausea/vomiting, and reflux were the most reported symptoms. Upper gastrointestinal (GI) series and endoscopy were performed for diagnosis. Surgical resection of the blind limb was performed in 13 studies with resolution of symptoms in 73%.

100%. In surgical series, 9 complications were reported with no mortality. One study reported the surgical construction of a jejunal pouch with clinical success. Six studies described endoscopic approaches with 100% clinical success and no complications. In one case report, endoscopic dilation did not improve the patient's symptoms.

## CONCLUSION

CCS remains underrecognized due to lack of knowledge about this condition. The growth of the obesity epidemic worldwide and the increase in bariatric surgery are likely to increase its prevalence. CCS can be prevented if an elongated blind loop is avoided or if a jejunal pouch is constructed after total gastrectomy. Diagnosis should be based on symptoms, endoscopy, and upper GI series. Blind loop resection is curative but complex and associated with significant complications. Endoscopic management using different approaches to divert flow is effective and should be further explored.

**Key Words:** Candy cane syndrome; Blind pouch syndrome; Post-gastrectomy syndromes; Side-to-side enteral anastomosis; End-to-side enteral anastomosis

©The Author(s) 2023. Published by Baishideng Publishing Group Inc. All rights reserved.

**Core Tip:** Enteral resections with side-to-side or end-to-end anastomosis, if a long blind end is left in place and dilates, can cause symptoms that may appear many years later. The classic designation for this clinical condition is blind pouch syndrome, although it is possible to find references under other designations, causing confusion. Candy cane syndrome (CCS) is a particular case of the blind pouch syndrome following gastrectomy or gastric bypass. CCS was first reported in a 2007 paper describing a series of patients with gastrointestinal symptoms associated with a long blind loop proximal to the gastro-jejunostomy after gastric bypass and creation of an end-to-side anastomosis to a jejunal loop. With unknown prevalence, few reports and case series have described the condition. Yet, with the increasing prevalence of obesity and number of operations being performed worldwide, surgical complications such as CCS are expected to become more frequent. Knowledge of candy cane syndrome is important to avoid delays in diagnosis and inadequate treatments. Thus, the goal of this study was to collate evidence on CCS symptoms, diagnosis, treatments, and outcomes. To the best of our knowledge, no previous literature review on this topic has been published.

**Citation:** Rio-Tinto R, Canena J, Devière J. Candy cane syndrome: A systematic review. *World J Gastrointest Endosc* 2023; 15(7): 510-517

**URL:** <https://www.wjgnet.com/1948-5190/full/v15/i7/510.htm>

**DOI:** <https://dx.doi.org/10.4253/wjge.v15.i7.510>

## INTRODUCTION

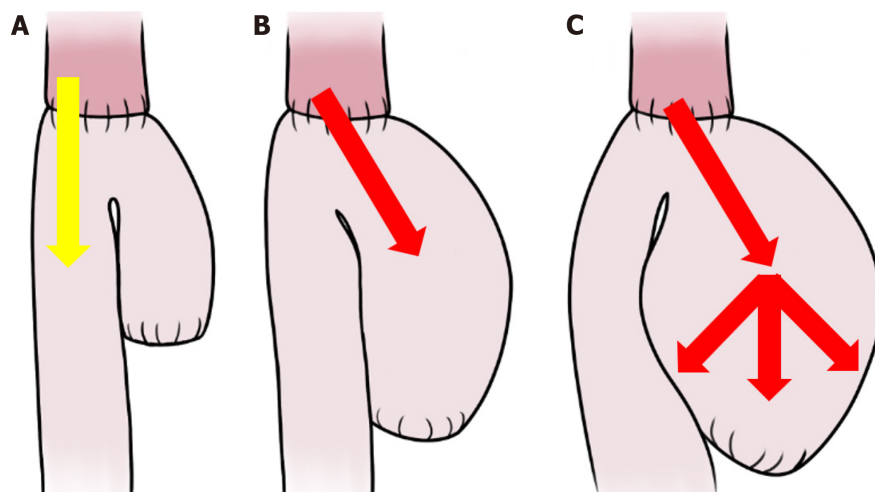
It has long been recognized that when long, blind enteral loops are left in place after a side-to-side or end-to-side anastomosis, they can dilate and be the cause of symptoms that may appear many years later[1]. The classic term for this clinical condition is "blind pouch syndrome", although it is possible to find references under other designations, causing confusion[2,3]. A particular case of blind pouch syndrome following gastrectomy or gastric bypass is called candy cane syndrome (CCS). CCS was first reported in a 2007 paper describing a series of patients with gastrointestinal (GI) symptoms associated with a long blind loop proximal to the gastro-jejunostomy after gastric bypass and creation of an end-to-side anastomosis to a jejunal loop[4]. Few case reports and retrospective studies have described this condition. However, with the increasing prevalence of obesity and number of obesity-related surgeries being performed worldwide, CCS is expected to become more frequent[5].

Probably, the pathophysiology of CCS is exclusively mechanical: A long, mispositioned blind loop preferentially directs luminal contents, increasing pressure and causing dilatation, pain, regurgitation, postprandial vomiting, and weight loss (Figure 1)[4-7]. Cachexia and spontaneous rupture of the blind loop are described[8,9]. Given its nonspecific presentation, the diagnosis of CCS is often subjective and based on clinical symptoms in conjunction with the endoscopic and/or radiographic appearance of a long and dilated blind jejunal limb proximal to the anastomosis, a finding which is known as the candy cane sign (Figure 2)[6,7,9,10].

CCS can be prevented by the avoidance of an unnecessary elongated jejunal (blind) loop proximal to the anastomosis during the initial surgery[2-4]. A blind loop of less than 3 to 4 cm is usually not associated with obstruction and therefore does not cause CCS. In addition, construction of a jejunal pouch after total gastrectomy prevents CCS and improves feeding, weight recovery, and quality of life[11-14].

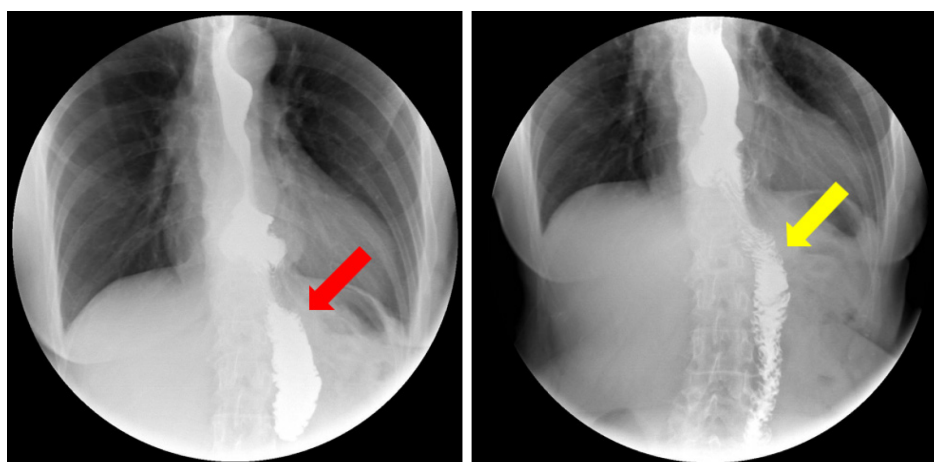
For treatment, surgical resection of the dilated loop is curative but technically complex, due to previous surgeries and adhesions, and is associated with non-negligible morbidity[15,16]. Endoscopic management of CCS using various approaches to divert the flow from the blind loop is possible, safe, and effective[6,7,17-19].





DOI: 10.4253/wjge.v15.i7.510 Copyright ©The Author(s) 2023.

**Figure 1 An esophago-jejunal anastomosis.** A: The optimal morphology of an esophago-jejunal anastomosis, where the blind loop is short, and the efferent loop is properly aligned (yellow arrow); B: A long blind loop preferentially aligned with the axis of the esophagus (red arrow) favoring the passage of food towards it; C: A blind loop filled with food compresses the efferent loop and progressively dilates (red arrows), which over time worsens patient's food intolerance.



DOI: 10.4253/wjge.v15.i7.510 Copyright ©The Author(s) 2023.

**Figure 2 An upper gastrointestinal series in a patient with candy cane syndrome demonstrates.** Left, the preferential filling of the blind limb (red arrow). Right, a delayed "spill" of contrast to the efferent limb (yellow arrow).

Knowledge of CCS is important to avoid delays in diagnosis and inadequate treatments. Thus, the goal of this study was to collate evidence on CCS symptoms, diagnosis, treatments, and outcomes.

To the best of our knowledge, no previous literature review on this topic has been published.

## MATERIALS AND METHODS

A literature search was conducted using the PubMed database and Google Scholar, and by searching the electronic links to related articles, from May 1, 2007 through March 31, 2023.

Search terms included candy cane syndrome, blind pouch syndrome, blind loop syndrome, afferent loop syndrome, Roux limb syndrome, post-gastrectomy syndromes, complications of gastrectomy, side-to-side intestinal anastomosis, end-to-side intestinal anastomosis, and symptoms (pain, reflux, regurgitation, vomiting, and/or weight loss) after gastrectomy. The latter terms were used in various combinations for the search. Language restrictions were not applied.

The bibliographies of the retrieved articles were manually searched for additional relevant articles. The articles were carefully read to identify only those exclusively focusing on candy cane syndrome.



DOI: 10.4253/wjge.v15.i7.510 Copyright ©The Author(s) 2023.

**Figure 3** A keep-in-mind image: This condition was first called candy cane syndrome in 2007 in reference to the so-called cane-shaped candy.

## RESULTS

In accordance with the search criteria, we identified a total of 21 articles (135 patients), including 13 case reports, 3 case series, 4 retrospective studies, and 1 prospective study. Among these studies, the most reported symptoms were abdominal pain, nausea/vomiting, and reflux. In addition, almost all studies performed upper GI series and endoscopy for diagnosis.

Fourteen studies reported surgical resection of the excessive and/or dilated blind limb (13 studies, 111 patients) or construction of an enteral pouch (1 study, 1 patient) with resolution of symptoms in 73%–100% of patients[4,15,16,20–24]. In one case, the surgical procedure was performed through thoracoscopy[25]. These studies reported a total of 9 complications (1 biliary leak, 3 infections, 1 anastomosis ulcer, 1 enterotomy, 1 hematoma, 1 pneumonia\hepatic infarction, 1 leak) with no mortality[16,20,22].

Seven studies, including 5 case reports, 1 case series, and the only prospective study available, described various endoscopic approaches: In two studies, a lumen-apposing metal stent was used to divert the luminal content into the efferent loop[18,26]; in another two cases, a suture device was used to prevent the passage of food content into the blind loop[17–19]. These approaches are technically complex and have low reproducibility; A case report and a prospective study used a magnetic device to cut the tissue between the blind loop and the efferent loop, creating a pouch and allowing the free passage of the food contents[6,7]. In this case, the food is not retained in the blind loop and progresses unhindered to the efferent loop. All these endoscopic approaches led to resolution of symptoms in 100% of patients with no reported complications. One case report described CCS treatment by endoscopic dilation, which does not divert the blind loop, without success[9] (Table 1).

## DISCUSSION

CCS remains underrecognized and misdiagnosed due to a lack of knowledge about the condition. However, its manifestations have been described as common after gastrectomy[27]. In this review, we collected the current evidence on CCS symptoms, diagnosis, and treatment.

When the luminal contents preferentially pass into an overly long blind loop that retains food and distends, the characteristic symptoms of CCS appear, most commonly postprandial abdominal pain associated with nausea and vomiting. These symptoms can appear several years after surgery. Although CCS is a particular case of blind pouch syndrome, it has characteristics that justify being considered an independent clinical entity. As the obesity epidemic persists worldwide and the use of bariatric surgery increases, the prevalence of CCS will likely rise. Thus, CCS should be included in the group of post-gastrectomy syndromes and should be more readily recognized to avoid misdiagnosis, delayed treatment, and inappropriate interventions (Figure 3).

The differential diagnosis of CCS should include other surgical complications such as anastomotic stenosis, dysmotility syndromes secondary to surgery, and recurrence in cases of an oncologic indication for gastrectomy.

Collective evidence indicates that the diagnosis of CCS can be suggested based on clinical history and symptoms and should be confirmed by endoscopy and dynamic fluoroscopy.

The characteristic finding in upper GI series is a preferential filling of the blind loop followed by delayed passage of contrast into the efferent loop, the so-called "candy cane sign"[10].

**Table 1 Studies reporting candy cane syndrome from May 2007 to January 2023**

Ref.	Type of study	n of patients	Symptoms	Timing of symptoms	Specific test	Management	Improvement rate	Complications
Dallal <i>et al</i> [4], 2007	Case series	3	AP, N/V, GERD	3 wk, 1 year, 3 years	UGS, endoscopy	Surgical resection	1	None
Romero-Mejia <i>et al</i> [28], 2010	Case report	1	AP	2 years	UGS, endoscopy	Surgical resection	1	None
Biju <i>et al</i> [29], 2012	Case report	1	AP, N/V, GERD	9 years	Endoscopy, UGS	Surgical resection	1	None
Razjouyan <i>et al</i> [9], 2015	Case report	1	Dysphagia	2 mo	UGS, endoscopy	Endoscopic dilation	0	None
Aryaie <i>et al</i> [20], 2017	Retrospective	19	AP, N/V	3-11 years	UGS, endoscopy	Surgical resection	0.94	1 biliary leak
Marti Fernandez <i>et al</i> [30], 2017	Case report	1	AP	Not mentioned	UGS, endoscopy	Surgical resection	1	None
Granata <i>et al</i> [17], 2019	Case report	1	N/V, AP	1 year	UGS, endoscopy	Endoscopic suture	1	None
Khan <i>et al</i> [15], 2018	Case series	3	AP, N/V	1 year	UGS, endoscopy, CT	Surgical resection	1	None
Kommunuri <i>et al</i> [21], 2018	Case report	1	N/V, AP	6 years	UGS, endoscopy	Surgical pouch	1	None
Frieder <i>et al</i> [23], 2019	Retrospective	26	AP, N/V, GERD	10 years	Not mentioned	Surgical resection	0.92	1 leak
Cartillone <i>et al</i> [31], 2020	Case report	1	AP, D, Vasomotor	5 years	CT	Surgical resection	1	None
Kamocka <i>et al</i> [16], 2020	Retrospective	28	AP, N/V, GERD	Not mentioned	CT, endoscopy, UGS	Surgical resection	0.73	3 Infections, 1 anastomosis ulcer, 1 enterotomy, 1 hematoma
Cobb and Banki [25], 2020	Case report	1	Dysphagia, regurgitation	1 year	UGS, CT, endoscopy	Surgical resection <sup>1</sup>	1	None
Wundsam <i>et al</i> [18], 2020	Case series	4	Not mentioned	Not mentioned	Not mentioned	Endoscopic LAMS	1	None
Acín-Gándara and Ruiz-Úcar [22], 2021	Case report	1	Dysphagia, GERD, AP	Not mentioned	Endoscopy, UGS	Surgical resection	1	Pneumonia, hepatic infarction
Greenberg <i>et al</i> [19], 2021	Case report	1	AP, N/V, GERD	8 years	Endoscopy, UGS	Endoscopic suture	1	None
Rio-Tinto <i>et al</i> [6], 2022	Prospective	14	AP, N/V	Not mentioned	Endoscopy, UGS	Endoscopic marsupialization	1	None
Rio-Tinto <i>et al</i> [7], 2022	Case report	1	AP, N/V	24 mo	Endoscopy, UGS	Endoscopic marsupialization	1	None
Shamia <i>et al</i> [32], 2022	Retrospective	25	AP, N/V, GERD	Not mentioned	Endoscopy	Surgical resection	0.84	Not mentioned
Ouazzani <i>et al</i> [26], 2023	Case report	1	N/V, GERD	40 years	Endoscopy, UGS	Endoscopic LAMS	1	None
Prakash <i>et al</i> [24], 2023	Case report	1	GERD	15 years	Endoscopy, UGS	Surgical resection	1	None

<sup>1</sup>Thoracoscopy.

AP: Abdominal pain; N/V: Nausea/vomiting; GERD: Gastroesophageal reflux disease; UGS: Upper gastrointestinal series; CT: Computed tomography.

Endoscopy in patients submitted to gastrectomy or gastric bypass should include the careful exploration of the blind loop and of the passage to the efferent loop. In these patients, access to the blind loop is usually easy and direct, and access to the efferent loop is difficult and done after passing through an angulation[21].



When CCS does arise, effective treatment options are available. Surgical resection of the excessively long and/or dilated loop is curative. However, this method is technically complex, due to previous surgeries and adhesions, and is associated with serious complications in a significant number of patients. By contrast, endoscopic management of CCS using various approaches to divert the flow from the blind loop is safe and effective and should be further explored.

## CONCLUSION

CCS is still an unknown diagnosis for most physicians, including gastroenterologists who are often the first clinicians to deal with these patients.

Although it is underreported, the prevalence of CCS is probably higher than is commonly thought. Its diagnosis is based on clinical, endoscopic, and imaging findings. Symptoms such as dysphagia, pain, regurgitation, or reflux after food intake are relatively frequent in patients after gastrectomy or gastric bypass and should lead to a detailed clinical investigation. Although surgical revision of the blind loop is an effective treatment, it is associated with complications in frail patients with comorbidities. Sectioning of the septum and marsupialization is the current standard mini-invasive treatment for esophageal diverticula. The development of a simple and safe endoscopic technique, such as the blind loop marsupialization described in the only existing prospective study, will in our opinion be the preferred treatment for CCS in the future.

## ARTICLE HIGHLIGHTS

### Research background

Candy cane syndrome (CCS) is a particular case of the blind pouch syndrome after gastrectomy or gastric bypass, so named in a 2007 paper describing a small series of patients with gastrointestinal symptoms associated with a long blind loop proximal to the gastro-jejunostomy after gastric bypass and creation of an end-to-side anastomosis to a jejunal loop. The pathophysiology of CCS appears to be predominantly mechanical, as an excessive long or mispositioned blind loop proximal to the anastomosis may preferably direct food and increase luminal pressure, causing dilatation, early satiety, fullness, pain, reflux, regurgitation, post-prandial vomiting, weight loss, and, ultimately, inability to eat and cachexia.

### Research motivation

CCS remains underrecognized and misdiagnosed due to the lack of knowledge about this condition, however, its manifestations have been described as common after gastrectomy. Since gastroenterologists are often the first clinicians to come into contact with patients with CCS, it is important that this clinical condition be part of the list of differential diagnoses for patients with digestive symptoms after gastrectomy or gastric bypass. To our knowledge, there is no published review on this subject.

### Research objectives

The objective of this work was to systematically gather all the published evidence on CCS, in order to make this clinical condition known and to systematize the diagnostic and therapeutic approach.

### Research methods

A literature search was conducted using PubMed and Google Scholar, and by searching in addition to electronic links to related articles, from May 1, 2007, through March 31, 2023. Search terms included candy cane syndrome, blind pouch syndrome, blind loop syndrome, afferent loop syndrome, Roux limb syndrome, post-gastrectomy syndromes, complications of gastrectomy, side-to-side intestinal anastomosis, end-to-side intestinal anastomosis, and symptoms (pain, reflux, regurgitation, vomiting, and/or weight loss) after gastrectomy. The bibliographies of the retrieved articles were manually searched for additional relevant articles.

### Research results

We found 20 articles on CCS, most case reports or case series in which the treatment was surgical, usually resection of the blind loop. In seven articles the treatment was endoscopic, using lumen-apposing metal stents to divert the passage of the luminal contents (two case reports), suture devices to close the blind loop (two case reports), or by cutting the septum between the blind loop and the efferent loop, promoting the marsupialization of the blind loop (one clinical case and the only prospective study available). In one case, balloon dilatation was performed, without clinical success. In general, treatment results are good, but the surgical approach is associated with complications in a significant number of patients.

### Research conclusions

CCS remains an under-recognized clinical condition and since gastroenterologists are usually the first clinicians to come into contact with these patients it is important to make it more familiar. As the number of bariatric surgeries increases, it is likely that the number of patients with CCS will increase as well. CCS patients are usually frail, with comorbidities, and it is important to establish the best diagnostic and therapeutic approach. Surgical treatment is effective but is associated with complications and there is still no optimal and reproducible endoscopic treatment.

## Research perspectives

We believe that, in the same way that the treatment of Zenker's diverticulum has changed from surgery to the endoscopic section of the diverticular septum, in a simple, fast, effective and reproducible procedure, marsupialization of the septum between the blind loop and the efferent loop can become the ideal treatment for CCS.

## FOOTNOTES

**Author contributions:** Rio-Tinto R reviewed the literature and wrote the manuscript; All authors critically reviewed the manuscript.

**Conflict-of-interest statement:** All the authors report no relevant conflicts of interest for this article.

**PRISMA 2009 Checklist statement:** The authors have read the PRISMA 2009 Checklist, and the manuscript was prepared and revised according to the PRISMA 2009 Checklist.

**Open-Access:** This article is an open-access article that was selected by an in-house editor and fully peer-reviewed by external reviewers. It is distributed in accordance with the Creative Commons Attribution NonCommercial (CC BY-NC 4.0) license, which permits others to distribute, remix, adapt, build upon this work non-commercially, and license their derivative works on different terms, provided the original work is properly cited and the use is non-commercial. See: <https://creativecommons.org/licenses/by-nc/4.0/>

**Country/Territory of origin:** Portugal

**ORCID number:** Ricardo Rio-Tinto 0000-0002-4431-9908; Jorge Canena 0000-0002-2539-5876.

**S-Editor:** Li L

**L-Editor:** A

**P-Editor:** Xu ZH

## REFERENCES

- 1 Botsford TW, Gazzaniga AB. Blind pouch syndrome. A complication of side to side intestinal anastomosis. *Am J Surg* 1967; **113**: 486-490 [PMID: 6023020 DOI: 10.1016/0002-9610(67)90192-4]
- 2 Schlegel DM, Maglinte DD. The blind pouch syndrome. *Surg Gynecol Obstet* 1982; **155**: 541-544 [PMID: 6981863]
- 3 Takiguchi S, Yano H, Sekimoto M, Taniguchi E, Monden T, Ohashi S, Monden M. Laparoscopic surgery for blind pouch syndrome following Roux-en Y gastrojejunostomy: report of a case. *Surg Today* 1999; **29**: 553-556 [PMID: 10385372 DOI: 10.1007/BF02482352]
- 4 Dallal RM, Cottam D. "Candy cane" Roux syndrome--a possible complication after gastric bypass surgery. *Surg Obes Relat Dis* 2007; **3**: 408-410 [PMID: 17533103 DOI: 10.1016/j.soard.2007.02.011]
- 5 Jaruvongvanich V, Law R. Endoscopic management of candy cane syndrome: A sweet and attractive solution? *Gastrointest Endosc* 2022; **95**: 1254-1255 [PMID: 35410730 DOI: 10.1016/j.gie.2022.02.032]
- 6 Rio-Tinto R, Huberland F, Van Ouytsel P, Delattre C, Dugardeyn S, Cauche N, Delchambre A, Devière J, Blero D. Magnet and wire remodeling for the treatment of candy cane syndrome: first case series of a new approach (with video). *Gastrointest Endosc* 2022; **95**: 1247-1253 [PMID: 34979115 DOI: 10.1016/j.gie.2021.12.027]
- 7 Rio-Tinto R, de Campos ST, Marques S, Bispo M, Fidalgo P, Devière J. Endoscopic marsupialization for severe candy cane syndrome: long-term follow-up. *Endosc Int Open* 2022; **10**: E1159-E1162 [PMID: 36238533 DOI: 10.1055/a-1869-2680]
- 8 Iaroseski J, Machado Grossi JV, Rossi LF. Acute abdomen and pneumoperitoneum: complications after gastric bypass in Candy Cane syndrome. *Chirurgia (Bucur)* 2022; **34** [DOI: 10.23736/S0394-9508.21.05263-3]
- 9 Razjouyan H, Tilara A, Chokhavatia S. Dysphagia After Total Gastrectomy. *Am J Gastroenterol* 2015; **110**: S262-263 [DOI: 10.14309/00000434-201510001-00595]
- 10 Coursier K, Verswijvel G. Candy cane sign. *Abdom Radiol (NY)* 2020; **45**: 885-886 [PMID: 31822967 DOI: 10.1007/s00261-019-02361-0]
- 11 Gertler R, Rosenberg R, Feith M, Schuster T, Friess H. Pouch vs. no pouch following total gastrectomy: meta-analysis and systematic review. *Am J Gastroenterol* 2009; **104**: 2838-2851 [PMID: 19672251 DOI: 10.1038/ajg.2009.456]
- 12 Dong HL, Huang YB, Ding XW, Song FJ, Chen KX, Hao XS. Pouch size influences clinical outcome of pouch construction after total gastrectomy: a meta-analysis. *World J Gastroenterol* 2014; **20**: 10166-10173 [PMID: 25110445 DOI: 10.3748/wjg.v20.i29.10166]
- 13 Syn NL, Wee I, Shabbir A, Kim G, So JB. Pouch Versus No Pouch Following Total Gastrectomy: Meta-analysis of Randomized and Non-randomized Studies. *Ann Surg* 2019; **269**: 1041-1053 [PMID: 31082900 DOI: 10.1097/SLA.0000000000003082]
- 14 Doussot A, Borraccino B, Rat P, Ortega-Deballon P, Facy O. Construction of a jejunal pouch after total gastrectomy. *J Surg Tech Case Rep* 2014; **6**: 37-38 [PMID: 25013552 DOI: 10.4103/2006-8808.135152]
- 15 Khan K, Rodriguez R, Saeed S, Persaud A, Ahmed L. A Case series of candy cane limb syndrome after laparoscopic Roux-en-Y gastric bypass. *J Surg Case Rep* 2018; **2018**: rjy244 [PMID: 30310639 DOI: 10.1093/jscr/rjy244]
- 16 Kamocka A, McGlone ER, Pérez-Pevida B, Moorthy K, Hakky S, Tsonis C, Chahal H, Miras AD, Tan T, Purkayastha S, Ahmed AR. Candy cane revision after Roux-en-Y gastric bypass. *Surg Endosc* 2020; **34**: 2076-2081 [PMID: 31392513 DOI: 10.1007/s00464-019-06988-4]
- 17 Granata A, Cicchese N, Amata M, De Monte L, Bertani A, Ligresti D, Traina M. "Candy cane" syndrome: a report of a mini-invasive endoscopic treatment using OverStitch, a novel endoluminal suturing system. *Endoscopy* 2019; **51**: E16-E17 [PMID: 30406630 DOI: 10.1055/a-0756-8304]
- 18 Wundsam HV, Kertesz V, Bräuer F, Fischer I, Zacherl J, Függer R, Spaun GO. Lumen-apposing metal stent creating jejuno-jejunostomy for

- blind pouch syndrome in patients with esophago-jejunostomy after gastrectomy: a novel technique. *Endoscopy* 2020; **52**: E35-E36 [PMID: 31434158 DOI: 10.1055/a-0985-4023]
- 19 **Greenberg I**, Braun D, Eke C, Lee D, Kedia P. Successful treatment of "candy cane" syndrome through endoscopic gastrojejunal anastomosis revision. *Clin J Gastroenterol* 2021; **14**: 1622-1625 [PMID: 34476757 DOI: 10.1007/s12328-021-01511-6]
  - 20 **Aryaie AH**, Fayeizadeh M, Wen Y, Alshehri M, Abbas M, Khaitan L. "Candy cane syndrome:" an underappreciated cause of abdominal pain and nausea after Roux-en-Y gastric bypass surgery. *Surg Obes Relat Dis* 2017; **13**: 1501-1505 [PMID: 28552743 DOI: 10.1016/j.soard.2017.04.006]
  - 21 **Kommunuri J**, Kulasegaran S, Stiven P. Blind Pouch Syndrome in Gastrojejunostomy. *N Z Med J* 2018; **131**: 74-77 [PMID: 30161115]
  - 22 **Acín-Gándara D**, Ruiz-Úcar E, Medina-García M, Pereira-Pérez F. Revision of a Previous Capella Bypass due to dysphagia, GERD and Candy Cane Syndrome. *Obes Surg* 2021; **31**: 2348-2349 [PMID: 33604867 DOI: 10.1007/s11695-021-05293-1]
  - 23 **Frieder JS**, Betancourt A, Aleman R, Fonseca MC, Ortiz Gomez C, De Stefano F, Romero Funes D, Lo Menzo E, Szomstein S, Rosenthal RJ. Candycane Roux Limb Syndrome after Roux-en-Y Gastric Bypass: Does Resection Improve the Symptoms of Nausea and Abdominal Pain? *J Am Coll Surg* 2019; **229**: e1 [DOI: 10.1016/j.jamcollsurg.2019.08.736]
  - 24 **Prakash S**, Saavedra R, Lehmann R, Mokadem M. Candy cane syndrome presenting with refractory heartburn 15 years after Roux-en-Y bypass. *J Surg Case Rep* 2023; **2023**: rjad130 [PMID: 36942285 DOI: 10.1093/jscr/rjad130]
  - 25 **Cobb T**, Banki F. Thoracoscopic revision of a herniated Roux-en-Y esophagojejunostomy for treatment of "candy cane" syndrome. *JTCVS Tech* 2020; **2**: 153-155 [PMID: 34317787 DOI: 10.1016/j.xjtc.2020.02.004]
  - 26 **Ouazzani S**, Gasmi M, Gonzalez JM, Barthet M. Candy cane syndrome: a new endoscopic treatment for this underappreciated surgical complication. *Endoscopy* 2023; **55**: E414-E415 [PMID: 36758628 DOI: 10.1055/a-2007-1952]
  - 27 Revisional Foregut Surgery. Borao FJ, Binenbaum SJ, Matharoo GS, Editors. Switzerland: Springer Nature Switzerland AG, 2020 [DOI: 10.1007/978-3-030-28273-8]
  - 28 **Romero-Mejía C**, Camacho-Aguilera JF, Paipilla-Monroy O. ["Candy cane" Roux syndrome in laparoscopic gastric by-pass]. *Cir Cir* 2010; **78**: 347-351 [PMID: 21167102]
  - 29 **Biju A**, Lane B, Chamberlain S. Candy Cane Roux Syndrome: A Not So Sweet Complication Following Roux-en-Y Gastric Bypass. *Am J Gastroenterol* 2017; **117**: S297-298 [DOI: 10.14309/0000434-201210001-00719]
  - 30 **Marti Fernandez R**, Marti Obiol R, Espi Macias A, Lopez Mozoz F. Candy Cane Syndrome after Gastric Cancer Surgery. *J Clin Rev Case Rep* 2017; **2**
  - 31 **Cartillone M**, Kassir R, Mis TC, Falsetti E, D'Alessandro A, Chahine E, Chouillard E. König's Syndrome After Roux-en-Y Gastric Bypass: Candy Cane Twist. *Obes Surg* 2020; **30**: 3251-3252 [PMID: 32377990 DOI: 10.1007/s11695-020-04563-8]
  - 32 **Shamia A**, Valdivieso S, Andrade J, Obregon F. Case series of long candy cane syndrome. *Surg Obes Relat Dis* 2022; **18**: S58 [DOI: 10.1016/j.soard.2022.06.190]



Published by **Baishideng Publishing Group Inc**  
7041 Koll Center Parkway, Suite 160, Pleasanton, CA 94566, USA

**Telephone:** +1-925-3991568

**E-mail:** [bpgoffice@wjgnet.com](mailto:bpgoffice@wjgnet.com)

**Help Desk:** <https://www.f6publishing.com/helpdesk>

<https://www.wjgnet.com>

