

Evaluating long-term attachment of two different endoclips in the human gastrointestinal tract

Hendrik Albert Maurits Swellengrebel, Cornelia Adriana Maria Marijnen, Andrew Vincent, Annemieke Cats

Hendrik Albert Maurits Swellengrebel, Annemieke Cats, Department of Gastroenterology and Hepatology, the Netherlands Cancer Institute - Antoni van Leeuwenhoek Hospital, Plesmanlaan 121, Amsterdam 1066CX, The Netherlands

Cornelia Adriana Maria Marijnen, Department of Radiation Oncology, the Netherlands Cancer Institute - Antoni van Leeuwenhoek Hospital, Plesmanlaan 121, Amsterdam 1066 CX, The Netherlands

Cornelia Adriana Maria Marijnen, Department of Clinical Oncology, Leiden University Medical Centre, Post box 9600, Leiden 2300 RC, The Netherlands

Andrew Vincent, Department of Biostatistics, the Netherlands Cancer Institute - Antoni van Leeuwenhoek Hospital, Plesmanlaan 121, Amsterdam 1066CX, The Netherlands

Author contributions: Swellengrebel HAM, Marijnen CAM and Cats A were involved in the study design, acquisition of data, analysis and interpretation of data, drafting and revising the manuscript and the final approval; and Vincent A was involved in study design, statistical data analysis, interpretation of data and final approval of the manuscript.

Correspondence to: Hendrik Albert Maurits Swellengrebel, MD, Department of Gastroenterology and Hepatology, the Netherlands Cancer Institute - Antoni van Leeuwenhoek Hospital, Plesmanlaan 121, Amsterdam 1066CX, The Netherlands. m.swellengrebel@nki.nl

Telephone: +31-20-5122566 Fax: +31-20-5122572

Received: June 1, 2010 Revised: August 31, 2010

Accepted: September 7, 2010

Published online: October 16, 2010

licator once a week for 3 wk, wk 9-11) in medically inoperable rectal cancer patients. Initially, the type and number of endoclips were chosen randomly and later refined to 1 Resolution[®] clip (Microvasive) proximal and 2 Quickclips[®] (Olympus) distal to the tumor. Nine consecutive patients from between September 2007 and August 2008 were analyzed. Retention rates were evaluated over three different observational periods [period 1: pre-HDRBT (wk -2-8), period 2: during HDRBT (wk 9-11) and period 3: post-HDRBT (wk 12-16)].

RESULTS: In this study, a total of 44 clips were placed during endoscopy, either at the beginning or at the end of period 1. The Resolution clip had a higher overall retention rate than the Quickclip ($P = 0.01$). After a median period of 81 d after placement (in period 1), long-term retention rates for the Resolution clip and Quickclip clip were 67% and 35% respectively.

CONCLUSION: The Resolution clip has a high retention rate and is useful in situations where long-term attachment to the human gastrointestinal mucosa is warranted.

© 2010 Baishideng. All rights reserved.

Key words: Endoclip; Radiotherapy; Retention rate; Cancer; Delineation

Peer reviewer: Perminder Phull, MD, FRCP, FRCPE, Gastrointestinal & Liver Service, Room 2.58, Ashgrove House, Aberdeen Royal Infirmary, Foresterhill, Aberdeen AB25 2ZN, United Kingdom

Abstract

AIM: To evaluate the long-term attachment of two types of endoclips in the human gastrointestinal tract.

METHODS: In this prospective observational study, endoclips were placed and followed-up during endoscopies or using fluoroscopic images as part of a prospective feasibility study evaluating external beam radiotherapy (EBRT, wk 1-3) followed by high dose rate brachytherapy (HDRBT with an endoluminal app

Swellengrebel HAM, Marijnen CAM, Vincent A, Cats A. Evaluating long-term attachment of two different endoclips in the human gastrointestinal tract. *World J Gastrointest Endosc* 2010; 2(10): 344-348 Available from: URL: <http://www.wjgnet.com/1948-5190/full/v2/i10/344.htm> DOI: <http://dx.doi.org/10.4253/wjge.v2.i10.344>

INTRODUCTION

In 1975, Hayashi *et al.*^[1] were the first to describe the metallic endoscopic clip as an alternative means to control bleeding by mechanical pressure. Since then, design and clinical indications have been refined. Nowadays, endoscopic clips are frequently used for hemostasis of arterial nonvariceal bleeding of the upper gastrointestinal tract^[2,3]. Other reported indications for endoscopic clip placement include the fixation of enteral feeding tubes^[4], stent anchorage^[5,6] and the management of small fistulas, perforations and anastomotic leaks^[7]. Utilizing their radiopaque characteristics, endoclips have recently been used to mark tumors or anatomical structures to facilitate intervention radiology^[8], to locate the tumor preoperatively^[9] and to delineate tumor volume for radiotherapy^[10,11].

Several types of endoscopic clips are commercially available. Most studies involve those from Olympus (Olympus Ltd., Tokyo, Japan), available in preloaded (Quickclip) and reloadable devices (HX-5L). Once the clip has been opened, re-positioning is not possible as the jaws cannot be closed and reopened. The Resolution clip (Microvasive, Boston Scientific Corp, Massachusetts, US) has the ability to reopen its jaws for repositioning which may result in superior positioning and tissue grasping.

The ability of an endoclip to remain attached for a longer period could facilitate procedures in which a tumor needs to be located routinely during the treatment period or when the clip anchors feeding tubes or stents. Retention rates have, however, only been evaluated in canines and pigs and have not yet been reported in the human gastrointestinal tract. The aim of this study was to evaluate the long-term attachment of two endoclips, the Quickclip and the Resolution clip, to human rectal mucosa.

MATERIAL AND METHODS

Study population

The 9 consecutive patients analyzed in this study were patients with medically inoperable rectal cancer who participated in a prospective feasibility study in the Netherlands Cancer Institute. The primary objective of this ongoing study is to evaluate the feasibility of external beam radiation therapy (EBRT) followed by high-dose rate endorectal brachytherapy (HDRBT) as definitive treatment in patients not suitable for surgery due to comorbidity, old age or for those refusing surgery. The study gained ethical approval from the Medical Ethics Committee of the Netherlands Cancer Institute. Written informed consent was obtained from all patients. Patient accrual commenced in September 2007.

Treatment protocol

The treatment regimen (Figure 1) consists of 39 Gy administered in 13 fractions of 3 Gy over 3½ wk. After a further 6 wk, HDRBT is applied once every week for 3 wk. HDRBT dose level will be elevated (starting at 5 Gy/fraction) after every 6 patients depending on experienced toxicity. HDRBT is applied using an endorectal applicator

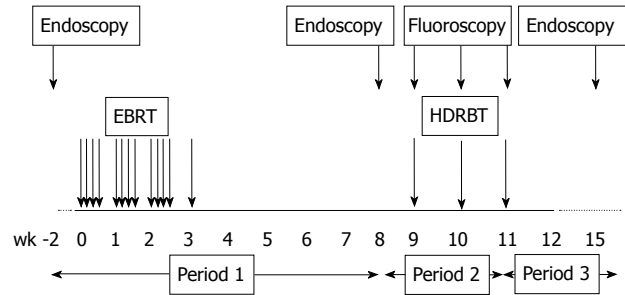


Figure 1 Treatment plan: Patients first receive external beam radiotherapy followed by high dose rate brachytherapy. EBRT: external beam radiotherapy; HDRBT: high dose rate brachytherapy.

(Oncosmart®, Nucletron, Veenendaal, the Netherlands) consisting of a flexible tube with 8 channels (Figure 2). The applicator is 2 cm in diameter and is inserted via the anus prior to each brachytherapy treatment.

Endoclips

The rectal tumor was marked (Figure 3A) with Quickclips (Olympus Ltd., Tokyo, Japan) and/or Resolution (Microvasive, Boston Scientific Corp, Massachusetts, US) endoclips to facilitate tumor localization during the HDRBT procedure. Endoscopy was performed before EBRT (baseline), before HDRBT (wk 8-9) and after HDRBT (wk 16-17). The tumor was marked before EBRT and, if necessary, additionally (when clips had been dislodged) before HDRBT. Initially, the type and number of endoclips were chosen randomly. Later on, this was refined to one Resolution endoclip at the proximal and two Quickclips at the distal border of the tumor.

Treatment planning

A CT-scan with the unloaded applicator inserted was performed for delineation and treatment planning purposes before the first HDRBT fraction. A 3D reconstruction of the applicator and radio-opaque endorectal clips was made and the target volume delineated on the CT-images. A 2D anterior-posterior projection of applicator and clips was reconstructed as a reference for C-arm fluoroscopy guided reinsertion of the applicator prior to each HDRBT session (wk 9-11, Figure 3B).

Data analyses

We evaluated retention rates between the two clip types over three different observational periods [period 1: pre-HDRBT (wk -2-8), period 2: during HDRBT (wk 9-11) and period 3: post-HDRBT (wk 12-16)] (Figure 1). The percentage and absolute number of clips still attached during follow-up endoscopy and on the fluoroscopic images were determined. To assess the retention rates of the two clip types (Quickclip or Resolution) a logistic mixed effects model was constructed with clip type as a fixed effect. To account for the influence of both the different periods (different in length and use of an endoluminal applicator) and the duration of attachment prior to assessment, we included placement (beginning of period 1 or 2) and asse

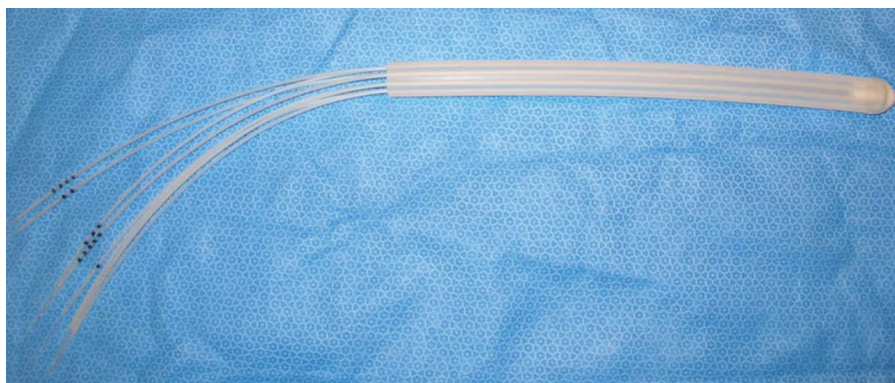


Figure 2 Depicts the endorectal applicator (Oncosmart®, Nucletron, Veenendaal, the Netherlands) used to apply High Dose Rate Brachytherapy.

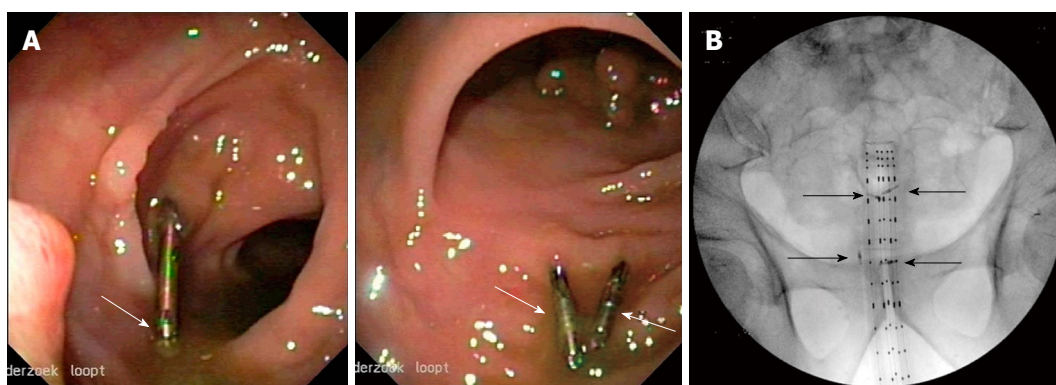


Figure 3 Imaging of the endoclips. A: Shows endoscopic images of an attached Resolution clip on the left (with a recognizable silver part at the loose end) and 2 attached Quickclips on the right (with a recognizable silver part at the center of the clip); B: Shows a fluoroscopic image as made for HDRBT planning purposes and in between HDRBT fractions. Four Quickclips are still attached (arrows).

ssment period as fixed effects. The assessments of clip retention was assumed to be correlated when they relate to the same clip (assessed for different periods) or from clips within the same patient. To account for this cluster correlation, we included clip and patient id as random intercepts. Due to insufficient events in period 2, a logistic model was unable to be constructed; hence the comparison of the retention rates of the two clip types in this period was performed using a Mantel-Haenszel test. Where appropriate, two-sided *p*-values are reported with a significance level set at 0.05.

RESULTS

Six male and three female patients were evaluated. Median age of patients was 81 (range 57-93) years. Seven of the nine patients completed the treatment. One patient did not receive HDRBT after the EBRT due to an ulcer located in the brachytherapy field while the other patient not completing treatment died due to a non-treatment related cardiac arrest after the first HDRBT treatment. Retention rates for the different observational periods are depicted in Table 1.

In this study, a total of 44 clips were placed during endoscopy, either at the beginning or at the end of period 1. At the beginning of period 1 (before EBRT), 26 clips were placed. The median duration of period 1 was 81 (49-90) d. Of the 20 Quickclips placed, 7 (35%) were

visualized during the follow-up endoscopy at the end of period 1. Four of the 6 (67%) Resolution clips placed were visualized at this second endoscopy. During the same endoscopy at the end of period 1, 18 clips were additionally placed (15 Quickclips and 3 Resolution clips) to replace dislodged clips. Median time between placement/visualization at the end of period 1 and the next follow-up endoscopy (end of period 3) was 72 (range 33-91) d. No Quickclips survived all three periods, while 1 additionally placed Quickclip was visualized at the end of period 3. One of the 6 Resolution clips placed at the beginning of period 1 survived all three periods and was still visible at the last follow-up after 231 d. One of the 3 additionally placed Resolution clips was visualized at the end of period 3 as well. Therefore, at the follow-up endoscopy after HDRBT (end of period 3), 1 (7%) Quickclip and 2 (40%) Resolution clips were visualized.

Retention rates gathered from the fluoroscopy images acquired every week during the HDRBT are depicted in table 1. After 1, 2 and 3 wk, these were 80%, 60% and 63% for the Quickclips versus 83%, 80% and 75% for the Resolution clip. In case no image was available, the clip was censored which explains why the 3 wk Quickclip retention rate is higher than the 2 wk rate. The retention rates after 1, 2 and 3 wk in period 2 did not differ significantly between the 2 types of clips (*P* = 0.17, Mantel Haenszel test). The Resolution clip had a higher overall retention rate than the Quickclip [Odds Ratio: 96 (2.5 -

Table 1 Clip retention rates over three periods

Period	Period 1		Period 2				Period 3			
Evaluation	During 2 nd endoscopy (before HDRBT, after EBRT)		Images after wk 1 (During HDRBT)		Images after wk2 (during HDRBT)		Images after wk 3 (during HDRBT)		During 3 rd endoscopy (after HDRBT)	
Patient	Quickclip (visualized/ placed ^a)	Resolution (visualized/ placed ^a)	Quickclip (visualized/ placed ^b)	Resolution (visualized/ placed ^b)	Quickclip (visualized/ placed ^b)	Resolution (visualized/ placed ^b)	Quickclip (visualized/ placed ^b)	Resolution (visualized/ placed ^b)	Quickclip (visualized/ placed ^c)	Resolution (visualized/ placed ^c)
1	0/1	0	2/5	0	1/5	0	1/5	0	0/1	0
2	4/11	0	7/7	0	6/7	0	6/7	0	0/6	0
3	0	0	1/1	1/1	1/1	1/1	1/1	1/1	1/1	1/1
4	2/2	1/1	2/2	0/1	2/2	0/1	2/2	0/1	0/2	0
5	0/1	0/1	no images	no images	no images	no images	no images	no images	0/2	0/1
6	0/1	1/1	2/2	1/1	2/2	1/1	2/2	1/1	0/2	0/1
7	0	1/1	0	1/1 ^d	-	-	-	-	-	-
8	0/2	0/1	1/1	1/1	0/1	1/1	no images	no images	0	0/1
9	1/2	1/1	1/2	1/1	0/2	1/1	0/2	1/1	0	1/1
Total	7/20 (35%)	4/6 (67%)	16/20 ^e (80%)	5/6 ^e (83%)	12/20 (60%)	4/5 (80%)	12/19 (63%)	3/4 (75%)	1/14 (7%)	2/5 (40%)

^a“Placed” includes those clips placed during the first endoscopy; ^b“Placed” includes those clips that were placed at the 2nd endoscopy but also those (7 Quickclips and 4 Resolution) that were still attached from the 1st endoscopy; ^c“Placed” are the number of clips at last visualization in period 2 (for patient 5 this is during placement during period 2); ^dThis patient died due to a sudden cardiac arrest during the HDRBT; ^eDue too missing images of patient 5, the 2 placed Quickclips and 1 Resolution clip were excluded from the analysis in the corresponding period; EBRT: external beam radiotherapy; HDRBT: high dose rate brachytherapy.

3614), $P = 0.01$]. In comparison to the first period, long-term retention rates deteriorated significantly in the third period when the endoluminal applicator had been inserted [Odds Ratio: 0.01 (0.0003 - 0.2), $P = 0.003$].

DISCUSSION

In this study, we found the Resolution clip to be superior to the Quickclip in situations where long-term attachment is warranted. The Resolution clip remained attached longer than the Quickclip, with encouraging long-term retention rates of up to 67% for the Resolution clip after nearly 12 wk. In contrast, only 35% of the Quickclips remained attached.

Recently, Eun Ji Shin *et al* compared the attachment duration of two endoscopic clips (the Quickclip's predecessor, the HX-5L, versus the Resolution clip) in the gastric mucosa of 5 pigs. They also found that the Resolution clip had the longest rate of retention, being visualized during follow-up endoscopy after 1, 2 and 4 or 5 wk (range of retention rates: 4-5 wk) and concluded that it should be preferred over the HX-5L clip (80% dislodged within 2 wk) when long-term attachment is important^[12]. Similar results were reported in a randomized controlled study of 3 types of endoscopic clips used for haemostasis in bleeding gastric ulcers in 7 canines. In their study, the median clip retention time was 2 wk for the Quickclip (maximum duration of attachment of 3 wk) and 4 wk for the Resolution clip (maximum duration of attachment of 18 wk)^[13]. The nature of our study enabled the first report in humans *in vivo* and is in line with these reports, favoring the Resolution clip when long-term attachment is required. Furthermore, we describe retention after almost 12 wk follow-up. Long-term attachment of an endoscopic clip was first described in 1994 when Iida *et al*^[14] reported clip retention (HX-3L, Olympus, total number of clips

placed unknown) of up to 26 mo after placement in a patient during a colonoscopic polypectomy. In our study, 1 Resolution clip was even visualized 33 wk after placement while the longest measured attachment of a Quickclip was 15 wk. Clinical indications that would benefit from long-term attachment include the fixation of stents and feeding tubes in the esophagus and bowel respectively.

Regarding the effect of mechanical exertion on the endoscopic clips, we found the following: overall, the resolution clip survived the continuous passing of stools more effectively than the Quickclip. However, in our study, the retention rates of both the Resolution clip and the Quickclip deteriorated during the second and third period (during and after HDRBT) in comparison to the first period, where patients underwent external beam radiotherapy (Table 1). As suggested earlier, one probable cause for this decreased retention is the fact that an endorectal brachytherapy applicator was placed in the second period in order to plan and perform the HDRBT (4 times in total) which could have mechanically dislodged both types of clips in the process. Another plausible reason could be that some of the clips (7 Quickclips and 4 Resolution clips) evaluated in period 2 were placed during the first endoscopy. With a grip that theoretically deteriorates due to cell renewal and mechanical pressure of passing stools during defecation, these clips could possibly have been on the verge of dislodgement, leading to the decreased retention rate over periods 2 and 3. Regarding the subgroup of endoscopic clips in our study in which attachment was determined after 1, 2 and 3 wk, retention rates (Table 1) are at least in line with those reported in the abovementioned study by Jensen *et al* (Quickclip: 74%, 30% and 11% versus the Resolution clip: 65%, 58% and 45% after 1, 2 and 4 wk)^[13]. Interestingly, when one only looks at the retention of the two clip types during these periods (at 1, 2 and 3 wk) in our study, the Quickclip retention rate did

not significantly differ from that of the Resolution clip ($P = 0.17$). That is in contrast to what Jensen *et al* describe, although this could be due to a lack of power for this subgroup analysis in our study. Our result implies that short-term attachment directly after external mechanical exertion (endorectal applicator) is not significantly superior for the Resolution clip but that does seem to be the case in the period thereafter in which 40% of Resolution clips were visualized versus 7% of the Quickclips. This suggests that if the clip survives the applicator, the Resolution clip seems to survive longer.

Finally, we found the endoscopic clips useful in locating and marking the tumor borders for radiotherapy volume delineation and for optimizing the position of the endorectal brachytherapy applicator. Pfau *et al*^[10] recently reported similar promising results in optimizing radiotherapy volume delineation in esophageal cancer patients. However, a possible downside for the clinical use of endoclips is the fact that they are not magnetic resonance imaging (MRI)-compatible, having caused artifacts on MRI in our series.

In conclusion, in this small prospective study we evaluated long-term attachment of the Quickclip and the Resolution clip to human rectal mucosa. We found that up to two thirds of Resolution clips were visualized at follow up after a median of nearly 12 wk, illustrating their superior value in situations where long-term attachment is warranted.

COMMENTS

Background

The endoscopic application of metallic clips has successfully been implemented in the gastrointestinal (GI) tract for hemostasis. For this purpose, attachment of the endoclip for several days is adequate. More recently, endoclips have been used for fixation of enteral feeding tubes, stent anchorage, marking lesions and in the management of (anastomotic) leaks. For these purposes, longer retention periods are warranted but data on retention rates in the human gastrointestinal tract are missing.

Research frontiers

This study reports the endoclip retention rates of different endoclips in the human gastrointestinal tract.

Innovations and breakthroughs

To our knowledge, this is the first series in which retention rates are described in humans as previous studies have only reported rates from animal models.

Applications

The knowledge that the vast majority of Resolution clips remain attached for several weeks may facilitate procedures in which long-term attachment is

warranted, for instance when a tumor needs to be located routinely during the treatment period or when the clip anchors feeding tubes or stents.

Peer reviews

The results have been somewhat "over-analysed"; the number of patients studied was small and as the authors found out, the results did not lend themselves to logistic regression analysis.

REFERENCES

- 1 Hayashi T, Yonezawa M, Kuwabara T. The study on staunch clip for the treatment by endoscopy. *Gastrointest Endosc* 1975; **17**: 92-101
- 2 Binmoeller KF, Thonke F, Soehendra N. Endoscopic hemoclip treatment for gastrointestinal bleeding. *Endoscopy* 1993; **25**: 167-170
- 3 Yuan Y, Wang C, Hunt RH. Endoscopic clipping for acute nonvariceal upper-GI bleeding: a meta-analysis and critical appraisal of randomized controlled trials. *Gastrointest Endosc* 2008; **68**: 339-351
- 4 Frizzell E, Darwin P. Endoscopic placement of jejunal feeding tubes by using the Resolution clip: report of 2 cases. *Gastrointest Endosc* 2006; **64**: 454-456
- 5 Sebastian S, Buckley M. Endoscopic clipping: a useful tool to prevent migration of rectal stents. *Endoscopy* 2004; **36**: 468
- 6 Segalin A, Bonavina L, Bona D, Chella B. Endoscopic clipping: a helpful tool for positioning self-expanding esophageal stents. *Endoscopy* 1995; **27**: 348
- 7 Grupka MJ, Benson J. Endoscopic clipping. *J Dig Dis* 2008; **9**: 72-78
- 8 Eriksson LG, Sundbom M, Gustavsson S, Nyman R. Endoscopic marking with a metallic clip facilitates transcatheter arterial embolization in upper peptic ulcer bleeding. *J Vasc Interv Radiol* 2006; **17**: 959-964
- 9 Kim SH, Milsom JW, Church JM, Ludwig KA, Garcia-Ruiz A, Okuda J, Fazio VW. Perioperative tumor localization for laparoscopic colorectal surgery. *Surg Endosc* 1997; **11**: 1013-1016
- 10 Pfau PR, Pham H, Ellis R, Das A, Isenberg G, Chak A. A novel use of endoscopic clips in the treatment planning for radiation therapy (XRT) of esophageal cancer. *J Clin Gastroenterol* 2005; **39**: 372-375
- 11 Weyman RL, Rao SS. A novel clinical application for endoscopic mucosal clipping. *Gastrointest Endosc* 1999; **49**: 522-524
- 12 Shin EJ, Ko CW, Magno P, Giday SA, Clarke JO, Buscaglia JM, Sedrakyan G, Jagannath SB, Kalloo AN, Kantsevoy SV. Comparative study of endoscopic clips: duration of attachment at the site of clip application. *Gastrointest Endosc* 2007; **66**: 757-761
- 13 Jensen DM, Machicado GA, Hirabayashi K. Randomized controlled study of 3 different types of hemoclips for hemostasis of bleeding canine acute gastric ulcers. *Gastrointest Endosc* 2006; **64**: 768-773
- 14 Iida Y, Miura S, Munemoto Y, Kasahara Y, Asada Y, Toya D, Fujisawa M. Endoscopic resection of large colorectal polyps using a clipping method. *Dis Colon Rectum* 1994; **37**: 179-180

S- Editor Zhang HN L- Editor Roemmele A E- Editor Liu N