

Basketing a basket: A novel emergency rescue technique

Fazal Imtiaz Khawaja, Mohammed Mushtaque Ahmad

Fazal Imtiaz Khawaja, Mohammed Mushtaque Ahmad, Department of Gastroenterology and Hepatology, King Fahad Hospital, Al-Madinah Al-Munwarah 41441, Saudi Arabia

Author contributions: Khawaja FI performed the ERCP and revised the manuscript for final submission; Ahmad MM assisted with the ERCP and prepared the manuscript.

Correspondence to: Fazal Imtiaz Khawaja, MD, FACG, Department of Gastroenterology and Hepatology, King Fahad Hospital, PO Box 1925, Al Madinah Al Munawarah 41441, Saudi Arabia. drkhawaja@yahoo.com

Telephone: +966-4-8461500 Fax: +966-4-8445019

Received: December 25, 2011 Revised: July 15, 2012

Accepted: September 12, 2012

Published online: September 16, 2012

Atsushi Irisawa, MD, PhD, Associate Professor, Department of Internal Medicine 2, Fukushima Medical University School of Medicine. 1, Hikarigaoka, Fukushima 960-1295, Japan

Khawaja FI, Ahmad MM. Basketing a basket: A novel emergency rescue technique. *World J Gastrointest Endosc* 2012; 4(9): 429-431 Available from: URL: <http://www.wjgnet.com/1948-5190/full/v4/i9/429.htm> DOI: <http://dx.doi.org/10.4253/wjge.v4.i9.429>

Abstract

Fracture of the central lead wire of an impacted basket during a mechanical lithotripsy for large common bile duct (CBD) stones poses a special challenge. Different maneuvers have been described to resolve this problem. Most techniques require equipment or facilities which may not be readily available in small community hospitals. We present here a similar situation in a patient with a large stone at the level of the cystic duct. Through the duodenoscope, a smaller Dormia basket was introduced into the CBD along the side of the impacted broken basket. The tip of the impacted basket was grasped and, by pulling downwards, the basket was disengaged from the stone. The two baskets were then removed successfully. We suggest this simple technique should be tried initially, before resorting to more advanced procedures.

© 2012 Baishideng. All rights reserved.

Key words: Endoscopic retrograde cholangiopancreatography; Impacted Dormia basket; Mechanical lithotripsy; Fractured Dormia basket

Peer reviewers: Sanjiv Mahadeva, MBBS, MRCP, CCST, MD, Associate Professor, Department of Medicine, Faculty of Medicine, University of Malaya, Kuala Lumpur 50603, Malaysia;

INTRODUCTION

Endoscopic management is now the standard of care for primary management of common bile duct (CBD) stones causing biliary obstruction. Stones are successfully removed with Endoscopic Retrograde Cholangiopancreatography (ERCP) using a Dormia basket or balloon catheters in 85% to 90% of cases^[1]. ERCP is now available even in small community hospitals. The usual complications of ERCP are hyperamylasemia, acute pancreatitis, bleeding, perforation and infection. Difficulty during stone removal occurs when the stone is hard and large (> 1 cm) or when there is discrepancy between the stone size and diameter of the distal bile duct. The management of non-extractable CBD stones includes mechanical lithotripsy, electrohydraulic probe lithotripsy, extracorporeal shock wave lithotripsy, laser lithotripsy and stenting until definitive stone treatment^[2]. Impaction of a biliary basket due to a hard stone is not an uncommon complication, reported in 0.8-5.9% of cases^[3]. Mechanical lithotripsy usually solves the problem by crushing the stone. Rarely, fracture of the basket during lithotripsy occurs and poses a special management problem. While referral to a higher facility due to lack of equipment or expertise is well accepted by patients, emergency referral for procedural complications may not be acceptable and runs a risk of potential litigation. With this particular situation in the background, we describe here a maneuver to remove an impacted and fractured Dormia basket, which can easily convert an emergency situation to a more planned referral.

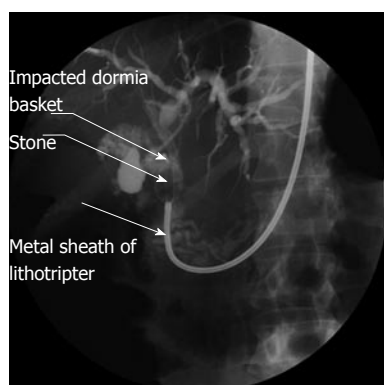

Figure 1 Impacted stone and the entrapped basket. A metal sheath of Soehendra type extra-endoscopic mechanical lithotripter was introduced to crush the stone.

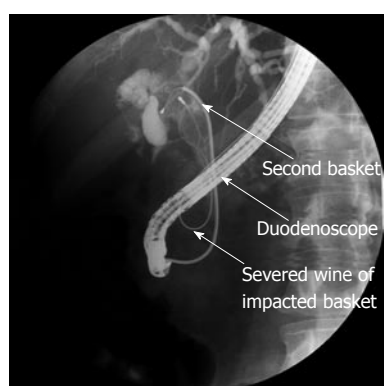


Figure 2 The second basket passed through the duodenoscope which was re-introduced, then advanced alongside the severed central wire of the first (entrapped) basket in order to catch the impacted one.

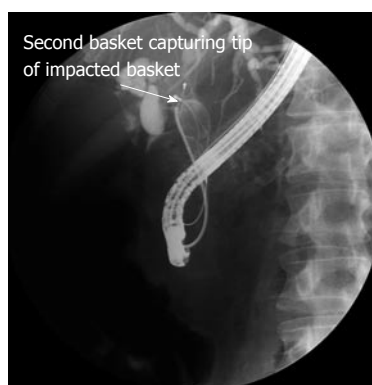

Figure 3 Tip of the impacted basket caught by the second basket.

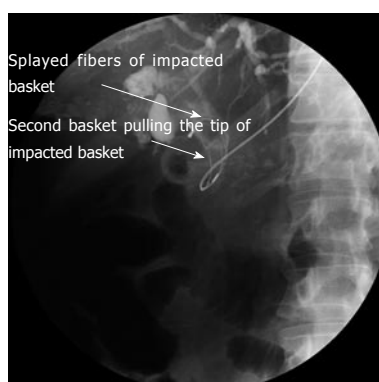


Figure 4 Splaying of impacted basket fibers during its disengagement from the stone.



Figure 5 Still image of the retrieved Dormia basket.

CASE REPORT

A 70-year-old Saudi male was admitted with a 1 wk history of colicky right upper quadrant pain and jaundice, associated with nausea and occasional vomiting. He had no past medical history. Physical examination revealed deep icterus, vitiligo on the forehead and tenderness in the right upper quadrant of the abdomen. Baseline investigations revealed high blood glucose (19.9 mmol/L) and raised total bilirubin (155 μ mol/L) and alkaline phosphatase (310 U/L). Other parameters were normal. Ultrasound abdomen reported a stone in left hepatic duct, measuring 1.5 cm in diameter. He was subjected to ERCP. The common hepatic duct was dilated with a stone at the level of the cystic duct and CBD junction. Further injection of dye displaced the common duct medially, confirming Mirizzi's syndrome. A Dormia basket (FG-23Q-1; Olympus) was advanced for a trial to remove the stone, which would otherwise need surgery. Unfortunately, it was stuck and could not be disengaged. The duodenoscope (TJF; Olympus) was withdrawn. In order to crush the stone, a metal sheath of extra-endoscopic lithotripter (MAJ-430; Olympus) was advanced over the basket wire after cutting away the handle and attached to Soehendra-type mechanical lithotripter handle (BML-

110A-1; Olympus) (Figure 1). However, upon cranking, the central wire of the Dormia basket severed at the proximal end just outside the oral cavity. The lithotripter was withdrawn and the duodenoscope re-introduced. Another Dormia basket was introduced along the side of the severed central wire and caught the upper tip of impacted basket (Figure 2). It was then pushed in the cephalad direction and the trapped basket flipped down (Figure 3), in order to splay the wires of impacted basket sideways. Subsequently, the trapped and severed basket disengaged from the stone and was removed (Figures 4 and 5). A plastic

stent (7 Fr) was inserted in the CBD to relieve obstruction and later the patient was subjected to surgical treatment.

DISCUSSION

Surgical treatment is the gold standard for Mirizzi's syndrome. However, an endoscopic attempt to remove the impacted stone will help in biliary drainage. Stone extraction using a Dormia basket and mechanical lithotripsy is a simple choice^[4]. Other reported endoscopic approaches for Mirizzi's syndrome include electrohydraulic lithotripsy^[5]. A junctional stone larger than the distal narrow CBD is at high risk of basket entrapment. However, the majority of these problems are resolved by mechanical lithotripsy. Although this might encourage the endoscopist to take a more aggressive approach, it is wise to avoid all temptation to use a basket unless reasonable facilities and expertise are available for advanced lithotripsy.

A fractured biliary basket is a rare but well known problem during ERCP for stone extraction and urological procedures. In the past, surgical intervention was the standard management. Non-surgical techniques to release the impacted stone and basket have been increasingly reported. If the stone is impacted at the papilla, extending the sphincterotomy might be enough. Spontaneous passage of the impacted basket and stone after successful biliary stent placement has also been reported^[6]. Lithotripsy to break the impacted stone and release the basket has been the most common approach used with success. Extra-endoscopic mechanical lithotripsy, extracorporeal shock wave lithotripsy^[7], endoscopic pulse-dye laser^[8,9] and transhepatic choledochoscopic lithotripsy^[10] have all been reported. Some of these techniques involve other specialties and may require shifting the patient to another facility on an emergency basis. In our case, we simply used another basket which is universally available. This technique is simple, cheap and does not need any special equipment or extra training. The endoscopic procedural complication was resolved immediately and without surgery. A similar case has been described before, where a second basket was used successfully to retrieve a severed basket with an impacted stone^[11]. Recently, Ryozaawa *et al*^[12]

used rat-tooth forceps to catch the basket fibers and disengage the trapped basket. Because ERCP is done under one dimensional fluoroscopy guidance, we feel that using forceps carries a higher risk of inadvertent injury to the bile duct compared to a basket. The main drawback of the technique we described is that, unlike other lithotripsy procedures, the stone still remains *in situ*. Nevertheless, the simplicity of the maneuver makes it a worthwhile first line salvage technique before referring the patient for more complicated and invasive procedures.

REFERENCES

- 1 **Cotton PB.** Endoscopic management of bile duct stones; (apples and oranges). *Gut* 1984; **25**: 587-597
- 2 **Hochberger J, Tex S, Maiss J, Hahn EG.** Management of difficult common bile duct stones. *Gastrointest Endosc Clin N Am* 2003; **13**: 623-634
- 3 **Siegel JH.** Stone extraction. In: Siegel JH, editor. Endoscopic retrograde cholangiopancreatography: Technique, diagnosis, and therapy. New York: Raven Press, 1992: 243
- 4 **England RE, Martin DF.** Endoscopic management of Mirizzi's syndrome. *Gut* 1997; **40**: 272-276
- 5 **Seitz U, Bapaye A, Bohnacker S, Navarrete C, Maydeo A, Soehendra N.** Advances in therapeutic endoscopic treatment of common bile duct stones. *World J Surg* 1998; **22**: 1133-1144
- 6 **Maple JT, Baron TH.** Biliary-basket impaction complicated by in vivo traction-wire fracture: report of a novel management approach. *Gastrointest Endosc* 2006; **64**: 1031-1033
- 7 **Merrett M, Desmond P.** Removal of impacted endoscopic basket and stone from the common bile duct by extracorporeal shock waves. *Endoscopy* 1990; **22**: 92
- 8 **Schreiber F, Gurakuqi GC, Trauner M.** Endoscopic intracorporeal laser lithotripsy of difficult common bile duct stones with a stone-recognition pulsed dye laser system. *Gastrointest Endosc* 1995; **42**: 416-419
- 9 **Neuhaus H, Hoffmann W, Classen M.** Endoscopic laser lithotripsy with an automatic stone recognition system for basket impaction in the common bile duct. *Endoscopy* 1992; **24**: 596-599
- 10 **Fujita R, Yamamura M, Fujita Y.** Combined endoscopic sphincterotomy and percutaneous transhepatic cholangioscopic lithotripsy. *Gastrointest Endosc* 1988; **34**: 91-94
- 11 **Ranjeew P, Goh K.** Retrieval of an impacted Dormia basket and stone in situ using a novel method. *Gastrointest Endosc* 2000; **51**: 504-506
- 12 **Ryozaawa S, Iwano H, Taba K, Senyo M, Sakaida I.** Successful retrieval of an impacted mechanical lithotripsy basket: a case report. *Dig Endosc* 2010; **22** Suppl 1: S111-S113

S- Editor Song XX L- Editor Roemmele A E- Editor Zheng XM