

## Novel serine/threonine kinase 11 gene mutations in Peutz-Jeghers syndrome patients and endoscopic management

Hiroyuki Yajima, Hajime Isomoto, Hiroaki Nishioka, Naoyuki Yamaguchi, Ken Ohnita, Tatsuki Ichikawa, Fuminao Takeshima, Saburo Shikuwa, Masahiro Ito, Kazuhiko Nakao, Kazuhiro Tsukamoto, Shigeru Kohno

Hiroyuki Yajima, Shigeru Kohno, Department of Molecular Microbiology and Immunology, Nagasaki University Graduate School of Biomedical Sciences, Nagasaki University School of Medicine, Nagasaki 852-8501, Japan

Hajime Isomoto, Naoyuki Yamaguchi, Ken Ohnita, Tatsuki Ichikawa, Fuminao Takeshima, Saburo Shikuwa, Kazuhiko Nakao, Department of Gastroenterology and Hepatology, Nagasaki University School of Medicine, Nagasaki 852-8501, Japan

Hiroaki Nishioka, Kazuhiro Tsukamoto, Department of Pharmacotherapeutics, Nagasaki University Graduate School of Biomedical Sciences, Nagasaki University School of Medicine, Nagasaki 852-8521, Japan

Masahiro Ito, Department of Pathology, National Nagasaki Medical Center, Omura, Nagasaki 856-0835, Japan

**Author contributions:** Isomoto H and Tsukamoto K contributed to study design; Yajima H, Nishioka H, Ohnita K, Shikuwa S and Ito M contributed to data collection; Yamaguchi N and Ichikawa T contributed to statistical analysis; Takeshima F and Nakao K contributed to data interpretation; Isomoto H, Yajima H and Kohno S contributed to manuscript preparation; Isomoto H, Yajima H and Tsukamoto K contributed to literature search.

**Correspondence to:** Hajime Isomoto, MD, Department of Gastroenterology and Hepatology, Nagasaki University School of Medicine, 1-7-1 Sakamoto, Nagasaki 852-8501, Japan. [hajime2002@yahoo.co.jp](mailto:hajime2002@yahoo.co.jp)

Telephone: +81-95-8199481 Fax: +81-95-8197482

Received: June 8, 2012 Revised: December 5, 2012

Accepted: December 15, 2012

Published online: March 16, 2013

### Abstract

**AIM:** To explore mutations in serine/threonine kinase 11 (*STK11*) gene in Peutz-Jeghers syndrome (PJS) with gastrointestinal (GI) hamartomatous polyps.

**METHODS:** Six Japanese PJS patients in 3 families were enrolled in this study. Each of the cases had hamartomatous polyposis in the gastrointestinal tract, including the small intestine, along with mucocutaneous

hyperpigmentation. Narrow-band imaging (NBI)-magnification endoscopy was employed to detect microvascular and microsurface irregularities in the GI lesions. NBI magnification findings could be classified into three groups (type A, type B, or type C). Endoscopic polypectomy was performed using double-balloon enteroscopy or colonoscopy. Genomic DNA was extracted from a whole blood sample from each subject. All of the coding exons of *STK11* gene, its boundary regions, and the promoter region containing the polymorphic regions were amplified by polymerase chain reaction, and direct sequencing was performed to assess the germline mutations.

**RESULTS:** NBI-magnification endoscopic observation could detect the abnormalities in microvessels and microsurface structures of GI polyps. Overall, we found 5 cases of type A and one case without the examination for the gastric polyps, while there were 4 cases of type B and 2 case of type A for the colorectal polyps. Seventy-nine small-bowel and 115 colorectal polyps over 27 sessions for each were resected endoscopically without significant complications. The only delayed complication included the occurrence of bleeding in a case, and this was successfully managed with hemoclips. Resected polyps contained no malignant components. Based on mutation analysis, all 3 cases in Family I exhibited the +658C>T nonsense mutation in exon 5, which resulted in the production of a truncated protein (Q220X). In Family II, a case had -252C>A and -193C>A in the promoter region. In Family III, a case was found to have the +1062C>G (F342L) mutation in exon 8.

**CONCLUSION:** We found two novel mutations of *STK11* in association with PJS. Endoscopic polypectomy of GI polyps in PJS patients appears to be useful to prevent emergency laparotomies and reduce the cancer risk.

© 2013 Baishideng. All rights reserved.

**Key words:** Peutz-Jeghers syndrome; Serine/threonine kinase 11; Gastrointestinal hamartomatous polyps; Double-balloon enteroscopy; Narrow-band imaging

Yajima H, Isomoto H, Nishioka H, Yamaguchi N, Ohnita K, Ichikawa T, Takeshima F, Shikuwa S, Ito M, Nakao K, Tsukamoto K, Kohno S. Novel serine/threonine kinase 11 gene mutations in Peutz-Jeghers syndrome patients and endoscopic management. *World J Gastrointest Endosc* 2013; 5(3): 102-110 Available from: URL: <http://www.wjgnet.com/1948-5190/full/v5/i3/102.htm> DOI: <http://dx.doi.org/10.4253/wjge.v5.i3.102>

## INTRODUCTION

Peutz-Jeghers syndrome (PJS) is a rare autosomal-dominant hereditary condition with incomplete penetrance that is characterized by hamartomatous polyps of the gastrointestinal (GI) tract and pigmented lesions of the buccal mucosa, perioral region and other sites<sup>[1,2]</sup>. Variable penetrance and clinical heterogeneity make it difficult to determine the exact frequency of PJS<sup>[2]</sup>. Most PJS patients develop significant hamartomatous polyps of the small bowel, with these polyps commonly arising in the stomach and colorectum. PJS patients also have an increased risk of cancer at multiple locations, although it is predominantly found in the colon, small intestine, stomach, esophagus, pancreas, breast, ovary and uterine cervix<sup>[3,4]</sup>.

PJS occurrence is primarily associated with germline mutations in the serine/threonine kinase 11 (*STK11/LKB1*) gene, which are localized on the chromosomal segment 19p13.3<sup>[5,6]</sup>. The gene spans 23 kb, and consists of nine coding exons and a final noncoding exon<sup>[3,6]</sup>. The coded protein plays a role in cellular energy metabolism, cell polarization, p53-dependent apoptosis, and Wnt signal transduction<sup>[3,7-9]</sup>. The germline mutation detection rates in PJS patients vary among reports<sup>[1]</sup>, but recent studies which have searched for germline mutations using state-of-art techniques demonstrate between 80% and 94%<sup>[10-12]</sup>. Most mutations are single base substitutions/insertions or small deletions that result in an abnormal truncated protein<sup>[1,3,10-12]</sup>.

Narrow-band imaging (NBI) is a recent innovative optical technique that modifies the center wavelength and bandwidth of an endoscope's light in order to produce narrow-band illuminations of 415 and 540 nm<sup>[13,14]</sup>. When combined with magnifying endoscopic observation, NBI can markedly improve the capillary pattern contrast. Use of this *in vivo* method makes it possible to visualize microvascular morphological changes that take place in the superficial neoplastic lesions<sup>[14-16]</sup>. Several studies have reported on the advantages of using magnification endoscopy NBI for diagnosis of gastrointestinal neoplasia<sup>[17]</sup>. Additionally, studies have also shown that when magnification chromoendoscopy is used in combination with crystal violet staining, the information obtained can be used to diagnose gastrointestinal tumors<sup>[18]</sup>.

However, PJS patients are subject to serious complications such as intussusception and bleeding from the GI, in particular from small intestinal polyps<sup>[19]</sup>. Therefore, many of these patients often need to undergo multiple laparotomies with intestinal resection, which can ultimately result in short-bowel syndrome and/or severe adhesions<sup>[20,21]</sup>. In order to control these small-bowel polyps, a combined endoscopic and surgical treatment procedure has been designed for use in these patients<sup>[22,23]</sup>. Even with the new treatment regimen, however, many of these patients still end up undergoing multiple surgical treatments because of the appearance of new lesions or the growth of existing polyps. Double-balloon endoscopy (DBE) was developed as a new technique for visualization of, and intervention in the lesions that occur throughout the entire small intestine<sup>[24]</sup>. DBE has been reported worldwide to be useful for both diagnosis and treatment of small intestinal polyps<sup>[25]</sup>. As such, the use of DBE could potentially be a means of providing prophylactic polypectomy in PJS patients, thereby helping to prevent the intussusception and bleeding complications<sup>[26,27]</sup>.

In the current study, we performed a mutation analysis of STK11 in three PJS families. This study also presents data on the magnified endoscopy findings and the endoscopic treatments for the polyps.

## MATERIALS AND METHODS

### Subjects

PJS patients in 3 families were enrolled in this study (Figure 1). The PJS diagnosis was based upon clinical criteria proposed in 1987<sup>[28]</sup>.

To definitively diagnose PJS in individuals with histopathologically confirmed hamartoma, two of the following three findings are required: (1) family history consistent with autosomal dominant inheritance; (2) mucocutaneous hyperpigmentation; and (3) small-bowel polyposis. In the current study, each of the cases had hamartomatous polyposis in the gastrointestinal tract, including the small intestine, along with mucocutaneous hyperpigmentation on the hands, feet or lips.

### Magnifying endoscopy

We performed NBI magnification gastroscopy and colonoscopy in each PJS case. The endoscopic system included a light source (CLV-260SL; Olympus, Tokyo, Japan), a processor (CV-260SL; Olympus), and a high-resolution magnifying endoscope (GIF-H260Z for the stomach and CF-H260AZI for the colorectum; Olympus). The unique features of PJS polyp are best appreciated in the larger PJS small intestine polyps, but the other polyps do not have specific gastrointestinal endoscopic findings. They can be similar to hyperplastic polyps<sup>[29]</sup>. Recently, Lam-Himlin *et al*<sup>[30]</sup> investigated the histologic features of gastric polyps in patients with established PJS to develop improved histologic criteria to distinguish these from gastric hyperplastic polyps. Histologic features to distinguish gas-

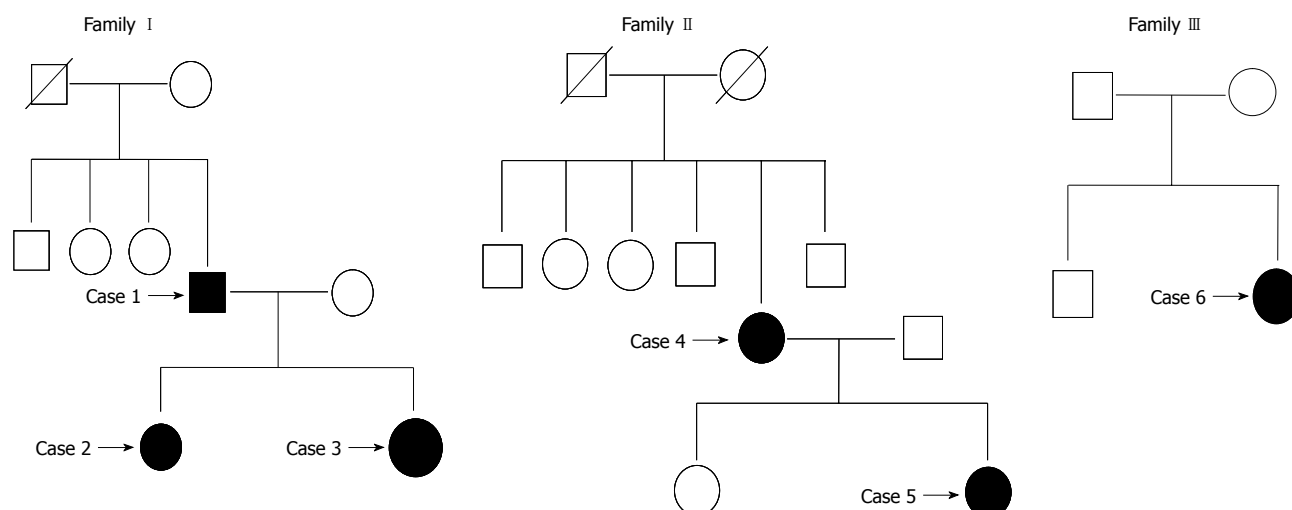


Figure 1 Each pedigree of the three families with Peutz-Jeghers syndrome.

tric PJS from gastric hyperplastic polyps were unreliable. There has been no available NBI classification for gastric non-neoplastic polyps including hamartomatous and hyperplastic polyps. Kanao *et al*<sup>[17]</sup> reported that NBI magnification findings could be classified into three groups (type A, type B, or type C) based on their microvessel architecture and pit appearance. In type A lesions, microvessels are not observed or are extremely opaque. Type B lesions exhibit fine microvessels around the pits, with clear pits observed *via* a nest of microvessels. Type C lesions exhibit irregular microvessels in which the vessel diameters or distributions are heterogeneous. Type C can be further divided into 3 subtypes (C1, C2, and C3) based on the detailed NBI magnification findings for the pit visibility, vessel diameter, irregularity, and distribution. Lesions are considered to be subtype C1 when the microvessels comprise an irregular network, the pits are slightly non distinct when observed *via* the microvessels, and the vessel diameters or distributions are homogeneous. For the C2 subtype, microvessels comprise an irregular network, the pits are irregular when observed *via* the microvessels, and the vessel diameters or distributions are heterogeneous. For the type C3 subtype, the pits *via* the microvessels are invisible, the irregular vessel diameters are thick or there is a heterogeneous vessel distribution, along with the observation of avascular areas.

#### Procedures of polypectomy *via* DBE and colonoscopy

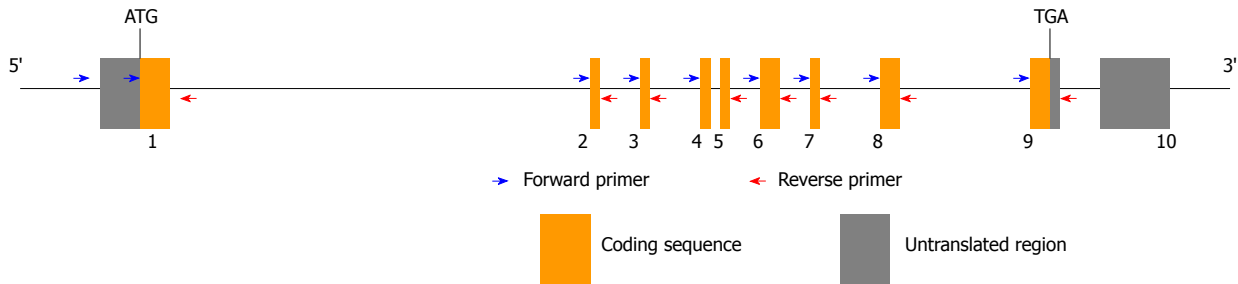
For the small intestinal polyps, we used an EN-450T5/W double-balloon endoscope (Fujifilm, Tokyo, Japan), which has an accessory channel that is 2.8 mm in diameter. This scope made it possible to use a variety of therapeutic devices, including an endoscopic hemoclip. For polypectomy of the colorectal polyps, we used a CF-Q260AI colonoscope (Olympus). All of the procedures were performed by specialists (Yajima H, Isomoto H, Ohnita K, Shikuwa S). While moderate sedation with a combination of intravenous pethidine and diazepam

and/or midazolam was administered to most patients, general anesthesia was used in symptomatic intussusception cases. A combined oral and anal approach was performed during the first session. If polyps were recognized, careful observation was performed in order to determine their size, shape, and location. Resected polyp sizes were estimated by visual measurement. To avoid post-polypectomy bleeding and thermal injury of the deeper tissue layers, a saline-epinephrine solution (0.9% sodium chloride, 0.001% epinephrine, 0.002% indigo carmine) was injected, as needed, into the submucosal layer of the stalk and the base of the polyp prior to the polypectomy. Snare cautery polypectomy was performed using commercially available snares up to 33 mm in diameter.

#### Polymerase chain reaction and direct sequencing

After obtaining written informed consent, a whole blood sample was collected from all the patients for the analysis of the *STK11* gene mutation. Genomic DNA was extracted from a whole blood sample from each subject using a DNA Extractor WB-Rapid Kit (Wako, Osaka, Japan) in accordance with the manufacturer's protocol. All of the coding exons of the *STK11* gene, its boundary regions, and the promoter region containing the polymorphic regions were amplified by polymerase chain reaction (PCR) (Figure 2). Amplification was performed with a GeneAmp PCR System 9700 thermal cycler (Life Technologies, Carlsbad, CA) using 20 ng genomic DNA in a 25- $\mu$ L reaction mixture containing 1X GoTaq Green Master Mix (Promega, Madison, WI) and 15 pmol each of forward and reverse primers (Table 1). The amplification protocol consisted of initial denaturation at 95 °C for 2 min, followed by 35 cycles of denaturation at 95 °C for 30 s, annealing at 64 °C for 30 s, extension at 72 °C for 30 s, and a final extension at 72 °C for 5 min.

The PCR products were treated with ExoSAP-IT (Amersham Pharmacia Biotech, Piscataway, NJ) and then cycle sequenced using a BigDye Terminator v3.1 Cycle



**Figure 2** Sites of primers which are employed for polymerase chain reaction and direct sequencing to assess germline mutations of serine/threonine kinase 11 gene.

**Table 1** Sequences of forward and reverse primers which are employed for analysis of germline mutations of serine/threonine kinase 11 gene

Primer	Sequence
STK11-5UTR-F	GGCCGTGTTTCATCTGTCC
STK11-Ex1-F	GTCGGAACACAAGGAAGGAC
STK11-Ex1-R	GACCCAGCAAGCCATACT
STK11-Ex2-F	TCCCACAGCACTGTGAATC
STK11-Ex2-R	ATTGCCACAATGGCTGACTT
STK11-Ex3-F	TTTCAGAGGGGTGGCTGAG
STK11-Ex3-R	CTGGCGACAGAGTGAGACT
STK11-Ex3-R-2	CAGAAGAATGGCGTGAACCT
STK11-Ex4-5-F	GCTGGACCTAGCCTTTCCTC
STK11-Ex4-5-R	ACCACCATCTGCCGTATGAG
STK11-Ex6-F	TGGTGAAGACAGAGGTGTCC
STK11-Ex6-R	AGTTCGGAGGGTGAACAGG
STK11-Ex7-F	AGGAGTGGAGTGGCCTCTGT
STK11-Ex7-R	AACAGGACACTGCCAGAGA
STK11-Ex8-F	ATGGCTGAGCTTCTGTGGTC
STK11-Ex8-R	CCACACCTTTTCAGCCATGT
STK11-Ex9-F	GCAGCATTTTCAGGCTGGATA
STK11-Ex9-R	ACGTAGGCCTCCATGACCA

STK11: Serine/threonine kinase 11.

Sequencing FS Ready Reaction Kit (Life Technologies). The cycle sequencing was hot-started at 96 °C for 30 s, followed by 25 cycles of denaturation at 96 °C for 10 s, annealing at 50 °C for 5 s, and extension at 60 °C for 4 min using 1 pmol PCR forward or reverse primer. Sequencing reaction solutions were purified using Sephadex G-50 superfine columns (Amersham Pharmacia Biotech), followed by drying and sequencing of the samples with an ABI Prism 3100 Genetic Analyzer (Life Technologies). All of the coding exons of the *STK11* gene, its boundary regions, and the promoter region were amplified by PCR in accordance with the standard literature methods. PCR was carried out in a total volume of 100 µL containing 200 ng of genomic DNA, 80 pmol of each primer, 100 µmol/L of each deoxyribonucleoside triphosphate, 1.5 µmol/L of magnesium chloride, 10 µL of 10X PCR buffer and 1.0 U of Taq DNA polymerase. The amplification conditions were 95 °C for 5 min, followed by 30 cycles of 94 °C for 30 s, 55 °C for 45 s, 72 °C for 1 min, with a final extension at 72 °C for 10 min in a thermal cycler.

### Statistical analysis

Data were shown as mean and range.

## RESULTS

The proband in Family I was a 52-year-old male (Case 1) without malignancy, who underwent a laparotomy for polypectomy of small intestinal polyps. His 26-year-old daughter was diagnosed as having cervical cancer, and subsequently underwent hysterectomy (Case 2). In addition, this daughter also underwent laparotomy four times for polypectomy of small intestinal polyps and related intussusceptions. Another daughter, who is 22 years old, has had no reported malignancies as of the present time (Case 3), although she has undergone laparotomy for polypectomy of small intestinal polyps. In Family II, a 65-year-old female (Case 4) was diagnosed with pancreatic cancer, and underwent pancreatoduodenectomy. After further being diagnosed with intraepithelial neoplasia, she underwent an endoscopic submucosal dissection, and had a laparotomy for polypectomy of small intestinal polyps. Her 37-year-old daughter (Case 5) was diagnosed with colon cancer, and had a colectomy. Subsequently, she was also found to have a benign ovarian tumor, in addition to undergoing laparotomy on three separate occasions for polypectomy of small intestinal polyps and related intussusceptions. In Family III, a laparotomy was performed in a 27-year-old female who at the present time has exhibited no malignancies (Case 6).

### Magnified endoscopic findings

Table 2 summarizes the NBI magnification endoscopic findings. Overall, we found 5 cases of type A (Figure 3A) and one case without the examination for the gastric polyps, while there were 4 cases of type B (Figure 3B) and 2 case of type A for the colorectal polyps.

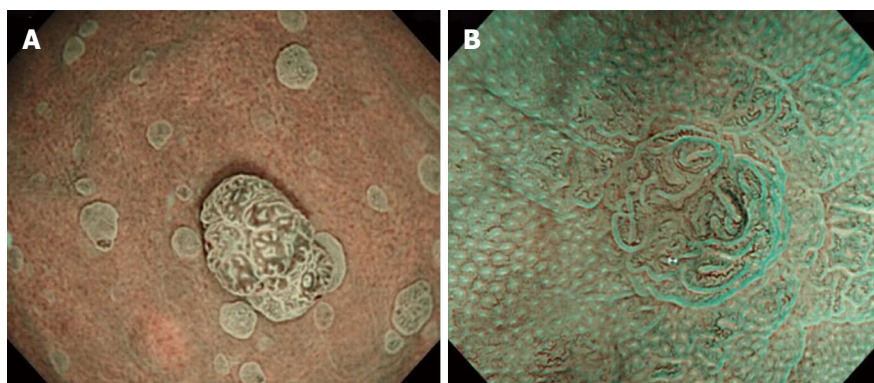
### Polypectomy

As seen in Table 3, we resected a total of 79 small-bowel polyps over 27 sessions, with a mean number of resected polyps per patient of 13.2 (range 1 to 31). The only delayed complication noted in the PJS patients was the occurrence of bleeding in Case 6, and this was successfully managed with hemoclips. Otherwise, there were no serious complications related to the therapeutic DBE. A total of 115 colorectal polyps were resected over 27 sessions, with the mean number of resected polyps per patient calculated to be 19.2 (range 0 to 39). There were also no complications associated with the colorectal pol-



**Table 2** Numbers of gastrointestinal polyps in the stomach, small intestine and colorectum, and narrow-band imaging magnification endoscopic findings of the gastric and colorectal lesions

Family	Case No.	Polyps			Narrow-band imaging magnification type	
		Stomach	Small intestine	Colorectum	Stomach	Colorectum
I	1	Sporadic	Multiple	Multiple	NE	A
	2	Multiple	Multiple	Multiple	A	B
	3	Sporadic	Sporadic	Multiple	A	B
II	4	Multiple	Multiple	Multiple	A	B
	5	Multiple	Multiple	Multiple	A	B
III	6	Multiple	Solitary	Sporadic	A	A

**Figure 3** Narrow-band imaging-magnification gastroscopic picture. A: Narrow-band imaging (NBI)-magnification gastroscopic picture showing type A of the classification; B: NBI-magnification colonoscopic picture showing type B of the classification.**Table 3** Numbers and sizes of the small-bowel and colorectal polyps that were resected endoscopically and session times of polypectomy

Family	Case No.	Polypectomy for the small intestinal polyps			Polypectomy for the colorectal polyps		
		Times	<i>n</i>	Size (mm)	Times	<i>n</i>	Size (mm)
I	1	5	21	10-35	6	10	5-15
	2	7	31	10-25	6	39	5-10
	3	1	1	20	1	3	5
II	4	6	10	10-20	10	54	5-10
	5	7	15	10-30	4	9	5-10
III	6	1	1	50	0	0	-

ypectomies. The resected polyps varied in size among the PJS patients, and histopathologically, no malignant components were found within these resected polyps.

### STK11 gene mutation

All 3 cases in Family I exhibited the +658C>T nonsense mutation in exon 5 (Figure 4), which resulted in the production of a truncated protein (Q220X). In Family II, Case 4 had -252C>A and -193C>A in the promoter region, while no germline mutations were noted for Case 5. In Family III, Case 6 was found to have the +1062C>G (F342L) mutation in exon 8.

## DISCUSSION

Mutations in the *STK11* gene on chromosome 19p13.3 have been identified as the cause of PJS<sup>[3,5,6]</sup>. *STK11* is a highly conserved gene that extends over 23 kb and con-

sists of nine exons, and one non-coding exon, coding for a 433-amino acid coding sequence and one non-coding exon<sup>[1,3,5,6]</sup>. *STK11* protein is primarily composed of three major domains, including an N-terminal non-catalytic domain, a catalytic kinase domain and a C-terminal regulatory domain<sup>[1,3,5-9]</sup>. Although the exact function of *STK11* as of yet remains unclear, prior studies have demonstrated that a mutation in the *STK11* gene can lead to a loss of kinase activity<sup>[1,3,5-9,31]</sup>. This loss of activity is most likely responsible for the development of the PJS phenotype. Codons 50-337 are responsible for encoding the catalytic kinase domain. It has been proposed that the *STK11* gene may act as a tumor suppressor gene and thus, could be involved in early development of the pathogenesis in which hamartomas are converted into adenocarcinoma<sup>[32-34]</sup>. In our study, we identified *STK11* mutations in both Families I and III. These mutations have never been reported in any database or in any pre-

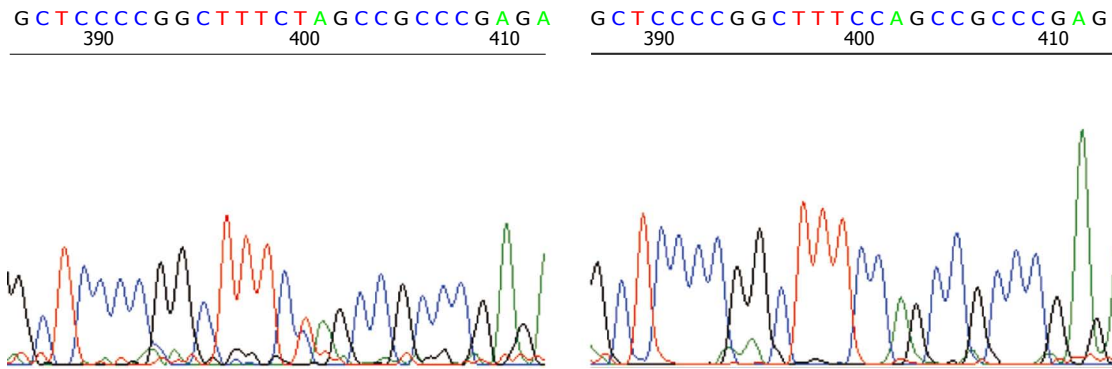


Figure 4 Serine/threonine kinase 11 germline mutation of +658C>T in exon5 that was identified in all the 3 Peutz-Jeghers syndrome patients in Family I.

viously published articles, which indicates that they are novel mutations. In particular, the +658C>T nonsense mutation that was found in exon 5 in the Family I results in a truncated protein that may be non-functional due to a loss of the kinase activity. More recently, Salloch *et al*<sup>[35]</sup> have shown that patients who have a truncating mutation in the *STK11* gene were more severely affected from the disease as compared with the patients with a non-truncating mutation. These findings suggest when the mutation is present, there is a tendency to have more carcinomas and polyps, in addition to having a significantly increased number of surgical interventions. In a further study that examined a larger number of subjects, a total of 240 PJS patients with the *STK11* mutation were analyzed<sup>[3]</sup>. Even though no differences were seen between individuals with missense and truncating mutations, or between familial and sporadic cases, the results did suggest that there was a higher risk of cancer in individuals with mutations in exon 3 of the gene<sup>[3]</sup>. On the other hand, a larger study found that the type and site of *STK11* mutation did not influence cancer risk<sup>[36]</sup>. Since we only examined a small series of PJS patients, it was not possible to assess the potential genotype-phenotype correlations in the current study.

The +1062C>G (F342L) mutation seen in exon 8 in Case 6 is a missense mutation that results in the F342L amino acid substitution. Since this mutation was not involved in the codons that encode the catalytic kinase domain, it might not affect the *STK11* functions. This may explain the relatively indolent phenotypes, including the sparse distribution and paucity of the gastrointestinal polyps that were seen in Case 6. Amos *et al*<sup>[37]</sup> suggested that individuals with these missense mutations have a later onset of symptoms as compared to those individuals with the other *STK11* mutations. Clearly, further studies are warranted in order to be able to definitively clarify the biologic significance of these non-truncating mutations.

Family II patient cases had multiple gastrointestinal polyps and more serious, complicated malignancies. Nevertheless, we could not detect any mutations in these subjects. While the absence of *STK11* mutations does occasionally occur in some PJS patients, the reason for this remains unclear at the present time. *STK11/LKB1* gene mutation is found in approximately 30%-70% of

sporadic cases of PJS and 70% of affected individuals with a family history of the condition<sup>[1]</sup>. Recent studies have attempted to use the multiplex ligation dependent probe amplification analysis to screen for gene and exon scale mutations in a set of PJS cases in which the *STK11* mutations could not be detected. These studies showed that the detection rates of *STK11* mutations in PJS patients tended to be higher, with rates reaching nearly 80%-94%<sup>[10-12]</sup>. It is likely that with continued improvements in genetic testing that mutation detection rates will improve further, making genetic heterogeneity even less likely. The lack of identification of a *STK11* gene mutation also suggests genetic mosaicism or additional PJS loci<sup>[1,38,39]</sup>.

PJS is associated with an increased risk of gastrointestinal and nongastrointestinal malignancies<sup>[1,3,4,28,36]</sup>. The most common sites for malignancy include colorectal, breast, stomach, small bowel, and pancreas. Since gastrointestinal hamartomatous polyps are benign, they were not initially thought to represent a premalignant condition<sup>[1,3,4]</sup>. However, several studies have shown that the distribution of the gastrointestinal cancers in PJS patients is similar to that of the hamartomatous polyps, in addition to clearly documenting that carcinoma arises in hamartomas<sup>[40,41]</sup>. As a result, surveillance GI endoscopy is now recommended for detection of cancer<sup>[3]</sup>. Moreover, the ability to be able to predict the histologic grade and invasion depth of gastrointestinal neoplastic lesions is of clinical importance. The NBI magnification classification scheme that was proposed by Kanao *et al*<sup>[17]</sup> has proven to be useful for both predicting the histology and for selecting optimal therapeutic strategies. In Kanao's study, they examined the sensitivity and specificity of the various lesions for diagnosing carcinomas. Their results showed that the sensitivities and specificities of the type A lesions for hyperplastic polyps were 100% and 98.9%, while the type B lesions for tubular adenoma were 85.5% and 71.0%, respectively. The sensitivities and specificities of the type C1 lesions for diagnosis of tubular adenoma or mucosal/minimally invasive colorectal cancer diagnosis were 80.0% and 89.4%, while for the type C3 lesions for the diagnosis of carcinoma with massive submucosal invasion, they were 63.8% and 100%, respectively. Based on these findings, endoscopic resection should be select-

ed when type B and C1 lesions are present, while surgical resection should be selected for type C3 lesions. In the current study, we diagnosed the gastric polyps observed in our patients according to the NBI-based classification. As seen in Table 2, all of these polyps were classified as type A in each of the cases and thus, they did not require further treatment. This suggests all of these polyps were of a hyperplastic (hamartomatous) histology type. On the other hand, the colorectal polyps were classified as B type polyps, and since they were larger than 5 mm in size, they were endoscopically resected. Regardless of the treatment, there were no complications noted in our series.

Small-bowel polyps are the most significant clinical feature of PJS<sup>[1,3,4,19]</sup>. These hamartomas can lead to complications such as bowel obstruction and severe GI bleeding, which necessitates multiple emergency laparotomies and bowel resections<sup>[20,21]</sup>. In the present study, 5 out of 6 cases had one or more laparotomies due to intussusception or other significant symptoms. Therefore, when small-bowel polyps were more than 10 mm in size in PJS patients, we performed endoscopic resection using DBE. In the current study, a total of 79 small-bowel polyps were safely resected without serious complications in any of the patients. However, in another study that examined a larger number of PJS cases, the total complication rate after therapeutic DBE was performed was relatively higher, with 6.8% of the patients exhibiting complications<sup>[19]</sup>. When taken together with the findings for our small case series, these results justify performing a future prospective multicenter study that is specifically designed to examine PJS patient treatment protocols.

We report two novel mutations of STK11 that are associated with PJS. Endoscopic management of GI polyps in PJS patients using DBE or colonoscopy appears to be both safe and effective, and may help to prevent emergency laparotomies and reduce the cancer risk. Additionally, NBI magnification endoscopic observation provides helpful information that can be used to select optimal therapeutic strategies for GI tumors in PJS.

## COMMENTS

### Background

Peutz-Jeghers syndrome (PJS) is an autosomal-dominant hereditary condition characterized by gastrointestinal (GI) hamartomatous polyps and mucocutaneous pigmentation. Mutations in the serine/threonine kinase 11 (*STK11*) gene play a causal role in PJS. Endoscopic polypectomy of GI polyps may help to prevent emergency laparotomies and reduce PJS-related cancer risk.

### Research frontiers

PJS occurrence is primarily associated with germline mutations in the *STK11/LKB1* gene, which are localized on the chromosomal segment 19p13.3. The gene spans 23 kb, and consists of nine coding exons and a final noncoding exon. The coded protein plays a role in cellular energy metabolism, cell polarization, p53-dependent apoptosis, and Wnt signal transduction. The germline mutation detection rates in PJS patients vary among reports, but recent studies which have searched for germline mutations using state-of-art techniques demonstrate between 80% and 94%. Most mutations are single base substitutions/insertions or small deletions that result in an abnormal truncated protein.

### Innovations and breakthroughs

Although the exact function of STK11 as of yet remains unclear, prior studies have demonstrated that a mutation in the *STK11* gene can lead to a loss of

kinase activity. This loss of activity is most likely responsible for the development of the PJS phenotype. Codons 50-337 are responsible for encoding the catalytic kinase domain. In the study, the authors identified *STK11* mutations in two families. These mutations have never been reported in any database or in any previously published articles, which indicates that they are novel mutations. In particular, the +658C>T nonsense mutation that was found in exon 5 results in a truncated protein that may be non-functional due to a loss of the kinase activity. The +1062C>G (F342L) mutation seen in exon 8 is a missense mutation that results in the F342L amino acid substitution. Since this mutation was not involved in the codons that encode the catalytic kinase domain, it might not affect the *STK11* functions, suggesting that individuals with these missense mutations have a later onset of symptoms.

### Applications

It has been proposed that the *STK11* gene may act as a tumor suppressor gene and thus, could be involved in early development of the pathogenesis in which hamartomas are converted into adenocarcinoma. It is useful in clinical management of PJS and to predict its clinical course to assess this gene mutations.

### Terminology

The *STK11* gene is located on chromosome 19p13.3 and the mutations in *STK11* gene have been identified as the cause of PJS. *STK11* is a highly conserved gene that extends over 23 kb and consists of nine exons, and one non-coding exon, coding for a 433-amino acid coding sequence and one non-coding exon. *STK11* protein is primarily composed of three major domains, including an N-terminal non-catalytic domain, a catalytic kinase domain and a C-terminal regulatory domain. PJS is a rare autosomal-dominant hereditary condition with incomplete penetrance that is characterized by hamartomatous polyps of the gastrointestinal tract and pigmented lesions of the buccal mucosa, perioral region and other sites. Variable penetrance and clinical heterogeneity make it difficult to determine the exact frequency of PJS. Most PJS patients develop significant hamartomatous polyps of the small bowel, with these polyps commonly arising in the stomach and colorectum.

### Peer review

This is a good study in which authors explore mutations in *STK11* gene in PJS with GI hamartomatous polyps. The results are interesting and suggest that endoscopic polypectomy of GI polyps in PJS patients appears to be useful to prevent emergency laparotomies and reduce the cancer risk.

## REFERENCES

- 1 **Giardiello FM**, Trimbath JD. Peutz-Jeghers syndrome and management recommendations. *Clin Gastroenterol Hepatol* 2006; **4**: 408-415 [PMID: 16616343 DOI: 10.1016/j.cgh.2005.11.005]
- 2 **McGarity TJ**, Amos C. Peutz-Jeghers syndrome: clinicopathology and molecular alterations. *Cell Mol Life Sci* 2006; **63**: 2135-2144 [PMID: 16952058 DOI: 10.1007/s00018-006-6080-0]
- 3 **Beggs AD**, Latchford AR, Vasen HF, Moslein G, Alonso A, Aretz S, Bertario L, Blanco I, Bülow S, Burn J, Capella G, Colas C, Friedl W, Möller P, Hes FJ, Järvinen H, Mecklin JP, Nagengast FM, Parc Y, Phillips RK, Hyer W, Ponz de Leon M, Renkonen-Sinisalo L, Sampson JR, Stormorken A, Tejpar S, Thomas HJ, Wijnen JT, Clark SK, Hodgson SV. Peutz-Jeghers syndrome: a systematic review and recommendations for management. *Gut* 2010; **59**: 975-986 [PMID: 20581245 DOI: 10.1136/gut.2009.198499]
- 4 **van Lier MG**, Wagner A, Mathus-Vliegen EM, Kuipers EJ, Steyerberg EW, van Leerdam ME. High cancer risk in Peutz-Jeghers syndrome: a systematic review and surveillance recommendations. *Am J Gastroenterol* 2010; **105**: 1258-164; author reply 1265 [PMID: 20051941 DOI: 10.1038/ajg.2009.725]
- 5 **Jenne DE**, Reimann H, Nezu J, Friedel W, Loff S, Jeschke R, Müller O, Back W, Zimmer M. Peutz-Jeghers syndrome is caused by mutations in a novel serine threonine kinase. *Nat Genet* 1998; **18**: 38-43 [PMID: 9425897 DOI: 10.1038/ng0198-38]
- 6 **Hemminki A**, Markie D, Tomlinson I, Avizienyte E, Roth S, Loukola A, Bignell G, Warren W, Aminoff M, Höglund P, Järvinen H, Kristo P, Pelin K, Ridanpää M, Salovaara R, Toro T, Bodmer W, Olschwang S, Olsen AS, Stratton MR,



- de la Chapelle A, Aaltonen LA. A serine/threonine kinase gene defective in Peutz-Jeghers syndrome. *Nature* 1998; **391**: 184-187 [PMID: 9428765 DOI: 10.1038/34432]
- 7 **Boudeau J**, Sapkota G, Alessi DR. LKB1, a protein kinase regulating cell proliferation and polarity. *FEBS Lett* 2003; **546**: 159-165 [PMID: 12829253 DOI: 10.1016/S0014-5793(03)00642-2]
  - 8 **Baas AF**, Kuipers J, van der Wel NN, Batlle E, Koerten HK, Peters PJ, Clevers HC. Complete polarization of single intestinal epithelial cells upon activation of LKB1 by STRAD. *Cell* 2004; **116**: 457-466 [PMID: 15016379 DOI: 10.1016/S0092-8674(04)00114-X]
  - 9 **Martin SG**, St Johnston D. A role for Drosophila LKB1 in anterior-posterior axis formation and epithelial polarity. *Nature* 2003; **421**: 379-384 [PMID: 12540903 DOI: 10.1038/nature01296]
  - 10 **Aretz S**, Stienen D, Uhlhaas S, Löff S, Back W, Pagenstecher C, McLeod DR, Graham GE, Mangold E, Santer R, Propping P, Friedl W. High proportion of large genomic STK11 deletions in Peutz-Jeghers syndrome. *Hum Mutat* 2005; **26**: 513-519 [PMID: 16287113 DOI: 10.1002/humu.20253]
  - 11 **Volikos E**, Robinson J, Aittomäki K, Mecklin JP, Järvinen H, Westerman AM, de Rooij FW, Vogel T, Moeslein G, Launonen V, Tomlinson IP, Silver AR, Aaltonen LA. LKB1 exonic and whole gene deletions are a common cause of Peutz-Jeghers syndrome. *J Med Genet* 2006; **43**: e18 [PMID: 16648371 DOI: 10.1136/jmg.2005.039875]
  - 12 **de Leng WW**, Jansen M, Carvalho R, Polak M, Musler AR, Milne AN, Keller JJ, Menko FH, de Rooij FW, Iacobuzio-Donahue CA, Giardiello FM, Weterman MA, Offerhaus GJ. Genetic defects underlying Peutz-Jeghers syndrome (PJS) and exclusion of the polarity-associated MARK/Par1 gene family as potential PJS candidates. *Clin Genet* 2007; **72**: 568-573 [PMID: 17924967 DOI: 10.1111/j.1399-0004.2007.00907.x]
  - 13 **Gono K**, Obi T, Yamaguchi M, Ohyama N, Machida H, Sano Y, Yoshida S, Hamamoto Y, Endo T. Appearance of enhanced tissue features in narrow-band endoscopic imaging. *J Biomed Opt* 2004; **9**: 568-577 [PMID: 15189095 DOI: 10.1117/1.1695563]
  - 14 **Ezoe Y**, Muto M, Horimatsu T, Morita S, Miyamoto S, Mochizuki S, Minashi K, Yano T, Ohtsu A, Chiba T. Efficacy of preventive endoscopic balloon dilation for esophageal stricture after endoscopic resection. *J Clin Gastroenterol* 2011; **45**: 222-227 [PMID: 20861798 DOI: 10.1111/j.1440-1746.2009.05925.x]
  - 15 **Muto M**, Horimatsu T, Ezoe Y, Hori K, Yukawa Y, Morita S, Miyamoto S, Chiba T. Narrow-band imaging of the gastrointestinal tract. *J Gastroenterol* 2009; **44**: 13-25 [PMID: 19159070 DOI: 10.1007/s00535-008-2291-5]
  - 16 **Tanaka S**, Sano Y. Aim to unify the narrow band imaging (NBI) magnifying classification for colorectal tumors: current status in Japan from a summary of the consensus symposium in the 79th Annual Meeting of the Japan Gastroenterological Endoscopy Society. *Dig Endosc* 2011; **23** Suppl 1: 131-139 [PMID: 21535219 DOI: 10.1111/j.1443-1661.2011.01106.x]
  - 17 **Kanao H**, Tanaka S, Oka S, Hirata M, Yoshida S, Chayama K. Narrow-band imaging magnification predicts the histology and invasion depth of colorectal tumors. *Gastrointest Endosc* 2009; **69**: 631-636 [PMID: 19251003 DOI: 10.1016/j.gie.2008.08.028]
  - 18 **Ohnita K**, Isomoto H, Shikuwa S, Yamaguchi N, Nakayama T, Nishiyama H, Okamoto K, Fukuda E, Takeshima F, Hayashi T, Kohno S, Nakao K. Magnifying chromoendoscopic findings of early gastric cancer and gastric adenoma. *Dig Dis Sci* 2011; **56**: 2715-2722 [PMID: 21360280 DOI: 10.1007/s10620-011-1638-6]
  - 19 **Sakamoto H**, Yamamoto H, Hayashi Y, Yano T, Miyata T, Nishimura N, Shinhata H, Sato H, Sunada K, Sugano K. Non-surgical management of small-bowel polyps in Peutz-Jeghers syndrome with extensive polypectomy by using double-balloon endoscopy. *Gastrointest Endosc* 2011; **74**: 328-333 [PMID: 21704992 DOI: 10.1016/j.gie.2011.04.001]
  - 20 **Wang H**, Luo T, Liu WQ, Huang Y, Wu XT, Wang XJ. Clinical presentations and surgical approach of acute intussusception caused by Peutz-Jeghers syndrome in adults. *J Gastrointest Surg* 2011; **15**: 2218-2225 [PMID: 22005897 DOI: 10.1007/s11605-011-1724-2]
  - 21 **Westerman AM**, Entius MM, de Baar E, Boor PP, Koole R, van Velthuysen ML, Offerhaus GJ, Lindhout D, de Rooij FW, Wilson JH. Peutz-Jeghers syndrome: 78-year follow-up of the original family. *Lancet* 1999; **353**: 1211-1215 [PMID: 10217080 DOI: 10.1016/S0140-6736(98)08018-0]
  - 22 **Lin BC**, Lien JM, Chen RJ, Fang JF, Wong YC. Combined endoscopic and surgical treatment for the polyposis of Peutz-Jeghers syndrome. *Surg Endosc* 2000; **14**: 1185-1187 [PMID: 11148795 DOI: 10.1007/s004640000029]
  - 23 **Pennazio M**, Rossini FP. Small bowel polyps in Peutz-Jeghers syndrome: management by combined push enteroscopy and intraoperative enteroscopy. *Gastrointest Endosc* 2000; **51**: 304-308 [PMID: 10699775 DOI: 10.1016/S0016-5107(00)70359-2]
  - 24 **Yamamoto H**, Sekine Y, Sato Y, Higashizawa T, Miyata T, Iino S, Ido K, Sugano K. Total enteroscopy with a nonsurgical steerable double-balloon method. *Gastrointest Endosc* 2001; **53**: 216-220 [PMID: 11174299 DOI: 10.1067/mge.2001.112181]
  - 25 **Yamamoto H**, Ell C, Binmoeller KF. Double-balloon endoscopy. *Endoscopy* 2008; **40**: 779-783 [PMID: 18773343 DOI: 10.1055/s-2008-1077518]
  - 26 **Ohmiya N**, Taguchi A, Shirai K, Mabuchi N, Arakawa D, Kanazawa H, Ozeki M, Yamada M, Nakamura M, Itoh A, Hirooka Y, Niwa Y, Nagasaka T, Ito M, Ohashi S, Okamura S, Goto H. Endoscopic resection of Peutz-Jeghers polyps throughout the small intestine at double-balloon enteroscopy without laparotomy. *Gastrointest Endosc* 2005; **61**: 140-147 [PMID: 15672077 DOI: 10.1016/S0016-5107(04)02457-5]
  - 27 **Gao H**, van Lier MG, Poley JW, Kuipers EJ, van Leerdam ME, Mensink PB. Endoscopic therapy of small-bowel polyps by double-balloon enteroscopy in patients with Peutz-Jeghers syndrome. *Gastrointest Endosc* 2010; **71**: 768-773 [PMID: 20188368 DOI: 10.1016/j.gie.2009.11.005]
  - 28 **Giardiello FM**, Welsh SB, Hamilton SR, Offerhaus GJ, Gittelsohn AM, Booker SV, Krush AJ, Yardley JH, Luk GD. Increased risk of cancer in the Peutz-Jeghers syndrome. *N Engl J Med* 1987; **316**: 1511-1514 [PMID: 3587280 DOI: 10.1056/NEJM198706113162404]
  - 29 **Kopacova M**, Tacheci I, Reichert S, Bures J. Peutz-Jeghers syndrome: diagnostic and therapeutic approach. *World J Gastroenterol* 2009; **15**: 5397-5408 [PMID: 19916169]
  - 30 **Lam-Himlin D**, Park JY, Cornish TC, Shi C, Montgomery E. Morphologic characterization of syndromic gastric polyps. *Am J Surg Pathol* 2010; **34**: 1656-1662 [PMID: 20924281]
  - 31 **Jansen M**, de Leng WW, Baas AF, Myoshi H, Mathus-Vliegen L, Taketo MM, Clevers H, Giardiello FM, Offerhaus GJ. Mucosal prolapse in the pathogenesis of Peutz-Jeghers polyposis. *Gut* 2006; **55**: 1-5 [PMID: 16344569 DOI: 10.1136/gut.2005.069062]
  - 32 **Zuo YG**, Xu KJ, Su B, Ho MG, Liu YH. Two novel STK11 mutations in three Chinese families with Peutz-Jeghers syndrome. *Chin Med J (Engl)* 2007; **120**: 1183-1186 [PMID: 17637250]
  - 33 **Mehenni H**, Gehrig C, Nezu J, Oku A, Shimane M, Rossier C, Guex N, Blouin JL, Scott HS, Antonarakis SE. Loss of LKB1 kinase activity in Peutz-Jeghers syndrome, and evidence for allelic and locus heterogeneity. *Am J Hum Genet* 1998; **63**: 1641-1650 [PMID: 9837816 DOI: 10.1086/302159]
  - 34 **Nakanishi C**, Yamaguchi T, Iijima T, Saji S, Toi M, Mori T, Miyaki M. Germline mutation of the LKB1/STK11 gene with loss of the normal allele in an aggressive breast cancer of Peutz-Jeghers syndrome. *Oncology* 2004; **67**: 476-479 [PMID: 15714005 DOI: 10.1159/000082933]
  - 35 **Salloch H**, Reinacher-Schick A, Schulmann K, Pox C, Willert J, Tannapfel A, Heringlake S, Goecke TO, Aretz S, Stemmler



- S, Schmieg W. Truncating mutations in Peutz-Jeghers syndrome are associated with more polyps, surgical interventions and cancers. *Int J Colorectal Dis* 2010; **25**: 97-107 [PMID: 19727776 DOI: 10.1007/s00384-009-0793-0]
- 36 **Hearle N**, Schumacher V, Menko FH, Olschwang S, Boardman LA, Gille JJ, Keller JJ, Westerman AM, Scott RJ, Lim W, Trimpath JD, Giardiello FM, Gruber SB, Offerhaus GJ, de Rooij FW, Wilson JH, Hansmann A, Möslin G, Royer-Pokora B, Vogel T, Phillips RK, Spigelman AD, Houlston RS. Frequency and spectrum of cancers in the Peutz-Jeghers syndrome. *Clin Cancer Res* 2006; **12**: 3209-3215 [PMID: 16707622 DOI: 10.1158/1078-0432.CCR-06-0083]
  - 37 **Amos CI**, Keitheri-Cheteri MB, Sabripour M, Wei C, McGarity TJ, Seldin MF, Nations L, Lynch PM, Fidler HH, Friedman E, Frazier ML. Genotype-phenotype correlations in Peutz-Jeghers syndrome. *J Med Genet* 2004; **41**: 327-333 [PMID: 15121768 DOI: 10.1136/jmg.2003.010900]
  - 38 **Buchet-Poyau K**, Mehenni H, Radhakrishna U, Antonarakis SE. Search for the second Peutz-Jeghers syndrome locus: exclusion of the STK13, PRKCG, KLK10, and PSCD2 genes on chromosome 19 and the STK11IP gene on chromosome 2. *Cytogenet Genome Res* 2002; **97**: 171-178 [PMID: 12438709 DOI: 10.1159/000066620]
  - 39 **Boardman LA**, Couch FJ, Burgart LJ, Schwartz D, Berry R, McDonnell SK, Schaid DJ, Hartmann LC, Schroeder JJ, Stratakis CA, Thibodeau SN. Genetic heterogeneity in Peutz-Jeghers syndrome. *Hum Mutat* 2000; **16**: 23-30 [PMID: 10874301 DOI: 10.1002/1098-1004(200007)16: ]
  - 40 **Perzin KH**, Bridge MF. Adenomatous and carcinomatous changes in hamartomatous polyps of the small intestine (Peutz-Jeghers syndrome): report of a case and review of the literature. *Cancer* 1982; **49**: 971-983 [PMID: 7059931 DOI: 10.1002/1097-0142(19820301)49: ]
  - 41 **Defago MR**, Higa AL, Campa JL, Paradelo M, Uehara A, Torres Mazzucchi MH, Videla R. Carcinoma in situ arising in a gastric hamartomatous polyp in a patient with Peutz-Jeghers syndrome. *Endoscopy* 1996; **28**: 267 [PMID: 8739752 DOI: 10.1055/s-2007-1005447]

**P-Reviewer** Ikematsu H **S-Editor** Gou SX **L-Editor** A  
**E-Editor** Zhang DN

