

Review of diagnostic and therapeutic endoscopic retrograde cholangiopancreatography using several endoscopic methods in patients with surgically altered gastrointestinal anatomy

Masaaki Shimatani, Makoto Takaoka, Mitsuo Tokuhara, Hideaki Miyoshi, Tsukasa Ikeura, Kazuichi Okazaki

Masaaki Shimatani, Makoto Takaoka, Mitsuo Tokuhara, Hideaki Miyoshi, Tsukasa Ikeura, Kazuichi Okazaki, Third Department of Internal Medicine, Kansai Medical University, Osaka 573-1010, Japan

Author contributions: All authors contributed to this manuscript.

Conflict-of-interest: Authors declare no conflict of interests for this article.

Open-Access: This article is an open-access article which was selected by an in-house editor and fully peer-reviewed by external reviewers. It is distributed in accordance with the Creative Commons Attribution Non Commercial (CC BY-NC 4.0) license, which permits others to distribute, remix, adapt, build upon this work non-commercially, and license their derivative works on different terms, provided the original work is properly cited and the use is non-commercial. See: <http://creativecommons.org/licenses/by-nc/4.0/>

Correspondence to: Masaaki Shimatani, MD, Third Department of Internal Medicine, Kansai Medical University, 2-5-1 Shinmachi, Hirakata, Osaka 573-1010, Japan. shimatam@hirakata.kmu.ac.jp
Telephone: +81-72-8040101
Fax: +81-72-8042524

Received: May 30, 2014

Peer-review started: June 16, 2014

First decision: July 29, 2014

Revised: February 10, 2015

Accepted: March 5, 2015

Article in press: March 9, 2015

Published online: June 10, 2015

Abstract

The endoscopic approach for biliary diseases in patients with surgically altered gastrointestinal anatomy (SAGA)

had been generally deemed impractical. However, it was radically made feasible by the introduction of double balloon endoscopy (DBE) that was originally developed for diagnosis and treatments for small-bowel diseases. Followed by the subsequent development of single-balloon endoscopy (SBE) and spiral endoscopy (SE), interventions using several endoscopes for biliary disease in patients with SAGA widely gained an acceptance as a new modality. Many studies have been made on this new technique. Yet, some problems are to be solved. For instance, the mutual unavailability among devices due to different working lengths and channels, and unestablished standardization of procedural techniques can be raised. Additionally, in an attempt to standardize endoscopic procedures, it is important to evaluate biliary cannulating methods by case with existence of papilla or not. A full comprehension of the features of respective scope types is also required. However there are not many papers written as a review. In our manuscript, we would like to evaluate and make a review of the present status of diagnostic and therapeutic endoscopic retrograde cholangiopancreatography applying DBE, SBE and SE for biliary diseases in patients with SAGA for establishment of these modalities as a new technology and further improvement of the scopes and devices.

Key words: Double balloon endoscopy; Single balloon endoscopy; Spiral endoscopy; Endoscopic retrograde cholangiopancreatography; Roux-en-Y reconstruction

© **The Author(s) 2015.** Published by Baishideng Publishing Group Inc. All rights reserved.

Core tip: This study is a review of the status of diagnostic and therapeutic endoscopic retrograde cholangiopancreatography using several endoscopic methods in patients with surgically altered gastrointestinal

anatomy, evaluating the results from multiple centers over the world. The descriptions of features of the respective endoscopes including the introduction of new endoscopes are summarized. Assessment of the procedures is concretely made by type of reconstruction methods and by type of applied endoscopes, which suggests the present and future challenges to be overcome.

Shimatani M, Takaoka M, Tokuhara M, Miyoshi H, Ikeura T, Okazaki K. Review of diagnostic and therapeutic endoscopic retrograde cholangiopancreatography using several endoscopic methods in patients with surgically altered gastrointestinal anatomy. *World J Gastrointest Endosc* 2015; 7(6): 617-627 Available from: URL: <http://www.wjgnet.com/1948-5190/full/v7/i6/617.htm> DOI: <http://dx.doi.org/10.4253/wjge.v7.i6.617>

INTRODUCTION

Endoscopic retrograde cholangiopancreatography (ERCP) is now one of the most effective diagnostic and therapeutic modalities in patients with biliary diseases. The success rate is > 90% for patients with normal anatomy^[1,2], however, ERCP in patients with surgically altered gastrointestinal anatomy (SAGA) is far more challenging because of the inability of the endoscope to reach the blind end due to the long bowel passage, and of the complicated angulation. Some acute angled surgical limbs preclude the scope maneuverability and hinder the scope advancement.

The success of ERCP in patients with SAGA is affected by methods of surgical operations^[3], and it often fails despite all the efforts. Consequently, many patients with SAGA are indicated for surgical or percutaneous operations, which is more invasive with greater risk of complications for patients than endoscopic therapy^[4]. As an alternative procedure, percutaneous transhepatic cholangiography (PTC) is widely accepted, though is technically limited in such cases as; the absence of the dilated intrahepatic ducts, a contraindication due to the abdominal dropsy or compromised coagulation. In addition, PTC cannot establish an access to the pancreatic duct system^[4]. Then surgery is left as the only alternative^[5], though it brings about greater adverse events, longer hospital admission, and increased financial costs. Thus, the endoscopic interventional approaches have come to be preferred.

Since Katon *et al.*^[6] introduced the first endoscopic approach to Billroth-II gastrectomy in 1975. In the late 1990s early 2000s, a number of papers studied on ERCP by using forward-viewing endoscopes or standard side-viewing duodenoscopes in various attempts, and the success rates widely ranged in 50%-92%^[7-12]. As for Roux-en-Y reconstruction, Gostout *et al.*^[13] first reported the endoscopic approach in 1988. Since then, many attempts had been made by using duodenoscopes, pediatric colonoscopes, and oblique-viewing endos-

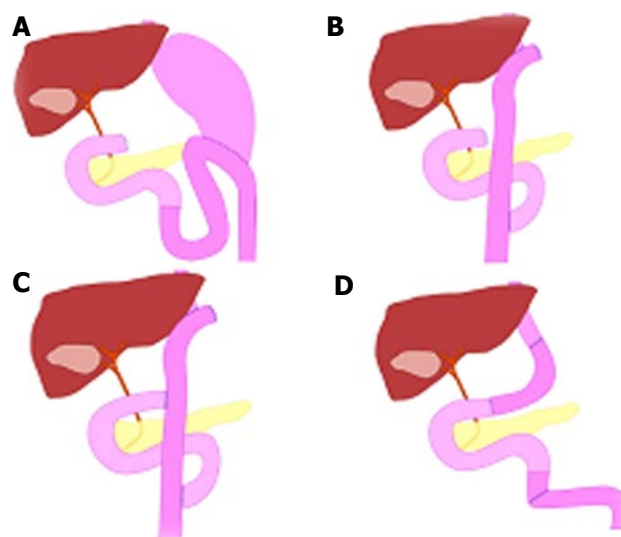


Figure 1 Schema of types of surgical anatomic reconstruction from gastrectomy. A: Billroth II reconstruction; B: Roux-en-Y reconstruction; C: Double-tract reconstruction; D: Jejunal pouch interposition.

copes, though the success rate was 33%-67% which was not satisfactory^[12,14-16]. However, the advent of recently developed balloon assisted endoscopy (BAE) and spiral endoscopy (SE) radically gained the efficacy of endoscopic interventions in post-operative patients with not only Billroth-II gastrectomy but also with Roux-en-Y reconstruction.

SURGICALLY ALTERED ANATOMY

In Japan, pancreaticoduodenectomy for treatment of pancreatic carcinoma and a total or partial gastrectomy for treatment of gastric diseases are often encountered. There are four common types of surgical anatomic reconstruction from gastrectomy; Billroth-II reconstruction, Roux-en-Y reconstruction, double-tract reconstruction and jejunal pouch interposition (Figure 1). The number of Billroth-II reconstruction has decreased due to the effective treatment of peptic ulcer disease whereas that of Roux-en-Y reconstruction has increased due to the recent spread of laparoscopic surgery. There are three common types of surgical anatomic reconstruction from pancreaticoduodenectomy; the Whipple Method, the (modified) Child surgery, the Cattell Method, and the Imanaga Method (Figure 2). Currently in Japan, the modified Child surgery is the first line reconstruction method for pancreaticoduodenectomies.

In United States in contrast, Roux-en-Y gastric bypass (RYGB) for morbid obesity^[17-20], hepaticojejunostomy for living donor liver transplantation (LDLT)^[21,22] or treatment of biliary injury or disease^[23,24], and pancreaticoduodenectomy for ampulla neoplasia and pancreatic carcinoma^[25,26] are more frequently encountered types of surgically altered anatomies. Because the severe morbid obesity is rarely encountered in Japan, RYGB for obese is not common and neither is hepaticojejunostomy for LDLT.

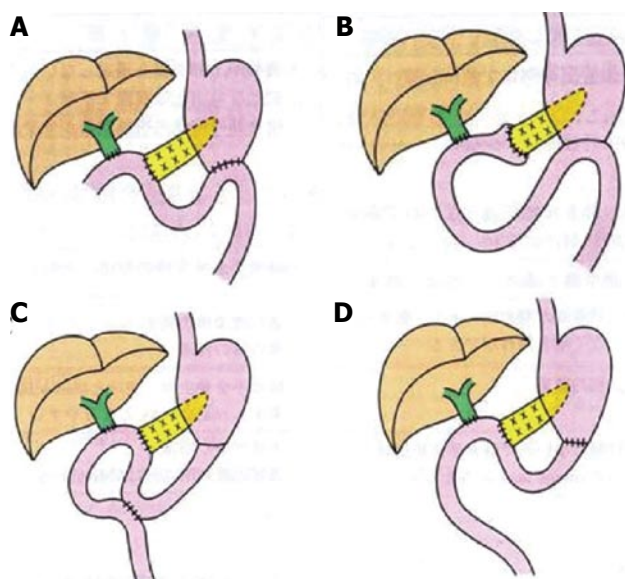


Figure 2 Schema of types of surgical anatomic reconstruction from pancreaticoduodenectomy. A: The Whipple Method; B: The (modified) Child surgery; C: The Cattell Method; D: The Imanaga Method.



Figure 3 Double-balloon endoscopy. The short type double balloon enteroscope (EC-530B; FUJIFILM, Osaka, Japan) with a working channel of 2.8 mm diameter and a working length of 152 cm.

ENDOSCOPES

The invention of deep endoscopy has revolutionized the management of patients with mid-small-bowel diseases. Since the first introduction of double-balloon endoscopy (DBE) by Yamamoto^[27] in 2001 (Figure 3), two additional techniques have become available, single-balloon endoscopy (SBE)^[28,29] (Figure 4) and spiral endoscopy (SE)^[30,31] (Figure 5). DBE and SBE entail a similar mechanism of advancement consisting of sequential bowel pleating by a push-pull technique that uses a balloon-fitted overtube with or without a second balloon inserted over the tip of a dedicated endoscope. The maneuver of the balloon or balloons in combination helps to hold and fix the intestine allowing the deep insertion by shortening the intestine. The inserting method of DBE (Figure 6) and SBE (Figure 7) is as shown in schemas. This technique enables the scope advancement selectively or retrogradely to reach the blind end in altered gastrointestinal anatomy with a

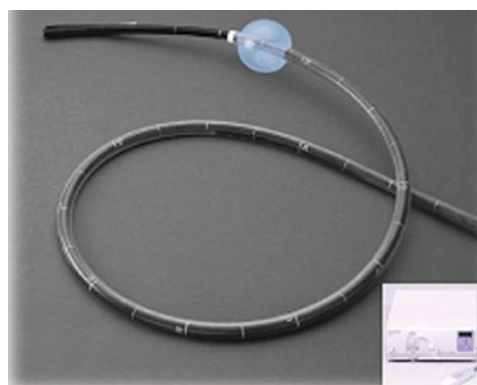

Figure 4 Single-balloon endoscopy. The standard type double balloon enteroscope (SIF-Q260; Olympus Systems, Tokyo, Japan) with a working channel of 2.8 mm diameter and a working length of 200 cm.



Figure 5 Spiral endoscopy. Discovery SB overtube over the enteroscope.

high success rate. In contrast, SE is based on a different concept of insertion that pleats small bowel onto the endoscope to advance it through the lumen using a rotating overtube [Discovery SB overtube (DSB); Spirus Medical, Inc., Stoughton, MA, United States]. This technique uses a spiral or raised helix-fitted overtube coupled with the endoscope, advanced as a unit into the small bowel by continuous rotation of the overtube in a manner similar to use of a corkscrew. An inner sleeve allows the independent motion of the overtube from the endoscope during advancement and withdrawal. The main difference between BAE and SE is that the latter uses a more or less continuous pleating of the small bowel by a clockwise rotation of the overtube rather than the push-pull technique. Unfortunately, SE is not currently commercially available.

Characteristic of DBE

There are two types of DBE. One is with a 2.2 mm working channel for observations, introduced in 2003. The DBE, EN-450P (FUJIFILM, Osaka, Japan) and the other is for treatments with a 2.8 mm working channel. For the treatment-type scope, it can be sorted into two types. The first type was introduced in 2004, the standard type DBE, EN-450T5 (FUJIFILM, Osaka, Japan) with a 2.8 mm working channel and a 200 cm working length. The second type is the short type DBE, EC-450B15 (FUJIFILM, Osaka, Japan) with a 2.8

Table 1 Information of balloon assisted endoscopy in Japan

	FUJIFILM					OLYMPUS		
	EN-450P/20	EN-450T5	EN-580T	EC-450BI5	EI-530B	SIF-Q260	SIF-Y 0004 (the first generation)	SIF-Y 0004 (the second generation)
	Standard type	Standard type	Standard type	Short type	Short type	Standard type	Short type	Short type
Release date (yr)	2003	2004	2013	2005	2011	2007	Prototype	Prototype
Direction of view	Forward view	Forward view	Forward view	Forward view	Forward view	Forward view	Forward view	Forward view
Angle of view	120°	140°	140°	140°	140°	140°	120°	120°
Outer diameter (mm)	8.5	9.4	9.4	9.4	9.4	9.2	9.2	9.2
Total length (mm)	2300	2300	2300	1820	1820	2305	1840	1840
Working length (mm)	2000	2000	2000	1520	1520	2000	1520	1520
Working channel (mm)	2.2	2.8	3.2	2.8	2.8	2.8	3.2	3.2
Passive bending part	No	No	No	No	No	No	No	Yes

mm working channel and a 152 cm working length that was introduced in 2005 as a colonoscope, and subsequently in 2011 another short type DBE EI-530B (FUJIFILM, Osaka, Japan) was introduced with a 2.8 mm working channel and a 152 cm working length as a pancreatobiliary scope. The short type DBE with the 152 cm working length is preferred and used rather than the standard type DBE with the 200 cm working length to perform ERCP in patients with (SAGA), because the 152 cm working length of the short type DBE allows the availability of almost all the ERCP-related devices, whereas the 200 cm working length limits the use of those devices.

In 2013, the treatment-type scope (EN-580T; FUJIFILM, Osaka, Japan) with a 3.2 mm working channel was introduced after further improvement, though it remained as the standard type with a 200 cm working length. For the use in ERCP in patients with SAGA, further development of short type DBE is strongly expected.

Characteristic of SBE

In 2007, Olympus introduced the standard type SBE (SIF-Q260; Olympus Medical Systems, Tokyo, Japan) with a 2.8 mm working channel and a 200 cm working length. Currently in Japan, only the standard type SBE is commercially available. Though, the short type SBE with a 3.2 mm working channel and a 152 cm working length (SIF-Y0004; Olympus Medical Systems, Tokyo, Japan), has been newly developed as the first-generation prototype. Some papers have been already written about the use of this scope for ERCP reporting that the 3.2 mm-working channel of the short type SBE allowed a smooth pushing-in and pulling-out action of devices, facilitating the employment of devices including a covered metallic stent that had been not applicable with the 2.8 mm working channel, which consequently enabled almost all the treatments that were equivalent to those of the conventional ERCP^[32-35]. Additionally, the short type SBE (SIF-Y0004; Olympus Medical Systems, Tokyo, Japan) has been recently introduced as the second-generation prototype. This new endoscope is equipped with a passive bending part. This device helps the scope to pass and advance smoothly in the small intestine, which makes a special feature of this

scope, as well as the 3.2 mm working channel that facilitated almost all the treatments equivalent to those of conventional ERCP. Some papers have been already written about ERCP using this scope^[34,35], implying that deep insertion to the blind end using the second-generation prototype was easier than that using the first-generation prototype. With the equipment of this new device, the excelling performance in deep insertion to the blind end seems to be highly expected. Characteristics of BAE are summarized in Table 1.

ENTERING THE AFFERENT LIMB BY TYPE OF SURGICAL RECONSTRUCTION

The method of insertion to the blind end differs according to the type of surgical reconstruction. A full comprehension of every feature of respective reconstruction method is essential.

Billroth II gastrectomy

In a case with Billroth II gastrectomy, there are short afferent loop (SAL) and long afferent loop (LAL). The latter contains a jejunojejunostomy called the Braun anastomosis between the afferent and the efferent limbs. As for SAL, the angulation of gastrojejunostomy is acute, and it is difficult to identify the intestinal orifice that is possibly-be-the afferent limb, as well as to insert. The afferent limbs often appear in the upper left direction over the normal anastomosis in the monitor with its lumen closed. Generally, identification of the afferent limb is challenging due to the complicated angulation of gastrojejunostomy, however once the scope is inserted, the blind end can be reached using conventional scopes such as duodenoscopes or forward-viewing endoscopes in a short time owing to the short length of afferent limb. Çiçek *et al.*^[36] reported that the success rate of reaching the blind end in patients with simple Billroth II gastroenterostomies using the duodenoscope was 83%.

In LAL, identification of the afferent limb is easy and the angulation is obtuse, which facilitates the scope insertion to the afferent limb because two intestinal orifices should be visible from the gastric lumen and either can be inserted easily. However due to the

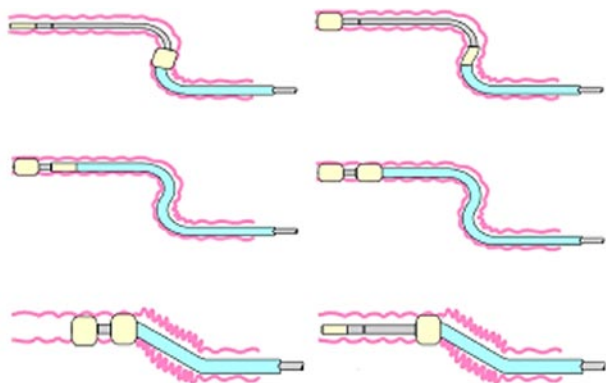


Figure 6 Schema of double-balloon endoscopy insertion.

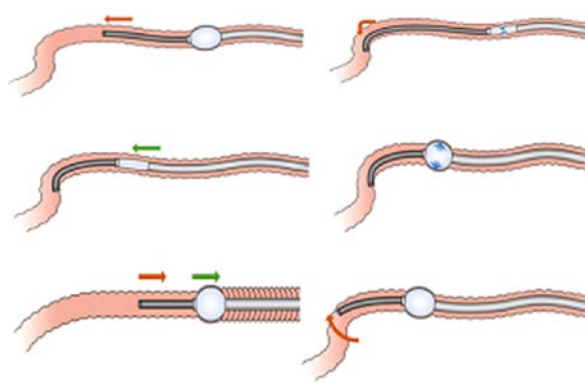


Figure 7 Schema of single-balloon endoscopy insertion.

longer length of the afferent limb it requires a longer duration to reach the blind end. It also precludes the advancement to the blind end. Thus, deep insertion using the conventional scopes is quite difficult.

In patients with both a Billroth II gastroenterostomy and an additional Braun anastomosis, Cıçek *et al.*^[36] reported that the success rate was lowered to 29% for reaching the blind end. Whereas, Wu *et al.*^[37] reported the success rate of reaching the blind end in patients with both a Billroth II gastroenterostomy and an additional Braun anastomosis was 90% even by using duodenoscopes by inserting the middle entrance of the lumen. Lin *et al.*^[38] reported the success rate of reaching the blind end using a duodenoscope was 69%. Furthermore in all the unsuccessful cases DBE was employed for the reattempted session and could successfully access the blind end. Also, in our previous report using short type DBE, the success rate of reaching the blind end was 100%^[39]. In cases with Braun anastomosis, we would also attempt the insertion to the middle entrance as Wu *et al.*^[37] reported. The Braun anastomosis shows like a maze. It is often considered as a disadvantage for endoscopic insertion, however when the efferent limb was entered by error, the scope can always return from the Braun anastomosis to the efferent limb. Applying the technique to insert the middle entrance, the Braun anastomosis is not necessarily a disadvantage for the scope insertion, rather can be an advantage.

Roux-en-Y reconstruction

In a case with Roux-en-Y reconstruction, identification of the afferent limb in Y anastomosis is very difficult. Also, the insertion is possibly hindered by the acute angulation of the afferent limb and the severe adhesion as a consequence of the long intestine to the blind end. In comparison with the cases of Billroth II gastrectomy, entering the afferent limb in cases with Roux-en-Y reconstruction is considered much more difficult. There are three challenges to be overcome for a successful insertion in cases with Roux-en-Y reconstruction.

The first challenge is identification of the afferent limb. It is difficult to identify the afferent limb in jejunojejunostomies. Because of the maze-like

feature of that area, endoscopists often lose their way or misjudge the orientation. Recently, Yano *et al.*^[40] reported a method using an intraluminal injection of indigo carmine to identify the afferent limb. The success rate was 80%, which suggests it should be helpful in identification of the afferent limb. However, the success rate based on our experience was approximately 50%. (unpublished observations) The divergence of the results could be reasoned that Yano *et al.*^[40] performed the procedure with the patient in a left-lateral position, whereas we performed in a pronation. Different postures in patients could have caused the divergence between the results.

The second challenge is the management of the complicated angulation in jejunojejunostomy and the length of the afferent limb. It requires endoscopist's experience and skill to control the of sharp angulation of jejunojejunostomy in order to reach the afferent limb, which in some patients forms an angle of up to 180 degrees. Shah *et al.*^[41] reported the success rate of deep insertion could be raised by change of patient's position from the typical semi-prone to a left-lateral or supine position during the procedure. Roux-en-Y gastric bypass (RYGB) is a particularly challenging postsurgical anatomy in terms of the length of the afferent limb. It consists of the long limb (often > 100 cm) that is traversed from the gastrojejunal orifice to the jejunojejunostomy to reach the afferent small-bowel limb^[14]. This reconstruction method is frequently performed in the United States for morbid obesity. Therefore, it was reported laparoscope-assisted ERCP was more efficient than endoscope-assisted ERCP for RYGB^[42,43]. The RYGB is infrequently performed in Japan. We assume that the primary disease and application of surgery method differ to some extent in gastrointestinal anatomy between the United States and Japan.

Adhesions are the third challenge, which are frequently observed in patients with SAGA. In Japan, lymphadenectomy of malignant tumors is likely to be performed, which often results in post-surgical severe adhesion. They often preclude the scope advancement, and if scope insertion to this lesion is forced by power, it increases a risk of perforation and bleeding. Therefore

a careful maneuver and the discretion to withdraw are necessary for endoscopists.

In order to challenge these three obstacles, various attempts have been made and reported. Hintze *et al.*^[12] reported that the success rate of reaching the ampulla in Roux-en-Y anastomoses was 33%, compared with 92% in Billroth II anatomy. Wright *et al.*^[14] reported a use of colonoscopy to access the biliary orifice and a guide wire for a duodenoscope to attempt ERCP in 15 patients with long-limb Roux-en-Y anastomoses. Kikuyama *et al.*^[16] used the oblique-viewing endoscope in couple with an overtube and reported a high success rate, though it was based on the small case series. Generally the results were not sufficiently practical or satisfactory.

Recently, two multicenter studies have been reported on the use of overtube-assisted endoscopy in the United States. One multicenter study^[41] observed 129 patients (180 procedures) focusing only on Roux-en-Y reconstruction, and reported that the success rate of reaching the papilla or the hepaticojejunostomy site was 71% using several scopes such as DBE, SBE and SE. They concluded there was no divergence in the result caused by the type of applied scopes, however, in the 3/4 of unsuccessful cases where endoscopy-ERCPs failed were simply due to the failure of reaching the blind end, which suggested that the success of endoscopy-ERCPs were significantly affected by the result of the deep insertion to the blind end. It indicates that insertion to the blind end is quite challenging and prerequisite for performing ERCP in cases with Roux-en-Y reconstruction. The other multicenter study^[44] focused on ERCP in 79 patients using the short-type DBE for several anatomical variations. The success rate of reaching the blind end was 90% (based on success rates of 82% for Roux-en-Y gastric bypass, 95% for pancreatoduodenectomy, and 100% for Billroth II gastrectomy, hepaticojejunostomy, Roux-en-Y hepaticojejunostomy, Roux-en-Y gastrojejunostomy, choledochojejunostomy, and Roux-en-Y pancreaticojejunostomy). They reported a very high success rate of 90% to reach the papilla or the hepaticojejunostomy site applying only the short type DBE. They raised two points as reasons for their good result owing to several advantages regarding the short DBE, which is quite agreeable: (1) DBE might have better maneuverability than the long conventional DBE, which is especially useful in patients with post-surgical severe adhesions; and (2) DBE allowed endoscopists to apply a power pressure more effectively to the endoscope, which might have raised the success rate of reaching the papilla or anastomosis.

REACHING THE BLIND END WITH OVERTUBE-ASSISTED ENDOSCOPY

Reaching the blind end with BAE

SBE and DBE are based on the same concept of insertion. The difference is the presence or absence of

the balloon at the tip of the endoscope. The absence of a balloon fitted to the tip of the endoscope impairs the stability in case with severe adhesions around the blind end. The slippery feature of intestine prevents the tip of the endoscope from being fixed still and orienting into the required direction to follow the overtube, which eventually hinders the deep advancement of overtube. Tsujikawa *et al.*^[28] suggested that the DBE was advantageous in cases with sharp angulations of the small intestine, because the balloon on the tip of the DBE could help pass around such angulations better than the hook-shaped tip of the SBE. In comparison with DBE, it is assumed that SBE is more disadvantageous in a performance of deep insertion. Shah *et al.*^[41] reported the success rates of reaching the blind end in patients with Roux-en-Y gastric bypass using standard type SBE ($n = 22$) or DBE ($n = 15$), using both the standard and the short type DBE, was 73% in the SBE group and 87% in the DBE group. It suggested that DBE showed a better performance in deep insertion to the blind end. However, the new short type SBE with the passive bending part has been introduced in order to improve the success rate of insertion to the blind end. Obana *et al.*^[33] reported the success rate of insertion to the blind end using the short type SBE without the passive bending part was 73%, which was relatively low. Recently we have reported the success rate using the short type SBE with the passive bending part was 92%^[34]. We assume that the success rate of deep insertion to the blind end might have been raised by the use of short type SBE equipped with the passive bending part. Today several challenges are yet to be overcome for deep insertions using BAEs into the blind end.

Reaching the blind end with SE

SE is based on the totally different concept of insertion from that of BAE. Previous small studies have suggested that SE allow more efficient advancement into the small bowel than BAE, however, there are not much paper written regarding the insertion to the blind end in patients with (SAGA) using SE. Therefore, sufficient data are not available to evaluate the SE in point of success rate of deep insertion, complication morbidity and efficacy. To evaluate the efficacy and the safety of this method, more studies and assessment in a larger number of cases are necessary.

OVERTUBE-ASSISTED ERCP

Many studies of DBE-assisted ERCP have been made since 2007^[39,41,44-61]. And studies of SBE-assisted ERCP were subsequently introduced in 2009^[62-69], followed by the studies of SE-assisted ERCP in 2011^[70-72]. As the DBE was introduced prior to the development of the SBE and SE, there existed more number of reports of successful ERCP using DBE in patients with PD than that of the SBE and SE. In comparison of the results before and after the advent of BAE and/or SE, it is obvious that

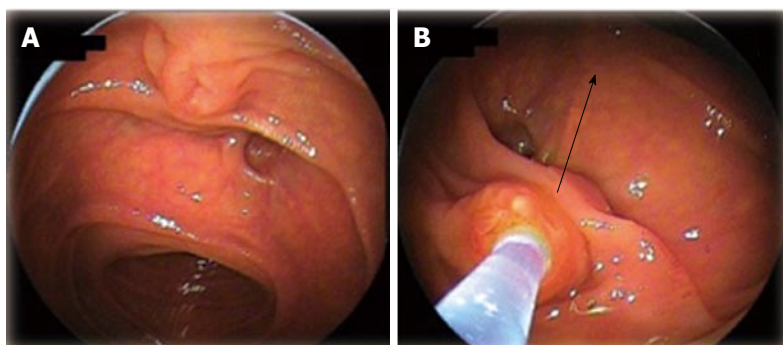


Figure 8 Biliary cannulation using double-balloon endoscopy in a patient with papilla. A: Papilla when the blind end was accessed; B: Locating papilla in 6 o'clock direction in the monitor, and performing cannulation adjusting the axis of catheter into 12 o'clock direction along the biliary duct.

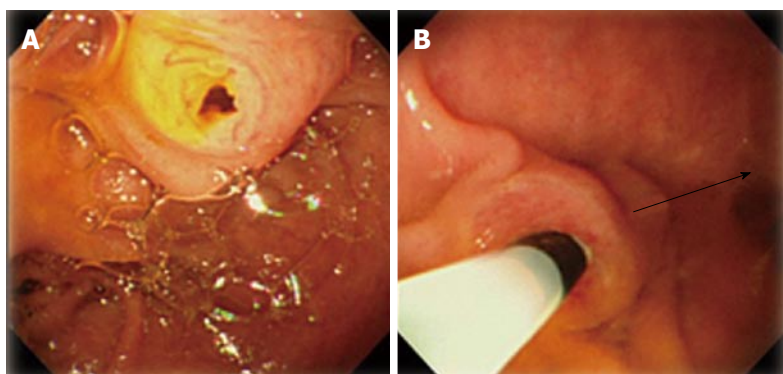


Figure 9 Biliary cannulation using single-balloon endoscopy in a patient with papilla. A: Papilla when the blind end was accessed; B: Locating papilla in 8-9 o'clock direction in the monitor, and performing cannulation adjusting the axis of catheter into 3 o'clock direction along the biliary duct.

the success rate has radically improved to a satisfactory level.

DBE-assisted ERCP

There are a lot of studies on DBE-assisted ERCP with wide ranging results. The success rate of ERCP-related interventions varied 60%-100%^[39,41,44-61], which was probably because many studies were based on a small number of cases. We have reported a large case single center study^[39], as a single center study in which we evaluated 103 procedures DBE-assisted ERCP by type of reconstruction method in 68 patients. The overall success rate for ERCP was 95% (based on success rates for Roux-en-Y reconstruction, Billroth II reconstruction, and pancreaticoduodenectomy of 91%, 100%, and 100%, respectively). In all successful ERCP cases, endoscopic therapeutic interventions were successfully accomplished. One multicenter study^[41] reported the overall ERCP success rate was 63%. The success rate of ERCP using SBE and DBE was similar between Roux-en-Y gastric bypass and other long-limb surgical bypass. It also reported that the success rate of ERCP in cases where the blind end was successfully reached was 88%, which was satisfactory though they explained the success rate was lowered because many cases had contained papilla. Itoi *et al*^[63] reported the success rate of ERCP using the standard type SBE was 72.3% mentioning that the biliary approach in patients with naïve papilla was difficult^[63]. It is agreeable, however, in our previous study^[39], the success rate of cannulation into papilla was 97%, suggesting the different type of applied scopes could affect the divergence of the results. For instance, because the position of the working

channel of DBE is located at 6:30, an attempt to bring the papilla in a 6 o'clock direction in monitor will allow a down-angled maneuver that helps to fix the papilla still by a direct power pressure, which facilitates a stable cannulation (Figure 8). Whereas, the position of the working channel of SBE is located at 9 o'clock, which makes difficult to fix the papilla, precluding a stable cannulation as a consequence (Figure 9). Whereas Shah *et al*^[41] concluded the type of scopes did not affect their result, though they used mostly the standard type DBE and SBE with the 200 cm working length in many cases. Namely, it could be inferred that not only using the DBE but the short type was the best appropriate scope for cannulation in cases with papilla. Siddiqui *et al*^[44] reported the overall ERCP success rate using only the short-type DBE was 90% raising a reason for the excellent result as; the short DBE allowed the use of commercially available ERCP cannulas for performance of wire-guided cannulation, and therapeutic instruments could be applied to carry out successful therapeutic treatments.

SBE-assisted ERCP

Dellon *et al*^[64] evaluated a use of the standard type SBE for diagnostic and therapeutic ERCP. They observed 4 patients with Roux-en-Y anatomy in total. (1 patient with RYGB, 2 patients with Roux-en-Y anatomy caused by bile duct injury, and 1 patient with Roux-en-Y anatomy after liver transplantation). The overall success rate of the therapeutic ERCP on the first session was 50%. In this report, the standard type SBE with 200 cm working length that was only applicable to limited variety of devices was used for the therapeutic ERCP,

Table 2 Review studies evaluating endoscopic retrograde cholangiopancreatography using several enteroscopy in patients with altered gastrointestinal anatomy

Ref.	No. of cases	Type of scope	Enteroscopy success (%)	Success rate of ERCP	Overall ERCP success (%)
Mehdizadeh <i>et al</i> ^[48]	5	Standard type DBE	67	100	67
Mönkemüller <i>et al</i> ^[53]	18	Standard type DBE	94	85	83
Maaser <i>et al</i> ^[41]	11	Standard type DBE	100	64	64
Kuga <i>et al</i> ^[59]	6	Standard type DBE	100	83	83
Tsujino <i>et al</i> ^[49]	12	Short type DBE	100	94	94
Siddiqui <i>et al</i> ^[44]	79	Short type DBE	89	90	81
Shimatani <i>et al</i> ^[39]	103	Short type DBE	97	96	94
Tomizawa <i>et al</i> ^[69]	22	Standard type SBE	68	73	50
Itoi <i>et al</i> ^[63]	13	Standard type SBE	92	83	77
Dellon <i>et al</i> ^[64]	4	Standard type SBE	75	67	50
Yamauchi <i>et al</i> ^[32]	31	Short type SBE	90	89	81
Obana <i>et al</i> ^[33]	19	Short type SBE	79	66	53
Shimatani <i>et al</i> ^[34]	26	Short type SBE	92	92	85
Lennon <i>et al</i> ^[70]	29	Standard type SBE	55	87	48
Shah <i>et al</i> ^[41]	27	Standard type DBE	85	85	63

ERCP: Endoscopic retrograde cholangiopancreatography; DBE: Double balloon endoscopy; SBE: Single-balloon endoscopy.

which could have caused the unsatisfactory success rate of SBE-assisted ERCP.

However, along the recent development of the short type SBE, several reports have been made on the short type SBE-assisted ERCP. The overall success rate of ERCP was 78%-90%, which was higher than that of ERCP using the standard type SBE. It could be reasoned that the 152 cm working length allowed the use of more variety of available devices.

SE-assisted ERCP

Although only published in abstract form, some studies on SE-assisted ERCP have been made. In a multi-center study, Shah *et al*^[41] reported 129 patients with surgically altered anatomy who underwent ERCP using SBE ($n = 15$), DBE ($n = 22$), and SE ($n = 13$). The ERCP success rates of each method were 60%, 63%, and 65%, respectively. Lennon *et al*^[70] discussed the comparison of SE and SBE. They concluded there was no significant difference between SE and SBE, and their overall ERCP success rate was 44%.

A review of studies evaluating overtube assisted ERCP in patients with (SAGA) *via* various techniques is

summarized in Table 2.

COMPLICATIONS

It is assumed that the morbidity of complications is affected by type of applied endoscopes and by method of surgical reconstruction. The common complications for overtube-assisted ERCP are comparable with those of conventional ERCP such as bleeding, perforation, and post-ERCP pancreatitis. There are few studies made only in a small case series, however, the actual rates of perforation, bleeding, and pancreatitis associated with overtube-assisted ERCP is unknown.

Performing ERCP in Patients with SAGApresents a greater risk of complications than in patients with NGA^[73,74]. The risk of retroperitoneal perforation in patients with Billroth II surgery has been reported as high as 7%-10%^[74]. Regarding Roux-en-Y reconstruction, our previous study retrospectively observed 55 procedures, reporting that procedural complications developed in 5 of 55 procedures (9%)^[39]. Shah *et al*^[41] retrospectively observed 129 patients, reporting that procedural complications were observed in 16 of 129 patients (12%), including pancreatitis (mild = 4, severe = 1), mild bleeding ($n = 1$), abdominal pain requiring hospital admission ($n = 3$), and throat pain requiring physician contact ($n = 4$). Two perforations were also observed and 1 case of death occurred. However, apart from those, studies based on only small case series can be found^[75,76]. In order to evaluate the safety and efficacy of the procedure, it is necessary to analyze and evaluate data of complications out of large case studies from multiple centers prospectively, particularly for Roux-en-Y reconstruction.

CONCLUSION

The endoscopic approach to PD in patients with (SAGA) has radically become practical. Development of new modalities such as DBE, SBE, and SE is in progress as a consequence of an increased demand for the endoscopic interventions. For the safety and a higher success of the procedures, further development of the scopes and devices, standardization of technical maneuverability, establishment of guidelines in decision making of indicated and contraindicated cases, and assessment of complications from a larger multi-center study are necessary.

REFERENCES

- 1 Suissa A, Yassin K, Lavy A, Lachter J, Chermech I, Karban A, Tamir A, Eliakim R. Outcome and early complications of ERCP: a prospective single center study. *Hepatogastroenterology* 2005; **52**: 352-355 [PMID: 15816433]
- 2 Freeman ML, Guda NM. ERCP cannulation: a review of reported techniques. *Gastrointest Endosc* 2005; **61**: 112-125 [PMID: 15672074 DOI: 10.1016/s0016-5107(04)02463-0]
- 3 Forbes A, Cotton PB. ERCP and sphincterotomy after Billroth II gastrectomy. *Gut* 1984; **25**: 971-974 [PMID: 6469083 DOI: 10.1136/gut.1984.02509710]

- 10.1136/gut.25.9.971]
- 4 **Maaser C**, Lenze F, Bokemeyer M, Ullerich H, Domagk D, Bruewer M, Luegering A, Domschke W, Kucharzik T. Double balloon enteroscopy: a useful tool for diagnostic and therapeutic procedures in the pancreaticobiliary system. *Am J Gastroenterol* 2008; **103**: 894-900 [PMID: 18371136 DOI: 10.1111/j.1572-0241.2007.01745.x]
- 5 **Teplick SK**, Flick P, Brandon JC. Transhepatic cholangiography in patients with suspected biliary disease and nondilated intrahepatic bile ducts. *Gastrointest Radiol* 1991; **16**: 193-197 [PMID: 1879632 DOI: 10.1007/bf01887344]
- 6 **Katon RM**, Bilbao MK, Parent JA, Smith FW. Endoscopic retrograde cholangiopancreatography in patients with gastrectomy and gastrojejunostomy (Billroth II), A case for the forward look. *Gastrointest Endosc* 1975; **21**: 164-165 [PMID: 1140534 DOI: 10.1016/s0016-5107(75)73838-5]
- 7 **Kim MH**, Lee SK, Lee MH, Myung SJ, Yoo BM, Seo DW, Min YI. Endoscopic retrograde cholangiopancreatography and needle-knife sphincterotomy in patients with Billroth II gastrectomy: a comparative study of the forward-viewing endoscope and the side-viewing duodenoscope. *Endoscopy* 1997; **29**: 82-85 [PMID: 9101144 DOI: 10.1055/s-2007-1004080]
- 8 **Aabakken L**, Holthe B, Sandstad O, Rosseland A, Osnes M. Endoscopic pancreaticobiliary procedures in patients with a Billroth II resection: a 10-year follow-up study. *Ital J Gastroenterol Hepatol* 1998; **30**: 301-305 [PMID: 9759601]
- 9 **Bergman JJ**, van Berkel AM, Bruno MJ, Fockens P, Rauws EA, Tijssen JG, Tytgat GN, Huibregtse K. A randomized trial of endoscopic balloon dilation and endoscopic sphincterotomy for removal of bile duct stones in patients with a prior Billroth II gastrectomy. *Gastrointest Endosc* 2001; **53**: 19-26 [PMID: 11154484 DOI: 10.1067/mge.2001.110454]
- 10 **Lin LF**, Siau CP, Ho KS, Tung JC. ERCP in post-Billroth II gastrectomy patients: emphasis on technique. *Am J Gastroenterol* 1999; **94**: 144-148 [PMID: 9934745 DOI: 10.1016/s0002-9270(98)00666-2]
- 11 **Osnes M**, Rosseland AR, Aabakken L. Endoscopic retrograde cholangiography and endoscopic papillotomy in patients with a previous Billroth-II resection. *Gut* 1986; **27**: 1193-1198 [PMID: 3781333 DOI: 10.1136/gut.27.10.1193]
- 12 **Hintze RE**, Adler A, Veltzke W, Abou-Rebyeh H. Endoscopic access to the papilla of Vater for endoscopic retrograde cholangiopancreatography in patients with billroth II or Roux-en-Y gastrojejunostomy. *Endoscopy* 1997; **29**: 69-73 [PMID: 9101141 DOI: 10.1055/s-2007-1004077]
- 13 **Gostout CJ**, Bender CE. Cholangiopancreatography, sphincterotomy, and common duct stone removal via Roux-en-Y limb enteroscopy. *Gastroenterology* 1988; **95**: 156-163 [PMID: 3371610]
- 14 **Wright BE**, Cass OW, Freeman ML. ERCP in patients with long-limb Roux-en-Y gastrojejunostomy and intact papilla. *Gastrointest Endosc* 2002; **56**: 225-232 [PMID: 12145601 DOI: 10.1016/s0016-5107(02)70182-x]
- 15 **Chahal P**, Baron TH, Topazian MD, Petersen BT, Levy MJ, Gostout CJ. Endoscopic retrograde cholangiopancreatography in post-Whipple patients. *Endoscopy* 2006; **38**: 1241-1245 [PMID: 17163326 DOI: 10.1055/s-2006-945003]
- 16 **Kikuyama M**, Sasada Y, Matsushashi T, Ota Y, Nakahodo J. ERCP after Roux-en-Y reconstruction can be carried out using an oblique-viewing endoscope with an overtube. *Dig Endosc* 2009; **21**: 180-184 [PMID: 19691766 DOI: 10.1111/j.1443-1661.2009.00882.x]
- 17 **Marsk R**, Freedman J, Tynelius P, Rasmussen F, Näslund E. Antibesity surgery in Sweden from 1980 to 2005: a population-based study with a focus on mortality. *Ann Surg* 2008; **248**: 777-781 [PMID: 18948804 DOI: 10.1097/SLA.0b013e318189b0cf]
- 18 **Flum DR**, Salem L, Elrod JA, Dellinger EP, Cheadle A, Chan L. Early mortality among Medicare beneficiaries undergoing bariatric surgical procedures. *JAMA* 2005; **294**: 1903-1908 [PMID: 16234496 DOI: 10.1001/jama.294.15.1903]
- 19 **Livingston EH**. Procedure incidence and in-hospital complication rates of bariatric surgery in the United States. *Am J Surg* 2004; **188**: 105-110 [PMID: 15249233 DOI: 10.1016/j.amjsurg.2004.03.001]
- 20 **Smith FJ**, Holman CD, Moorin RE, Fletcher DR. Incidence of bariatric surgery and postoperative outcomes: a population-based analysis in Western Australia. *Med J Aust* 2008; **189**: 198-202 [PMID: 18707562]
- 21 **Soejima Y**, Taketomi A, Yoshizumi T, Uchiyama H, Harada N, Ijichi H, Yonemura Y, Ikeda T, Shimada M, Maehara Y. Biliary strictures in living donor liver transplantation: incidence, management, and technical evolution. *Liver Transpl* 2006; **12**: 979-986 [PMID: 16721777 DOI: 10.1002/lt.20740]
- 22 **Yi NJ**, Suh KS, Cho JY, Kwon CH, Lee KU. In adult-to-adult living donor liver transplantation hepaticojejunostomy shows a better long-term outcome than duct-to-duct anastomosis. *Transpl Int* 2005; **18**: 1240-1247 [PMID: 16221154 DOI: 10.1111/j.1432-2277.2005.00209.x]
- 23 **Mercado MA**, Chan C, Orozco H, Tielve M, Hinojosa CA. Acute bile duct injury. The need for a high repair. *Surg Endosc* 2003; **17**: 1351-1355 [PMID: 12811664]
- 24 **Johnson SR**, Koehler A, Pennington LK, Hanto DW. Long-term results of surgical repair of bile duct injuries following laparoscopic cholecystectomy. *Surgery* 2000; **128**: 668-677 [PMID: 11015101 DOI: 10.1067/msy.2000.108422]
- 25 **Yeo CJ**, Cameron JL, Sohn TA, Lillemoe KD, Pitt HA, Talamini MA, Hruban RH, Ord SE, Sauter PK, Coleman J, Zahurak ML, Grochow LB, Abrams RA. Six hundred fifty consecutive pancreaticoduodenectomies in the 1990s: pathology, complications, and outcomes. *Ann Surg* 1997; **226**: 248-257; discussion 257-260 [PMID: 9339931 DOI: 10.1097/0000658-199709000-00004]
- 26 **Meguid RA**, Ahuja N, Chang DC. What constitutes a "high-volume" hospital for pancreatic resection? *J Am Coll Surg* 2008; **206**: 622.e1-622.e9 [PMID: 18387466 DOI: 10.1016/j.jamcollsurg.2007.11.011]
- 27 **Yamamoto H**, Sekine Y, Sato Y, Higashizawa T, Miyata T, Iino S, Ido K, Sugano K. Total enteroscopy with a nonsurgical steerable double-balloon method. *Gastrointest Endosc* 2001; **53**: 216-220 [PMID: 11174299 DOI: 10.1067/mge.2001.112181]
- 28 **Tsujikawa T**, Saitoh Y, Andoh A, Imaeda H, Hata K, Minematsu H, Senoh K, Hayafuji K, Ogawa A, Nakahara T, Sasaki M, Fujiyama Y. Novel single-balloon enteroscopy for diagnosis and treatment of the small intestine: preliminary experiences. *Endoscopy* 2008; **40**: 11-15 [PMID: 18058613 DOI: 10.1055/s-2007-966976]
- 29 **Hartmann D**, Eickhoff A, Tamm R, Riemann JF. Balloon-assisted enteroscopy using a single-balloon technique. *Endoscopy* 2007; **39** Suppl 1: E276 [PMID: 17957636 DOI: 10.1055/s-2007-966616]
- 30 **Akerman PA**, Cantero D. Spiral enteroscopy and push enteroscopy. *Gastrointest Endosc Clin N Am* 2009; **19**: 357-369 [PMID: 19647645 DOI: 10.1016/j.giec.2009.04.001]
- 31 **Akerman PA**, Agrawal D, Cantero D, Pangtay J. Spiral enteroscopy with the new DSB overtube: a novel technique for deep peroral small-bowel intubation. *Endoscopy* 2008; **40**: 974-978 [PMID: 19065477 DOI: 10.1055/s-0028-1103402]
- 32 **Yamauchi H**, Kida M, Okuwaki K, Miyazawa S, Iwai T, Takezawa M, Kikuchi H, Watanabe M, Imaizumi H, Koizumi W. Short-type single balloon enteroscope for endoscopic retrograde cholangiopancreatography with altered gastrointestinal anatomy. *World J Gastroenterol* 2013; **19**: 1728-1735 [PMID: 23555161 DOI: 10.3748/wjg.v19.i11.1728]
- 33 **Obana T**, Fujita N, Ito K, Noda Y, Kobayashi G, Horaguchi J, Koshita S, Kanno Y, Ogawa T, Hashimoto S, Masu K. Therapeutic endoscopic retrograde cholangiography using a single-balloon enteroscope in patients with Roux-en-Y anastomosis. *Dig Endosc* 2013; **25**: 601-607 [PMID: 23362835 DOI: 10.1111/den.12039]
- 34 **Shimatani M**, Takaoka M, Ikeura T, Mitsuyama T, Okazaki K. Evaluation of endoscopic retrograde cholangiopancreatography using a newly developed short-type single-balloon endoscope in patients with altered gastrointestinal anatomy. *Dig Endosc* 2014; **26** Suppl 2: 147-155 [PMID: 24750166 DOI: 10.1111/den.12283]
- 35 **Iwai T**, Kida M, Yamauchi H, Imaizumi H, Koizumi W. Short-type and conventional single-balloon enteroscopes for endoscopic retrograde cholangiopancreatography in patients with surgically altered anatomy: single-center experience. *Dig Endosc* 2014; **26**

- Suppl 2: 156-163 [PMID: 24750167 DOI: 10.1111/den.12258]
- 36 **Cicek B**, Parlak E, Dişibeyaz S, Koksall AS, Sahin B. Endoscopic retrograde cholangiopancreatography in patients with Billroth II gastroenterostomy. *J Gastroenterol Hepatol* 2007; **22**: 1210-1213 [PMID: 17688662 DOI: 10.1111/j.1440-1746.2006.04765.x]
 - 37 **Wu WG**, Gu J, Zhang WJ, Zhao MN, Zhuang M, Tao YJ, Liu YB, Wang XF. ERCP for patients who have undergone Billroth II gastroenterostomy and Braun anastomosis. *World J Gastroenterol* 2014; **20**: 607-610 [PMID: 24574733 DOI: 10.3748/wjg.v20.i2.607]
 - 38 **Lin CH**, Tang JH, Cheng CL, Tsou YK, Cheng HT, Lee MH, Sung KF, Lee CS, Liu NJ. Double balloon endoscopy increases the ERCP success rate in patients with a history of Billroth II gastrectomy. *World J Gastroenterol* 2010; **16**: 4594-4598 [PMID: 20857532 DOI: 10.3748/wjg.v16.i36.4594]
 - 39 **Shimatani M**, Matsushita M, Takaoka M, Koyabu M, Ikeura T, Kato K, Fukui T, Uchida K, Okazaki K. Effective “short” double-balloon enteroscope for diagnostic and therapeutic ERCP in patients with altered gastrointestinal anatomy: a large case series. *Endoscopy* 2009; **41**: 849-854 [PMID: 19750447 DOI: 10.1055/s-0029-1215108]
 - 40 **Yano T**, Hatanaka H, Yamamoto H, Nakazawa K, Nishimura N, Wada S, Tamada K, Sugano K. Intraluminal injection of indigo carmine facilitates identification of the afferent limb during double-balloon ERCP. *Endoscopy* 2012; **44** Suppl 2 UCTN: E340-E341 [PMID: 23012011 DOI: 10.1055/s-0032-1309865]
 - 41 **Shah RJ**, Smolkin M, Yen R, Ross A, Kozarek RA, Howell DA, Bakis G, Jonnalagadda SS, Al-Lehibi AA, Hardy A, Morgan DR, Sethi A, Stevens PD, Akerman PA, Thakkar SJ, Brauer BC. A multicenter, U.S. experience of single-balloon, double-balloon, and rotational overtube-assisted enteroscopy ERCP in patients with surgically altered pancreaticobiliary anatomy (with video). *Gastrointest Endosc* 2013; **77**: 593-600 [PMID: 23290720 DOI: 10.1016/j.gie.2012.10.015]
 - 42 **Ross AS**. Techniques for Performing ERCP in Roux-en-Y Gastric Bypass Patients. *Gastroenterol Hepatol* (N Y) 2012; **8**: 390-392 [PMID: 22933875]
 - 43 **Saleem A**, Levy MJ, Petersen BT, Que FG, Baron TH. Laparoscopic assisted ERCP in Roux-en-Y gastric bypass (RYGB) surgery patients. *J Gastrointest Surg* 2012; **16**: 203-208 [PMID: 22042568 DOI: 10.1007/s11605-011-1760-y]
 - 44 **Siddiqui AA**, Chaaya A, Shelton C, Marmion J, Kowalski TE, Loren DE, Heller SJ, Haluszka O, Adler DG, Tokar JL. Utility of the short double-balloon enteroscope to perform pancreaticobiliary interventions in patients with surgically altered anatomy in a US multicenter study. *Dig Dis Sci* 2013; **58**: 858-864 [PMID: 22975796 DOI: 10.1007/s10620-012-2385-z]
 - 45 **Shimatani M**, Matsushita M, Takaoka M, Kusuda T, Fukata N, Koyabu M, Uchida K, Okazaki K. “Short” double balloon enteroscope for endoscopic retrograde cholangiopancreatography with conventional sphincterotomy and metallic stent placement after Billroth II gastrectomy. *Endoscopy* 2009; **41** Suppl 2: E19-E20 [PMID: 19219763 DOI: 10.1055/s-0028-1103466]
 - 46 **Albrecht H**, Konturek PC, Diebel H, Kraus F, Hahn EG, Raithel M. Successful interventional treatment of postoperative bile duct leakage after Billroth II resection by unusual procedure using double balloon enteroscopy. *Med Sci Monit* 2011; **17**: CS29-CS33 [PMID: 21358608 DOI: 10.12659/msm.881437]
 - 47 **Haruta H**, Yamamoto H, Mizuta K, Kita Y, Uno T, Egami S, Hishikawa S, Sugano K, Kawarasaki H. A case of successful enteroscopic balloon dilation for late anastomotic stricture of choledochojunostomy after living donor liver transplantation. *Liver Transpl* 2005; **11**: 1608-1610 [PMID: 16315301 DOI: 10.1002/lt.20623]
 - 48 **Mehdizadeh S**, Ross A, Gerson L, Leighton J, Chen A, Schembre D, Chen G, Semrad C, Kamal A, Harrison EM, Binmoeller K, Waxman I, Kozarek R, Lo SK. What is the learning curve associated with double-balloon enteroscopy? Technical details and early experience in 6 U.S. tertiary care centers. *Gastrointest Endosc* 2006; **64**: 740-750 [PMID: 17055868 DOI: 10.1016/j.gie.2006.05.022]
 - 49 **Tsujino T**, Yamada A, Isayama H, Kogure H, Sasahira N, Hirano K, Tada M, Kawabe T, Omata M. Experiences of biliary interventions using short double-balloon enteroscopy in patients with Roux-en-Y anastomosis or hepaticojunostomy. *Dig Endosc* 2010; **22**: 211-216 [PMID: 20642611 DOI: 10.1111/j.1443-1661.2010.00985.x]
 - 50 **Haber GB**. Double balloon endoscopy for pancreatic and biliary access in altered anatomy (with videos). *Gastrointest Endosc* 2007; **66**: S47-S50 [PMID: 17709030 DOI: 10.1016/j.gie.2007.06.017]
 - 51 **Emmett DS**, Mallat DB. Double-balloon ERCP in patients who have undergone Roux-en-Y surgery: a case series. *Gastrointest Endosc* 2007; **66**: 1038-1041 [PMID: 17963892 DOI: 10.1016/j.gie.2007.06.056]
 - 52 **Aabakken L**, Bretthauer M, Line PD. Double-balloon enteroscopy for endoscopic retrograde cholangiography in patients with a Roux-en-Y anastomosis. *Endoscopy* 2007; **39**: 1068-1071 [PMID: 18072058 DOI: 10.1055/s-2007-966841]
 - 53 **Mönkemüller K**, Bellutti M, Neumann H, Malfertheiner P. Therapeutic ERCP with the double-balloon enteroscope in patients with Roux-en-Y anastomosis. *Gastrointest Endosc* 2008; **67**: 992-996 [PMID: 18279869 DOI: 10.1016/j.gie.2007.10.023]
 - 54 **Chu YC**, Yang CC, Yeh YH, Chen CH, Yueh SK. Double-balloon enteroscopy application in biliary tract disease-its therapeutic and diagnostic functions. *Gastrointest Endosc* 2008; **68**: 585-591 [PMID: 18561917 DOI: 10.1016/j.gie.2008.03.1083]
 - 55 **Koornstra JJ**, Fry L, Mönkemüller K. ERCP with the balloon-assisted enteroscopy technique: a systematic review. *Dig Dis* 2008; **26**: 324-329 [PMID: 19188723 DOI: 10.1159/000177017]
 - 56 **Matsushita M**, Shimatani M, Takaoka M, Okazaki K. “Short” double-balloon enteroscope for diagnostic and therapeutic ERCP in patients with altered gastrointestinal anatomy. *Am J Gastroenterol* 2008; **103**: 3218-3219 [PMID: 19086985 DOI: 10.1111/j.1572-0241.2008.02161_18.x]
 - 57 **Matsushita M**, Shimatani M, Takaoka M, Okazaki K. Effective endoscope for endoscopic retrograde cholangiopancreatography in patients with Roux-en-Y anastomosis: a single-, double-, or “short” double-balloon enteroscope? *Dig Dis Sci* 2010; **55**: 874-885; author reply 875 [PMID: 20108120 DOI: 10.1007/s10620-009-1110-z]
 - 58 **Matsushita M**, Shimatani M, Ikeura T, Takaoka M, Okazaki K. “Short” double-balloon or single-balloon enteroscopy for ERCP in patients with billroth II gastrectomy or Roux-en-Y anastomosis. *Am J Gastroenterol* 2010; **105**: 2294; author reply 2294-2295 [PMID: 20927071 DOI: 10.1038/ajg.2010.255]
 - 59 **Kuga R**, Furuya CK, Hondo FY, Ide E, Ishioka S, Sakai P. ERCP using double-balloon enteroscopy in patients with Roux-en-Y anatomy. *Dig Dis* 2008; **26**: 330-335 [PMID: 19188724 DOI: 10.1159/000177018]
 - 60 **Shimatani M**, Takaoka M, Matsushita M, Okazaki K. Endoscopic approaches for pancreaticobiliary diseases in patients with altered gastrointestinal anatomy. *Dig Endosc* 2014; **26** Suppl 1: 70-78 [PMID: 24118126 DOI: 10.1111/den.12175]
 - 61 **Shimatani M**, Takaoka M, Okazaki K. Tips for double balloon enteroscopy in patients with Roux-en-Y reconstruction and modified child surgery. *J Hepatobiliary Pancreat Sci* 2014; **21**: E22-E28 [PMID: 24307491 DOI: 10.1002/jhpb.53]
 - 62 **Kawamura T**, Yasuda K, Tanaka K, Uno K, Ueda M, Sanada K, Nakajima M. Clinical evaluation of a newly developed single-balloon enteroscopy. *Gastrointest Endosc* 2008; **68**: 1112-1116 [PMID: 18599052 DOI: 10.1016/j.gie.2008.03.1063]
 - 63 **Itoi T**, Ishii K, Sofuni A, Itokawa F, Tsuchiya T, Kurihara T, Tsuji S, Ikeuchi N, Umeda J, Moriyasu F. Single-balloon enteroscopy-assisted ERCP in patients with Billroth II gastrectomy or Roux-en-Y anastomosis (with video). *Am J Gastroenterol* 2010; **105**: 93-99 [PMID: 19809409 DOI: 10.1038/ajg.2009.559]
 - 64 **Dellon ES**, Kohn GP, Morgan DR, Grimm IS. Endoscopic retrograde cholangiopancreatography with single-balloon enteroscopy is feasible in patients with a prior Roux-en-Y anastomosis. *Dig Dis Sci* 2009; **54**: 1798-1803 [PMID: 18989776 DOI: 10.1007/s10620-008-0538-x]
 - 65 **Mönkemüller K**, Fry LC, Bellutti M, Neumann H, Malfertheiner P. ERCP using single-balloon instead of double-balloon enteroscopy in patients with Roux-en-Y anastomosis. *Endoscopy* 2008; **40** Suppl 2: E19-E20 [PMID: 18278720 DOI: 10.1055/s-2007-966949]

- 66 **Neumann H**, Fry LC, Meyer F, Malfertheiner P, Monkemüller K. Endoscopic retrograde cholangiopancreatography using the single balloon enteroscope technique in patients with Roux-en-Y anastomosis. *Digestion* 2009; **80**: 52-57 [PMID: 19478486 DOI: 10.1159/000216351]
- 67 **Moreels TG**, Pelckmans PA. Comparison between double-balloon and single-balloon enteroscopy in therapeutic ERC after Roux-en-Y entero-enteric anastomosis. *World J Gastrointest Endosc* 2010; **2**: 314-317 [PMID: 21160763 DOI: 10.4253/wjge.v2.i9.314]
- 68 **Wang AY**, Sauer BG, Behm BW, Ramanath M, Cox DG, Ellen KL, Shami VM, Kahaleh M. Single-balloon enteroscopy effectively enables diagnostic and therapeutic retrograde cholangiography in patients with surgically altered anatomy. *Gastrointest Endosc* 2010; **71**: 641-649 [PMID: 20189529 DOI: 10.1016/j.gie.2009.10.051]
- 69 **Tomizawa Y**, Sullivan CT, Gelrud A. Single balloon enteroscopy (SBE) assisted therapeutic endoscopic retrograde cholangiopancreatography (ERCP) in patients with roux-en-y anastomosis. *Dig Dis Sci* 2014; **59**: 465-470 [PMID: 24185681 DOI: 10.1007/s10620-013-2916-2]
- 70 **Lennon AM**, Kapoor S, Khashab M, Corless E, Amateau S, Dunbar K, Chandrasekhara V, Singh V, Okolo PI. Spiral assisted ERCP is equivalent to single balloon assisted ERCP in patients with Roux-en-Y anatomy. *Dig Dis Sci* 2012; **57**: 1391-1398 [PMID: 22198702 DOI: 10.1007/s10620-011-2000-8]
- 71 **Kogure H**, Watabe H, Yamada A, Isayama H, Yamaji Y, Itoi T, Koike K. Spiral enteroscopy for therapeutic ERCP in patients with surgically altered anatomy: actual technique and review of the literature. *J Hepatobiliary Pancreat Sci* 2011; **18**: 375-379 [PMID: 21116655 DOI: 10.1007/s00534-010-0357-2]
- 72 **Wagh MS**, Draganov PV. Prospective evaluation of spiral overtube-assisted ERCP in patients with surgically altered anatomy. *Gastrointest Endosc* 2012; **76**: 439-443 [PMID: 22817798 DOI: 10.1016/j.gie.2012.04.444]
- 73 **Bagci S**, Tuzun A, Ates Y, Gulsen M, Uygur A, Yesilova Z, Karaeren N, Dagalp K. Efficacy and safety of endoscopic retrograde cholangiopancreatography in patients with Billroth II anastomosis. *Hepatogastroenterology* 1999; **52**: 356-359 [PMID: 15816434]
- 74 **Faylona JM**, Qadir A, Chan AC, Lau JY, Chung SC. Small-bowel perforations related to endoscopic retrograde cholangiopancreatography (ERCP) in patients with Billroth II gastrectomy. *Endoscopy* 1999; **31**: 546-549 [PMID: 10533739 DOI: 10.1055/s-1999-61]
- 75 **Mönkemüller K**, Fry LC, Bellutti M, Neumann H, Malfertheiner P. ERCP with the double balloon enteroscope in patients with Roux-en-Y anastomosis. *Surg Endosc* 2009; **23**: 1961-1967 [PMID: 19067052 DOI: 10.1007/s00464-008-0239-8]
- 76 **Itoi T**, Ishii K, Sofuni A, Itokawa F, Tsuchiya T, Kurihara T, Tsuji S, Ikeuchi N, Fukuzawa K, Moriyasu F, Tsuchida A. Long- and short-type double-balloon enteroscopy-assisted therapeutic ERCP for intact papilla in patients with a Roux-en-Y anastomosis. *Surg Endosc* 2011; **25**: 713-721 [PMID: 20976503 DOI: 10.1007/s00464-010-1226-4]

P- Reviewer: Li YM, Tekin A, Wehrmann T **S- Editor:** Ji FF

L- Editor: A **E- Editor:** Wu HL





Published by **Baishideng Publishing Group Inc**

8226 Regency Drive, Pleasanton, CA 94588, USA

Telephone: +1-925-223-8242

Fax: +1-925-223-8243

E-mail: bpgoffice@wjgnet.com

Help Desk: <http://www.wjgnet.com/esps/helpdesk.aspx>

<http://www.wjgnet.com>

