

# World Journal of *Gastrointestinal Endoscopy*

*World J Gastrointest Endosc* 2017 December 16; 9(12): 561-593



### ORIGINAL ARTICLE

#### Retrospective Study

- 561 Gastric endoscopic submucosal dissection as a treatment for early neoplasia and for accurate staging of early cancers in a United Kingdom Caucasian population

*Sooltongos A, Davenport M, McGrath S, Vickers J, Senapati S, Akhtar K, George R, Ang Y*

#### Observational Study

- 571 Lumen-apposing metal stents for benign gastrointestinal tract strictures: An international multicenter experience

*Santos-Fernandez J, Paiji C, Shakhathreh M, Becerro-Gonzalez I, Sanchez-Ocana R, Yeaton P, Samarasena J, Perez-Miranda M*

### CASE REPORT

- 579 Retroperitoneal epithelioid sarcoma: A case report

*Coronado JA, Chávez MA, Manrique MA, Cerna J, Trejo AL*

- 583 Endoscopic ultrasound-guided fine-needle aspiration for diagnosing a rare extraluminal duodenal gastrointestinal tumor

*Hayashi K, Kamimura K, Hosaka K, Ikarashi S, Kohisa J, Takahashi K, Tominaga K, Mizuno K, Hashimoto S, Yokoyama J, Yamagiwa S, Takizawa K, Wakai T, Umezu H, Terai S*

- 590 Deanxit relieves symptoms in a patient with jackhammer esophagus: A case report

*Li JY, Zhang WH, Huang CL, Huang D, Zuo GW, Liang LX*

## Contents

*World Journal of Gastrointestinal Endoscopy*  
Volume 9 Number 12 December 16, 2017

### ABOUT COVER

Editorial Board Member of *World Journal of Gastrointestinal Endoscopy*, Gelu Osian, MD, PhD, Doctor, Head, Surgeon, Multi Organ Transplant Center, Department of Transplant Surgery, King Fahad Specialist Hospital-Dammam, Dammam 31444, Eastern Province, Saudi Arabia

### AIM AND SCOPE

*World Journal of Gastrointestinal Endoscopy* (*World J Gastrointest Endosc*, *WJGE*, online ISSN 1948-5190, DOI: 10.4253) is a peer-reviewed open access (OA) academic journal that aims to guide clinical practice and improve diagnostic and therapeutic skills of clinicians.

*WJGE* covers topics concerning gastroscopy, intestinal endoscopy, colonoscopy, capsule endoscopy, laparoscopy, interventional diagnosis and therapy, as well as advances in technology. Emphasis is placed on the clinical practice of treating gastrointestinal diseases with or under endoscopy.

We encourage authors to submit their manuscripts to *WJGE*. We will give priority to manuscripts that are supported by major national and international foundations and those that are of great clinical significance.

### INDEXING/ABSTRACTING

*World Journal of Gastrointestinal Endoscopy* is now indexed in Emerging Sources Citation Index (Web of Science), PubMed, and PubMed Central.

### FLYLEAF

#### I-III Editorial Board

### EDITORS FOR THIS ISSUE

Responsible Assistant Editor: *Xiang Li*  
Responsible Electronic Editor: *Ya-Jing Lu*  
Proofing Editor-in-Chief: *Lian-Sheng Ma*

Responsible Science Editor: *Li-Jun Cui*  
Proofing Editorial Office Director: *Xiu-Xia Song*

NAME OF JOURNAL  
*World Journal of Gastrointestinal Endoscopy*

ISSN  
ISSN 1948-5190 (online)

LAUNCH DATE  
October 15, 2009

FREQUENCY  
Monthly

EDITORS-IN-CHIEF  
**Atsushi Imagawa, PhD, Director, Doctor**, Department of Gastroenterology, Mitoyo General Hospital, Kan-onji, Kagawa 769-1695, Japan

**Juan Manuel Herrerias Gutierrez, PhD, Academic Fellow, Chief Doctor, Professor**, Unidad de Gestión Clínica de Aparato Digestivo, Hospital Universitario Virgen Macarena, Sevilla 41009, Spain

EDITORIAL BOARD MEMBERS  
All editorial board members resources online at <http://www.wjgnet.com>

[www.wjgnet.com/1948-5190/editorialboard.htm](http://www.wjgnet.com/1948-5190/editorialboard.htm)

EDITORIAL OFFICE  
Xiu-Xia Song, Director  
*World Journal of Gastrointestinal Endoscopy*  
Baishideng Publishing Group Inc  
7901 Stoneridge Drive, Suite 501, Pleasanton, CA 94588, USA  
Telephone: +1-925-2238242  
Fax: +1-925-2238243  
E-mail: [editorialoffice@wjgnet.com](mailto:editorialoffice@wjgnet.com)  
Help Desk: <http://www.f6publishing.com/helpdesk>  
<http://www.wjgnet.com>

PUBLISHER  
Baishideng Publishing Group Inc  
7901 Stoneridge Drive, Suite 501, Pleasanton, CA 94588, USA  
Telephone: +1-925-2238242  
Fax: +1-925-2238243  
E-mail: [bpgoffice@wjgnet.com](mailto:bpgoffice@wjgnet.com)  
Help Desk: <http://www.f6publishing.com/helpdesk>  
<http://www.wjgnet.com>

PUBLICATION DATE  
December 16, 2017

COPYRIGHT  
© 2017 Baishideng Publishing Group Inc. Articles published by this Open-Access journal are distributed under the terms of the Creative Commons Attribution Non-commercial License, which permits use, distribution, and reproduction in any medium, provided the original work is properly cited, the use is non commercial and is otherwise in compliance with the license.

SPECIAL STATEMENT  
All articles published in journals owned by the Baishideng Publishing Group (BPG) represent the views and opinions of their authors, and not the views, opinions or policies of the BPG, except where otherwise explicitly indicated.

INSTRUCTIONS TO AUTHORS  
<http://www.wjgnet.com/bpg/gerinfo/204>

ONLINE SUBMISSION  
<http://www.f6publishing.com>

## Deanxit relieves symptoms in a patient with jackhammer esophagus: A case report

Jin-Ying Li, Wen-Huan Zhang, Chun-Ling Huang, Dang Huang, Guo-Wen Zuo, Lie-Xin Liang

Jin-Ying Li, Wen-Huan Zhang, Chun-Ling Huang, Dang Huang, Guo-Wen Zuo, Lie-Xin Liang, Department of Gastroenterology, People's Hospital of Guangxi Zhuang Autonomous Region, Nanning 530021, Guangxi Zhuang Autonomous Region, China

ORCID number: Jin-Ying Li (0000-0002-4101-1553); Wen-Huan Zhang (0000-0002-4362-7378); Chun-Ling Huang (0000-0001-5512-173X); Dang Huang (0000-0003-2447-8319); Guo-Wen Zuo (0000-0002-3100-937X); Lie-Xin Liang (0000-0002-2029-5059).

**Author contributions:** Zuo GW designed the report; Li JY collected references and prepared the manuscript, with the help of Huang D; Zhang WH and Huang CL provided the figures; Zuo GW and Liang LX supervised the preparation of the manuscript.

**Informed consent statement:** The patient involved in this study gave his written informed consent authorizing use and disclosure of his protected health information.

**Conflict-of-interest statement:** All authors declare no conflict of interest.

**Open-Access:** This article is an open-access article which was selected by an in-house editor and fully peer-reviewed by external reviewers. It is distributed in accordance with the Creative Commons Attribution Non Commercial (CC BY-NC 4.0) license, which permits others to distribute, remix, adapt, build upon this work non-commercially, and license their derivative works on different terms, provided the original work is properly cited and the use is non-commercial. See: <http://creativecommons.org/licenses/by-nc/4.0/>

**Manuscript source:** Unsolicited manuscript

**Correspondence to:** Guo-Wen Zuo, MD, Department of Gastroenterology, People's Hospital of Guangxi Zhuang Autonomous Region, 6 Taoyuan Road, Nanning 530021, Guangxi Zhuang Autonomous Region, China. [mdzuoguwowen@163.com](mailto:mdzuoguwowen@163.com)  
Telephone: +86-771-2186007  
Fax: +86-771-2186007

**Received:** August 27, 2017

**Peer-review started:** August 27, 2017

**First decision:** October 9, 2017

**Revised:** October 25, 2017

**Accepted:** November 11, 2017

**Article in press:** November 11, 2017

**Published online:** December 16, 2017

### Abstract

Jackhammer (hypercontractile) esophagus presents with dysphagia and chest pain. Current treatments are limited. We describe a 60-year-old man who presented with dysphagia, chest pain and heartburn for a period of 1 year. His workup showed Barrett's esophagus on endoscopy and high-resolution manometry demonstrated jackhammer esophagus with esophagogastric junction outflow obstruction. The patient was treated with proton pump inhibitor and nifedipine but without resolution of his symptoms. He was followed up to assess the efficacy of treatment with deanxit (flupentixol + melitracen). Dysphagia and chest pain resolved during the therapeutic trial and efficacy was maintained on maintenance treatment without troublesome side effects.

**Key words:** High-resolution manometry; jackhammer esophagus; Deanxit; Therapy

© The Author(s) 2017. Published by Baishideng Publishing Group Inc. All rights reserved.

**Core tip:** Low-dose antidepressants can improve patients' reaction to the pain associated with esophageal dynamic disorders. The case report describes that deanxit (flupentixol + melitracen) has a positive effect on a new, rare disease, jackhammer esophagus, and speculates upon the potential relationship between mental factors and jackhammer esophagus.

Li JY, Zhang WH, Huang CL, Huang D, Zuo GW, Liang LX. Deanxit relieves symptoms in a patient with jackhammer esophagus: A case report. *World J Gastrointest Endosc* 2017; 9(12):



## INTRODUCTION

High-resolution manometry (HRM) has provided a new method for clinical diagnosis and treatment of esophageal motility disorders. Based on HRM techniques, the new Chicago classification has revised the esophageal motility disorder diagnostic criteria, mainly for achalasia and esophageal body motility disorders. Jackhammer esophagus is a new entity within spastic disorders of the esophagus<sup>[1]</sup>. Moreover, it has recently been described by a new Chicago Classification version 3.0 with at least two swallows with distal contractile integral (DCI) > 8000 mmHg-s-cm<sup>[2]</sup>. We describe a patient with impaired esophagogastric junction (EGJ) relaxation and hypercontractile peristaltic disorder, accompanying depressive disorder, which has not been reported in China. Treatment with deanxit (flupentixol + melitracen) led to an unusual recovery.

## CASE REPORT

A 60-year-old man visited our hospital because of a 1-year history of intermittent and recurrent episodes of dysphagia, chest pain and heartburn in January 2015. In another hospital, he had taken proton pump inhibitors (PPIs) for > 1 mo, but he was not relieved of any symptoms. There was nothing remarkable in his medical history. Physical and laboratory examinations showed no specific findings. Endoscopy showed possible Barrett's esophagus (BE) (Figure 1A). Moreover, esophageal mucosal biopsy suggested gastric mucosa ectopia. A barium esophagogram showed reflux esophagitis and spastic contraction in the distal esophagus (Figure 1B). He underwent HRM (Sierra Scientific Instruments, Los Angeles, CA, United States) and 24-h esophageal impedance-pH monitoring (Sierra Scientific Instruments). HRM showed that the maximum DCI was 8099.9 mmHg-s-cm and the integrated relaxation pressure (IRP) was 21.5 mmHg (Figure 1C). Pathological acid reflux was reported by 24-h esophageal impedance-pH evaluation (Figure 1D). Medical therapy with nifedipine 10 mg twice daily, esomeprazole 20 mg twice daily and teprenone 50 mg twice daily for approximately 10 mo showed no improvement in dysphagia and chest pain, but the symptoms of acid regurgitation and heartburn had relieved.

He was seen in our hospital in December 2015 with worsening dysphagia and chest pain. However, laboratory investigations were normal again including serum troponin level, electrocardiography monitoring and coronary angiography. HRM and 24-h esophageal impedance-pH monitoring were repeated. HRM showed typical hypercontractile contractions (6 swallows with DCI > 8000 mmHg-s-cm in 10 liquid swallows) and IRP 14.7 mmHg (Figure 2A), whereas impedance-pH

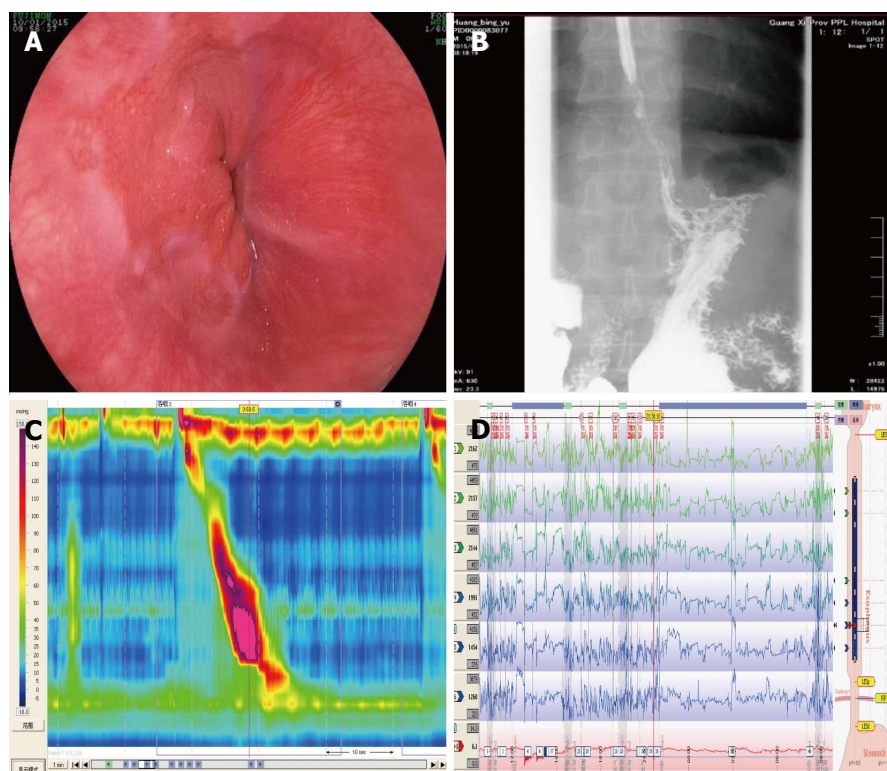
monitoring was negative (Figure 2B). Close examination of his medical history revealed long-term sleep disorders, with difficulty falling asleep, worrying about cancer, and anxiety. The patient was judged to be in a depressive state by a psychiatrist. Drug therapy was adjusted to deanxit 0.5 mg/10 mg (one piece) twice daily, rabeprazole 10 mg twice daily and hydrotalcite 1 g three times daily, and the patient's symptoms improved, with no obviously reflux, chest pain, and dysphagia after 5 d treatment. Moreover, he continued this therapy as-maintained basis.

At follow-up 5 mo later, the patient described clinical improvement with only one episode of dysphagia and chest pain, because of stopping his medication without permission. However, symptoms were relieved soon after he takes medicine. He was re-examined by HRM in May 2016, which showed IRP 10.1 mmHg (normal < 15 mmHg) and mean DCI 6750 mmHg-s-cm (Figure 3). The total period of treatment was 6 mo, with deanxit dose gradually reduced until withdrawal under the guidance of a psychologist and gastroenterologist. In June 2017, the patient had recovered well without recurrence of symptoms.

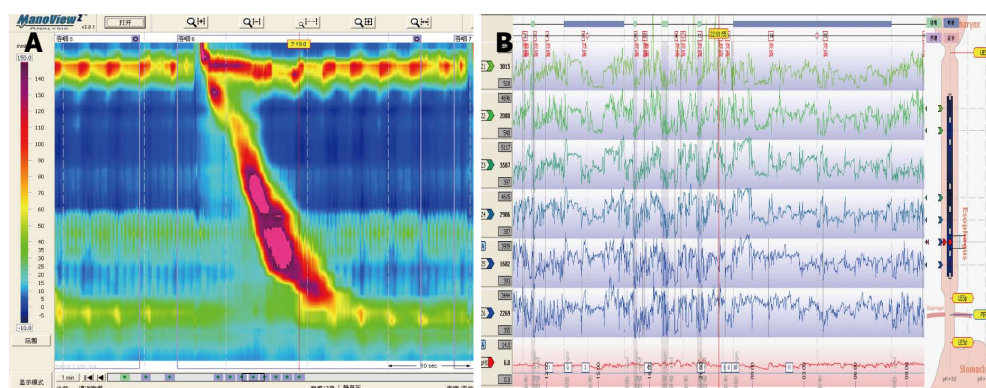
## DISCUSSION

Jackhammer esophagus is a rare disorder that occurs in 4% of patients referred to a tertiary center for HRM, and these patients with extreme phenotypes of esophageal hypercontractility present mainly with dysphagia, chest pain, and gastroesophageal reflux symptoms<sup>[3]</sup>. Nowadays there appears to be no clear consensus about optimal therapy, and options are similar to other esophageal dysmotility disorders. Pharmacological treatment should be considered first, with a combination of nitrates, calcium channel blockers, phosphodiesterase-5 inhibitors and PPIs having potential benefit<sup>[4]</sup>. Recently, Marjoux *et al*<sup>[5]</sup> reported that esophageal botulinum toxin was effective for treatment of hypertensive esophageal motility disorders. There were also recently reported cases of successful treatment with peroral endoscopic myotomy<sup>[6]</sup> and balloon dilatation<sup>[7]</sup>. Tsutomu *et al*<sup>[8]</sup> have reported that surgery using thoracoscopic esophageal extended myotomy is beneficial.

Patients with jackhammer esophagus can present with mechanical EGJ outflow obstruction, gastro-esophageal reflux disease, or primary esophageal muscle hypercontractility<sup>[3]</sup>. Our patient had high IRP; a hypercontractile peristaltic disorder of the esophagus that overlaps with BE. The first treatment strategy of spastic disorders depends on whether there is an accompanying EGJ outflow obstruction<sup>[4]</sup>. Moreover, there is a lack of evidence for the value of pharmacological treatment alone if EGJ relaxation is impaired. Therefore, we selected medical therapy first. A trial of nifedipine and PPIs have been chosen. The IRP was normal and changed to jackhammer esophagus without EGJ outflow obstruction and pathological acid reflux.



**Figure 1** The workup of the patient for the first time. A: Esophageal lesions of the patient under endoscopy, which were suggestive of BE; B: Barium esophagogram showing reflux esophagitis and spastic contraction in the distal esophagus; C: Representative swallow from the patient's initial HRM. The median IRP was high at 21.5 mmHg, and the DCI was elevated to 8099.9 mmHg-s-cm; D: 24-h pH-impedance monitoring. It can monitor 100% acid reflux into the esophagus. DCI: Distal contractile integral; HRM: High-resolution manometry; IRP: Integrated relaxation pressure.

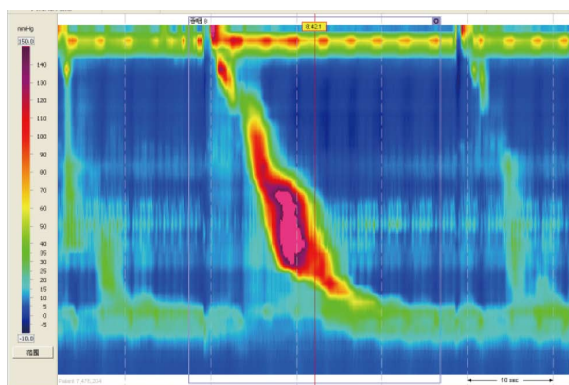


**Figure 2** Esophageal test results for the second time. A: Representative swallow from the patient's repeat esophageal HRM. Median IRP was normal at 14.7 mmHg. DCI was higher than normal, which was 8120.1 mmHg-s-cm, and six swallows with DCI > 8000 mmHg-s-cm in 10 liquid swallows. Esophageal manometry was consistent with jackhammer esophagus; B: 24-h pH-impedance monitoring was repeated, which was negative for gastroesophageal reflux disease. DCI: Distal contractile integral; HRM: High-resolution manometry; IRP: Integrated relaxation pressure.

Low-dose antidepressants can improve patients' reaction to pain without objectively improving motility function<sup>[9]</sup>. Our patient had obvious chest pain and dysphagia with esophageal hypercontractility. We allowed him to take antidepressants (deanxit) because he had depression. The patient's clinical and objective esophageal indexes were improved. Previous studies have established that the psychosocial aspects are related to gastroesophageal reflux disease and functional esophageal disorders, such as functional chest pain, functional dysphagia and hypersensitive esophagus<sup>[10,11]</sup>. In the present study, we examined the influence of the

relationship between mental factors and jackhammer esophagus. Deanxit had surprising efficacy for this patient, so we speculated that his depressive disorder may have caused hypercontractile peristaltic disorder because of nonspecific esophageal motility disorder. Alternatively, it may be that the patient endured painful symptoms for a long period, resulting in psychiatric comorbidity of jackhammer esophagus. The underlying pathological mechanisms in this case are unclear and deserve further study.

In summary, despite the evidence of efficacy, the long-term optimal management of jackhammer esophagus is



**Figure 3** A representative swallow from the patient's repeat esophageal high-resolution manometry after administration of deanxit. Median IRP was elevated at 10.1 mmHg. DCI of each swallow was higher than the normal range but < 8000 mmHg-cm-s, which was improved after treatment. DCI: Distal contractile integral; IRP: Integrated relaxation pressure.

not yet established. In our patient with a rare esophageal motility disorder and depression, antianxiety and antidepressant agents relieved his symptoms. However, the duration of treatment with antidepressants in patients with jackhammer esophagus and longer follow-up need further discussion.

## ARTICLE HIGHLIGHTS

### Case characteristics

A 60-year-old man with a 1-year history of intermittent and recurrent episodes of dysphagia, chest pain and heartburn, who had taken PPIs for a long time, but without relief of any symptoms.

### Clinical diagnosis

Dysphagia, chest pain and heartburn and depressive state.

### Differential diagnosis

Achalasia, gastroesophageal reflux disease, esophageal infections, esophageal carcinoma, coronary heart disease.

### Laboratory diagnosis

All laboratory parameters were within normal limits.

### Imaging diagnosis

High-resolution manometry (HRM) showed six swallows with distal contractile integral (DCI) > 8000 mmHg-s-cm in 10 liquid swallows and integrated relaxation pressure (IRP) 14.7 mmHg.

### Pathological diagnosis

Esophageal mucosa appeared as ectopia of gastric mucosa.

### Treatment

Deanxit for 6 mo, gradually reduced until withdrawal.

### Related reports

Jackhammer esophagus is a rare disorder, and current treatments are limited,

such as botulinum toxin injection, peroral endoscopic myotomy, and balloon dilatation.

### Term explanation

Jackhammer esophagus is a rare esophagus disorder, and patients with extreme phenotypes of esophageal hypercontractility present mainly with dysphagia, chest pain, and gastroesophageal reflux symptoms. Jackhammer esophagus is described by a new Chicago Classification version 3.0 with at least two swallows with DCI > 8000 mmHg-s-cm.

### Experiences and lessons

Patients with esophageal hypercontractility present mainly with dysphagia, chest pain, and HRM is the primary diagnostic method. Patients may also have mental illness, so at the time of diagnosis, psychological evaluation is necessary. Antianxiety and antidepressant agents are promising medical treatment to relieve symptoms in patients with jackhammer esophagus combined with psychosocial problems, but longer follow-up is needed.

## REFERENCES

- 1 Roman S, Pandolfino JE, Chen J, Boris L, Luger D, Kahrilas PJ. Phenotypes and clinical context of hypercontractility in high-resolution esophageal pressure topography (EPT). *Am J Gastroenterol* 2012; **107**: 37-45 [PMID: 21931377 DOI: 10.1038/ajg.2011.313]
- 2 Kahrilas PJ, Bredenoord AJ, Fox M, Gyawali CP, Roman S, Smout AJ, Pandolfino JE; International High Resolution Manometry Working Group. The Chicago Classification of esophageal motility disorders, v3.0. *Neurogastroenterol Motil* 2015; **27**: 160-174 [PMID: 25469569 DOI: 10.1111/nmo.12477]
- 3 Jia Y, Arenas J, Hejazi RA, Elhanafi S, Saadi M, McCallum RW. Frequency of Jackhammer Esophagus as the Extreme Phenotypes of Esophageal Hypercontractility Based on the New Chicago Classification. *J Clin Gastroenterol* 2016; **50**: 615-618 [PMID: 26927491 DOI: 10.1097/MCG.0000000000000496]
- 4 Roman S, Kahrilas PJ. Management of spastic disorders of the esophagus. *Gastroenterol Clin North Am* 2013; **42**: 27-43 [PMID: 23452629]
- 5 Marjoux S, Brochard C, Roman S, Gincul R, Pagenault M, Ponchon T, Ropert A, Mion F. Botulinum toxin injection for hypercontractile or spastic esophageal motility disorders: may high-resolution manometry help to select cases? *Dis Esophagus* 2015; **28**: 735-741 [PMID: 25212219 DOI: 10.1111/dote.12282]
- 6 Ko WJ, Lee BM, Park WY, Kim JN, Cho JH, Lee TH, Hong SJ, Cho JY. Jackhammer esophagus treated by a peroral endoscopic myotomy. *Korean J Gastroenterol* 2014; **64**: 370-374 [PMID: 25530589]
- 7 Pelletier AL, Pospai D, Merrouche M. Balloon against Jackhammer Disorder. *Case Rep Gastroenterol* 2013; **7**: 467-469 [PMID: 24403887 DOI: 10.1159/000355873]
- 8 Nomura T, Iwakiri K, Uchida E. Thoracoscopic treatment of a patient with jackhammer esophagus. *Dig Endosc* 2014; **26**: 753-754 [PMID: 25092351 DOI: 10.1111/den.12339]
- 9 Clouse RE, Lustman PJ, Eckert TC, Ferney DM, Griffith LS. Low-dose trazodone for symptomatic patients with esophageal contraction abnormalities. A double-blind, placebo-controlled trial. *Gastroenterology* 1987; **92**: 1027-1036 [PMID: 3549420]
- 10 Bilgi MM, Vardar R, Yildirim E, Veznedaroglu B, Bor S. Prevalence of Psychiatric Comorbidity in Symptomatic Gastroesophageal Reflux Subgroups. *Dig Dis Sci* 2017; **62**: 984-993 [PMID: 27565506 DOI: 10.1007/s10620-016-4273-4]
- 11 Drossman DA. Functional Gastrointestinal Disorders: History, Pathophysiology, Clinical Features and Rome IV. *Gastroenterology* 2016; Epub ahead of print [PMID: 27144617 DOI: 10.1053/j.gastro.2016.02.032]

P- Reviewer: Conzo G, Kvolik S, Yu SP S- Editor: Gong ZM

L- Editor: A E- Editor: Lu YJ





Published by **Baishideng Publishing Group Inc**  
7901 Stoneridge Drive, Suite 501, Pleasanton, CA 94588, USA  
Telephone: +1-925-223-8242  
Fax: +1-925-223-8243  
E-mail: [bpgoffice@wjgnet.com](mailto:bpgoffice@wjgnet.com)  
Help Desk: <http://www.f6publishing.com/helpdesk>  
<http://www.wjgnet.com>

