

World Journal of *Hepatology*

World J Hepatol 2021 November 27; 13(11): 1459-1815



FRONTIER

- 1459** Role of endoscopic ultrasound in the field of hepatology: Recent advances and future trends
Dhar J, Samanta J

OPINION REVIEW

- 1484** Porta-caval fibrous connections — the lesser-known structure of intrahepatic connective-tissue framework: A unified view of liver extracellular matrix
Patarashvili L, Gvidiani S, Azmaipharashvili E, Tsomaia K, Sareli M, Kordzaia D, Chanukvadze I

REVIEW

- 1494** Promising diagnostic biomarkers of nonalcoholic fatty liver disease and nonalcoholic steatohepatitis: From clinical proteomics to microbiome
Castillo-Castro C, Martagón-Rosado AJ, Ortiz-Lopez R, Garrido-Treviño LF, Villegas-Albo M, Bosques-Padilla FJ
- 1512** Fatty acid metabolism and acyl-CoA synthetases in the liver-gut axis
Ma Y, Nenkov M, Chen Y, Press AT, Kaemmerer E, Gassler N
- 1534** Liver involvement in inflammatory bowel disease: What should the clinician know?
Losurdo G, Brescia IV, Lillo C, Mezzapesa M, Barone M, Principi M, Ierardi E, Di Leo A, Rendina M
- 1552** Chelation therapy in liver diseases of childhood: Current status and response
Seetharaman J, Sarma MS
- 1568** Hepatocellular carcinoma: Understanding molecular mechanisms for defining potential clinical modalities
Natu A, Singh A, Gupta S
- 1584** Heterogeneity of non-alcoholic fatty liver disease: Implications for clinical practice and research activity
Pal P, Palui R, Ray S
- 1611** Newly discovered endocrine functions of the liver
Rhyu J, Yu R

MINIREVIEWS

- 1629** Current strategies to induce liver remnant hypertrophy before major liver resection
Del Basso C, Gaillard M, Lainas P, Zervaki S, Perlemuter G, Chagué P, Rocher L, Voican CS, Dagher I, Tranchart H
- 1642** Health-related quality of life in autoimmune hepatitis
Snijders RJ, Milkiewicz P, Schramm C, Gevers TJ

- 1653** Fungal infections following liver transplantation
Khalid M, Neupane R, Anjum H, Surani S
- 1663** Elastography as a predictor of liver cirrhosis complications after hepatitis C virus eradication in the era of direct-acting antivirals
Cerrito L, Ainora ME, Nicoletti A, Garcovich M, Riccardi L, Pompili M, Gasbarrini A, Zocco MA
- 1677** Role of immune dysfunction in drug induced liver injury
Girish C, Sanjay S
- 1688** Abnormal liver enzymes: A review for clinicians
Kalas MA, Chavez L, Leon M, Taweessdt PT, Surani S
- 1699** Hepatopulmonary syndrome: An update
Gandhi KD, Taweessdt PT, Sharma M, Surani S
- 1707** Mitochondrial hepatopathy: Respiratory chain disorders- 'breathing in and out of the liver'
Gopan A, Sarma MS
- 1727** Cystic fibrosis associated liver disease in children
Valamparampil JJ, Gupte GL

ORIGINAL ARTICLE**Case Control Study**

- 1743** Tumor characteristics of hepatocellular carcinoma after direct-acting antiviral treatment for hepatitis C: Comparative analysis with antiviral therapy-naïve patients
Fouad M, El Kassas M, Ahmed E, El Sheemy R
- 1753** Circulating microRNA 9-3p and serum endocan as potential biomarkers for hepatitis C virus-related hepatocellular carcinoma
Wahb AMSE, El Kassas M, Khamis AK, Elhelbawy M, Elhelbawy N, Habieb MSE

Retrospective Cohort Study

- 1766** Do peripartum and postmenopausal women with primary liver cancer have a worse prognosis? A nationwide cohort in Taiwan
Tseng GW, Lin MC, Lai SW, Peng CY, Chuang PH, Su WP, Kao JT, Lai HC
- 1777** Nonalcoholic fatty liver disease is associated with worse intestinal complications in patients hospitalized for *Clostridioides difficile* infection
Jiang Y, Chowdhury S, Xu BH, Meybodi MA, Damiris K, Devalaraju S, Pyrsopoulos N

Observational Study

- 1791** Six-minute walking test performance is associated with survival in cirrhotic patients
Pimentel CFMG, Amaral ACC, Gonzalez AM, Lai M, Mota DO, Ferraz MLG, Junior WM, Kondo M

SYSTEMATIC REVIEWS

- 1802** Incidence of umbilical vein catheter-associated thrombosis of the portal system: A systematic review and meta-analysis

Bersani I, Piersigilli F, Iacona G, Savarese I, Campi F, Dotta A, Auriti C, Di Stasio E, Garcovich M

ABOUT COVER

Editorial Board Member of *World Journal of Hepatology*, Igor Skrypnyk, MD, MDS, PhD, Professor, Internal Medicine #1, Poltava State Medical University, Poltava 36011, Ukraine. inskrypnyk@gmail.com

AIMS AND SCOPE

The primary aim of *World Journal of Hepatology* (*WJH*, *World J Hepatol*) is to provide scholars and readers from various fields of hepatology with a platform to publish high-quality basic and clinical research articles and communicate their research findings online.

WJH mainly publishes articles reporting research results and findings obtained in the field of hepatology and covering a wide range of topics including chronic cholestatic liver diseases, cirrhosis and its complications, clinical alcoholic liver disease, drug induced liver disease autoimmune, fatty liver disease, genetic and pediatric liver diseases, hepatocellular carcinoma, hepatic stellate cells and fibrosis, liver immunology, liver regeneration, hepatic surgery, liver transplantation, biliary tract pathophysiology, non-invasive markers of liver fibrosis, viral hepatitis.

INDEXING/ABSTRACTING

The *WJH* is now abstracted and indexed in PubMed, PubMed Central, Emerging Sources Citation Index (Web of Science), Scopus, China National Knowledge Infrastructure (CNKI), China Science and Technology Journal Database (CSTJ), and Superstar Journals Database. The 2021 edition of Journal Citation Reports® cites the 2020 Journal Citation Indicator (JCI) for *WJH* as 0.61. The *WJH*'s CiteScore for 2020 is 5.6 and Scopus CiteScore rank 2020: Hepatology is 24/62.

RESPONSIBLE EDITORS FOR THIS ISSUE

Production Editor: *Xu Guo*; Production Department Director: *Xiang Li*; Editorial Office Director: *Xiang Li*.

NAME OF JOURNAL

World Journal of Hepatology

ISSN

ISSN 1948-5182 (online)

LAUNCH DATE

October 31, 2009

FREQUENCY

Monthly

EDITORS-IN-CHIEF

Nikolaos Pylsopoulos, Ke-Qin Hu, Koo Jeong Kang

EDITORIAL BOARD MEMBERS

<https://www.wjnet.com/1948-5182/editorialboard.htm>

PUBLICATION DATE

November 27, 2021

COPYRIGHT

© 2021 Baishideng Publishing Group Inc

INSTRUCTIONS TO AUTHORS

<https://www.wjnet.com/bpg/gerinfo/204>

GUIDELINES FOR ETHICS DOCUMENTS

<https://www.wjnet.com/bpg/GerInfo/287>

GUIDELINES FOR NON-NATIVE SPEAKERS OF ENGLISH

<https://www.wjnet.com/bpg/gerinfo/240>

PUBLICATION ETHICS

<https://www.wjnet.com/bpg/GerInfo/288>

PUBLICATION MISCONDUCT

<https://www.wjnet.com/bpg/gerinfo/208>

ARTICLE PROCESSING CHARGE

<https://www.wjnet.com/bpg/gerinfo/242>

STEPS FOR SUBMITTING MANUSCRIPTS

<https://www.wjnet.com/bpg/GerInfo/239>

ONLINE SUBMISSION

<https://www.f6publishing.com>



Current strategies to induce liver remnant hypertrophy before major liver resection

Celeste Del Basso, Martin Gaillard, Panagiotis Lainas, Stella Zervaki, Gabriel Perlemuter, Pierre Chagué, Laurence Rocher, Cosmin Sebastian Voican, Ibrahim Dagher, Hadrien Tranchart

ORCID number: Celeste Del Basso 0000-0003-3606-9512; Martin Gaillard 0000-0003-1539-2118; Panagiotis Lainas 0000-0002-2438-8519; Stella Zervaki 0000-0001-6289-6437; Gabriel Perlemuter 0000-0001-9985-8725; Pierre Chagué 0000-0003-3992-537X; Laurence Rocher 0000-0002-3775-6886; Cosmin Sebastian Voican 0000-0002-7161-9631; Ibrahim Dagher 0000-0002-3989-7148; Hadrien Tranchart 0000-0003-2173-2828.

Author contributions: Del Basso C, Zervaki S, Voican CS made substantial contributions to conception and design of the study, acquisition of data, analysis and interpretation of data; Del Basso C, Gaillard M, Lainas P and Tranchart H wrote the article and made critical revisions related to important intellectual content of the manuscript; Perlemuter G, Dagher I, Rocher L and Chagué P approved the version of the article to be published.

Conflict-of-interest statement: The authors declare that they have no conflict of interest.

Country/Territory of origin: France

Specialty type: Gastroenterology and hepatology

Provenance and peer review: Invited article; Externally peer

Celeste Del Basso, Martin Gaillard, Panagiotis Lainas, Stella Zervaki, Ibrahim Dagher, Hadrien Tranchart, Department of Minimally Invasive Digestive Surgery, Antoine Bécélère Hospital, Clamart 92140, France

Gabriel Perlemuter, Cosmin Sebastian Voican, Department of Hepato-Gastroenterology and Nutrition, Antoine Bécélère Hospital, Clamart 92140, France

Pierre Chagué, Laurence Rocher, Department of Radiology, Antoine Bécélère Hospital, Clamart 92140, France

Corresponding author: Hadrien Tranchart, MD, PhD, Associate Professor, Department of Minimally Invasive Digestive Surgery, Antoine Bécélère Hospital, 157 rue de la Porte de Trivaux, Clamart 92140, France. hadrien.tranchart@aphp.fr

Abstract

Hepatic resection is the gold standard for patients affected by primary or metastatic liver tumors but is hampered by the risk of post-hepatectomy liver failure. Despite recent improvements, liver surgery still requires excellent clinical judgement in selecting patients for surgery and, above all, efficient pre-operative strategies to provide adequate future liver remnant. The aim of this article is to review the literature on the rational, the preliminary assessment, the advantages as well as the limits of each existing technique for preparing the liver for major hepatectomy.

Key Words: Liver regeneration; Major hepatectomy; Liver insufficiency; Future liver remnant; Portal vein embolization

©The Author(s) 2021. Published by Baishideng Publishing Group Inc. All rights reserved.

Core Tip: Hepatic resection is the gold standard for patients affected by liver tumors but is hampered by the risk of post-hepatectomy liver failure. We herein review the literature on the rational, the preliminary assessment, the advantages as well as the limits of each existing technique for preparing the liver for major hepatectomy.

reviewed.

Peer-review report's scientific quality classification

Grade A (Excellent): 0
Grade B (Very good): B
Grade C (Good): 0
Grade D (Fair): 0
Grade E (Poor): 0

Open-Access: This article is an open-access article that was selected by an in-house editor and fully peer-reviewed by external reviewers. It is distributed in accordance with the Creative Commons Attribution NonCommercial (CC BY-NC 4.0) license, which permits others to distribute, remix, adapt, build upon this work non-commercially, and license their derivative works on different terms, provided the original work is properly cited and the use is non-commercial. See: <http://creativecommons.org/licenses/by-nc/4.0/>

Received: February 23, 2021

Peer-review started: February 23, 2021

First decision: June 4, 2021

Revised: June 8, 2021

Accepted: October 11, 2021

Article in press: October 11, 2021

Published online: November 27, 2021

P-Reviewer: Jin Y

S-Editor: Wang LL

L-Editor: Webster JR

P-Editor: Wang LL



Citation: Del Basso C, Gaillard M, Lainas P, Zervaki S, Perlemuter G, Chagué P, Rocher L, Voican CS, Dagher I, Tranchart H. Current strategies to induce liver remnant hypertrophy before major liver resection. *World J Hepatol* 2021; 13(11): 1629-1641

URL: <https://www.wjgnet.com/1948-5182/full/v13/i11/1629.htm>

DOI: <https://dx.doi.org/10.4254/wjh.v13.i11.1629>

INTRODUCTION

Hepatic resection is the gold standard for patients affected by primary or metastatic liver tumors but is hampered by the risk of post hepatectomy liver failure (PHLF). Indeed, PHLF is considered the most frightening complication of liver surgery, representing a major source of severe morbidity and mortality[1]. Despite recent improvements, liver surgery still requires excellent clinical judgement in selecting patients for surgery and, above all, efficient pre-operative tools to provide an adequate future liver remnant (FLR).

The liver has a unique capacity of preserving its volume due to regeneration. The atrophy-hypertrophy phenomenon is a prime example of the liver's pathophysiological (atrophy) and restorative (hypertrophy) response to injury[2]. It occurs whenever there is impairment of bile or blood flow: the liver reacts with atrophy of the region concerned and with compensatory hypertrophy of the less or not impaired regions, resulting in characteristic gross deformity of the organ and, in some instances, in rotation of the liver around a virtual hilar axis[3]. The mechanisms that induce cellular division are complex and based on different inflammatory cytokines. The Hepatocyte Growth Factor (HGF) seems to be the main mitogenic factor and its role has been established in liver regeneration[4].

The first case of *in vivo* human hepatic regeneration was described by Pack *et al*[5] in 1962. Starting from animal models in the first half of the 20th century, it was recognized that liver regeneration could also be induced by portal vein ligation (PVL)[6]. In 1986, the first cases of percutaneous transhepatic portal vein embolization (PVE) were performed before liver resection in the setting of hepatocellular carcinoma[7], and a few years later Makuuchi *et al*[8] reported the utility of PVE in promoting FLR hypertrophy prior to hepatic resection in patients with hilar cholangiocarcinoma. Since those initial reports, preoperative PVE has been established as the standard procedure for obtaining FLR hypertrophy, increasing the eligibility of patients for major hepatectomy as well as improving postoperative outcomes and safety. However, concerns regarding the insufficient increase of FLR and/or concomitant tumoral progression after PVE have led to the development of recent alternative techniques to push further the limits of liver surgery.

The aim of this article is to review the techniques available for preparing the liver for major hepatectomy, and to depict their advantages and limitations.

LIVER REGENERATION

The liver's unique capacity for regeneration was first recorded in the legend of Prometheus in Greek mythology and it represents the basis of the treatment of many liver diseases. Regeneration of the liver is a pathophysiological process, embracing both hypertrophy (increase in cell size or protein content in the prereplicative phase) and hyperplasia (increase in cell numbers). Both events can take place independently [9]. The mechanisms of liver regeneration have mainly been studied after extensive hepatectomy. The players of regeneration following the different techniques exposed in this article are thought to be similar to those after hepatectomy, but the precise mechanism remains unknown. Basically, the regeneration process is a cytokine- and growth-factor-mediated pathway. The main cytokine-mediated pathways include members of the innate immune system, tumor necrosis factor (TNF) α and interleukin (IL)-6, and growth-factor-mediated pathways are regulated by HGF and transforming growth factor (TGF) α [10]. It is a multi-step process, starting from the "priming" of hepatocytes, the moment they acquire replicative capacity, followed by the proliferative step in which an adequate cell mass is attained, and a termination stage in which liver cell proliferation is ended once the necessary functional mass has been reached[11]. Proliferation of hepatocytes advances from periportal to pericentral areas of the lobule, as a wave of mitoses[12]. Proliferation of biliary epithelial cells occurs a

little later than hepatocytes. The particularity of liver regeneration is that replacement of the lost hepatic mass is not mediated by selected stem cells proliferation but it entirely depends on mature adult hepatocytes and other hepatic cell types. Concerning the time interval, as far as we know, normal liver weight is reestablished within 8-15 d in humans[13].

POST-HEPATECTOMY LIVER FAILURE

Although morbidity and mortality after liver surgery have improved over the past 10 years, PHLF is still reported in up to 8%, ranging from 1.2% to 32%, and depends on the patient's condition and functional reserve of the liver before resection[1]. Different definitions of PHLF are available. In 2011, the International Study Group of Liver Surgery (ISGLS) defined PHLF as "a post-operatively acquired deterioration in the ability of the liver to maintain its synthetic, excretory, and detoxifying functions, which are characterized by an increased International Normalized Ratio (INR) and concomitant hyperbilirubinemia on or after postoperative day 5"[14]. It is worth pointing out that severe PHLF is associated with a mortality rate of 54%.

A related syndrome that results in a transient but sometimes fatal form of liver failure has been described following liver transplantation (LT) but also after extensive liver resection. This is the so-called Small For Size Syndrome (SFSS). In 2005, Dahm *et al*[15] defined SFSS as a graft to recipient weight ratio < 0.8% alongside two of the following for three consecutive days; bilirubin > 100 mmol/L, INR > 2 and encephalopathy grade 3 or 4. In this definition, SFSS is a clinical syndrome characterized by post-operative liver dysfunction, prolonged cholestasis and coagulopathy, portal hypertension and ascites. It can lead to a higher rate of hemorrhage, sepsis and gastrointestinal bleeding[16]. The key point of SFSS is the presence of portal hypertension and intra-hepatic portal congestion as the underlying cause of liver failure[17].

PREDICTION OF PHLF RISK

Despite improvements in surgical and postoperative management, parameters determining the degree of possible hepatectomy remain largely uncertain. Different patient related and surgical factors have to be considered to decrease PHLF incidence. Surgical factors include the extent of resection and volume of FLR, duration of intraoperative liver ischemia during portal pedicle clamping, duration of surgery and the need for blood transfusion. The risk of PHLF is highly influenced by the quality of underlying liver parenchyma. The type of underlying liver parenchyma is frequently assessed by preoperative liver biopsy, but noninvasive methods, such as liver stiffness, are now available. For example, liver stiffness measurement by transient elastography (Fibroscan) predicts persistent hepatic decompensation in patients undergoing resection for hepatocellular carcinoma[18].

It is generally thought that the minimal functional liver mass needed for adequate postoperative liver function is estimated to be 20%-25% in patients with normal liver parenchyma, whereas those with chemotherapy-induced liver injury require a FLR volume of approximately 30%, while those with cirrhosis at least a 40% minimal functional liver mass[19]. Therefore, standardized FLR volume can be easily evaluated by a tridimensional computed tomography (CT) reconstruction method, as FLR/estimated total liver volume[20]. Estimated total liver volume is generally calculated using a formula based on body surface area[21].

In addition to volume, estimation of FLR function is an important factor. Typical biochemical parameters, such as liver function tests, albumin, and clotting factors must be evaluated. The old but effective Child-Turcotte-Pugh score, which was introduced in 1964, still represents a simple system for grading liver function[22]. The model for end-stage liver disease score, which is mainly used in liver transplantation, can also predict the survival rate of cirrhotic patients to better select ideal candidates for surgery[23]. A recent study also showed that mean serum level of hyaluronic acid can be a useful tool, especially when liver biopsy is not feasible[24].

Dynamic tests of liver function can also be used. The most well-known is indocyanine green (ICG) clearance. ICG is a water soluble, inert, fluorescent tricarboxyanine dye with protein binding close to 95% (mainly, alpha1- and beta-lipoproteins and albumin), a hepatic extraction rate above 70%, and is almost completely excreted in its unchanged form by the liver. ICG elimination can be

expressed as ICG plasma disappearance rate (ICGPDR) or retention rate at 15 min (ICGR15), reflecting liver function. Use of the ICG test for patient selection has been shown to decrease postoperative mortality[25].

In recent years, there have been several attempts to assess hepatobiliary magnetic resonance imaging (MRI) as a tool to predict liver dysfunction. Since it was first described in 1991 by Weinmann *et al*[26], MRI has been showed to provide both global and segmental liver function information, and postoperative remnant liver function thanks to the measurement of liver signal intensity in the hepatobiliary phase.

Liver function evaluation by nuclear medicine techniques is also more and more used. Dynamic ^{99m}Tc-mebrofenin hepatobiliary scintigraphy has been used to provide quantitative information on total and regional liver function. The hepatic uptake of ^{99m}Tc-mebrofenin is similar to the uptake of organic anions such as bilirubin[27]. This technique efficiently estimates the risk of postoperative liver failure especially in patients with uncertain quality of liver parenchyma[28]. The ^{99m}Tc-GSA is another recently proposed agent that is not affected by hyperbilirubinemia and can be used for liver function assessment in cholestatic patients[29]. Finally, the LiMAx test allows real-time *in vivo* determination of liver Cytochrome P450 1A2 (CYP1A2) activity. The CYP1A2 is not influenced by cholestasis or drugs and is ubiquitous in liver parenchyma. Intravenous administration of ¹³C methacetin, a substance exclusively metabolized by CYP1A2, with continuous real-time breath analysis represents the basis of the LiMAx test[30].

PORTAL VEIN EMBOLIZATION

Since the first report in 1986, PVE has progressively become the gold standard for inducing liver hypertrophy with satisfying safety and efficacy[31]. Initially described by laparotomy, the portal system access is now obtained by percutaneous puncture of the portal vein. According to the operator's preference, an ipsilateral or contralateral approach can be chosen, in reference to the segment bearing the tumor. The ipsilateral approach has the main advantage of protecting the FLR from injury[2] whereas the contralateral approach facilitates embolization[32]. Irrespective of the approach chosen, PVE is performed in a retrograde manner (Figure 1). Many embolic materials have been used for PVE without significant differences in terms of hypertrophy. Embolic materials include fibrin glue, N-butyl-2-cyanoacrylate and ethiodized oil, gelatin sponge and thrombin, coils, microparticles [*e.g.*, polyvinyl alcohol (PVA) particles or tris-acryl gelatin microspheres] and absolute alcohol[33]. A non-absorbable material is generally used. However, interesting results were reported with the use of an absorbable powder material (Gelfoam® powder, Pfizer, New York, USA) that lasts approximately 2 wk, leading to temporary PVE. In an animal model, this method showed efficient and stable liver regeneration[34]. These results were confirmed in a limited preliminary series in clinical practice[35] and a prospective study is undergoing (EMBORES study, NCT02945059). One of the advantages of temporary PVE is that it can theoretically be repeated several times to boost more liver hypertrophy, as has been suggested in an animal model[36].

PVE is successfully performed in more than 90% of cases[37]. A computed tomography scan with volumetric evaluation is generally performed between 4 and 8 wk after embolization. PVE induces a FLR hypertrophy that can reach 40%[37], with a low 2% morbidity rate and no mortality in the vast majority of studies[37-39]. PVE is considered an efficient method, allowing successful hepatectomy in more than 70% of cases[37,38,40].

Contraindications to PVE are extensive portal thrombus and important portal hypertension[41]. Another potential limit of PVE is the risk of tumor growth during the 4 to 8 wk separating PVE and liver surgery. In addition, several authors have suggested that PVE itself could promote tumor growth within the embolized liver[42-45]. Among others, these reasons have led to the development of alternative strategies.

PORTAL VEIN LIGATION (PVL) AND TWO-STAGE HEPATECTOMY

As it requires a surgical procedure with portal pedicles dissection, PVL is nowadays mainly indicated in the setting of two-stage hepatectomy (TSH) for the treatment of bilobar liver disease[46,47]. In the TSH strategy, the first surgical step includes tumoral clearance of the FLR (usually by parenchymal sparing resections or locoregional treatment like radiofrequency ablation) and concomitant PVL that allows FLR growth.

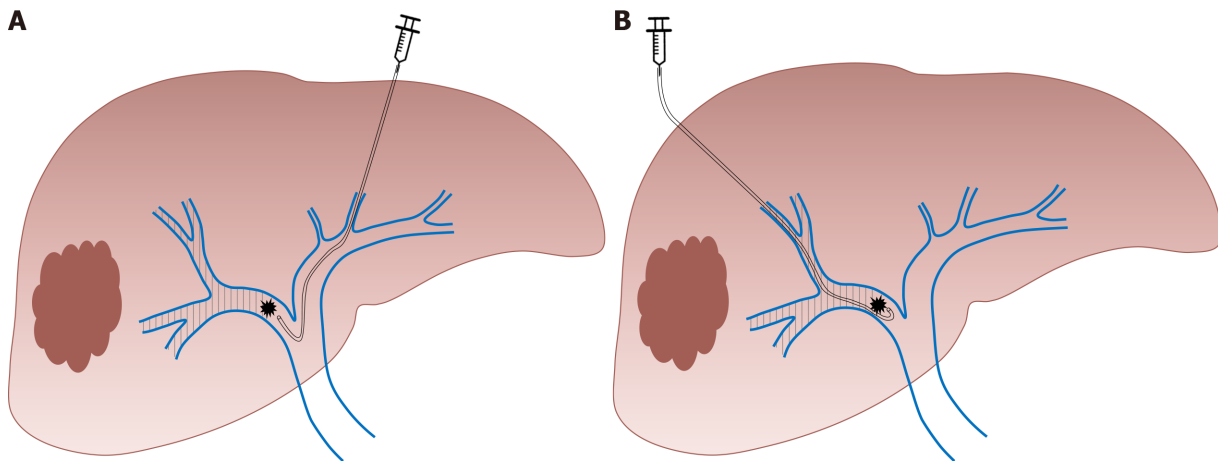


Figure 1 Right portal vein embolization using. A: Contralateral; B: Ipsilateral approach.

In the second step, after liver regeneration (approximately 4 to 8 wk later), major liver resection is performed (usually right or right extended hepatectomy) (Figure 2). Similarly, PVL can be performed for the management of patients presenting synchronous colorectal metastases or neuroendocrine tumors[47]. The first surgical step associates colorectal resection with PVL, followed by major liver surgery in the second procedure. However, many centers have adopted PVE (performed by the percutaneous approach after FLR clearance or colorectal resection) for two-step procedures, avoiding portal pedicle dissection and facilitating the second procedure [48].

It was initially suggested that PVE resulted in superior FLR growth compared to PVL[49] as in theory PVE allows distal portal obstruction which decreases the possibility of intrahepatic collateral development. Several studies demonstrated that the results are globally similar[50,51]. In fact, the debate concerning the efficiency of PVL compared to PVE is no longer relevant. PVL requires a surgical procedure and can appear as an alternative to PVE only when a two-step surgery is planned. In other cases, percutaneous PVE is clearly a simpler and better tolerated approach.

ASSOCIATING LIVER PARTITION AND PORTAL VEIN LIGATION FOR STAGED HEPATECTOMY

The aim of this alternative strategy, described by Schnitzbauer *et al*[52] in 2012, is to induce rapid and massive liver hypertrophy, to allow liver surgery in a short period of time in patients with initially very limited FRL volume. The first step of the associating liver partition and portal vein ligation for staged hepatectomy (ALPPS) procedure consists of performing PVL and an *in situ* splitting of the liver parenchyma, leaving the hepatic artery, bile duct, and hepatic vein intact until the subsequent operation. This first surgical step can be associated with tumoral clearance of the FRL. During the second operation (that can be performed one to two weeks later) the remaining hepatic artery, bile duct, and hepatic vein are divided and the liver specimen is extracted (Figure 3).

The first report demonstrated a morbidity rate of 44% and a mortality rate of 12% [52], and triggered an intense debate on the safety of this procedure, limiting its promotion worldwide. The morbi-mortality rate decreased with experience but remains high, with approximately 40% of major postoperative complications and 9% of mortality[53]. Nevertheless, the ALPPS technique induces more than 65% of FLR growth in approximately 7 days[52-55] and the second procedure is feasible in more than 90% of cases[56]. The main advantage of the ALPPS procedure is the rapid increase in FLR volume in a short interval and therefore a shorter interval between the two stages. Although the volumetric results of this technique are impressive, several authors suggested that FLR volume hypertrophy is not correlated to functional improvement[57,58] which could partly explain the high morbidity of the procedure. Besides, concerns have been raised by some authors regarding potentially poorer oncological results comparing to the classical TSH[59]. The results of a meta-analysis comparing ALPPS to TSH showed that the extent of FLR increase was not different

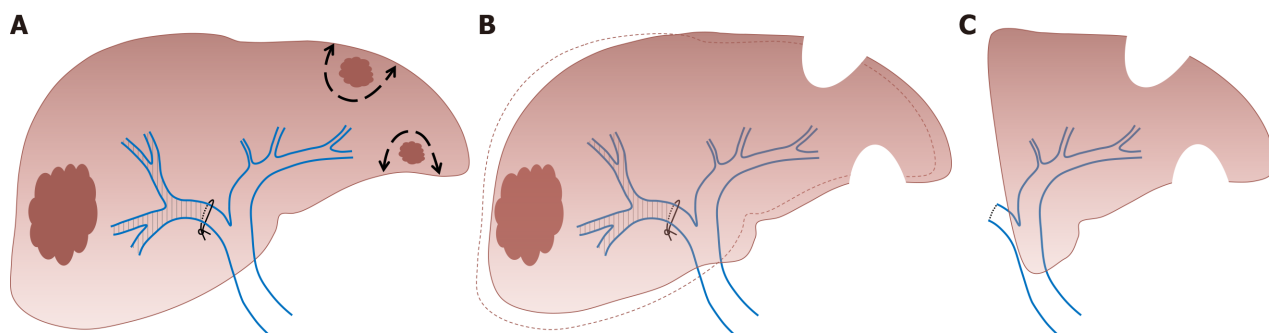


Figure 2 Two-stage hepatectomy procedure starts with tumoral clearance of the future liver remnant. A: Concomitant right portal vein ligation; B: Allowing left liver growth; C: Ends with right hepatectomy.

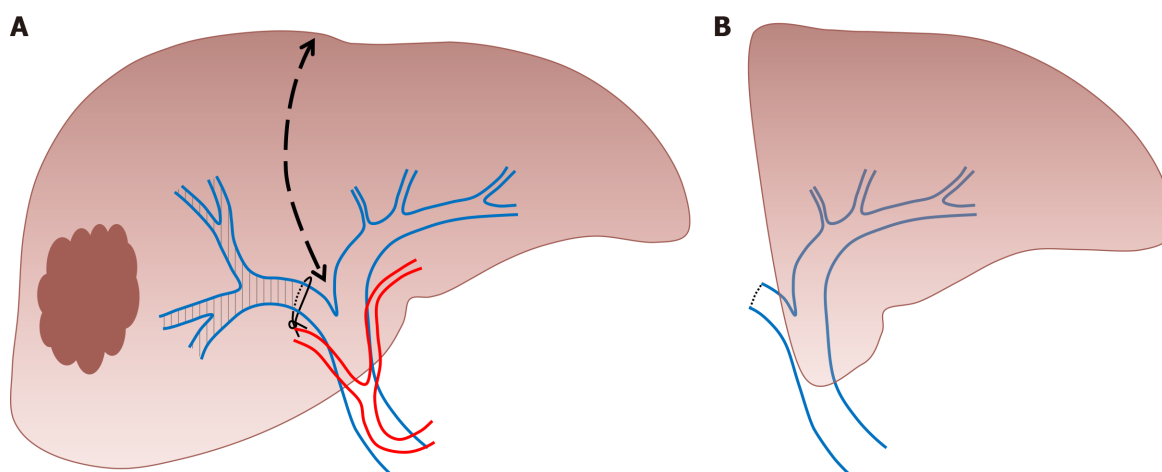


Figure 3 Associating liver partition and portal vein ligation for staged hepatectomy procedure. A: Starts with *in situ* splitting of the liver parenchyma with concomitant right portal vein ligation; B: Ends with right hepatectomy.

between the two groups[60]. The time needed to reach final liver volume was shorter in ALPPS than in the TSH approach[60]. In this meta-analysis, ALPPS was associated with a higher incidence of major and overall morbidity and mortality compared to TSH[60]. However, in a recent randomized controlled trial, Hasselgren *et al*[61] observed similar morbidity between ALPPS and classical TSH and an improved survival in the ALPPS group.

To decrease complication rate, a variety of technical modifications have been proposed such as partial-ALPPS, mini-ALPPS, tourniquet-ALPPS, hybrid-ALPPS, microwave ablation-assisted ALPPS and radiofrequency ablation-assisted ALPPS. Huang *et al*[62] suggested in a systematic review that a partial ALPPS technique in which only partial parenchymal sparing is performed during the first surgical step could achieve lower morbidity and mortality rates, reaching the same FLR hypertrophy rate as ALPPS in non-cirrhotic patients.

SEQUENTIAL TRANS-ARTERIAL EMBOLIZATION (TAE) AND PORTAL VEIN EMBOLIZATION

Although PVE remains the gold standard for FLR hypertrophy, two concerns persist with this approach: An insufficient contralateral hypertrophy, particularly in patients with underlying liver disease (steatosis, fibrosis or cirrhosis), and the eventuality of tumor progression while waiting for the non-embolized liver to hypertrophy. In particular, portal flow interruption may induce a compensatory increase in arterial blood flow of embolized segments and result in a paradoxical growth of tumors vascularized by arterial blood flow. In this context, it has been postulated that the addition of trans-arterial embolization (TAE) or trans-arterial chemoembolization (TACE) would produce more rapid and extensive FLR growth (by obtaining

obliteration of intrahepatic arterioportal shunts) and may help to counteract the stimulating effect on tumor growth[63]. Therefore, hepatocellular carcinomas, which are tumors particularly vascularized by arterial blood flow and develop generally in underlying pathological liver parenchyma, are the main target of this combined strategy[64].

During TAE, a catheter is directly inserted *via* either the common femoral or left radial artery and an intra-arterial injection of a combination of microspheres and PVA particles is performed in the arterial branches of the segments to be resected. During TACE, an intra-arterial injection of a cytotoxic drug is performed such as doxorubicin, epirubicin, idarubicin, mitomycin C, or cisplatin, that is emulsified in ethiodized oil (Lipiodol® Ultra-Fluid, Guerbet). This is followed by intra-arterial injection of an embolic agent, such as gelatin sponge, PVA particles, or microspheres[65] (Figure 4). TACE can also be performed using recently developed drug-eluting beads (DEB) that allow the slow release of chemotherapeutic agents, and increase ischemia intensity and duration[65].

A sequential approach, with a time interval of a few days, is recommended to limit the risk of nontumoral liver ischemic necrosis[66] and TAE is mostly performed before PVE[66,67]. Although the number of patients reported in studies that evaluated this approach is limited, observed FLR hypertrophy is generally superior to that observed after isolated PVE. For example, Yoo *et al*[68] reported a statistically significant increase of 7.3% and 5.8% in FLR (over the total liver volume) for sequential TACE/PVE and isolated PVE, respectively.

An important elevation of transaminases is generally observed after this sequential approach without important clinical consequences. In the largest series reporting this approach, Peng *et al*[64] reported 29 procedures without deaths and only one complication and 27 patients (93%) underwent subsequent hepatectomy. Post-hepatectomy morbidity and mortality among these patients was 27.5% and 6.9%, respectively.

Theoretical contraindications of this method include extensive portal thrombus, important portal hypertension or previous biliary surgery (biliodigestive anastomosis) which exposes the patient to hepatic abscess formation after arterial embolization.

LIVER VENOUS DEPRIVATION

This technique consists of performing conventional PVE and ipsilateral hepatic vein obstruction (Figure 5). By associating hepatic vein embolization, the aim is to eliminate any residual portal vein flow and reduce hepatic artery inflow which can further encourage liver regeneration. Initially described as a sequential approach in which hepatic vein embolization is secondarily performed in case of insufficient FLR growth after PVE, it was demonstrated that both procedures (portal and hepatic vein embolization) can be performed simultaneously[69,70]. This novel approach is particularly interesting as it allows important liver regeneration with good tolerance. Although no study comparing ALPPS to LVD is available, it has been suggested that LVD could overcome the limits of ALPPS, abolishing the necessity of two major surgical interventions in close sequence.

Firstly, PVE is performed as previously described. For hepatic vein embolization, a vascular plug is placed in the proximal part of the hepatic vein to avoid migration of embolization agent. The vein is then embolized with a mixture of ethiodized oil and N- butyl cyanoacrylate[71]. The term “extended LVD” is used for concomitant embolization of the right and middle hepatic vein with the right portal branch[57].

The results of this approach on FLR increase are superior to those observed after isolated PVE. In a recent large comparative study, Laurent *et al*[71] observed a FLR volume increase of 28.9% after PVE compared to 61.2% after LVD ($P < 0.0001$). In this study, LVD allowed surgery in 86.4% of patients and no PHLF was reported. Kobayashi *et al*[72] observed similar results with a superior FLR hypertrophy after LVD compared to PVE (35% *vs* 24%, $P = 0.034$). In addition, the tolerance of LVD seems to be similar to the tolerance of isolated PVE[71,72].

RADIATION LOBECTOMY

This recent approach is derived from trans-arterial radioembolization with yttrium-90 [73]. In radiation lobectomy (RL), radioembolization of both the tumor and the non-tumoral liver parenchyma that will be secondarily resected is performed, which

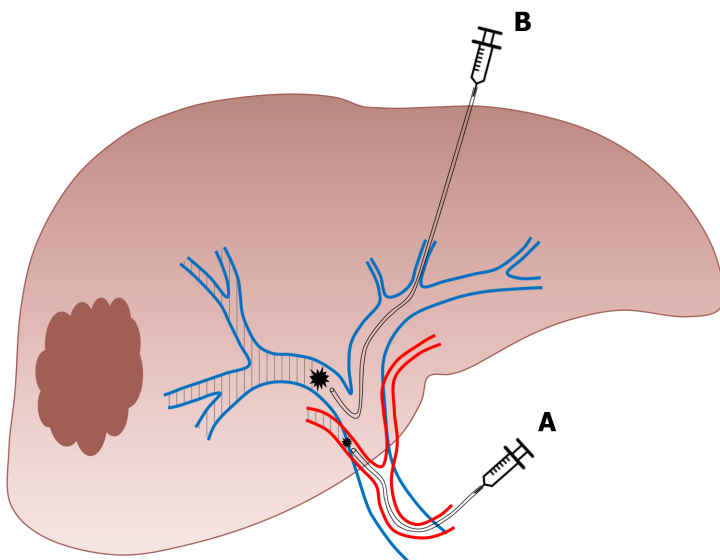


Figure 4 Sequential embolization. A: Trans-arterial embolization; B: Portal vein embolization of the right liver.

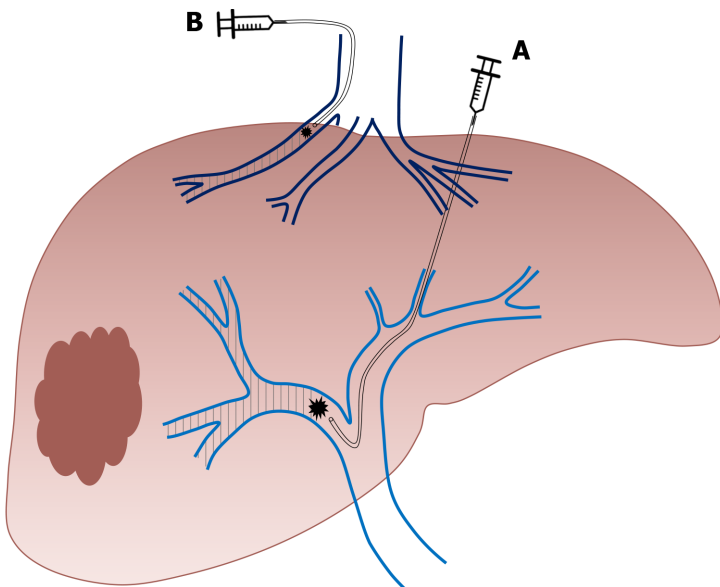


Figure 5 Right liver venous derivation associates in a sequential or concomitant approach. A: Right portal vein embolization; B: Ipsilateral hepatic vein embolization.

requires higher radiation doses[74,75]. This technique allows concomitant tumoral control and FLR increase. One major advantage of this approach is that it could be carried out in patients with portal vein thrombosis[75].

The procedure is well-tolerated[74] with transient moderate adverse events. Results in terms of FLR volume growth are very similar to those observed after PVE. Vouche *et al*[74] reported 45% of FLR hypertrophy and observed a correlation between the presence of a portal vein thrombosis and FLR growth. However, series reporting major liver resection after RL are scarce[76,77]. Andel *et al*[77] recently reported 10 major hepatectomies in patients that were initially treated with RL for insufficient functional FLR. The RL allowed a 41% increase in FLR volume with 84% of FLR function increase (evaluated on scintigraphy). All resections were performed without major intraoperative problems. Only one patient developed a serious complication not directly related to the liver surgery and other complications were mild.

Table 1 Indication, advantages, and disadvantages of existing approaches to induce liver remnant hypertrophy before major liver resection

Approach	Indication	Advantage	Disadvantage
PVE	Insufficient FLR volume	Percutaneous approach	Contraindicated in patients with extensive portal thrombus and important portal hypertension; Could promote tumoral growth within the embolized liver
PVL and two-stage hepatectomy	Insufficient FLR volume and treatment of bilobar liver disease	PVL is performed during the first surgical step (tumoral clearance of the FLR)	Surgical procedure; Morbidity
Associating liver partition and PVL for staged hepatectomy	Insufficient FLR volume +/- treatment of bilobar liver disease	Liver surgery is performed in a short period of time (15 d); First surgical step (PVL and <i>in situ</i> splitting of the liver parenchyma) can be associated with tumoral clearance of the FLR	Surgical procedure; Morbidity
Sequential trans arterial embolization and PVE	Insufficient FLR volume in patients with hepatocellular carcinoma	Percutaneous approachMay help to counteract the stimulating effect of PVE on tumor growth	Sequential approach (two procedures) is recommended to limit the risk of nontumoral liver ischemic necrosis; Contraindicated in patients with extensive portal thrombus, important portal hypertension or previous biliary surgery (biliodigestive anastomosis)
Liver venous deprivation	Insufficient FLR volume	Percutaneous approach	Contraindicated in patients with extensive portal thrombus and important portal hypertension; Could promote tumoral growth within the embolized liver
RL	Insufficient FLR volume	Percutaneous approachConcomitant tumoral control and FLR increaseCan be carried out in patients with portal vein thrombosis	Data reporting liver resection after RL is scarce

PVE: Portal vein embolization; FLR: Future liver remnant; PVL: Portal vein ligation; RL: Radiation lobectomy.

CONCLUSION

Careful initial evaluation of FLR volume and function is crucial before planning major liver resection. When required, several approaches are now available to decrease the risk of PHLF (Table 1) and thus postoperative mortality. Although PVE remains the gold standard, recent techniques that are derived from PVE might play an increasingly important role in future years.

REFERENCES

- Schreckenbach T, Liese J, Bechstein WO, Moench C. Posthepatectomy liver failure. *Dig Surg* 2012; **29**: 79-85 [PMID: 22441624 DOI: 10.1159/000335741]
- Black DM, Behrns KE. A scientist revisits the atrophy-hypertrophy complex: hepatic apoptosis and regeneration. *Surg Oncol Clin N Am* 2002; **11**: 849-864 [PMID: 12607575 DOI: 10.1016/s1055-3207(02)00031-5]
- Kim RD, Kim JS, Watanabe G, Mohuczy D, Behrns KE. Liver regeneration and the atrophy-hypertrophy complex. *Semin Intervent Radiol* 2008; **25**: 92-103 [PMID: 21326550 DOI: 10.1055/s-2008-1076679]
- Fajardo-Puerta AB, Mato Prado M, Frampton AE, Jiao LR. Gene of the month: HGF. *J Clin Pathol* 2016; **69**: 575-579 [PMID: 27072686 DOI: 10.1136/jclinpath-2015-203575]
- Pack GT, Islami AH, Hubbard JC, Brasfield RD. Regeneration of human liver after major hepatectomy. *Surgery* 1962; **52**: 617-623 [PMID: 14483060]
- Honjo I, Suzuki T, Ozawa K, Takasan H, Kitamura O. Ligation of a branch of the portal vein for carcinoma of the liver. *Am J Surg* 1975; **130**: 296-302 [PMID: 170837 DOI: 10.1016/0002-9610(75)90389-x]
- Kinoshita H, Sakai K, Hirohashi K, Igawa S, Yamasaki O, Kubo S. Preoperative portal vein embolization for hepatocellular carcinoma. *World J Surg* 1986; **10**: 803-808 [PMID: 3022488 DOI: 10.1007/BF01655244]
- Makuuchi M, Thai BL, Takayasu K, Takayama T, Kosuge T, Gunvén P, Yamazaki S, Hasegawa H, Ozaki H. Preoperative portal embolization to increase safety of major hepatectomy for hilar bile duct carcinoma: a preliminary report. *Surgery* 1990; **107**: 521-527 [PMID: 2333592]
- Palmes D, Spiegel HU. Animal models of liver regeneration. *Biomaterials* 2004; **25**: 1601-1611 [PMID: 14697862 DOI: 10.1016/s0142-9612(03)00508-8]
- Taub R. Liver regeneration: from myth to mechanism. *Nat Rev Mol Cell Biol* 2004; **5**: 836-847 [PMID: 15459664 DOI: 10.1038/nrm1489]
- Markiewski MM, DeAngelis RA, Lambris JD. Liver inflammation and regeneration: two distinct

- biological phenomena or parallel pathophysiologic processes? *Mol Immunol* 2006; **43**: 45-56 [PMID: 16002143 DOI: 10.1016/j.molimm.2005.06.019]
- 12 **Rabes HM**. Kinetics of hepatocellular proliferation as a function of the microvascular structure and functional state of the liver. *Ciba Found Symp* 1977; 31-53 [PMID: 248005 DOI: 10.1002/9780470720363.ch3]
 - 13 **Michalopoulos GK**. Liver regeneration. *J Cell Physiol* 2007; **213**: 286-300 [PMID: 17559071 DOI: 10.1002/jcp.21172]
 - 14 **Rahbari NN**, Garden OJ, Padbury R, Brooke-Smith M, Crawford M, Adam R, Koch M, Makuuchi M, Dematteo RP, Christophi C, Banting S, Usatoff V, Nagino M, Maddern G, Hugh TJ, Vauthey JN, Greig P, Rees M, Yokoyama Y, Fan ST, Nimura Y, Figueras J, Capussotti L, Büchler MW, Weitz J. Posthepatectomy liver failure: a definition and grading by the International Study Group of Liver Surgery (ISGLS). *Surgery* 2011; **149**: 713-724 [PMID: 21236455 DOI: 10.1016/j.surg.2010.10.001]
 - 15 **Dahm F**, Georgiev P, Clavien PA. Small-for-size syndrome after partial liver transplantation: definition, mechanisms of disease and clinical implications. *Am J Transplant* 2005; **5**: 2605-2610 [PMID: 16212618 DOI: 10.1111/j.1600-6143.2005.01081.x]
 - 16 **Tucker ON**, Heaton N. The 'small for size' liver syndrome. *Curr Opin Crit Care* 2005; **11**: 150-155 [PMID: 15758596 DOI: 10.1097/01.ccx.0000157080.11117.45]
 - 17 **Riddiough GE**, Christophi C, Jones RM, Muralidharan V, Perini MV. A systematic review of small for size syndrome after major hepatectomy and liver transplantation. *HPB (Oxford)* 2020; **22**: 487-496 [PMID: 31786053 DOI: 10.1016/j.hpb.2019.10.2445]
 - 18 **Rajakannu M**, Cherqui D, Ciacio O, Golse N, Pittau G, Allard MA, Antonini TM, Coilly A, Sa Cunha A, Castaing D, Samuel D, Guettier C, Adam R, Vibert E. Liver stiffness measurement by transient elastography predicts late posthepatectomy outcomes in patients undergoing resection for hepatocellular carcinoma. *Surgery* 2017; **162**: 766-774 [PMID: 28711320 DOI: 10.1016/j.surg.2017.06.006]
 - 19 **Adams RB**, Aloia TA, Loyer E, Pawlik TM, Taouli B, Vauthey JN; Americas Hepato-Pancreato-Biliary Association; Society of Surgical Oncology; Society for Surgery of the Alimentary Tract. Selection for hepatic resection of colorectal liver metastases: expert consensus statement. *HPB (Oxford)* 2013; **15**: 91-103 [PMID: 23297719 DOI: 10.1111/j.1477-2574.2012.00557.x]
 - 20 **Shindoh J**, Truty MJ, Aloia TA, Curley SA, Zimmiti G, Huang SY, Mahvash A, Gupta S, Wallace MJ, Vauthey JN. Kinetic growth rate after portal vein embolization predicts posthepatectomy outcomes: toward zero liver-related mortality in patients with colorectal liver metastases and small future liver remnant. *J Am Coll Surg* 2013; **216**: 201-209 [PMID: 23219349 DOI: 10.1016/j.jamcollsurg.2012.10.018]
 - 21 **Vauthey JN**, Abdalla EK, Doherty DA, Gertsch P, Fenstermacher MJ, Loyer EM, Lerut J, Matern R, Wang X, Encarnacion A, Herron D, Mathey C, Ferrari G, Charnsangavej C, Do KA, Denys A. Body surface area and body weight predict total liver volume in Western adults. *Liver Transpl* 2002; **8**: 233-240 [PMID: 11910568 DOI: 10.1053/jlts.2002.31654]
 - 22 **Child CG**, Turcotte JG. Surgery and portal hypertension. *Major Probl Clin Surg* 1964; **1**: 1-85 [PMID: 4950264]
 - 23 **Kong FH**, Miao XY, Zou H, Xiong L, Wen Y, Chen B, Liu X, Zhou JJ. End-stage liver disease score and future liver remnant volume predict post-hepatectomy liver failure in hepatocellular carcinoma. *World J Clin Cases* 2019; **7**: 3734-3741 [PMID: 31799298 DOI: 10.12998/wjcc.v7.i22.3734]
 - 24 **Gudowska M**, Gruszevska E, Panasiuk A, Cylwik B, Flisiak R, Świdarska M, Szmikowski M, Chrostek L. Hyaluronic acid concentration in liver diseases. *Clin Exp Med* 2016; **16**: 523-528 [PMID: 26354758 DOI: 10.1007/s10238-015-0388-8]
 - 25 **Imamura H**, Sano K, Sugawara Y, Kokudo N, Makuuchi M. Assessment of hepatic reserve for indication of hepatic resection: decision tree incorporating indocyanine green test. *J Hepatobiliary Pancreat Surg* 2005; **12**: 16-22 [PMID: 15754094 DOI: 10.1007/s00534-004-0965-9]
 - 26 **Weinmann HJ**, Schuhmann-Giampieri G, Schmitt-Willich H, Vogler H, Frenzel T, Gries H. A new lipophilic gadolinium chelate as a tissue-specific contrast medium for MRI. *Magn Reson Med* 1991; **22**: 233-7; discussion 242 [PMID: 1812351 DOI: 10.1002/mrm.1910220214]
 - 27 **de Graaf W**, van Lienden KP, Dinant S, Roelofs JJ, Busch OR, Gouma DJ, Bennink RJ, van Gulik TM. Assessment of future remnant liver function using hepatobiliary scintigraphy in patients undergoing major liver resection. *J Gastrointest Surg* 2010; **14**: 369-378 [PMID: 19937195 DOI: 10.1007/s11605-009-1085-2]
 - 28 **Erdogan D**, Heijnen BH, Bennink RJ, Kok M, Dinant S, Straatsburg IH, Gouma DJ, van Gulik TM. Preoperative assessment of liver function: a comparison of 99mTc-Mebrofenin scintigraphy with indocyanine green clearance test. *Liver Int* 2004; **24**: 117-123 [PMID: 15078475 DOI: 10.1111/j.1478-3231.2004.00901.x]
 - 29 **Cieslak KP**, Runge JH, Heger M, Stoker J, Bennink RJ, van Gulik TM. New perspectives in the assessment of future remnant liver. *Dig Surg* 2014; **31**: 255-268 [PMID: 25322678 DOI: 10.1159/000364836]
 - 30 **Stockmann M**, Lock JF, Riecke B, Heyne K, Martus P, Fricke M, Lehmann S, Niehues SM, Schwabe M, Lemke AJ, Neuhaus P. Prediction of postoperative outcome after hepatectomy with a new bedside test for maximal liver function capacity. *Ann Surg* 2009; **250**: 119-125 [PMID: 19561474 DOI: 10.1097/SLA.0b013e3181ad85b5]
 - 31 **Shinkawa H**, Takemura S, Tanaka S, Kubo S. Portal Vein Embolization: History and Current Indications. *Visc Med* 2017; **33**: 414-417 [PMID: 29344514 DOI: 10.1159/000479474]

- 32 **Li D**, Madoff DC. Portal vein embolization for induction of selective hepatic hypertrophy prior to major hepatectomy: rationale, techniques, outcomes and future directions. *Cancer Biol Med* 2016; **13**: 426-442 [PMID: [28154774](#) DOI: [10.20892/j.issn.2095-3941.2016.0083](#)]
- 33 **Madoff DC**, Abdalla EK, Vauthey JN. Portal vein embolization in preparation for major hepatic resection: evolution of a new standard of care. *J Vasc Interv Radiol* 2005; **16**: 779-790 [PMID: [15947041](#) DOI: [10.1097/01.RVI.0000159543.28222.73](#)]
- 34 **Lainas P**, Boudechiche L, Osorio A, Coulomb A, Weber A, Pariente D, Franco D, Dagher I. Liver regeneration and recanalization time course following reversible portal vein embolization. *J Hepatol* 2008; **49**: 354-362 [PMID: [18387688](#) DOI: [10.1016/j.jhep.2008.01.034](#)]
- 35 **Tranchart H**, Catherine L, Maitre S, Lainas P, De Laveaucoupet J, Dagher I. Efficient liver regeneration following temporary portal vein embolization with absorbable gelatin sponge powder in humans. *J Vasc Interv Radiol* 2015; **26**: 507-515 [PMID: [25640643](#) DOI: [10.1016/j.jvir.2014.11.033](#)]
- 36 **Tranchart H**, Koffi GM, Gaillard M, Lainas P, Poüs C, Gonin P, Nguyen TH, Dubart-Kupperschmitt A, Dagher I. Liver regeneration following repeated reversible portal vein embolization in an experimental model. *Br J Surg* 2016; **103**: 1209-1219 [PMID: [27256140](#) DOI: [10.1002/bjs.10153](#)]
- 37 **van Lienden KP**, van den Esschert JW, de Graaf W, Bipat S, Lameris JS, van Gulik TM, van Delden OM. Portal vein embolization before liver resection: a systematic review. *Cardiovasc Intervent Radiol* 2013; **36**: 25-34 [PMID: [22806245](#) DOI: [10.1007/s00270-012-0440-y](#)]
- 38 **Abulkhir A**, Limongelli P, Healey AJ, Damrah O, Tait P, Jackson J, Habib N, Jiao LR. Preoperative portal vein embolization for major liver resection: a meta-analysis. *Ann Surg* 2008; **247**: 49-57 [PMID: [18156923](#) DOI: [10.1097/SLA.0b013e31815f6e5b](#)]
- 39 **Isfordink CJ**, Samim M, Braat MNGJA, Almalki AM, Hagendoorn J, Borel Rinkes IHM, Molenaar IQ. Portal vein ligation vs portal vein embolization for induction of hypertrophy of the future liver remnant: A systematic review and meta-analysis. *Surg Oncol* 2017; **26**: 257-267 [PMID: [28807245](#) DOI: [10.1016/j.suronc.2017.05.001](#)]
- 40 **Wajswol E**, Jazmati T, Contractor S, Kumar A. Portal Vein Embolization Utilizing N-Butyl Cyanoacrylate for Contralateral Lobe Hypertrophy Prior to Liver Resection: A Systematic Review and Meta-Analysis. *Cardiovasc Intervent Radiol* 2018; **41**: 1302-1312 [PMID: [29687262](#) DOI: [10.1007/s00270-018-1964-6](#)]
- 41 **May BJ**, Madoff DC. Portal vein embolization: rationale, technique, and current application. *Semin Intervent Radiol* 2012; **29**: 81-89 [PMID: [23729977](#) DOI: [10.1055/s-0032-1312568](#)]
- 42 **Hoekstra LT**, van Lienden KP, Doets A, Busch OR, Gouma DJ, van Gulik TM. Tumor progression after preoperative portal vein embolization. *Ann Surg* 2012; **256**: 812-7; discussion 817 [PMID: [23095626](#) DOI: [10.1097/SLA.0b013e3182733f09](#)]
- 43 **Hoekstra LT**, van Lienden KP, Verheij J, van der Loos CM, Heger M, van Gulik TM. Enhanced tumor growth after portal vein embolization in a rabbit tumor model. *J Surg Res* 2013; **180**: 89-96 [PMID: [23149224](#) DOI: [10.1016/j.jss.2012.10.032](#)]
- 44 **Maggiori L**, Bretagnol F, Sibert A, Paradis V, Vilgrain V, Panis Y. Selective portal vein ligation and embolization induce different tumoral responses in the rat liver. *Surgery* 2011; **149**: 496-503 [PMID: [21167542](#) DOI: [10.1016/j.surg.2010.10.012](#)]
- 45 **Pamecha V**, Levene A, Grillo F, Woodward N, Dhillon A, Davidson BR. Effect of portal vein embolisation on the growth rate of colorectal liver metastases. *Br J Cancer* 2009; **100**: 617-622 [PMID: [19209170](#) DOI: [10.1038/sj.bjc.6604872](#)]
- 46 **Adam R**, Laurent A, Azoulay D, Castaing D, Bismuth H. Two-stage hepatectomy: A planned strategy to treat irresectable liver tumors. *Ann Surg* 2000; **232**: 777-785 [PMID: [11088072](#) DOI: [10.1097/0000658-200012000-00006](#)]
- 47 **Kianmanesh R**, Farges O, Abdalla EK, Sauvanet A, Ruszniewski P, Belghiti J. Right portal vein ligation: a new planned two-step all-surgical approach for complete resection of primary gastrointestinal tumors with multiple bilateral liver metastases. *J Am Coll Surg* 2003; **197**: 164-170 [PMID: [12831938](#) DOI: [10.1016/S1072-7515\(03\)00334-X](#)]
- 48 **Jaeck D**, Oussoultzoglou E, Rosso E, Greget M, Weber JC, Bachellier P. A two-stage hepatectomy procedure combined with portal vein embolization to achieve curative resection for initially unresectable multiple and bilobar colorectal liver metastases. *Ann Surg* 2004; **240**: 1037-49; discussion 1049 [PMID: [15570209](#) DOI: [10.1097/01.sla.0000145965.86383.89](#)]
- 49 **Broering DC**, Hillert C, Krupski G, Fischer L, Mueller L, Achilles EG, Schulte am Esch J, Rogiers X. Portal vein embolization vs portal vein ligation for induction of hypertrophy of the future liver remnant. *J Gastrointest Surg* 2002; **6**: 905-13; discussion 913 [PMID: [12504230](#) DOI: [10.1016/s1091-255x\(02\)00122-1](#)]
- 50 **Aussilhou B**, Lesurtel M, Sauvanet A, Farges O, Dokmak S, Goasguen N, Sibert A, Vilgrain V, Belghiti J. Right portal vein ligation is as efficient as portal vein embolization to induce hypertrophy of the left liver remnant. *J Gastrointest Surg* 2008; **12**: 297-303 [PMID: [18060468](#) DOI: [10.1007/s11605-007-0410-x](#)]
- 51 **Capussotti L**, Muratore A, Baracchi F, Lelong B, Ferrero A, Regge D, Delperio JR. Portal vein ligation as an efficient method of increasing the future liver remnant volume in the surgical treatment of colorectal metastases. *Arch Surg* 2008; **143**: 978-82; discussion 982 [PMID: [18936377](#) DOI: [10.1001/archsurg.143.10.978](#)]
- 52 **Schnitzbauer AA**, Lang SA, Goessmann H, Nadalin S, Baumgart J, Farkas SA, Fichtner-Feigl S, Lorf T, Goralcyk A, Hörbelt R, Kroemer A, Loss M, Rümmele P, Scherer MN, Padberg W, Königsrainer A, Lang H, Obed A, Schlitt HJ. Right portal vein ligation combined with in situ splitting

- induces rapid left lateral liver lobe hypertrophy enabling 2-staged extended right hepatic resection in small-for-size settings. *Ann Surg* 2012; **255**: 405-414 [PMID: [22330038](#) DOI: [10.1097/SLA.0b013e31824856f5](#)]
- 53 **Sandström P**, Røskok BI, Sparrelid E, Larsen PN, Larsson AL, Lindell G, Schultz NA, Bjørneth BA, Isaksson B, Rizell M, Björnsson B. ALPPS Improves Resectability Compared With Conventional Two-stage Hepatectomy in Patients With Advanced Colorectal Liver Metastasis: Results From a Scandinavian Multicenter Randomized Controlled Trial (LIGRO Trial). *Ann Surg* 2018; **267**: 833-840 [PMID: [28902669](#) DOI: [10.1097/SLA.0000000000002511](#)]
 - 54 **Schadde E**, Ardiles V, Robles-Campos R, Malago M, Machado M, Hernandez-Alejandro R, Soubrane O, Schnitzbauer AA, Raptis D, Tschuor C, Petrowsky H, De Santibanes E, Clavien PA; ALPPS Registry Group. Early survival and safety of ALPPS: first report of the International ALPPS Registry. *Ann Surg* 2014; **260**: 829-36; discussion 836 [PMID: [25379854](#) DOI: [10.1097/SLA.0000000000000947](#)]
 - 55 **Knoefel WT**, Gabor I, Rehders A, Alexander A, Krausch M, Schulte am Esch J, Fürst G, Topp SA. In situ liver transection with portal vein ligation for rapid growth of the future liver remnant in two-stage liver resection. *Br J Surg* 2013; **100**: 388-394 [PMID: [23124776](#) DOI: [10.1002/bjs.8955](#)]
 - 56 **Schadde E**, Schnitzbauer AA, Tschuor C, Raptis DA, Bechstein WO, Clavien PA. Systematic review and meta-analysis of feasibility, safety, and efficacy of a novel procedure: associating liver partition and portal vein ligation for staged hepatectomy. *Ann Surg Oncol* 2015; **22**: 3109-3120 [PMID: [25448799](#) DOI: [10.1245/s10434-014-4213-5](#)]
 - 57 **Deshayes E**, Schadde E, Piron L, Quenet F, Guiu B. Extended Liver Venous Deprivation Leads to a Higher Increase in Liver Function than ALPPS in Early Assessment: A comment to "Sparrelid E *et al*". Dynamic Evaluation of Liver Volume and Function in Associating Liver Partition and Portal Vein Ligation for Staged Hepatectomy. *J Gastrointest Surg* 2017; **21**: 1754-1755 [PMID: [28785933](#) DOI: [10.1007/s11605-017-3508-9](#)]
 - 58 **Sparrelid E**, Jonas E, Tzortzakakis A, Dahlén U, Murquist G, Brismar T, Axelsson R, Isaksson B. Dynamic Evaluation of Liver Volume and Function in Associating Liver Partition and Portal Vein Ligation for Staged Hepatectomy. *J Gastrointest Surg* 2017; **21**: 967-974 [PMID: [28283924](#) DOI: [10.1007/s11605-017-3389-y](#)]
 - 59 **Adam R**, Imai K, Castro Benitez C, Allard MA, Vibert E, Sa Cunha A, Cherqui D, Baba H, Castaing D. Outcome after associating liver partition and portal vein ligation for staged hepatectomy and conventional two-stage hepatectomy for colorectal liver metastases. *Br J Surg* 2016; **103**: 1521-1529 [PMID: [27517369](#) DOI: [10.1002/bjs.10256](#)]
 - 60 **Moris D**, Ronnekleiv-Kelly S, Kostakis ID, Tsilimigras DI, Beal EW, Papalampros A, Dimitroulis D, Felekouras E, Pawlik TM. Operative Results and Oncologic Outcomes of Associating Liver Partition and Portal Vein Ligation for Staged Hepatectomy (ALPPS) Versus Two-Stage Hepatectomy (TSH) in Patients with Unresectable Colorectal Liver Metastases: A Systematic Review and Meta-Analysis. *World J Surg* 2018; **42**: 806-815 [PMID: [28798996](#) DOI: [10.1007/s00268-017-4181-6](#)]
 - 61 **Hasselgren K**, Røskok BI, Larsen PN, Sparrelid E, Lindell G, Schultz NA, Bjørneth BA, Isaksson B, Larsson AL, Rizell M, Björnsson B, Sandström P. ALPPS Improves Survival Compared With TSH in Patients Affected of CRLM: Survival Analysis From the Randomized Controlled Trial LIGRO. *Ann Surg* 2021; **273**: 442-448 [PMID: [32049675](#) DOI: [10.1097/SLA.0000000000003701](#)]
 - 62 **Huang HC**, Bian J, Bai Y, Lu X, Xu YY, Sang XT, Zhao HT. Complete or partial split in associating liver partition and portal vein ligation for staged hepatectomy: A systematic review and meta-analysis. *World J Gastroenterol* 2019; **25**: 6016-6024 [PMID: [31660037](#) DOI: [10.3748/wjg.v25.i39.6016](#)]
 - 63 **Kim D**, Cormman-Homonoff J, Madoff DC. Preparing for liver surgery with "Alphabet Soup": PVE, ALPPS, TAE-PVE, LVD and RL. *Hepatobiliary Surg Nutr* 2020; **9**: 136-151 [PMID: [32355673](#) DOI: [10.21037/hbsn.2019.09.10](#)]
 - 64 **Peng PD**, Hyder O, Bloomston M, Marques H, Corona-Villalobos C, Dixon E, Pulitano C, Hirose K, Schulick RD, Barroso E, Aldrighetti L, Choti M, Shen F, Kamel I, Geschwind JF, Pawlik TM. Sequential intra-arterial therapy and portal vein embolization is feasible and safe in patients with advanced hepatic malignancies. *HPB (Oxford)* 2012; **14**: 523-531 [PMID: [22762400](#) DOI: [10.1111/j.1477-2574.2012.00492.x](#)]
 - 65 **Raoul JL**, Forner A, Bolondi L, Cheung TT, Kloeckner R, de Baere T. Updated use of TACE for hepatocellular carcinoma treatment: How and when to use it based on clinical evidence. *Cancer Treat Rev* 2019; **72**: 28-36 [PMID: [30447470](#) DOI: [10.1016/j.ctrv.2018.11.002](#)]
 - 66 **Ogata S**, Belghiti J, Farges O, Varma D, Sibert A, Vilgrain V. Sequential arterial and portal vein embolizations before right hepatectomy in patients with cirrhosis and hepatocellular carcinoma. *Br J Surg* 2006; **93**: 1091-1098 [PMID: [16779884](#) DOI: [10.1002/bjs.5341](#)]
 - 67 **Aoki T**, Imamura H, Hasegawa K, Matsukura A, Sano K, Sugawara Y, Kokudo N, Makuuchi M. Sequential preoperative arterial and portal venous embolizations in patients with hepatocellular carcinoma. *Arch Surg* 2004; **139**: 766-774 [PMID: [15249411](#) DOI: [10.1001/archsurg.139.7.766](#)]
 - 68 **Yoo H**, Kim JH, Ko GY, Kim KW, Gwon DI, Lee SG, Hwang S. Sequential transcatheter arterial chemoembolization and portal vein embolization vs portal vein embolization only before major hepatectomy for patients with hepatocellular carcinoma. *Ann Surg Oncol* 2011; **18**: 1251-1257 [PMID: [21069467](#) DOI: [10.1245/s10434-010-1423-3](#)]
 - 69 **Hwang S**, Lee SG, Ko GY, Kim BS, Sung KB, Kim MH, Lee SK, Hong HN. Sequential preoperative ipsilateral hepatic vein embolization after portal vein embolization to induce further liver regeneration in patients with hepatobiliary malignancy. *Ann Surg* 2009; **249**: 608-616 [PMID: [19300228](#) DOI: [10.1007/s10434-009-0022-8](#)]

- 10.1097/SLA.0b013e31819ecc5c]
- 70 **Le Roy B**, Perrey A, Fontarensky M, Gagnière J, Abergel A, Pereira B, Lambert C, Boyer L, Pezet D, Chabrot P, Buc E. Combined Preoperative Portal and Hepatic Vein Embolization (Biembolization) to Improve Liver Regeneration Before Major Liver Resection: A Preliminary Report. *World J Surg* 2017; **41**: 1848-1856 [PMID: 28417185 DOI: 10.1007/s00268-017-4016-5]
 - 71 **Laurent C**, Fernandez B, Marichez A, Adam JP, Papadopoulos P, Lapuyade B, Chiche L. Radiological Simultaneous Portohepatic Vein Embolization (RASPE) Before Major Hepatectomy: A Better Way to Optimize Liver Hypertrophy Compared to Portal Vein Embolization. *Ann Surg* 2020; **272**: 199-205 [PMID: 32675481 DOI: 10.1097/SLA.0000000000003905]
 - 72 **Kobayashi K**, Yamaguchi T, Denys A, Perron L, Halkic N, Demartines N, Melloul E. Liver venous deprivation compared to portal vein embolization to induce hypertrophy of the future liver remnant before major hepatectomy: A single center experience. *Surgery* 2020; **167**: 917-923 [PMID: 32014304 DOI: 10.1016/j.surg.2019.12.006]
 - 73 **Vilgrain V**, Pereira H, Assenat E, Guiu B, Ilonca AD, Pageaux GP, Sibert A, Bouattour M, Lebtahi R, Allaham W, Barraud H, Laurent V, Mathias E, Bronowicki JP, Tasu JP, Perdrisot R, Silvain C, Gerolami R, Mundler O, Seitz JF, Vidal V, Aubé C, Oberti F, Couturier O, Brenot-Rossi I, Raoul JL, Sarra A, Costentin C, Itti E, Luciani A, Adam R, Lewin M, Samuel D, Ronot M, Dinut A, Castera L, Chatellier G; SARAH Trial Group. Efficacy and safety of selective internal radiotherapy with yttrium-90 resin microspheres compared with sorafenib in locally advanced and inoperable hepatocellular carcinoma (SARAH): an open-label randomised controlled phase 3 trial. *Lancet Oncol* 2017; **18**: 1624-1636 [PMID: 29107679 DOI: 10.1016/S1470-2045(17)30683-6]
 - 74 **Vouche M**, Lewandowski RJ, Atassi R, Memon K, Gates VL, Ryu RK, Gaba RC, Mulcahy MF, Baker T, Sato K, Hickey R, Ganger D, Riaz A, Fryer J, Caicedo JC, Abecassis M, Kulik L, Salem R. Radiation lobectomy: time-dependent analysis of future liver remnant volume in unresectable liver cancer as a bridge to resection. *J Hepatol* 2013; **59**: 1029-1036 [PMID: 23811303 DOI: 10.1016/j.jhep.2013.06.015]
 - 75 **Malhotra A**, Liu DM, Talenfeld AD. Radiation Segmentectomy and Radiation Lobectomy: A Practical Review of Techniques. *Tech Vasc Interv Radiol* 2019; **22**: 49-57 [PMID: 31079710 DOI: 10.1053/j.tvir.2019.02.003]
 - 76 **Lewandowski RJ**, Donahue L, Chokechanachaisakul A, Kulik L, Mouli S, Caicedo J, Abecassis M, Fryer J, Salem R, Baker T. (90) Y radiation lobectomy: Outcomes following surgical resection in patients with hepatic tumors and small future liver remnant volumes. *J Surg Oncol* 2016; **114**: 99-105 [PMID: 27103352 DOI: 10.1002/jso.24269]
 - 77 **Andel D**, Dassen MG, Reinders-Hut MTM, Peters NA, Kranenburg OW, Lam MGEH, Hagendoorn J, Rinkes IHMB. Surgical outcomes of major hepatectomy following "radiation lobectomy" for hepatic malignancies and insufficiently functional future liver remnant: initial experience. *Br J Surg* 2020; **107**: e609-e610 [PMID: 32936446 DOI: 10.1002/bjs.11828]



Published by **Baishideng Publishing Group Inc**
7041 Koll Center Parkway, Suite 160, Pleasanton, CA 94566, USA

Telephone: +1-925-3991568

E-mail: bpgoffice@wjgnet.com

Help Desk: <https://www.f6publishing.com/helpdesk>

<https://www.wjgnet.com>

