

World Journal of *Hepatology*

World J Hepatol 2021 November 27; 13(11): 1459-1815



FRONTIER

- 1459 Role of endoscopic ultrasound in the field of hepatology: Recent advances and future trends
Dhar J, Samanta J

OPINION REVIEW

- 1484 Porta-caval fibrous connections — the lesser-known structure of intrahepatic connective-tissue framework: A unified view of liver extracellular matrix
Patarashvili L, Gvidiani S, Azmaipharashvili E, Tsomaia K, Sareli M, Kordzaia D, Chanukvadze I

REVIEW

- 1494 Promising diagnostic biomarkers of nonalcoholic fatty liver disease and nonalcoholic steatohepatitis: From clinical proteomics to microbiome
Castillo-Castro C, Martagón-Rosado AJ, Ortiz-Lopez R, Garrido-Treviño LF, Villegas-Albo M, Bosques-Padilla FJ
- 1512 Fatty acid metabolism and acyl-CoA synthetases in the liver-gut axis
Ma Y, Nenkov M, Chen Y, Press AT, Kaemmerer E, Gassler N
- 1534 Liver involvement in inflammatory bowel disease: What should the clinician know?
Losurdo G, Brescia IV, Lillo C, Mezzapesa M, Barone M, Principi M, Ierardi E, Di Leo A, Rendina M
- 1552 Chelation therapy in liver diseases of childhood: Current status and response
Seetharaman J, Sarma MS
- 1568 Hepatocellular carcinoma: Understanding molecular mechanisms for defining potential clinical modalities
Natu A, Singh A, Gupta S
- 1584 Heterogeneity of non-alcoholic fatty liver disease: Implications for clinical practice and research activity
Pal P, Palui R, Ray S
- 1611 Newly discovered endocrine functions of the liver
Rhyu J, Yu R

MINIREVIEWS

- 1629 Current strategies to induce liver remnant hypertrophy before major liver resection
Del Basso C, Gaillard M, Lainas P, Zervaki S, Perlemuter G, Chagué P, Rocher L, Voican CS, Dagher I, Tranchart H
- 1642 Health-related quality of life in autoimmune hepatitis
Snijders RJ, Milkiewicz P, Schramm C, Gevers TJ

- 1653** Fungal infections following liver transplantation
Khalid M, Neupane R, Anjum H, Surani S
- 1663** Elastography as a predictor of liver cirrhosis complications after hepatitis C virus eradication in the era of direct-acting antivirals
Cerrito L, Ainora ME, Nicoletti A, Garcovich M, Riccardi L, Pompili M, Gasbarrini A, Zocco MA
- 1677** Role of immune dysfunction in drug induced liver injury
Girish C, Sanjay S
- 1688** Abnormal liver enzymes: A review for clinicians
Kalas MA, Chavez L, Leon M, Taweessdt PT, Surani S
- 1699** Hepatopulmonary syndrome: An update
Gandhi KD, Taweessdt PT, Sharma M, Surani S
- 1707** Mitochondrial hepatopathy: Respiratory chain disorders- 'breathing in and out of the liver'
Gopan A, Sarma MS
- 1727** Cystic fibrosis associated liver disease in children
Valamparampil JJ, Gupte GL

ORIGINAL ARTICLE**Case Control Study**

- 1743** Tumor characteristics of hepatocellular carcinoma after direct-acting antiviral treatment for hepatitis C: Comparative analysis with antiviral therapy-naïve patients
Fouad M, El Kassas M, Ahmed E, El Sheemy R
- 1753** Circulating microRNA 9-3p and serum endocan as potential biomarkers for hepatitis C virus-related hepatocellular carcinoma
Wahb AMSE, El Kassas M, Khamis AK, Elhelbawy M, Elhelbawy N, Habieb MSE

Retrospective Cohort Study

- 1766** Do peripartum and postmenopausal women with primary liver cancer have a worse prognosis? A nationwide cohort in Taiwan
Tseng GW, Lin MC, Lai SW, Peng CY, Chuang PH, Su WP, Kao JT, Lai HC
- 1777** Nonalcoholic fatty liver disease is associated with worse intestinal complications in patients hospitalized for *Clostridioides difficile* infection
Jiang Y, Chowdhury S, Xu BH, Meybodi MA, Damiris K, Devalaraju S, Pyrsopoulos N

Observational Study

- 1791** Six-minute walking test performance is associated with survival in cirrhotic patients
Pimentel CFMG, Amaral ACC, Gonzalez AM, Lai M, Mota DO, Ferraz MLG, Junior WM, Kondo M

SYSTEMATIC REVIEWS

- 1802** Incidence of umbilical vein catheter-associated thrombosis of the portal system: A systematic review and meta-analysis

Bersani I, Piersigilli F, Iacona G, Savarese I, Campi F, Dotta A, Auriti C, Di Stasio E, Garcovich M

ABOUT COVER

Editorial Board Member of *World Journal of Hepatology*, Igor Skrypnyk, MD, MDS, PhD, Professor, Internal Medicine #1, Poltava State Medical University, Poltava 36011, Ukraine. inskrypnyk@gmail.com

AIMS AND SCOPE

The primary aim of *World Journal of Hepatology* (*WJH*, *World J Hepatol*) is to provide scholars and readers from various fields of hepatology with a platform to publish high-quality basic and clinical research articles and communicate their research findings online.

WJH mainly publishes articles reporting research results and findings obtained in the field of hepatology and covering a wide range of topics including chronic cholestatic liver diseases, cirrhosis and its complications, clinical alcoholic liver disease, drug induced liver disease autoimmune, fatty liver disease, genetic and pediatric liver diseases, hepatocellular carcinoma, hepatic stellate cells and fibrosis, liver immunology, liver regeneration, hepatic surgery, liver transplantation, biliary tract pathophysiology, non-invasive markers of liver fibrosis, viral hepatitis.

INDEXING/ABSTRACTING

The *WJH* is now abstracted and indexed in PubMed, PubMed Central, Emerging Sources Citation Index (Web of Science), Scopus, China National Knowledge Infrastructure (CNKI), China Science and Technology Journal Database (CSTJ), and Superstar Journals Database. The 2021 edition of Journal Citation Reports® cites the 2020 Journal Citation Indicator (JCI) for *WJH* as 0.61. The *WJH*'s CiteScore for 2020 is 5.6 and Scopus CiteScore rank 2020: Hepatology is 24/62.

RESPONSIBLE EDITORS FOR THIS ISSUE

Production Editor: *Xu Guo*; Production Department Director: *Xiang Li*; Editorial Office Director: *Xiang Li*.

NAME OF JOURNAL

World Journal of Hepatology

ISSN

ISSN 1948-5182 (online)

LAUNCH DATE

October 31, 2009

FREQUENCY

Monthly

EDITORS-IN-CHIEF

Nikolaos Pylsopoulos, Ke-Qin Hu, Koo Jeong Kang

EDITORIAL BOARD MEMBERS

<https://www.wjgnet.com/1948-5182/editorialboard.htm>

PUBLICATION DATE

November 27, 2021

COPYRIGHT

© 2021 Baishideng Publishing Group Inc

INSTRUCTIONS TO AUTHORS

<https://www.wjgnet.com/bpg/gerinfo/204>

GUIDELINES FOR ETHICS DOCUMENTS

<https://www.wjgnet.com/bpg/GerInfo/287>

GUIDELINES FOR NON-NATIVE SPEAKERS OF ENGLISH

<https://www.wjgnet.com/bpg/gerinfo/240>

PUBLICATION ETHICS

<https://www.wjgnet.com/bpg/GerInfo/288>

PUBLICATION MISCONDUCT

<https://www.wjgnet.com/bpg/gerinfo/208>

ARTICLE PROCESSING CHARGE

<https://www.wjgnet.com/bpg/gerinfo/242>

STEPS FOR SUBMITTING MANUSCRIPTS

<https://www.wjgnet.com/bpg/GerInfo/239>

ONLINE SUBMISSION

<https://www.f6publishing.com>

Case Control Study

Tumor characteristics of hepatocellular carcinoma after direct-acting antiviral treatment for hepatitis C: Comparative analysis with antiviral therapy-naïve patients

Magdy Fouad, Mohamed El Kassas, Elham Ahmed, Reem El Sheemy

ORCID number: Magdy Fouad 0000-0001-8065-5581; Mohamed El Kassas 0000-0002-3396-6894; Elham Ahmed 0000-0002-7182-3245; Reem El Sheemy 0000-0001-8158-8878.

Author contributions: Fouad M and El Kassas M conceptualized the idea and design; El Sheemy R drafted, revised and edited the manuscript; all authors participated in and supervised patients' treatment and follow-up, revised and approved the final version of the manuscript.

Institutional review board

statement: The study protocol was approved by the Institutional Research Board at the Faculty of Medicine, Minia University, Egypt. Informed written consent was obtained from all patients of the study. This research was performed in agreement with the guidelines of the 1975 Declaration of Helsinki.

Informed consent statement:

Informed consent was obtained from all individual participants included in the study

Conflict-of-interest statement: All authors declare that they do not have any conflict of interest.

Magdy Fouad, Department of Tropical Medicine and Gastroenterology, Minia University, Minia 61519, Egypt

Mohamed El Kassas, Department of Endemic Medicine, Faculty of Medicine, Helwan University, Cairo 11795, Egypt

Elham Ahmed, Department of Internal Medicine, Minia University, Minia 61519, Egypt

Reem El Sheemy, Department of Tropical Medicine, Minia University, Minia 61111, Egypt

Corresponding author: Mohamed El Kassas, MD, Associate Professor, Department of Endemic Medicine, Faculty of Medicine, Helwan University, Ain Helwan, Cairo 11795, Egypt.
m_elkassas@hq.helwan.edu.eg

Abstract

BACKGROUND

Insufficient and contradictory data are available about the relation between direct-acting antivirals (DAAs) and hepatocellular carcinoma (HCC) development in patients with hepatitis C virus (HCV).

AIM

To analyze differences in basic clinical, radiological, and laboratory characteristics in addition to tumor behavior upon HCC diagnosis between patients with and without a previous history of DAAs exposure.

METHODS

This multicenter case-control study included 497 patients with chronic HCV-related HCC, allocated into one of two groups according to their history of antiviral treatment for their HCV.

RESULTS

Group I included 151 HCC patients with a history of DAAs, while 346 patients who had never been treated with DAAs were assigned to group II. A significant difference was observed between both groups regarding basic assessment scores (Child, MELD, and BCLC), which tended to have more advanced liver disease and HCC stage upon diagnosis in group I. However, serum albumin was

Data sharing statement: No additional data are available.

STROBE statement: The authors have read the STROBE Statement – checklist of items, and the manuscript was prepared and revised according to the STROBE Statement – checklist of items.

Country/Territory of origin: Egypt

Specialty type: Gastroenterology and hepatology

Provenance and peer review: Invited article; Externally peer reviewed.

Peer-review report's scientific quality classification

Grade A (Excellent): 0
Grade B (Very good): B
Grade C (Good): C, C
Grade D (Fair): 0
Grade E (Poor): 0

Open-Access: This article is an open-access article that was selected by an in-house editor and fully peer-reviewed by external reviewers. It is distributed in accordance with the Creative Commons Attribution NonCommercial (CC BY-NC 4.0) license, which permits others to distribute, remix, adapt, build upon this work non-commercially, and license their derivative works on different terms, provided the original work is properly cited and the use is non-commercial. See: <http://creativecommons.org/licenses/by-nc/4.0/>

Received: April 15, 2021

Peer-review started: April 15, 2021

First decision: June 15, 2021

Revised: June 30, 2021

Accepted: September 29, 2021

Article in press: September 29, 2021

Published online: November 27, 2021

P-Reviewer: Gaspar R, Sachu A, Shi YJ

S-Editor: Wang LL

L-Editor: A

P-Editor: Wang LL

significantly affected, and serum α -fetoprotein was significantly higher in group II ($P < 0.001$). In addition, group I showed significant HCC multicentricity than group II, while the incidence of portal vein thrombosis was significantly higher in group I ($P < 0.001$).

CONCLUSION

The basic clinical scores and laboratory characteristics of HCC patients are advanced in patients who are naïve to DAAs treatment; however, HCC behavior is more aggressive in DAA-treated patients.

Key Words: Hepatocellular carcinoma; Direct-acting antiviral treatment; Hepatitis C; Tumor behavior; Occurrence

©The Author(s) 2021. Published by Baishideng Publishing Group Inc. All rights reserved.

Core Tip: Despite the introduction of newer direct-acting antivirals (DAAs), hepatitis C virus (HCV)-related hepatocellular carcinoma (HCC) will continue to be a significant public health concern in the coming decades. Post-treatment HCV-related HCC has been discovered to be an emerging issue due to unmet needs for early HCC identification and intervention. In addition, we found that aggressive tumors were more common in DAAs exposed patients, which needs to be investigated further in prospective studies with larger cohorts and necessitates proactive screening for HCC in HCV-treated patients *via* public or private pharmacovigilance programs.

Citation: Fouad M, El Kassas M, Ahmed E, El Sheemy R. Tumor characteristics of hepatocellular carcinoma after direct-acting antiviral treatment for hepatitis C: Comparative analysis with antiviral therapy-naïve patients. *World J Hepatol* 2021; 13(11): 1743-1752

URL: <https://www.wjnet.com/1948-5182/full/v13/i11/1743.htm>

DOI: <https://dx.doi.org/10.4254/wjh.v13.i11.1743>

INTRODUCTION

Hepatocellular carcinoma (HCC) is the sixth most common cancer and the third most common cause of cancer-related mortality worldwide[1]. In Egypt, HCC is a significant public health problem responsible for 33.63% and 13.54% of all cancers in males and females, respectively[2]. On the other hand, hepatitis C virus infection (HCV) is considered a leading cause of chronic liver disease in Europe, the United States, and many other countries, including Egypt[3,4]. The risk of HCC development in HCV-related liver cirrhosis is 2% to 8% per year[5]. Multiple studies and meta-analyses demonstrated during the era of interferon (IFN)-based therapy that HCV eradication decreased the risk of hepatocarcinogenesis regardless of fibrosis stage[6,7]. Furthermore, these studies showed that the achievement of sustained virologic response (SVR) after IFN based treatment is directly related to reduced incidence of HCC and increased survival rates[8].

In 2014, the introduction of the more effective direct-acting antivirals (DAAs) for HCV treatment was generally expected to benefit all patients, including those who were not permitted to be treated with IFN-based therapy[7]. However, unexpectedly, the clinical use of DAAs has evoked a significant dilemma about the relationship between DAAs and the development of HCC. Some studies have suggested a direct relation between DAAs and the development of HCC, while others have insisted that DAAs are protective against HCC development[7].

In 2016, the first report in this context showed an unexpectedly high recurrence rate of previously treated HCC after DAAs exposure[6]. This initial report was followed by another retrospective study conducted in Italy which included 344 patients with HCV-related cirrhosis who received different DAA regimens; 91% achieved SVR. The patients were followed for 24 wk. The study revealed a 29% recurrence rate for those with a history of HCC and a 3.16% incidence rate (de novo HCCs) in those without a history of prior HCC irrespective of the used DAA regimen[9].



In addition to HCC recurrence, the different biological behavior of HCC in DAAs exposed patients, and the pattern of recurrence after DAA treatment has also been reported in studies coming from various countries. For example, in 2017, Reig and his colleagues reported more aggressive HCC recurrence after DAA treatment, as defined by an advanced Barcelona Clinic Liver Cancer (BCLC) stage[6]. Moreover, Renzulli *et al*[10] found a more aggressive HCC recurrence pattern with vascular invasion evidence after DAA therapy.

This study aimed to analyze differences in basic clinical, radiological, and laboratory characteristics and tumor behavior upon HCC diagnosis between patients with and without a previous history of DAAs exposure.

MATERIALS AND METHODS

Study design

The current study is a multicenter retrospective case-control study designed to compare the basic demographic, laboratory, and radiological criteria of HCC in patients with a history of DAAs treatment for their chronic HCV infection compared to HCC patients with no previous history of HCV antiviral treatment. Patients were recruited from December 2016 to April 2019 from Minia university hospital and Minia fever hospital, Minia, Egypt. Study patients were assigned to one of 2 groups according to previous DAAs exposure. The first group included 151 HCC patients who were previously treated with DAAs (Group I). According to a standardized treatment protocol, all patients were treated in one of the specialized viral hepatitis treatment centers affiliated to the Egyptian National Committee for Control of Viral Hepatitis. Group II included 346 HCC patients with the first presentation as HCC and no history of antiviral treatment for their HCV infection. Patients with combined HBV or HIV infections and patients with extrahepatic malignancies were excluded from the study.

Methods

All patients were recruited and diagnosed according to EASL guidelines and updated AASLD practice guidelines for managing HCC and BCLC guidelines[11-13]. In addition, baseline demographic, clinical, laboratory, and radiological criteria were studied. The Child-Turcotte Pugh score (CTP), Model for End-stage Liver Disease (MELD) score, BCLC score, and FIB 4 as a non-invasive marker for fibrosis were calculated and presented.

Lines of treatment for HCV have been verified as well as the viral response. In addition, all baseline characteristics, laboratory, radiological and medical scores were compared between the two groups.

The study was performed according to the ethical guidelines of the 1975 Declaration of Helsinki after approval from the Research Ethics Committee for human subject research at the Faculty of Medicine, Minia University (Serial: 165: 2/2019) on Feb 25, 2019. In addition, written informed consent was obtained from all participants before enrolment in the study.

Statistical analysis

Statistical analyses were performed using IBM SPSS advanced statistics, version 26 (SPSS Inc., Chicago, Illinois, USA). Numerical data were presented as mean \pm SD and median (range), whereas categorical data were presented as number (percent). The Mann-Whitney U-test and the χ^2 -test are used when appropriate. Statistical significance is considered if *P* value is less than or equal to 0.05.

RESULTS

This study included 497 patients with chronic HCV-related HCC, allocated into one of two groups according to their history of antiviral treatment for their HCV. Group I included 151 patients with chronic HCV and HCC who were previously treated with DAAs. Group II included 346 patients representing all patients recruited in the same period with HCV-related HCC and age and sex-matched with group I. Most of the studied patients in both groups were males: (76.2%) and (72.0%) (*P* value 0.33), with a mean age of 60.2 years and 59.8 years in groups I and II, respectively (*P* value 0.70) (Table 1). Regarding the received DAAs regimen in group I patients, 44.4% of patients

Table 1 Basic demographic data and underlying liver status in both groups

	Group I	Group II	P value
	HCC with previous DAAs (n = 151)	HCC without previous DAAs (n = 346)	
Age (mean ± SD)	60.17 ± 7.75	59.84 ± 9.12	0.70
Gender			0.33
Female	36 (23.8)	97 (28.0)	
Male	115 (76.2)	249 (72.0)	
Residence			0.28
Rural	131 (86.8)	287 (82.9)	
Urban	20 (13.2)	59 (17.1)	
BCLC			< 0.001 ^a
0	5 (3.3)	15 (4.3)	
A	47 (31.1)	134 (38.7)	
B	17 (11.3)	68 (19.7)	
C	49 (32.5)	50 (14.5)	
D	33 (21.9)	79 (22.8)	
MELD (mean ± SD)	14.35 ± 5.041	36.10 ± 30.22	< 0.001 ^a
CTP score			0.04
A	50 (33.1)	88 (25.4)	
B	65(43.0)	138 (39.9)	
C	36 (23.8)	120 (34.7)	
FIB4			< 0.001 ^c
mean ± SD	3.25 ± 9.87	7.11 ± 7.68	
Median	0.023	4.49	
IQR	4.51	6.2	
HCC detection time after stop of DAAs	Range: 1-72 moMedian: 8 mo	-	-

^aP < 0.05.^cP < 0.001.

HCC: Hepatocellular carcinoma; MELD: Model for end stage liver disease; CTP: Child Turcotte-pough; BCLC: Barcelona cancer liver clinic.

received sofosbuvir/daclatasvir (SOF/DAC), 40.1% received SOF/DAC/RBV, 13.2% received SOF/RBV, and only 2% received SOF/RBV/PEG IFN. **Figure 1** shows patients' distribution among various treatment regimens and treatment duration, in addition to treatment viral response.

Notably, significant differences were observed between the two groups regarding the case assessment scores that reflect the severity of the underlying liver condition upon HCC discovery. A total of 34.7% of patients in group II were CTP class C, and only 23.8% of group I patients were class C. Mean MELD score in group I was 14, while the mean MELD in group II was 36 (*P* value < 0.001). Moreover, a significant difference was observed in the BCLC score (*P* value < 0.001). A significant difference was encountered in FIB4 as a method for non-invasive fibrosis assessment with a mean FIB4 of 3.25 in group I, compared to 7.11 in group II (*P* value < 0.001). Basic demographic data and underlying liver status in both groups are detailed in **Table 1**. The time between stopping DAAs and the development of HCC ranged from 1 to 72 mo with a median of 8 mo.

When comparing both groups' clinical data, no significant differences were observed except in the current smoking status, which was significantly increased in group I compared to the other group (*P* value 0.005). On the other hand, a significant history of blood transfusion was observed in patients with no previous history of DAAs (*P* value 0.01); cellular decompensation in the form of hepatic encephalopathy is

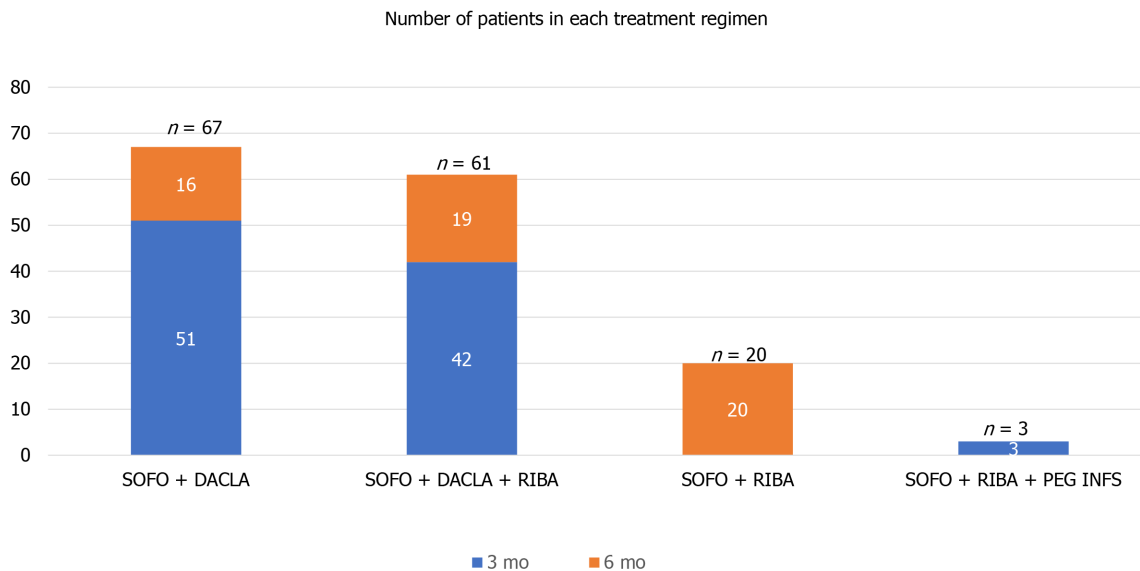


Figure 1 Patients in group I distribution among different treatment regimen. SOFO: Sofosbuvir; DACLA: Daclatasvir; RIBA: Ribavirin; PEG INFS: Pegylated interferon.

significantly observed in patients with no previous history of DAAs (P value 0.01). Detailed clinical data of the two studied groups are well presented in [Table 2](#).

Comparing laboratory data in both groups, hemoglobin level and total leukocytic count were significantly different (P values are 0.02 and 0.004, respectively). Median ALT in group I was 77 IU in comparison to 54 IU in group II (P value 0.001). Mean albumin in groups I and II was (3.3 and 2.9 respectively) (P value 0.004), and mean urea in groups I and II was (40 and 54 respectively) (P value 0.04). Median AFP in group I was 184 in comparison to 60 in group II (P value < 0.001). An illustrated comparison of all laboratory data is presented in [Table 3](#).

Regarding the radiological characters of HCC in both groups, HCC in group I patients was more multifocal (53%) in comparison to (25%) in group II (P value < 0.001). Moreover, HCCs in group I patients tended to present with a bigger tumor size at the initial presentation than group II patients. More precisely, less than 1% of group I patients were presented with tumors less than 2 cm, while more than 15% of group II patients presented with tumors less than 2 cm (P value < 0.001), indicating more aggressive tumor behavior associated with the previous history of DAAs. The right lobe was the dominant victim in both groups. Early vascular invasion was significantly higher in group I compared to group II as evidenced radiologically by portal vein thrombosis (PVT), which present in 45% of group I patients and only 21% of group II patients (P value < 0.001), all radiological data for HCCs in the studied patients are detailed in [Table 4](#).

DISCUSSION

Chronic HCV infection is a significant risk factor for developing liver cirrhosis in approximately 20%-30% of patients with subsequent increased risk for HCC development in those patients with an estimated annual incidence of 3.5%[14]. This risk is shown to be lower in patients with chronic HCV infection without cirrhosis and in patients who succeeded in achieving eradication, as proved by their SVR[15]. Despite the notable decrease in the overall incidence of HCV infection, its prevalence in HCC patients is still high[16]. Surprisingly, HCC development's risk is continuous in HCV-induced liver cirrhosis even after viral eradication and SVR achievement[16]. During the interferon-based treatment era, successful viral eradication decreases the risk for HCC and improvement in the fibrosis stage[9].

The emergence of DAAs with their extended patient spectrum, improved efficacy, and safety profile increased our expectations regarding a decrease in HCC occurrence and recurrence. However, unpleasant data from new studies showed that DAAs might encourage tumor occurrence in patients with cirrhosis or recurrence in patients with previously treated HCC[9,17]. The same was reported in some studies regarding HCC

Table 2 Clinical presentation in both groups

	Group I	Group II	P value
	HCC with previous DAAs (n = 151)	HCC without previous DAAs (n = 346)	
Hypertension	56 (37.1)	135 (39.0)	0.68
DM	56 (37.1)	113 (32.7)	0.33
Smoking	73 (48.3)	121 (35.0)	0.005 ^a
Surgical operations	32 (21.2)	101 (29.2)	0.06
Blood transfusion	23 (15.2)	87 (25.1)	0.01 ^a
Jaundice	60 (39.7)	154 (44.5)	0.32
Ascites	90 (59.6)	197 (56.9)	0.58
LL edema	48 (31.8)	143 (41.3)	0.07
Hepatic encephalopathy	14 (9.3)	61 (17.6)	0.01 ^a

^aP < 0.05.

HCC: Hepatocellular carcinoma; DM: Diabetes mellitus; LL: Lower limb.

Table 3 Comparison of laboratory data in both groups

	Group I	Group II	P value
	HCC with previous DAAs (n = 151)	HCC without previous DAAs (n = 346)	
HB (mean ± SD)	10.41 ± 1.88	10.78 ± 1.99	0.02 ^a
TLC (mean ± SD)	6.55 ± 6.20	7.74 ± 8.60	0.004 ^b
PLATELETS (mean ± SD)	147.28 ± 79.76	135.95 ± 61.17	0.22
TBIL (median)	3.07	2.5	0.93
DBIL (median)	0.7	0.9	0.84
ALB (mean ± SD)	3.32 ± 1.47	2.98 ± 0.85	0.004 ^b
INR	1.31 ± 0.35	1.44 ± 0.47	0.4
ALT (median)	77	54	0.001 ^c
AST (median)	76	70	0.62
CREAT (mean ± SD)	1.21 ± 0.45	1.43 ± 3.67	0.15
UREA (mean ± SD)	40.81 ± 16.01	54.93 ± 46.17	0.04 ^a
AFP (median)	184.0	60.0	< 0.001 ^c

^aP < 0.05.^bP < 0.01.^cP < 0.001.

HCC: Hepatocellular carcinoma; CBC: Complete blood picture; TLC: Total leucocytic count; TBIL: Total bilirubin; DBIL: Direct bilirubin; ALB: Albumin, ALT: Alanine aminotransferase; AST: Aspartate aminotransferase; AFP: Alfa feto protein.

recurrence after initial management upon treatment with DAAs^[18].

This study stands at the current dilemma between DAAs' benefits and drawbacks; studying the basic characteristics of HCC patients previously treated with DAAs and comparing them with HCC patients never treated with DAAs provides the central part of this controversy.

In our study, significant differences were found in the CTP, MELD, and BCLC scores in HCC patients without DAAs and those who received DAAs; these findings are contrary to what proved by Abdelaziz *et al*^[19], who found matching between patients with HCC and previous DAAs and HCC without DAAs regarding CTP score. In accordance with our results, a large study from Pakistan reported a raised neutrophil to lymphocyte ratio and younger patient age with more aggressive tumor

Table 4 Radiological characters of hepatocellular carcinoma in both groups

	Group I	Group II	P value ^c
	HCC with previous DAAs (n = 151)	HCC without previous DAAs (n = 346)	
Number			< 0.001
Single	71 (47.0)	259 (74.9)	
Multiple	80 (53.0)	87 (25.1)	
Size			< 0.001
Less than 2 cm	1 (0.7)	54 (15.6)	
2.5 cm	91(60.3)	177 (51.2)	
Greater than 5 cm	59 (39.1)	115 (33.2)	
Site			0.001
Bilobar	21 (13.9)	29 (8.4)	
Lt lobe	24 (15.9)	23 (6.6)	
RT lobe	106 (70.2)	294 (84.9)	
PVT	68 (45.0)	75 (21.7)	< 0.001
Splenomegaly			< 0.001
Average	38 (25.2)	98 (28.3)	
Mild	113 (74.8)	214 (61.8)	
Moderate	0 (0.0)	34 (9.8)	

^cP < 0.001.

HCC: Hepatocellular carcinoma; DAAs: Directly acting antiviral agents; PVT: Portal vein thrombosis.

behavior in HCV-treated HCC patients[20].

The pattern of HCC invasion either locally inside the liver manifested by multiplicity and larger size or vascularity manifested by PVT is significantly increased with the previous history of DAAs, suggesting a possible DAAs role in such aggressive behavior. In accordance with the current study, Reig *et al*[6] stated the increased aggressiveness of HCC, but in recurrent cases, he omitted de novo HCC in his study. Also, Renzulli *et al*[10] noticed a faster rate of development of HCC after DAA therapy with an aggressive course of microvascular invasion. Similarly, Faillaci *et al*[21] proved that DAAs are associated with increased aggressiveness and tumor recurrence growth. Another study done by Romano *et al*[21] demonstrated an aggressive behavior of tumors after DAA in the form of a higher number of nodules and extrahepatic metastases, suggesting that such patients' tumor growth is faster than usual. Many theories have been proposed to explain this unexpected event; some researchers have related the development of HCC to baseline risk factors such as advanced fibrosis grade, HBV co-infection, or age[7]. Another theory proposes that DAAs cause immune surveillance mechanisms to become dysregulated due to the rapid viral clearance, and this behavior has been confirmed by several investigations [16,19]. With the downregulation of type II and III IFNs, their receptors, and IFN-stimulated genes, this dysregulation may result in the re-establishment of innate immunity. Due to the anti-angiogenic and anti-proliferative capabilities of IFN, which DAAs lack, a reduction in IFN activation may promote the proliferation of malignant cells. Furthermore, after HCV eradication, one of the immune system alterations observed is a decrease in the number of cytotoxic activity of natural killer cells in the liver, favoring a faster progression of HCC foci[7,22].

A significant difference was observed in AFP levels between the two groups, explained mainly by the invasive pattern and prominent vascular invasion in group I, and this is in agreement with Abdelaziz *et al*[20].

The strengths of our study include its design and the large number of included subjects. Limitations include the exclusive existence of genotype four patients because of its prevalence in Egypt and lack of tight evaluation of other risk factors for HCC, like non-alcoholic fatty liver disease and aflatoxin effect, and the lack of further longitudinal follow up of the studied cohort.

CONCLUSION

In conclusion, despite the introduction of newer DAAs, HCV-related HCC will continue to be a significant public health concern in the coming period. Post-treatment HCV-related HCC has been discovered to be an emerging issue due to unmet needs for early HCC identification and intervention. In this study, more aggressive tumor behavior was encountered in DAAs exposed patients. Such finding needs to be investigated further in prospective studies with larger cohorts and more longitudinal follow-up for comparing survival and necessitates proactive screening for HCC in HCV-treated patients *via* public or private pharmacovigilance programs. Furthermore, anti-HCV therapy in HCC patients should be postponed until a consistent risk-benefit ratio is established through further research.

ARTICLE HIGHLIGHTS

Research background

The evidence on the link between direct-acting antivirals (DAAs) and the development of hepatocellular carcinoma (HCC) in hepatitis C virus (HCV) patients is insufficient and conflicting.

Research motivation

Due to unmet needs for early HCC detection and care, post-treatment HCV-related HCC is an increasing concern.

Research objectives

To compare fundamental clinical, radiographic, and laboratory features and tumor behavior in individuals with and without a history of DAAs exposure after HCC diagnosis.

Research methods

A multicenter case-control study including 497 patients with chronic HCV-related HCC, allocated into one of two groups according to their history of antiviral treatment for their HCV.

Research results

Group I consisted of 151 HCC patients who had previously been treated with DAAs, while group II included 346 patients who had never been treated with DAAs. Regarding basic assessment scores (Child, MELD, and BCLC), there was a substantial difference between the two groups, with group I showing a tendency for more advanced liver disease and HCC stage at diagnosis. However, serum albumin levels were considerably lower in group II, and serum-fetoprotein levels were significantly greater ($P = 0.001$). In addition, HCC multicentricity was substantially higher in group I than in group II, and the rate of portal vein thrombosis was significantly higher in group I ($P = 0.001$).

Research conclusions

HCC patients who are naïve to DAAs have more advanced clinical scores and laboratory features than those who have never been treated with DAAs; yet, HCC behavior is more aggressive in DAA-treated patients.

Research perspectives

The findings of this study warrant additional investigation in prospective trials with larger cohorts and longer follow-up for comparing survival and proactive screening for HCC in HCV-treated patients through public or private pharmacovigilance programs.

ACKNOWLEDGEMENTS

The authors acknowledge the physicians of Minia University who helped in this research.

REFERENCES

- 1 **Tabrizian P**, Roayaie S, Schwartz ME. Current management of hepatocellular carcinoma. *World J Gastroenterol* 2014; **20**: 10223-10237 [PMID: [25132740](#) DOI: [10.3748/wjg.v20.i30.10223](#)]
- 2 **Holah NS**, El-Azab DS, Aiad HAE, Sweed DMM. The Diagnostic Role of SPINK1 in Differentiating Hepatocellular Carcinoma From Nonmalignant Lesions. *Appl Immunohistochem Mol Morphol* 2017; **25**: 703-711 [PMID: [27028242](#) DOI: [10.1097/PAI.0000000000000363](#)]
- 3 **Messina JP**, Humphreys I, Flaxman A, Brown A, Cooke GS, Pybus OG, Barnes E. Global distribution and prevalence of hepatitis C virus genotypes. *Hepatology* 2015; **61**: 77-87 [PMID: [25069599](#) DOI: [10.1002/hep.27259](#)]
- 4 **Kandeel A**, Genedy M, El-Refai S, Funk AL, Fontanet A, Talaat M. The prevalence of hepatitis C virus infection in Egypt 2015: implications for future policy on prevention and treatment. *Liver Int* 2017; **37**: 45-53 [PMID: [27275625](#) DOI: [10.1111/liv.13186](#)]
- 5 **Ioannou GN**, Splan MF, Weiss NS, McDonald GB, Beretta L, Lee SP. Incidence and predictors of hepatocellular carcinoma in patients with cirrhosis. *Clin Gastroenterol Hepatol* 2007; **5**: 938-945, 945.e1 [PMID: [17509946](#) DOI: [10.1016/j.cgh.2007.02.039](#)]
- 6 **Reig M**, Mariño Z, Perelló C, Iñarrairaegui M, Ribeiro A, Lens S, Díaz A, Vilana R, Darnell A, Varela M, Sangro B, Calleja JL, Forns X, Bruix J. Unexpected high rate of early tumor recurrence in patients with HCV-related HCC undergoing interferon-free therapy. *J Hepatol* 2016; **65**: 719-726 [PMID: [27084592](#) DOI: [10.1016/j.jhep.2016.04.008](#)]
- 7 **El Kassas M**, Elbaz T, Salaheldin M, Abdelsalam L, Kaseb A, Esmat G. Impact of treating chronic hepatitis C infection with direct-acting antivirals on the risk of hepatocellular carcinoma: The debate continues - A mini-review. *J Adv Res* 2019; **17**: 43-48 [PMID: [31193326](#) DOI: [10.1016/j.jare.2019.03.001](#)]
- 8 **Tanimoto Y**, Tashiro H, Aikata H, Amano H, Oshita A, Kobayashi T, Kuroda S, Tazawa H, Takahashi S, Itamoto T, Chayama K, Ohdan H. Impact of pegylated interferon therapy on outcomes of patients with hepatitis C virus-related hepatocellular carcinoma after curative hepatic resection. *Ann Surg Oncol* 2012; **19**: 418-425 [PMID: [21710324](#) DOI: [10.1245/s10434-011-1866-1](#)]
- 9 **Conti F**, Buonfiglioli F, Scuteri A, Crespi C, Bolondi L, Caraceni P, Foschi FG, Lenzi M, Mazzella G, Verucchi G, Andreone P, Brillanti S. Early occurrence and recurrence of hepatocellular carcinoma in HCV-related cirrhosis treated with direct-acting antivirals. *J Hepatol* 2016; **65**: 727-733 [PMID: [27349488](#) DOI: [10.1016/j.jhep.2016.06.015](#)]
- 10 **Renzulli M**, Buonfiglioli F, Conti F, Brocchi S, Serio I, Foschi FG, Caraceni P, Mazzella G, Verucchi G, Golfieri R, Andreone P, Brillanti S. Imaging features of microvascular invasion in hepatocellular carcinoma developed after direct-acting antiviral therapy in HCV-related cirrhosis. *Eur Radiol* 2018; **28**: 506-513 [PMID: [28894901](#) DOI: [10.1007/s00330-017-5033-3](#)]
- 11 **Bruix J**, Sherman M, Llovet JM, Beaugrand M, Lencioni R, Burroughs AK, Christensen E, Pagliaro L, Colombo M, Rodés J; EASL Panel of Experts on HCC. Clinical management of hepatocellular carcinoma. Conclusions of the Barcelona-2000 EASL conference. European Association for the Study of the Liver. *J Hepatol* 2001; **35**: 421-430 [PMID: [11592607](#) DOI: [10.1016/s0168-8278\(01\)00130-1](#)]
- 12 **Bruix J**, Sherman M; American Association for the Study of Liver Diseases. Management of hepatocellular carcinoma: an update. *Hepatology* 2011; **53**: 1020-1022 [PMID: [21374666](#) DOI: [10.1002/hep.24199](#).]
- 13 **Llovet JM**, Bustamante J, Castells A, Vilana R, Ayuso Mdel C, Sala M, Brú C, Rodés J, Bruix J. Natural history of untreated nonsurgical hepatocellular carcinoma: rationale for the design and evaluation of therapeutic trials. *Hepatology* 1999; **29**: 62-67 [PMID: [9862851](#) DOI: [10.1002/hep.510290145](#)]
- 14 **Lok AS**, Seeff LB, Morgan TR, di Bisceglie AM, Sterling RK, Curto TM, Everson GT, Lindsay KL, Lee WM, Bonkovsky HL, Dienstag JL, Ghany MG, Morishima C, Goodman ZD; HALT-C Trial Group. Incidence of hepatocellular carcinoma and associated risk factors in hepatitis C-related advanced liver disease. *Gastroenterology* 2009; **136**: 138-148 [PMID: [18848939](#) DOI: [10.1053/j.gastro.2008.09.014](#).]
- 15 **Swain MG**, Lai MY, Shiffman ML, Cooksley WG, Zeuzem S, Dieterich DT, Abergel A, Pessôa MG, Lin A, Tietz A, Connell EV, Diago M. A sustained virologic response is durable in patients with chronic hepatitis C treated with peginterferon alfa-2a and ribavirin. *Gastroenterology* 2010; **139**: 1593-1601 [PMID: [20637202](#) DOI: [10.1053/j.gastro.2010.07.009](#)]
- 16 **Robert S B Jr.** The Possible Association Between DAA Treatment for HCV Infection and HCC Recurrence. *Gastroenterol Hepatol (N Y)* 2016; **12**: 776-779 [PMID: [28035203](#)]
- 17 **Tayyab GUN**, Rasool S, Nasir B, Rubi G, Abou-Samra AB, Butt AA. Hepatocellular carcinoma occurs frequently and early after treatment in HCV genotype 3 infected persons treated with DAA regimens. *BMC Gastroenterol* 2020; **20**: 93 [PMID: [32252635](#) DOI: [10.1186/s12876-020-01249-4](#)]
- 18 **Sapena V**, Enea M, Torres F, Celsa C, Rios J, Rizzo GEM, Nahon P, Mariño Z, Tateishi R, Minami T, Sangiovanni A, Forns X, Toyoda H, Brillanti S, Conti F, Degasperis E, Yu ML, Tsai PC, Jean K, El Kassas M, Shousha HI, Omar A, Zavaglia C, Nagata H, Nakagawa M, Asahina Y, Singal AG, Murphy C, Kohla M, Masetti C, Dufour JF, Merchante N, Cavalletto L, Chemello LL, Pol S, Crespo J, Calleja JL, Villani R, Serviddio G, Zanetto A, Shalaby S, Russo FP, Bielen R, Trevisani F, Cammà C, Bruix J, Cabibbo G, Reig M. Hepatocellular carcinoma recurrence after direct-acting antiviral therapy: an individual patient data meta-analysis. *Gut* 2021 [DOI: [10.1136/gutjnl-2020-323663](#)]
- 19 **Abdelaziz AO**, Nabil MM, Abdelmaksoud AH, Shousha HI, Hashem MB, Hassan EM, Salah A,

- Omran DA, Elbaz TM. Tumor behavior of hepatocellular carcinoma after hepatitis C treatment by direct-acting antivirals: comparative analysis with non-direct-acting antivirals-treated patients. *Eur J Gastroenterol Hepatol* 2019; **31**: 75-79 [PMID: [30199473](#) DOI: [10.1097/MEG.0000000000001264](#)]
- 20 **Khalid J**, Umar M, Ur-Rehman T, Ali M, Khan GM. Tumor aggression among hepatitis-C related hepatocellular carcinoma patients: an observational study regarding the impact of anti-HCV therapy. *Infect Agent Cancer* 2020; **15**: 35 [PMID: [32508980](#) DOI: [10.1186/s13027-020-00300-z](#)]
- 21 **Faillaci F**, Marzi L, Critelli R, Milosa F, Schepis F, Turola E, Andreani S, Vandelli G, Bernabucci V, Lei B, D'Ambrosio F, Bristot L, Cavalletto L, Chemello L, Sighinolfi P, Manni P, Maiorana A, Caporali C, Bianchini M, Marsico M, Turco L, de Maria N, Del Buono M, Todesca P, di Lena L, Romagnoli D, Magistri P, di Benedetto F, Bruno S, Taliani G, Giannelli G, Martinez-Chantar ML, Villa E. Liver Angiopoietin-2 Is a Key Predictor of De Novo or Recurrent Hepatocellular Cancer After Hepatitis C Virus Direct-Acting Antivirals. *Hepatology* 2018; **68**: 1010-1024 [PMID: [29604220](#) DOI: [10.1002/hep.29911](#)]
- 22 **Innes H**, Barclay ST, Hayes PC, Fraser A, Dillon JF, Stanley A, Bathgate A, McDonald SA, Goldberg D, Valerio H, Fox R, Kennedy N, Bramley P, Hutchinson SJ. The risk of hepatocellular carcinoma in cirrhotic patients with hepatitis C and sustained viral response: Role of the treatment regimen. *J Hepatol* 2018; **68**: 646-654 [PMID: [29155019](#) DOI: [10.1016/j.jhep.2017.10.033](#)]



Published by **Baishideng Publishing Group Inc**
7041 Koll Center Parkway, Suite 160, Pleasanton, CA 94566, USA

Telephone: +1-925-3991568

E-mail: bpgoffice@wjgnet.com

Help Desk: <https://www.f6publishing.com/helpdesk>

<https://www.wjgnet.com>

