

World Journal of *Hepatology*

World J Hepatol 2021 December 27; 13(12): 1816-2200



OPINION REVIEW

- 1816** Non-alcoholic fatty liver disease in irritable bowel syndrome: More than a coincidence?
Purssell H, Whorwell PJ, Athwal VS, Vasant DH

REVIEW

- 1828** Liver-side of inflammatory bowel diseases: Hepatobiliary and drug-induced disorders
Mazza S, Soro S, Verga MC, Elvo B, Ferretti F, Cereatti F, Drago A, Grassia R
- 1850** Gastrointestinal and hepatic side effects of potential treatment for COVID-19 and vaccination in patients with chronic liver diseases
Law MF, Ho R, Law KWT, Cheung CKM
- 1875** Genotype E: The neglected genotype of hepatitis B virus
Ingasia LAO, Wose Kinge C, Kramvis A

MINIREVIEWS

- 1892** One stop shop approach for the diagnosis of liver hemangioma
Sandulescu LD, Urhut CM, Sandulescu SM, Ciurea AM, Cazacu SM, Iordache S
- 1909** Liver function in COVID-19 infection
Przekop D, Gruszevska E, Chrostek L
- 1919** Potential role of noninvasive biomarkers during liver fibrosis
Kaur N, Goyal G, Garg R, Tapasvi C, Chawla S, Kaur R
- 1936** Imaging evaluation of the liver in oncology patients: A comparison of techniques
Freitas PS, Janicas C, Veiga J, Matos AP, Herédia V, Ramalho M
- 1956** Liver manifestations and complications in inflammatory bowel disease: A review
Gaspar R, Branco CC, Macedo G
- 1968** Dengue hemorrhagic fever and the liver
Leowattana W, Leowattana T
- 1977** Artificial Intelligence in hepatology, liver surgery and transplantation: Emerging applications and frontiers of research
Veerankutty FH, Jayan G, Yadav MK, Manoj KS, Yadav A, Nair SRS, Shabeerali TU, Yeldho V, Sasidharan M, Rather SA
- 1991** De novo and recurrence of metabolic dysfunction-associated fatty liver disease after liver transplantation
Han MAT, Olivo R, Choi CJ, Pyrsopoulos N

- 2005** Liver dysfunction as a cytokine storm manifestation and prognostic factor for severe COVID-19

Taneva G, Dimitrov D, Velikova T

- 2013** COVID-19 and the liver: A brief and core review

Kayaaslan B, Guner R

- 2024** Newer variants of progressive familial intrahepatic cholestasis

Vinayagamoorthy V, Srivastava A, Sarma MS

- 2039** Deep learning in hepatocellular carcinoma: Current status and future perspectives

Ahn JC, Qureshi TA, Singal AG, Li D, Yang JD

ORIGINAL ARTICLE

Basic Study

- 2052** Gut dysbiosis and systemic inflammation promote cardiomyocyte abnormalities in an experimental model of steatohepatitis

Longo L, Rampelotto PH, Filippi-Chiela E, de Souza VEG, Salvati F, Cerski CT, da Silveira TR, Oliveira CP, Uribe-Cruz C, Álvares-da-Silva MR

Case Control Study

- 2071** Leukocyte cell-derived chemotaxin-2 and fibroblast growth factor 21 in alcohol-induced liver cirrhosis

Sak JJ, Prystupa A, Kiciński P, Luchowska-Kocot D, Kurys-Denis E, Bis-Wencel H

Retrospective Study

- 2081** Biliary complications in recipients of living donor liver transplantation: A single-centre study

Guirguis RN, Nashaat EH, Yassin AE, Ibrahim WA, Saleh SA, Bahaa M, El-Meteini M, Fathy M, Dabbous HM, Montasser IF, Salah M, Mohamed GA

- 2104** Liver function tests and metabolic-associated fatty liver disease: Changes in upper normal limits, does it really matter?

Forlano R, Mullish BH, Dhar A, Goldin RD, Thursz M, Manousou P

- 2113** Use of oral vancomycin in children with autoimmune liver disease: A single centre experience

Di Giorgio A, Tulone A, Nicastro E, Norsa L, Sonzogni A, D'Antiga L

- 2128** Trends of alcoholic liver cirrhosis readmissions from 2010 to 2018: Rates and healthcare burden associated with readmissions

Kichloo A, El-Amir Z, Dahiya DS, Wani F, Singh J, Solanki D, Edigin E, Eseaton P, Mehboob A, Shaka H

Observational Study

- 2137** New stem cell autophagy surrogate diagnostic biomarkers in early-stage hepatocellular carcinoma in Egypt: A pilot study

Yosef T, Ibrahim WA, Matboli M, Swilam AA, El-Nakeep S

- 2150** Determination of "indeterminate score" measurements in lean nonalcoholic fatty liver disease patients from western Saudi Arabia

Khayyat YM

- 2161** Managing liver transplantation during the COVID-19 pandemic: A survey among transplant centers in the Southeast United States

Gonzalez AJ, Kapila N, Thomas E, Pinna A, Tzakis A, Zervos XB

Prospective Study

- 2168** Accuracy of virtual chromoendoscopy in differentiating gastric antral vascular ectasia from portal hypertensive gastropathy: A proof of concept study

Al-Taei AM, Cubillan MP, Hinton A, Sobotka LA, Befeler AS, Hachem CY, Hussan H

- 2179** Non-alcoholic steatohepatitis in liver transplant recipients diagnosed by serum cytokeratin 18 and transient elastography: A prospective study

Alhinai A, Qayyum-Khan A, Zhang X, Samaha P, Metrakos P, Deschenes M, Wong P, Ghali P, Chen TY, Sebastiani G

CASE REPORT

- 2192** Rare primary mature teratoma of the liver: A case report

Kovalenko YA, Zharikov YO, Kiseleva YV, Goncharov AB, Shevchenko TV, Gurmikov BN, Kalinin DV, Zhao AV

ABOUT COVER

Editorial Board Member of *World Journal of Hepatology*, Manuel Luis Rodríguez-Perálvarez, MD, PhD, Consultant Hepatologist and Associate Professor of Medicine, Department of Hepatology and Liver Transplantation, Reina Sofia University Hospital, Córdoba 14014, Spain. ropeml@hotmail.com

AIMS AND SCOPE

The primary aim of *World Journal of Hepatology* (*WJH*, *World J Hepatol*) is to provide scholars and readers from various fields of hepatology with a platform to publish high-quality basic and clinical research articles and communicate their research findings online.

WJH mainly publishes articles reporting research results and findings obtained in the field of hepatology and covering a wide range of topics including chronic cholestatic liver diseases, cirrhosis and its complications, clinical alcoholic liver disease, drug induced liver disease autoimmune, fatty liver disease, genetic and pediatric liver diseases, hepatocellular carcinoma, hepatic stellate cells and fibrosis, liver immunology, liver regeneration, hepatic surgery, liver transplantation, biliary tract pathophysiology, non-invasive markers of liver fibrosis, viral hepatitis.

INDEXING/ABSTRACTING

The *WJH* is now abstracted and indexed in PubMed, PubMed Central, Emerging Sources Citation Index (Web of Science), Scopus, China National Knowledge Infrastructure (CNKI), China Science and Technology Journal Database (CSTJ), and Superstar Journals Database. The 2021 edition of Journal Citation Reports® cites the 2020 Journal Citation Indicator (JCI) for *WJH* as 0.61. The *WJH*'s CiteScore for 2020 is 5.6 and Scopus CiteScore rank 2020: Hepatology is 24/62.

RESPONSIBLE EDITORS FOR THIS ISSUE

Production Editor: *Xu Guo*; Production Department Director: *Xiang Li*; Editorial Office Director: *Xiang Li*.

NAME OF JOURNAL

World Journal of Hepatology

ISSN

ISSN 1948-5182 (online)

LAUNCH DATE

October 31, 2009

FREQUENCY

Monthly

EDITORS-IN-CHIEF

Nikolaos Pyrsopoulos, Ke-Qin Hu, Koo Jeong Kang

EDITORIAL BOARD MEMBERS

<https://www.wjnet.com/1948-5182/editorialboard.htm>

PUBLICATION DATE

December 27, 2021

COPYRIGHT

© 2021 Baishideng Publishing Group Inc

INSTRUCTIONS TO AUTHORS

<https://www.wjnet.com/bpg/gerinfo/204>

GUIDELINES FOR ETHICS DOCUMENTS

<https://www.wjnet.com/bpg/GerInfo/287>

GUIDELINES FOR NON-NATIVE SPEAKERS OF ENGLISH

<https://www.wjnet.com/bpg/gerinfo/240>

PUBLICATION ETHICS

<https://www.wjnet.com/bpg/GerInfo/288>

PUBLICATION MISCONDUCT

<https://www.wjnet.com/bpg/gerinfo/208>

ARTICLE PROCESSING CHARGE

<https://www.wjnet.com/bpg/gerinfo/242>

STEPS FOR SUBMITTING MANUSCRIPTS

<https://www.wjnet.com/bpg/GerInfo/239>

ONLINE SUBMISSION

<https://www.f6publishing.com>

Newer variants of progressive familial intrahepatic cholestasis

Vignesh Vinayagamoorthy, Anshu Srivastava, Moinak Sen Sarma

ORCID number: Vignesh

Vinayagamoorthy 0000-0003-4860-683X; Anshu Srivastava 0000-0003-0902-4140; Moinak Sen Sarma 0000-0003-2015-4069.

Author contributions:

Vinayagamoorthy V contributed literature retrieval, primary draft of manuscript; Srivastava A contributed concept and design, literature retrieval, intellectual input and critical revision of manuscript; Sarma MS contributed intellectual input and critical revision of manuscript; all authors reviewed and approved the final manuscript as submitted.

Conflict-of-interest statement: The authors declare that they do not have any conflict of interest to disclose.

Country/Territory of origin: India

Specialty type: Gastroenterology and hepatology

Provenance and peer review:

Invited article; Externally peer reviewed.

Peer-review model: Single blind

Peer-review report's scientific quality classification

Grade A (Excellent): 0
Grade B (Very good): B
Grade C (Good): 0
Grade D (Fair): 0
Grade E (Poor): 0

Vignesh Vinayagamoorthy, Anshu Srivastava, Moinak Sen Sarma, Department of Pediatric Gastroenterology, Sanjay Gandhi Postgraduate Institute of Medical Sciences, Lucknow 226014, Uttar Pradesh, India

Corresponding author: Anshu Srivastava, MD, Professor, Department of Pediatric Gastroenterology, Sanjay Gandhi Postgraduate Institute of Medical Sciences, Raebareli Road, Lucknow 226014, Uttar Pradesh, India. avanianshu@yahoo.com

Abstract

Progressive familial intrahepatic cholestasis (PFIC) is a heterogeneous group of disorders characterized by defects in bile secretion and presentation with intrahepatic cholestasis in infancy or childhood. The most common types include PFIC 1 (deficiency of FIC1 protein, ATP8B1 gene mutation), PFIC 2 (bile salt export pump deficiency, ABCB11 gene mutation), and PFIC 3 (multidrug resistance protein-3 deficiency, ABCB4 gene mutation). Mutational analysis of subjects with normal gamma-glutamyl transferase cholestasis of unknown etiology has led to the identification of newer variants of PFIC, known as PFIC 4, 5, and MYO5B related (sometimes known as PFIC 6). PFIC 4 is caused by the loss of function of tight junction protein 2 (TJP2) and PFIC 5 is due to NR1H4 mutation causing Farnesoid X receptor deficiency. MYO5B gene mutation causes microvillous inclusion disease (MVID) and is also associated with isolated cholestasis. Children with TJP2 related cholestasis (PFIC-4) have a variable spectrum of presentation. Some have a self-limiting disease, while others have progressive liver disease with an increased risk of hepatocellular carcinoma. Hence, frequent surveillance for hepatocellular carcinoma is recommended from infancy. PFIC-5 patients usually have rapidly progressive liver disease with early onset coagulopathy, high alpha-fetoprotein and ultimately require a liver transplant. Subjects with MYO5 B-related disease can present with isolated cholestasis or cholestasis with intractable diarrhea (MVID). These children are at risk of worsening cholestasis post intestinal transplant (IT) for MVID, hence combined intestinal and liver transplant or IT with biliary diversion is preferred. Immunohistochemistry can differentiate most of the variants of PFIC but confirmation requires genetic analysis.

Key Words: Progressive familial intrahepatic cholestasis; Tight junction protein; Hepatocellular carcinoma; Biliary diversion; Microvillous inclusion disease

©The Author(s) 2021. Published by Baishideng Publishing Group Inc. All rights reserved.

Open-Access: This article is an open-access article that was selected by an in-house editor and fully peer-reviewed by external reviewers. It is distributed in accordance with the Creative Commons Attribution NonCommercial (CC BY-NC 4.0) license, which permits others to distribute, remix, adapt, build upon this work non-commercially, and license their derivative works on different terms, provided the original work is properly cited and the use is non-commercial. See: <http://creativecommons.org/licenses/by-nc/4.0/>

Received: May 22, 2021

Peer-review started: May 22, 2021

First decision: July 27, 2021

Revised: August 19, 2021

Accepted: November 4, 2021

Article in press: November 4, 2021

Published online: December 27, 2021

P-Reviewer: Andreone P

S-Editor: Gao CC

L-Editor: A

P-Editor: Gao CC



Core Tip: Progressive familial intrahepatic cholestasis (PFIC) manifests with a varying spectrum of clinical features, with some variants progressing rapidly into end stage liver disease. Recently, newer variants of PFIC have been described including PFIC 4 due to tight junction protein 2 (TJP2) mutation, PFIC 5 due to NR1H4 mutation and MYO5B related cholestasis also sometimes known as PFIC 6. TJP2 related PFIC also has a risk of hepatocellular carcinoma. This article describes the pathogenesis and clinical features of the newer variants of PFIC.

Citation: Vinayagamoorthy V, Srivastava A, Sarma MS. Newer variants of progressive familial intrahepatic cholestasis. *World J Hepatol* 2021; 13(12): 2024-2038

URL: <https://www.wjgnet.com/1948-5182/full/v13/i12/2024.htm>

DOI: <https://dx.doi.org/10.4254/wjh.v13.i12.2024>

INTRODUCTION

Progressive familial intrahepatic cholestasis (PFIC) is a heterogeneous group of intrahepatic cholestatic disorders caused by a defect in bile transport and secretion. It manifests in infancy or childhood and can progress to end-stage liver disease[1-3]. Genetically confirmed PFIC accounts for 12%-13% of cholestatic disorders in infants and children[4]. Disease variants are classified based on the specific bile transporter defects and all of them have an autosomal recessive inheritance. The three most prominent varieties are familial intrahepatic cholestasis-1, 2 and 3, which are caused by mutations in ATP8B1 gene encoding FIC1, ABCB11 gene encoding bile salt export pump, and ABCB4 gene encoding multidrug resistance protein-3 respectively (Figure 1). Nearly two-thirds of subjects with normal gamma-glutamyl transpeptidase (GGT) cholestasis (normally associated with PFIC except PFIC 3) do not have any mutations identified in ATP8B1 or ABCB11 genes[3]. Detailed mutational analysis in patients with this phenotype has led to the identification of 3 more conditions, often known as PFIC 4, 5, and 6. PFIC 4 is caused by the loss of function of tight junction protein 2 (TJP2)[5], and PFIC 5 is due to NR1H4 mutation causing farnesoid X receptor (FXR) deficiency[6,7]. MYO5B mutation, known to cause microvillous inclusion disease (MVID), is also reported to cause isolated cholestasis and is sometimes known as PFIC 6 though it is not yet recognized by the Online Mendelian Inheritance in Man [8]. The exact incidence of newer variants of PFIC is not known due to the limited number of studies, which are mostly case reports or small case series. Based on the available literature, this review attempts to sensitize physicians to the disease.

GENETICS AND PATHOGENESIS

PFIC 4

TJP2 gene, located in chromosome 9q21 was first discovered in 1991 by Gumbiner *et al* [9]. It encodes a protein called tight junction protein 2 or zona occludens-2. Though named as tight junction protein, it is not present in the tight junction. Instead, TJP2 is a cytosolic protein, involved in maintaining cell-to-cell adhesion by linking the transmembrane tight junction proteins like claudin with the actin cytoskeleton. There are two types of claudin *i.e.*, claudin-1 (CLDN1) and claudin-2 (CLDN2), both of which are localized to the bile canalicular membrane[10]. In TJP2 mutation, CLDN1 fails to localize to the bile canalicular membrane (Figure 2). This results in reduced integrity of the canalicular membrane and reflux of toxic bile acids through the paracellular spaces into hepatocytes, causing hepatocyte damage and cholestasis[11]. TJP2 has a widespread expression, including the respiratory and central nervous systems. This may explain the systemic features reported in a few cases[11]. The detergent action of the bile potentiates damage in the liver, which explains the predominant hepatic manifestations in this condition.

PFIC 5

PFIC 5 is related to a deficiency of the FXR due to loss of function mutation in the NR1H4 gene located in chromosome 12q23. NR1H4 related PFIC 5 is a less commonly

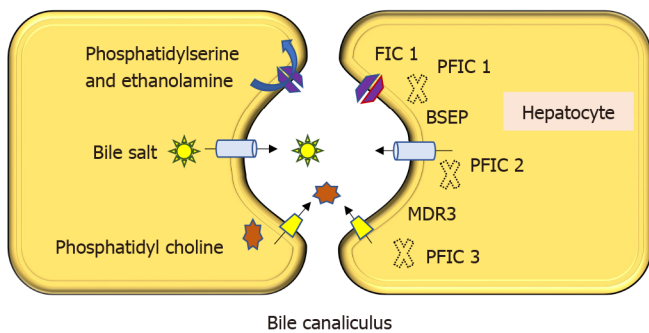


Figure 1 Pathogenesis of progressive familial intrahepatic cholestasis 1, 2 and 3. Familial intrahepatic cholestasis protein 1 is a flippase that helps in movement of phosphatidylserine and phosphatidylethanolamine from the outer to inner leaflet of the plasma membrane of hepatocyte; Bile salt exporter pump exports bile acid from hepatocytes to bile canaliculus; Multidrug resistance protein 3 is a floppase involved in transporting phosphatidylcholine into bile canaliculus. PFIC: Progressive familial intrahepatic cholestasis; FIC1: Familial intrahepatic cholestasis protein 1; BSEP: Bile salt exporter pump; MDR3: Multidrug resistance protein 3.

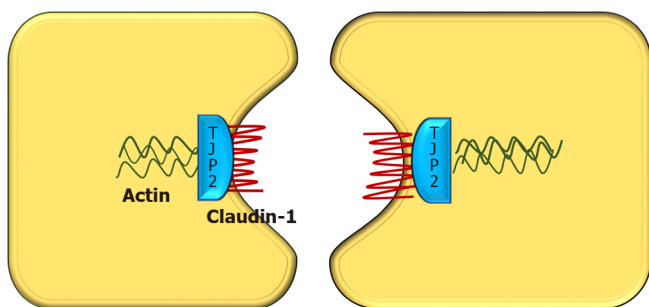


Figure 2 Diagrammatic representation of interaction between various tight junction proteins in hepatocytes. Claudin, tight junction proteins (TJP2), and actin form intercellular cytoskeletal support. Tight junctions prevent mixing of bile and blood. Absence of TJP2 causes a failure of claudin-1 localization at the canalicular membrane, leading to loss of compactness of the tight junctions and leakage of the bile through the paracellular space. TJP2: Tight junction proteins 2.

reported variant, with < 10 cases reported by 2020. FXR, a protein translated from the NR1H4 gene was first described in 1995 by Forman *et al*[12]. It belongs to a nuclear receptor group activated by farnesyl, an intermediate metabolite of the mevalonic acid synthesis pathway. FXR is the master regulator of cholesterol, bile acid, triglyceride and various sterol ring-containing compounds (Vitamin D, carotenoids, retinoids, *etc.*) [13]. In the liver, the FXR acts as a nuclear bile acid-sensing receptor involved in the expression of bile salt export protein (BSEP) and sometimes MDR3[6,14]. Apart from the liver, FXR is also expressed in the small intestine. Whenever bile acid levels are elevated in the ileal enterocytes, FXR is activated to induce the synthesis of fibroblast growth factor 19 (FGF19). FGF 19 is then transported *via* enterohepatic recirculation to the liver, where it binds to the fibroblast growth factor receptor 4/ β -Klotho complex, and causes inhibition of bile acid synthesis by repressing CYP7A1. Elevated bile acid inside hepatocytes also activates FXR which induces ABCB11 gene transcription, BSEP synthesis, and bile acid export from the liver. Hence, the NR1H4 mutation causes loss of BSEP expression, leading to the accumulation of toxic bile and hepatocellular damage (Figure 3). FXR is also involved in the regulation of coagulation factor synthesis by transactivating fibrinogen and kininogen genes. Thus, the FXR mutation leads to the development of vitamin K independent, early-onset coagulopathy, well before liver failure sets in[6].

Homozygous or compound heterozygous loss of function mutations (c.526C>T and c.419 420insAAA/intragenic 31.7-kb deletion, respectively) have been described[7]. In one woman with intrahepatic cholestasis of pregnancy, NR1H4 heterozygous variant (c.-1G>T) was found to be associated with cholestasis[15].

PFIC 6

The MYO5B gene located in chromosome 18q21.1 encodes an actin-associated molecular motor protein called MYO5B. MYO5B and RAS-related GTP-binding protein 11A (RAB11A) is essential for the epithelial cell polarization in multiple tissues (Figure 4). In hepatocytes, it is important for the localization of ATP-dependent bile canalicular transporters like BSEP to the canalicular membrane, and in the intestine, it

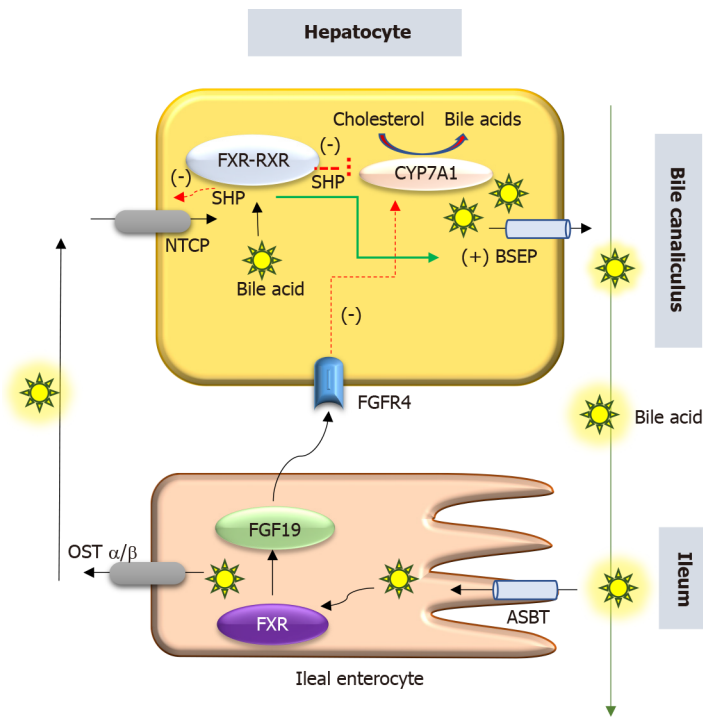


Figure 3 Schematic representation of role of farnesoid X receptor in hepatocyte. Bile acids are transported into the hepatocyte by NTCP. De novo synthesis of bile acids from cholesterol is mediated by CYP7A1. Bile acids and farnesoid X receptor (FXR) interact and enter the nucleus to promote expression of bile salt export protein and short heterodimer partner (SHP). SHP suppresses expression of NTCP and CYP7A1. FXR also induces FGF-19 in ileal enterocytes which inhibits CYP7A1 via FGFR4. ASBT: Apical sodium bile transporter, BSEP: Bile salt export pump; FGF-19: Fibroblast growth factor-19; FGFR-4: Fibroblast growth factor receptor-4; FXR: Farnesoid X receptor; NTCP: Na⁺-taurocholate co-transporting polypeptide; OST α/β : Organic solute transporter; RXR: Retinoid X receptor; SHP: Short heterodimer partner.

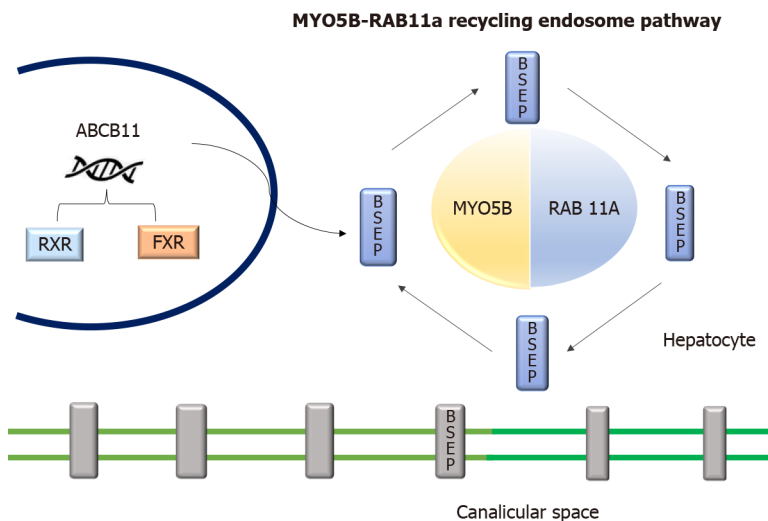


Figure 4 Diagrammatic representation of role of MYO5B and RAS-related GTP-binding protein 11A interaction and endosome recycling pathway and bile salt export pump expression. MYO5B and RAS-related GTP-binding protein 11A (RAB11A) interaction is essential for epithelial cell polarization and BSEP localization to the canalicular membrane. Diminished MYO5B/RAB11A recycling endosome pathway leads to disruption of bile salt export pump localization. ABCB11: ATP Binding Cassette Subfamily B Member 11; BSEP: Bile salt export pump; FXR: Farnesoid X receptor; RAB11A: RAS-related GTP-binding protein 11A; RXR: Retinoid X receptor.

is important for maintaining enterocyte polarity[16]. MYO5B mutations disrupt the MYO5B/RAB11A recycling endosome pathway leading to defective targeting of BSEP [17]. MYO5B gene mutations can result in cholestatic liver disease with or without associated MVID, which presents as intractable diarrhea in infancy[8,18]. Staining of BSEP and MDR3 by immunohistochemistry in these patients is sub-canalicular in the location instead of the regular localization in the canalicular membrane[8].

There is a suggestion that the type of MYO5B mutation affects the clinical presentation[18,19]. Less severe mutations have a loss of canalicular transporter function in hepatocytes without any loss of enterocytes functionality. These patients present with isolated cholestasis. In severe variants of mutations, there is a dysfunction of both bile canalicular transporter and enterocyte polarization. However, a severe loss of enterocyte function leads to a reduced bile acid absorption in the intestine and in turn decreased bile acid load to the hepatocyte, potentially preventing cholestatic manifestations[18]. Patients with MVID more often have biallelic severe mutations in MYO5B. Biallelic mutations in the MYO5B-RAB11A interaction domain are more in MVID than those with isolated cholestasis[20]. Thus, isolated cholestasis appears to reflect relatively mild MYO5B functional deficiency, whereas severe mutations in MYO5B primarily cause MVID[20].

CLINICAL PRESENTATION

Intrahepatic cholestasis is the hallmark of how these 3 genetic conditions present. Most often, patients present with variable combinations of pruritus, jaundice, pale stools, and failure to thrive. The published literature on each of these three entities (TJP2, FXR, and MYO5B) is limited and has been summarized in [Tables 1-3](#) respectively.

PFIC 4

A varying spectrum of clinical presentation, ranging from mild anicteric illness, recurrent jaundice to severe progressive liver disease has been described[5,11]. Incomplete penetrant, homozygous, missense mutations affecting both isoforms of TJP2 have been shown to cause familial hypercholanemia in the Amish population which manifests as a mild anicteric disease with pruritus and steatorrhea. In this condition, the binding of TJP2 to claudins is impaired[21]. Milder mutations of TJP2 are also known to be associated with intrahepatic cholestasis of pregnancy[15].

In the 12 cases reported by Sambrotta *et al*[5], 9 (75%) required liver transplantation (LT) while 2 had portal hypertension. In contrast, none of the 7 cases reported by Zhang *et al*[22] required LT, and cholestasis responded to medical therapy in a majority. Zhang *et al*[22] also showed that truncating or canonical splice-site biallelic TJP2 mutations caused a more severe presentation due to a complete loss of protein expression. In their study, 3 children with severe mutations had growth failure. While the other 3 cases with missense variants had normal growth and sustained response in pruritus with ursodeoxycholic acid (UDCA) and cholestyramine.

All homozygous mutations are predicted to abolish protein translation and a complete loss of function[5]. Mutations involving missense and frame deletion lead to less severe clinical disease due to residual TJP2 protein expression[22]. This suggests the presence of a genotype-phenotype correlation based on the amount of remnant functional TJP2 activity.

There is a higher risk of developing hepatocellular carcinoma (HCC) in these cases, similar to that seen in PFIC 2 patients. Subjects can either present with a space-occupying lesion (SOL) in the liver or are detected to have HCC after LT on histology of the explanted liver[23,24]. This predisposition to HCC highlights the importance of close follow-up and regular monitoring.

PFIC 5

FXR is the master player of bile acid regulation and plays an important role in reducing bile acid-induced hepatotoxicity. Rapidly progressive liver disease and early onset vitamin K independent coagulopathy are the main features of this condition. The details of the 8 published cases are given in [Table 2](#). A majority of patients presented early in the first 3 mo of life and progressed rapidly to liver failure. Patients have markedly increased alpha-fetoprotein and deranged international normalized ratio. Without a liver transplant, 5/8 died in infancy itself. Three cases survived post-liver transplant, of which 2 were found to have liver function abnormality with graft steatosis in the follow-up[6]. This post-transplant hepatic damage may be attributed to the altered enterohepatic circulation and FXR signalling in these cases. The absence of FXR in the intestine leads to low FGF 19 levels and this allows for continued and increased synthesis of bile acids by the liver[25]. Intrahepatic cholestasis of pregnancy has been reported and attributed to the downregulation of BSEP in this condition[26].

Table 1 Clinical characteristics and outcome in patients with *TJP2* mutation

Ref.	n	Age at onset of symptoms	Symptoms	Other symptoms	Treatment	Liver transplant	Outcome
Sambrotta <i>et al</i> [5]	12	1 wk-3 mo	NC-12/12	Chronic respiratory disease-1, recurrent unexplained hematoma-1	UDCA, PEBD-2	9/12 cases at the age of 1.5-10 yr	Post-transplant-9 (doing well, no disease recurrence); Stable liver disease with PHT-2; Mortality-1 at 13 mo age
Zhang <i>et al</i> [22]	7 (M = 6, F = 1)	3 d-2 mo	NC-6/7, pruritus at 7 mo-1/7	Gallstones 2/7	Response to UDCA, cholestyramine	None	Resolved cholestasis (<i>n</i> = 6) over 7-26 mo; Persisting icterus-1
Ge <i>et al</i> [46]	1 (F)	6mo	Jaundice, pruritus, FTT	-	Responded to medical treatment	None	Resolved cholestasis
Mirza <i>et al</i> [47]	1 (M)	4 yr	Jaundice, pruritus	-	Medical treatment	None	Cirrhosis, PHT with variceal bleed at 15 yr
Wei <i>et al</i> [24]	Index case (M) with multiple affected family members ¹	19 yr	Cirrhosis, PHT with variceal bleed, HCC at 22 yr	-	Medical treatment including EVL	23 yr	Well in post-transplant period

¹Variable severity of liver disease: Cholestatic liver disease requiring transplant, cholestatic liver disease and intrahepatic cholestasis of pregnancy in other affected members.

EVL: Endoscopic variceal ligation; F: Female; FTT: Failure to thrive; HCC: Hepatocellular carcinoma; M: Male; NC: Neonatal cholestasis; PEBD: Partial external biliary diversion; PHT: Portal hypertension; UDCA: Ursodeoxycholic acid.

PFIC associated with *MYO5B* defects

Patients with *MYO5B* mutations can present with isolated cholestasis, isolated MVID, or both MVID and cholestasis. Typically, the child presents with jaundice, pruritus, and hepatomegaly. In patients with MVID and cholestasis, the onset of cholestasis may be pre or post-small bowel transplant. The exact explanation as to why some MVID cases develop cholestasis while others do not is unclear but it may be related to the severity of mutation (*vide supra*). The summary of the clinical presentation of 29 cases with *MYO5B* mutation, as reported in 4 papers, is shown in Table 3. Even in siblings with the same mutation and presentation with cholestasis, the disease severity may vary[20]. This suggests the possible role of modifier genes or environmental factors. Among Han Chinese children, defects in *MYO5B* accounted for approximately 20% of cases of idiopathic low-normal GGT intrahepatic cholestasis[20].

INVESTIGATIONS AND THE APPROACH TO DIAGNOSIS

The main steps for making a diagnosis of PFIC and determining the specific type in any given child with cholestasis are as follows: Step 1: Detailed history and physical examination including family history, consanguinity, extraintestinal symptoms, growth, nutritional deficiencies, and features of advanced liver disease; Step 2:

Table 2 Clinical characteristics and outcome in patients with NR1H4 mutation

Ref.		Sex	Age at onset of symptoms	Age at initial evaluation	Symptoms	Lab parameters			Histology/IHC	Age at LTx	Outcome
						GGT	INR (at onset)	AFP ng/mL			
Gomez-Ospina <i>et al</i> [6], 2016	All cases had homozygous mutations										
	¹ Patient 1	F	2 wk	20 mo	J, FTT	53	2	716	Cirrhosis	22 mo	10 yr ⁴
	¹ Patient 2	M	2 wk	7 wk	J, FTT	45	2	146000	Fibrosis	4.4 mo	15 mo ⁴
	² Patient 3	F	6 wk	6 wk	J	59	1.4	13900	Fibrosis	ND	Died 8 mo
	² Patient 4	M	Birth	Birth	J, ascites, pleural effusion, ICB		-	-	Fibrosis	ND	Died at 4 wk
Himes <i>et al</i> [7], 2020	Patient 5 and 7 had homozygous mutations										
	Patient 5	M	16 mo	17 mo	J, ascites	81	1.9	9610	Cirrhosis	20 mo	Alive at 8 yr of age, no graft steatosis
	³ Patient 6	M	3 wk	1 mo	J, FTT, hydrothorax	-	-	-	-	ND	Died at 8 mo, liver failure
	³ Patient 7	F	1 wk	4 mo	J, FTT, hydrothorax	-	-	> 100000	-	ND	Died at 7 mo, liver failure
Chen <i>et al</i> [27], 2019	Patient had compound heterozygote mutation										
	Patient 8		N/A	3 mo	J, splenomegaly		3.0	> 80000	-	ND	Died at 5 mo

¹Family 1.²Family 2.³Family 3.⁴Post transplant both cases have hepatic steatosis and liver function test abnormalities.

AFP: Alpha fetoprotein; BSEP: Bile salt export pump; F: Female; FTT: Failure to thrive; FXR: Farnesoid X receptor; GGT: Gamma-glutamyltransferase; ICB: Intracranial bleed; IHC: Immunohistochemistry; INR: International normalized ratio; J: Jaundice; LTx: Liver transplantation; MDR3: Multidrug resistance protein 3; M: Male; N/A: Not applicable; ND: Not done.

Complete liver function test with GGT. Low-normal GGT is seen in ATP8B1, ABCB11, TJP2, NR1H4, and MYO5B disease. Early-onset of vitamin K unresponsive coagulopathy is a feature of NR1H4 disease; Step 3: Radiologic imaging. Ultrasonography (USG) of the abdomen is useful to exclude structural causes of neonatal cholestasis, like biliary atresia or choledochal cyst. The presence of biliary radicle dilatation may suggest sclerosing cholangitis, which needs to be confirmed by MRCP. USG is also useful to document features of advanced liver disease like ascites, splenomegaly, dilated portal vein, and collaterals. Gall stones have been reported in TJP2 disease, as also in PFIC 2 and 3. The presence of hepatic SOL raises suspicion of HCC and needs evaluation by triple-phase CT and alpha-fetoprotein. Early HCC is a feature of TJP2 disease; Step 4: Liver histology including immunohistochemistry and next-generation sequencing (NGS). Liver biopsy shows canalicular cholestasis in all three

Table 3 MYO5B mutation clinical characteristics and outcome

Ref.		Age at onset of symptom	Age at initial evaluation	Symptoms	Treatment	Lab parameters			Outcome
						GGT (IU/L)	AST (IU/L)	ALT (IU/L)	
Qiu <i>et al</i> [20], 2017	n = 10, M-8, F-2, 4 had affected siblings	2 d-19 mo	1 mo-10 yr	Jaundice and pruritus; No diarrhea	UDCA, cholestyramine	9-99	24-255	41-432	Recurrent-3, persistent-2, transient cholestasis-2, lost to follow-3, listed for LT -1 (died)
Cockar <i>et al</i> [19], 2020	n = 6, M-3, F-3	-	6 mo-15 yr	Pruritus with pale stools-6, Jaundice-3; FTT-3; Diarrhea-2, (intractable and settled at 3 yr and 7 yr), gallstone-1	Antipruritic medications-6; PIBD-1; PIBD followed by PEBD-1; ENBD followed by PEBD-1	10-22	-	15-177	1-LT for poor QOL and pruritus; 5-Partial response with mild pruritus while on medications
Gonzales <i>et al</i> [8], 2017	n = 5, M-4, F-1	-	7-15 mo	Pruritus-5; Jaundice-5; Pale stools-5 hepatomegaly-5; Language delay-1 episodes of severe diarrhea before 3 yr of age-1	UDCA and rifampicin-5; PEBD-1	7-11	31-170	57-207	Followed till 3.5-13.5 yr of age; Fluctuating cholestasis-4; Cholestasis resolved after 1 mo of PEBD, well till 7 yr of age
Girard <i>et al</i> [17], 2014	n = 8/28 MVID, patients with cholestasis M-5, F-3	3-60 mo		Jaundice, pruritus, hepatomegaly-8; Pre Int Tx-5, post Int Tx-3	Antipruritic medications-8; PIBD followed by PEBD-1; PIBD-1; PEBD-1; Combined liver and Int Tx-1	8-42	51-124	52-121	Follow up till 2.8-14 yr of age, remission-6, partial remission-2; Removal of small bowel graft due to acute rejection in 2 cases improved cholestasis

AST: Aspartate aminotransferase; ALT: Alanine aminotransferase; ENBD: Endonasal biliary drainage; F: Female; FTT: Failure to thrive; GGT: Gamma glutamyl transferase; Int Tx: Intestinal transplant; LT: Liver transplantation; M: Male; MVID: Microvillus inclusion disease; PEBD: Partial external biliary drainage; PIBD: Partial internal biliary drainage; QOL: Quality of life; UDCA: Ursodeoxycholic acid.

types (TJP2, NR1H4, and MYO5B defects) along with a variable degree of fibrosis and giant cell transformation[6]. On electron microscopy, the tight junctions appear elongated and lack the densest part of the zona occludens in PFIC 4[6]. In subjects with MYO5B and liver disease, electron microscopy will show dilatation of the bile canalicular lumen, canalicular thickening, and disappearance of the microvilli apart from cholestasis[17]. Inclusion bodies are not seen in the hepatocytes on transmission electron microscopy, in contrast to the findings in intestines in MVID[17]. The comparative features at histology in these three types are given in Table 4.

A complete panel of immunohistochemistry including BSEP, MDR3, TJP2, FXR, MYO5B, and Claudin1 can help in identifying the subtype of PFIC as shown in Table 4. However, simultaneous NGS for multiple genes (cholestasis panel) is a rapid and affordable way of confirming the molecular diagnosis[27]. A recent study has shown that a molecular genetic diagnosis can be made in a quarter of cases with neonatal cholestasis using NGS[28]. A study with a 66-gene cholestasis panel in 2171 cholestatic children and young adults, had a diagnostic yield of 12% and turnaround time of only 21 d[29]. The simultaneous testing for multiple genes helps in not only confirming the diagnosis but also in excluding other conditions. NGS is becoming the test of choice in the primary evaluation of patients with PFIC phenotype as it is non-invasive in comparison to liver biopsy and immunohistochemistry. For cases in which

Table 4 Comparison of clinical features, laboratory profile and outcome in progressive familial intrahepatic cholestasis 4, 5 and 6

	PFIC 4	PFIC 5	PFIC 6
Gene mutation	TJP2/Zona occludens-2 located in 9q21.11	NR1H4/FXR-located in 12q23.1	MYO5B located in 18q21.1
Clinical features			
Clinical features	Cholestatic jaundice with pruritus	Rapidly progressive neonatal-onset cholestasis with uncorrectable coagulopathy	Cholestasis with pruritus, with/without transient, recurrent or progressive diarrhea (association with MVID)
Extrahepatic features	Neurological and respiratory symptoms	-	-
ICP	Yes	Yes (uncommon)	No
Laboratory parameters			
AST/ALT	Elevated	Moderate elevation	Mild to moderate elevation
GGT	Normal or mild elevation	Normal	Normal
Coagulopathy	Late-onset	Early-onset	Late-onset
Alpha fetoprotein	Normal, elevated in cases with HCC	Elevated	Normal
S. Bile acids	Elevated	Elevated	Elevated
Histopathology			
Canalicular cholestasis	Yes	Yes	Yes
Portal/lobular fibrosis	Yes	Yes	Yes
Giant-cell transformation	Yes	Diffuse	Sparse
Ductular reaction	No	Yes	Yes
Hepatocyte necrosis	Yes	-	-
Cirrhosis	Yes	Yes	Less common
Immunohistochemistry			
BSEP	Present	Absent BSEP staining on bile canaliculus	Abnormally thick, irregular and granular positivity that overflows into subcanalicular area
MDR3	Present	Present	Thickened canalicular staining granular and patchy pattern overflows into subcanalicular area
TJP2	Absent expression in canalicular membrane	Present	Present
Claudin1	Absent or reduced staining on bile canaliculi	Present	Present
FXR	Normal	Absent staining on bile canaliculus	Normal
MYO5B/RAB11	Normal	Normal	Intense, granular staining pattern in hepatocyte cytoplasm, and weak/loss of canalicular expression
Progression	Rapid	Very rapid	Slow
Complications	Hepatocellular carcinoma	Post-transplant graft steatosis similar to PFIC1	Worsening of cholestasis post intestinal transplant
Treatment			
Medical management	UDCA, Rifampicin	Minimal role	UDCA, rifampin, cholestyramine
Biliary diversion	PEBD some role	Not tried	Cholestasis subsides after BD in MVID patients with cholestasis
Liver transplant	Yes	Yes	Yes. Combined liver intestinal transplant in children with MVID and ongoing cholestasis

ALT: Alanine aminotransferase; ASBT: Apical sodium-dependent bile acid transporter; AST: Aspartate aminotransferase; BD: Biliary diversion; BSEP: Bile salt export pump; FXR: Farnesoid X receptor; GGT: Gamma-glutamyl transferase; HCC: Hepatocellular carcinoma; MDR3: Multidrug resistance class 3 glyco-protein; ICP: Intrahepatic cholestasis of pregnancy; MVID: Microvillus inclusion disease; MYO5B: Myosin-5b; NBD: Nasobiliary drainage; PEBD: Partial external biliary drainage; PFIC1: Progressive familial intrahepatic cholestasis-1; RAB11: RAS-related GTP-binding protein-11; TJP2: Tight junction protein-2; UDCA: Ursodeoxycholic acid.

the panel yields a negative result and the index of suspicion is high, further testing by the whole exome (WES) or whole-genome (WGS) sequencing may be done. The presence of variables of unknown significance and monoallelic pathogenic/likely pathogenic variants in a significant proportion of cases highlights the complexity of analysis and the need for expertise for proper interpretation. Also, the ongoing discovery of new genes requires expansion of the genetic testing panel from time to time.

DIFFERENTIAL DIAGNOSIS

The main differentials to be considered in a patient with intrahepatic cholestasis with low-normal GGT (< 100 U/L) include bile acid synthetic defect (BASD), arthrogryposis-renal dysfunction-cholestasis (ARC) syndrome, and USP53 related cholestasis, apart from the different types of PFIC (1, 2, 4, 5 and MYO5B associated). Type 3 PFIC (ABCB4) has raised GGT[1,30]. The serum bile acids are raised in PFIC and ARC syndrome, while they are low in the BASD. These entities can be differentiated by their distinct clinical presentation and liver histopathology with immunohistochemistry. However, the confirmation of diagnoses is best done by genetic analysis.

Bile acid synthetic defects

In bile acid synthetic defects (BASD) there is an accumulation of toxic bile acid intermediates in the hepatocytes due to deficiency of various enzymes involved in bile acid synthesis. Patients present with cholestatic jaundice, overt steatorrhea and florid manifestations of fat-soluble vitamin deficiencies like rickets. Pruritus is distinctly uncommon. Sometimes they may also present with neonatal liver failure, and cholestatic liver disease along with neurological manifestations like hypotonia, seizures[31]. BASD is diagnosed with fast-atom bombardment mass spectrometry of urine, which shows the accumulation of the distinct bile acid intermediaries due to a block in the bile acid synthesis pathway. Genetic analysis is confirmatory. Supplementation of cholic acid (CA) and chenodeoxycholic acid (CDCA) along with fat-soluble vitamins is the mainstay of therapy[32].

ARC syndrome

ARC syndrome (MIM 208085) is a rare multisystem disorder with autosomal recessive inheritance. It includes a triad of arthrogryposis, renal tubular acidosis, and neonatal cholestatic jaundice. Some patients may have accompanying features like ichthyosis (approximately 50%), platelet anomalies (approximately 25%), agenesis of the corpus callosum ($> 20\%$), congenital cardiovascular anomalies (approximately 10%), and deafness. The clinical features are very useful to suspect the diagnosis, which is confirmed by a demonstration of mutations in the VPS33B or VIPAR gene. Histopathology shows bile duct paucity, giant cell transformation, bile plugs, and portal fibrosis. Caution is required before proceeding with a renal or liver biopsy due to the increased risk of a life-threatening bleed. Treatment is supportive and includes management of joint contractures, renal tubular acidosis, and cholestasis (UDCA, fat-soluble vitamins)[33].

USP53 related cholestasis

USP53 encodes an enzyme known as ubiquitin carboxyl-terminal hydrolase 53, which belongs to the de-ubiquitinating enzyme family and helps in maintaining cell integrity by interacting with TJP2 in hepatocytes. Whole-exome sequencing in 69 Han Chinese infants, with low GGT cholestasis without any pathological variants in ATP8B1, ABCB11, NR1H4, TJP2, and MYO5B genes, showed the presence of biallelic USP53 mutations (homozygous or compound heterozygous) in 7 patients[34]. All these children had cholestatic jaundice in infancy and responded to medications (UDCA, cholestyramine). Liver biopsy showed varying levels of lobular disarray and hepatocellular and canalicular cholestasis, rosetting, portal tract fibrosis, ductular prolif-

eration, and giant-cell transformation. Ultrastructural examination in 2 cases revealed abnormality of tight junction complexes and expression of TJP2 and CLDN1 were reduced. Two children also had sensorineural hearing loss. In another report on the novel USP53 mutation, three members from the same family (2 sisters and a cousin) had low-GGT cholestasis, pruritus, elevated transaminases, very high alkaline phosphatase, and sensorineural hearing loss ($n = 2$). One of them required LT because of intractable pruritus[35].

Alagille syndrome

Alagille syndrome is also known as arteriohepatic dysplasia or syndromic paucity of interlobular bile ducts. This disorder is autosomal dominant with variable phenotypic penetrance. Alagille syndrome is one of the commonest causes of genetic cholestasis [36]. The defining feature is cholestasis with multisystemic involvement. Features include neonatal cholestasis in 95%, extrahepatic biliary hypoplasia, pruritus, xanthoma and associated facial dysmorphism. Structural cardiac defects such as peripheral pulmonary stenosis and septal defects are seen in 88%. Vertebral anomalies, ocular abnormalities most commonly posterior embryotoxon, renal dysplasia, vascular anomalies like Moyamoya disease, carotid and subclavian artery aneurysm are the other systemic features. Genetic analysis reveals *JAG1* mutation in the majority (approximately 90%) and *NOTCH2* mutation in minority[35].

Citrin deficiency

It is caused due to SLC25A13 (Solute Carrier family 25) gene mutation located in chromosome 7q21.3. The disease spectrum includes neonatal intrahepatic cholestasis, failure to thrive and dyslipidemia, and adult-onset type II citrullinemia. Chubby cheeks in infancy are a hallmark finding. These children also have a characteristic history of aversion to carbohydrates and a dietary preference towards a protein and lipid-rich diet[37].

Neonatal ichthyosis-sclerosing cholangitis syndrome

Neonatal Ichthyosis Sclerosing cholangitis is a rare cause of neonatal cholestasis with an autosomal recessive inheritance pattern. It is caused due to a mutation in the CLDN1 gene which encodes the CLDN1 protein located at the tight junction. This condition presents with neonatal cholestasis, cicatricial alopecia, ichthyosis and pruritus. Magnetic resonance cholangiopancreatography will show features of sclerosing cholangitis[38].

Other PFIC subtypes

Amongst the different PFIC subtypes, PFIC 1, 2, 4, 5 and 6 have low-normal GGT cholestasis. The presence of diarrhea is a feature of PFIC 1 and MYO5B disease. While neurological symptoms may be seen in ARC syndrome and sometimes in patients with MVID, a higher risk of HCC is a feature of TJP2 and BSEP deficiency. Table 4 gives the comparison of the clinical features and investigations in TJP2, FXR, and MYO5B defects. A detailed description and comparison of PFIC 1 and 2 are given elsewhere [39].

TREATMENT

Medical management

The main components include counselling of parents in detail, providing adequate nutrition, correcting vitamin deficiencies, controlling pruritus, managing complications like ascites, variceal bleeding *etc.*, growth monitoring, and vaccination[40].

Nutritional therapy: A diet that provides adequate calories (125%-140% of RDA) and protein (2-3 g/kg) with supplementation of medium-chain triglyceride and fat-soluble vitamins is recommended[41]. The doses of vitamin supplementation may need modification based on clinical signs and symptoms of vitamin deficiency and serum level monitoring (if available). Anemia, if present, needs to be corrected. Age-appropriate immunization including vaccination against hepatotropic viruses (hepatitis A and hepatitis B) is essential.

Management of pruritus: Pruritus is one of the most disabling symptoms in these children. Apart from skincare, medications such as UDCA, cholestyramine, rifampicin, naltrexone, and sertraline are used for controlling pruritus. These aspects have been

addressed in detail elsewhere[42]. There are no published reports on the use of FXR agonists like obeticholic acid, or apical sodium-bile acid transporter inhibitors like maralixibat in PFIC 4, 5 and MYO5B related diseases. Long-term follow-up includes growth monitoring, monitoring for nutritional deficiencies, and HCC surveillance, especially in TJP2 related cholestasis.

Biliary diversion

Biliary diversion (BD) takes away bile from the intestine, thereby reducing the reabsorption of bile acids through the enterohepatic circulation[43]. It has an important role in the alleviation of pruritus that is refractory to medical management in PFIC 1 and 2[44]. The role of BD is not well known in the newer variants of PFIC. BD has been tried in MVID patients who developed worsened cholestasis post intestinal transplant and was found to be helpful[17]. In MYO5B mutation, the ongoing cholestatic liver disease worsens after the intestinal transplant, leading to progressive liver fibrosis. Hence combined liver and intestinal transplantation are preferred. But in cases of isolated intestinal transplants, gallbladders should be preserved so that in case the cholestasis worsens, partial external biliary drainage can be attempted. The ileal bypass should be avoided as it removes a part of the transplanted bowel and doesn't result in long-term remission of cholestasis[16].

Liver transplant

LT is to be considered in children with decompensated chronic liver disease, growth failure (not amenable to dietary modification), refractory pruritus, or associated complications like hepato-pulmonary syndrome. In NR1H4 related PFIC, an early transplant may be required due to progressive liver disease with decompensation. Post liver transplant graft steatosis may develop in patients with NR1H4 mutation-associated cholestasis[6].

Genetic counseling

Once a child is confirmed to have PFIC, parents need to be counselled about the nature of the disease and the autosomal recessive pattern of inheritance. A geneticist should be involved in counselling about future pregnancies and testing during pregnancy[45].

CONCLUSION

TJP2, FXR, and MYO5B are recent additions to the three well-known types of PFIC (1, 2, and 3). This review has described the genetics, clinical profile, investigative findings, and treatments of these newer entities. There are gaps in our understanding of these conditions due to the limited literature at present. Advances in bioinformatics and techniques of next-generation gene-sequencing will help us study the genotype-phenotype correlation and synergistic effect of multiple mutations. Despite the recognition of these entities, not all cases with the PFIC phenotype have a confirmed genetic diagnosis, which indicates the presence of other causative genes that are waiting to be discovered.

REFERENCES

- 1 **Davit-Spraul A**, Gonzales E, Baussan C, Jacquemin E. Progressive familial intrahepatic cholestasis. *Orphanet J Rare Dis* 2009; **4**: 1 [PMID: [19133130](#) DOI: [10.1186/1750-1172-4-1](#)]
- 2 **Hori T**, Nguyen JH, Uemoto S. Progressive familial intrahepatic cholestasis. *Hepatobiliary Pancreat Dis Int* 2010; **9**: 570-578 [PMID: [21134824](#)]
- 3 **Jacquemin E**. Progressive familial intrahepatic cholestasis. *Clin Res Hepatol Gastroenterol* 2012; **36** Suppl 1: S26-S35 [PMID: [23141890](#) DOI: [10.1016/S2210-7401\(12\)70018-9](#)]
- 4 **Baker A**, Kerkar N, Todorova L, Kamath BM, Houwen RHJ. Systematic review of progressive familial intrahepatic cholestasis. *Clin Res Hepatol Gastroenterol* 2019; **43**: 20-36 [PMID: [30236549](#) DOI: [10.1016/j.clinre.2018.07.010](#)]
- 5 **Sambrotta M**, Strautnieks S, Papouli E, Rushton P, Clark BE, Parry DA, Logan CV, Newbury LJ, Kamath BM, Ling S, Grammatikopoulos T, Wagner BE, Magee JC, Sokol RJ, Mieli-Vergani G; University of Washington Center for Mendelian Genomics, Smith JD, Johnson CA, McClean P, Simpson MA, Knisely AS, Bull LN, Thompson RJ. Mutations in TJP2 cause progressive cholestatic liver disease. *Nat Genet* 2014; **46**: 326-328 [PMID: [24614073](#) DOI: [10.1038/ng.2918](#)]
- 6 **Gomez-Ospina N**, Potter CJ, Xiao R, Manickam K, Kim MS, Kim KH, Shneider BL, Picarsic JL,

- Jacobson TA, Zhang J, He W, Liu P, Knisely AS, Finegold MJ, Muzny DM, Boerwinkle E, Lupski JR, Plon SE, Gibbs RA, Eng CM, Yang Y, Washington GC, Porteus MH, Berquist WE, Kambham N, Singh RJ, Xia F, Enns GM, Moore DD. Mutations in the nuclear bile acid receptor FXR cause progressive familial intrahepatic cholestasis. *Nat Commun* 2016; **7**: 10713 [PMID: [26888176](#) DOI: [10.1038/ncomms10713](#)]
- 7 **Himes RW**, Mojarrad M, Eslahi A, Finegold MJ, Maroofian R, Moore DD. NR1H4-related Progressive Familial Intrahepatic Cholestasis 5: Further Evidence for Rapidly Progressive Liver Failure. *J Pediatr Gastroenterol Nutr* 2020; **70**: e111-e113 [PMID: [32443034](#) DOI: [10.1097/MPG.0000000000002670](#)]
- 8 **Gonzales E**, Taylor SA, Davit-Spraul A, Thébaud A, Thomassin N, Guettier C, Whittington PF, Jacquemin E. MYO5B mutations cause cholestasis with normal serum gamma-glutamyl transferase activity in children without microvillous inclusion disease. *Hepatology* 2017; **65**: 164-173 [PMID: [27532546](#) DOI: [10.1002/hep.28779](#)]
- 9 **Gumbiner B**, Lowenkopf T, Apatira D. Identification of a 160-kDa polypeptide that binds to the tight junction protein ZO-1. *Proc Natl Acad Sci U S A* 1991; **88**: 3460-3464 [PMID: [2014265](#) DOI: [10.1073/pnas.88.8.3460](#)]
- 10 **Furuse M**, Fujita K, Hiiragi T, Fujimoto K, Tsukita S. Claudin-1 and -2: novel integral membrane proteins localizing at tight junctions with no sequence similarity to occludin. *J Cell Biol* 1998; **141**: 1539-1550 [PMID: [9647647](#) DOI: [10.1083/jcb.141.7.1539](#)]
- 11 **Sambrotta M**, Thompson RJ. Mutations in TJP2, encoding zona occludens 2, and liver disease. *Tissue Barriers* 2015; **3**: e1026537 [PMID: [26451340](#) DOI: [10.1080/21688370.2015.1026537](#)]
- 12 **Forman BM**, Goode E, Chen J, Oro AE, Bradley DJ, Perlmann T, Noonan DJ, Burka LT, McMorris T, Lamph WW, Evans RM, Weinberger C. Identification of a nuclear receptor that is activated by farnesol metabolites. *Cell* 1995; **81**: 687-693 [PMID: [7774010](#) DOI: [10.1038/cr.2008.289](#)]
- 13 **Trauner M**, Claudel T, Fickert P, Moustafa T, Wagner M. Bile acids as regulators of hepatic lipid and glucose metabolism. *Dig Dis* 2010; **28**: 220-224 [PMID: [20460915](#) DOI: [10.1159/000282091](#)]
- 14 **Huang L**, Zhao A, Lew JL, Zhang T, Hrywna Y, Thompson JR, de Pedro N, Royo I, Blevins RA, Peláez F, Wright SD, Cui J. Farnesoid X receptor activates transcription of the phospholipid pump MDR3. *J Biol Chem* 2003; **278**: 51085-51090 [PMID: [14527955](#) DOI: [10.1074/jbc.M308321200](#)]
- 15 **Dixon PH**, Sambrotta M, Chambers J, Taylor-Harris P, Syngelaki A, Nicolaides K, Knisely AS, Thompson RJ, Williamson C. An expanded role for heterozygous mutations of ABCB4, ABCB11, ATP8B1, ABCC2 and TJP2 in intrahepatic cholestasis of pregnancy. *Sci Rep* 2017; **7**: 11823 [PMID: [28924228](#) DOI: [10.1038/s41598-017-11626-x](#)]
- 16 **Lapierre LA**, Kumar R, Hales CM, Navarre J, Bhartur SG, Burnette JO, Provance DW Jr, Mercer JA, Bähler M, Goldenring JR. Myosin vb is associated with plasma membrane recycling systems. *Mol Biol Cell* 2001; **12**: 1843-1857 [PMID: [11408590](#) DOI: [10.1091/mbc.12.6.1843](#)]
- 17 **Girard M**, Lacaille F, Verkarre V, Mategot R, Feldmann G, Grodet A, Sauvat F, Irtan S, Davit-Spraul A, Jacquemin E, Ruemmele F, Rainteau D, Goulet O, Colomb V, Chardot C, Henrion-Caude A, Debray D. MYO5B and bile salt export pump contribute to cholestatic liver disorder in microvillous inclusion disease. *Hepatology* 2014; **60**: 301-310 [PMID: [24375397](#) DOI: [10.1002/hep.26974](#)]
- 18 **Aldrian D**, Vogel GF, Frey TK, Ayyıldız Civan H, Aksu AÜ, Avitzur Y, Ramos Boluda E, Çakır M, Demir AM, Deppisch C, Duba HC, Düker G, Gerner P, Hertecant J, Hornová J, Kathemann S, Koeglmeier J, Koutroumpa A, Lanzersdorfer R, Lev-Tzion R, Lima R, Mansour S, Meissl M, Melek J, Miqdady M, Montoya JH, Posovszky C, Rachman Y, Siahianidou T, Tabbers M, Uhlig HH, Ünal S, Wirth S, Ruemmele FM, Hess MW, Huber LA, Müller T, Sturm E, Jancke AR. Congenital Diarrhea and Cholestatic Liver Disease: Phenotypic Spectrum Associated with MYO5B Mutations. *J Clin Med* 2021; **10** [PMID: [33525641](#) DOI: [10.3390/jcm10030481](#)]
- 19 **Cockar I**, Foksett P, Strautnieks S, Clinch Y, Fustok J, Rahman O, Sutton H, Mtegha M, Fessatou S, Kontaki E, Papaevangelou V, Deheragoda M, Thompson RJ, Grammatikopoulos T. Mutations in Myosin 5B in Children With Early-onset Cholestasis. *J Pediatr Gastroenterol Nutr* 2020; **71**: 184-188 [PMID: [32304554](#) DOI: [10.1097/MPG.0000000000002740](#)]
- 20 **Qiu YL**, Gong JY, Feng JY, Wang RX, Han J, Liu T, Lu Y, Li LT, Zhang MH, Sheps JA, Wang NL, Yan YY, Li JQ, Chen L, Borchers CH, Sipos B, Knisely AS, Ling V, Xing QH, Wang JS. Defects in myosin VB are associated with a spectrum of previously undiagnosed low γ -glutamyltransferase cholestasis. *Hepatology* 2017; **65**: 1655-1669 [PMID: [28027573](#) DOI: [10.1002/hep.29020](#)]
- 21 **Carlton VE**, Harris BZ, Puffenberger EG, Batta AK, Knisely AS, Robinson DL, Strauss KA, Shneider BL, Lim WA, Salen G, Morton DH, Bull LN. Complex inheritance of familial hypercholanemia with associated mutations in TJP2 and BAAT. *Nat Genet* 2003; **34**: 91-96 [PMID: [12704386](#) DOI: [10.1038/ng1147](#)]
- 22 **Zhang J**, Liu LL, Gong JY, Hao CZ, Qiu YL, Lu Y, Feng JY, Li JQ, Li ZD, Wang MX, Xing QH, Knisely AS, Wang JS. TJP2 hepatobiliary disorders: Novel variants and clinical diversity. *Hum Mutat* 2020; **41**: 502-511 [PMID: [31696999](#) DOI: [10.1002/humu.23947](#)]
- 23 **Vij M**, Shanmugam NP, Reddy MS, Sankaranarayanan S, Rela M. Paediatric hepatocellular carcinoma in tight junction protein 2 (TJP2) deficiency. *Virchows Arch* 2017; **471**: 679-683 [PMID: [28733884](#) DOI: [10.1007/s00428-017-2204-1](#)]
- 24 **Wei CS**, Becher N, Friis JB, Ott P, Vogel I, Grønbaek H. New tight junction protein 2 variant causing progressive familial intrahepatic cholestasis type 4 in adults: A case report. *World J Gastroenterol* 2020; **26**: 550-561 [PMID: [32089630](#) DOI: [10.3748/wjg.v26.i5.550](#)]

- 25 **Kliwer SA**, Mangelsdorf DJ. Bile Acids as Hormones: The FXR-FGF15/19 Pathway. *Dig Dis* 2015; **33**: 327-331 [PMID: [26045265](#) DOI: [10.1159/000371670](#)]
- 26 **Van Mil SW**, Milona A, Dixon PH, Mullenbach R, Geenes VL, Chambers J, Shevchuk V, Moore GE, Lammert F, Glantz AG, Mattsson LA, Whittaker J, Parker MG, White R, Williamson C. Functional variants of the central bile acid sensor FXR identified in intrahepatic cholestasis of pregnancy. *Gastroenterology* 2007; **133**: 507-516 [PMID: [17681172](#) DOI: [10.1053/j.gastro.2007.05.015](#)]
- 27 **Chen HL**, Li HY, Wu JF, Wu SH, Chen HL, Yang YH, Hsu YH, Liou BY, Chang MH, Ni YH. Panel-Based Next-Generation Sequencing for the Diagnosis of Cholestatic Genetic Liver Diseases: Clinical Utility and Challenges. *J Pediatr* 2019; **205**: 153-159.e6 [PMID: [30366773](#) DOI: [10.1016/j.jpeds.2018.09.028](#)]
- 28 **Togawa T**, Sugiura T, Ito K, Endo T, Aoyama K, Ohashi K, Negishi Y, Kudo T, Ito R, Kikuchi A, Arai-Ichinoi N, Kure S, Saitoh S. Molecular Genetic Dissection and Neonatal/Infantile Intrahepatic Cholestasis Using Targeted Next-Generation Sequencing. *J Pediatr* 2016; **171**: 171-7.e1 [PMID: [26858187](#) DOI: [10.1016/j.jpeds.2016.01.006](#)]
- 29 **Feldman AG**, Sokol RJ. Neonatal cholestasis: emerging molecular diagnostics and potential novel therapeutics. *Nat Rev Gastroenterol Hepatol* 2019; **16**: 346-360 [PMID: [30903105](#) DOI: [10.1038/s41575-019-0132-z](#)]
- 30 **de Vree JM**, Jacquemin E, Sturm E, Cresteil D, Bosma PJ, Aten J, Deleuze JF, Desrochers M, Burdelski M, Bernard O, Oude Elferink RP, Hadchouel M. Mutations in the MDR3 gene cause progressive familial intrahepatic cholestasis. *Proc Natl Acad Sci U S A* 1998; **95**: 282-287 [PMID: [9419367](#) DOI: [10.1073/pnas.95.1.282](#)]
- 31 **Ravindranath A**, Sen Sarma M, Yachha SK. Bile acid synthetic defects: Simplified approach in a nutshell. *Hepatobiliary Pancreat Dis Int* 2020; **19**: 80-84 [PMID: [31558365](#) DOI: [10.1016/j.hbpd.2019.09.003](#)]
- 32 **Gonzales E**, Matarazzo L, Franchi-Abella S, Dabadie A, Cohen J, Habes D, Hillaire S, Guettier C, Taburet AM, Myara A, Jacquemin E. Cholic acid for primary bile acid synthesis defects: a life-saving therapy allowing a favorable outcome in adulthood. *Orphanet J Rare Dis* 2018; **13**: 190 [PMID: [30373615](#) DOI: [10.1186/s13023-018-0920-5](#)]
- 33 **Zhou Y**, Zhang J. Arthrogryposis-renal dysfunction-cholestasis (ARC) syndrome: from molecular genetics to clinical features. *Ital J Pediatr* 2014; **40**: 77 [PMID: [25239142](#) DOI: [10.1186/s13052-014-0077-3](#)]
- 34 **Zhang J**, Yang Y, Gong JY, Li LT, Li JQ, Zhang MH, Lu Y, Xie XB, Hong YR, Yu Z, Knisely AS, Wang JS. Low-GGT intrahepatic cholestasis associated with biallelic USP53 variants: Clinical, histological and ultrastructural characterization. *Liver Int* 2020; **40**: 1142-1150 [PMID: [32124521](#) DOI: [10.1111/liv.14422](#)]
- 35 **Maddirevula S**, Alhebbi H, Alqahtani A, Algoufi T, Alsaif HS, Ibrahim N, Abdulwahab F, Barr M, Alzaidan H, Almehaideb A, AlSasi O, Alhashem A, Hussaini HA, Wali S, Alkuray FS. Identification of novel loci for pediatric cholestatic liver disease defined by KIF12, PPM1F, USP53, LSR, and WDR83OS pathogenic variants. *Genet Med* 2019; **21**: 1164-1172 [PMID: [30250217](#) DOI: [10.1038/s41436-018-0288-x](#)]
- 36 **Mitchell E**, Gilbert M, Loomes KM. Alagille Syndrome. *Clin Liver Dis* 2018; **22**: 625-641 [PMID: [30266153](#) DOI: [10.1016/j.cld.2018.06.001](#)]
- 37 **Hayasaka K**. Metabolic basis and treatment of citrin deficiency. *J Inherit Metab Dis* 2021; **44**: 110-117 [PMID: [32740958](#) DOI: [10.1002/jimd.12294](#)]
- 38 **Nagtzaam IF**, van Geel M, Driessen A, Steijlen PM, van Steensel MA. Bile duct paucity is part of the neonatal ichthyosis-sclerosing cholangitis phenotype. *Br J Dermatol* 2010; **163**: 205-207 [PMID: [20645982](#) DOI: [10.1111/j.1365-2133.2010.09794.x](#)]
- 39 **Srivastava A**. Progressive familial intrahepatic cholestasis. *J Clin Exp Hepatol* 2014; **4**: 25-36 [PMID: [25755532](#) DOI: [10.1016/j.jceh.2013.10.005](#)]
- 40 **Jagadisan B**, Srivastava A. Child with Jaundice and Pruritus: How to Evaluate? *Indian J Pediatr* 2016; **83**: 1311-1320 [PMID: [26932879](#) DOI: [10.1007/s12098-016-2058-6](#)]
- 41 **Lane E**, Murray KF. Neonatal Cholestasis. *Pediatr Clin North Am* 2017; **64**: 621-639 [PMID: [28502442](#) DOI: [10.1016/j.pcl.2017.01.006](#)]
- 42 **Thébaud A**, Debray D, Gonzales E. An update on the physiopathology and therapeutic management of cholestatic pruritus in children. *Clin Res Hepatol Gastroenterol* 2018; **42**: 103-109 [PMID: [29031874](#) DOI: [10.1016/j.clinre.2017.08.007](#)]
- 43 **Lemoine C**, Superina R. Surgical diversion of enterohepatic circulation in pediatric cholestasis. *Semin Pediatr Surg* 2020; **29**: 150946 [PMID: [32861450](#) DOI: [10.1016/j.sempedsurg.2020.150946](#)]
- 44 **Verkade HJ**, Thompson RJ, Arnell H, Fischler B, Gillberg PG, Mattsson JP, Torfgård K, Lindström E. Systematic Review and Meta-analysis: Partial External Biliary Diversion in Progressive Familial Intrahepatic Cholestasis. *J Pediatr Gastroenterol Nutr* 2020; **71**: 176-183 [PMID: [32433433](#) DOI: [10.1097/MPG.0000000000002789](#)]
- 45 **Fonda Allen J**, Stoll K, Bernhardt BA. Pre- and post-test genetic counseling for chromosomal and Mendelian disorders. *Semin Perinatol* 2016; **40**: 44-55 [PMID: [26718445](#) DOI: [10.1053/j.semperi.2015.11.007](#)]
- 46 **Ge T**, Zhang X, Xiao Y, Wang Y, Zhang T. Novel compound heterozygote mutations of TJP2 in a Chinese child with progressive cholestatic liver disease. *BMC Med Genet* 2019; **20**: 18 [PMID: [30658709](#) DOI: [10.1186/s12881-019-0753-7](#)]

- 47 **Mirza N**, Bharadwaj R, Malhotra S, Sibal A. Progressive familial intrahepatic cholestasis type 4 in an Indian child: presentation, initial course and novel compound heterozygous mutation. *BMJ Case Rep* 2020; **13** [PMID: [32636225](#) DOI: [10.1136/bcr-2019-234193](#)]



Published by **Baishideng Publishing Group Inc**
7041 Koll Center Parkway, Suite 160, Pleasanton, CA 94566, USA

Telephone: +1-925-3991568

E-mail: bpgoffice@wjgnet.com

Help Desk: <https://www.f6publishing.com/helpdesk>

<https://www.wjgnet.com>

