

# World Journal of *Hepatology*

*World J Hepatol* 2022 January 27; 14(1): 1-303



# REVIEW

- 1 Hepatitis C virus: A critical approach to who really needs treatment  
*Kouroumalis E, Voumvouraki A*
- 45 Current aspects of renal dysfunction after liver transplantation  
*Pacheco MP, Carneiro-D'Albuquerque LA, Mazo DF*
- 62 Hepatitis C: Problems to extinction and residual hepatic and extrahepatic lesions after sustained virological response  
*Cuesta-Sancho S, Márquez-Coello M, Illanes-Álvarez F, Márquez-Ruiz D, Arizcorreta A, Galán-Sánchez F, Montiel N, Rodríguez-Iglesias M, Girón-González JA*
- 80 Metabolic and nutritional triggers associated with increased risk of liver complications in SARS-CoV-2  
*de Jesus RP, de Carvalho JF, de Oliveira LPM, Cunha CM, Alves TCHS, Vieira STB, Figueiredo VM, Bueno AA*
- 98 Recent updates on progressive familial intrahepatic cholestasis types 1, 2 and 3: Outcome and therapeutic strategies  
*Alam S, Lal BB*
- 119 Is there a role of lipid-lowering therapies in the management of fatty liver disease?  
*Tzanaki I, Agouridis AP, Kostapanos MS*

# MINIREVIEWS

- 140 Targets of immunotherapy for hepatocellular carcinoma: An update  
*Rai V, Mukherjee S*
- 158 Redefining non-alcoholic fatty liver disease to metabolic associated fatty liver disease: Is this plausible?  
*Devi J, Raees A, Butt AS*
- 168 Stearoyl-CoA desaturase 1: A potential target for non-alcoholic fatty liver disease?-perspective on emerging experimental evidence  
*Jeyakumar SM, Vajreswari A*
- 180 Mitochondrial hepatopathy: Anticipated difficulties in management of fatty acid oxidation defects and urea cycle defects  
*Ravindranath A, Sarma MS*

# ORIGINAL ARTICLE

## Retrospective Cohort Study

- 195 Direct-acting antivirals for chronic hepatitis C treatment: The experience of two tertiary university centers in Brazil  
*Lourenço MS, Zitelli PMY, Cunha-Silva M, Oliveira AIN, Oliveira CP, Sevá-Pereira T, Carrilho FJ, Pessoa MG, Mazo DF*

- 209 Prognostic factors of survival and a new scoring system for liver resection of colorectal liver metastasis  
*Cheng KC, Yip ASM*

### Retrospective Study

- 224 Short-term outcomes of robotic liver resection: An initial single-institution experience  
*Durán M, Briceño J, Padial A, Anelli FM, Sánchez-Hidalgo JM, Ayllón MD, Calleja-Lozano R, García-Gaitan C*
- 234 Assessment for the minimal invasiveness of laparoscopic liver resection by interleukin-6 and thrombospondin-1  
*Kaida T, Hayashi H, Sato H, Kinoshita S, Matsumoto T, Shiraishi Y, Kitano Y, Higashi T, Imai K, Yamashita YI, Baba H*
- 244 Can the computed tomography texture analysis of colorectal liver metastases predict the response to first-line cytotoxic chemotherapy?  
*Rabe E, Cioni D, Baglietto L, Fornili M, Gabelloni M, Neri E*
- 260 Correlation of hepatitis B surface antigen expression with clinicopathological and biochemical parameters in liver biopsies: A comprehensive study  
*Alpsoy A, Adanir H, Bayramoglu Z, Elpek GO*

### Observational Study

- 274 COVID-19 emergency: Changes in quality of life perception in patients with chronic liver disease-An Italian single-centre study  
*Zannella A, Fanella S, Marignani M, Begini P*

### CASE REPORT

- 287 Acute liver failure secondary to acute antibody mediated rejection after compatible liver transplant: A case report  
*Robinson TJ, Hendeke JB, Gimferrer I, Leca N, Biggins SW, Reyes JD, Sibulesky L*

### LETTER TO THE EDITOR

- 295 Vitamin D supplementation for autoimmune hepatitis: A need for further investigation  
*Sergi CM*
- 300 Current highlights on solid pseudopapillary neoplasm of the pancreas  
*Sibio S, Di Carlo S*

**ABOUT COVER**

Editorial Board Member of *World Journal of Hepatology*, Fátima Higuera-de la Tijera, MD, MSc, PhD, Academic Research, Doctor, Professor, Department of Gastroenterology and Hepatology, Hospital General de México, Dr. Eduardo Liceaga, Mexico City 06726, Mexico. fatimahiguera@yahoo.com.mx

**AIMS AND SCOPE**

The primary aim of *World Journal of Hepatology* (*WJH*, *World J Hepatol*) is to provide scholars and readers from various fields of hepatology with a platform to publish high-quality basic and clinical research articles and communicate their research findings online.

*WJH* mainly publishes articles reporting research results and findings obtained in the field of hepatology and covering a wide range of topics including chronic cholestatic liver diseases, cirrhosis and its complications, clinical alcoholic liver disease, drug induced liver disease autoimmune, fatty liver disease, genetic and pediatric liver diseases, hepatocellular carcinoma, hepatic stellate cells and fibrosis, liver immunology, liver regeneration, hepatic surgery, liver transplantation, biliary tract pathophysiology, non-invasive markers of liver fibrosis, viral hepatitis.

**INDEXING/ABSTRACTING**

The *WJH* is now abstracted and indexed in PubMed, PubMed Central, Emerging Sources Citation Index (Web of Science), Scopus, China National Knowledge Infrastructure (CNKI), China Science and Technology Journal Database (CSTJ), and Superstar Journals Database. The 2021 edition of Journal Citation Reports® cites the 2020 Journal Citation Indicator (JCI) for *WJH* as 0.61. The *WJH*'s CiteScore for 2020 is 5.6 and Scopus CiteScore rank 2020: Hepatology is 24/62.

**RESPONSIBLE EDITORS FOR THIS ISSUE**

Production Editor: Lin-YuTong Wang; Production Department Director: Xiang Li; Editorial Office Director: Xiang Li.

**NAME OF JOURNAL**

*World Journal of Hepatology*

**ISSN**

ISSN 1948-5182 (online)

**LAUNCH DATE**

October 31, 2009

**FREQUENCY**

Monthly

**EDITORS-IN-CHIEF**

Nikolaos Pyrsopoulos, Ke-Qin Hu, Koo Jeong Kang

**EDITORIAL BOARD MEMBERS**

<https://www.wjnet.com/1948-5182/editorialboard.htm>

**PUBLICATION DATE**

January 27, 2022

**COPYRIGHT**

© 2022 Baishideng Publishing Group Inc

**INSTRUCTIONS TO AUTHORS**

<https://www.wjnet.com/bpg/gerinfo/204>

**GUIDELINES FOR ETHICS DOCUMENTS**

<https://www.wjnet.com/bpg/GerInfo/287>

**GUIDELINES FOR NON-NATIVE SPEAKERS OF ENGLISH**

<https://www.wjnet.com/bpg/gerinfo/240>

**PUBLICATION ETHICS**

<https://www.wjnet.com/bpg/GerInfo/288>

**PUBLICATION MISCONDUCT**

<https://www.wjnet.com/bpg/gerinfo/208>

**ARTICLE PROCESSING CHARGE**

<https://www.wjnet.com/bpg/gerinfo/242>

**STEPS FOR SUBMITTING MANUSCRIPTS**

<https://www.wjnet.com/bpg/GerInfo/239>

**ONLINE SUBMISSION**

<https://www.f6publishing.com>

## Retrospective Study

# Short-term outcomes of robotic liver resection: An initial single-institution experience

Manuel Durán, Javier Briceño, Ana Padial, Ferdinando Massimiliano Anelli, Juan Manuel Sánchez-Hidalgo, María Dolores Ayllón, Rafael Calleja-Lozano, Carmen García-Gaitan

**ORCID number:** Manuel Durán 0000-0003-1161-2195; Javier Briceño 0000-0001-7027-7898; Ana Padial 0000-0002-0608-4175; Ferdinando Massimiliano Anelli 0000-0002-0916-1949; Juan Manuel Sánchez-Hidalgo 0000-0002-0258-0673; María Dolores Ayllón 0000-0003-2493-3756; Rafael Calleja-Lozano 0000-0003-0048-0756; Carmen García-Gaitan 0000-0001-5087-5057.

**Author contributions:** Durán M and Briceño J have contributed equally to this paper; Briceño J was the principal surgeon in all the procedures, guarantor and designed the study; Durán M, Padial A, Anelli FM, Ayllón MD and García-Gaitán C participated in the acquisition, analysis, and interpretation of the data; Calleja-Lozano R and Durán M did the literature review; Durán M drafted the initial manuscript; Briceño J and Sánchez-Hidalgo JM revised the article critically for important intellectual content.

### Institutional review board

**statement:** The study was reviewed and approved by Comité de Ética de la Investigación de Córdoba, Hospital Universitario Reina Sofía, España.

**Informed consent statement:** All study participants, or their legal

**Manuel Durán, Javier Briceño, Ana Padial, Ferdinando Massimiliano Anelli, Juan Manuel Sánchez-Hidalgo, María Dolores Ayllón, Rafael Calleja-Lozano,** Unit of Hepatobiliary Surgery and Liver Transplantation, General and Digestive Surgery Department, Reina Sofia University Hospital, Cordoba 14004, Spain

**Manuel Durán, Javier Briceño, Ana Padial, Ferdinando Massimiliano Anelli, María Dolores Ayllón, Rafael Calleja-Lozano,** GC18 Translational Research in Surgery of Solid Organ Transplantation, Maimonides Biomedical Research Institute, Córdoba 14004, Spain

**Juan Manuel Sánchez-Hidalgo,** GE09 Research in Peritoneal and Retroperitoneal Oncological Surgery, Maimonides Biomedical Research Institute, Córdoba 14004, Spain

**Carmen García-Gaitan,** Department of Anesthesiology and Resuscitation, Reina Sofia University Hospital, Cordoba 14004, Spain

**Corresponding author:** Javier Briceño, MD, PhD, Chairman, Unit of Hepatobiliary Surgery and Liver Transplantation, General and Digestive Surgery Department, Reina Sofia University Hospital, Avda. Menéndez Pidal s/n, Cordoba 14004, Spain. [javibriceno@hotmail.com](mailto:javibriceno@hotmail.com)

## Abstract

### BACKGROUND

Liver surgery has traditionally been characterized by the complexity of its procedures and potentially high rates of morbidity and mortality in inexperienced hands. The robotic approach has gradually been introduced in liver surgery and has increased notably in recent years. However, few centers currently perform robotic liver surgery and experiences in robot-assisted surgical procedures continue to be limited compared to the laparoscopic approach.

### AIM

To analyze the outcomes and feasibility of an initial robotic liver program implemented in an experienced laparoscopic hepatobiliary center.

### METHODS

A total of forty consecutive patients underwent robotic liver resection (da Vinci Xi, intuitive.com, United States) between June 2019 and January 2021. Patients were prospectively followed and retrospectively reviewed. Clinicopathological characteristics and perioperative and short-term outcomes were analyzed. Data

guardian, provided informed written consent prior to study enrollment.

**Conflict-of-interest statement:**

There are no conflicts of interest to report.

**Data sharing statement:**

No additional data are available.

**Country/Territory of origin:**

Spain

**Specialty type:**

Surgery

**Provenance and peer review:**

Invited article; Externally peer reviewed.

**Peer-review model:**

Single blind

**Peer-review report's scientific quality classification**

Grade A (Excellent): 0

Grade B (Very good): B

Grade C (Good): C

Grade D (Fair): 0

Grade E (Poor): 0

**Open-Access:** This article is an open-access article that was selected by an in-house editor and fully peer-reviewed by external reviewers. It is distributed in accordance with the Creative Commons Attribution NonCommercial (CC BY-NC 4.0) license, which permits others to distribute, remix, adapt, build upon this work non-commercially, and license their derivative works on different terms, provided the original work is properly cited and the use is non-commercial. See: <http://creativecommons.org/licenses/by-nc/4.0/>

**Received:** March 26, 2021

**Peer-review started:** March 26, 2021

**First decision:** November 11, 2021

**Revised:** December 2, 2021

**Accepted:** December 25, 2021

**Article in press:** December 25, 2021

**Published online:** January 27, 2022

**P-Reviewer:** Li HL, Ziogas IA

**S-Editor:** Wang JL

**L-Editor:** Filipodia

**P-Editor:** Wang JL



are expressed as mean and standard deviation. The study was approved by the Institutional Review Board.

## RESULTS

The mean age of patients was 59.55 years, of which 18 (45%) were female. The mean body mass index was 29.41 kg/m<sup>2</sup>. Nine patients (22.5%) were cirrhotic. Patients were divided by type of resection as follows: Ten segmentectomies, three wedge resections, ten left lateral sectionectomies, six bisegmentectomies (two V-VI bisegmentectomies and four IVb-V bisegmentectomies), two right anterior sectionectomies, five left hepatectomies and two right hepatectomies. Malignant lesions occurred in twenty-nine (72.5%) of the patients. The mean operative time was 258.11 min and two patients were transfused intraoperatively (5%). Inflow occlusion was used in thirty cases (75%) and the mean total clamping time was 32.62 min. There was a single conversion due to uncontrollable hemorrhage. Major postoperative complications (Clavien-Dindo > IIIb) occurred in three patients (7.5%) and mortality in one (2.5%). No patient required readmission to the hospital. The mean hospital stay was 5.6 d.

## CONCLUSION

Although robotic hepatectomy is a safe and feasible procedure with favorable short-term outcomes, it involves a demanding learning curve that requires a high level of training, skill and dexterity.

**Key Words:** Robotics; Hepatectomy; Minimally invasive surgery; Liver surgery; Da vinci

©The Author(s) 2022. Published by Baishideng Publishing Group Inc. All rights reserved.

**Core Tip:** The number of liver procedures performed laparoscopically remains highly variable, ranging from 10% up to 80% in some centers, and complex hepatectomies are still confined to expert and experienced laparoscopic liver surgeons. The robotic approach is gradually being introduced in liver surgery and has increased notably in recent years, which could compensate for the inherent difficulties of the laparoscopic approach. In this study, we analyzed our single-center data of robotic liver resections using the da Vinci Xi System®.

**Citation:** Durán M, Briceño J, Padial A, Anelli FM, Sánchez-Hidalgo JM, Ayllón MD, Calleja-Lozano R, García-Gaitan C. Short-term outcomes of robotic liver resection: An initial single-institution experience. *World J Hepatol* 2022; 14(1): 224-233

**URL:** <https://www.wjgnet.com/1948-5182/full/v14/i1/224.htm>

**DOI:** <https://dx.doi.org/10.4254/wjh.v14.i1.224>

## INTRODUCTION

Liver surgery has traditionally been characterized by the complexity of its procedures and potentially high rates of morbidity and mortality in inexperienced hands. In recent years, laparoscopic liver surgery has notably increased due to the beneficial outcomes in terms of fewer complications and transfusions, less blood loss and shorter hospital stays compared to open surgery with similar oncologic outcomes[1,2].

The number of liver procedures performed laparoscopically remains highly variable, ranging from 10% up to 80% in some centers[3]. Complex hepatectomies such as major hepatectomies or in posterosuperior segments are still restricted to expert laparoscopic liver surgeons with considerable experience due to their inherent risk, which make them very technically demanding procedures[4-6]. The increase in laparoscopic liver resections (LLR) has been accompanied by the development of parenchymal transection equipment and improved optical systems to compensate for the limitations of this approach and to increase the safety of hepatic resections[7].

The robotic approach is gradually being introduced in liver surgery and could compensate for the inherent difficulties of the laparoscopic approach. However, only some centers have implemented robotic-assisted surgery and the experience continues



to be limited compared to laparoscopy[8]. In this study, we report an initial experience with our first forty robotic liver resections (RLRs) using the da Vinci Xi System<sup>®</sup> (Intuitive Surgical, Inc., Sunnyvale, CA, United States). The aim of this study was to analyze the outcomes and feasibility of an initial robotic liver program implemented in an experienced laparoscopic hepatobiliary center.

## MATERIALS AND METHODS

Following Institutional Review Board approval, we performed a retrospective review on our prospective recorded single-institution data between June 2019 and January 2021, including sixty-three patients who underwent a hepatobiliopancreatic procedure as follows: Nineteen distal pancreatectomies, four bilioenteric reconstructions and forty Liver resections. Forty RLRs were performed by a single hepatic surgeon (Dr. Briceño J) and included in the study. The indication of robotic surgery was established when the patient was considered a suitable candidate for minimally invasive surgical approach. All patients gave their informed consent prior to surgery.

Patient preoperative data included age, sex, body mass index (BMI), American society of anesthesiologists (ASA) classification, comorbidities, previous abdominal surgery and presence of chronic liver disease.

Intraoperative parameters included operative time, blood transfusion, use of inflow occlusion and duration and conversion rate. Operative time was defined as the time from the first incision to closure. Intraoperative complications were defined as an event requiring major deviation from the planned procedure.

The anatomical location of the lesions and surgical resection were defined according to the Brisbane terminology[9]. The difficulty of the liver resections was graded according to the IWATE scoring system as revised in the Morioka consensus conference whereby a score of 0-3 is graded as low difficulty, 4-6 as intermediate difficulty, 7-9 as advanced difficulty and 10-12 as expert difficulty[10].

Postoperative variables were postoperative complications, length of stay, readmission within 30 d and mortality. Postoperative complications were recorded using the Clavien–Dindo classification up to 90 d after surgery[11]. Complications were considered major when Clavien-Dindo > III.

The characteristics, diagnosis, number and size of the lesions were determined by pathological reports. Resection margins were defined as R0 resection when tumor distance from the margin was greater than 1 mm, as R1 resection when tumor distance from the margin was less than 1 mm and as R2 resection upon presence of macroscopic tumor at the margin.

Statistics demographic data and clinical outcomes were analyzed. The descriptive analysis included mean and standard deviation in continuous variables, while categorical and ordinal variables were reported as counts with proportions. A *P*-value of less than 0.05 was considered statistically significant. Statistical analyses were performed using SPSS Statistics version 22.0 (IBM, Armonk, NY, United States).

### **Surgical technique**

After anesthesia, patients are placed in the French position and in the reverse Trendelenburg position (15°) with a slight left tilt (5°). The assistant is located between the patient's legs and the robot is located at the left shoulder. The trocars are placed according to the following surgical requirements: The transection plane, the segments involved and the position of the endostapler. For a right hepatic lobe procedure, a 12 mm camera port is introduced in the right paraumbilical area and the main working ports (first and third robotic arm ports on the left and right, respectively) are placed in the left and right upper quadrant area. The fourth robotic trocar is placed near the left anterior axillary line. For a left hepatic lobe procedure or a left hepatectomy, trocar placement is similar to that described previously; however, the camera port is placed at the umbilicus to visualize the target anatomy. Once the robotic trocars are placed, the da Vinci Xi robotic system (Intuitive.com, United States) is docked. An AirSeal port (SurgiQuest Inc., Milford, CT, United States) is used for bedside assistance. An intracorporeal pringle maneuver using Huang's loop is applied and used when deemed appropriate (Figure 1).

A robotic vessel sealer and bipolar cautery are the main instruments employed for parenchymal transection using the crush-clamp technique. An intraoperative robotic ultrasound device is employed to confirm the location of the tumor and to check the surgical transection line. For anatomic liver resection, indocyanine green may be injected intravenously to visualize hepatic perfusion and the demarcation line by

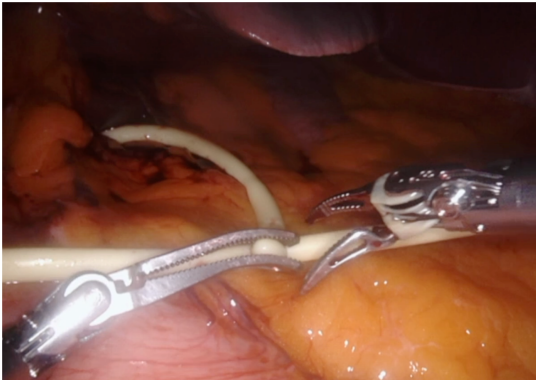

Figure 1 Huang's loop is applied and used when deemed appropriate.

negative staining (Figure 2). Finally, the specimen is removed from the abdominal cavity by means of an extraction bag.

## RESULTS

Forty patients underwent RLR for benign or malignant tumors. Overall, the mean age was 59.6 ( $\pm 11.8$ ), of which 18 (45%) were female. The mean BMI was 29.4 ( $\pm 4.7$ ). Seventeen patients (42.5%) underwent a previous surgery (laparoscopic or "open"). A total of 72.5% ( $n = 29$ ) of all lesions were malignant (primary lesions  $n = 23$ , metastatic lesions  $n = 6$ ). Five lesions (12.5%) were located in the postero-superior segments (IVa, VII and VIII). The patients' characteristics are summarized in Table 1.

### Perioperative outcomes

The type of liver resection, simultaneous combined procedures and outcomes are summarized in Table 2. Nine patients (22.5%) were cirrhotic and another 22.5% had moderate to severe hepatic steatosis. Seven (17.5%) major hepatectomies were performed, of which five were left hepatectomies and two right hepatectomies. Additionally, thirty-three (82.5%) minor hepatectomies were performed: Ten segmentectomies, three wedge resections, ten left lateral sectionectomies, six bisegmentectomies (two V-VI bisegmentectomies, four IVb-V bisegmentectomies), two right posterior sectionectomies and two right anterior sectionectomies. Two patients underwent a simultaneous resection of the primary tumor and the metastatic liver lesions. Of these, one underwent a distal pancreatectomy with splenectomy and anatomic right hepatectomy and the other underwent a low anterior resection with hepatic wedge resection. Only one patient was converted to the "open" approach due to hemorrhage. Based on the IWATE criteria, 3/40 operations were categorized as low difficulty, 19/40 as intermediate, 13/40 as advanced and 5/40 as expert (see Figure 3).

Eight patients developed complications and are summarized in Tables 2 and 3. Major complications (Clavien-Dindo > III) occurred in three patients (7.5%). Postoperative complications included ascites (1), ileus (1), acute renal injury (1) and bile leak (2), for which one patient required endoscopic retrograde cholangiopancreatography. One cirrhotic patient who underwent a right hepatectomy developed post-hepatectomy liver failure, ascites, acute kidney injury and lower gastrointestinal bleeding with no findings at colonoscopy.

The mean operative duration was 247.6 ( $\pm 119.2$ ) min. Inflow occlusion was used in 30 cases (75%) and mean total clamping time was 32.6 ( $\pm 26.6$ ) min. Two patients were transfused intraoperatively (5%) and vasopressors were used intraoperatively in fourteen cases (35%). The overall mean length of stay was 5.6 ( $\pm 6.1$ ) d, while for minor hepatectomies was 4.4 ( $\pm 3.6$ ) d and for major hepatectomies was 14 ( $\pm 12.6$ ) d.

The pathologic findings are summarized in Table 4. The mean number of lesions was 1.2 ( $\pm 0.7$ ), the mean size was 60.6 ( $\pm 40.5$ ) and R0 resection was performed in twenty-seven (93%) of malignant cases. Of the forty operations, the most common diagnoses were as follows: Sixteen (40%) hepatocellular carcinoma, six (15%) intrahepatic cholangiocarcinoma, five (12.5%) colorectal metastases and four (10%) giant hemangiomas.



**Table 1 Patient demographics and chronic preoperative conditions, *n* (%)**

Sex (female)	18 (45)
Age (yr)	59.6 ± 11.8
BMI	29.4 ± 4.7
ASA class	
ASA I	3 (7.5)
ASA II	13 (32.5)
ASA III	24 (60)
Previous abdominal surgery	17 (42.5)
Chronic liver disease	12 (30)
History of type 2 diabetes	14 (35)
History of hypertension	22 (55)
Chronic respiratory disease	7 (17.5)
Chronic cardiac disease	7 (17.5)
Chronic renal disease	2 (5)
Viral infection	
HCV	5 (17.5)
HBV	1 (2.5)
Benign/malignant	11 (27.5)/29 (72.5)

BMI: Body mass index; ASA: American Society of Anesthesiologists; HCV: Hepatitis C virus; HBV: Hepatitis B virus.

**Table 2 Type of liver resection**

Type of liver resection, <i>n</i> (%)	Combined procedures	Cirrhosis	Conversion	Postoperative complications
Wedge resection	3 (7.5)	LAR (1), CH (2)		
Segmentectomy	10 (25)	CH (3)	4	1 (Bleeding)
Left lateral sectionectomy	10 (25)	CH (1)	4	Ascites (1), colon ischemia (1)
Bisegmentectomy V-VI	2 (5)	CH (1)		AKI (1), POT (1)
Bisegmentectomy IVb-V	4 (10)	CH (3)		
Right posterior sectionectomy	2 (5)	CH (1)		
Right anterior sectionectomy	2 (5)	CH (2)		Ileus (1)
Left hepatectomy	5 (12.5)	RFA (1), CH (4)		Bile leak (1)
Right hepatectomy	2 (5)	PS (1), CH (1)	1	PHLF, ascites, LGIB and AKI (1), Bile leak (1)

LAR: Low anterior resection; CH: Cholecystectomy; RFA: Radiofrequency ablation; PS: Pancreatosplenectomy; AKI: Acute kidney injury; POT: Postoperative red blood cell transfusion; PHLF: Post-hepatectomy liver failure; LGIB: Low gastrointestinal bleeding.

## DISCUSSION

The minimally invasive approach in liver surgery has revolutionized the management of patients with liver tumors due to its demonstrated superiority over open surgery in terms of hospital stay, morbidity and blood loss[12,13].

Despite the exponential increase in laparoscopic liver surgery in recent years, the development of this surgical procedure has been a real challenge and even today the majority of hepatectomies performed by laparoscopy are the least complex, while major LLRs are still performed in few expert centers. A recent meta-analysis has demonstrated similar outcomes between laparoscopic and robotic major hepatec-


**Table 3 Perioperative and postoperative outcomes**

Operative duration (min)	247.6 ± 119.2
Inflow occlusion	30 (75%)
Total clamping time (min)	32.6 ± 26.6
Intraoperative vasopressors use	14 (35%)
Intraoperative blood transfusion	2 (5%)
Postoperative complications	8 (20%)
Clavien–dindo classification	
Grade I	1
Grade II	4
Grade IIIa	2
Grade IIIb	
Grade IV	
Grade V	1
Conversion	1 (2.5%)
Mortality	1 (2.5%)
Length of stay (d)	5.6 ± 6.1
30-d readmission	

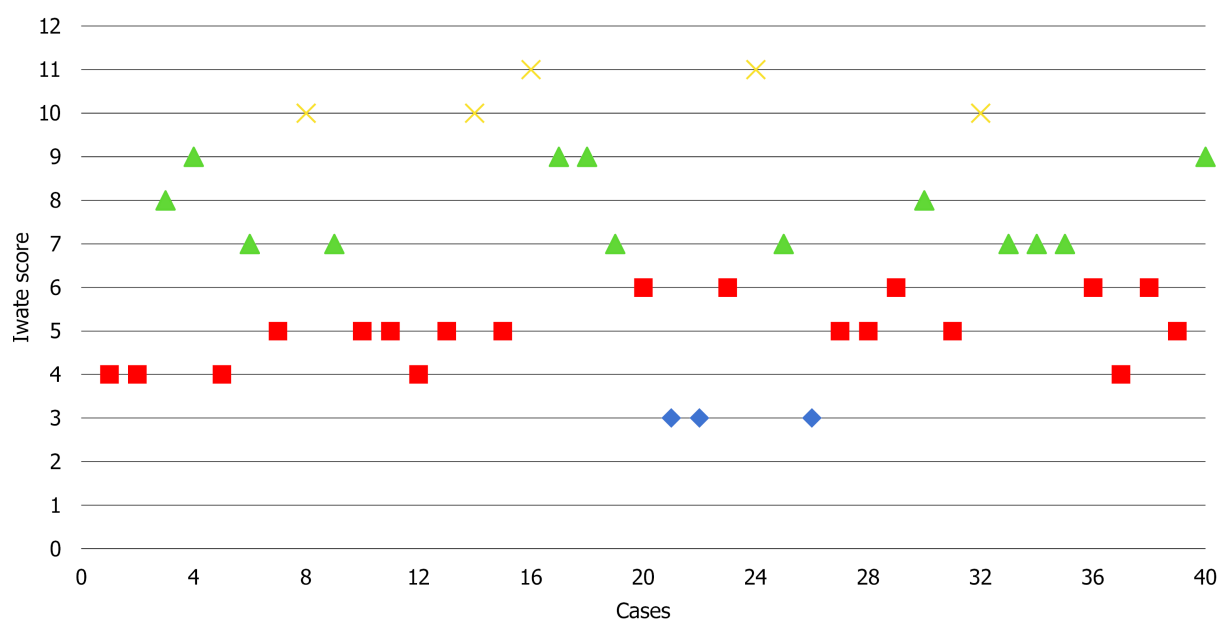
**Table 4 Pathologic examination**

Malignant	n (%)
Primary	
Hepatocellular carcinoma	16 (40)
Intrahepatic cholangiocarcinoma	6 (15)
Gallbladder carcinoma	1 (2.5)
Metastatic	
Colorectal metastases	5 (12.5)
Non-colorectal metastases	1 (2.5)
Benign	
Adenoma	1 (2.5)
Giant hemangioma	4 (10)
Giant focal nodular hyperplasia	3 (7.5)
Hydatid cyst	2 (5)
Simple cyst	1 (2.5)
Number of lesions	1.2 ± 0.7
Tumor size (mm)	60.6 ± 40.5
Surgical margin	
R0	27 (93)
R1	2 (7)

tomies[14]. Most procedures were performed in specialized centers by liver surgeons with great previous expertise on minimally invasive surgery, demonstrating a severe complication rate of 6.7% and 3.6%, respectively, and almost zero risk of death.



**Figure 2** Demarcation line by indole cyanide green negative staining of anatomic segment 3 resections.



**Figure 3** Consecutive case series and degree of difficulty according to the IWATE score. Low: 3 (7.5%) was in blue; Intermediate: 19 (47.5%) was in red; Advanced: 13 (32.5%) was in green; Expert: 5 (12.5%) was in yellow.

Certain aspects associated with the laparoscopic approach, such as unstable cameras, rigid instruments with reduced degrees of freedom, human hand tremors, poor surgeon ergonomics and the difficulty of suturing in hard-to-reach locations constitute a serious limitation for performing complex hepatectomies[15]. Robotic systems have compensated for the limitations inherent in the laparoscopic approach as they use stable, 3D high-definition cameras that eliminate hand tremors and provide 7 degrees of freedom, thus increasing manual dexterity and facilitating liver resections. Moreover, it has been shown that robotic platforms reduce physical workload and are less strenuous for surgeons, so they may reduce musculoskeletal strain and disorders [16,17].

In this study, we present our initial experience in robotic liver surgery. Comparing our experience with those reported by other specialized centers, some have performed a greater number of RLRs, but the study interval is greater[18-25]. In our series, forty RLRs were performed in 18 mo and included major hepatectomies and cirrhotic patients. Most of the patients were overweight, middle-aged men, the majority of whom were ASA class III and had several comorbidities. Resections were mainly performed for malignant lesions, with hepatocellular carcinoma, intrahepatic cholangiocarcinoma and colorectal metastases being the most common diagnoses. Two patients underwent a simultaneous resection of the primary tumor (distal pancreaticectomy and low anterior resection) and liver metastasis.

Resections for liver metastases were only performed in the absence of peritoneal carcinomatosis or unresectable extrahepatic disease. All patients with malignant disease except two had negative margins after the resection. Of the total number of

patients, eleven (27.5%) had benign indications for liver resections. Benign lesions were resected because of severe symptoms caused by tumor size, radiological features of malignancy or diagnostic uncertainty despite preoperative biopsies and underwent anatomic resection.

Regarding the type of resection performed, left lateral sectionectomy (25%) and segmentectomy (25%) were the most frequently performed resections. To study the complexity of the RLRs performed, we employed the IWATE score. The effectiveness of the IWATE score as an indicator of operative difficulty in LLR has been demonstrated and several groups have previously considered that its usefulness in laparoscopic liver surgery could be extrapolated to the robotic approach[26,27]. In this study, 45% of the procedures were classified as advanced and expert. These percentages are similar to those of Labadie *et al*[26] (43%) and lower than the data reported by Sucandy *et al*[27] (68.6%). As can be seen in Figure 3 showing the cases performed to date and their degree of difficulty, the 45% of RLRs performed were classified as advanced and expert. In our experience, this is due to two reasons: The advantages of the robotic approach for surgeons and the extensive background of our group in laparoscopic liver surgery, which has provided the surgeons an understanding of the specific features and difficulties of this minimally invasive approach. In the coming years, the IWATE score will likely have to be adapted to robotic-assisted liver surgery, as this approach allows accessing posterior superior segments but shows difficulties associated with the resection of various lesions in different quadrants. RLR may favor the operative feasibility of highly difficult resections reducing the conversion rate and increasing safety. However, it does not translate directly into a postoperative course more favorable than pure laparoscopy, as we are still comparing two minimally invasive approaches[28].

Although the overall complication rate was 20%, major complications (Clavien-Dindo > III) occurred in three patients (7.5%). The postoperative complication rate in our study (20%) is similar to that published in a recent metaanalysis by Guan *et al*[29] (19.2%), which included 435 RLRs. Reported conversion rates range from 0%-6% [18,19,21,22,30]. The only conversion to the “open” approach in our series (2.5%) occurred in a cirrhotic patient due to hemorrhage from a right inferior hepatic vein during a segment VI resection which required a cava vein venorrhaphy. The only death in our series occurred in a patient with a previous history of autoimmune vasculopathy who underwent a segment VI segmentectomy. The patient developed pancolonic ischemia at postoperative day 7 requiring intervention and died 18 d after being admitted to the Intensive care unit due to massive intestinal ischemia.

The main limitations to the present study are its single-arm design, the relatively small sample size and the retrospective nature of the analysis despite prospective recording. The lack of financial costs and quality of life analysis prevent a deeper investigation.

## CONCLUSION

The results reported in this initial case series reflect perioperative outcomes similar to those published previously which support the safety and feasibility of this approach in liver surgery. Previous experience in minimally invasive liver surgery is necessary to overcome the initial difficulties of the robotic approach and perform complex liver procedures in a short period of time.

## ARTICLE HIGHLIGHTS

### Research perspectives

Future work is required to clarify the role of the robotic approach in complex hepatectomies.

### Research conclusions

The implementation of a liver robotic surgery program is safe and feasible with favorable short-term outcomes.

## Research results

Forty consecutive patients underwent robotic liver resection between June 2019 and January 2021. Liver resection included: Ten segmentectomies, three wedge resections, ten left lateral sectionectomies, six bisegmentectomies (two V-VI bisegmentectomies and four IVb-V bisegmentectomies), two right anterior sectionectomies, five left hepatectomies and two right hepatectomies.

## Research methods

In this study patients were prospectively followed and retrospectively reviewed. The study was conducted according to STROBE statements.

## Research objectives

The authors aimed to analyze the outcomes and feasibility of an initial robotic liver surgery program implemented in an experienced laparoscopic hepatobiliary center.

## Research motivation

A robotic liver surgery program has been implemented in our center which has significant previous experience in minimally invasive surgery.

## Research background

In recent years, minimal invasive liver surgery has notably increased due to its perioperative and postoperative favorable outcomes.

## REFERENCES

- 1 **Jin B**, Chen MT, Fei YT, Du SD, Mao YL. Safety and efficacy for laparoscopic versus open hepatectomy: A meta-analysis. *Surg Oncol* 2018; **27**: A26-A34 [PMID: [28687154](#) DOI: [10.1016/j.suronc.2017.06.007](#)]
- 2 **Xing L**, Guo HB, Kan JL, Liu SG, Lv HT, Liu JH, Bian W. Clinical outcome of open surgery versus laparoscopic surgery for cirrhotic hepatocellular carcinoma patients: a meta-analysis. *Eur J Gastroenterol Hepatol* 2020; **32**: 239-245 [PMID: [31567715](#) DOI: [10.1097/MEG.0000000000001495](#)]
- 3 **Viganò L**, Cimino M, Aldrighetti L, Ferrero A, Cillo U, Guglielmi A, Ettorre GM, Giuliani F, Dalla Valle R, Mazzaferro V, Jovine E, De Carlis L, Calise F, Torzilli G; Italian Group of Minimally Invasive Liver Surgery (I Go MILS). Multicentre evaluation of case volume in minimally invasive hepatectomy. *Br J Surg* 2020; **107**: 443-451 [PMID: [32167174](#) DOI: [10.1002/bjs.11369](#)]
- 4 **Choi GH**, Chong JU, Han DH, Choi JS, Lee WJ. Robotic hepatectomy: the Korean experience and perspective. *Hepatobiliary Surg Nutr* 2017; **6**: 230-238 [PMID: [28848745](#) DOI: [10.21037/hbsn.2017.01.14](#)]
- 5 **Tzanis D**, Shivathirthan N, Laurent A, Abu Hilal M, Soubrane O, Kazaryan AM, Ettore GM, Van Dam RM, Lainas P, Tranchart H, Edwin B, Belli G, Campos RR, Pearce N, Gayet B, Dagher I. European experience of laparoscopic major hepatectomy. *J Hepatobiliary Pancreat Sci* 2013; **20**: 120-124 [PMID: [23053354](#) DOI: [10.1007/s00534-012-0554-2](#)]
- 6 **Kasai M**, Cipriani F, Gayet B, Aldrighetti L, Ratti F, Sarmiento JM, Scatton O, Kim KH, Dagher I, Topal B, Primrose J, Nomi T, Fuks D, Abu Hilal M. Laparoscopic versus open major hepatectomy: a systematic review and meta-analysis of individual patient data. *Surgery* 2018; **163**: 985-995 [PMID: [29555197](#) DOI: [10.1016/j.surg.2018.01.020](#)]
- 7 **Velayutham V**, Fuks D, Nomi T, Kawaguchi Y, Gayet B. 3D visualization reduces operating time when compared to high-definition 2D in laparoscopic liver resection: a case-matched study. *Surg Endosc* 2016; **30**: 147-153 [PMID: [25805241](#) DOI: [10.1007/s00464-015-4174-1](#)]
- 8 **Ciria R**, Berardi G, Alconchel F, Briceño J, Choi GH, Wu YM, Sugioaka A, Troisi RI, Salloum C, Soubrane O, Pratschke J, Martinie J, Tsung A, Araujo R, Sucandy I, Tang CN, Wakabayashi G. The impact of robotics in liver surgery: A worldwide systematic review and short-term outcomes meta-analysis on 2,728 cases. *J Hepatobiliary Pancreat Sci* 2020 [PMID: [33200536](#) DOI: [10.1002/jhbp.869](#)]
- 9 **Strasberg SM**. Nomenclature of hepatic anatomy and resections: a review of the Brisbane 2000 system. *J Hepatobiliary Pancreat Surg* 2005; **12**: 351-355 [PMID: [16258801](#) DOI: [10.1007/s00534-005-0999-7](#)]
- 10 **Wakabayashi G**. What has changed after the Morioka consensus conference 2014 on laparoscopic liver resection? *Hepatobiliary Surg Nutr* 2016; **5**: 281-289 [PMID: [27500140](#) DOI: [10.21037/hbsn.2016.03.03](#)]
- 11 **Dindo D**, Demartines N, Clavien PA. Classification of surgical complications: a new proposal with evaluation in a cohort of 6336 patients and results of a survey. *Ann Surg* 2004; **240**: 205-213 [PMID: [15273542](#) DOI: [10.1097/01.sla.0000133083.54934.ae](#)]
- 12 **Okuno M**, Goumard C, Mizuno T, Omichi K, Tzeng CD, Chun YS, Aloia TA, Fleming JB, Lee JE,

- Vauthey JN, Conrad C. Operative and short-term oncologic outcomes of laparoscopic versus open liver resection for colorectal liver metastases located in the posterosuperior liver: a propensity score matching analysis. *Surg Endosc* 2018; **32**: 1776-1786 [PMID: [28917012](#) DOI: [10.1007/s00464-017-5861-x](#)]
- 13 **Meng XF**, Xu YZ, Pan YW, Lu SC, Duan WD. Open versus laparoscopic hepatic resection for hepatocellular carcinoma: a systematic review and meta-analysis. *Surg Endosc* 2019; **33**: 2396-2418 [PMID: [31139980](#) DOI: [10.1007/s00464-019-06781-3](#)]
  - 14 **Ziogas IA**, Giannis D, Esagian SM, Economopoulos KP, Tohme S, Geller DA. Laparoscopic versus robotic major hepatectomy: a systematic review and meta-analysis. *Surg Endosc* 2021; **35**: 524-535 [PMID: [32989544](#) DOI: [10.1007/s00464-020-08008-2](#)]
  - 15 **Tsilimigras DI**, Moris D, Vagios S, Merath K, Pawlik TM. Safety and oncologic outcomes of robotic liver resections: A systematic review. *J Surg Oncol* 2018; **117**: 1517-1530 [PMID: [29473968](#) DOI: [10.1002/jso.25018](#)]
  - 16 **Dalager T**, Jensen PT, Eriksen JR, Jakobsen HL, Mogensen O, Søgaard K. Surgeons' posture and muscle strain during laparoscopic and robotic surgery. *Br J Surg* 2020; **107**: 756-766 [PMID: [31922258](#) DOI: [10.1002/bjs.11394](#)]
  - 17 **Dalsgaard T**, Jensen MD, Hartwell D, Mosgaard BJ, Jørgensen A, Jensen BR. Robotic Surgery Is Less Physically Demanding Than Laparoscopic Surgery: Paired Cross Sectional Study. *Ann Surg* 2020; **271**: 106-113 [PMID: [29923873](#) DOI: [10.1097/SLA.0000000000002845](#)]
  - 18 **Sucandy I**, Giovannetti A, Ross S, Rosemurgy A. Institutional First 100 Case Experience and Outcomes of Robotic Hepatectomy for Liver Tumors. *Am Surg* 2020; **86**: 200-207 [PMID: [32223798](#)]
  - 19 **Quijano Y**, Vicente E, Ielpo B, Duran H, Diaz E, Fabra I, Olivares S, Ferri V, Ortega I, Malavé L, Ferronetti A, Piccinni G, Caruso R. Robotic Liver Surgery: Early Experience From a Single Surgical Center. *Surg Laparosc Endosc Percutan Tech* 2016; **26**: 66-71 [PMID: [26836628](#) DOI: [10.1097/SLE.0000000000000227](#)]
  - 20 **Fruscione M**, Pickens R, Baker EH, Cochran A, Khan A, Ocuin L, Iannitti DA, Vrochides D, Martinie JB. Robotic-assisted versus laparoscopic major liver resection: analysis of outcomes from a single center. *HPB (Oxford)* 2019; **21**: 906-911 [PMID: [30617001](#) DOI: [10.1016/j.hpb.2018.11.011](#)]
  - 21 **Choi GH**, Choi SH, Kim SH, Hwang HK, Kang CM, Choi JS, Lee WJ. Robotic liver resection: technique and results of 30 consecutive procedures. *Surg Endosc* 2012; **26**: 2247-2258 [PMID: [22311301](#) DOI: [10.1007/s00464-012-2168-9](#)]
  - 22 **Valverde A**, Abdallah S, Danoussou D, Goasguen N, Jouvin I, Oberlin O, Lupinacci RM. Transitioning From Open to Robotic Liver Resection. Results of 46 Consecutive Procedures Including a Majority of Major Hepatectomies. *Surg Innov* 2021; **28**: 309-315 [PMID: [32857664](#) DOI: [10.1177/1553350620954580](#)]
  - 23 **Goh BKP**, Lee LS, Lee SY, Chow PKH, Chan CY, Chiow AKH. Initial experience with robotic hepatectomy in Singapore: analysis of 48 resections in 43 consecutive patients. *ANZ J Surg* 2019; **89**: 201-205 [PMID: [29512261](#) DOI: [10.1111/ans.14417](#)]
  - 24 **Ceccarelli G**, Andolfi E, Fontani A, Calise F, Rocca A, Giuliani A. Robot-assisted liver surgery in a general surgery unit with a "Referral Centre Hub&Spoke Learning Program". Early outcomes after our first 70 consecutive patients. *Minerva Chir* 2018; **73**: 460-468 [PMID: [29795060](#) DOI: [10.23736/S0026-4733.18.07651-4](#)]
  - 25 **Lee B**, Choi Y, Cho JY, Yoon YS, Han HS. Initial experience with a robotic hepatectomy program at a high-volume laparoscopic center: single-center experience and surgical tips. *Ann Transl Med* 2021; **9**: 1132 [PMID: [34430573](#) DOI: [10.21037/atm-21-202](#)]
  - 26 **Labadie KP**, Drouillard DJ, Lois AW, Daniel SK, McNevin KE, Gonzalez JV, Seo YD, Sullivan KM, Bilodeau KS, Dickerson LK, Utria AF, Calhoun J, Pillarisetty VG, Sham JG, Yeung RS, Park JO. IWATE criteria are associated with perioperative outcomes in robotic hepatectomy: a retrospective review of 225 resections. *Surg Endosc* 2021 [PMID: [33608766](#) DOI: [10.1007/s00464-021-08345-w](#)]
  - 27 **Luberice K**, Sucandy I, Modasi A, Castro M, Krill E, Ross S, Rosemurgy A. Applying IWATE criteria to robotic hepatectomy: is there a "robotic effect"? *HPB (Oxford)* 2021; **23**: 899-906 [PMID: [33144052](#) DOI: [10.1016/j.hpb.2020.10.008](#)]
  - 28 **Cipriani F**, Fiorentini G, Magistri P, Fontani A, Menonna F, Anecchiarico M, Lauterio A, De Carlis L, Coratti A, Boggi U, Ceccarelli G, Di Benedetto F, Aldrighetti L. Pure laparoscopic versus robotic liver resections: Multicentric propensity score-based analysis with stratification according to difficulty scores. *J Hepatobiliary Pancreat Sci* 2021 [PMID: [34291591](#) DOI: [10.1002/jhbp.1022](#)]
  - 29 **Guan R**, Chen Y, Yang K, Ma D, Gong X, Shen B, Peng C. Clinical efficacy of robot-assisted versus laparoscopic liver resection: a meta analysis. *Asian J Surg* 2019; **42**: 19-31 [PMID: [30170946](#) DOI: [10.1016/j.asjsur.2018.05.008](#)]
  - 30 **Morel P**, Jung M, Cornateanu S, Buehler L, Majno P, Toso C, Buchs NC, Rubbia-Brandt L, Hagen ME. Robotic versus open liver resections: A case-matched comparison. *Int J Med Robot* 2017; **13** [PMID: [28058770](#) DOI: [10.1002/rcs.1800](#)]





Published by **Baishideng Publishing Group Inc**  
7041 Koll Center Parkway, Suite 160, Pleasanton, CA 94566, USA

**Telephone:** +1-925-3991568

**E-mail:** [bpgoffice@wjgnet.com](mailto:bpgoffice@wjgnet.com)

**Help Desk:** <https://www.f6publishing.com/helpdesk>

<https://www.wjgnet.com>

