

World Journal of *Hepatology*

World J Hepatol 2022 January 27; 14(1): 1-303



REVIEW

- 1 Hepatitis C virus: A critical approach to who really needs treatment
Kouroumalis E, Voumvouraki A
- 45 Current aspects of renal dysfunction after liver transplantation
Pacheco MP, Carneiro-D'Albuquerque LA, Mazo DF
- 62 Hepatitis C: Problems to extinction and residual hepatic and extrahepatic lesions after sustained virological response
Cuesta-Sancho S, Márquez-Coello M, Illanes-Álvarez F, Márquez-Ruiz D, Arizcorreta A, Galán-Sánchez F, Montiel N, Rodríguez-Iglesias M, Girón-González JA
- 80 Metabolic and nutritional triggers associated with increased risk of liver complications in SARS-CoV-2
de Jesus RP, de Carvalho JF, de Oliveira LPM, Cunha CM, Alves TCHS, Vieira STB, Figueiredo VM, Bueno AA
- 98 Recent updates on progressive familial intrahepatic cholestasis types 1, 2 and 3: Outcome and therapeutic strategies
Alam S, Lal BB
- 119 Is there a role of lipid-lowering therapies in the management of fatty liver disease?
Tzanaki I, Agouridis AP, Kostapanos MS

MINIREVIEWS

- 140 Targets of immunotherapy for hepatocellular carcinoma: An update
Rai V, Mukherjee S
- 158 Redefining non-alcoholic fatty liver disease to metabolic associated fatty liver disease: Is this plausible?
Devi J, Raees A, Butt AS
- 168 Stearoyl-CoA desaturase 1: A potential target for non-alcoholic fatty liver disease?-perspective on emerging experimental evidence
Jeyakumar SM, Vajreswari A
- 180 Mitochondrial hepatopathy: Anticipated difficulties in management of fatty acid oxidation defects and urea cycle defects
Ravindranath A, Sarma MS

ORIGINAL ARTICLE

Retrospective Cohort Study

- 195 Direct-acting antivirals for chronic hepatitis C treatment: The experience of two tertiary university centers in Brazil
Lourenço MS, Zitelli PMY, Cunha-Silva M, Oliveira AIN, Oliveira CP, Sevá-Pereira T, Carrilho FJ, Pessoa MG, Mazo DF

- 209 Prognostic factors of survival and a new scoring system for liver resection of colorectal liver metastasis
Cheng KC, Yip ASM

Retrospective Study

- 224 Short-term outcomes of robotic liver resection: An initial single-institution experience
Durán M, Briceño J, Padial A, Anelli FM, Sánchez-Hidalgo JM, Ayllón MD, Calleja-Lozano R, García-Gaitan C
- 234 Assessment for the minimal invasiveness of laparoscopic liver resection by interleukin-6 and thrombospondin-1
Kaida T, Hayashi H, Sato H, Kinoshita S, Matsumoto T, Shiraishi Y, Kitano Y, Higashi T, Imai K, Yamashita YI, Baba H
- 244 Can the computed tomography texture analysis of colorectal liver metastases predict the response to first-line cytotoxic chemotherapy?
Rabe E, Cioni D, Baglietto L, Fornili M, Gabelloni M, Neri E
- 260 Correlation of hepatitis B surface antigen expression with clinicopathological and biochemical parameters in liver biopsies: A comprehensive study
Alpsoy A, Adanir H, Bayramoglu Z, Elpek GO

Observational Study

- 274 COVID-19 emergency: Changes in quality of life perception in patients with chronic liver disease-An Italian single-centre study
Zannella A, Fanella S, Marignani M, Begini P

CASE REPORT

- 287 Acute liver failure secondary to acute antibody mediated rejection after compatible liver transplant: A case report
Robinson TJ, Hendeke JB, Gimferrer I, Leca N, Biggins SW, Reyes JD, Sibulesky L

LETTER TO THE EDITOR

- 295 Vitamin D supplementation for autoimmune hepatitis: A need for further investigation
Sergi CM
- 300 Current highlights on solid pseudopapillary neoplasm of the pancreas
Sibio S, Di Carlo S

ABOUT COVER

Editorial Board Member of *World Journal of Hepatology*, Fátima Higuera-de la Tijera, MD, MSc, PhD, Academic Research, Doctor, Professor, Department of Gastroenterology and Hepatology, Hospital General de México, Dr. Eduardo Liceaga, Mexico City 06726, Mexico. fatimahiguera@yahoo.com.mx

AIMS AND SCOPE

The primary aim of *World Journal of Hepatology* (*WJH*, *World J Hepatol*) is to provide scholars and readers from various fields of hepatology with a platform to publish high-quality basic and clinical research articles and communicate their research findings online.

WJH mainly publishes articles reporting research results and findings obtained in the field of hepatology and covering a wide range of topics including chronic cholestatic liver diseases, cirrhosis and its complications, clinical alcoholic liver disease, drug induced liver disease autoimmune, fatty liver disease, genetic and pediatric liver diseases, hepatocellular carcinoma, hepatic stellate cells and fibrosis, liver immunology, liver regeneration, hepatic surgery, liver transplantation, biliary tract pathophysiology, non-invasive markers of liver fibrosis, viral hepatitis.

INDEXING/ABSTRACTING

The *WJH* is now abstracted and indexed in PubMed, PubMed Central, Emerging Sources Citation Index (Web of Science), Scopus, China National Knowledge Infrastructure (CNKI), China Science and Technology Journal Database (CSTJ), and Superstar Journals Database. The 2021 edition of Journal Citation Reports® cites the 2020 Journal Citation Indicator (JCI) for *WJH* as 0.61. The *WJH*'s CiteScore for 2020 is 5.6 and Scopus CiteScore rank 2020: Hepatology is 24/62.

RESPONSIBLE EDITORS FOR THIS ISSUE

Production Editor: Lin-YuTong Wang; Production Department Director: Xiang Li; Editorial Office Director: Xiang Li.

NAME OF JOURNAL

World Journal of Hepatology

ISSN

ISSN 1948-5182 (online)

LAUNCH DATE

October 31, 2009

FREQUENCY

Monthly

EDITORS-IN-CHIEF

Nikolaos Pyrsopoulos, Ke-Qin Hu, Koo Jeong Kang

EDITORIAL BOARD MEMBERS

<https://www.wjnet.com/1948-5182/editorialboard.htm>

PUBLICATION DATE

January 27, 2022

COPYRIGHT

© 2022 Baishideng Publishing Group Inc

INSTRUCTIONS TO AUTHORS

<https://www.wjnet.com/bpg/gerinfo/204>

GUIDELINES FOR ETHICS DOCUMENTS

<https://www.wjnet.com/bpg/GerInfo/287>

GUIDELINES FOR NON-NATIVE SPEAKERS OF ENGLISH

<https://www.wjnet.com/bpg/gerinfo/240>

PUBLICATION ETHICS

<https://www.wjnet.com/bpg/GerInfo/288>

PUBLICATION MISCONDUCT

<https://www.wjnet.com/bpg/gerinfo/208>

ARTICLE PROCESSING CHARGE

<https://www.wjnet.com/bpg/gerinfo/242>

STEPS FOR SUBMITTING MANUSCRIPTS

<https://www.wjnet.com/bpg/GerInfo/239>

ONLINE SUBMISSION

<https://www.f6publishing.com>

Recent updates on progressive familial intrahepatic cholestasis types 1, 2 and 3: Outcome and therapeutic strategies

Seema Alam, Bikrant Bihari Lal

ORCID number: Seema Alam 0000-0003-0888-8625; Bikrant Bihari Lal 0000-0001-6275-7736.

Author contributions: Alam S contributed to the conceptualization and intellectual input of final draft of manuscript; Lal BB contributed to the primary draft of manuscript, data collection and literature retrieval; and both authors contributed equally to the manuscript.

Conflict-of-interest statement: Seema Alam and Bikrant Bihari Lal declare no conflict of interest.

Country/Territory of origin: India

Specialty type: Gastroenterology and hepatology

Provenance and peer review: Invited article; Externally peer reviewed.

Peer-review model: Single blind

Peer-review report's scientific quality classification

Grade A (Excellent): 0
Grade B (Very good): B
Grade C (Good): 0
Grade D (Fair): D
Grade E (Poor): 0

Open-Access: This article is an open-access article that was selected by an in-house editor and

Seema Alam, Bikrant Bihari Lal, Department of Pediatric Hepatology, Institute of Liver and Biliary Sciences, New Delhi 110070, India

Corresponding author: Seema Alam, MD, Professor, Department of Pediatric Hepatology, Institute of Liver and Biliary Sciences, D-1 Vasant Kunj, New Delhi 110070, India.
seema_alam@hotmail.com

Abstract

Recent evidence points towards the role of genotype to understand the phenotype, predict the natural course and long term outcome of patients with progressive familial intrahepatic cholestasis (PFIC). Expanded role of the heterozygous transporter defects presenting late needs to be suspected and identified. Treatment of pruritus, nutritional rehabilitation, prevention of fibrosis progression and liver transplantation (LT) in those with end stage liver disease form the crux of the treatment. LT in PFIC has its own unique issues like high rates of intractable diarrhoea, growth failure; steatohepatitis and graft failure in PFIC1 and antibody-mediated bile salt export pump deficiency in PFIC2. Drugs inhibiting apical sodium-dependent bile transporter and adenovirus-associated vector mediated gene therapy hold promise for future.

Key Words: Genotype; Biliary diversion; Gene therapy; Liver transplantation

©The Author(s) 2021. Published by Baishideng Publishing Group Inc. All rights reserved.

Core Tip: The spectrum of clinical manifestations in progressive familial intrahepatic cholestasis varies from mild to severe leading to end stage liver disease necessitating liver transplantation. Medical therapy forms the mainstay of treatment of pruritus with surgical biliary diversion reserved for refractory cases. Apical sodium bile salt co-transporter inhibitors are among the most promising newer drugs. This article describes the recent advances in understanding the clinical course and emerging therapies.

Citation: Alam S, Lal BB. Recent updates on progressive familial intrahepatic cholestasis types 1, 2 and 3: Outcome and therapeutic strategies. *World J Hepatol* 2022; 14(1): 98-118

URL: <https://www.wjgnet.com/1948-5182/full/v14/i1/98.htm>

DOI: <https://dx.doi.org/10.4254/wjh.v14.i1.98>

fully peer-reviewed by external reviewers. It is distributed in accordance with the Creative Commons Attribution Non Commercial (CC BY-NC 4.0) license, which permits others to distribute, remix, adapt, build upon this work non-commercially, and license their derivative works on different terms, provided the original work is properly cited and the use is non-commercial. See: <https://creativecommons.org/licenses/by-nc/4.0/>

Received: May 22, 2021

Peer-review started: May 22, 2021

First decision: July 6, 2021

Revised: July 17, 2021

Accepted: November 30, 2022

Article in press: November 30, 2021

Published online: January 27, 2022

P-Reviewer: Cheung MCM,
Dabbous H

S-Editor: Wang JJ

L-Editor: A

P-Editor: Wang JJ



INTRODUCTION

Progressive familial intrahepatic cholestasis (PFIC) is estimated to affect 1 in 50000-100000 births[1]. With improved awareness about the various presentations of these bile transport disorders, we now know that the clinical presentation can vary from early-onset severe liver disease to episodic late-onset occurrence triggered by an external stimulus. **Figure 1** describes the various transporters which are involved in different types of PFIC. This article will focus on the PFIC types 1, 2 and 3. **Table 1** depicts the phenotype and genotype of these three types of PFIC.

FAMILIAL INTRAHEPATIC CHOLESTASIS 1 DEFICIENCY

Prevalence of familial intrahepatic cholestasis 1 (FIC1) deficiency is 10.4%-37.5% amongst the cholestatic disorders[2]. Earlier known as Byler's disease, seen predominantly in children of Amish descent, this disease is now known to occur in all racial and ethnic groups.

Pathogenesis

FIC1 is encoded by the ATPase phospholipid transporting-8B1 gene (ATP8B1), located on chromosome 18 and responsible for maintaining the asymmetric distribution of phospholipids across the lipid bilayer by the flippase movement of phospholipids from the outer lipid leaflet of the canalicular membrane to the inner lipid leaflet. Earlier it was believed that FIC1 was responsible for the flippase movement of phosphatidyl-serine, but it is now proven that the preferred substrate is phosphatidyl-choline[3]. Phosphatidyl-choline helps in protecting the canalicular membrane from hydrophobic bile acids (BA). Hence, in the absence of FIC1, proteins in the canalicular membrane such as the bile salt export pump (BSEP) can have impaired function. ATP-binding cassette subfamily B member 4 (ABCB4) and ATP8B1 maintain lipid asymmetry which is important for the integrity of the canalicular membrane. When ABCB4 flops the phosphatidyl-choline, there is destabilization of the canalicular membrane which is counteracted by the flippase activity of FIC1. Hence by maintaining the integrity of the canalicular membrane, FIC1 maintains the function of multidrug-resistant type 3 (MDR3) which is also known as ABCB4[4]. The mechanism by which loss in ATP8B1 leads to cholestasis is poorly understood, but it has been proposed that an abnormal lipid packing (due to the loss in ATP8B1 flippase activity) makes the outer leaflet of the canalicular membrane susceptible to bile salt-mediated extraction of cholesterol and phospholipids. This results in reduced activity of ABCB11, a major bile salt exporter that has also been linked to PFIC2[5-7]. Further, the lower expression of FIC1 down-regulates farnesoid X receptor (FXR) expression, encoded by the NR1H4 gene. FXR has a dual action. FXR in hepatocytes regulates the secretion of bile through BSEP and FXR in enterocytes regulates bile salt reabsorption through apical sodium-dependent bile acid transporter (ASBT)[8].

FIC1 is expressed in a variety of tissues, including the canalicular membrane of hepatocytes, apical membrane of cholangiocytes, brush border of enterocytes and cochlear hair cells[9]. Hearing loss is attributed to defects in the composition of membranes of inner ear cilia. Knockdown ATP8B1 in Caco-2 cell model of intestinal epithelium leads to an unorganized apical actin cytoskeleton and post-transcriptional defect in apical protein expression. This prevents the movement of the ATP8B1 into the apical membrane further causing inhibition of ASBT through the intestinal FXR, eventually resulting in bile malabsorption and diarrhea[8]. FIC1 is also expressed in the pneumocytes where ATP8B1 inhibits cardiolipin. Hence deficiency of ATP8B1 increases the cardiolipin which can disrupt surfactant function within pulmonary alveoli and increase the risk for pneumonia[10]. ATP8B1 deficiency is also associated with down-regulation of cystic fibrosis transmembrane conductance regulator (CFTR) and increased sweat chloride test in 15% of patients.

Clinical and laboratory presentation

Based on the patients' clinical, laboratory profile, and liver histology, the presentation of ATP8B1 deficiency ranges from a severe (earlier known as PFIC1) to a milder phenotype [earlier known as benign recurrent intrahepatic cholestasis (BRIC)][11].

Severe ATP8B1 deficiency presents in children with refractory cholestasis (typically beginning in early infancy) manifesting as jaundice, severe failure to thrive (disproportionate to the degree of cholestasis), delayed puberty and fat-soluble vitamin deficiency (e.g., coagulopathy of vitamin K deficiency). The jaundice can often be

Table 1 Genotype, phenotype and histopathological differentiation of the various types of progressive familial intrahepatic cholestasis

	PFIC1	PFIC2	PFIC 3
Locus/gene/protein	18q21-22/ATP8B1/FIC1	2q24/ABCB11/BSEP	7q21/ABCB4/MDR3
Known mutations (<i>n</i>) ¹	50	200	300
Clinical profile			
Onset	Early onset	Early onset	Second decade
Age of presentation pruritus	60% by 3 mo	72% by 3 mo	2-3 yr
Jaundice	Severe	Severe	Mild to none
Cirrhosis	Severe; By end of first decade	Severe; Majority within first 2 yr of life	Mild to moderate; By end of first decade
Growth failure	Present 90%	Present 59%	
Others	Diarrhea 61%; Pneumonia 13%; Pancreatitis 12%; Deafness 31%	Gall stones in 32%	Delayed puberty
Progression	Moderate rate of progression	Rapidly progressive	Highly variable rate of progression
Associations with other cholestatic presentations	BRIC; ICP	BRIC, DIC, ICP, HCC	DIC, LPAC; ICP
Laboratory profile			
TBA	High	Very high	High
GGT	Low to normal	Low to normal	High
AST/ALT	Mild elevation	Moderate elevation	Mild elevation
AFP	Normal	High	Normal
Histopathology	As disease progresses, periportal & pericentrilobular fibrosis develops; Leads to bridging fibrosis and micronodular cirrhosis	Canalicular cholestasis, lobular/portal fibrosis and inflammation with giant cells; Severe hepatocellular necrosis	Portal inflammation, portal fibrosis, cholestasis, ductular proliferation
Immunohistochemistry	Canalicular BSEP is normal or faint and MDR3 is normal bland intralobular cholestasis	BSEP expression decreased to absent in the canalicular membrane	MDR3 decreased to absent in the canalicular membrane

¹Medline genetics. BRIC: Benign recurrent intrahepatic cholestasis; BSEP: Bile salt exporter pump; ICP: Intrahepatic cholestasis of pregnancy; HCC: Hepatocellular carcinoma; DIC: Drug induced cholestasis; FIC1: Familial Intrahepatic Cholestasis-1; LPAC: Low-phospholipid-associated cholelithiasis; MDR3: Multidrug resistant protein-3; PFIC: Progressive familial intrahepatic cholestasis; ABCB: ATP-binding cassette subfamily B.

intermittent. The liver disease is progressive causing secondary biliary cirrhosis and end-stage liver disease. Pruritus is often disproportionate to hyperbilirubinemia but correlates with the serum BA levels[1]. Symptoms begin in the first month of life in 15% of patients and by 3 mo of age in 61% of patients with PFIC1[12]. Undernutrition is generally responsible for poor growth. However, proportionate growth failure and delayed puberty together suggests a likely systemic manifestation of ATP8B1 deficiency. BA is high and serum cholesterol is characteristically low. ATP8B1 deficiency is associated with extrahepatic manifestations such as hearing loss, pancreatitis (8%) or pancreatic exocrine insufficiency, kidney stones, resistance to parathyroid hormone and diarrhea (61%) not attributable to fat malabsorption[9,13]. The severe form of ATP8B1 deficiency may be associated with congenital hypothyroidism (both clinical + subclinical) which can be treated[14]. Coarsely granular canalicular bile may be found on electron microscopy which may improve after the administration of ursodeoxycholic acid (UDCA). A recent multi-centric study included 130 patients with pathological ATP8B1 mutations and low-gamma-glutamyl transpeptidase (GGT) cholestasis phenotype[15]. Among these patients, 15 initially presented as BRIC that later evolved into a severe FIC1 phenotype. Age at first presentation to the tertiary center was 0.6 (0.3-2.2) years, illustrating an early onset of disease. Hepatocellular carcinoma (HCC) was not seen in any of the patients, either before transplantation or in the explants.

Mild ATP8B1 deficiency: Episodic cholestasis beginning later in childhood, adolescence or young adulthood usually rules out severe disease. The presentation may

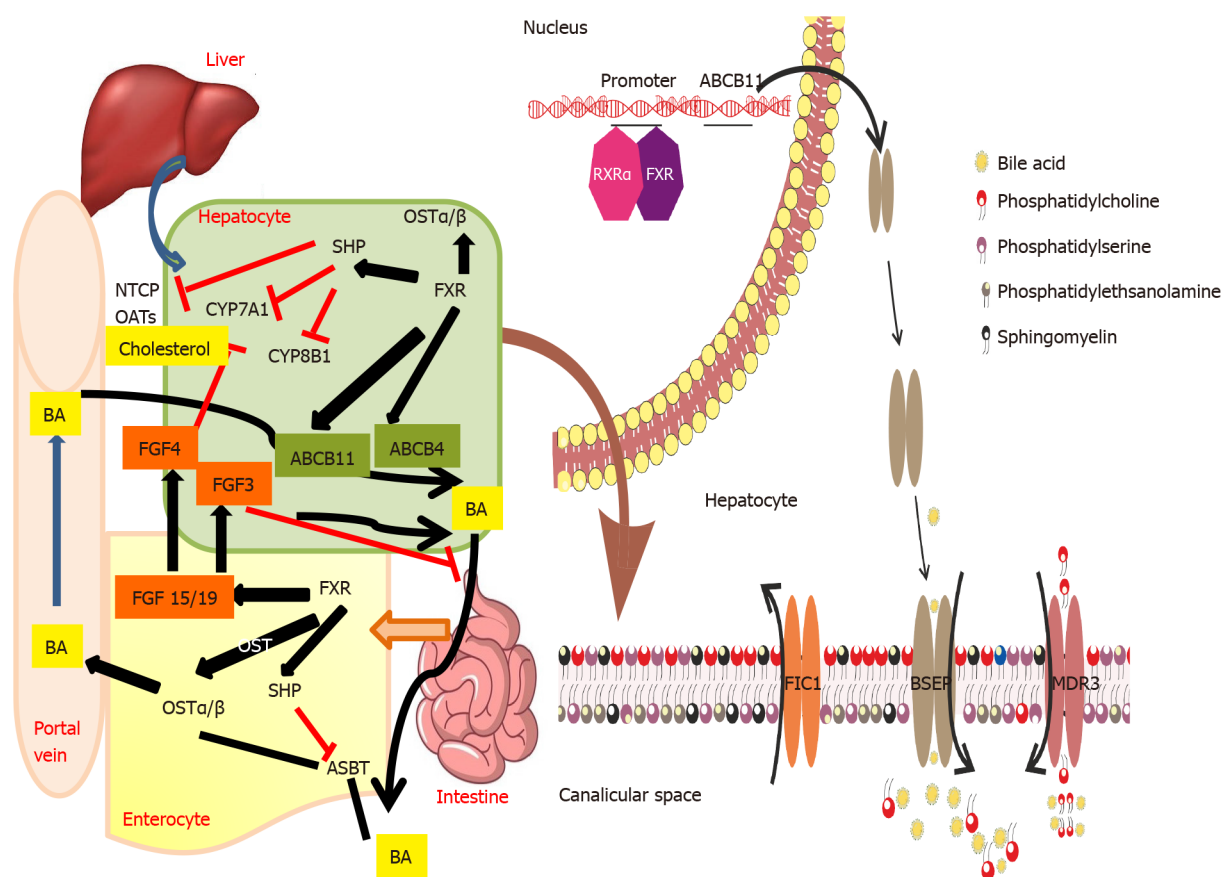


Figure 1 Bile acid secretion and transport from the hepatocyte across the canalicular membrane and enterohepatic circulation: Role of various transporters involved in transport of bile salts and phospholipids across the canalicular membrane. Enterohepatic circulation of bile salts and their regulation *via* farnesoid X receptor - fibroblast growth factor 15/19 is also depicted. ABCB: ATP-binding cassette subfamily B; FXR: Farnesoid X receptor; FGF: Fibroblast growth factor; FIC1: Familial intrahepatic cholestasis 1; BSEP: Bile salt exporter pump; MDR3: Multidrug-resistant type 3; BA: Bile acids; NTCP: Sodium taurocholate cotransporting polypeptide; OATs: Organic anion transporters.

include pruritus without jaundice or presence of mild jaundice. Episodes may last from weeks to months and symptom-free intervals may vary from months to years. The intermittent disease pattern is usually associated with different or unknown triggers which may include fever or any other inter-current illness, drugs (such as contraceptives), malignancy, hormonal changes or pregnancy. BA is high and serum cholesterol is low during symptomatic periods. Histopathological findings during the symptomatic periods may be milder, yet similar to that seen in severe form.

Genotypic variation

In a recent study with 18 potential disease-causing mutations in ATP8B1, 14 patients (4 homozygous, 6 compound heterozygous, 4 heterozygous) were below 18 years of age and had a median age of 0.75 years[16]. Overall, 28 different genetic variants were identified including two common single nucleotide polymorphisms (SNPs) (p.R952Q and c.3531+8G>T)[16]. These variants have been described earlier in European patients with intrahepatic cholestasis of pregnancy (ICP)[17] and pancreatitis[13]. Pathogenic variants with underlying severe ATP8B1 deficiency are likely to be fully penetrant but some of the milder variants may not become symptomatic even in adulthood. The p.Ile661Thr pathogenic variant, which is frequently detected in people with a mild disease of European descent, appears occasionally to be non-penetrant. However, it is also found in compound heterozygous form in persons with severe disease. A multicentric study on FIC1 patients further classified the patients based on the presence of predicted protein-truncating mutations (PPTMs) (*i.e.*, splice site, frameshift due to deletion or insertion, nonsense, duplication)[15]. FIC1-A patients harbored no PPTMs, FIC1-B patients had one PPTM, and FIC1-C patients manifested two PPTMs. Patients with FIC1-C genotype presented to the referral center at 0.4 (0.2-0.7) years, which is significantly earlier as compared to FIC1-A [0.8 years; interquartile range (IQR): 0.4-3] and FIC1-B (0.9 years; IQR: 0.4-2.7) respectively ($P = 0.004$). At presentation, levels of BA, aminotransferases, and GGT were comparable among the three genotype groups.

FIC1-B patients had the highest bilirubin levels. Half the cases of FIC1-A were receiving UDCA at presentation but did not show a significant improvement biochemistry in comparison to the other patient groups.

Natural history and outcome

The majority of the severe variants of ATP8B1 deficiency will have disease onset within infancy. Some may experience episodes of severe cholestasis followed by disease-free intervals with eventual persistence of cholestasis. Malnutrition and fat-soluble vitamin deficiencies can cause significant morbidity, if left untreated. Features of chronic liver disease and portal hypertension may develop leading to cirrhosis by the end of the first decade of life but variations have been noted within families[15]. Without surgical intervention, end-stage hepatic failure and death usually occur in the second decade of life. In some of those with mild disease, clinical monitoring may reveal a shift in the clinical spectrum from mild intermittent disease to more persistent cholestasis and fibrosis on the follow-up biopsies[2]. The Natural course and Prognosis of PFIC and Effect of biliary Diversion (NAPPED) consortium data revealed that 8 of 130 patients (6%) died before liver transplantation (LT), of which 3 had undergone surgical biliary diversion (SBD)[15]. Survival analysis showed that at 18 years of age, 44% of patients were alive with their native liver. Three-fourths of those alive with their native liver had undergone SBD by 18 years and a significantly lower percentage of patients with a FIC1-C genotype underwent SBD (FIC1-A 65%, FIC1-B 57%, FIC1-C 45%; $P = 0.03$). Native liver survival (NLS) was comparable between the three genotype sub-groups at 10 years of age (FIC1-A 67%, FIC1-B 41%, FIC1-C 59%; $P = 0.15$) with or without SBD. However, the proportions of total patients alive with the native liver at the age of 10 years were lower in patients without SBD than in patients who had undergone an SBD during follow-up.

BSEP DEFICIENCY

BSEP is a liver-specific transporter involved in actively transporting monovalent bile salts out of hepatocytes into biliary canaliculi against a concentration gradient. BSEP is encoded by the ABCB11 gene located on chromosome 2q31. Homozygous or compound heterozygous mutations in this gene results in PFIC2[18].

Pathogenesis

Chenodeoxycholic acid (CDCA) and the Retinoid X Receptors (FXR) α -heterodimer together activate the ABCB11[18]. Increasing bile acid concentration in the hepatocytes stimulates greater synthesis of BSEP to maintain equilibrium. There are over 200 mutations of ABCB11 causing PFIC2[18]. Common mutants that cause retention of the protein in the endoplasmic reticulum are G238V, D482G, G982R, R1153C, R1286Q, and Δ Gly. The mutant protein that is retained and translocated out of the endoplasmic reticulum is then broken down by proteasomes[19]. Intrahepatic accumulation of bile salts and inflammation promote carcinogenesis through genomic modifications[19]. Metabolomic studies have shown that ABCB11 knock-out mice have impaired mitochondrial fatty acid β -oxidation with the resulting increase in reactive oxygen species that might exacerbate the liver injury[19].

Clinical and laboratory presentation

BSEP deficiency is the most common subtype of PFIC (with an estimated incidence of 1 in 50000 to 1 in 100000)[8]. It accounts for 37.5%-90.9% of cholestatic patients in the 9 studies that were analyzed in a systematic review[2]. Symptoms appear in the first month of life in 44% and by 3 mo of age in 72%[12]. Some patients with BSEP deficiency also present with early signs of vitamin D deficiency (rickets 3%-22%), vitamin K deficiency (bleeding 8%) or cholelithiasis (28%)[8,12]. High serum alanine aminotransferase and alpha-fetoprotein levels, early liver failure, cholelithiasis, HCC, very low biliary BA concentration, and negative BSEP canalicular staining suggesting PFIC2 (Figures 2A and 2B)[12]. In infancy, PFIC2 has mild to severe portal and lobular fibrosis with bridging fibrosis. Beyond infancy, advanced portal and lobular fibrosis are observed[2]. Early progression to HCC is described[19]. For more details see Table 1.

Genotypic variation

Of the 252 patients with cholestatic liver disease screened for ABCB11, 88 (34.9%) were identified with at least one disease-causing BSEP mutation with the median age of

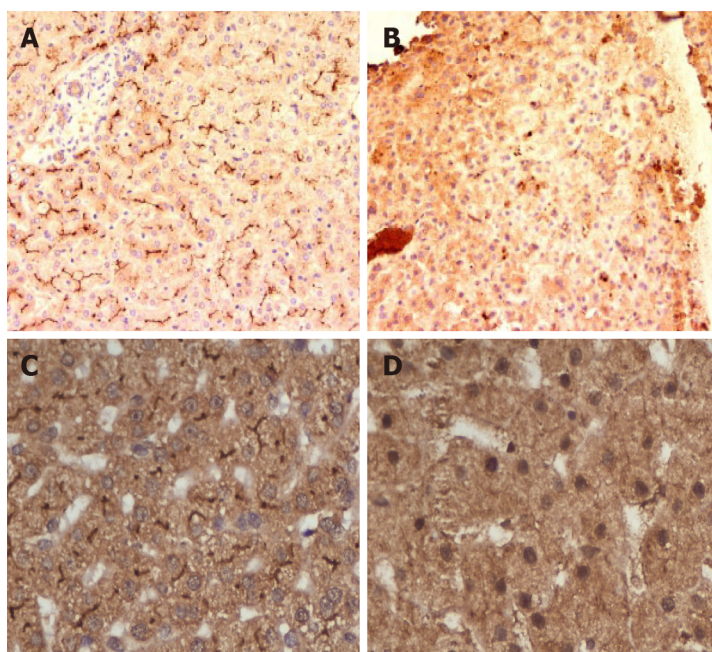


Figure 2 Immunohistochemistry of progressive familial intrahepatic cholestasis type 2 and 3. A: Normal liver showing canalicular bile salt exporter pump (BSEP) immunostaining; B: Faint BSEP immunostaining in a case of progressive familial intrahepatic cholestasis (PFIC2); C: Normal Liver showing canalicular multidrug resistant protein-3 (MDR3) immunostaining; D: Faint or absent MDR3 immunostaining in a case of PFIC3.

disease onset being 0.75 years[16]. 64.3% had no disease-causing mutation but at least one BSEP SNP. Amongst the common SNPs, p.A1028A was found in 197 of 252 families and p.V444A in 204 of 252 families of this cohort. The most common PFIC-2 mutations were p.E297G, p.D482G, and p.N591S. Apart from PFIC2, ABCB11 mutations cause BRIC2, ICP, contraceptive induced cholestasis and drug-induced cholestasis[16]. Four potential ABCB11 mutations and a donor splice site mutation (intron 19) were identified in 147 women with ICP[17]. Please also see the section on BRIC2 and ICP.

A global consortium on BSEP deficiency categorized the mutations as BSEP1 [p.D482G (c.1445A>G) or p.E297G (c.890A>G) mutation], BSEP2 (at least 1 missense mutation, not p.D482G or p.E297G) or BSEP3 (mutations leading to a predicted non-functional protein)[20]. Patients with BSEP1 genotype (p.D482G and p.E297G) have residual BSEP functionality and thus have a milder phenotype as compared to patients exhibiting BSEP2/BSEP3 genotype. There is wide geographical variations in genotype with the commonest mutations found in a study from Shanghai being c.145C>T (p.Gln49Ter) and c.2594C>T (p.Ala865Val)[21]. Severe phenotypes are often associated with mutations leading to premature protein truncation or failure of protein production. Insertion, deletion, nonsense and splicing mutations exhibit little or no detectable BSEP at the hepatocyte canalicular membrane.

Natural history and outcome

PFIC2 is likely to have more severe lobular injury, portal fibrosis and inflammation than PFIC1. Hepatocellular necrosis and giant cell transformation are also much more pronounced in PFIC2 than in PFIC1 and may persist with time. Majority of homozygous or compound heterozygous mutations present as severe disease in infancy with progressive liver disease which requires LT. Despite treatment, 76%-100% of PFIC2 continue to have pruritus with progression to severe liver disease and this may occur as early as 7 mo of age. Advanced portal and lobular fibrosis are seen in children beyond infancy[12]. Among patients undergoing LT, liver failure and/or HCC were detectable in about 60%. Liver samples obtained from 10 children with HCC aged 13-52 mo showed that 9 had evidence of BSEP deficiency and/or mutations in ABCB11. Recently, HCC and/or cholangiocarcinoma was described in 15% of those with PFIC2. Hence, close monitoring of these children particularly those carrying 2 null mutations is essential[22]. Children with transient neonatal cholestasis harbour non-null variants, express immune-histochemically detectable BSEP and have better outcomes[21].

The global NAPPED consortium reported that 23.1% PFIC2 had undergone SBD and 46.1% had undergone LT[20]. In total, 16 (6%) [BSEP1: $n = 3/72$ (4%), BSEP2: $n = 8/136$ (6%), BSEP3: $n = 5/56$ (9%)] died prior to LT at a mean age of 1.6 years. NLS was 32% at 18 years of age. Five patients underwent LT beyond 18 years of age (19.6-27.5 years). Patients with mutations categorized as BSEP1 had better long-term outcomes than those with BSEP2 or BSEP3, with a median NLS of 20.4 years, 7 years and 3.5 years respectively. The incidence of HCC increased with the genotype severity from 4% in BSEP1 to 7% in BSEP2 and 34% in BSEP3. HCC occurred in 3% of patients who had SBD as against 7% who had not received SBD[20].

MDR3 DEFICIENCY

Pathogenesis

This autosomal recessive condition is caused by mutations of the MDR3 glycoprotein, which is coded by the ABCB4 gene located on chromosome 7q21. The gene consists of 27 coding exons spanning-74 kb[23]. ABCB4/MDR3 P-glycoprotein consists of six intracellular domains and six extracellular loops separated by twelve transmembrane domains. The protein contains two intracytoplasmic ATP-binding domains, also known as nucleotide-binding domain. The nucleotide-binding domains provide energy for the trans-membrane transfer of the substrate against the concentration gradient. The trans-membrane domains in turn provide specificity for the substrate. A study on fetal liver demonstrated that ABCB4 mRNA levels are 16-fold lower compared to the normal adult liver with only faint and focal canalicular MDR3 immunostaining suggesting that ABCB4 normally develops late in gestation or possibly in the postnatal period. The protein is present in the canalicular membrane of hepatocytes and transports phosphatidyl-choline from the hepatocytes to the bile canaliculi. Phosphatidyl-choline is a key component of micelles which keeps the cholesterol in soluble form thus protecting the cholangiocytes from damage. In presence of abnormal MDR3, phosphatidyl-choline is not transported across to the bile canaliculi leading to abnormal micelle formation. Inadequate micellar formation results in presence of insoluble bile salts and cholesterol in the biliary canaliculi which damage the cholangiocytes. Cholesterol is more likely to crystallize into stones, damaging liver structures by obstructing small bile ducts.

Clinical and laboratory presentation

These patients present with a wide spectrum of manifestations ranging from transient neonatal cholestasis, episodic cholestasis, gall stones, cirrhosis to end-stage liver disease[24,25]. The patients with PFIC3 have elevated GGT and alkaline phosphatase. Bile salts and cholesterol values can be normal while biliary phospholipids are significantly reduced. Age of the onset of PFIC3 can vary widely from the neonatal period to adulthood. PFIC3 often presents later as compared to PFIC1 and PFIC2, as late as adulthood in some cases[25]. The early-onset disease can present with jaundice, pruritus, variceal bleeding (portal hypertension), stunted growth, reduced bone density and learning disabilities[25]. The complete absence of canalicular staining of MDR3 protein is associated with mutations leading to a truncated protein form (Figures 2C and 2D). Those with missense mutations have faint or normal MDR3 canalicular expression. The abnormal MDR3 canalicular expression combined with low levels of biliary phospholipids is highly suggestive of MDR3 deficiency. Histopathological findings associated with PFIC3 include primarily portal-based inflammatory infiltrate with marked periportal ductular reaction. They usually progress to biliary-type cirrhosis, lobular disarray, and hepato-canalicular cholestasis.

Genotypic variation

Degiorio *et al*[26] analyzed ABCB4 gene mutations in 68 PFIC3 patients and found 29 mutations in the coding region and 10 in the transmembrane domains which involved phosphatidyl-choline translocation. Delaunay *et al*[27] devised a classification system for the various forms of these mutations: Class I (nonsense mutations that result in a defective synthesis), class II (missense variations that prevent protein maturation), class III (missense mutants resulting in defective protein activity), class IV (unstable variations) and class V mutants (unknown pathogenicity). These classifications are useful in determining potential therapies for patients. Approximately 300 disease-causing ABCB4 variants have been reported, typically in those with homozygous status who have a rapidly progressive cholestatic liver disease with potentially life-threatening complications. Those with heterozygous status have less severe manifest-

ations.

Natural history and outcome

Patients with residual phosphatidyl-choline secretion and MDR3 expression (especially those with missense mutations), respond to treatment with UDCA in 70% of cases. LT is reserved for patients with PFIC3 associated with end-stage liver disease. The mean age at LT is 9.6 (2-33) years[28]. HCC and cholangiocarcinoma have both been described with PFIC3.

BRIC

BRIC is an autosomal recessive inherited disorder characterized by the intermittent occurrence of severe and recurrent cholestasis[29]. BRIC typically appears later than PFIC and is not progressive. Two genetic forms of BRIC are known; BRIC1 is characterized by the mutations of the ATP8B1 gene while BRIC2 presents a mutation in the ABCB11 gene. BRIC shows a non-progressive course since the protein function is only partially impaired[29]. Most of them have missense mutations located in less conserved regions of the gene. The global NAPPED consortium reported 11 BRIC2 who later presented with persistent cholestasis and progressive liver disease with pathological genetic variants[20].

Association with other cholestatic presentations

ICP is the occurrence of intense pruritus in a pregnant woman without pre-existent liver disorder; beginning usually in the third trimester and resolving completely after delivery. Elevated levels of BA, aminotransferase and alkaline phosphatase are typically present. Although the disease is benign in the mothers, poor fetal outcomes have been reported. Heterozygous mutations in ABCB4, ABCB11, ATP8B1, ABCC2 and tight junction protein 2 have been associated with ICP[30]. While GGT is normal in ABCB11-related forms of estrogen-associated cholestasis, increased GGT levels could serve as a discriminating feature of ABCB4 deficiency.

The associations of heterozygous missense and nonsense ABCB4 mutations in cryptogenic liver fibrosis and biliary cirrhosis have been reported[28,31]. The histomorphological phenotype associated with ABCB4 mutations includes portal fibrosis with periportal ductular proliferation. Early diagnosis and therapy with UDCA may slow down fibrosis progression in few cases. Some cases of ABCB4 mutations may also present with chronic cholangiopathy[32].

MDR3 deficiency also leads to gallbladder disease or low phospholipid-associated cholelithiasis (GBD-1/LPAC)[32]. There is more evidence that either biallelic or monoallelic ABCB4 defects may cause or predispose patients to a wide spectrum of human liver diseases such as LPAC, small duct sclerosing cholangitis and adult biliary fibrosis or cirrhosis[28]. Liver cirrhosis accompanied by vanishing bile duct syndrome (ductopenia) in ABCB4 deficient patients have been reported[33].

ABCB11 and ABCB4 deficiency may predispose to the cholestatic liver injury induced by oral contraceptives, psychotropic drugs, selected chemotherapy drugs, statins, and antibiotics[34]. The common variant p.Val444Ala in ABCB11 is associated with an increased risk of drug-induced liver injury[35]. Most cases improve on withdrawing the drug and adding UDCA. Recent studies have demonstrated, that ABCB4 mutations (c.504C>T and c.485T>A in exon 6 and c.2793 frameshift mutation in exon 23) are possibly involved in the development of parenteral nutrition-associated liver disease in premature infants[36].

THERAPEUTIC STRATEGIES FOR PFIC

The holistic management of patients with PFIC includes their nutritional rehabilitation, fat-soluble vitamin supplementation, control of pruritus, prevention of fibrosis progression and LT for those with end-stage liver disease.

Nutritional rehabilitation

Chronic malnutrition due to cholestasis and steatorrhea affects almost all children with PFIC, especially those with PFIC1[37,38]. Apart from cholestasis-related malabsorption, complex interactions of the liver with the hypothalamus-pituitary-adrenal axis in chronic cholestasis have been advocated as one of the mechanisms for growth failure in these children[39]. Severe cholestasis leads to deficiency of fat-soluble vitamins (FSV) with decreased bone mineral density, often refractory to FSV supplementation[38]. Meticulous nutritional assessment should be performed and

documented at the first visit. The goal of nutritional rehabilitation should be to give calories around 125% of the recommended daily dietary allowance for the ideal weight targeting around 180-200 cal/kg/d along with high protein about 2-3 g/kg/d[38]. FSV should be supplemented orally: Vitamin A 5000-10000 IU/d; Vitamin D (cholecalciferol) 2000-5000 IU/d; Vitamin E 50-400 IU/d and Vitamin K 5 mg/wk to 5 mg/d [40]. Weekly or daily supplementation of FSV, especially vitamin D, is more effective than large bolus doses for the treatment of vitamin D deficiency in children with chronic liver disease[41]. Refractory deficiency or those with significant bony changes should be treated with calcitriol at a dose of 0.05-0.2 µg/kg[40]. The oral water-soluble liquid formulation of FSV containing vitamins A, D, E and K have shown to be more efficacious than conventional preparation in infants and children with cholestatic liver disease. Medium-chain triglycerides should be supplemented as they are absorbed directly into the portal circulation and are not affected by cholestasis[40].

Treatment of pruritus

Pruritus is the most disabling symptom of PFIC disturbing daily activities, schooling and sleep. A step-up approach of medical therapy is advocated in children with pruritus. SBD is a very useful tool in medical non-responders (Figure 3). Table 2 lists the drugs used for the management of pruritus with their mechanism of action, dose and adverse effects. Apart from medical therapy, trimmed nails, full-sleeve clothing-stockings during sleep and well moisturized skin are advocated. Various tools like visual analog scale, Whittington scale or 5D-pruritus score have been used for objective measurement of pruritus and to assess response to medications or surgical therapy [42].

Role of medical therapy

UDCA leads to complete resolution of pruritus in about a third of children with PFIC2 [38] and response is mainly dependent on the mutation and resultant residual protein expression[24]. Long-term therapy with UDCA has been shown to reverse fibrosis in MDR3 heterozygotes with residual protein expression[43]. The role of rifampicin in management of pruritus has been established by meta-analyses (pooled odds ratio of 15.2 for complete/partial relief) as compared to placebo/alternative therapy[44]. Bile acid sequestrants are less favourable in children due to non-palatability[38]. Spacing is needed from food and other drugs leading to loss of compliance and optimal effect [45]. Opioid antagonists can ameliorate pruritus, although with increased incidence of adverse events[44]. Sertraline, a selective serotonin reuptake inhibitor is also beneficial for the relief of pruritus. Sertraline has high first-pass metabolism in the liver and should be used with caution. The other drugs with equivocal efficacy for control of pruritus in PFIC include ondansetron, phenobarbitone and antihistaminics[40,41]. Newer modalities to treat pruritus of cholestasis that have not been extensively analyzed in studies include albumin dialysis using molecular adsorbent recirculating system, plasmapheresis and endoscopic nasobiliary drainage[46]. Plasmapheresis reduces autotaxin activity thereby reducing lysophosphatidic acid and reducing pruritus in ICP.

Surgical interruption of enterohepatic circulation

Commonly used SBD include partial external biliary diversion (PEBD), ileal exclusion (IE) and partial internal biliary diversion (PIBD). Figure 4 shows a schematic representation of the various diversion surgeries, techniques and their common complications. PEBD, although being the most widely used diversion surgery is associated with a host of stoma-related complications[47-49]. Recently, external fistulae have been intubated with gastrostomy devices for intermittent drainage[49]. IE[50,51] and PIBD [52,53] are therapeutic options in those with failed PEBD or for better cosmetic results, especially in adolescents. Recent studies on SBD with their outcome and complications have been tabulated in Table 3[51-55]. Biliary diversion leads to a relatively higher ratio of cholic acid to CDCA in bile, reduced taurine-to-glycine conjugate ratio, increase in secondary bile acid pool, ultimately causing bile to become more hydrophilic[55]. Total biliary diversion involves diverting all the bile flow from the common bile duct to the exterior through a jejunal loop. It is usually reserved for pruritus refractory to PEBD or to prevent and treat allograft steatosis in post LT PFIC1 [56]. Irrespective of the technique used, biliary diversion surgeries lead to a decrease in the concentration of BA, improvement in pruritus score, growth spurt, histological improvement and even reversal of fibrosis in some cases[38,47]. There are no head-to-head trials to compare the efficacy and safety of these techniques. Post SBD, the child should be monitored for improvement in pruritus, changes in growth parameters and for decrease in BA and bilirubin in the serum. Recently, the NAPPED consortium and

Table 2 Drugs used for control of pruritus in progressive familial intrahepatic cholestasis: Mechanism of action, dose, adverse effects

Drug	Mechanism of action	Dose	Adverse effects
Ursodeoxycholic acid	Protection of cholangiocytes from the hydrophobic bile acids; Choleretic action through both bile acid dependent (cholehepatic shunt) and independent pathway; Protection of hepatocytes from bile acid induced apoptosis; Direct membrane stabilizing effect in cholangiocytes; Up-regulate synthesis, apical insertion & activation of BSEP & Mrp2 <i>via</i> Ca ²⁺ and PKC-dependent mechanisms or <i>via</i> activation of p38 MAPK and Erk-1/2-dependent mechanisms in animal models	10-30 mg/kg/d	Adverse effects rare: Severe vomiting or diarrhoea
Rifampicin	Activates pregnane X receptor leading to decrease in autotoxin level thus leading to decrease in lysophosphatidic acid synthesis and down-regulation of TRP vanilloid 1; Upregulates multidrug-resistance protein 2; Activates enzymes UDP-glucuronosyltransferase-1A and cytochrome P450-3A4 and stimulates 6 α -hydroxylation of bile acids, promoting urinary excretion of dihydroxy and monohydroxy bile acids	5-10 mg/kg/d	Adverse effects rare: Hepatotoxicity, vomiting
Bile acid sequestrants: Cholestyramine, colestipol, colesevelam	Non-absorbable anion exchange resins that bind bile acids, cholesterol and other compounds in the intestinal lumen and prevent their enterohepatic circulation	240-500 mg/kg/d; Usually administered mixed with juice	Palatability, steatorrhea, constipation, intestinal obstruction from inspissations, hyperchloremic metabolic acidosis; Growth failure; Decreased absorption of other drugs (<i>e.g.</i> , UDCA) if not spaced; Need to be spaced from food
Opioid antagonists: Naltrexone	Reduces central opioidergic tone, believed to be raised in patients with cholestatic pruritus; Decreasing plasma levels of endogenous opioids like enkephalins	Gradually increment starting at 12.5 mg/d increasing every 3-7 d till pruritus reduces	Opioid withdrawal-like symptoms including abdominal pain, tachycardia and hypertension
Selective serotonin reuptake inhibitors: Sertraline	Exact mechanism of action not elucidated; Mediates its effect through serotonergic signals in the central nervous system that provide inhibitory signals to the itch pathways; Neuropharmacologic inhibition of stress	Adults: 75-100 mg/d; Children: 2.2 mg/kg/d	Adverse effects: Allergic reaction, behavioural issues, diarrhoea, insomnia, dizziness, high first pass metabolism-risk of hepatotoxicity

BSEP: Bile salt export pump; PKC: Protein kinase C; MAPK: Mitogen-activated protein kinase; TRP: Transient receptor potential; UDP: Uridine diphosphate; UDCA: Ursodeoxycholic acid.

another meta-analysis have shown improved NLS in those with common missense mutations (D482G or E297G) and in those with more than 75% reduction in BA post SBD[20,57]. Around 18%-39% of children undergoing SBD require LT in 5-10 years of follow-up, mostly those with advanced fibrosis at the time of SBD and those with failure of SBD[51-55]. Those with advanced fibrosis do not show a reduction in serum BA with biliary diversion surgeries, hence a liver biopsy should precede the surgery [57]. The choice of biliary diversion technique depends on the patient's preference and experience and comfort of the surgeon/centre. Health-related quality of life is comparable between those undergoing PEBD for PFIC and healthy controls.

LT

LT is indicated in children with end-stage liver disease, advanced fibrosis and those with refractory pruritus despite biliary diversion surgeries, yet it is fraught with its unique complications and conundrums in children with PFIC[58]. PFIC is one of the most common indications accounting for 13.4% of total pediatric LT[59]. LT in patients with PFIC2 and PFIC3, where the mutation affects only the liver has resulted in excellent graft and patient survival[37]. On the other hand, due to a wide extrahepatic tissue distribution of FIC1 expression, LT for PFIC1 has been associated with a high risk of complications due to the involvement of these extrahepatic sites after LT[60]. There are three unique issues related to LT in PFIC: (1) High rate of graft failure, allograft steatosis and diarrhea in PFIC1; (2) Antibody-induced BSEP deficiency leading to graft loss in PFIC2; and (3) Utilization of heterozygous family members as donors in living donor LT program.

Allograft steatosis, refractory diarrhea and graft failure in PFIC1: Post LT in PFIC1, the graft liver starts to secrete and excrete normal amounts of bile salts which can't be handled by the intestines as the intestinal FIC1 is still defective leading to intractable diarrhea[60]. This plausible mechanism for intractable diarrhea is further strengthened by the clinical response to bile adsorption resins and total biliary diversion. FIC1 in the

Table 3 Recent studies describing outcome and complications with biliary diversion surgeries in progressive familial intrahepatic cholestasis

Study	Type of biliary diversion	No of patients	Median follow up	Outcome	Adverse events
Yang <i>et al</i> [54] (2009)	PEBD	14 (11-PFIC)	3.1 yr (2-5.7)	Resolution of pruritus: 50%; Decrease in pruritus: 21%; Decrease in serum bile acids; Improvement in growth; Improved quality of life; No response in 2 patients with advanced fibrosis; 21.4% were listed for LT at mean follow-up 3.2 yr (all had advanced fibrosis pre-PEBD)	3 developed stoma prolapse; Post-op bleed and wound dehiscence in 1 each
Schukfeh <i>et al</i> [55] (2012)	PEBD	24	9.8 yr (1.6-14.3)	Resolution of pruritus with normalization of bile acids in 54%; 37.5% received LT at mean 1.9 yr; All of them had failed PEBD & 78% of them had cirrhosis pre-PEBD	Stomal prolapse in 2; Cholangitis, dyselektrolytemia, GI bleed and intestinal obstruction in 1 each
Wang <i>et al</i> [50] (2017)	PEBD; IE; PIBD	39; 11; 7; (38 PFIC & 20 alagillesyndrome)	24 mopostsurgery	Decrease in severe pruritus-54% in PFIC1 and 30% in PFIC2; Trend towards decreased pruritus after IE and PIBD; PEBD but not IE led to decrease in bilirubin and ALT in PFIC1; 23.7% of PFIC underwent LT post diversion	PEBD: Dehydration/ dyselektrolytemia in 4; Stoma prolapse in 3; Intestinal ischemia & bowel obstruction in 1 each; IE; Dyselektrolytemia-2; PIBD: Dyselektrolytemia in 2, intestinal ischemia & intussusception-1 each
Cielecka-Kuszyk <i>et al</i> [47] (2019)	PEBD	4 (all PFIC2)	> 10 yr	Resolved cholestasis in 3; Reversal of fibrosis in 2	
Bull <i>et al</i> [48] (2018)	PEBD; IE	57; 6		Sustained improvement in pruritus: PFIC1-57%; PFIC2 (D482G/E297G mutations)-76%; PFIC2 other mutations-33%; Improvement in bilirubin and bile acids; Improvement in growth; 27% of PFIC1 & 31% of PFIC2 were listed or received LT (less often in D482G/E297G)	Dehydration/ dyselektrolytemia due to high stoma output seen in 6 patients (1 died); Cholangitis in 3; Bile stagnation in 2; Stoma bleed in 1
Van Wessel <i>et al</i> [20] (2020)	PEBD; IE; PIBD	47; 13; 1; (all PFIC2)	8.4 yr (1.6-12)	Relief in pruritus – sustained: 54%; Transient: 17%; None: 29%; Relief in pruritus more common in BSEP1 mutations (66%) vs BSEP2 (36%) & BSEP3 (0%); Decrease in serum bile acids, bilirubin, AST & ALT; A 75% reduction in bile acids or decrease to a level < 102 μmol/L post diversion predicts long term NLS of > 15 yr; Biliary diversion associated with higher NLS: HR 0.51; 95%CI: 0.29-0.91, P = 0.02	
Bjørnland <i>et al</i> [49] (2021)	PEBD	33; (25 PFIC)	10 yr (0.6-25.2)	Decrease in bile acids 1 wk post-op predictive of successful drainage; 39% received LT or were listed LT at a median follow up of 10 yr	42% early post op complications; Long term stoma related complications in 55%-20% secondary surgeries
Van Vaisberg <i>et al</i> [51] (2020)	IE	11	5 yr	Significant relief in pruritus: 8 (72.7%); 2/11 (18.2%) progressed to ESLD within a year and were listed for LT	Intussusception in 1; No diarrhoea
Foroutan <i>et al</i> [53] (2020)	PIBD	44	54 mo (10-105)	Significant decrease in jaundice and pruritus	Ascending cholangitis in 19.2%; No difference in cholangitis between standard procedure and PIBD with anti-reflux valve
Chen <i>et al</i> [52] (2018)	PIBD	34; (PFIC1-10, PFIC2-14, PFIC3-5)	-	Decreased bilirubin and bile acids; Improved growth; 2 (5.9%) underwent LT at 20 & 39 mo post PIBD	Dyselektrolytemia/ dehydration in 2; Relapse of symptoms in 4
Agarwal <i>et al</i> [38] (2016)	PIBD; PEBD	3; 1	2 yr (1-2)	PIBD: Decrease in pruritus score, improved growth & decreased serum bile acids; PEBD: Failed; One with failed PEBD needed LT in 7 yr; Rest all survived with native liver at mean follow up 8 yr	No complications with PIBD
Bull <i>et al</i> [48] (2018)	PEBD; IE	57; 6		Sustained improvement in pruritus: PFIC1-57%; PFIC2 (D482G/E297G mutations)-76%; PFIC2 other mutations-33%; Improvement in bilirubin and bile acids; Improvement in growth; 27% of	Dehydration/ dyselektrolytemia due to high stoma output seen in 6 patients (1 died); Cholangitis in 3; Bile stagnation in 2; Stoma bleed in 1

PFIC1 & 31% of PFIC2 were listed or received LT (less often in D482G/E297G)

PEBD: Partial external biliary diversion; PIBD: Partial internal biliary diversion; PFIC: Progressive Familial Intrahepatic Cholestasis; IE: Ileal Exclusion; AST: Aspartate aminotransferase; ALT: Alanine aminotransferase; TBD: Total biliary diversion; LT: Liver transplantation; NLS: Native Liver Survival; BSEP: Bile salt exporter pump; ESLD: End stage liver disease.

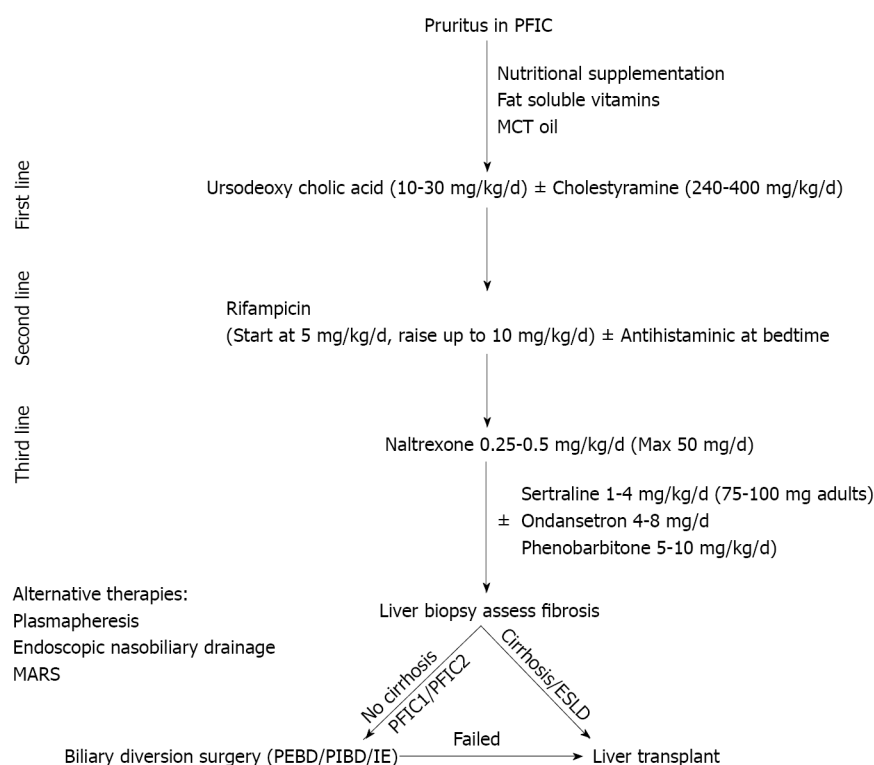


Figure 3 Algorithm for management of pruritus in children with progressive familial intrahepatic cholestasis. PFIC: Progressive familial intrahepatic cholestasis; MCT: Medium chain triglyceride; ESLD: End stage liver disease; PEBD: Partial external biliary diversion; PIBD: Partial internal biliary diversion; IE: Ileal exclusion.

intestine which has a strong correlation to SLC10A2, the ileal sodium/bile acid co-transporter is defective in PFIC1 leading to the impaired enterohepatic circulation of bile salts[61]. When the intestine of these patients which are defective in FIC1/SLC10A2 starts receiving a normal amount of BA secreted by the graft liver, it leads to bile acid diarrhea, steatosis and graft fibrosis necessitating re-transplant[60]. Hori *et al*[37] reported chronic diarrhea in 91%, grade 3 steatosis in 72.7% and significant graft fibrosis in 82%; 27% died at a median of 12 years post LT and 3 required re-transplant. Davit-Spraul *et al*[25] reported extrahepatic complications post LT in 100% of PFIC1 and one-third required re-transplant for massive steatosis. There is a recurrence of steatosis and graft failure even in the second graft[12,60]. The genetic analysis predicts the patients likely to develop these complications and thus pre-LT genetic analysis should be considered mandatory for patients with PFIC1[60]. Total internal biliary diversion during the time of LT has been described as a modality by the Kasahara group to prevent complications of diarrhea and steatosis post LT[62].

Antibody induced BSEP deficiency: Post-transplant recurrence of cholestasis in PFIC2 has been described due to *de novo* polyclonal antibodies directed against extracellular loop 1 domain of BSEP protein in the sera and on the canalicular membrane[63]. Patients with severe mutations with resultant complete absence of BSEP are typically prone to this complication as the BSEP of the transplanted liver is recognized as a foreign new antigen by the recipient's immune system, usually seen after an episode of acute rejection. Initial treatment of antibody-induced BSEP-deficiency disease is increased immunosuppression followed by either rituximab, bortezomib, intravenous immunoglobulin or plasmapheresis[64]. Those refractory to the above treatment may be considered for allogeneic hematopoietic stem cell transplantation[65]. Re-transplant

Table 4 Potential novel therapeutic drugs for treatment of progressive familial intrahepatic cholestasis

Drug	Mechanism of action	Clinical trials and current status	Notes
Maralixibat/LUM001	Apical sodium-dependent bile acid transporter inhibitor	NCT04185363: Open label phase III trial; Recruiting patients; NCT03905330: MARCH-PFIC trial; Randomized controlled trial, recruiting patients; NCT04729751: RISE trial in infants; Open label phase II safety study; NCT04168385: Long term safety study; NCT02057718; Open label phase II trial; Completed	Orphan drug designation by FDA; Breakthrough therapy for PFIC2
Odevixibat/A4250	Selective inhibitor of ileal bile acid transporter	NCT03566238: PEDFIC 1 study; Phase III, open label, randomized controlled trial; Ongoing; NCT04483531: Expanded access study including patients not enrolled in PEDFIC 1 study	Orphan drug designation by FDA; Fast track designation for PFIC
4-PB/GPA	Prolongs degradation rate & increases cell surface expression of BSEP & functions as a chemical chaperone to correct the misfolded proteins	Leads to long term reduction in serum BA, improvement in liver biochemistry as well as relief of pruritus; Increased canalicular localization of E297G and D482G BSEP mutants; GPA more palatable, has lower sodium, doesn't interact with rifampicin; Doses: 4-PB: 500 mg/kg/d; GPA: 8 g/m ² /d	4-PB FDA approved for urea cycle defect
Ivacaftor	Rescues the function of missense mutations in the nucleotide binding domains of BSEP & MDR3	<i>In vitro</i> correction of binding domain missense mutation (T463I) of BSEP; Improved phospholipid secretion activity in mutant ABCB4	<i>In vitro</i> studies; Animal studies
Oxcarbazepine	Nerve stabilizing effect; Enzyme inducer – possible role in potentiating action of 4-PB	Single case report on its combined use with 4-PB and maralixibat	
Gentamicin	Induce readthrough in nonsense mutation	<i>In vitro</i> increased readthrough in 6 common nonsense mutation of BSEP leading to increased canalicular expression of bile salt transporter	
FXR agonist (Obeticholic acid)	Farnesoid X receptor agonist	No trials in PFIC; Safe and efficacious in treatment of PSC and non-alcoholic steatohepatitis	FDA approved for PSC
Nor-UDCA	Side-chain-shortened derivative of UDCA; Increases cholehepatic shunt	No trials in PFIC; NCT03872921: Ongoing phase III randomized controlled trial in PSC	
Steroids	Possible upregulation of BSEP transporter? Up-regulation of sodium taurocholate copeptide transporterproviding increased gradient for BSEP	Only case reports and animal studies	
NGM282	FGF19 analogue	NGM282 inhibited bile acid synthesis and decreased fibrosis markers, without change in alkaline phosphatase level	
Bezafibrate	Peroxisome proliferator activated receptor agonist	Bezafibrate reduced pruritus and cholestasis in 2 out of 3 children with PFIC1 and improved lipid profile in all	

PFIC: Progressive familial intrahepatic cholestasis; BSEP: Bile salt export pump; FGF: Fibroblast growth factor; NGM282: Codename of drug which is an engineered analogue of fibroblast growth factor - 19; UDCA: Ursodeoxycholic acid; PSC: Primary sclerosing cholangitis; FDA: Food and drug administration; PB: Phenyl-butyrate; MDR3: Multidrug-resistant type 3; ABCB: ATP-binding cassette subfamily B; GPA: Glycerol phenylbutyrate; BA: Bile acids.

may be considered in those refractory to all therapy but the threat of recurrence in the re-transplanted liver is high[63].

Donor issues in living-related liver transplant: There have been apprehensions about using family members as donors, who may be heterozygous. Bassas *et al*[66] described living-related donor LT in 13 children with PFIC with good outcomes and no recurrence of symptoms in the recipients. Other studies have also reported favourable outcomes in PFIC2 and PFIC3 with living-related LT[67]. Genetically proven heterozygous family members have been used as donors without recurrence of symptoms in the recipients. Currently, there is not enough evidence to perform a genetic analysis of the related donor before LT. It remains to be seen if the heterozygous donor liver in PFIC3 patients may predispose the recipient to drug-induced cholestasis, contraceptive induced cholestasis, ICP or GBD-1/LPAC.

Gene therapy: The additional complications associated with LT warrant the consideration of innovative therapeutic modalities like gene therapy. Recent approval for Adenovirus Associated viral (AAV) vector-based gene therapy for other monogenic disorders, raises hope for such future therapies for PFIC[68]. The liver tropism of AAV

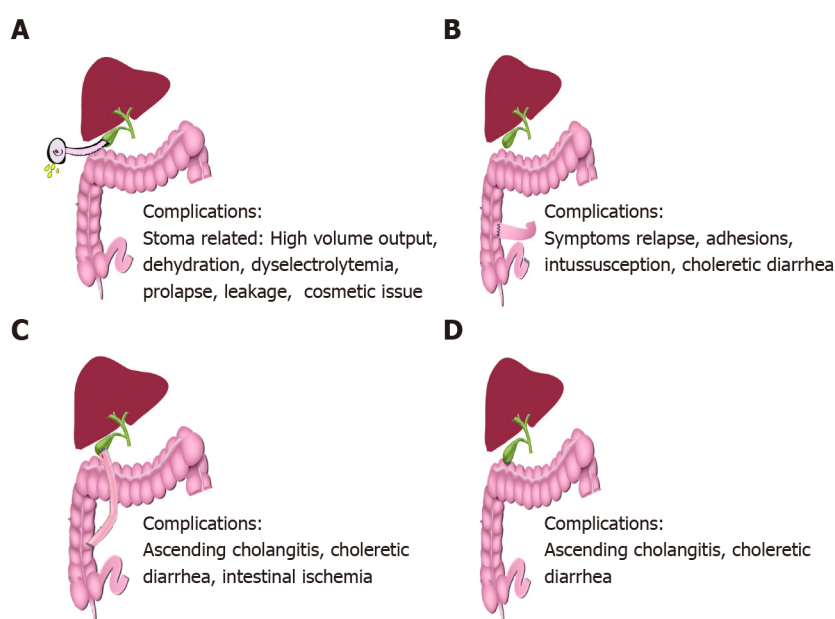


Figure 4 Schematic representation of biliary diversion surgeries. A: Partial external biliary diversion: A conduit of around 15-20 cm is made from gall bladder to an exteriorized cutaneous stoma using a jejunal conduit. This conduit diverts a variable (~50%) proportion of bile away from the intestine into the connected stoma bag which needs to be emptied regularly; B: Ileal exclusion (IE): IE involves formation of an end to side ileocolonic anastomosis in such a way that the terminal 15% of ileum is excluded, hence drastically reducing the enterohepatic circulation. The proximal end of the resected ileum is sutured to the colon around 5 cm distal to the ileocecal valve; C: Partial internal biliary diversion (PIBD): The most common technique of PIBD is a cholecysto-jejuno-colonic anastomosis. An isolated jejunal conduit of around 12-15 cm length is created and anastomosed proximally to the gallbladder and distally to the mid part of the ascending colon; D: Another commonly used technique of PIBD is cholecysto-colostomy where gall bladder is directly connected to the transverse colon to partially bypass the terminal ileum.

vectors is a major advantage in the treatment of PFIC as this would imply the need for a lower vector dose for therapeutic efficacy. Higher AAV vector doses have been shown to cause adverse effects ranging from transient liver inflammation to even progressive liver failure and deaths in few reports[69]. Gene therapy can be non-integrating where each cell division post therapy will lead to some loss of episomal AAV vector genome or integrating *in vivo* where these integrated genes are copied during cell division and passed on to the daughter cells without any loss of vector genome upon cell division[68]. The benefit of integrating gene therapy is that a limited number of corrected hepatocytes will repopulate the liver and correct the defect[68, 70]. Theoretically, *in vivo* non-integrating AAV mediated gene therapy can be successful in PFIC3 as establishing ABCB4 expression in a proportion of hepatocytes. This can partially correct phosphatidylcholine transport and prevent the progression of the disease. Gene therapy for PFIC has only been done successfully in double knockout murine models (*Abcb4*^{-/-}) to date[71]. Treatment with modified mRNA variants encoding human ABCB4 encapsulated in lipid nanoparticles lead to *de novo* expression of functional ABCB4 and restored phospholipid transport in cultured cells as well as *Abcb4*^{-/-} mice. Hepatocyte damage due to accumulated BA in PFIC1 and 2; and decreased membrane stability in PFIC1 would warrant the correction of the genetic defect in all the hepatocytes, thus needing an integrating gene therapy strategy [68]. Tumor genes is a possible major risk factor with integrating gene therapy as seen in trials on patients with severe combined immunodeficiency[72]. The evolution of CRISPR/Cas9 based gene-editing tools that exhibit fewer off-target effects raises hope for integrating *in vivo* controlled gene therapy in future[73].

Newer targets for therapy in PFIC: Several drugs and therapeutic molecules are currently being investigated for their therapeutic efficacy and safety in PFIC1 and 2. Table 4 and Figure 5 describes the various experimental drugs being evaluated for their therapeutic role in PFIC. Among them, the class of drugs that have generated the maximum interest are those which inhibit the ileal ASBTs.

Apical sodium bile acid transporter inhibitors: ASBTi is currently under various stages of clinical trials include maralixibat and odevixibat (A4250). Currently, there are 4 registered clinical trials for maralixibat including one in infants and two clinical trials for odevixibat. The ASBTi interfere with bile salts reabsorption in the terminal ileum and hence greatly reduce the enterohepatic circulation of bile salts which are then

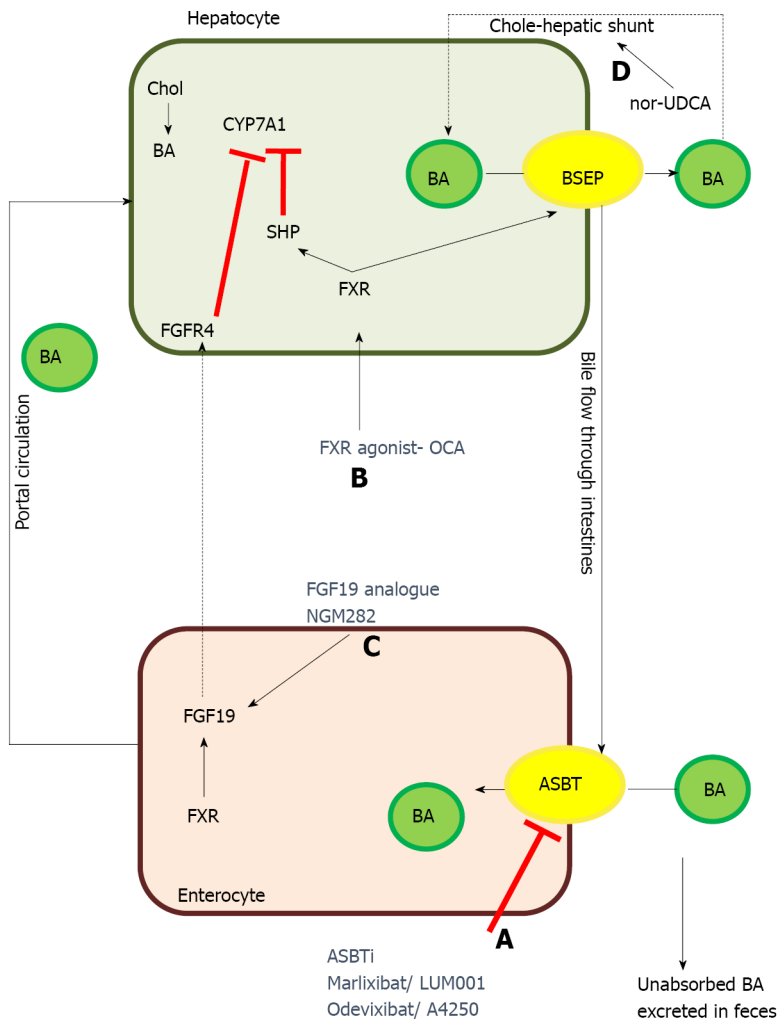


Figure 5 Therapeutic targets of some of the newer drugs for treatment of progressive familial intrahepatic cholestasis. A: Apical sodium-dependent bile salt transporter inhibitors prevent the absorption of bile acids in the terminal ileum resulting in significant decrease in enterohepatic circulation of bile acids, ultimately resulting in decreased serum bile acids; B: Farnesoid X receptor agonist acts by increasing bile salt exporter pump expression as well as by inhibiting CYP7A1, the rate limiting step in synthesis of bile acids in hepatocytes; C: Fibroblast growth factor 19 analogue act via fibroblast growth factor receptor-4 and inhibit CYP7A1; D: Nor-ursodeoxycholic acid increases the bile-acid dependent bile flow by increasing the cholehepatic shunt. ASBT: Apical sodium-dependent bile salt transporter; BA: Bile acid; BSEP: Bile salt exporter pump; Chol: Cholesterol; CYP7A1: Cholesterol 7- α hydroxylase; FGFR4: Fibroblast growth factor receptor-4; FXR: Farnesoid X receptor; FGF19: Fibroblast growth factor 19; nor-UDCA: Nor-ursodeoxycholic acid; OCA: Obeticholic acid; SHP: Small heterodimer partner-1.

excreted in the stool. ASBTi thus shrinks the bile acid pool and helps reduce BA and in turn improves cholestasis[74]. Odevixibat is as effective as PEBD in reducing BA as well as pruritus in a child with PFIC2 thus raising hope of a very effective medical management of cholestasis[75]. However, on stopping therapy after the completion of the trial, the patient had a relapse of symptoms and underwent PEBD. The preliminary results from the trials of marlixibat and odevixibat have shown that these ASBTi reduce BA and pruritus while improving growth[74,75].

Ivacaftor: Ivacaftor (VX-770), a CFTR/ABCC7 potentiator has been demonstrated to cause functional rescue of missense mutations of ABCB11 and ABCB4 located in a highly conserved ABC transporter motif[76]. *In vitro* molecular modelling showed that ivacaftor led to the functional rescue of mutant ABCB4 resulting in increased phospholipid secretion[76].

4 phenyl butyrate: 4-phenyl butyrate (4-PB), an FDA approved drug for urea cycle defect acts by 2 mechanisms to correct the defect in BSEP missense mutations: (1) It modulates the short-chain ubiquitination to prolong the degradation rate of cell surface resident BSEP and hence increases the cell surface expression of BSEP; and (2) Functions as a chemical chaperone to correct the misfolding of some endoplasmic reticulum-retained BSEP missense mutants[77]. *In vitro* studies in HEK293 and MDCKII cell lines showed increased cell surface expression of wild-type E297G and

D482G BSEP. This resulted in an increased taurocholic acid transport on treatment with 4-PB, long term reduction in BA, improved presence of BSEP at canalicular membrane and relief of pruritus. 4-PB therapy was effective at a dose of 500 mg/kg/d with no adverse events but with relapse of symptoms after stopping therapy[78]. However, concerns have been raised about the palatability of this drug, compliance and hepatotoxicity potential when combined with rifampicin. Glycerol phenylbutyrate was shown to be equally efficacious with good tolerance and adherence. Malatack *et al* [79] described a case report of a PFIC2 with a missense mutation in BSEP who improved with combination therapy of 4-PB, maralixibat and oxcarbazepine. They hypothesized that enzyme inducer action of oxcarbazepine augments conversion of 4-PB to phenylacetate leading to synergistic effect apart from its usual nerve stabilizing effect[79]. Although 4-PB is safe in most studies, a recent report of bipolar disorder in an adolescent on 4-PB raises concerns[80].

Readthrough therapy-gentamicin: Gentamicin has been shown to induce readthrough leading to the expression of a full-length protein in stable MDCK clones. Gentamicin in combination with 4-PB significantly increased the readthrough level of common nonsense mutation studied (p.R415X, p.R470X, p.R1057X, p.R1090X) in HEK293 cells. The maximum response was seen for the p.R1090X mutation with a 40% increase in taurocholate transport and correct localization at the cell membrane[81]. There has been an emphasis on mutation-specific therapies with: (1) Gentamicin and ataluren likely to suppress nonsense mutations by promoting the readthrough of premature stop codons; and (2) U1-small nuclear-RNA likely to rescue splicing for several ATP8B1 mutations located at donor, acceptor and splice sites[81].

Other drugs: Nor-UDCA is a side-chain shortened derivative of UDCA with relative resistance to amidation thus increasing the cholehepatic shunt and in turn increases the bile salt-dependent bile flow[82]. Peroxisome proliferator-activated receptor agonist bezafibrate has been reported to correct dyslipidemia and reduce pruritus and cholestasis in children with PFIC1 and other diseases[83]. Rapamycin restores bile acid excretion, attenuates hepatocyte damage and extends the lifespan of Abcb11b mutant zebrafish which is the ortholog of human ABCB11. Other drug categories which could theoretically be beneficial but have not yet been tried in clinical trials include FXR agonist and fibroblast growth factor-19 analogue[84]. Obeticholic acid is a very potent FXR agonist, promotes transcription of BSEP, improves histopathology and reverse fibrosis and could therefore be useful in patients with PFIC2[84].

CONCLUSION

To conclude, there has been a recent emphasis on understanding the genetic spectrum of PFIC, their phenotype, natural course and long-term outcome. Genotype correlates well with phenotype in PFIC2 but not in PFIC1. The expanded role of the heterozygous transporter defects presenting late needs to be suspected and identified even in adulthood. Medical therapy and SBD form the cornerstone of the management of pruritus. LT in these children is associated with unique issues like a high rate of intractable diarrhea, growth failure, steatohepatitis and graft failure in PFIC1 and antibody-mediated BSEP deficiency. There is a promising role of ASBT inhibitors in the management of cholestasis.

REFERENCES

- 1 **Jacquemin E.** Progressive familial intrahepatic cholestasis. *Clin Res Hepatol Gastroenterol* 2012; **36** Suppl 1: S26-S35 [PMID: 23141890 DOI: 10.1016/S2210-7401(12)70018-9]
- 2 **Baker A, Kerkar N, Todorova L, Kamath BM, Houwen RHJ.** Systematic review of progressive familial intrahepatic cholestasis. *Clin Res Hepatol Gastroenterol* 2019; **43**: 20-36 [PMID: 30236549 DOI: 10.1016/j.clinre.2018.07.010]
- 3 **Takatsu H, Tanaka G, Segawa K, Suzuki J, Nagata S, Nakayama K, Shin HW.** Phospholipid flippase activities and substrate specificities of human type IV P-type ATPases localized to the plasma membrane. *J Biol Chem* 2014; **289**: 33543-33556 [PMID: 25315773 DOI: 10.1074/jbc.M114.593012]
- 4 **Groen A, Romero MR, Kunne C, Hoosdally SJ, Dixon PH, Wooding C, Williamson C, Seppen J, Van den Oever K, Mok KS, Paulusma CC, Linton KJ, Oude Elferink RP.** Complementary functions of the flippase ATP8B1 and the floppase ABCB4 in maintaining canalicular membrane integrity. *Gastroenterology* 2011; **141**: 1927-37.e1 [PMID: 21820390 DOI: 10.1053/j.gastro.2011.07.042]

- 5 **Strautnieks SS**, Bull LN, Knisely AS, Kocoshis SA, Dahl N, Arnell H, Sokal E, Dahan K, Childs S, Ling V, Tanner MS, Kagalwalla AF, Németh A, Pawlowska J, Baker A, Mieli-Vergani G, Freimer NB, Gardiner RM, Thompson RJ. A gene encoding a liver-specific ABC transporter is mutated in progressive familial intrahepatic cholestasis. *Nat Genet* 1998; **20**: 233-238 [PMID: [9806540](#) DOI: [10.1038/3034](#)]
- 6 **Folmer DE**, Elferink RP, Paulusma CC. P4 ATPases - lipid flippases and their role in disease. *BiochimBiophys Acta* 2009; **1791**: 628-635 [PMID: [19254779](#) DOI: [10.1016/j.bbalip.2009.02.008](#)]
- 7 **Chen F**, Ellis E, Strom SC, Shneider BL. ATPase Class I Type 8B Member 1 and protein kinase C zeta induce the expression of the canalicular bile salt export pump in human hepatocytes. *Pediatr Res* 2010; **67**: 183-187 [PMID: [19809379](#) DOI: [10.1203/PDR.0b013e3181c2df16](#)]
- 8 **Vitale G**, Gitto S, Vukotic R, Raimondi F, Andreone P. Familial intrahepatic cholestasis: New and wide perspectives. *Dig Liver Dis* 2019; **51**: 922-933 [PMID: [31105019](#) DOI: [10.1016/j.dld.2019.04.013](#)]
- 9 **Stapelbroek JM**, Peters TA, van Beurden DH, Curfs JH, Joosten A, Beynon AJ, van Leeuwen BM, van der Velden LM, Bull L, Oude Elferink RP, van Zanten BA, Klomp LW, Houwen RH. ATP8B1 is essential for maintaining normal hearing. *Proc Natl Acad Sci U S A* 2009; **106**: 9709-9714 [PMID: [19478059](#) DOI: [10.1073/pnas.0807919106](#)]
- 10 **Ray NB**, Durairaj L, Chen BB, McVerry BJ, Ryan AJ, Donahoe M, Waltenbaugh AK, O'Donnell CP, Henderson FC, Etscheidt CA, McCoy DM, Agassandian M, Hayes-Rowan EC, Coon TA, Butler PL, Gakhar L, Mathur SN, Sieren JC, Tyurina YY, Kagan VE, McLennan G, Mallampalli RK. Dynamic regulation of cardiolipin by the lipid pump Atp8b1 determines the severity of lung injury in experimental pneumonia. *Nat Med* 2010; **16**: 1120-1127 [PMID: [20852622](#) DOI: [10.1038/nm.2213](#)]
- 11 **Bull LN**, Morotti R, Squires JE. ATP8B1 Deficiency. 2001 Oct 15. In: GeneReviews® [Internet]. Seattle (WA): University of Washington, Seattle; 1993–2021 [PMID: [20301474](#)]
- 12 **Al-Hussaini A**, Lone K, Bashir MS, Alrashidi S, Fagih M, Alanazi A, AlYaseen S, Almayouf A, Alruwaithi M, Asery A. ATP8B1, ABCB11, and ABCB4 Genes Defects: Novel Mutations Associated with Cholestasis with Different Phenotypes and Outcomes. *J Pediatr* 2021; **236**: 113-123.e2 [PMID: [33915153](#) DOI: [10.1016/j.jpeds.2021.04.040](#)]
- 13 **van der Woerd WL**, van Haaften-Visser DY, van de Graaf SF, Férec C, Masson E, Stapelbroek JM, Bugert P, Witt H, Houwen RH. Mutational analysis of ATP8B1 in patients with chronic pancreatitis. *PLoS One* 2013; **8**: e80553 [PMID: [24260417](#) DOI: [10.1371/journal.pone.0080553](#)]
- 14 **Li L**, Deheragoda M, Lu Y, Gong J, Wang J. Hypothyroidism Associated with ATP8B1 Deficiency. *J Pediatr* 2015; **167**: 1334-9.e1 [PMID: [26382629](#) DOI: [10.1016/j.jpeds.2015.08.037](#)]
- 15 **van Wessel DBE**, Thompson RJ, Gonzales E, Jankowska I, Shneider BL, Sokal E, Grammatikopoulos T, Kadaristiana A, Jacquemin E, Spraul A, Lipiński P, Czubkowski P, Rock N, Shagrani M, Broering D, Algoufi T, Mazhar N, Nicastro E, Kelly D, Nebbia G, Arnell H, Fischler B, Hulscher JBF, Serranti D, Arikian C, Debray D, Lacaille F, Goncalves C, Hierro L, Muñoz Bartolo G, Mozer-Glassberg Y, Azaz A, Breclj J, Dezsőfi A, Luigi Calvo P, Krebs-Schmitt D, Hartleif S, van der Woerd WL, Wang JS, Li LT, Durmaz Ö, Kerker N, Hørbjerg Jensen M, Fischer R, Jimenez-Rivera C, Alam S, Cananzi M, Laverdure N, Targa Ferreira C, Ordenez F, Wang H, Sency V, Mo Kim K, Chen HL, Carvalho E, Fabre A, Quintero Bernabeu J, Alonso EM, Sokol RJ, Suchy FJ, Loomes KM, McKiernan PJ, Rosenthal P, Turmelle Y, Rao GS, Horslen S, Kamath BM, Rogalidou M, Karnsakul WW, Hansen B, Verkade HJ; Natural Course and Prognosis of PFIC and Effect of Biliary Diversion Consortium. Impact of Genotype, Serum Bile Acids, and Surgical Biliary Diversion on Native Liver Survival in FIC1 Deficiency. *Hepatology* 2021; **74**: 892-906 [PMID: [33666275](#) DOI: [10.1002/hep.31787](#)]
- 16 **Dröge C**, Bonus M, Baumann U, Klindt C, Lainka E, Kathemann S, Brinkert F, Grabhorn E, Pfister ED, Wenning D, Fichtner A, Gotthardt DN, Weiss KH, McKiernan P, Puri RD, Verma IC, Kluge S, Gohlke H, Schmitt L, Kubitz R, Häussinger D, Keitel V. Sequencing of FIC1, BSEP and MDR3 in a large cohort of patients with cholestasis revealed a high number of different genetic variants. *J Hepatol* 2017; **67**: 1253-1264 [PMID: [28733223](#) DOI: [10.1016/j.jhep.2017.07.004](#)]
- 17 **Painter JN**, Savander M, Ropponen A, Nupponen N, Riikonen S, Ylikorkala O, Lehesjoki AE, Aittomäki K. Sequence variation in the ATP8B1 gene and intrahepatic cholestasis of pregnancy. *Eur J Hum Genet* 2005; **13**: 435-439 [PMID: [15657619](#) DOI: [10.1038/sj.ejhg.5201355](#)]
- 18 **Henkel SA**, Squires JH, Ayers M, Ganoza A, McKiernan P, Squires JE. Expanding etiology of progressive familial intrahepatic cholestasis. *World J Hepatol* 2019; **11**: 450-463 [PMID: [31183005](#) DOI: [10.4254/wjh.v11.i5.450](#)]
- 19 **Zhang Y**, Li F, Patterson AD, Wang Y, Krausz KW, Neale G, Thomas S, Nachagari D, Vogel P, Vore M, Gonzalez FJ, Schuetz JD. Abcb11 deficiency induces cholestasis coupled to impaired β -fatty acid oxidation in mice. *J Biol Chem* 2012; **287**: 24784-24794 [PMID: [22619174](#) DOI: [10.1074/jbc.M111.329318](#)]
- 20 **van Wessel DBE**, Thompson RJ, Gonzales E, Jankowska I, Sokal E, Grammatikopoulos T, Kadaristiana A, Jacquemin E, Spraul A, Lipiński P, Czubkowski P, Rock N, Shagrani M, Broering D, Algoufi T, Mazhar N, Nicastro E, Kelly DA, Nebbia G, Arnell H, Björn Fischler, Hulscher JBF, Serranti D, Arikian C, Polat E, Debray D, Lacaille F, Goncalves C, Hierro L, Muñoz Bartolo G, Mozer-Glassberg Y, Azaz A, Breclj J, Dezsőfi A, Calvo PL, Grabhorn E, Sturm E, van der Woerd WJ, Kamath BM, Wang JS, Li L, Durmaz Ö, Onal Z, Bunt TMG, Hansen BE, Verkade HJ; NATural course and Prognosis of PFIC and Effect of biliary Diversion (NAPPED) consortium. Genotype correlates with the natural history of severe bile salt export pump deficiency. *J Hepatol* 2020; **73**: 84-

- 93 [PMID: 32087350 DOI: 10.1016/j.jhep.2020.02.007]
- 21 **Li LT**, Li ZD, Yang Y, Lu Y, Xie XB, Chen L, Feng JY, Knisely AS, Wang JS. ABCB11 deficiency presenting as transient neonatal cholestasis: Correlation with genotypes and BSEP expression. *Liver Int* 2020; **40**: 2788-2796 [PMID: 32808743 DOI: 10.1111/liv.14642]
- 22 **Strautnieks SS**, Byrne JA, Pawlikowska L, Cebecauerová D, Rayner A, Dutton L, Meier Y, Antoniou A, Stieger B, Arnell H, Özçay F, Al-Hussaini HF, Bassas AF, Verkade HJ, Fischler B, Németh A, Kotalová R, Shneider BL, Cielecka-Kuszyk J, McClean P, Whittington PF, Sokal E, Jirsa M, Wali SH, Jankowska I, Pawłowska J, Mieli-Vergani G, Knisely AS, Bull LN, Thompson RJ. Severe bile salt export pump deficiency: 82 different ABCB11 mutations in 109 families. *Gastroenterology* 2008; **134**: 1203-1214 [PMID: 18395098 DOI: 10.1053/j.gastro.2008.01.038]
- 23 **Sticova E**, Jirsa M. ABCB4 disease: Many faces of one gene deficiency. *Ann Hepatol* 2020; **19**: 126-133 [PMID: 31759867 DOI: 10.1016/j.aohp.2019.09.010]
- 24 **Davit-Spraul A**, Gonzales E, Baussan C, Jacquemin E. Progressive familial intrahepatic cholestasis. *Orphanet J Rare Dis* 2009; **4**: 1 [PMID: 19133130 DOI: 10.1186/1750-1172-4-1]
- 25 **Davit-Spraul A**, Gonzales E, Baussan C, Jacquemin E. The spectrum of liver diseases related to ABCB4 gene mutations: pathophysiology and clinical aspects. *Semin Liver Dis* 2010; **30**: 134-146 [PMID: 20422496 DOI: 10.1055/s-0030-1253223]
- 26 **Degiorio D**, Colombo C, Seia M, Porcario L, Costantino L, Zazzaron L, Bordo D, Coviello DA. Molecular characterization and structural implications of 25 new ABCB4 mutations in progressive familial intrahepatic cholestasis type 3 (PFIC3). *Eur J Hum Genet* 2007; **15**: 1230-1238 [PMID: 17726488 DOI: 10.1038/sj.ejhg.5201908]
- 27 **Delaunay JL**, Durand-Schneider AM, Dossier C, Falguières T, Gautherot J, Davit-Spraul A, Aït-Slimane T, Housset C, Jacquemin E, Maurice M. A functional classification of ABCB4 variations causing progressive familial intrahepatic cholestasis type 3. *Hepatology* 2016; **63**: 1620-1631 [PMID: 26474921 DOI: 10.1002/hep.28300]
- 28 **Jacquemin E**. Role of multidrug resistance 3 deficiency in pediatric and adult liver disease: one gene for three diseases. *Semin Liver Dis* 2001; **21**: 551-562 [PMID: 11745043 DOI: 10.1055/s-2001-19033]
- 29 **Folvik G**, Hilde O, Helge GO. Benign recurrent intrahepatic cholestasis: review and long-term follow-up of five cases. *Scand J Gastroenterol* 2012; **47**: 482-488 [PMID: 2229830 DOI: 10.3109/00365521.2011.650191]
- 30 **Dixon PH**, Sambrotta M, Chambers J, Taylor-Harris P, Syngelaki A, Nicolaidis K, Knisely AS, Thompson RJ, Williamson C. An expanded role for heterozygous mutations of ABCB4, ABCB11, ATP8B1, ABCC2 and TJP2 in intrahepatic cholestasis of pregnancy. *Sci Rep* 2017; **7**: 11823 [PMID: 28924228 DOI: 10.1038/s41598-017-11626-x]
- 31 **Aamann L**, Ørntoft N, Vogel I, Grønbaek H, Becher N, Vilstrup H, Ott P, Lildballe DL. Unexplained cholestasis in adults and adolescents: diagnostic benefit of genetic examination. *Scand J Gastroenterol* 2018; **53**: 305-311 [PMID: 29304564 DOI: 10.1080/00365521.2017.1422800]
- 32 **Bull LN**, Thompson RJ. Progressive Familial Intrahepatic Cholestasis. *Clin Liver Dis* 2018; **22**: 657-669 [PMID: 30266155 DOI: 10.1016/j.cld.2018.06.003]
- 33 **Vij M**, Valamparampil J, Shanmugum N, Reddy SM, Rajindrajith S, Rela M. Paucity of Interlobular Bile Ducts in Multidrug-Resistant P-Glycoprotein 3 (MDR3) Deficiency. *Int J Surg Pathol* 2019; **27**: 343-347 [PMID: 30222019 DOI: 10.1177/1066896918799941]
- 34 **Lang C**, Meier Y, Stieger B, Beuers U, Lang T, Kerb R, Kullak-Ublick GA, Meier PJ, Pauli-Magnus C. Mutations and polymorphisms in the bile salt export pump and the multidrug resistance protein 3 associated with drug-induced liver injury. *Pharmacogenet Genomics* 2007; **17**: 47-60 [PMID: 17264802 DOI: 10.1097/01.fpc.0000230418.28091.76]
- 35 **Nayagam JS**, Williamson C, Joshi D, Thompson RJ. Review article: liver disease in adults with variants in the cholestasis-related genes ABCB11, ABCB4 and ATP8B1. *Aliment Pharmacol Ther* 2020; **52**: 1628-1639 [PMID: 33070363 DOI: 10.1111/apt.16118]
- 36 **Yang XF**, Liu GS, Li MX. Analysis of mutations of *MDR3* exons 9 and 23 in infants with parenteral nutrition-associated cholestasis. *Exp Ther Med* 2015; **10**: 2361-2365 [PMID: 26668642 DOI: 10.3892/etm.2015.2800]
- 37 **Hori T**, Egawa H, Takada Y, Ueda M, Oike F, Ogura Y, Sakamoto S, Kasahara M, Ogawa K, Miyagawa-Hayashino A, Yonekawa Y, Yorifuji T, Watanabe K, Doi H, Nguyen JH, Chen F, Baine AM, Gardner LB, Uemoto S. Progressive familial intrahepatic cholestasis: a single-center experience of living-donor liver transplantation during two decades in Japan. *Clin Transplant* 2011; **25**: 776-785 [PMID: 21158920 DOI: 10.1111/j.1399-0012.2010.01368.x]
- 38 **Agarwal S**, Lal BB, Rawat D, Rastogi A, Bharathy KG, Alam S. Progressive Familial Intrahepatic Cholestasis (PFIC) in Indian Children: Clinical Spectrum and Outcome. *J Clin Exp Hepatol* 2016; **6**: 203-208 [PMID: 27746616 DOI: 10.1016/j.jceh.2016.05.003]
- 39 **Petrescu AD**, Kain J, Liere V, Heavener T, DeMorrow S. Hypothalamus-Pituitary-Adrenal Dysfunction in Cholestatic Liver Disease. *Front Endocrinol (Lausanne)* 2018; **9**: 660 [PMID: 30483216 DOI: 10.3389/fendo.2018.00660]
- 40 **Feranchak AP**, Suchy FJ, Sokol RJ. Medical and Nutritional management of cholestasis in infants and children. 4th edition. Suchy FJ, Sokol RJ, Balistreri WF, editors. Liver Disease in Children. New York: Cambridge University Press, 2014: 111-139
- 41 **Lal BB**, Alam S, Khanna R, Rawat D. Weekly regimen of vitamin D supplementation is more efficacious than stoss regimen for treatment of vitamin D deficiency in children with chronic liver

- diseases. *Eur J Pediatr* 2018; **177**: 827-834 [PMID: 29504044 DOI: 10.1007/s00431-018-3123-0]
- 42 **Elman S**, Hynan LS, Gabriel V, Mayo MJ. The 5-D itch scale: a new measure of pruritus. *Br J Dermatol* 2010; **162**: 587-593 [PMID: 19995367 DOI: 10.1111/j.1365-2133.2009.09586.x]
- 43 **Frider B**, Castillo A, Gordo-Gilart R, Bruno A, Amante M, Alvarez L, Mathet V. Reversal of advanced fibrosis after long-term ursodeoxycholic acid therapy in a patient with residual expression of MDR3. *Ann Hepatol* 2015; **14**: 745-751 [PMID: 26256905]
- 44 **Tandon P**, Rowe BH, Vandermeer B, Bain VG. The efficacy and safety of bile Acid binding agents, opioid antagonists, or rifampin in the treatment of cholestasis-associated pruritus. *Am J Gastroenterol* 2007; **102**: 1528-1536 [PMID: 17403073 DOI: 10.1111/j.1572-0241.2007.01200.x]
- 45 **Imam MH**, Gossard AA, Sinakos E, Lindor KD. Pathogenesis and management of pruritus in cholestatic liver disease. *J Gastroenterol Hepatol* 2012; **27**: 1150-1158 [PMID: 22413872 DOI: 10.1111/j.1440-1746.2012.07109.x]
- 46 **Appleby VJ**, Hutchinson JM, Davies MH. Safety and efficacy of long-term nasobiliary drainage to treat intractable pruritus in cholestatic liver disease. *Frontline Gastroenterol* 2015; **6**: 252-254 [PMID: 28839819 DOI: 10.1136/flgastro-2014-100489]
- 47 **Cielecka-Kuszyk J**, Lipiński P, Szymańska S, Ismail H, Jankowska I. Long-term follow-up in children with progressive familial intrahepatic cholestasis type 2 after partial external biliary diversion with focus on histopathological features. *Pol J Pathol* 2019; **70**: 79-83 [PMID: 31556557 DOI: 10.5114/pjp.2019.87099]
- 48 **Bull LN**, Pawlikowska L, Strautnieks S, Jankowska I, Czubkowski P, Dodge JL, Emerick K, Wanty C, Wali S, Blanchard S, Lacaille F, Byrne JA, van Eerde AM, Kolho KL, Houwen R, Lobritto S, Hupertz V, McClean P, Mieli-Vergani G, Sokal E, Rosenthal P, Whittington PF, Pawlowska J, Thompson RJ. Outcomes of surgical management of familial intrahepatic cholestasis 1 and bile salt export protein deficiencies. *Hepatol Commun* 2018; **2**: 515-528 [PMID: 29761168 DOI: 10.1002/hep4.1168]
- 49 **Bjørnland K**, Hukkinen M, Gatzinsky V, Arnell H, Pakarinen MP, Almaas R, Svensson JF. Partial Biliary Diversion May Promote Long-Term Relief of Pruritus and Native Liver Survival in Children with Cholestatic Liver Diseases. *Eur J Pediatr Surg* 2021; **31**: 341-346 [PMID: 32707578 DOI: 10.1055/s-0040-1714657]
- 50 **Wang KS**, Tiao G, Bass LM, Hertel PM, Mogul D, Kerker N, Clifton M, Azen C, Bull L, Rosenthal P, Stewart D, Superina R, Arnon R, Bozic M, Brandt ML, Dillon PA, Fecteau A, Iyer K, Kamath B, Karpen S, Karrer F, Loomes KM, Mack C, Mattei P, Miethke A, Soltys K, Turmelle YP, West K, Zagory J, Goodhue C, Shneider BL; Childhood Liver Disease Research Network (ChILDReN). Analysis of surgical interruption of the enterohepatic circulation as a treatment for pediatric cholestasis. *Hepatology* 2017; **65**: 1645-1654 [PMID: 28027587 DOI: 10.1002/hep.29019]
- 51 **Van Vaisberg V**, Tannuri ACA, Lima FR, Tannuri U. Ileal exclusion for pruritus treatment in children with progressive familial intrahepatic cholestasis and other cholestatic diseases. *J Pediatr Surg* 2020; **55**: 1385-1391 [PMID: 31708211 DOI: 10.1016/j.jpedsurg.2019.09.018]
- 52 **Chen L**, Xiao H, Ren XH, Li L. Long-term outcomes after cholecystocolostomy for progressive familial intrahepatic cholestasis. *Hepatol Res* 2018; **48**: 1163-1171 [PMID: 29934967 DOI: 10.1111/hepr.13222]
- 53 **Foroutan HR**, Bahador A, Ghanim SM, Dehghani SM, Anbardar MH, Fattahi MR, Forooghi M, Azh O, Tadayon A, Sherfat A, Yaghoobi AA, Ashraf MA. Effects of partial internal biliary diversion on long-term outcomes in patients with progressive familial intrahepatic cholestasis: experience in 44 patients. *Pediatr Surg Int* 2020; **36**: 603-610 [PMID: 32206891 DOI: 10.1007/s00383-020-04641-z]
- 54 **Yang H**, Porte RJ, Verkade HJ, De Langen ZJ, Hulscher JB. Partial external biliary diversion in children with progressive familial intrahepatic cholestasis and Alagille disease. *J Pediatr Gastroenterol Nutr* 2009; **49**: 216-221 [PMID: 19561545 DOI: 10.1097/MPG.0b013e31819a4e3d]
- 55 **Schukfeh N**, Metzelder ML, Petersen C, Reismann M, Pfister ED, Ure BM, Kuebler JF. Normalization of serum bile acids after partial external biliary diversion indicates an excellent long-term outcome in children with progressive familial intrahepatic cholestasis. *J Pediatr Surg* 2012; **47**: 501-505 [PMID: 22424345 DOI: 10.1016/j.jpedsurg.2011.08.010]
- 56 **Alrabadi LS**, Morotti RA, Valentino PL, Rodriguez-Davalos MI, Ekong UD, Emre SH. Biliary drainage as treatment for allograft steatosis following liver transplantation for PFIC-1 disease: A single-center experience. *Pediatr Transplant* 2018; **22**: e13184 [PMID: 29654655 DOI: 10.1111/ptr.13184]
- 57 **Verkade HJ**, Thompson RJ, Arnell H, Fischler B, Gillberg PG, Mattsson JP, Torfgård K, Lindström E. Systematic Review and Meta-analysis: Partial External Biliary Diversion in Progressive Familial Intrahepatic Cholestasis. *J Pediatr Gastroenterol Nutr* 2020; **71**: 176-183 [PMID: 32433433 DOI: 10.1097/MPG.0000000000002789]
- 58 **Mehl A**, Bohorquez H, Serrano MS, Galliano G, Reichman TW. Liver transplantation and the management of progressive familial intrahepatic cholestasis in children. *World J Transplant* 2016; **6**: 278-290 [PMID: 27358773 DOI: 10.5500/wjt.v6.i2.278]
- 59 **Nikeghbalian S**, Malekhosseini SA, Kazemi K, Arasteh P, Eghlimi H, Shamsaeefar A, Nikoupour H, Gholami S, Dehghani M, Dehghani SM, Bahador A, Salahi H. The Largest Single Center Report on Pediatric Liver Transplantation: Experiences and Lessons Learned. *Ann Surg* 2021; **273**: e70-e72 [PMID: 32541224 DOI: 10.1097/SLA.0000000000004047]
- 60 **Okamoto T**, Sonoda M, Ogawa E, Ito S, Togawa T, Hayashi H, Okajima H, Uemoto S. Long-term Outcomes of Living-donor Liver Transplantation for Progressive Familial Intrahepatic Cholestasis

- Type 1. *J Pediatr Gastroenterol Nutr* 2021; **72**: 425-429 [PMID: [33264179](#) DOI: [10.1097/MPG.0000000000002983](#)]
- 61 **van der Mark VA**, de Waart DR, Ho-Mok KS, Tabbers MM, Voogt HW, Oude Elferink RP, Knisely AS, Paulusma CC. The lipid flippase heterodimer ATP8B1-CDC50A is essential for surface expression of the apical sodium-dependent bile acid transporter (SLC10A2/ASBT) in intestinal Caco-2 cells. *Biochim Biophys Acta* 2014; **1842**: 2378-2386 [PMID: [25239307](#) DOI: [10.1016/j.bbdis.2014.09.003](#)]
 - 62 **Mali VP**, Fukuda A, Shigeta T, Uchida H, Hirata Y, Rahayatri TH, Kanazawa H, Sasaki K, de Ville de Goyet J, Kasahara M. Total internal biliary diversion during liver transplantation for type 1 progressive familial intrahepatic cholestasis: a novel approach. *Pediatr Transplant* 2016; **20**: 981-986 [PMID: [27534385](#) DOI: [10.1111/ptr.12782](#)]
 - 63 **Stindt J**, Kluge S, Dröge C, Keitel V, Stross C, Baumann U, Brinkert F, Dhawan A, Engelmann G, Ganschow R, Gerner P, Grabhorn E, Knisely AS, Noli KA, Pukite I, Shepherd RW, Ueno T, Schmitt L, Wiek C, Hanenberg H, Häussinger D, Kubitz R. Bile salt export pump-reactive antibodies form a polyclonal, multi-inhibitory response in antibody-induced bile salt export pump deficiency. *Hepatology* 2016; **63**: 524-537 [PMID: [26516723](#) DOI: [10.1002/hep.28311](#)]
 - 64 **Quintero J**, Juamperez J, Gonzales E, Julio E, Mercadal-Hally M, Collado-Hilly M, Marín-Sánchez A, Charco R. Successful Treatment with Rituximab and Immunoabsorption for an Auto-Antibody Induced Bile Salt Export Pump Deficiency in a Liver Transplanted Patient. *Pediatr Gastroenterol Hepatol Nutr* 2020; **23**: 174-179 [PMID: [32206630](#) DOI: [10.5223/pghn.2020.23.2.174](#)]
 - 65 **Brinkert F**, Pukite I, Krebs-Schmitt D, Briem-Richter A, Stindt J, Häussinger D, Keitel V, Müller I, Grabhorn E. Allogeneic haematopoietic stem cell transplantation eliminates alloreactive inhibitory antibodies after liver transplantation for bile salt export pump deficiency. *J Hepatol* 2018; **69**: 961-965 [PMID: [29935200](#) DOI: [10.1016/j.jhep.2018.06.003](#)]
 - 66 **Bassas A**, Chehab M, Hebby H, Al Shahed M, Al Hussein H, Al Zahrani A, Wali S. Living related liver transplantation in 13 cases of progressive familial intrahepatic cholestasis. *Transplant Proc* 2003; **35**: 3003-3005 [PMID: [14697961](#) DOI: [10.1016/j.transproceed.2003.10.047](#)]
 - 67 **Aydogdu S**, Cakir M, Arikian C, Tumgor G, Yuksekkaya HA, Yilmaz F, Kilic M. Liver transplantation for progressive familial intrahepatic cholestasis: clinical and histopathological findings, outcome and impact on growth. *Pediatr Transplant* 2007; **11**: 634-640 [PMID: [17663686](#) DOI: [10.1111/j.1399-3046.2007.00722.x](#)]
 - 68 **Bosma PJ**, Wits M, Oude-Elferink RP. Gene Therapy for Progressive Familial Intrahepatic Cholestasis: Current Progress and Future Prospects. *Int J Mol Sci* 2020; **22** [PMID: [33383947](#) DOI: [10.3390/ijms22010273](#)]
 - 69 High-dose AAV gene therapy deaths. *Nat Biotechnol* 2020; **38**: 910 [PMID: [32760031](#) DOI: [10.1038/s41587-020-0642-9](#)]
 - 70 **De Vree JM**, Ottenhoff R, Bosma PJ, Smith AJ, Aten J, Oude Elferink RP. Correction of liver disease by hepatocyte transplantation in a mouse model of progressive familial intrahepatic cholestasis. *Gastroenterology* 2000; **119**: 1720-1730 [PMID: [11113093](#) DOI: [10.1053/gast.2000.20222](#)]
 - 71 **Weber ND**, Odriozola L, Martínez-García J, Ferrer V, Douar A, Bénichou B, González-Aseguinolaza G, Smerdou C. Gene therapy for progressive familial intrahepatic cholestasis type 3 in a clinically relevant mouse model. *Nat Commun* 2019; **10**: 5694 [PMID: [31836711](#) DOI: [10.1038/s41467-019-13614-3](#)]
 - 72 **Aiuti A**, Slavin S, Aker M, Ficara F, Deola S, Mortellaro A, Morecki S, Andolfi G, Tabucchi A, Carlucci F, Marinello E, Cattaneo F, Vai S, Servida P, Miniero R, Roncarolo MG, Bordignon C. Correction of ADA-SCID by stem cell gene therapy combined with nonmyeloablative conditioning. *Science* 2002; **296**: 2410-2413 [PMID: [12089448](#) DOI: [10.1126/science.1070104](#)]
 - 73 **Alagoz M**, Kherad N. Advance genome editing technologies in the treatment of human diseases: CRISPR therapy (Review). *Int J Mol Med* 2020; **46**: 521-534 [PMID: [32467995](#) DOI: [10.3892/ijmm.2020.4609](#)]
 - 74 **Kamath BM**, Stein P, Houwen RHJ, Verkade HJ. Potential of ileal bile acid transporter inhibition as a therapeutic target in Alagille syndrome and progressive familial intrahepatic cholestasis. *Liver Int* 2020; **40**: 1812-1822 [PMID: [32492754](#) DOI: [10.1111/liv.14553](#)]
 - 75 **Slavetinsky C**, Sturm E. Odevixibat and partial external biliary diversion showed equal improvement of cholestasis in a patient with progressive familial intrahepatic cholestasis. *BMJ Case Rep* 2020; **13** [PMID: [32601135](#) DOI: [10.1136/bcr-2019-234185](#)]
 - 76 **Mareux E**, Lapalus M, Amzal R, Almes M, Ait-Slimane T, Delaunay JL, Adnot P, Collado-Hilly M, Davit-Spraul A, Falguières T, Callebaut I, Gonzales E, Jacquemin E. Functional rescue of an ABCB11 mutant by ivacaftor: A new targeted pharmacotherapy approach in bile salt export pump deficiency. *Liver Int* 2020; **40**: 1917-1925 [PMID: [32433800](#) DOI: [10.1111/liv.14518](#)]
 - 77 **Hayashi H**, Sugiyama Y. Short-chain ubiquitination is associated with the degradation rate of a cell-surface-resident bile salt export pump (BSEP/ABCB11). *Mol Pharmacol* 2009; **75**: 143-150 [PMID: [18829893](#) DOI: [10.1124/mol.108.049288](#)]
 - 78 **Hayashi H**, Naoi S, Hirose Y, Matsuzaka Y, Tanikawa K, Igarashi K, Nagasaka H, Kage M, Inui A, Kusuha H. Successful treatment with 4-phenylbutyrate in a patient with benign recurrent intrahepatic cholestasis type 2 refractory to biliary drainage and bilirubin absorption. *Hepatol Res* 2016; **46**: 192-200 [PMID: [26223708](#) DOI: [10.1111/hepr.12561](#)]
 - 79 **Malatack JJ**, Doyle D. A Drug Regimen for Progressive Familial Cholestasis Type 2. *Pediatrics* 2018; **141** [PMID: [29284646](#) DOI: [10.1542/peds.2016-3877](#)]

- 80 **Vitale G**, Simonetti G, Pirillo M, Taruschio G, Andreone P. Bipolar and Related Disorders Induced by Sodium 4-Phenylbutyrate in a Male Adolescent with Bile Salt Export Pump Deficiency Disease. *Psychiatry Investig* 2016; **13**: 580-582 [PMID: [27757140](#) DOI: [10.4306/pi.2016.13.5.580](#)]
- 81 **Sohail MI**, Dönmez-Cakil Y, Szöllősi D, Stockner T, Chiba P. The Bile Salt Export Pump: Molecular Structure, Study Models and Small-Molecule Drugs for the Treatment of Inherited BSEP Deficiencies. *Int J Mol Sci* 2021; **22** [PMID: [33466755](#) DOI: [10.3390/ijms22020784](#)]
- 82 **Halilbasic E**, Steinacher D, Trauner M. Nor-Ursodeoxycholic Acid as a Novel Therapeutic Approach for Cholestatic and Metabolic Liver Diseases. *Dig Dis* 2017; **35**: 288-292 [PMID: [28249255](#) DOI: [10.1159/000454904](#)]
- 83 **Corpechot C**, Chazouillères O, Rousseau A, Le Gruyer A, Habersetzer F, Mathurin P, Gorla O, Potier P, Minello A, Silvain C, Abergel A, Debette-Gratien M, Larrey D, Roux O, Bronowicki JP, Boursier J, de Ledinghen V, Heurgue-Berlot A, Nguyen-Khac E, Zoulim F, Ollivier-Hourmand I, Zarski JP, Nkontchou G, Lemoine S, Humbert L, Rainteau D, Lefèvre G, de Chaisemartin L, Chollet-Martin S, Gaouar F, Admane FH, Simon T, Poupon R. A Placebo-Controlled Trial of Bezafibrate in Primary Biliary Cholangitis. *N Engl J Med* 2018; **378**: 2171-2181 [PMID: [29874528](#) DOI: [10.1056/NEJMoa1714519](#)]
- 84 **Trauner M**, Nevens F, Shiffman ML, Drenth JPH, Bowlus CL, Vargas V, Andreone P, Hirschfield GM, Pencek R, Malecha ES, MacConell L, Shapiro D. Long-term efficacy and safety of obeticholic acid for patients with primary biliary cholangitis: 3-year results of an international open-label extension study. *Lancet Gastroenterol Hepatol* 2019; **4**: 445-453 [PMID: [30922873](#) DOI: [10.1016/S2468-1253\(19\)30094-9](#)]



Published by **Baishideng Publishing Group Inc**
7041 Koll Center Parkway, Suite 160, Pleasanton, CA 94566, USA

Telephone: +1-925-3991568

E-mail: bpgoffice@wjgnet.com

Help Desk: <https://www.f6publishing.com/helpdesk>

<https://www.wjgnet.com>

