

World Journal of *Hepatology*

World J Hepatol 2022 April 27; 14(4): 647-865



FRONTIER

- 647 Revolution in the diagnosis and management of hepatitis C virus infection in current era
Hanif FM, Majid Z, Luck NH, Tasneem AA, Laeeq SM, Mubarak M

EVIDENCE REVIEW

- 670 Evidence-based approach to management of hepatic encephalopathy in adults
Hoilat GJ, Suhail FK, Adhami T, John S

MINIREVIEWS

- 682 Direct oral anticoagulant administration in cirrhotic patients with portal vein thrombosis: What is the evidence?
Biolato M, Paratore M, Di Gialleonardo L, Marrone G, Grieco A
- 696 Noninvasive diagnosis of periportal fibrosis in schistosomiasis mansoni: A comprehensive review
Santos JC, Pereira CLD, Domingues ALC, Lopes EP
- 708 Review on hepatitis B virus precore/core promoter mutations and their correlation with genotypes and liver disease severity
Kumar R

ORIGINAL ARTICLE

Basic Study

- 719 Assessment of periportal fibrosis in *Schistosomiasis mansoni* patients by proton nuclear magnetic resonance-based metabonomics models
Rodrigues ML, da Luz TPSR, Pereira CLD, Batista AD, Domingues ALC, Silva RO, Lopes EP
- 729 Baicalin provides protection against fluoxetine-induced hepatotoxicity by modulation of oxidative stress and inflammation
Ganguly R, Kumar R, Pandey AK

Clinical and Translational Research

- 744 Correlation between Fibroscan and laboratory tests in non-alcoholic fatty liver disease/non-alcoholic steatohepatitis patients for assessing liver fibrosis
Al Danaf L, Hussein Kamareddine M, Fayad E, Hussain A, Farhat S

Retrospective Study

- 754 Testosterone therapy reduces hepatic steatosis in men with type 2 diabetes and low serum testosterone concentrations
Apostolov R, Gianatti E, Wong D, Kutaiba N, Gow P, Grossmann M, Sinclair M

- 766** Impact of liver cirrhosis on ST-elevation myocardial infarction related shock and interventional management, a nationwide analysis

Dar SH, Rahim M, Hosseini DK, Sarfraz K

Observational Study

- 778** Gravity assistance enables liver stiffness measurements to detect liver fibrosis under congestive circumstances

Suda T, Sugimoto A, Kanefuji T, Abe A, Yokoo T, Hoshi T, Abe S, Morita S, Yagi K, Takahashi M, Terai S

- 791** Total cholesterol to high-density lipoprotein ratio and nonalcoholic fatty liver disease in a population with chronic hepatitis B

Zhou YG, Tian N, Xie WN

- 802** Assessment of resting energy expenditure in patients with cirrhosis

Ferreira S, Marroni CA, Stein JT, Rayn R, Henz AC, Schmidt NP, Carteri RB, Fernandes SA

Prospective Study

- 812** Prognostic value of von-Willebrand factor in patients with liver cirrhosis and its relation to other prognostic indicators

Curakova Ristovska E, Genadieva-Dimitrova M

META-ANALYSIS

- 827** Effects and safety of natriuretic peptides as treatment of cirrhotic ascites: A systematic review and meta-analysis

Gantzel RH, Kjær MB, Jepsen P, Aagaard NK, Watson H, Gluud LL, Grønbaek H

CASE REPORT

- 846** Late polymicrobial transjugular intrahepatic portosystemic shunt infection in a liver transplant patient: A case report

Perez IC, Haskal ZJ, Hogan JJ, Argo CK

- 854** Angiotensin converting enzyme inhibitor associated spontaneous herniation of liver mimicking a pleural mass: A case report

Tebha SS, Zaidi ZA, Sethar S, Virk MAA, Yousaf MN

- 860** Not all liver tumors are alike — an accidentally discovered primary hepatic leiomyosarcoma: A case report

Garrido I, Andrade P, Pacheco J, Rios E, Macedo G

ABOUT COVER

Editorial Board Member of *World Journal of Hepatology*, Salvatore Sutti, MSc, PhD, Assistant Professor, Department of Health Sciences, University of East Piedmont, Novara 28100, Italy. salvatore.sutti@med.uniupo.it

AIMS AND SCOPE

The primary aim of *World Journal of Hepatology* (*WJH*, *World J Hepatol*) is to provide scholars and readers from various fields of hepatology with a platform to publish high-quality basic and clinical research articles and communicate their research findings online.

WJH mainly publishes articles reporting research results and findings obtained in the field of hepatology and covering a wide range of topics including chronic cholestatic liver diseases, cirrhosis and its complications, clinical alcoholic liver disease, drug induced liver disease autoimmune, fatty liver disease, genetic and pediatric liver diseases, hepatocellular carcinoma, hepatic stellate cells and fibrosis, liver immunology, liver regeneration, hepatic surgery, liver transplantation, biliary tract pathophysiology, non-invasive markers of liver fibrosis, viral hepatitis.

INDEXING/ABSTRACTING

The *WJH* is now abstracted and indexed in PubMed, PubMed Central, Emerging Sources Citation Index (Web of Science), Scopus, Reference Citation Analysis, China National Knowledge Infrastructure, China Science and Technology Journal Database, and Superstar Journals Database. The 2021 edition of Journal Citation Reports® cites the 2020 Journal Citation Indicator (JCI) for *WJH* as 0.61. The *WJH*'s CiteScore for 2020 is 5.6 and Scopus CiteScore rank 2020: Hepatology is 24/62.

RESPONSIBLE EDITORS FOR THIS ISSUE

Production Editor: Yi-Xuan Cai, Production Department Director: Xiang Li, Editorial Office Director: Xiang Li.

NAME OF JOURNAL

World Journal of Hepatology

ISSN

ISSN 1948-5182 (online)

LAUNCH DATE

October 31, 2009

FREQUENCY

Monthly

EDITORS-IN-CHIEF

Nikolaos Pyrsopoulos, Ke-Qin Hu, Koo Jeong Kang

EDITORIAL BOARD MEMBERS

<https://www.wjgnet.com/1948-5182/editorialboard.htm>

PUBLICATION DATE

April 27, 2022

COPYRIGHT

© 2022 Baishideng Publishing Group Inc

INSTRUCTIONS TO AUTHORS

<https://www.wjgnet.com/bpg/gerinfo/204>

GUIDELINES FOR ETHICS DOCUMENTS

<https://www.wjgnet.com/bpg/GerInfo/287>

GUIDELINES FOR NON-NATIVE SPEAKERS OF ENGLISH

<https://www.wjgnet.com/bpg/gerinfo/240>

PUBLICATION ETHICS

<https://www.wjgnet.com/bpg/GerInfo/288>

PUBLICATION MISCONDUCT

<https://www.wjgnet.com/bpg/gerinfo/208>

ARTICLE PROCESSING CHARGE

<https://www.wjgnet.com/bpg/gerinfo/242>

STEPS FOR SUBMITTING MANUSCRIPTS

<https://www.wjgnet.com/bpg/GerInfo/239>

ONLINE SUBMISSION

<https://www.f6publishing.com>



Not all liver tumors are alike — an accidentally discovered primary hepatic leiomyosarcoma: A case report

Isabel Garrido, Patrícia Andrade, João Pacheco, Elisabete Rios, Guilherme Macedo

Specialty type: Gastroenterology and hepatology

Provenance and peer review: Unsolicited article; Externally peer reviewed.

Peer-review model: Single blind

Peer-review report's scientific quality classification

Grade A (Excellent): 0
Grade B (Very good): B
Grade C (Good): 0
Grade D (Fair): D
Grade E (Poor): E

P-Reviewer: Gupta V, India; Hien NX, Vietnam

Received: January 10, 2022

Peer-review started: January 10, 2022

First decision: January 22, 2022

Revised: January 22, 2022

Accepted: March 6, 2022

Article in press: March 6, 2022

Published online: April 27, 2022



Isabel Garrido, Patrícia Andrade, Guilherme Macedo, Gastroenterology and Hepatology Department, Centro Hospitalar Universitário de São João, Porto 4200-319, Portugal

Isabel Garrido, Patrícia Andrade, Guilherme Macedo, World Gastroenterology Organization Porto Training Center, Porto 4200-319, Portugal

João Pacheco, Elisabete Rios, Pathology Department, Centro Hospitalar Universitário de São João, Porto 4200-319, Portugal

Corresponding author: Isabel Garrido, MD, Doctor, Gastroenterology and Hepatology Department, Centro Hospitalar Universitário de São João, Alameda Prof. Hernâni Monteiro, Porto 4200-319, Portugal. isabelmng@hotmail.com

Abstract

BACKGROUND

Primary hepatic leiomyosarcoma is a very rare entity that originates from smooth muscle. Preoperative diagnosis requires a high degree of suspicion due to atypical clinical presentation and non-specific imaging features.

CASE SUMMARY

We report the case of a 42-year-old man, with no relevant past medical history, accidentally diagnosed with a nodular liver lesion on a routine abdominal ultrasound. Liver function tests and hematology parameters as well as tumor markers were normal. A contrast-enhanced abdominal computed tomography scan revealed a heterogenous hepatic lesion measuring 40 mm 30 mm, adjacent to the left branch of the portal vein and the round ligament. Due to the unclear diagnosis, the patient underwent surgical resection. Histopathological and immunohistochemical examinations confirmed complete (R0) resection of a hepatic leiomyosarcoma. The patient remains without any signs of tumor recurrence for more than 2 years.

CONCLUSION

We report a rare case of accidentally diagnosed primary hepatic leiomyosarcoma originating from the portal vein or the round ligament. Although this tumor has aggressive metastatic potential, a tumor-free resection margin is essential to improve survival.

Key Words: Primary hepatic leiomyosarcoma; Portal vein; Round ligament; Surgical

resection; Case report

©The Author(s) 2022. Published by Baishideng Publishing Group Inc. All rights reserved.

Core Tip: Sarcomas comprise only 1%-2% of all primary liver malignancies, and leiomyosarcoma is even rarer. We report a rare case of primary hepatic leiomyosarcoma accidentally diagnosed and surgically treated. The diagnosis requires a high level of suspicion because the clinical scenario and cross-imaging are not specific. Thus, histological examination is the only way to reach the diagnosis. In our case, the tumor probably originated from the left branch of the portal vein or the round ligament. Radical hepatectomy is the cornerstone of treatment. However, this tumor has aggressive metastatic potential and is usually diagnosed in locally advanced or metastatic disease. Two years after surgical resection, our patient is alive and with no evidence of tumor recurrence, likely because the diagnosis was established at an early stage and the surgery achieved a tumor-free margin.

Citation: Garrido I, Andrade P, Pacheco J, Rios E, Macedo G. Not all liver tumors are alike — an accidentally discovered primary hepatic leiomyosarcoma: A case report. *World J Hepatol* 2022; 14(4): 860-865

URL: <https://www.wjgnet.com/1948-5182/full/v14/i4/860.htm>

DOI: <https://dx.doi.org/10.4254/wjh.v14.i4.860>

INTRODUCTION

Sarcomas comprise only 1%-2% of all primary liver malignancies, and leiomyosarcoma is even rarer[1]. In the vast majority of cases of primary hepatic leiomyosarcoma, the tumor originates in the inferior vena cava. Clinical presentation and imaging features are non-specific and can mimic the most frequent primary liver tumors, namely hepatocellular carcinoma and intrahepatic cholangiocarcinoma. This tumor has aggressive metastatic potential and is usually diagnosed in a locally advanced or metastatic disease[2]. We report a rare case of primary hepatic leiomyosarcoma originating from the portal vein or the round ligament, accidentally diagnosed and surgically treated.

CASE PRESENTATION

Chief complaints

The patient was asymptomatic.

History of present illness

A 42-year-old man was referred for gastroenterology consultation due to a nodular hepatic lesion identified in a routine abdominal ultrasound.

History of past illness

Healthy, with no specific diseases.

Personal and family history

There was no family history of liver disease.

Physical examination

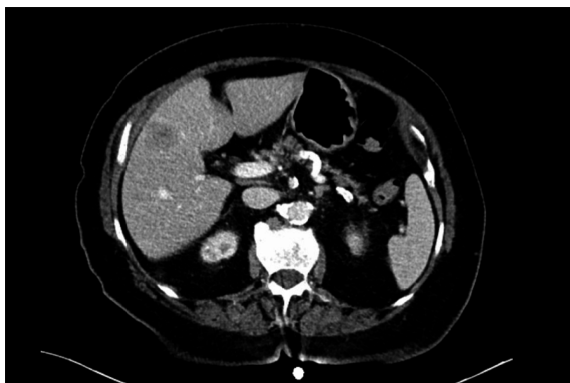There were no relevant changes on physical examination.

Laboratory examinations

Liver tests were normal. The metabolic, virological and autoimmune study was negative. Alpha-fetoprotein and cancer antigen 19-9 were also normal.

Imaging examinations

A contrast-enhanced abdominal computed tomography scan was performed, revealing a nodular hepatic lesion measuring 40 mm × 30 mm, adjacent to the left branch of the portal vein, in the transition from the right to the left lobe (Figure 1). The tumor was contrast-enhancing, with heterogeneous areas inside.



DOI: 10.4254/wjh.v14.i4.860 Copyright ©The Author(s) 2022.

Figure 1 Preoperative contrast-enhanced computed tomography scan demonstrated a heterogeneous mass in the liver adjacent to the left branch of the portal vein.

MULTIDISCIPLINARY EXPERT CONSULTATION

The imaging characteristics did not allow for a categorical distinction between hydatid cyst or other etiology. Therefore, it was decided at the multidisciplinary team meeting to perform surgical resection.

TREATMENT

In the explored laparoscopy, an exophytic lesion in segment IV was identified, involving the left branch of the portal vein and the round ligament; non-anatomic resection was performed without complications.

FINAL DIAGNOSIS

Histological examination showed complete resection of malignant mesenchymal neoplasia consisting of spindle cells with nuclei elongated to ovoid, with atypia and marked pleomorphism (Figure 2). In the immunohistochemical study, diffuse expression of actin and desmin was observed in neoplastic cells, in the absence of S100 expression. A chest-abdomen-pelvis computed tomography scan was performed in the postoperative period, with no evidence of residual or metastatic lesions. Moreover, this examination made it clear that it was a primary lesion. Thus, primary hepatic leiomyosarcoma was diagnosed with origin in the portal vein wall or the round ligament.

OUTCOME AND FOLLOW-UP

The patient remained under clinical surveillance. Two years after surgery, he is asymptomatic, with no evidence of tumor recurrence.

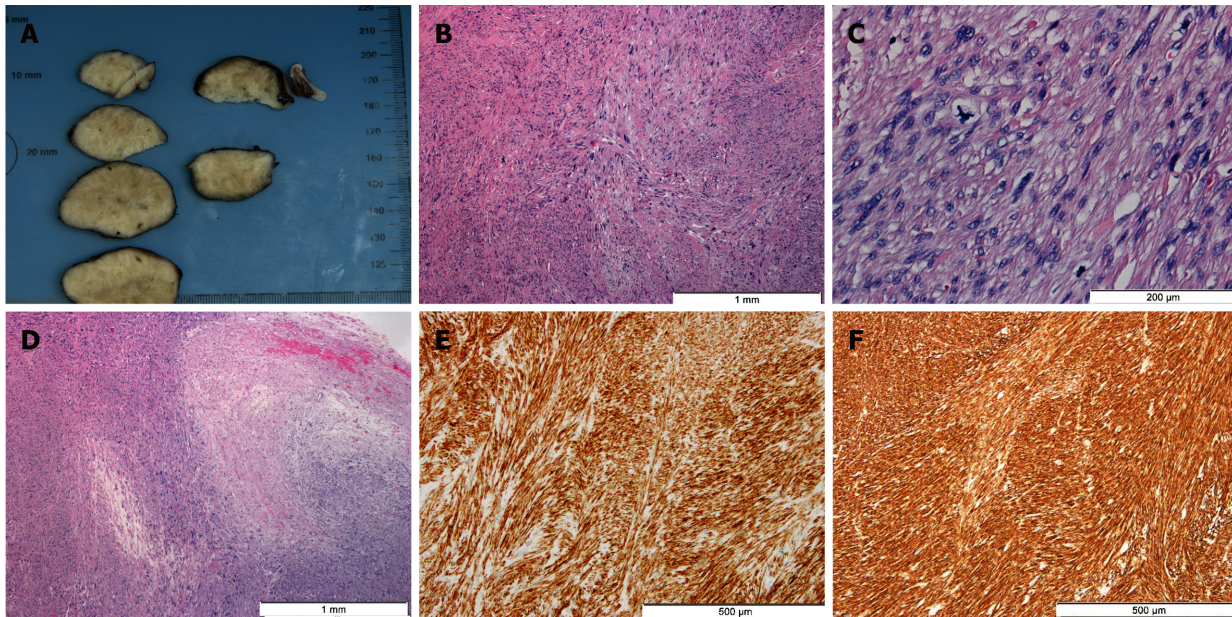
DISCUSSION

Primary hepatic leiomyosarcoma is a rare type of liver sarcoma; so far, less than 100 cases have been reported in the literature. Its diagnosis requires a high level of suspicion because the clinical scenario and cross-imaging are not specific[3]. In fact, patients are often asymptomatic or their symptoms are non-specific. Furthermore, alpha-fetoprotein and other serological markers are usually normal. Thus, histological examination is the only way to achieve the diagnosis, as in our case.

Primary hepatic leiomyosarcoma can arise from intrahepatic vascular structures, bile ducts or the round ligament. In our case, the tumor probably originated from the left branch of the portal vein or the round ligament. The first description of leiomyosarcoma by Perl in 1871 involved a tumor of the inferior vena cava[4]. Indeed, leiomyosarcoma of vascular origin often occurs in the inferior vena cava. On the other hand, those arising from portal vein are extremely rare and only 6 cases have been reported in the literature (Table 1)[5-10].

Table 1 Reported cases of leiomyosarcoma of the portal vein

Ref.	Wilson <i>et al</i> [5]	Sundaresan <i>et al</i> [6]	Boudjema <i>et al</i> [7]	Gohrbandt <i>et al</i> [8]	Gagnard <i>et al</i> [9]	Esposito <i>et al</i> [10]
Patient characteristics	Female, 28 yr	Female, 67 yr	Female, 44 yr	Female, 71 yr	Male, 53 yr	Male, 78 yr
Treatment	Operated - not resected	Left hepatectomy (R2)	Whipple with portal and biliary confluence reconstruction (R0)	Right hepatectomy with portal and biliary reconstruction (R0)	Right hepatectomy with portal and biliary reconstruction (R0)	Left hepatectomy (R0)
Outcome	Not available	Not available	Recurrence 27 mo after surgery. Died, 47 mo after surgery	Recurrence 36 mo after surgery. Alive	No recurrence. Alive	No recurrence. Alive



DOI: 10.4254/wjh.v14.i4.860 Copyright ©The Author(s) 2022.

Figure 2 Hepatic leiomyosarcoma. A: A well-circumscribed, white, solid mass of 4.3 cm exhibiting whorled features was seen on gross examination. B: Histologically, intersecting fascicles of spindle cells with elongate to ovoid nuclei displaying marked pleomorphism were observed [hematoxylin & eosin (HE), 40 ×]. C: Mitotic figures, including atypical ones, were frequent (7 mitosis/10 high power field) (HE, 200 ×). D: Foci of coagulative necrosis were observed (HE, 40 ×). E and F: Tumor cells were diffusely positive for desmin (100 ×) (E) and smooth muscle actin (100 ×) (F), in the absence of S100, c-Kit and discovered on GIST-1 (not shown).

No risk factors have been identified yet, although the increasing incidence of the tumor has been noted among immunosuppressed patients[11]. Nevertheless, more studies are needed to investigate the underlying pathogenetic mechanisms of this uncommon entity.

Due to the rarity of primary hepatic sarcomas in general and primary hepatic leiomyosarcoma in particular, the standard of care has not been defined. Radical R0 hepatectomy, in the form of wedge resection, segmentectomy, lobectomy or extended hepatectomy, is the cornerstone of successful management of primary hepatic leiomyosarcoma[12]. In our case, as the tumor was located in the liver, we were able to perform a surgical resection, obtaining a tumor-free margin. However, this tumor has aggressive metastatic potential and is usually diagnosed in locally advanced or metastatic disease. The role of adjuvant or neoadjuvant chemotherapy and radiotherapy regimens in these circumstances has not yet been established. Similarly, orthotopic liver transplantation remains controversial.

Little is known about the natural history of the disease. However, survival rates are relatively low, as the tumor is usually diagnosed in advanced stages. Chi *et al*[1] reported a median overall survival of 19 mo (range 0-181 mo) with 1-, 2- and 5-year survival rates of 61.2%, 41.1% and 14.5%, respectively. The smaller size of the lesion and tumor-free resection margin were identified as independent predictors of improved survival. Two years after surgical resection, our patient is alive and with no evidence of tumor recurrence, probably because the diagnosis was established at an early stage and the surgery achieved a tumor-free margin.

CONCLUSION

Primary hepatic leiomyosarcoma is a rare malignant disease with a poor prognosis. The authors report a rare case of resected primary hepatic leiomyosarcoma originating from the portal vein or the round ligament. Although there is no standard treatment due to the rarity of this disease, we showed that liver resection with a tumor-free resection margin could be an effective treatment in the early stages. Gastroenterologists should be alert to this unusual entity as early diagnosis requires a high degree of suspicion due to atypical clinical presentation and non-specific imaging features. We emphasize the need for a global database for these rare tumors to promote a better understanding and standardized treatment of these patients.

FOOTNOTES

Author contributions: Garrido I drafted the manuscript; Garrido I, Andrade P, Pacheco J, Rios E and Macedo G have revised and finalized the manuscript; All authors have approved the final version of the manuscript.

Informed consent statement: Written informed consent was obtained from the patient for publication of this case report and any accompanying images.

Conflict-of-interest statement: The authors have no disclosures to report.

CARE Checklist (2016) statement: The authors have read the CARE Checklist (2016), and the manuscript was prepared and revised according to the CARE Checklist (2016).

Open-Access: This article is an open-access article that was selected by an in-house editor and fully peer-reviewed by external reviewers. It is distributed in accordance with the Creative Commons Attribution NonCommercial (CC BY-NC 4.0) license, which permits others to distribute, remix, adapt, build upon this work non-commercially, and license their derivative works on different terms, provided the original work is properly cited and the use is non-commercial. See: <https://creativecommons.org/licenses/by-nc/4.0/>

Country/Territory of origin: Portugal

ORCID number: Isabel Garrido 0000-0002-7801-466X; Patrícia Andrade 0000-0003-1334-0947; João Pacheco 0000-0001-9348-1226; Elisabete Rios 0000-0002-3523-5032; Guilherme Macedo 0000-0002-9387-9872.

S-Editor: Gong ZM

L-Editor: Filipodia

P-Editor: Gong ZM

REFERENCES

- Chi M, Dudek AZ, Wind KP. Primary hepatic leiomyosarcoma in adults: analysis of prognostic factors. *Onkologie* 2012; **35**: 210-214 [PMID: 22488093 DOI: 10.1159/000337416]
- Shivathirthan N, Kita J, Iso Y, Hachiya H, Kyunghwa P, Sawada T, Kubota K. Primary hepatic leiomyosarcoma: Case report and literature review. *World J Gastrointest Oncol* 2011; **3**: 148-152 [PMID: 22046492 DOI: 10.4251/wjgo.v3.i10.148]
- Hamed MO, Roberts KJ, Merchant W, Lodge JP. Contemporary management and classification of hepatic leiomyosarcoma. *HPB (Oxford)* 2015; **17**: 362-367 [PMID: 25418451 DOI: 10.1111/hpb.12366]
- Halyo V, Martin L, Perl (1927-2014). *Nature* 2014; **516**: 330 [PMID: 25519123 DOI: 10.1038/516330a]
- Wilson SR, Hine AL. Leiomyosarcoma of the portal vein. *AJR Am J Roentgenol* 1987; **149**: 183-184 [PMID: 3495979 DOI: 10.2214/ajr.149.1.183]
- Sundaresan M, Kelly SB, Benjamin IS, Akosa AB. Primary hepatic vascular leiomyosarcoma of probable portal vein origin. *J Clin Pathol* 1990; **43**: 1036 [PMID: 2266177 DOI: 10.1136/jcp.43.12.1036-a]
- Boudjema K, Sulpice L, Levi Sandri GB, Meunier B. Portal vein leiomyosarcoma, an unusual cause of jaundice. *Dig Liver Dis* 2014; **46**: 1053-1054 [PMID: 25087678 DOI: 10.1016/j.dld.2014.07.001]
- Gohrbandt AE, Hansen T, Ell C, Heinrich SS, Lang H. Portal vein leiomyosarcoma: a case report and review of the literature. *BMC Surg* 2016; **16**: 60 [PMID: 27580598 DOI: 10.1186/s12893-016-0174-x]
- Gaignard E, Bergeat D, Stock N, Robin F, Boudjema K, Sulpice L, Rayar M, Meunier B. Portal vein leiomyosarcoma: A rare case of hepatic hilar tumor with review of the literature. *Indian J Cancer* 2019; **56**: 83-85 [PMID: 30950452 DOI: 10.4103/ijc.IJC_199_18]
- Esposito F, Lim C, Baranes L, Salloum C, Feray C, Calderaro J, Azoulay D. Primary leiomyosarcoma of the liver: Two new cases and a systematic review. *Ann Hepatobiliary Pancreat Surg* 2020; **24**: 63-67 [PMID: 32181431 DOI: 10.14701/ahbps.2020.24.1.63]
- Brichard B, Smets F, Sokal E, Clapuyt P, Vermeylen C, Cornu G, Rahier J, Otte JB. Unusual evolution of an Epstein-Barr

virus-associated leiomyosarcoma occurring after liver transplantation. *Pediatr Transplant* 2001; **5**: 365-369 [PMID: 11560757 DOI: 10.1034/j.1399-3046.2001.00022.x]



Published by **Baishideng Publishing Group Inc**
7041 Koll Center Parkway, Suite 160, Pleasanton, CA 94566, USA

Telephone: +1-925-3991568

E-mail: bpgoffice@wjgnet.com

Help Desk: <https://www.f6publishing.com/helpdesk>

<https://www.wjgnet.com>

