

# World Journal of *Hepatology*

*World J Hepatol* 2022 May 27; 14(5): 866-1052



### REVIEW

- 866** Role of hepatitis B virus in development of hepatocellular carcinoma: Focus on covalently closed circular DNA  
*Bianca C, Sidhartha E, Tiribelli C, El-Khobar KE, Sukowati CHC*
- 885** Emerging curative-intent minimally-invasive therapies for hepatocellular carcinoma  
*Zane KE, Nagib PB, Jalil S, Mumtaz K, Makary MS*

### MINIREVIEWS

- 896** Saving time and effort: Best practice for adapting existing patient-reported outcome measures in hepatology  
*Alrubaiy L, Hutchings HA, Hughes SE, Dobbs T*
- 911** Loco-regional treatment of hepatocellular carcinoma: Role of contrast-enhanced ultrasonography  
*Inzerillo A, Meloni MF, Taibbi A, Bartolotta TV*
- 923** Benign focal liver lesions: The role of magnetic resonance imaging  
*Gatti M, Maino C, Tore D, Carisio A, Darvizeh F, Tricarico E, Inchingolo R, Ippolito D, Faletti R*
- 944** Pediatric acute viral hepatitis with atypical variants: Clinical dilemmas and natural history  
*Sarma MS, Ravindranath A*

### ORIGINAL ARTICLE

#### Basic Study

- 956** Functions of three ubiquitin-conjugating enzyme 2 genes in hepatocellular carcinoma diagnosis and prognosis  
*Zhang CY, Yang M*

#### Case Control Study

- 972** Innovations in education: A prospective study of storytelling narratives to enhance hepatitis C virus knowledge among substance users  
*Talal AH, Ding YX, Markatou M*

#### Retrospective Study

- 984** Impact of utilization of hepatitis C positive organs in liver transplant: Analysis of united network for organ sharing database  
*Dhaliwal A, Dhindsa B, Ramai D, Sayles H, Chandan S, Rangray R*

- 992** Angle of covered self-expandable metallic stents after placement is a risk factor for recurrent biliary obstruction

*Tanoue K, Maruyama H, Ishikawa-Kakiya Y, Kinoshita Y, Hayashi K, Yamamura M, Ominami M, Nadatani Y, Fukunaga S, Otani K, Hosomi S, Tanaka F, Kamata N, Nagami Y, Taira K, Watanabe T, Fujiwara Y*

### Observational Study

- 1006** Dietary phytochemical consumption is inversely associated with liver alkaline phosphatase in Middle Eastern adults

*Darabi Z, Webb RJ, Mozaffari-Khosravi H, Mirzaei M, Davies IG, Khayyatadeh SS, Mazidi M*

### Prospective Study

- 1016** Prospective validation to prevent symptomatic portal vein thrombosis after liver resection

*Yoshida N, Yamazaki S, Masamichi M, Okamura Y, Takayama T*

### SYSTEMATIC REVIEWS

- 1025** Prognostic non-invasive biomarkers for all-cause mortality in non-alcoholic fatty liver disease: A systematic review and meta-analysis

*Cianci N, Subhani M, Hill T, Khanna A, Zheng D, Sheth A, Crooks C, Aithal GP*

### CASE REPORT

- 1038** Biliary obstruction following transjugular intrahepatic portosystemic shunt placement in a patient after liver transplantation: A case report

*Macinga P, Gogova D, Raupach J, Jarosova J, Janousek L, Honsova E, Taimr P, Spicak J, Novotny J, Peregrin J, Hucl T*

### LETTER TO THE EDITOR

- 1047** Reply to "Six-minute walking test performance is associated with survival in cirrhotic patients" to the editor

*Malaguti C, Mourão-Junior CA, Chebli JM*

- 1050** Role of biliary complications in chronic graft rejection after living donor liver transplantation

*Obed A, Bashir A, Jarrad A, Fuzesi L*

**ABOUT COVER**

Editorial Board Member of *World Journal of Hepatology*, Francesco Bellanti, MD, PhD, Doctor, Associate Professor, Department of Medical and Surgical Sciences, University of Foggia, Foggia 71122, Italy. francesco.bellanti@unifg.it

**AIMS AND SCOPE**

The primary aim of *World Journal of Hepatology* (WJH, *World J Hepatol*) is to provide scholars and readers from various fields of hepatology with a platform to publish high-quality basic and clinical research articles and communicate their research findings online.

WJH mainly publishes articles reporting research results and findings obtained in the field of hepatology and covering a wide range of topics including chronic cholestatic liver diseases, cirrhosis and its complications, clinical alcoholic liver disease, drug induced liver disease autoimmune, fatty liver disease, genetic and pediatric liver diseases, hepatocellular carcinoma, hepatic stellate cells and fibrosis, liver immunology, liver regeneration, hepatic surgery, liver transplantation, biliary tract pathophysiology, non-invasive markers of liver fibrosis, viral hepatitis.

**INDEXING/ABSTRACTING**

The WJH is now abstracted and indexed in PubMed, PubMed Central, Emerging Sources Citation Index (Web of Science), Scopus, Reference Citation Analysis, China National Knowledge Infrastructure, China Science and Technology Journal Database, and Superstar Journals Database. The 2021 edition of Journal Citation Reports® cites the 2020 Journal Citation Indicator (JCI) for WJH as 0.61. The WJH's CiteScore for 2020 is 5.6 and Scopus CiteScore rank 2020: Hepatology is 24/62.

**RESPONSIBLE EDITORS FOR THIS ISSUE**

Production Editor: Yi-Xuan Cai, Production Department Director: Xiang Li, Editorial Office Director: Xiang Li.

**NAME OF JOURNAL**

*World Journal of Hepatology*

**ISSN**

ISSN 1948-5182 (online)

**LAUNCH DATE**

October 31, 2009

**FREQUENCY**

Monthly

**EDITORS-IN-CHIEF**

Nikolaos Pyrsopoulos, Ke-Qin Hu, Koo Jeong Kang

**EDITORIAL BOARD MEMBERS**

<https://www.wjnet.com/1948-5182/editorialboard.htm>

**PUBLICATION DATE**

May 27, 2022

**COPYRIGHT**

© 2022 Baishideng Publishing Group Inc

**INSTRUCTIONS TO AUTHORS**

<https://www.wjnet.com/bpg/gerinfo/204>

**GUIDELINES FOR ETHICS DOCUMENTS**

<https://www.wjnet.com/bpg/GerInfo/287>

**GUIDELINES FOR NON-NATIVE SPEAKERS OF ENGLISH**

<https://www.wjnet.com/bpg/gerinfo/240>

**PUBLICATION ETHICS**

<https://www.wjnet.com/bpg/GerInfo/288>

**PUBLICATION MISCONDUCT**

<https://www.wjnet.com/bpg/gerinfo/208>

**ARTICLE PROCESSING CHARGE**

<https://www.wjnet.com/bpg/gerinfo/242>

**STEPS FOR SUBMITTING MANUSCRIPTS**

<https://www.wjnet.com/bpg/GerInfo/239>

**ONLINE SUBMISSION**

<https://www.f6publishing.com>



Prospective Study

# Prospective validation to prevent symptomatic portal vein thrombosis after liver resection

Nao Yoshida, Shintaro Yamazaki, Moriguchi Masamichi, Yukiyasu Okamura, Tadatoshi Takayama

**Specialty type:** Gastroenterology and hepatology

**Provenance and peer review:** Unsolicited article; Externally peer reviewed

**Peer-review model:** Single blind

**Peer-review report's scientific quality classification**

Grade A (Excellent): 0  
Grade B (Very good): 0  
Grade C (Good): 0  
Grade D (Fair): 0  
Grade E (Poor): 0

**P-Reviewer:** Li HL, China; Zhuge YZ, China

**Received:** March 26, 2021

**Peer-review started:** March 26, 2021

**First decision:** August 18, 2021

**Revised:** September 17, 2021

**Accepted:** May 8, 2022

**Article in press:** May 8, 2022

**Published online:** May 27, 2022



Nao Yoshida, Shintaro Yamazaki, Moriguchi Masamichi, Yukiyasu Okamura, Tadatoshi Takayama, Department of Digestive Surgery, Nihon University School of Medicine, Tokyo 1738610, Japan

**Corresponding author:** Shintaro Yamazaki, PhD, Associate Professor, Department of Digestive Surgery, Nihon University School of Medicine, 30-1 Ohayaguchi kami-mahi Itabashi-ku, Tokyo 1738610, Japan. [yamazaki-nmed@umin.ac.jp](mailto:yamazaki-nmed@umin.ac.jp)

## Abstract

### BACKGROUND

Portal vein thrombosis (PVT) after liver resection is rare but can lead to life-threatening liver failure. This prospective study evaluated patients using contrast-enhanced computed tomography (E-CT) on the first day after liver resection for early PVT detection and management.

### AIM

To evaluate patients by E-CT on the first day after liver resection for early PVT detection and immediate management.

### METHODS

Patients who underwent liver resection for primary liver cancer from January 2015 were enrolled. E-CT was performed on the first day after surgery in patients undergoing anatomical resection, multiple resections, or with postoperative bile leakage in the high-risk group for PVT. When PVT was detected, anticoagulant therapy including heparin, warfarin, and edoxaban was administered. E-CT was performed monthly until PVT resolved.

### RESULTS

The overall incidence of PVT was 1.57% (8/508). E-CT was performed on the first day after surgery in 235 consecutive high-risk patients (165 anatomical resections, 74 multiple resections, and 28 bile leakages), with a PVT incidence of 3.4% (8/235). Symptomatic PVT was not observed in the excluded cohort. Multivariate analyses revealed that sectionectomy was the only independent predictor of PVT [odds ratio (OR) = 12.20; 95% confidence interval (CI): 2.22-115.97;  $P = 0.003$ ]. PVT was found in the umbilical portion of 75.0% (6/8) of patients, and sectionectomy on the left side showed the highest risk of PVT (OR = 14.10; 95%CI: 3.17-62.71;  $P < 0.0001$ ).



## CONCLUSION

Sectionectomy on the left side should be chosen with caution as it showed the highest risk of PVT. E-CT followed by anticoagulant therapy was effective in managing early-phase PVT for 2 mo without adverse events.

**Key Words:** Portal vein thrombosis; Liver resection; Anatomical resection; Anticoagulant therapy; Hepatocellular carcinoma; Umbilical port

©The Author(s) 2022. Published by Baishideng Publishing Group Inc. All rights reserved.

**Core Tip:** This prospective study evaluated patients by contrast-enhanced computed tomography (E-CT) on the first day after liver resection for early portal vein thrombosis (PVT) detection and immediate management. Sectionectomy on the left side should be treated with caution as it showed the highest risk of PVT. E-CT on the first day and immediate anticoagulant therapy were effective in managing early-phase PVT for 2 mo without adverse events.

**Citation:** Yoshida N, Yamazaki S, Masamichi M, Okamura Y, Takayama T. Prospective validation to prevent symptomatic portal vein thrombosis after liver resection. *World J Hepatol* 2022; 14(5): 1016-1024

**URL:** <https://www.wjgnet.com/1948-5182/full/v14/i5/1016.htm>

**DOI:** <https://dx.doi.org/10.4254/wjh.v14.i5.1016>

## INTRODUCTION

The rate of portal vein thrombosis (PVT) after liver resection occurs in 2.1%-11.1% of cases[1-5] and was unchanged in recent series[6-8]. While no symptoms are detected in the early phase, severe PVT can lead to life-threatening liver failure[9,10]. Immediate anticoagulant therapy after surgery is recommended in some cases[11]. However, patients who undergo liver resection may have coagulation disorders such as hepatocellular carcinoma, which makes it difficult to administer routine anticoagulant therapy. Therefore, early detection and immediate intervention for asymptomatic PVT are essential. The risk factors for PVT after liver resection include hepatic clumping and total operation time[1,2,4,7,8], resection scale and location[1,3], splenectomy[3], and portal vein reconstruction[4,5].

Studies have reported the occurrence of postoperative PVT in high-risk[1-3,7,8] or symptomatic cases in the first 5-7 d after liver resection[4,6]. However, there is a lack of information regarding the timing of PVT occurrence, approaches for its early detection, and the efficacy of early interventions. No study has focused on early detection and intervention before symptomatic PVT. Therefore, we conducted a prospective study and assessed patients considered to be at high risk for PVT after liver resection using screening with contrast-enhanced computed tomography (E-CT). E-CT was performed on the first day after liver resection, and immediate anticoagulant therapy was started when PVT was detected. We assessed the frequency, predictive factors, and efficacy of early intervention for PVT.

## MATERIALS AND METHODS

### Patients

This study was conducted in patients who underwent liver resection for primary liver cancer from January 2015 onward. E-CT was performed on the first day after surgery for patients at high risk of PVT, including those undergoing: Anatomical resection, multiple resections, or postoperative bile leakage. In previous studies, the frequency of PVT was hypothesized to be 5%. Consequently, a total of 400 resections was expected to detect 20 PVT events[1]. Our institution performs an average of 150 liver resections for primary liver cancer annually; thus, the study was estimated to take 3 years to complete. This study excluded patients with metastatic liver cancer, bile duct or portal vein reconstruction, laparoscopic surgery, contrast medium allergy, renal dysfunction, or thrombus requiring anticoagulant therapy. The liver, lungs, and legs of patients with abnormal preoperative serum D-dimer levels were screened by ultrasound and E-CT.

### Surgical procedure and postoperative management

Liver resection was performed under general anesthesia with hypoventilation during liver transection. Total hepatic inflow occlusion was performed using Pringle's maneuver, in which the protocol called for a 15-min blood flow clamp and a 5-min release[12,13]. The liver parenchyma was transected using the

crush-clamping method, and the vessels were ligated using an energy device or silk thread[14-16]. At the end of the operation, routine intraoperative ultrasonography was performed to detect any thrombus in the liver. A drain was placed on the resected stump of the liver and removed 3 d after the operation [17]. Elastic bandages and intermittent air compression on the legs were routinely used to prevent thrombosis.

### **Evaluation of PVT and anticoagulant therapy**

PVT was defined as a defect image that was confirmed in the portal phase of dynamic CT. The images were checked by a surgeon (Yoshida N) and 2 independent radiologists. When PVT was detected, anticoagulant therapy was performed according to the following protocol: Unfractionated heparin (10000-12000 units/d), warfarin (2 mg/d), and direct oral anticoagulant edoxaban tosylate hydrate (LIXIANA®, 30 mg/d). The target range of anticoagulant therapy was an activated partial thromboplastin time of 50-60 s and a prothrombin time-international normalized ratio of 1.5-2.0. In small cases of PVT, short half-life heparin was used just after the detection of PVT by E-CT, whereas in cases of large PVT, intravenous heparin combined with oral anticoagulation (warfarin or direct oral anticoagulant) was used as an initial treatment. Heparin was then changed to an oral anticoagulant 10 d after the operation. E-CT was performed in all treated cases for 1 wk after starting anticoagulant therapy to confirm the severity or new appearance of PVT. Anticoagulant therapy was continued when the PVT had disappeared by monthly E-CT after discharge. Patients who had no PVT on E-CT the first day after surgery did not undergo E-CT until discharge. All patients received E-CT at 2 or 3 mo after discharge as a routine follow-up post liver resection.

### **Statistical analyses**

Statistical analyses were performed using JMP 10.0.2 (SAS Institute Inc., Cary, NC, United States). Data are expressed as the mean  $\pm$  standard error of the mean. Categorical variables were compared using  $\chi^2$  tests, whereas continuous variables were compared using nonparametric Wilcoxon or parametric *t*-tests. Statistical significance was set at  $P \leq 0.05$ . Risk factors evaluated by univariate logistic regression ( $P < 0.05$ ) were included in the multivariate analysis to determine the independent risk factors. This study protocol was approved by the ethics committee of Nihon University School of Medicine (Protocol No. RK-170214-3; Tokyo, Japan) and was registered in the UMIN Clinical Trials Registry under entry number UMIN000047362.

## **RESULTS**

### **PVT analyses using patient flow**

This study was started in January 2015 and discontinued in December 2018 after 4 years because the occurrence of PVT was lower than our hypothesis. The incidence of PVT was 8 (1.57%) among the 508 participants over the study period. E-CT was performed on the first day after liver resection in 235 patients (165 for anatomical resections, 74 for multiple resections, and 28 for bile leakage). The incidence of PVT in the high-risk group was 3.4% (8/235) (Figure 1). No cases of symptomatic PVT occurred in patients who met the exclusion criteria.

### **Risk factors associated with PVT after liver resection**

In univariate analyses, the occurrence of PVT was significantly higher in women (50.0% *vs* 79.7%;  $P = 0.04$ ) and in patients who had undergone sectionectomy (75.0% *vs* 24.2%;  $P = 0.001$ ). In multivariate analyses, sectionectomy [odds ratio (OR) = 12.2, 95% confidence interval (CI): 2.22-115.97;  $P = 0.003$ ] was the only independent predictor of PVT occurrence (Table 1). There were 2 postoperative deaths, neither of which was related to PVT. One patient with pneumonia underwent a pathological autopsy and did not show thrombus anywhere. One patient with liver failure and no PVT was observed on E-CT during the study.

### **PVT frequency and distribution**

Six of the eight patients with PVT underwent anatomical resection. Most instances of PVT were found on the left side of the liver, with 62.5% (5/8) around the umbilical portion (UP) and one in the apex of the UP (12.5%). Only one instance was found at the resection stump of segment 8 and one in the anterior branch (Figure 2). All PVTs at the UP were found in the second-to third-order branches, with preserved peripheral blood flow from the thrombus at the time of detection. Among the procedures, 3 patients among 26 who underwent left lateral sectionectomy developed PVT (11.5%). PVT also developed in 2 of 3 patients undergoing left medial sectionectomy (66.7%) and in 1 of the 25 patients who underwent right posterior sectionectomy (4%). Among the procedures, sectionectomy on the left side was associated with the highest risk of PVT (OR = 14.10; 95%CI: 3.17-62.71;  $P < 0.0001$ ) (Table 2).

**Table 1 Risk factors associated with portal vein thrombosis after liver resection**

Variables	Univariate analyses			Multivariate analyses		
	PVT (+), <i>n</i> = 8	PVT (-), <i>n</i> = 227	<i>P</i> value	OR	95%CI	<i>P</i> value
Back ground characteristics						
Age	69.9 ± 3.4	67.8 ± 0.6	0.54			
Male sex	4 (50.0%)	181 (79.7%)	0.04	0.25	0.05-1.29	0.10
Hepatocellular carcinoma (+)	7 (87.5%)	190 (73.7%)	0.77			
Multiple tumor	2 (25.0%)	72 (31.7%)	0.69			
Heavy drinker	2 (25.0%)	55 (24.2%)	0.96			
Portal vein embolization	0	12 (5.3%)	0.50			
Body mass index	24.8 ± 1.2	23.7 ± 0.2	0.39			
Preoperative anticoagulant therapy	1 (12.5%)	10 (4.4%)	0.29	7.95	0.32-106.81	0.17
Diabetes mellitus	2 (25.0%)	92 (40.5%)	0.38			
HBsAg (+)	1 (12.5%)	39 (17.2%)	0.73			
HCVAb (+)	2 (25.0%)	52 (22.9%)	0.89			
Platelet count as × 10 <sup>4</sup> /μL	18.6 ± 7.8	21.4 ± 1.5	0.72			
Albumin in g/dL	4.2 ± 0.2	4.2 ± 0.03	0.79			
Total bilirubin in mg/dL	0.7 ± 0.2	0.7 ± 0.03	0.92			
Prothrombin time, %	93.8 ± 3.8	93.4 ± 0.7	0.94			
D-dimer in ng/mL	1.7 ± 0.8	1.7 ± 0.2	0.97			
ICGR15, %	15.0 ± 2.2	11.7 ± 0.4	0.14	0.91	0.82-1.02	0.09
Liver damage B	0	10 (6.3%)	0.53			
Procedure						
Anatomical resection	6 (75.0%)	159 (70.0%)	0.76			
Segmentectomy	0	48 (21.2%)	0.14			
Sectionectomy	6 (75.0%)	55 (24.2%)	0.001	12.20	2.22-115.97	0.003
Hemihepatectomy	0	56 (24.7%)	0.11			
Surgical outcomes						
Operatin time in min	324 ± 40	374 ± 8	0.21			
Hepatic clamping time in min	76 ± 15	89 ± 3	0.38	1.01	0.99-1.03	0.56
Blood loss in g	517 ± 186	455 ± 35	0.74			
RBC transfusion	1 (12.5%)	13 (5.7%)	0.43			
Surgical results						
Complication CD ≥ 3a	3 (37.5%)	50 (22.0%)	0.30			
Bile leakage	2 (25.0%)	26 (11.5%)	0.25	3.12	0.35-21.58	0.28
Mortality	0	2 (0.9%)	0.79			
Histological cirrhosis	1 (12.5%)	32 (14.1%)	0.90			

CD: Clavian-Dindo classification; CI: Confidence interval; HBsAg: Hepatitis B surface antigen; HCVAb: Hepatitis C virus antibody; OR: Odds ratio; PVT: Portal vein thrombosis; RBC: Red blood cell.

### Treatment and outcomes

No adverse events were observed with anticoagulant therapy, and all patients were successfully treated (Table 3 and Figure 3). One patient (case 5) stopped treatment because the thrombus did not extend to the central side. The median period of PVT treatment was 55 d (range: 37-140 d).



**Table 2 Comparisons of left and right sides for each procedure**

		PVT (+), <i>n</i> = 8	PVT (-), <i>n</i> = 227	<i>P</i> value	OR	95%CI
Partial resection		2 (25.0%)	68 (30.0%)	0.76	0.78	0.15-3.96
Segmentectomy	Left	-	8 (3.5%)	0.59		
	Right	-	40 (17.6%)	0.19		
Sectionectomy	Left	5 (62.5%)	24 (10.6%)	< 0.0001	14.10	3.17-62.71
	Right	1 (12.5%)	31 (13.7%)	0.93	0.90	0.11-7.60
Hemihepatectomy	Left	-	37 (16.3%)	0.21		
	Right	-	19 (8.4%)	0.39		

CI: Confidence interval; OR: Odds ratio; PVT: Portal vein thrombosis.

**Table 3 Portal vein thrombosis cases, treatments, and outcomes**

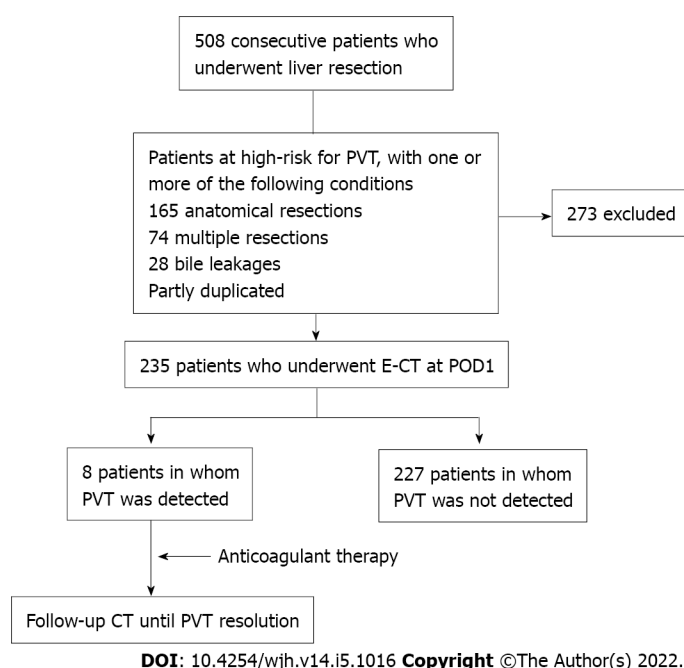
Case	No. of patients	Age	Sex	Diagnosis	Extent of resection	PVT location	Anticoagulation	Outcome	PVT treatment period in d
1	65	71	Male	HCC	Left medial sectionectomy	UP	Heparin, warfarin	Resolved	53
2	135	83	Male	ICC	Left lateral sectionectomy	Lt branch, UP	Heparin, warfarin	Resolved	37
3	151	50	Female	HCC	Left lateral sectionectomy, partial resection (S1)	UP	Heparin, warfarin	Resolved	63
4	214	75	Female	HCC	Left lateral sectionectomy	UP	Warfarin	Resolved	59
5	385	78	Female	HCC	Partial resection (S8)	P8 stump	Edoxaban	Stable	46
6	391	70	Male	HCC	Right posterior sectionectomy	Anterior branch	Heparin, warfarin	Resolved	44
7	417	75	Female	HCC	Partial resection (S4, S7)	UP	Heparin, edoxaban	Resolved	140
8	475	57	Male	HCC	Left medial sectionectomy	UP	Heparin, edoxaban	Resolved	58

HCC: Hepatocellular carcinoma; ICC: Intrahepatic cholangiocarcinoma; PVT: Portal vein thrombosis; UP: Umbilical portion.

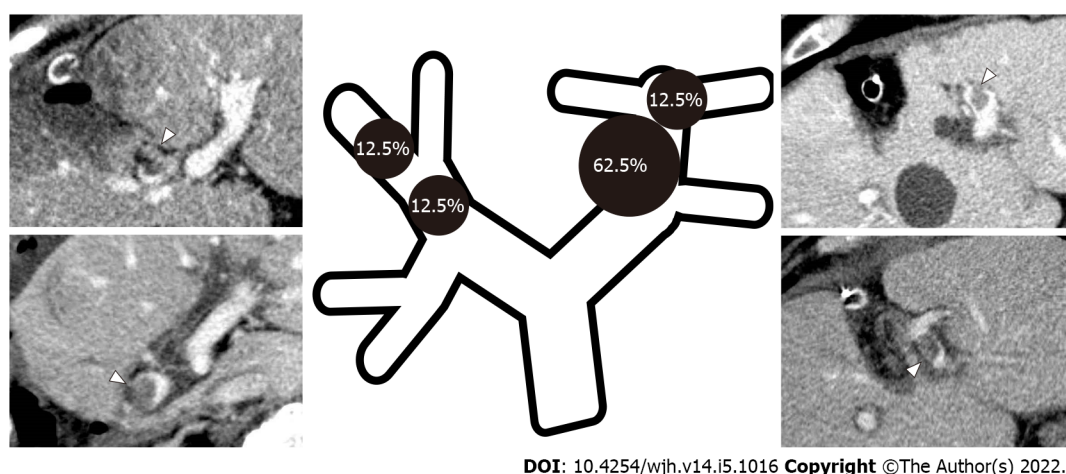
## DISCUSSION

The incidence of PVT was lower (1.56%) in this study than in previous reports[3,4,6]. In the high-risk group, E-CT on the first day after surgery had an incidence of the initial phase of asymptomatic PVT of 3.4% (8/235), which was successfully treated with anticoagulant therapy. The results of this study demonstrated that PVT formed as early as the first day after liver resection. To date, most studies have found PVT at 5-7 d after liver resection[1-3,7,8]. In this phase, peripheral blood flow is obstructed and impaired by a large thrombus. Anticoagulant therapy takes a long time to resolve the thrombus, and some patients experience severe liver failure[3,6]. Early anticoagulant therapy is an ideal option for patients at high-risk for PVT; however, no study has reported the initiation of PVT. Consequently, in this study, we aimed to detect early-stage PVT in a high-risk group of patients using E-CT. This enabled the prompt initiation of anticoagulant therapy and thus preserved peripheral blood flow from PVT.

The risk factors for PVT after liver resection include operating procedure or scale[1,3], operation or hepatic clamping time[1,2,4,7,8], portal vein reconstruction, and complications[3,5]. Sectionectomy is the only independent predictor of PVT occurrence. Sectionectomy requires ligation of the second branch root of the liver, which is more complex than hemihepatectomy. With regard to the sites of PVT, six of the eight PVTs identified in this study were found in the UP and 5 patients had undergone sectionectomy on the left side. A previous report suggested a higher PVT incidence in the UP than in other sites, and that left lateral sectionectomy was a risk factor for PVT[6]. Thrombi occur due to three factors (*i.e.*, stasis of blood flow, hypercoagulable state, and endothelial injury), known as Virchow's triad[18]. Blood stasis occurs due to the shape of the UP, which flows dorsal to ventral and caudal to cranial, especially following liver transection. The initial site of PVT is unknown, but this study detected small PVTs in the UP. Turbulent flow caused by reduced liver parenchyma after liver resection and a change



**Figure 1 Patient flow of the analysis of portal vein thrombosis.** Contrast-enhanced computed tomography was performed on the first day in 235 patients, who were categorized as high risk by three factors: Anatomical resection (165 patients), multiple resections (74 patients), and bile leakage (28 patients). Eight patients were detected with portal vein thrombosis in the high-risk group. E-CT: Contrast-enhanced computed tomography; POD: Post operative day; PVT: Portal vein thrombosis.



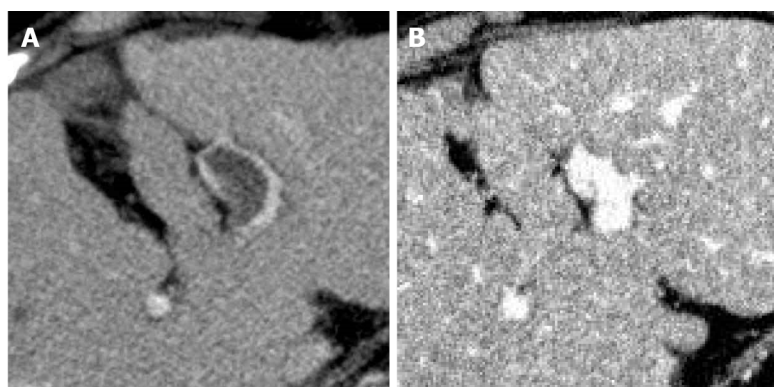
**Figure 2 Portal vein thrombosis distribution and frequency.** The sites of portal vein thrombosis included those around the umbilical portion (UP) (62.5%, 5/8 patients) and in the apex of the UP (12.5%, 1 patient), as well as the P8 resection stump (12.5%, 1 patient) and the anterior portal vein branch (12.5%, 1 patient).

in the shape of the UP in cases of sectionectomy on the left side may increase the risk of PVT.

Although this was a prospective study, it had several limitations. First, the incidence of PVT was lower than expected. The statistical power to analyze the risk factors for PVT was not optimal therefore, this protocol is ongoing to analyze larger population in the future. Second, E-CT and anticoagulant therapy were contraindicated. Third, cost-effectiveness is low for E-CT; therefore, routine ultrasonography may be more practical for the high-risk group in our study. Fourth, E-CT alone was insufficient to detect a small PVT on day 1. Therefore, it is necessary to combine coagulation makers and images.

## CONCLUSION

In conclusion, sectionectomy on the left side should be cautiously managed, as this patient group showed the highest risk of PVT. Immediate anticoagulant therapy from the first day after surgery is recommended for patients at high risk for PVT.



DOI: 10.4254/wjh.v14.i5.1016 Copyright ©The Author(s) 2022.

**Figure 3 Before and after anticoagulation therapy.** A: In case 7, portal vein thrombosis (PVT) was found in the umbilical portion; B: PVT disappeared 140 d after starting anticoagulant therapy.

## ARTICLE HIGHLIGHTS

### Research background

Portal vein thrombus (PVT) is one of the potentially lethal complication after liver resection; however, its etiology and the way for immediate treatment is unsettled.

### Research motivation

Based on our experience, we tried to resolve hepatic failure due to huge PVT.

### Research objectives

The study was conducted in patients who underwent open liver resection for cancer in our institution.

### Research methods

Retrospective but retrospectively collected cohort.

### Research results

In a total of 235 patients, 8 had major PVT. We successfully treated the patients with anticoagulant therapy without adverse events. No hepatic failure observed through this study.

### Research conclusions

Performing enhanced computed tomography (CT) on post-operative day 1 is an effective option to find a thrombi at the portal vein close to the surgical site.

### Research perspectives

The early detection of PVT by enhanced CT is a promising way to avoid hepatic failure after liver resection.

## FOOTNOTES

**Author contributions:** Yoshida N collected the patient's data; Yamazaki S designed this study; Masamichi M contributed to the proofreading of manuscript; Okamura Y and Takayama T supervised the writing of the manuscript.

**Institutional review board statement:** The ethics committee of Nihon University School of Medicine approved this clinical study.

**Clinical trial registration statement:** This study was registered in the UMIN Clinical Trials Registry under entry number UMIN000047362.

**Informed consent statement:** All study participants, or their legal guardian, provided informed written consent prior to study enrollment.

**Conflict-of-interest statement:** Authors have no conflict-of-interest of this study.

**Data sharing statement:** Author can provide any data of this study.

**CONSORT 2010 statement:** The authors have read the CONSORT 2010 statement, and the manuscript was prepared and revised according to the CONSORT 2010 statement.

**Open-Access:** This article is an open-access article that was selected by an in-house editor and fully peer-reviewed by external reviewers. It is distributed in accordance with the Creative Commons Attribution NonCommercial (CC BY-NC 4.0) license, which permits others to distribute, remix, adapt, build upon this work non-commercially, and license their derivative works on different terms, provided the original work is properly cited and the use is non-commercial. See: <https://creativecommons.org/licenses/by-nc/4.0/>

**Country/Territory of origin:** Japan

**ORCID number:** Nao Yoshida 0000-0002-6602-0042; Shintaro Yamazaki 0000-0002-0190-5923; Moriguchi Masamichi 0000-0001-5726-0864; Yukiyasu Okamura 0000-0003-3384-2709; Tadatoshi Takayama 0000-0002-4683-4743.

**S-Editor:** Wang JJ

**L-Editor:** Filipodia

**P-Editor:** Wang JJ

## REFERENCES

- 1 **Yoshiya S**, Shirabe K, Nakagawara H, Soejima Y, Yoshizumi T, Ikegami T, Yamashita Y, Harimoto N, Nishie A, Yamanaka T, Machara Y. Portal vein thrombosis after hepatectomy. *World J Surg* 2014; **38**: 1491-1497 [PMID: 24407940 DOI: 10.1007/s00268-013-2440-8]
- 2 **Yamashita Y**, Bekki Y, Imai D, Ikegami T, Yoshizumi T, Ikeda T, Kawanaka H, Nishie A, Shirabe K, Machara Y. Efficacy of postoperative anticoagulation therapy with enoxaparin for portal vein thrombosis after hepatic resection in patients with liver cancer. *Thromb Res* 2014; **134**: 826-831 [PMID: 25156238 DOI: 10.1016/j.thromres.2014.07.038]
- 3 **Kuboki S**, Shimizu H, Ohtsuka M, Kato A, Yoshitomi H, Furukawa K, Takayashiki T, Takano S, Okamura D, Suzuki D, Sakai N, Kagawa S, Miyazaki M. Incidence, risk factors, and management options for portal vein thrombosis after hepatectomy: a 14-year, single-center experience. *Am J Surg* 2015; **210**: 878-85.e2 [PMID: 26307424 DOI: 10.1016/j.amjsurg.2014.11.021]
- 4 **Han JH**, Kim DS, Yu YD, Jung SW, Yoon YI, Jo HS. Analysis of risk factors for portal vein thrombosis after liver resection. *Ann Surg Treat Res* 2019; **96**: 230-236 [PMID: 31073513 DOI: 10.4174/astr.2019.96.5.230]
- 5 **Uchida T**, Yamamoto Y, Sugiura T, Okamura Y, Ito T, Ashida R, Ohgi K, Aramaki T, Uesaka K. Prediction of Portal Vein Thrombosis Following Hepatectomy for Perihilar Cholangiocarcinoma: Efficacy of Postoperative Portal Vein Diameter Ratio and Angle. *Anticancer Res* 2019; **39**: 5019-5026 [PMID: 31519609 DOI: 10.21873/anticancer.13692]
- 6 **Mori A**, Arimoto A, Hamaguchi Y, Kajiura M, Nakajima A, Kanaya S. Risk Factors and Outcome of Portal Vein Thrombosis After Laparoscopic and Open Hepatectomy for Primary Liver Cancer: A Single-Center Experience. *World J Surg* 2020; **44**: 3093-3099 [PMID: 32394012 DOI: 10.1007/s00268-020-05565-4]
- 7 **Onda S**, Furukawa K, Shirai Y, Hamura R, Horiuchi T, Yasuda J, Shiozaki H, Gocho T, Shiba H, Ikegami T. New classification-oriented treatment strategy for portal vein thrombosis after hepatectomy. *Ann Gastroenterol Surg* 2020; **4**: 701-709 [PMID: 33319161 DOI: 10.1002/ags3.12383]
- 8 **Takata H**, Hirakata A, Ueda J, Yokoyama T, Maruyama H, Taniia N, Takano R, Haruna T, Makino H, Yoshida H. Prediction of portal vein thrombosis after hepatectomy for hepatocellular carcinoma. *Langenbecks Arch Surg* 2021; **406**: 781-789 [PMID: 33640991 DOI: 10.1007/s00423-021-02125-9]
- 9 **Amitrano L**, Guardascione MA, Brancaccio V, Margaglione M, Manguso F, Iannaccone L, Grandone E, Balzano A. Risk factors and clinical presentation of portal vein thrombosis in patients with liver cirrhosis. *J Hepatol* 2004; **40**: 736-741 [PMID: 15094219 DOI: 10.1016/j.jhep.2004.01.001]
- 10 **Lertpipopmetha K**, Auewarakul CU. High incidence of hepatitis B infection-associated cirrhosis and hepatocellular carcinoma in the Southeast Asian patients with portal vein thrombosis. *BMC Gastroenterol* 2011; **11**: 66 [PMID: 21658275 DOI: 10.1186/1471-230X-11-66]
- 11 **JCS Joint Working Group**. Guidelines for the diagnosis, treatment and prevention of pulmonary thromboembolism and deep vein thrombosis (JCS 2009). *Circ J* 2011; **75**: 1258-1281 [PMID: 21441695 DOI: 10.1253/circj.88-0010]
- 12 **Pringle JH**. V. Notes on the Arrest of Hepatic Hemorrhage Due to Trauma. *Ann Surg* 1908; **48**: 541-549 [PMID: 17862242 DOI: 10.1097/0000658-190810000-00005]
- 13 **Takayama T**, Makuuchi M, Inoue K, Sakamoto Y, Kubota K, Harihara Y. Selective and unselective clamping in cirrhotic liver. *Hepatogastroenterology* 1998; **45**: 376-380 [PMID: 9638410]
- 14 **Ikeda M**, Hasegawa K, Sano K, Imamura H, Beck Y, Sugawara Y, Kokudo N, Makuuchi M. The vessel sealing system (LigaSure) in hepatic resection: a randomized controlled trial. *Ann Surg* 2009; **250**: 199-203 [PMID: 19638927 DOI: 10.1097/SLA.0b013e3181a334f9]
- 15 **Gotohda N**, Yamanaka T, Saiura A, Uesaka K, Hashimoto M, Konishi M, Shimada K. Impact of energy devices during liver parenchymal transection: a multicenter randomized controlled trial. *World J Surg* 2015; **39**: 1543-1549 [PMID: 25637271 DOI: 10.1007/s00268-015-2967-y]
- 16 **Ichida A**, Hasegawa K, Takayama T, Kudo H, Sakamoto Y, Yamazaki S, Midorikawa Y, Higaki T, Matsuyama Y, Kokudo

- N. Randomized clinical trial comparing two vessel-sealing devices with crush clamping during liver transection. *Br J Surg* 2016; **103**: 1795-1803 [PMID: [27682642](#) DOI: [10.1002/bjs.10297](#)]
- 17 **Mitsuka Y**, Yamazaki S, Yoshida N, Masamichi M, Higaki T, Takayama T. Prospective Validation of Optimal Drain Management "The 3 × 3 Rule" after Liver Resection. *World J Surg* 2016; **40**: 2213-2220 [PMID: [27138885](#) DOI: [10.1007/s00268-016-3523-0](#)]
- 18 **Kumar DR**, Hanlin E, Glurich I, Mazza JJ, Yale SH. Virchow's contribution to the understanding of thrombosis and cellular biology. *Clin Med Res* 2010; **8**: 168-172 [PMID: [20739582](#) DOI: [10.3121/cmr.2009.866](#)]



Published by **Baishideng Publishing Group Inc**  
7041 Koll Center Parkway, Suite 160, Pleasanton, CA 94566, USA

**Telephone:** +1-925-3991568

**E-mail:** [bpgoffice@wjgnet.com](mailto:bpgoffice@wjgnet.com)

**Help Desk:** <https://www.f6publishing.com/helpdesk>

<https://www.wjgnet.com>

