

World Journal of *Hepatology*

World J Hepatol 2023 April 27; 15(4): 441-584



REVIEW

- 441 COVID-19 and liver injury: Pathophysiology, risk factors, outcome and management in special populations
Roshanshad R, Roshanshad A, Fereidooni R, Hosseini-Bensenjan M
- 460 Recent advances in recurrent hepatocellular carcinoma therapy
Gao YX, Ning QQ, Yang PX, Guan YY, Liu PX, Liu ML, Qiao LX, Guo XH, Yang TW, Chen DX
- 477 Comparison between metabolic-associated fatty liver disease and nonalcoholic fatty liver disease: From nomenclature to clinical outcomes
Alomari M, Rashid MU, Chadalavada P, Ragheb J, Zafar H, Suarez ZK, Khazaaleh S, Gonzalez AJ, Castro FJ
- 497 Emerging concepts in the care of patients with cirrhosis and septic shock
Jimenez JV, Garcia-Tsao G, Saffo S

MINIREVIEWS

- 515 Ablative strategies for recurrent hepatocellular carcinoma
Wang L, Liu BX, Long HY
- 525 Therapeutic possibilities of gut microbiota modulation in acute decompensation of liver cirrhosis
Garbuzenko DV
- 538 Morphological aspects of small-duct cholangiopathies: A minireview
Sticova E, Fabian O

ORIGINAL ARTICLE

Retrospective Study

- 554 Inferior outcomes of liver transplantation for hepatocellular carcinoma during early-COVID-19 pandemic in the United States
Lee IS, Okumura K, Misawa R, Sogawa H, Veillette G, John D, Diflo T, Nishida S, Dhand A
- 564 Peptic ulcer disease in non-alcoholic fatty liver disease hospitalizations: A new challenge on the horizon in the United States
Dahiya DS, Jahagirdar V, Ali H, Gangwani MK, Aziz M, Chandan S, Singh A, Perisetti A, Soni A, Inamdar S, Sanaka MR, Al-Haddad M

Observational Study

- 577 Clinicopathological features of 11 cases of chronic hepatitis B infection complicated with primary biliary cholangitis
Ye Y, Zhang Q, Lu ZH, Tan YW

ABOUT COVER

Editorial Board Member of *World Journal of Hepatology*, Nouhoum Bouare, DSc, PhD, Research Scientist, Biomedical Research, National Institute of Public Health, Bamako 1771, Mali. nbouare@insp.ml

AIMS AND SCOPE

The primary aim of *World Journal of Hepatology* (*WJH*, *World J Hepatol*) is to provide scholars and readers from various fields of hepatology with a platform to publish high-quality basic and clinical research articles and communicate their research findings online.

WJH mainly publishes articles reporting research results and findings obtained in the field of hepatology and covering a wide range of topics including chronic cholestatic liver diseases, cirrhosis and its complications, clinical alcoholic liver disease, drug induced liver disease autoimmune, fatty liver disease, genetic and pediatric liver diseases, hepatocellular carcinoma, hepatic stellate cells and fibrosis, liver immunology, liver regeneration, hepatic surgery, liver transplantation, biliary tract pathophysiology, non-invasive markers of liver fibrosis, viral hepatitis.

INDEXING/ABSTRACTING

The *WJH* is now abstracted and indexed in PubMed, PubMed Central, Emerging Sources Citation Index (Web of Science), Scopus, Reference Citation Analysis, China National Knowledge Infrastructure, China Science and Technology Journal Database, and Superstar Journals Database. The 2022 edition of Journal Citation Reports® cites the 2021 Journal Citation Indicator (JCI) for *WJH* as 0.52. The *WJH*'s CiteScore for 2021 is 3.6 and Scopus CiteScore rank 2021: Hepatology is 42/70.

RESPONSIBLE EDITORS FOR THIS ISSUE

Production Editor: Yi-Xuan Cai, Production Department Director: Xiang Li, Editorial Office Director: Xiang Li.

NAME OF JOURNAL

World Journal of Hepatology

ISSN

ISSN 1948-5182 (online)

LAUNCH DATE

October 31, 2009

FREQUENCY

Monthly

EDITORS-IN-CHIEF

Nikolaos Pylsopoulos, Ke-Qin Hu, Koo Jeong Kang

EDITORIAL BOARD MEMBERS

<https://www.wjnet.com/1948-5182/editorialboard.htm>

PUBLICATION DATE

April 27, 2023

COPYRIGHT

© 2023 Baishideng Publishing Group Inc

INSTRUCTIONS TO AUTHORS

<https://www.wjnet.com/bpg/gerinfo/204>

GUIDELINES FOR ETHICS DOCUMENTS

<https://www.wjnet.com/bpg/GerInfo/287>

GUIDELINES FOR NON-NATIVE SPEAKERS OF ENGLISH

<https://www.wjnet.com/bpg/gerinfo/240>

PUBLICATION ETHICS

<https://www.wjnet.com/bpg/GerInfo/288>

PUBLICATION MISCONDUCT

<https://www.wjnet.com/bpg/gerinfo/208>

ARTICLE PROCESSING CHARGE

<https://www.wjnet.com/bpg/gerinfo/242>

STEPS FOR SUBMITTING MANUSCRIPTS

<https://www.wjnet.com/bpg/GerInfo/239>

ONLINE SUBMISSION

<https://www.f6publishing.com>



Recent advances in recurrent hepatocellular carcinoma therapy

Yu-Xue Gao, Qi-Qi Ning, Peng-Xiang Yang, Yuan-Yue Guan, Peng-Xiang Liu, Meng-Lu Liu, Lu-Xin Qiao, Xiang-Hua Guo, Tong-Wang Yang, De-Xi Chen

Specialty type: Gastroenterology and hepatology

Provenance and peer review: Invited article; Externally peer reviewed.

Peer-review model: Single blind

Peer-review report's scientific quality classification

Grade A (Excellent): 0
Grade B (Very good): 0
Grade C (Good): C, C
Grade D (Fair): 0
Grade E (Poor): 0

P-Reviewer: Hori T, Japan; Pop TL, Romania

Received: September 19, 2022

Peer-review started: September 19, 2022

First decision: December 1, 2022

Revised: December 20, 2022

Accepted: March 24, 2023

Article in press: March 24, 2023

Published online: April 27, 2023



Yu-Xue Gao, Qi-Qi Ning, Peng-Xiang Yang, Yuan-Yue Guan, Peng-Xiang Liu, Meng-Lu Liu, Lu-Xin Qiao, Xiang-Hua Guo, Tong-Wang Yang, De-Xi Chen, Beijing Institute of Hepatology, Beijing You An Hospital, Capital Medical University, Beijing 100069, China

Yu-Xue Gao, Qi-Qi Ning, Peng-Xiang Yang, Yuan-Yue Guan, Peng-Xiang Liu, Meng-Lu Liu, Lu-Xin Qiao, Xiang-Hua Guo, De-Xi Chen, Beijing Precision Medicine and Transformation Engineering Technology Research Center of Hepatitis and Liver Cancer, Beijing 100069, China

Tong-Wang Yang, Academician Workstation, Changsha Medical University, Changsha 410219, Hunan Province, China

Tong-Wang Yang, Hunan Key Laboratory of the Research and Development of Novel Pharmaceutical Preparations, Changsha Medical University, Changsha 410219, Hunan Province, China

Corresponding author: De-Xi Chen, PhD, Professor, Beijing Institute of Hepatology, Beijing You An Hospital, Capital Medical University, No. 8 Youanmenwai, Youanmen Street, Fengtai District, Beijing 100069, China. dexichen@ccmu.edu.cn

Abstract

Hepatocellular carcinoma (HCC) is the most prevalent form of primary liver cancer, accounting for 75%-85% of cases. Although treatments are given to cure early-stage HCC, up to 50%-70% of individuals may experience a relapse of the illness in the liver after 5 years. Research on the fundamental treatment modalities for recurrent HCC is moving significantly further. The precise selection of individuals for therapy strategies with established survival advantages is crucial to ensuring better outcomes. These strategies aim to minimize substantial morbidity, support good life quality, and enhance survival for patients with recurrent HCC. For individuals with recurring HCC after curative treatment, no approved therapeutic regimen is currently available. A recent study presented novel approaches, like immunotherapy and antiviral medication, to improve the prognosis of patients with recurring HCC with the apparent lack of data to guide the clinical treatment. The data supporting several neoadjuvant and adjuvant therapies for patients with recurring HCC are outlined in this review. We also discuss the potential for future clinical and translational investigations.

Key Words: Recurrent hepatocellular carcinoma; Liver transplantation; Therapy; Immunotherapy; Neoadjuvant and adjuvant therapy

Core Tip: Hepatocellular carcinoma (HCC) is the most prevalent form of primary liver cancer, and up to 50%-70% of individuals may experience a relapse of the illness in the liver after 5 years. This review will provide novel approaches to improve the prognosis of patients with recurring HCC with the apparent lack of data to guide the clinical treatment. Neoadjuvant and/or adjuvant therapy methods potentially elevate the opportunity of cure in refractory patients with recurrent HCC and contribute to a better long-term prognosis.

Citation: Gao YX, Ning QQ, Yang PX, Guan YY, Liu PX, Liu ML, Qiao LX, Guo XH, Yang TW, Chen DX. Recent advances in recurrent hepatocellular carcinoma therapy. *World J Hepatol* 2023; 15(4): 460-476

URL: <https://www.wjgnet.com/1948-5182/full/v15/i4/460.htm>

DOI: <https://dx.doi.org/10.4254/wjh.v15.i4.460>

INTRODUCTION

With an expected 906000 new cases and over 800000 fatalities, primary liver cancer is ranked as the sixth most commonly diagnosed malignancy and the third most prevalent cause of cancer-related deaths worldwide in 2020[1]. Hepatocellular carcinoma (HCC) accounts for 75%-85% of cases of primary liver cancer[2]. As medical care has improved, liver transplantation (LT) has emerged as the best option for individuals with HCC that is either incurable or who have progressive liver damage as a result of their HCC[3]. Although patients receive treatments for early stage HCC intending to cure the disease, up to 50%-70% of patients may experience disease relapse in the liver after 5 years[4,5]. This is not only related to the inadequacy of the surgery (*i.e.*, positive surgical margin) but is also frequently associated with the development of *de novo* tumors as the disease progresses. Additionally, 70% of patients with recurrent HCC experience an early relapse within 2 years of surgery, which is nearly incurable and has been linked to a poor prognosis[6]. The molecular mechanisms underlying the prompt relapse of HCC are still unclear.

In a small percentage of HCC patients with multifocal intra or extrahepatic relapse, liver function impairment, and tumors that cannot be removed, rehepatectomy is necessary[7]. According to reports, HCC patients with tumors that meet the Milan criteria had excellent 5-year survival rates and minimal risks of relapse after LT[8]. Until the disease worsened or tolerance was established, monotherapy was thought to be the only course of therapy. At least two treatments administered simultaneously or within 4 wk of each other were considered multimodal therapy[9]. Preclinical findings suggest that neoadjuvant and adjuvant dosages should be used in combination instead of using either of them individually[10].

Therefore, it is crucial to devise the best treatment plans and fully comprehend the mechanism of HCC relapse. As a result of these problems, numerous researchers have looked into the benefits of neoadjuvant and adjuvant therapeutic approaches to lower relapse rates and enhance prognosis. Adjuvant therapy is not typically advised following curative treatment since its benefits are unclear[11]. It is clear that some additional treatment modalities are necessary, and in this regard, either neoadjuvant or adjuvant approaches are mostly taken into consideration. These include adjuvant antiviral therapy, repeated excision, transarterial chemoembolization (TACE), transarterial radioembolization, radiofrequency ablation (RFA), LT, tyrosine kinase inhibitors, and immunotherapy. Here, we will discuss the current state of knowledge on and recent advances in the therapy of recurrent HCC in this narrative review.

MECHANISM OF RECURRENT HCC

Up to 70% of early HCC recurrence cases were thought to manifest within the first two years following curative therapy; relapses that occur after this point are referred to as late HCC recurrences[12]. Malignant, immunological, and stromal cells are made up of heterogeneous cell types that interact spatiotemporally in complex tumor ecosystems[13]. Recent research has found similarities between the genetic variants of primary and early recurrent HCC[14]. Nevertheless, explanations for differences between the cellular ecosystems of primary and recurrent HCC are still being sought after. Early-relapse HCC displayed decreased regulatory T cells (Tregs) and higher dendritic cells (DCs) and CD8+ T cells compared to primary HCC, which were associated with a poor prognosis[15], as shown in Figure 1. Treg recruitment is a characteristic of the immunosuppressive milieu of primary HCC[16]. In contrast to the traditional depletion state in primary HCC, CD8+ T cells in relapsed HCC displayed higher CD161

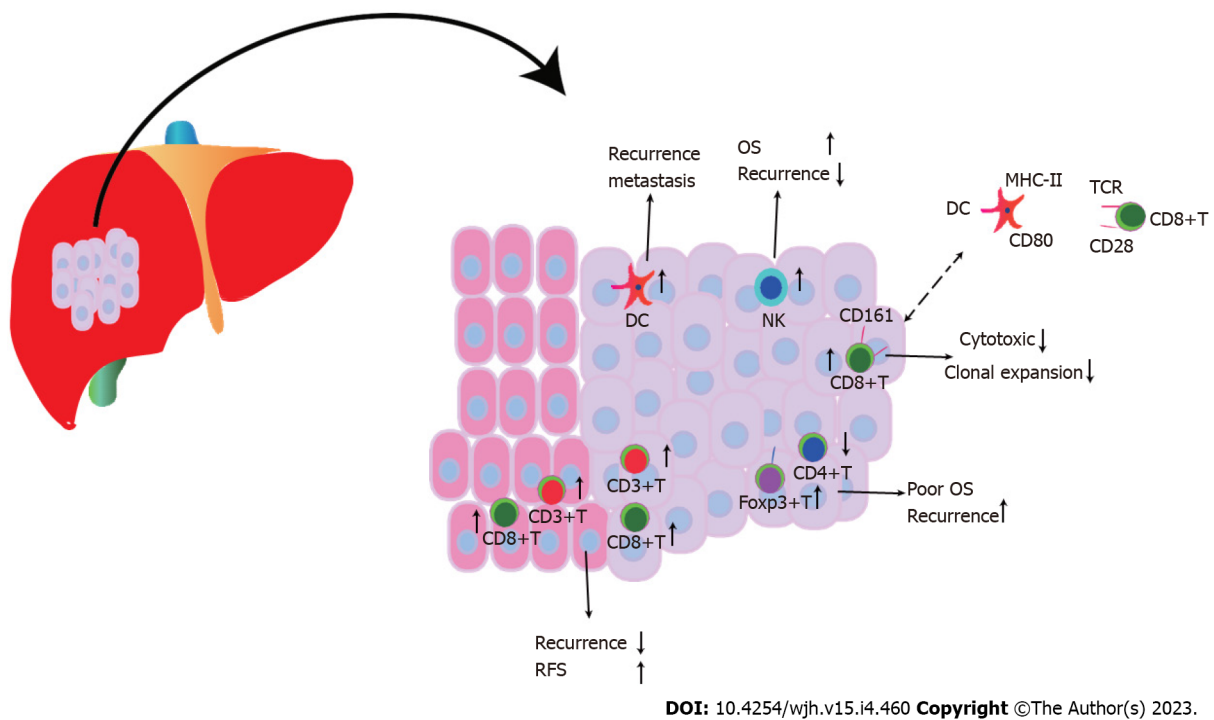


Figure 1 Mechanism of action of immune cells under investigation for recurrence of hepatocellular carcinoma. Early-relapse hepatocellular carcinoma displays decreased regulatory T cells, and higher dendritic cells and CD8+T cells. FoxP3(+) regulatory T cells encourage a gradual decline in CD4+ cytotoxic T cells, which contributes to poorer survival and high recurrence rates. OS: Overall survival; RFS: Relapse-free survival; DC: Dendritic cells; NK: Natural killer cell.

expression, a low cytotoxic state that was innate, and reduced clonal expansion. This is significant because the immune escape mechanism underlying HCC relapse was connected to the inhibition of DC antigen presentation and infiltration of innate-like CD8+ T cells[15], which caused intrahepatic dissemination of HCC. Tregs and intrahepatic Toll-like receptor 4/C-X-C motif chemokine 10/CXCR3 C-X-C motif chemokine receptor 3 levels were higher in patients with HCC recurrence following LT, which was further substantiated in a rat transplantation model[17].

According to a meta-analysis, HCC patients with high Foxp3+ T cell infiltration had worse 1-, 3-, and 5-year survival rates and a greater rate of recurrence than patients with low Foxp3+ T cell infiltration [18]. The frequency of CD8+ tumor-infiltrating lymphocytes in the intratumor and margin area was positively correlated with overall survival (OS) and disease-free survival (DFS) in two HCC cohorts (a combined total of 449), and a larger proportion of CD8+ tumor-infiltrating lymphocytes was associated with a lower recurrence rate[19]. As a result of their inflammatory condition, increased densities of CD8+T lymphocytes that infiltrate the liver in HCC patients contribute to tumor recurrence and carcinogenesis[20]. High CD3+ and CD8+ T cell densities were associated with minimal relapse and extended relapse-free survival in both the tumor center and margin[21]. In HCC patients, increased FoxP3(+) regulatory T cells encouraged a gradual decline in CD4+ cytotoxic T cells, which contributed to poorer survival and high recurrence rates[22]. A high Foxp3/CD8 ratio indicated a higher Edmondson-Steiner nuclear grade, relapse, and shorter OS and DFS, along with worse differentiation[23]. In HCC patients who received LT but not Foxp3+ T-lymphocytes, a correlation between CD4/CD8 ratio and tumor recurrence was established[24]. After surgical excision, high DC infiltration in HCC nodules can be used as a predictor of the recurrence and metastasis of the disease[25]. The response to sorafenib improved relapse-free survival, and OS in patients was significantly influenced by the increased density of natural killer (NK) cells[26].

In HCC patients after surgery, higher interleukin (IL-11) levels enhanced tumor expansion, and in genetic mouse model, suppression of IL-11-STAT3 signaling greatly reduced cell proliferation and post-surgical recurrences of HCC tumors[27]. Local recurrence is caused by the invasion of local tumor blood flow and peritumoral diffusion, whereas systemic dissemination is caused by the “rehomeing” of circulating tumor cells that have spread from the initial nodules[28]. HCC recurrence can occur as a result of tumor cells that are circulating or at rest, evading the host’s immune responses. The total somatic mutations and copy number depletion of WNK2 (WNK lysine deficient protein kinase 2) were associated with low levels of WNK2 protein expression, premature tumor relapse, and poor cumulative survival in patients with HCC following curative excision, indicating a tumor-suppressor role of WNK2 [29]. WNK2 inactivation results in the recruitment of tumor-associated macrophages, ERK1/2 signaling activation, tumor growth, and metastasis.

Following therapy, HCC shows pathological modifications; therapy induced pathological variation, particularly sarcomatous transformation, results in random and frequent recurrences after RFA[30]. It is generally accepted that recurrent HCC following curative therapy was caused by both initial incomplete treatment as well as current technological and biomarker limitations that make it difficult to detect preexisting microscopic tumors[31]. Occasionally, local therapies like TACE result in the direct diffusion of tumor cells from the RFA needle, which eventually causes a relapse of HCC[32]. However, multicentric origin HCC developed from *de novo* carcinogenic effect following curative excision, and the latter has a better OS than the former[33], consistent with the results of Kuo *et al*[34]. The incidence of intrahepatic metastasis and multicentric recurrent HCC was 59.4% and 27.5%, respectively, which were accompanied by loss of heterozygosity (63.8%) and microsatellite instability (30.0%) between primary and recurrent tumors[34]. Concerning previously unidentified circulating tumor cells or preexisting metastasis caused by the current technology that contribute to extrahepatic relapse, metastatic tumor lesions in the graft are originally formed from circulating cells or extrahepatic locales, providing a greater potential for biological advancement[35].

ADJUVANT ANTIVIRAL TREATMENT

Adjuvant antiviral therapy has been shown to decrease multicentric HCC recurrence, which in turn reduces post-treatment recurrence[33]. However, the ideal time for starting therapy with direct-acting antivirals (DAAs) for hepatitis C virus (HCV)-related HCC patients following surgical resection, and the impact of DAA on HCC recurrence remain unclear. Low risk of HCC recurrence after DAA treatment was suggested in some studies, while others have reported contrasting outcomes. Furthermore, there is conflicting evidence concerning HCV-related HCC recurrence in previously cured patients following virus elimination with DAAs. With a 5.7-mo follow-up in 20 DAA-treated HCV patients, a high rate of early HCV-related HCC recurrence was observed[36]. Even though DAA treatment was not associated with HCC or early HCC recurrence, a higher proportion of DAA-treated patients accepted potential curative therapy for recurrent HCV-related HCC compared to untreated patients (32.0% *vs* 24.6%) and developed a non-significant complete or partial response (45.3% *vs* 41.0%)[37]. A systematic review has highlighted an association of HCC recurrence with the status of previous HCC recurrences and the shorter interval between HCV-related HCC complete response and initiation of DAA treatment, and similar recurrences in patients treated with DAAs, those treated with interferon, or untreated patients [38]. HCV-related HCC patients, who had a shorter interval between HCC treatment and DAA therapy (less than 4 mo), appeared to be at greater risk, with a relapse rate of 41.2%[39]. DAA treatment following curative HCC therapy was not associated with early or advanced cancer recurrence[40]. DAA treatment is not associated with a high risk of recurrence in LT patients with HCV and HCC who achieved an original complete response to local-regional therapy, but rather involves a low risk of waitlist dropout due to cancer aggression or death[41]. In three separate prospective cohorts, no increased risk of HCC recurrence following DAA therapy was found, particularly in patients who received curative treatment, such as LT[42].

Even though the impact of DAAs on HCV-related HCC recurrence remains debatable, the results of anti-hepatitis B virus (HBV) treatment following HCC therapy showed that NAs might potentially inhibit HCC recurrence after curative hepatectomy in patients with HBV-related HCC[43]. Managing viral conditions and reactivation of viral replication plays a major role in suppressing HCC recurrence, maintaining liver function, and improving survival for HBV-related HCC post-therapy[44]. After curative therapy, NAs significantly improved recurrence-free survival and OS in HBV-related HCC patients, and entecavir was on par with other NAs, including lamivudine and adefovir, in this regard [45]. Another study discovered that after curative therapy, antiviral therapy with NA could increase survival and reduce early recurrence in patients with HBV-related HCC[46]. NA with or without anti-HBs immunoglobulins was significantly effective in inhibiting post-LT HBV recurrence[47]. In a limited sample cohort, NA did not lower the short-term recurrence rate but increased the elimination of postoperative serum HBV and remnant liver volume, which resulted in significantly improved tolerance to follow-up treatment for HCC recurrence[48]. In a large cohort of 4569 patients with HBV-related HCC who underwent curative resection, the anti-HBV therapy cohort had a significantly lower 6-year HCC recurrence rate than the control cohort [anti-HBV therapy, 45.6%; 95% confidence interval (CI): 36.5%-54.6% *vs* control, 54.6%; 95% CI: 52.5%-56.6%][49]. According to a previous study, recipients who accepted LT by removing HBV-infected initial liver at undetected serum HBV DNA levels continue to have an elevated risk for posttransplant recurrent HBV due to the absence of any particular treatment [50]. In comparison to lamivudine for HCC after curative therapy, entecavir is associated with a four-fold higher one-year OS rate and lower HCC recurrence, suggesting that entecavir may be more suitable for HBV-related HCC patients[51].

REPEAT RESECTION

Only a small proportion of patients with recurrent HCC are candidates for repeat hepatectomy due to recurrent multifocal tumors and compromised liver function[52]. Twenty-two patients with recurrent HCC following LT (2 intrahepatic HCC patients and 20 extrahepatic HCC patients) received complete hepatectomy and had a longer median survival of 35 mo than unresected patients with a median survival of 15 mo[53], suggesting a less aggressive tumor biology. According to a retrospective cohort study, 15 patients with HCC recurrence who underwent LT had a better 5-year OS rate and 5-year DFS rate than the patients with RFA treatment (35% *vs* 28%, and 16% *vs* 0%, respectively)[54]. A recent study reported that repeat laparoscopic liver resection (LR) for recurrent HCC is both feasible and suitable with promising short-term results[55]. Laparoscopic repeat LR was associated with shorter hospitalization and prolonged operation time compared to open repeat LR for recurrent HCC but they had similar perioperative results for primary HCC except for a longer operation time[56]. Patients who underwent wedge resection during laparoscopic repeat LR showed a significantly lower postoperative complication rate than open repeat LR (7.2% *vs* 21.8%)[57]. Even though patients with open LR have a higher morbidity rate than those who underwent LR for primary HCC, there are no striking differences in the clinical characteristics of repeat laparoscopic LR based on prior resection method (open or laparoscopic) or tumor location (segments 7 and 8 or other)[55].

A meta-analysis of 767 patients, 334 of who had repeat laparoscopic hepatectomy and 433 of whom had repeat open hepatectomy, discovered that repeat laparoscopic hepatectomy resulted in less intraoperative blood loss, fewer major complications, shortened hospitalization, and a higher rate of R0 resection[58]. The repeat-surgery group had better liver function, long recurrence-free survival (16.5 mo *vs* 11.4 mo), and better 5-year survival after recurrence (repeat surgery group *vs* non-surgery group: overall, 53.0% *vs* 25.7%; intrahepatic recurrence, 73.8% *vs* 37.2%; extrahepatic recurrence, 30.0% *vs* 0%; intrahepatic and extrahepatic recurrence, 34.1% *vs* 10.6%) compared to the non-surgery group[59] for recurrent HCC. Patients with recurrences within 6 mo of resection had poor survival outcomes than those who experienced recurrences later, and patients with intrahepatic-only recurrences had a better prognosis than those with either extrahepatic-only or intra and extrahepatic recurrences[60]. Additionally, repeated resection of recurrences with a remediable objective produced better outcomes than other therapy options[60]. After 18 mo of initial hepatectomy, repeat hepatectomy may be suggested as a treatment for recurrent HCC. When compared to patients with intrahepatic metastasis, repeat hepatectomy improves survival rates in HCC patients with multicentric occurrence[61]. Although RFA is associated with lower grade 3 morbidity and shorter hospital stay, repeated hepatic resection resulted in a longer median recurrence-free survival *vs* RFA (23.6 mo *vs* 15.2 mo) in patients with recurrent HCC[62]. Resection can be advised as a treatment option for patients with extrahepatic recurrent HCC in conjunction with local treatment for intrahepatic recurrent HCC due to the superior outcomes[63]. At the third (71.3% *vs* 65.7%), fifth (59.9% *vs* 45.4%), and tenth (35.4% *vs* 32.2%) year follow-up, repeat hepatectomy improved long-term OS more than RFA and showed a late survival advantage for patients with recurrent HCC despite a higher morbidity rate[64].

LT

According to reports, the results of salvage LT (SLT) for recurrent HCC following hepatectomy are comparable to the outcomes of initial transplantation, even when examined on an intention-to-treat basis[65]. LT seems to be the most effective treatment for HCC patients to remove both tumors and underlying liver diseases, but the scarcity of organ donors available globally and stringent criteria for patients who are not eligible for transplantation are the major challenges. However, recurrent HCC patients following LT have a poorer prognosis, with a median OS of 10-13 mo as opposed to 2-3 years for patients who had hepatectomy[66-68]. In 2000, Majno *et al*[69] made the first suggestion for SLT, which was used in patients with recurrent HCC or liver dysfunction following primary hepatectomy as initial treatment. Fortunately, liver transplants were an option for 80% of patients with recurrent HCC following curative hepatectomy[70]. A case of salvage living donor LT in a patient with tumor recurrence following surgical resection of combined HCC and cholangiocarcinoma has multiple tumor recurrences after 21 mo due to the more aggressive tumor biology of this type of cancer[71]. The patients receiving SLT demonstrated better DFS than those receiving re-resection or RFA, which is a beneficial strategy for intrahepatic recurrent HCC, particularly for patients with multicentric occurrence that is related to better long-term outcomes than the intrahepatic metastasis pattern[72].

SLT ($n = 16$) revealed poorer short-term perioperative results than repeat LR ($n = 16$), with a higher incidence of morbidity (57.8% *vs* 5.4%), reoperations (39.1% *vs* 0%), renal dysfunction (30.1% *vs* 3%), bleeding (19.8% *vs* 2.2%), prolonged intensive care unit stay (4 d *vs* 0 d), and hospitalization (19.8 d *vs* 7.1 d) but significantly decreased recurrence (15.4% *vs* 70.3%) and 5-year cumulative incidence of recurrences (19.4% *vs* 68.4%) to improve long-term survival outcomes for recurrent HCC[73]. SLT was found in a meta-analysis to have higher blood loss, longer hospital stays and surgeries, increased DFS, and elevated risk of postoperative morbidity than repeat LR, while there was no clear difference in

postoperative mortality or OS[74] for recurrent HCC. In terms of disease-specific and recurrence-free survival of patients with intrahepatic HCC recurrence, SLT with transplantable patients is superior to repeat resection, even in patients with Child-Pugh class A liver cirrhosis[75]. Only 56% of cases can be cured using the SLT strategy. A successful SLT strategy is predicted by higher end-stage liver disease scores at the start of the strategy and the absence of pre-resection TACE[76]. Even though SLT is associated with a higher rate of surgical complications, SLT for recurrent HCC following primary hepatic resection is still an efficient and safe treatment that increases survival and reduces tumor recurrence compared to patients with HCC exceeding the Milan criteria who accepted primary orthotopic LT[77]. After hepatectomy, HCC patients with larger tumor sizes were more likely to experience relapse, even with SLT. As a result, LT should be recommended as soon as possible, ideally within a year, for patients with recurrent HCC after LR, followed by meeting the requirements for transplantation[78]. For patients with recurrent HCC after hepatectomy, SLT has a poorer OS and RFS, as well as a higher risk of recurrence and death compared to primary LT, particularly for those who meet the Milan criteria[79]. Another study discovered no difference between patients receiving primary LT and SLT for HCC recurrence following primary treatment with LR or RFA in terms of the 5-year risk of recurrence and 5-year actuarial survival[80]. SLT for relapsed HCC patients after initial LR followed by SLT showed overall and recurrence-free survival rates on par with primary LT. Despite this, there are higher rates of Child-Pugh class A, more than three transplant treatments, and reoperation for postsurgical bleeding[81]. Patient background possibly has various effects on therapy, as Hong Kong patients with recurrent HCC following LR who received SLT, but not Roman patients, showed an increased recurrence rate[82].

RFA

Clinical therapy for HCC frequently involves ablation. Following ablation, the tumor experiences residual and local recurrence due to asymmetrical heat diffusion and heat absorption *via* circulating blood or air around the tumor[83]. For HCC patients who experience recurrence but cannot undergo a suitable operation, ablation is used as a safe and efficient therapy[84]. With ablation alone, the 5-year recurrence rate of HCC patients was 70%[85]. Although a small set of 11 patients with relapsing HCC following LT embraced microwave ablation without serious side effects, this safe technique still needs to be validated in larger studies or compared with other treatment options[86]. RFA and repeat resection are better choices for late-relapsing HCC patients post-curative hepatectomy who meet the Milan criteria[87]. Although the 1-, 3-, and 5-year OS (90.7%, 69.04%, and 55.6% *vs* 87.7%, 62.9%, and 38.1%, respectively) and progression-free survival (PFS) (56.5%, 27.9%, and 14.6% *vs* 50.2%, 21.9%, and 19.2%, respectively) were comparable between the RFA and repeat resection groups for locally recurrent HCC following primary resection, the former was superior to the latter in term of complications and hospitalization[88]. In a different study, repeat resection was found to increase survival for recurrent HCC, particularly for patients who had relapsed within two years and whose primary tumor burden exceeded the Milan criteria[89]. Primary HCC (94.8%, 75.7%, 61.6%, and 47.3%, respectively) and recurrent HCC (91.9%, 71.2%, 58.7%, and 45.2%, respectively) did not differ in the 1-, 3-, 5-, or 10-year OS rate[90]. RFA offers comparable long-term survival whether treatment is for the first-time or recurrent HCC that is 5 cm or less. Although LR with long-term survival results is superior to RFA for recurrent HCC patients, RFA is a good alternative to LR in patients with small-sized recurrence or patients with a limited number of recurrent nodules, even though LR has better long-term survival outcomes for patients with recurrent HCC[91]. Multiprobe stereotactic RFA as first-line therapy for recurrent HCC following LR has such low morbidity that the OS and DFS rates at 1, 3, and 5 years were 94.0%, 70.2%, and 53.3%, and 52.6%, 19.7%, and 15.8%, respectively[92]. RFA is beneficial and effective for intrahepatic recurrent HCC with 1-, 3-, and 5-year OS rates of 68.5%, 40.3%, and 40.3%, respectively, particularly for recurrent HCC following LT in the absence of finite extrahepatic metastases[93]. Due to its advantages of being less invasive, extreme selectivity, and reproducibility, RFA is suggested as a better therapy for intrahepatic HCC recurrence given that it is associated with a lower recurrence-free survival than LT[94].

In patients with recurrent HCC (tumor size < 3 cm, tumor number ≤ 2), a phase III non-inferiority trial found that the 2-, 3-, and 4-year local PFS of proton beam radiotherapy was comparable to that for RFA. However, the most common adverse outcomes were radiation pneumonitis (32.5%) and decreased leukocyte counts (23.8%) for proton beam radiotherapy, and increased alanine aminotransferase levels (96.4%) and abdominal pain (30.4%) for RFA[95], which suggested that proton beam radiotherapy was tolerable and safe with long PFS values comparable to those of RFA.

TACE

TACE is generally considered a standard therapeutic method for patients with unresectable HCC[11]. The most widely used treatment for postoperative recurrence is TACE, especially when there is a large mass or multifocal relapsed HCC[96]. The outcomes of TACE in the neoadjuvant setting are debatable.

OS showed no difference between 71 patients treated with TACE before surgery and 21 patients who underwent surgery without TACE[97]. In a retrospective study, 1457 patients were evaluated, of whom 120 were treated with preoperative TACE, and it was found that 5-year DFS was improved in patients treated with TACE[98]. Patients with primary HCC who undergo embolization have a strikingly higher chance of survival than those with recurrent HCC. A study revealed that primary HCC patients who received TACE had a median survival of 30 mo and a 29% 3-year survival rate[99]. The results of treating patients with recurrent HCC, however, showed a low median survival time of 19 mo and an 11% survival rate. Patients with primary HCC and microvascular invasion (MVI) experience recurrence after resection, and TACE treatment is more effective than resection and RFA for recurrent HCC[100]. There was no significant difference in prognostic factors or OS between the initial and recurrent TACE groups[101]. TACE was administered to 28 patients with recurrent HCC following LT; 19 of these patients (67.9%) experienced tumor-shrinking by over 25%. However, the 1-, 3-, and 5-year survival rates were lower (47.9%, 6.0%, and 0%, respectively) due to extrahepatic metastases or intrahepatic recurrences[102]. According to a different study, patients who underwent chemoembolization without experiencing any serious side effects had a significantly longer OS time following the diagnosis of HCC recurrence post-LT than those who did not receive the treatment[103]. The 1-, 3-, and 5-year OS rates did not significantly differ between the repeat resection or RFA and the TACE groups, suggesting that TACE likely was as effective as repeat resection or RFA for preventing early intrahepatic relapse following curative resection of HCC[87]. Although there is no obvious difference between RFA and TACE treatment for isolated intrahepatic recurrent HCC following LT in terms of 2-year DFS rate (20% *vs* 14%) and 4-year OS rate (33% *vs* 25%), TACE treatment seems to be more beneficial in isolated intrahepatic recurrent HCC patients following LT when RFA therapy is not suitable[104]. In contrast to TACE-alone treatment for intrahepatic recurrent HCC after hepatectomy, apatinib, a vascular endothelial growth factor receptor 2 inhibitor, in conjunction with TACE significantly improved the median PFS, short-term objective responses, and disease control rate, and had a tendency of increasing the 1- and 2-year OS rates[105]. The patients who received TACE-RFA for recurrent HCC that was less than 5 cm following LT had a higher DFS than those who received TACE alone[106]. After a follow-up of 24 mo, the median OS for patients with the first recurrence of HCC treated with multimodality therapy was 40 mo (range 8-85 mo), far exceeding that of patients with LR/ablation (27 mo, range 4-75 mo), TACE/XRT (13 mo, range 4-68 mo), and systemic treatments (26 mo, range 3-59 mo)[9].

SORAFENIB

Sorafenib, a multitarget tyrosine kinase inhibitor (TKI) and the first approved drug for HCC patients, is most frequently used as an adjuvant therapy in resected HCC patients[107] and as a frontline systemic treatment in patients with HCC recurrence after LT. However, the current data are mainly based on observational research due to the exclusion of Randomized Protocol studies and Asia-Pacific trials of sorafenib from the registered studies for HCC[107,108]. Sorafenib has a few drawbacks, including poor oral bioavailability and drug toxicities, and its OS is only marginally improved by 2.8 mo[107,109]. The impacts of sorafenib in patients with recurrent HCC who underwent an incurable liver transplant have been estimated in several retrospective studies. Based on a retrospective cohort study of 50 patients with recurrent HCC following liver transplants who initially accepted sorafenib, an objective response rate of 16% and stable disease in 50% of this population were observed, and the median OS was 18 mo[110]. Patients with HCC recurrence following LT treated with sorafenib had a better median survival of 42 mo compared to 16.2 mo for patients not receiving sorafenib, supporting the notion that sorafenib increases survival[111].

According to this study, patients with relapsed HCC have a better chance of longer OS and a better prognosis by receiving the sorafenib treatment. For patients with recurrent HCC, sorafenib-lenvatinib continuous treatment and radical resection together with nonoperative therapy were both independent favorable factors for post-recurrence survival[112]. According to Lee *et al*[113], sorafenib for recurrent HCC is associated with a better prognosis because it involves smaller intrahepatic HCC combined with favorable liver function in LT recipients, which may explain why the median OS (16.8 mo *vs* 7.1 mo) and time to development were higher in 42 HCC patients in the LT group than in 790 non-LT patients. Sequential sorafenib treatments are similarly common in recurrent HCC patients following LT. These treatments improve OS compared to non-LT treatments and do not suppress systemic treatments with concurrent antirejection strategy[35]. Treatment with sorafenib and TACE was associated with a higher 5-year OS and PFS compared to those treated with TACE alone in patients with recurrent intermediate-stage HCC and lesions positive for MVI, but patients with MVI-negative lesions did not show a survival benefit from combined therapy[114]. Treatment with sorafenib plus TACE improves hepatic reserve, leads to a better OS, and results in longer intervals between TACE rounds in TACE-refractory patients with recurrent advanced HCC than repeated TACE treatments[115]. The RFA plus sorafenib treatment resulted in a significantly improved OS than RFA alone (1-, 3-, and 5-year OS rates of RFA-sorafenib *vs* RFA: 97.7%, 83.7%, and 54.7% *vs* 93.1%, 61.3%, and 30.9%, respectively), suggesting that adjuvant sorafenib combined with RFA was superior to RFA alone in improving survival results in patients with

recurrent HCC who meet the Milan criteria after initial LT[116]. Prussian blue (PB) nanomaterial is safe and has multiple roles as an antidote to thallium poisoning[83]. With minimal injury to surrounding healthy tissues, photothermal therapy is a highly effective and noninvasive therapeutic option[117]. By using human and mouse HCC cell lines, Zhou *et al*[118] developed HCC-targeted SP94 peptide and cyanine (Cy) 5.5-conjugated PB nanoparticles loaded with sorafenib for HCC-targeted multimodality imaging and combined photothermal therapy/sorafenib treatment. These nanoparticles accumulated in HCC tumor sites and then controlled the release of sorafenib to eradicate the tumor without any local recurrence and with a minimal amount of toxic side effects.

OTHER TKIS

The United States and Europe approved lenvatinib in the first line, cabozantinib, and ramucirumab in the second line as a potential systemic therapeutic approach for liver transplant recipients with relapsed HCC. A retrospective multicenter study discovered that regorafenib, a multitarget TKI, was safe and effective for patients with recurrent HCC following LT who were tolerable to sorafenib, with a median OS of 12.9 mo[119]. Lenvatinib, as a TKI, has been used as an optional frontline treatment strategy. Patients with recurrent HCC treated with lenvatinib who are tolerable to sorafenib have a longer median OS (19.5 mo), far exceeding those who are receiving intermittent sorafenib or regorafenib following sorafenib failure (12 mo)[112]. Cabozantinib, a TKI of vascular endothelial growth factor receptor 2 (VEGFR2), is used as an effective and safe monotherapy to proceed with third-line systemic therapies in advanced HCC[120]. Patients with recurrent HCC who received lenvatinib treatment had decreased expression of programmed death ligand 1 (PD-L1) and Treg infiltration in the tumor compared to the matched primary tumor, suggesting that lenvatinib targets fibroblast growth factor receptor 4 to increase the antitumor immune response of anti-programmed cell death-1 (PD-1) treatment, which is accompanied by decreased expression of tumor PD-L1 and Treg infiltration[121]. As a multi-kinase inhibitor, cabozantinib is expected to be an effective treatment for advanced HCC patients with sorafenib tolerance[122]. A case study identified a patient with recurrent HCC who had more than 10 years of survival after receiving an intensive multimodal therapeutic strategy that included surgery, RFA, and systemic therapy with cabozantinib as the second-line therapy in living-donor LT[123]. In patients with HCC recurrence following LT with sorafenib tolerance, regorafenib treatment resulted in a longer median OS (28.8 mo) than best supportive care (15.3 mo). This makes regorafenib a safe and effective second-line treatment option[124].

IMMUNE CHECKPOINT INHIBITORS

Although the importance of immune evasion in the progression of HCC recurrence was widely acknowledged, the lack of effective medications to reverse cancer-related immune suppression remained an untreatable condition until recently. Programmed cell death receptors on T cells and their ligands PDL-1 and PDL-2 on tumor cells are the targets of immune checkpoint inhibitors (ICPIs). Only 15–20% of patients benefit from anti-PD-L1 monoclonal antibodies (mAbs), which block interactions with PD-1 and PD-L1 and restore the roles of T cells in the tumor microenvironment[125,126]. Stimulation-induced immune surveillance has notable antitumoral outcomes in advanced and recurrent HCC, with significant response rates and even complete responses. Despite their promising prospects, ICPIs must be used with caution in transplant patients due to the complexity of HCC. In particular, HCC patients with multifocal tumors, higher AFP levels, larger tumor volume, and poorer differentiation presented a high risk of post-LT relapse when given neoadjuvant ICPIs[127]. The perioperative nivolumab *vs* ipilimumab/nivolumab combination had fine effects, according to a phase II study, with a 29% complete response rate[128]. The immune checkpoint blockade remedy resulted in only 16%–20% response rates among patients with advanced HCC[129]. Combination therapy with anti-PD-1 plus RFA for recurrent HCC achieved a superior recurrence-free survival compared to RFA monotherapy[130]. By combining anti-PD-L1 mAb with SP94-PB-sorafenib-Cy5.5 nanoparticles plus near-infrared therapy, Zhou *et al*[118] also observed the production of extraordinary results, such as suppression of distant metastases and obstruction of cancer relapse. Note that, different from primary HCC, the therapeutic strategy for recurrent HCC following LT has to be discrete due to the higher risk of allograft rejection or graft loss[131,132]. For early HCC recurrence after radical resection, TKIs combined with PD-1 therapy demonstrated a better survival benefit than TKIs alone[133]. In a patient with recurrent, refractory, metastatic HCC following LT, PD-1 inhibitor eliminated lung metastases and resulted in a partial radiological response of metastatic retroperitoneal lymph nodes after 13 cycles[134].

HBV-SPECIFIC T-CELL IMMUNOTHERAPY

Chimeric or classical T-cell receptors (TCRs)-redirected T cells target HBV antigens/epitopes expressed on HBV-infected hepatocytes or in HCC cells as an immunotherapeutic approach. According to a case study, the HBV antigen was expressed in the metastases of a patient with HBV-related HCC after LT [135]. To treat extrahepatic metastases of chemotherapy resistance, HCC autologous T cells were genetically redirected to express an HBsAg-specific T cell receptor. This resulted in decreased HBsAg levels without worsening liver inflammation or other toxicity [135]. In two patients with metastatic recurrence of HBV-related HCC after LT, immunotherapy of HBV-specific TCRs was safe and did not cause any damage to liver function over a year [136]. Notably, a patient appeared to have a reduced volume in 5 of 6 pulmonary metastases during the first year of T-cell management [136]. HBV-specific TCR T-cells transiently escape the immunosuppressive effects of tacrolimus and mycophenolate mofetil owing to the activation of CD39+ Ki67+ peripheral blood mononuclear cells, which are positively correlated to clinical outcomes in patients with HBV-related HCC relapses following LT [137].

OTHER IMMUNOTHERAPIES

Cytokine-induced killing (CIK) cell-based immunotherapy has gained popularity as a promising new adjuvant therapy approach. CIK cells are a mixture of T lymphocytes, which are *ex vivo* amplified with cytokines and comprised of CD3+/CD56+ and CD3+/CD56- T cells, as well as CD3-/CD56+ NK cells, which have potent antitumor activity with the combined ability of both T cells and NK cells and minimal cytotoxicity to normal cells, but tremendous specificity to cancer cells [138]. Multiple clinical trials revealed that CIK cell-based immunotherapy increased RFS in HCC patients who underwent surgical resection [139,140]. The production of an individual autologous CIK cell-based immunotherapeutic agent involves activating peripheral blood mononuclear cells from the relevant patients with IL-2 and anti-CD3 antibodies [141]. According to research by Lee *et al* [141], the average RFS for HCC patients who accepted the CIK cell-based agent after curative therapy was 44.0 mo, as opposed to 30.0 mo for those who did not receive adjuvant immunotherapy. The results of a meta-analysis reported that the results of DC-based immunotherapy increased antitumor immunity, enhanced survival rate, and improved survival times in HCC patients [142]. Another meta-analysis listed 22 distinct studies with 3756 HCC patients that received DC-based vaccine and/or CIK-based adoptive therapy after receiving different HCC interventional therapies. These studies showed a prolonged OS (6 mo, 1, 3, and 5 years) and reduced mortality and recurrence at 1, 2, and 3 years but not 5 years [143]. For HCC patients, a personalized neoantigen vaccine served as a safe, practical, and effective anti-recurrence treatment [144]. After a radical operation on seven postoperative HCC patients who had received all of the planned neoantigen vaccinations, five of them showed neoantigen-activated cell responses and longer RFS than the other five patients, who had only received primary vaccination and had propensity scores that matched with those of control patients [144]. After curative resection or RFA in the first stage, the personalized neoantigen-loaded DC vaccine and neoantigen-activated T-cell therapy were successfully used on ten patients with HCC without unexpected delay or grade 3 therapy-related side effects [145]. New circulating multiclonal neoantigen-specific T-cell responses, activated neoantigen-specific immunity, an upregulated immune stimulatory signature, increased immune-cell infiltration, and elevated T-cell inflammatory gene expression, were produced in 70% of patients who had improved DFS compared to non-responders, and 71.4% of patients were without relapse for 2 years after curative treatment. Neoantigen depletion (immunoediting) also increased in recurrent tumors compared to primary tumors, suggesting that immune evasion developed as a result of immunological therapy [145].

CONCLUSION

With its unique characteristics, recurrent HCC is still a difficult disease to treat. Every stage of the disease calls for a multidisciplinary approach, which is still predominantly evolving. LT and hepatectomy remain successful therapeutic strategies for patients with recurrent HCC. Additionally, neoadjuvant and/or adjuvant therapy techniques may improve the long-term prognosis and increase the chance of cure in refractory patients with recurrent HCC. Relying on the tumor biology and possible hepatic reserve, multimodality therapy should be used in patients with recurrent HCC. By simultaneously optimizing oncologic outcomes and minimal side effects, this therapy helps these patients have better OS and tolerability.

FOOTNOTES

Author contributions: Gao YX and Ning QQ contributed equally to this work; Yang PX, Guan YY, Liu PX, Liu ML

Qiao LX, and Guo XH searched the references and polished the manuscript; Yang TW and Chen DX designed the review; all authors have read and approved the final manuscript.

Supported by National Natural Science Foundation of China, No. 82073676; Chinesisch-Deutsches Forschungsprojekt in Sonderprogramm zu COVID-19, No. C-0012; Key Programs of Beijing Municipal Education Commission of China, No. KZ202010025037; Third Round of Public Welfare Development and Reform Pilot Projects of Beijing Municipal Medical Research Institutes, No. Jing 2019-6; and Fourth Round of Public Welfare Development and Reform Pilot Projects of Beijing Municipal Medical Research Institutes, No. Jing 2021-10.

Conflict-of-interest statement: All the authors report no relevant conflicts of interest for this article.

Open-Access: This article is an open-access article that was selected by an in-house editor and fully peer-reviewed by external reviewers. It is distributed in accordance with the Creative Commons Attribution NonCommercial (CC BY-NC 4.0) license, which permits others to distribute, remix, adapt, build upon this work non-commercially, and license their derivative works on different terms, provided the original work is properly cited and the use is non-commercial. See: <https://creativecommons.org/licenses/by-nc/4.0/>

Country/Territory of origin: China

ORCID number: Qi-Qi Ning 0000-0001-6198-2595; Peng-Xiang Yang 0000-0001-8500-7866; Tong-Wang Yang 0000-0002-6030-8416; De-Xi Chen 0000-0002-6833-6462.

S-Editor: Gao CC

L-Editor: Wang TQ

P-Editor: Gao CC

REFERENCES

- 1 **Sung H**, Ferlay J, Siegel RL, Laversanne M, Soerjomataram I, Jemal A, Bray F. Global Cancer Statistics 2020: GLOBOCAN Estimates of Incidence and Mortality Worldwide for 36 Cancers in 185 Countries. *CA Cancer J Clin* 2021; **71**: 209-249 [PMID: 33538338 DOI: 10.3322/caac.21660]
- 2 **Gao YX**, Yang TW, Yin JM, Yang PX, Kou BX, Chai MY, Liu XN, Chen DX. Progress and prospects of biomarkers in primary liver cancer (Review). *Int J Oncol* 2020; **57**: 54-66 [PMID: 32236573 DOI: 10.3892/ijo.2020.5035]
- 3 **Heimbach JK**, Kulik LM, Finn RS, Sirlin CB, Abecassis MM, Roberts LR, Zhu AX, Murad MH, Marrero JA. AASLD guidelines for the treatment of hepatocellular carcinoma. *Hepatology* 2018; **67**: 358-380 [PMID: 28130846 DOI: 10.1002/hep.29086]
- 4 **Yi Y**, Sun BY, Weng JL, Zhou C, Zhou CH, Cai MH, Zhang JY, Gao H, Sun J, Zhou J, Fan J, Ren N, Qiu SJ. Lenvatinib plus anti-PD-1 therapy represents a feasible conversion resection strategy for patients with initially unresectable hepatocellular carcinoma: A retrospective study. *Front Oncol* 2022; **12**: 1046584 [PMID: 36505772 DOI: 10.3389/fonc.2022.1046584]
- 5 **European Association for the Study of the Liver**. EASL Clinical Practice Guidelines: Management of hepatocellular carcinoma. *J Hepatol* 2018; **69**: 182-236 [PMID: 29628281 DOI: 10.1016/j.jhep.2018.03.019]
- 6 **Zheng J**, Kuk D, Gönen M, Balachandran VP, Kingham TP, Allen PJ, D'Angelica MI, Jarnagin WR, DeMatteo RP. Actual 10-Year Survivors After Resection of Hepatocellular Carcinoma. *Ann Surg Oncol* 2017; **24**: 1358-1366 [PMID: 27921192 DOI: 10.1245/s10434-016-5713-2]
- 7 **Song H**, Ding H, Zhu C. CT-Guided Percutaneous Microwave Ablation of Sclerosing Hepatic Carcinoma. *Can J Gastroenterol Hepatol* 2020; **2020**: 8881978 [PMID: 32733821 DOI: 10.1155/2020/8881978]
- 8 **Tabrizian P**, Holzner ML, Mehta N, Halazun K, Agopian VG, Yao F, Busuttil RW, Roberts J, Emond JC, Samstein B, Brown RS Jr, Najjar M, Chapman WC, Doyle MM, Florman SS, Schwartz ME, Llovet JM. Ten-Year Outcomes of Liver Transplant and Downstaging for Hepatocellular Carcinoma. *JAMA Surg* 2022; **157**: 779-788 [PMID: 35857294 DOI: 10.1001/jamasurg.2022.2800]
- 9 **Tampaki M**, Papatheodoridis GV, Cholongitas E. Intrahepatic recurrence of hepatocellular carcinoma after resection: an update. *Clin J Gastroenterol* 2021; **14**: 699-713 [PMID: 33774785 DOI: 10.1007/s12328-021-01394-7]
- 10 **Sanmamed MF**, Berraondo P, Rodriguez-Ruiz ME, Melero I. Charting roadmaps towards novel and safe synergistic immunotherapy combinations. *Nat Cancer* 2022; **3**: 665-680 [PMID: 35764745 DOI: 10.1038/s43018-022-00401-1]
- 11 **Fronza M**, Mistretta F, Calandri M, Ciferri F, Nardelli F, Bergamasco L, Fonio P, Doriguzzi Breatta A. The Role of Immediate Post-Procedural Cone-Beam Computed Tomography (CBCT) in Predicting the Early Radiologic Response of Hepatocellular Carcinoma (HCC) Nodules to Drug-Eluting Bead Transarterial Chemoembolization (DEB-TACE). *J Clin Med* 2022; **11** [PMID: 36498664 DOI: 10.3390/jcm11237089]
- 12 **Li Z**, Tan C, Liu X, Feng Z, Li K. Early and late recurrence after hepatectomy in patients with low-level HBV-DNA hepatocellular carcinoma under antiviral therapy. *Infect Agent Cancer* 2022; **17**: 56 [PMID: 36397089 DOI: 10.1186/s13027-022-00468-6]
- 13 **Wagner J**, Rapsomaniki MA, Chevrier S, Anzeneder T, Langwieder C, Dykgers A, Rees M, Ramaswamy A, Muenst S, Soysal SD, Jacobs A, Windhager J, Silina K, van den Broek M, Dedes KJ, Rodríguez Martínez M, Weber WP, Bodenmiller B. A Single-Cell Atlas of the Tumor and Immune Ecosystem of Human Breast Cancer. *Cell* 2019; **177**: 1330-1345.e18 [PMID: 30982598 DOI: 10.1016/j.cell.2019.03.005]

- 14 **Ding X**, He M, Chan AWH, Song QX, Sze SC, Chen H, Man MKH, Man K, Chan SL, Lai PBS, Wang X, Wong N. Genomic and Epigenomic Features of Primary and Recurrent Hepatocellular Carcinomas. *Gastroenterology* 2019; **157**: 1630-1645.e6 [PMID: [31560893](#) DOI: [10.1053/j.gastro.2019.09.005](#)]
- 15 **Sun Y**, Wu L, Zhong Y, Zhou K, Hou Y, Wang Z, Zhang X, Xie J, Wang C, Chen D, Huang Y, Wei X, Shi Y, Zhao Z, Li Y, Guo Z, Yu Q, Xu L, Volpe G, Qiu S, Zhou J, Ward C, Sun H, Yin Y, Xu X, Wang X, Esteban MA, Yang H, Wang J, Dean M, Zhang Y, Liu S, Yang X, Fan J. Single-cell landscape of the ecosystem in early-relapse hepatocellular carcinoma. *Cell* 2021; **184**: 404-421.e16 [PMID: [33357445](#) DOI: [10.1016/j.cell.2020.11.041](#)]
- 16 **Zheng C**, Zheng L, Yoo JK, Guo H, Zhang Y, Guo X, Kang B, Hu R, Huang JY, Zhang Q, Liu Z, Dong M, Hu X, Ouyang W, Peng J, Zhang Z. Landscape of Infiltrating T Cells in Liver Cancer Revealed by Single-Cell Sequencing. *Cell* 2017; **169**: 1342-1356.e16 [PMID: [28622514](#) DOI: [10.1016/j.cell.2017.05.035](#)]
- 17 **Li CX**, Ling CC, Shao Y, Xu A, Li XC, Ng KT, Liu XB, Ma YY, Qi X, Liu H, Liu J, Yeung OW, Yang XX, Liu QS, Lam YF, Zhai Y, Lo CM, Man K. CXCL10/CXCR3 signaling mobilized-regulatory T cells promote liver tumor recurrence after transplantation. *J Hepatol* 2016; **65**: 944-952 [PMID: [27245433](#) DOI: [10.1016/j.jhep.2016.05.032](#)]
- 18 **Zheng X**, Jin W, Wang S, Ding H. Progression on the Roles and Mechanisms of Tumor-Infiltrating T Lymphocytes in Patients With Hepatocellular Carcinoma. *Front Immunol* 2021; **12**: 729705 [PMID: [34566989](#) DOI: [10.3389/fimmu.2021.729705](#)]
- 19 **Ambrozkiwicz F**, Trailin A, Červenková L, Vaclavikova R, Hanicinc V, Allah MAO, Palek R, Třeška V, Daum O, Tonar Z, Liška V, Hemminki K. CTNNB1 mutations, TERT polymorphism and CD8+ cell densities in resected hepatocellular carcinoma are associated with longer time to recurrence. *BMC Cancer* 2022; **22**: 884 [PMID: [35962322](#) DOI: [10.1186/s12885-022-09989-0](#)]
- 20 **Dash S**, Aydin Y, Widmer KE, Nayak L. Hepatocellular Carcinoma Mechanisms Associated with Chronic HCV Infection and the Impact of Direct-Acting Antiviral Treatment. *J Hepatocell Carcinoma* 2020; **7**: 45-76 [PMID: [32346535](#) DOI: [10.2147/JHC.S221187](#)]
- 21 **Qu WF**, Tian MX, Qiu JT, Guo YC, Tao CY, Liu WR, Tang Z, Qian K, Wang ZX, Li XY, Hu WA, Zhou J, Fan J, Zou H, Hou YY, Shi YH. Exploring pathological signatures for predicting the recurrence of early-stage hepatocellular carcinoma based on deep learning. *Front Oncol* 2022; **12**: 968202 [PMID: [36059627](#) DOI: [10.3389/fonc.2022.968202](#)]
- 22 **Zaki MYW**, Fathi AM, Samir S, Eldafashi N, William KY, Nazmy MH, Fathy M, Gill US, Shetty S. Innate and Adaptive Immunopathogenesis in Viral Hepatitis; Crucial Determinants of Hepatocellular Carcinoma. *Cancers (Basel)* 2022; **14** [PMID: [35267563](#) DOI: [10.3390/cancers14051255](#)]
- 23 **Zeng Z**, Jiang X, Pan Z, Zhou R, Lin Z, Tang Y, Cui Y, Zhang E, Cao Z. Highly expressed centromere protein L indicates adverse survival and associates with immune infiltration in hepatocellular carcinoma. *Aging (Albany NY)* 2021; **13**: 22802-22829 [PMID: [34607313](#) DOI: [10.18632/aging.203574](#)]
- 24 **Zhang L**, Yang Z, Zhang S, Zhou K, Zhang W, Ling S, Sun R, Tang H, Wen X, Feng X, Song P, Xu X, Xie H, Zheng S. Polyploidy Spectrum Correlates with Immunophenotype and Shapes Hepatocellular Carcinoma Recurrence Following Liver Transplantation. *J Inflamm Res* 2022; **15**: 217-233 [PMID: [35046696](#) DOI: [10.2147/JIR.S345681](#)]
- 25 **Li FP**, Liu GH, Zhang XQ, Kong WJ, Mei J, Wang M, Dai YH. Overexpressed SNRBP/D1/D3/E/F/G correlate with poor survival and immune infiltration in hepatocellular carcinoma. *Am J Transl Res* 2022; **14**: 4207-4228 [PMID: [35836882](#)]
- 26 **Wu M**, Mei F, Liu W, Jiang J. Comprehensive characterization of tumor infiltrating natural killer cells and clinical significance in hepatocellular carcinoma based on gene expression profiles. *Biomed Pharmacother* 2020; **121**: 109637 [PMID: [31810126](#) DOI: [10.1016/j.biopha.2019.109637](#)]
- 27 **Wang D**, Zheng X, Fu B, Nian Z, Qian Y, Sun R, Tian Z, Wei H. Hepatectomy promotes recurrence of liver cancer by enhancing IL-11-STAT3 signaling. *EBioMedicine* 2019; **46**: 119-132 [PMID: [31375423](#) DOI: [10.1016/j.ebiom.2019.07.058](#)]
- 28 **Carissimi F**, Barbaglia MN, Salmi L, Ciulli C, Roccamatysi L, Cordaro G, Mallela VR, Minisini R, Leone BE, Donadon M, Torzilli G, Pirisi M, Romano F, Famularo S. Finding the seed of recurrence: Hepatocellular carcinoma circulating tumor cells and their potential to drive the surgical treatment. *World J Gastrointest Surg* 2021; **13**: 967-978 [PMID: [34621473](#) DOI: [10.4240/wjgs.v13.i9.967](#)]
- 29 **Zhou SL**, Zhou ZJ, Hu ZQ, Song CL, Luo YJ, Luo CB, Xin HY, Yang XR, Shi YH, Wang Z, Huang XW, Cao Y, Fan J, Zhou J. Genomic sequencing identifies WNK2 as a driver in hepatocellular carcinoma and a risk factor for early recurrence. *J Hepatol* 2019; **71**: 1152-1163 [PMID: [31349001](#) DOI: [10.1016/j.jhep.2019.07.014](#)]
- 30 **Cao S**, Lyu T, Fan Z, Guan H, Song L, Tong X, Wang J, Zou Y. Long-term outcome of percutaneous radiofrequency ablation for periportal hepatocellular carcinoma: tumor recurrence or progression, survival and clinical significance. *Cancer Imaging* 2022; **22**: 2 [PMID: [34983650](#) DOI: [10.1186/s40644-021-00442-2](#)]
- 31 **Minami Y**, Minami T, Ueshima K, Yagyu Y, Tsurusaki M, Okada T, Hori M, Kudo M, Murakami T. Three-Dimensional Radiological Assessment of Ablative Margins in Hepatocellular Carcinoma: Pilot Study of Overlay Fused CT/MRI Imaging with Automatic Registration. *Cancers (Basel)* 2021; **13** [PMID: [33806751](#) DOI: [10.3390/cancers13061460](#)]
- 32 **Guo Y**, Ren Y, Dong X, Kan X, Zheng C. An Overview of Hepatocellular Carcinoma After Insufficient Radiofrequency Ablation. *J Hepatocell Carcinoma* 2022; **9**: 343-355 [PMID: [35502292](#) DOI: [10.2147/JHC.S358539](#)]
- 33 **Xie DY**, Fan HK, Ren ZG, Fan J, Gao Q. Identifying Clonal Origin of Multifocal Hepatocellular Carcinoma and Its Clinical Implications. *Clin Transl Gastroenterol* 2019; **10**: e00006 [PMID: [30829920](#) DOI: [10.14309/ctg.0000000000000006](#)]
- 34 **Kuo MJ**, Mo LR, Chen CL. Factors predicting long-term outcomes of early-stage hepatocellular carcinoma after primary curative treatment: the role of surgical or nonsurgical methods. *BMC Cancer* 2021; **21**: 250 [PMID: [33685409](#) DOI: [10.1186/s12885-021-07948-9](#)]
- 35 **Tovoli F**, Pallotta DP, Sansone V, Iavarone M, De Giorgio M, Ielasi L, Di Costanzo GG, Giuffrida P, Sacco R, Pressiani T, Di Donato MF, Trevisani F, Fagioli S, Piscaglia F, Granito A. Outcomes of Sorafenib for Recurrent Hepatocellular Carcinoma After Liver Transplantation in the Era of Combined and Sequential Treatments. *Transplantation* 2023; **107**: 156-161 [PMID: [35996072](#) DOI: [10.1097/TP.0000000000004271](#)]
- 36 **Reig M**, Mariño Z, Perelló C, Iñarrairaegui M, Ribeiro A, Lens S, Díaz A, Vilana R, Darnell A, Varela M, Sangro B,

- Calleja JL, Forns X, Bruix J. Unexpected high rate of early tumor recurrence in patients with HCV-related HCC undergoing interferon-free therapy. *J Hepatol* 2016; **65**: 719-726 [PMID: 27084592 DOI: 10.1016/j.jhep.2016.04.008]
- 37 Singal AG, Rich NE, Mehta N, Branch A, Pillai A, Hoteit M, Volk M, Odewole M, Scaglione S, Guy J, Said A, Feld JJ, John BV, Frenette C, Mantry P, Rangnekar AS, Oloruntoba O, Leise M, Jou JH, Bhamidimarri KR, Kulik L, Tran T, Samant H, Dhanasekaran R, Duarte-Rojo A, Salgia R, Eswaran S, Jalal P, Flores A, Satapathy SK, Wong R, Huang A, Misra S, Schwartz M, Mitrani R, Nakka S, Nouredine W, Ho C, Konjeti VR, Dao A, Nelson K, Delarosa K, Rahim U, Mavuram M, Xie JJ, Murphy CC, Parikh ND. Direct-Acting Antiviral Therapy Not Associated With Recurrence of Hepatocellular Carcinoma in a Multicenter North American Cohort Study. *Gastroenterology* 2019; **156**: 1683-1692.e1 [PMID: 30660729 DOI: 10.1053/j.gastro.2019.01.027]
 - 38 Saraiya N, Yopp AC, Rich NE, Odewole M, Parikh ND, Singal AG. Systematic review with meta-analysis: recurrence of hepatocellular carcinoma following direct-acting antiviral therapy. *Aliment Pharmacol Ther* 2018; **48**: 127-137 [PMID: 29851093 DOI: 10.1111/apt.14823]
 - 39 Kolly P, Waidmann O, Vermehren J, Moreno C, Vögeli I, Berg T, Semela D, Zeuzem S, Dufour JF. Hepatocellular carcinoma recurrence after direct antiviral agent treatment: A European multicentre study. *J Hepatol* 2017; **67**: 876-878 [PMID: 28733219 DOI: 10.1016/j.jhep.2017.07.007]
 - 40 Baumert TF, Berg T, Lim JK, Nelson DR. Status of Direct-Acting Antiviral Therapy for Hepatitis C Virus Infection and Remaining Challenges. *Gastroenterology* 2019; **156**: 431-445 [PMID: 30342035 DOI: 10.1053/j.gastro.2018.10.024]
 - 41 Huang AC, Mehta N, Dodge JL, Yao FY, Terrault NA. Direct-acting antivirals do not increase the risk of hepatocellular carcinoma recurrence after local-regional therapy or liver transplant waitlist dropout. *Hepatology* 2018; **68**: 449-461 [PMID: 29476694 DOI: 10.1002/hep.29855]
 - 42 Mori Y, Matsuda S, Sato M, Muraoka M, Suzuki Y, Tatsumi A, Nakayama Y, Inoue T, Maekawa S, Enomoto N. The Impact of Antiviral Therapy for Hepatitis C Virus on the Survival of Patients after Hepatocellular Carcinoma Treatment. *Intern Med* 2022; **61**: 2721-2729 [PMID: 36104175 DOI: 10.2169/internalmedicine.8456-21]
 - 43 Pazgan-Simon M, Simon KA, Jarowicz E, Rotter K, Szymanek-Pasternak A, Zuwała-Jagiello J. Hepatitis B virus treatment in hepatocellular carcinoma patients prolongs survival and reduces the risk of cancer recurrence. *Clin Exp Hepatol* 2018; **4**: 210-216 [PMID: 30324148 DOI: 10.5114/ceh.2018.78127]
 - 44 Jeng LB, Li TC, Hsu SC, Chan WL, Teng CF. Association of Low Serum Albumin Level with Higher Hepatocellular Carcinoma Recurrence in Patients with Hepatitis B Virus Pre-S2 Mutant after Curative Surgical Resection. *J Clin Med* 2021; **10** [PMID: 34575311 DOI: 10.3390/jcm10184187]
 - 45 Liu GM, Huang XY, Shen SL, Hu WJ, Peng BG. Adjuvant antiviral therapy for hepatitis B virus-related hepatocellular carcinoma after curative treatment: A systematic review and meta-analysis. *Hepatol Res* 2016; **46**: 100-110 [PMID: 26331530 DOI: 10.1111/hepr.12584]
 - 46 Xia BW, Zhang YC, Wang J, Ding FH, He XD. Efficacy of antiviral therapy with nucleotide/nucleoside analogs after curative treatment for patients with hepatitis B virus-related hepatocellular carcinoma: A systematic review and meta-analysis. *Clin Res Hepatol Gastroenterol* 2015; **39**: 458-468 [PMID: 25650304 DOI: 10.1016/j.clinre.2014.12.003]
 - 47 Durand F, Francoz C. The future of liver transplantation for viral hepatitis. *Liver Int* 2017; **37** Suppl 1: 130-135 [PMID: 28052618 DOI: 10.1111/liv.13310]
 - 48 Xia Z, He L, Xiong L, Wen T. The comparison of different antiviral therapies on the prognosis of hepatitis B virus-related hepatocellular carcinoma after curative treatments: A network meta-analysis. *Medicine (Baltimore)* 2020; **99**: e20877 [PMID: 32871973 DOI: 10.1097/MD.00000000000020877]
 - 49 Yun B, Ahn SH, Oh J, Yoon JH, Kim BK. Prognostic Impact of MAFLD Following Surgical Resection of Hepatitis B Virus-Related Hepatocellular Carcinoma: A Nationwide Cohort Study. *Cancers (Basel)* 2022; **14** [PMID: 36291786 DOI: 10.3390/cancers14205002]
 - 50 Roche B, Bauhofer A, Gomez Bravo MÃ, Pageaux GP, Zoulum F, Otero A, Prieto M, Baliellias C, Samuel D. Long-Term Effectiveness, Safety, and Patient-Reported Outcomes of Self-Administered Subcutaneous Hepatitis B Immunoglobulin in Liver Post-Transplant Hepatitis B Prophylaxis: A Prospective Non-Interventional Study. *Ann Transplant* 2022; **27**: e936162 [PMID: 35534995 DOI: 10.12659/AOT.936162]
 - 51 Jin H, Wang H, Li G, Hou Q, Wu W, Liu F. Risk factors for early postoperative recurrence in single and small hepatitis B virus-associated primary hepatocellular carcinoma. *J Int Med Res* 2020; **48**: 300060520961260 [PMID: 33044114 DOI: 10.1177/0300060520961260]
 - 52 Morise Z. Developments and perspectives of laparoscopic liver resection in the treatment of hepatocellular carcinoma. *Surg Today* 2019; **49**: 649-655 [PMID: 30649611 DOI: 10.1007/s00595-019-1765-9]
 - 53 Fernandez-Sevilla E, Allard MA, Selten J, Golse N, Vibert E, Sa Cunha A, Cherqui D, Castaing D, Adam R. Recurrence of hepatocellular carcinoma after liver transplantation: Is there a place for resection? *Liver Transpl* 2017; **23**: 440-447 [PMID: 28187493 DOI: 10.1002/lt.24742]
 - 54 Huang J, Yan L, Wu H, Yang J, Liao M, Zeng Y. Is radiofrequency ablation applicable for recurrent hepatocellular carcinoma after liver transplantation? *J Surg Res* 2016; **200**: 122-130 [PMID: 26277218 DOI: 10.1016/j.jss.2015.07.033]
 - 55 Onoe T, Yamaguchi M, Irei T, Ishiyama K, Sudo T, Hadano N, Kojima M, Kubota H, Ide R, Tazawa H, Shimizu W, Suzuki T, Shimizu Y, Hinoi T, Tashiro H. Feasibility and efficacy of repeat laparoscopic liver resection for recurrent hepatocellular carcinoma. *Surg Endosc* 2020; **34**: 4574-4581 [PMID: 31853630 DOI: 10.1007/s00464-019-07246-3]
 - 56 Goh BKP, Syn N, Teo JY, Guo YX, Lee SY, Cheow PC, Chow PKH, Ooi LLPJ, Chung AYT, Chan CY. Perioperative Outcomes of Laparoscopic Repeat Liver Resection for Recurrent HCC: Comparison with Open Repeat Liver Resection for Recurrent HCC and Laparoscopic Resection for Primary HCC. *World J Surg* 2019; **43**: 878-885 [PMID: 30361747 DOI: 10.1007/s00268-018-4828-y]
 - 57 Nomi T, Kaibori M, Tanaka S, Hirokawa F, Hokuto D, Noda T, Ueno M, Nakai T, Ikoma H, Iida H, Matsui K, Komeda K, Hayami S, Eguchi H, Matsumoto M, Morimura R, Machira H, Yoshikawa T, Kubo S. Short- and long-term outcomes of laparoscopic vs open repeat liver resection for hepatocellular carcinoma: A multicenter study. *J Hepatobiliary Pancreat Sci* 2022 [PMID: 35918904 DOI: 10.1002/jhbp.1222]
 - 58 Liang Y, Lin C, Zhang B, Cao J, Chen M, Shen J, Feng X, Xiao G, Pan L, Chen K, Maher H, Cai X. Perioperative

- outcomes comparing laparoscopic with open repeat liver resection for post-hepatectomy recurrent liver cancer: A systematic review and meta-analysis. *Int J Surg* 2020; **79**: 17-28 [PMID: 32240816 DOI: 10.1016/j.ijssu.2020.03.052]
- 59 **Yoh T**, Seo S, Taura K, Iguchi K, Ogiso S, Fukumitsu K, Ishii T, Kaide T, Uemoto S. Surgery for Recurrent Hepatocellular Carcinoma: Achieving Long-term Survival. *Ann Surg* 2021; **273**: 792-799 [PMID: 31058698 DOI: 10.1097/SLA.0000000000003358]
 - 60 **Chen ZH**, Zhang XP, Feng JK, Li LQ, Zhang F, Hu YR, Zhong CQ, Wang K, Chai ZT, Wei XB, Shi J, Guo WX, Wu MC, Lau WY, Cheng SQ. Patterns, treatments, and prognosis of tumor recurrence after resection for hepatocellular carcinoma with microvascular invasion: a multicenter study from China. *HPB (Oxford)* 2022; **24**: 1063-1073 [PMID: 34961677 DOI: 10.1016/j.hpb.2021.11.016]
 - 61 **Bednarsch J**, Czigan Z, Heij LR, Amygdalos I, Heise D, Bruners P, Ulmer TF, Neumann UP, Lang SA. The role of re-resection in recurrent hepatocellular carcinoma. *Langenbecks Arch Surg* 2022; **407**: 2381-2391 [PMID: 35599252 DOI: 10.1007/s00423-022-02545-1]
 - 62 **Zhong JH**, Xing BC, Zhang WG, Chan AW, Chong CCN, Serenari M, Peng N, Huang T, Lu SD, Liang ZY, Huo RR, Wang YY, Cescon M, Liu TQ, Li L, Wu FX, Ma L, Ravaioli M, Neri J, Cucchetti A, Johnson PJ, Li LQ, Xiang BD. Repeat hepatic resection vs radiofrequency ablation for recurrent hepatocellular carcinoma: retrospective multicentre study. *Br J Surg* 2021; **109**: 71-78 [PMID: 34643677 DOI: 10.1093/bjs/zna340]
 - 63 **Midorikawa Y**, Takayama T, Nakayama H, Moriguchi M, Aramaki O, Yamazaki S, Teramoto K, Yoshida N, Kobayashi N, Tsuji S, Higaki T. Favorable outcomes of surgical resection for extrahepatic recurrent hepatocellular carcinoma. *Hepatol Res* 2020; **50**: 978-984 [PMID: 32573905 DOI: 10.1111/hepr.13526]
 - 64 **Chua DW**, Koh YX, Syn NL, Chuan TY, Yao TJ, Lee SY, Goh BKP, Cheow PC, Chung AY, Chan CY. Repeat hepatectomy vs radiofrequency ablation in management of recurrent hepatocellular carcinoma: an average treatment effect analysis. *Ann Surg Oncol* 2021; **28**: 7731-7740 [PMID: 33969464 DOI: 10.1245/s10434-021-09948-2]
 - 65 **Tabrizian P**, Jibara G, Shrager B, Schwartz M, Roayaie S. Recurrence of hepatocellular cancer after resection: patterns, treatments, and prognosis. *Ann Surg* 2015; **261**: 947-955 [PMID: 25010665 DOI: 10.1097/SLA.0000000000000710]
 - 66 **Bodzin AS**, Lunsford KE, Markovic D, Harlander-Locke MP, Busuttill RW, Agopian VG. Predicting Mortality in Patients Developing Recurrent Hepatocellular Carcinoma After Liver Transplantation: Impact of Treatment Modality and Recurrence Characteristics. *Ann Surg* 2017; **266**: 118-125 [PMID: 27433914 DOI: 10.1097/SLA.0000000000001894]
 - 67 **de'Angelis N**, Landi F, Carra MC, Azoulay D. Managements of recurrent hepatocellular carcinoma after liver transplantation: A systematic review. *World J Gastroenterol* 2015; **21**: 11185-11198 [PMID: 26494973 DOI: 10.3748/wjg.v21.i39.11185]
 - 68 **Matsumoto M**, Yanaga K, Shiba H, Wakiyama S, Sakamoto T, Futagawa Y, Gocho T, Ishida Y, Ikegami T. Treatment of intrahepatic recurrence after hepatectomy for hepatocellular carcinoma. *Ann Gastroenterol Surg* 2021; **5**: 538-552 [PMID: 34337303 DOI: 10.1002/ags3.12449]
 - 69 **Majno PE**, Sarasin FP, Mentha G, Hadengue A. Primary liver resection and salvage transplantation or primary liver transplantation in patients with single, small hepatocellular carcinoma and preserved liver function: an outcome-oriented decision analysis. *Hepatology* 2000; **31**: 899-906 [PMID: 10733546 DOI: 10.1053/he.2000.5763]
 - 70 **Zheng S**, Xie Q, Cheng J. Salvage liver transplant for hepatocellular carcinoma: rescues and benefits. *Transl Gastroenterol Hepatol* 2018; **3**: 65 [PMID: 30363838 DOI: 10.21037/tgh.2018.09.06]
 - 71 **Kim M**, Hwang S, Song GW, Ahn CS, Moon DB, Jung DH, Park GC, Lee SG. Salvage living donor liver transplantation for post-resection recurrence of combined hepatocellular carcinoma-cholangiocarcinoma. *Korean J Transplant* 2021; **35**: 116-123 [PMID: 35769525 DOI: 10.4285/kjt.20.0037]
 - 72 **Zhang X**, Li C, Wen T, Peng W, Yan L, Yang J. Outcomes of Salvage Liver Transplantation and Re-resection/ Radiofrequency Ablation for Intrahepatic Recurrent Hepatocellular Carcinoma: A New Surgical Strategy Based on Recurrence Pattern. *Dig Dis Sci* 2018; **63**: 502-514 [PMID: 29238896 DOI: 10.1007/s10620-017-4861-y]
 - 73 **Guo Y**, Tan EK, Syn NL, Krishnamoorthy TL, Tan CK, Lim R, Lee SY, Chan CY, Cheow PC, Chung AYF, Jeyaraj PR, Goh BKP. Repeat liver resection vs salvage liver transplant for recurrent hepatocellular carcinoma: A propensity score-adjusted and -matched comparison analysis. *Ann Hepatobiliary Pancreat Surg* 2019; **23**: 305-312 [PMID: 31824994 DOI: 10.14701/ahbps.2019.23.4.305]
 - 74 **Kostakis ID**, Machairas N, Prodromidou A, Stamopoulos P, Garoufalia Z, Fouzas I, Sotiropoulos GC. Comparison Between Salvage Liver Transplantation and Repeat Liver Resection for Recurrent Hepatocellular Carcinoma: A Systematic Review and Meta-analysis. *Transplant Proc* 2019; **51**: 433-436 [PMID: 30879559 DOI: 10.1016/j.transproceed.2019.01.072]
 - 75 **Yoon YI**, Song GW, Lee S, Moon D, Hwang S, Kang WH, Cho HD, Ha SM, Kim MJ, Kim SH, Na BG, Yang G, Min Kim S, Hyun Shim J, Park JI. Salvage living donor liver transplantation vs repeat liver resection for patients with recurrent hepatocellular carcinoma and Child-Pugh class A liver cirrhosis: A propensity score-matched comparison. *Am J Transplant* 2022; **22**: 165-176 [PMID: 34383368 DOI: 10.1111/ajt.16790]
 - 76 **de Haas RJ**, Lim C, Bhangui P, Salloum C, Compagnon P, Feray C, Calderaro J, Luciani A, Azoulay D. Curative salvage liver transplantation in patients with cirrhosis and hepatocellular carcinoma: An intention-to-treat analysis. *Hepatology* 2018; **67**: 204-215 [PMID: 28806477 DOI: 10.1002/hep.29468]
 - 77 **Chan KM**, Cheng CH, Wu TH, Lee CF, Wu TJ, Chou HS, Lee WC. Salvage living donor liver transplantation for posthepatectomy recurrence: a higher incidence of recurrence but promising strategy for long-term survival. *Cancer Manag Res* 2019; **11**: 7295-7305 [PMID: 31447587 DOI: 10.2147/CMAR.S215732]
 - 78 **Chan KM**, Wu TH, Cheng CH, Lee CF, Wu TJ, Chou HS, Lee WC. Advantage of early liver transplantation whenever indicated for hepatocellular carcinoma recurrence after primary liver resection. *Biomed J* 2019; **42**: 335-342 [PMID: 31783994 DOI: 10.1016/j.bj.2019.04.001]
 - 79 **Shan Y**, Huang L, Xia Q. Salvage Liver Transplantation Leads to Poorer Outcome in Hepatocellular Carcinoma Compared with Primary Liver Transplantation. *Sci Rep* 2017; **7**: 44652 [PMID: 28294176 DOI: 10.1038/srep44652]
 - 80 **Muaddi H**, Al-Adra DP, Beecroft R, Ghanekar A, Moulton CA, Doyle A, Selzner M, Wei A, McGilvray ID, Gallinger S, Grant DR, Cattral MS, Greig PD, Kachura J, Cleary SP, Sapisochin G. Liver Transplantation is Equally Effective as a

- Salvage Therapy for Patients with Hepatocellular Carcinoma Recurrence Following Radiofrequency Ablation or Liver Resection with Curative Intent. *Ann Surg Oncol* 2018; **25**: 991-999 [PMID: 29327179 DOI: 10.1245/s10434-017-6329-x]
- 81 Abe T, Tashiro H, Teraoka Y, Hattori M, Tanimine N, Kuroda S, Tahara H, Ohira M, Tanaka Y, Kobayashi T, Ide K, Ishiyama K, Ohdan H. Efficacy and Feasibility of Salvage Living Donor Liver Transplantation after Initial Liver Resection in Patients with Hepatocellular Carcinoma. *Dig Surg* 2016; **33**: 8-14 [PMID: 26551258 DOI: 10.1159/000441397]
 - 82 Roddy H, Meyer T, Roddie C. Novel Cellular Therapies for Hepatocellular Carcinoma. *Cancers (Basel)* 2022; **14** [PMID: 35158772 DOI: 10.3390/cancers14030504]
 - 83 Li J, Wang S, Fontana F, Tapeinos C, Shahbazi MA, Han H, Santos HA. Nanoparticles-based phototherapy systems for cancer treatment: Current status and clinical potential. *Bioact Mater* 2023; **23**: 471-507 [PMID: 36514388 DOI: 10.1016/j.bioactmat.2022.11.013]
 - 84 Yang Y, Yu H, Tan X, You Y, Liu F, Zhao T, Qi J, Li J, Feng Y, Zhu Q. Liver resection vs radiofrequency ablation for recurrent hepatocellular carcinoma: a systematic review and meta-analysis. *Int J Hyperthermia* 2021; **38**: 875-886 [PMID: 34078221 DOI: 10.1080/02656736.2021.1933218]
 - 85 Forner A, Reig M, Bruix J. Hepatocellular carcinoma. *Lancet* 2018; **391**: 1301-1314 [PMID: 29307467 DOI: 10.1016/S0140-6736(18)30010-2]
 - 86 Pelizzaro F, Gambato M, Gringeri E, Vitale A, Cillo U, Farinati F, Burra P, Russo FP. Management of Hepatocellular Carcinoma Recurrence after Liver Transplantation. *Cancers (Basel)* 2021; **13** [PMID: 34638365 DOI: 10.3390/cancers13194882]
 - 87 Zhang X, Li C, Wen T, Yan L, Li B, Yang J, Wang W, Xu M, Lu W, Jiang L. Appropriate treatment strategies for intrahepatic recurrence after curative resection of hepatocellular carcinoma initially within the Milan criteria: according to the recurrence pattern. *Eur J Gastroenterol Hepatol* 2015; **27**: 933-940 [PMID: 25933127 DOI: 10.1097/MEG.0000000000000383]
 - 88 Feng Y, Wu H, Huang DQ, Xu C, Zheng H, Maeda M, Zhao X, Wang L, Xiao F, Lv H, Liu T, Qi J, Li J, Zhong N, Wang C, Feng H, Liang B, Ren W, Qin C, Nguyen MH, Zhu Q. Radiofrequency ablation vs repeat resection for recurrent hepatocellular carcinoma (≤ 5 cm) after initial curative resection. *Eur Radiol* 2020; **30**: 6357-6368 [PMID: 32529568 DOI: 10.1007/s00330-020-06990-8]
 - 89 Lu LH, Mei J, Kan A, Ling YH, Li SH, Wei W, Chen MS, Zhang YF, Guo RP. Treatment optimization for recurrent hepatocellular carcinoma: Repeat hepatic resection vs radiofrequency ablation. *Cancer Med* 2020; **9**: 2997-3005 [PMID: 32108433 DOI: 10.1002/cam4.2951]
 - 90 Bai XM, Cui M, Yang W, Wang H, Wang S, Zhang ZY, Wu W, Chen MH, Yan K, Goldberg SN. The 10-year Survival Analysis of Radiofrequency Ablation for Solitary Hepatocellular Carcinoma 5 cm or Smaller: Primary vs Recurrent HCC. *Radiology* 2021; **300**: 458-469 [PMID: 34003058 DOI: 10.1148/radiol.2021200153]
 - 91 Shin SW, Ahn KS, Kim SW, Kim TS, Kim YH, Kang KJ. Liver Resection Versus Local Ablation Therapies for Hepatocellular Carcinoma Within the Milan Criteria: A Systematic Review and Meta-analysis. *Ann Surg* 2021; **273**: 656-666 [PMID: 33074898 DOI: 10.1097/SLA.0000000000004350]
 - 92 Schullian P, Laimer G, Putzer D, Levy E, Braunwarth E, Stättner S, Bale R. Stereotactic radiofrequency ablation as first-line treatment of recurrent HCC following hepatic resection. *Eur J Surg Oncol* 2020; **46**: 1503-1509 [PMID: 32222261 DOI: 10.1016/j.ejso.2020.03.207]
 - 93 Liu B, Huang G, Xie X, Zhao Q, Su L, Liu M, Li X, Long J, Kuang M. Feasibility and outcomes of percutaneous radiofrequency ablation for intrahepatic recurrent hepatocellular carcinoma after liver transplantation: a single-center experience. *Int J Hyperthermia* 2020; **37**: 1202-1209 [PMID: 33100042 DOI: 10.1080/02656736.2020.1834154]
 - 94 Chen X, Chen Y, Li Q, Ma D, Shen B, Peng C. Radiofrequency ablation vs surgical resection for intrahepatic hepatocellular carcinoma recurrence: a meta-analysis. *J Surg Res* 2015; **195**: 166-174 [PMID: 25724768 DOI: 10.1016/j.jss.2015.01.042]
 - 95 Kim TH, Koh YH, Kim BH, Kim MJ, Lee JH, Park B, Park JW. Proton beam radiotherapy vs. radiofrequency ablation for recurrent hepatocellular carcinoma: A randomized phase III trial. *J Hepatol* 2021; **74**: 603-612 [PMID: 33031846 DOI: 10.1016/j.jhep.2020.09.026]
 - 96 Jeon MY, Kim HS, Lim TS, Han DH, Kim BK, Park JY, Kim DY, Ahn SH, Choi GH, Choi JS, Han KH, Kim SU. Refractoriness to transarterial chemoembolization in patients with recurrent hepatocellular carcinoma after curative resection. *PLoS One* 2019; **14**: e0214613 [PMID: 30947275 DOI: 10.1371/journal.pone.0214613]
 - 97 Akateh C, Black SM, Conteh L, Miller ED, Noonan A, Elliott E, Pawlik TM, Tsung A, Cloyd JM. Neoadjuvant and adjuvant treatment strategies for hepatocellular carcinoma. *World J Gastroenterol* 2019; **25**: 3704-3721 [PMID: 31391767 DOI: 10.3748/wjg.v25.i28.3704]
 - 98 Manjunatha N, Ganduri V, Rajasekaran K, Duraiyaran S, Adefuye M. Transarterial Chemoembolization and Unresectable Hepatocellular Carcinoma: A Narrative Review. *Cureus* 2022; **14**: e28439 [PMID: 36176866 DOI: 10.7759/cureus.28439]
 - 99 Raoul JL, Forner A, Bolondi L, Cheung TT, Kloeckner R, de Baere T. Updated use of TACE for hepatocellular carcinoma treatment: How and when to use it based on clinical evidence. *Cancer Treat Rev* 2019; **72**: 28-36 [PMID: 30447470 DOI: 10.1016/j.ctrv.2018.11.002]
 - 100 Qi YP, Zhong JH, Liang ZY, Zhang J, Chen B, Chen CZ, Li LQ, Xiang BD. Adjuvant transarterial chemoembolization for patients with hepatocellular carcinoma involving microvascular invasion. *Am J Surg* 2019; **217**: 739-744 [PMID: 30103903 DOI: 10.1016/j.amjsurg.2018.07.054]
 - 101 Cerban R, Ester C, Iacob S, Grasu M, Păslaru L, Dumitru R, Lupescu I, Constantin G, Croitoru A, Gheorghe L. Predictive Factors of Tumor Recurrence and Survival in Patients with Hepatocellular Carcinoma treated with Transarterial Chemoembolization. *J Gastrointest Liver Dis* 2018; **27**: 409-417 [PMID: 30574623 DOI: 10.15403/jgld.2014.1121.274.fcr]
 - 102 Sposito C, Citterio D, Virdis M, Battiston C, Droz Dit Busset M, Flores M, Mazzaferro V. Therapeutic strategies for post-transplant recurrence of hepatocellular carcinoma. *World J Gastroenterol* 2022; **28**: 4929-4942 [PMID: 36160651 DOI: 10.3748/wjg.v28.i34.4929]

- 103 **Zhou B**, Shan H, Zhu KS, Jiang ZB, Guan SH, Meng XC, Zeng XC. Chemoembolization with lobaplatin mixed with iodized oil for unresectable recurrent hepatocellular carcinoma after orthotopic liver transplantation. *J Vasc Interv Radiol* 2010; **21**: 333-338 [PMID: 20116286 DOI: 10.1016/j.jvir.2009.11.006]
- 104 **Kim SS**, Kang TW, Song KD, Cho SK, Lee MW, Rhim H, Sinn DH, Jung SH. Radiofrequency ablation and transarterial chemoembolisation as first-line treatment for recurrent hepatocellular carcinoma or isolated intrahepatic recurrent hepatocellular carcinoma in transplanted livers. *Clin Radiol* 2017; **72**: 141-149 [PMID: 27742104 DOI: 10.1016/j.crad.2016.09.008]
- 105 **Gu H**, Li J, You N, Wu K, Wang Z, Wang L, Zhu Y, Liu Q, Peng X, Zheng L. Efficacy and safety of apatinib combined with transarterial chemoembolization (TACE) in treating patients with recurrent hepatocellular carcinoma. *Ann Transl Med* 2020; **8**: 1677 [PMID: 33490189 DOI: 10.21037/atm-20-7244]
- 106 **Song Q**, Ren W, Fan L, Zhao M, Mao L, Jiang S, Zhao C, Cui Y. Long-Term Outcomes of Transarterial Chemoembolization Combined with Radiofrequency Ablation Versus Transarterial Chemoembolization Alone for Recurrent Hepatocellular Carcinoma After Surgical Resection. *Dig Dis Sci* 2020; **65**: 1266-1275 [PMID: 31312995 DOI: 10.1007/s10620-019-05733-0]
- 107 **Sun KX**, Cao SS, Shi FH, Guan Y, Tang M, Zhao MN, Jian YF, Cui B, Li ZY, Wang JW, Yu F, Ding Y. First-line treatments for advanced hepatocellular carcinoma: a network meta-analysis and cost-effectiveness analysis in China and the United States. *Therap Adv Gastroenterol* 2022; **15**: 17562848221140662 [PMID: 36518883 DOI: 10.1177/17562848221140662]
- 108 **Hur MH**, Kim YJ. Evolution of systemic therapy for advanced-stage hepatocellular carcinoma. *Hepatobiliary Surg Nutr* 2022; **11**: 899-902 [PMID: 36523933 DOI: 10.21037/hbsn-22-507]
- 109 **Farinha D**, Migawa M, Sarmento-Ribeiro A, Faneca H. A Combined Antitumor Strategy Mediated by a New Targeted Nanosystem to Hepatocellular Carcinoma. *Int J Nanomedicine* 2021; **16**: 3385-3405 [PMID: 34040370 DOI: 10.2147/IJN.S302288]
- 110 **Invernizzi F**, Iavarone M, Zavaglia C, Mazza S, Maggi U, Cesarini L, Antonelli B, Airoidi A, Manini MA, Sangiovanni A, Rossi G, Donato MF, Saverio Belli L, Lampertico P. Experience With Early Sorafenib Treatment With mTOR Inhibitors in Hepatocellular Carcinoma Recurring After Liver Transplantation. *Transplantation* 2020; **104**: 568-574 [PMID: 31517781 DOI: 10.1097/TP.0000000000002955]
- 111 **Alsina AE**, Makris A, Nenos V, Sucre E, Arrobas J, Franco E, Kemmer N. Can sorafenib increase survival for recurrent hepatocellular carcinoma after liver transplantation? *Am Surg* 2014; **80**: 680-684 [PMID: 24987900 DOI: 10.1177/000313481408000723]
- 112 **Yang Z**, Wang S, Tian XY, Xie QF, Zhuang L, Li QY, Chen CZ, Zheng SS. Impact of treatment modalities on patients with recurrent hepatocellular carcinoma after liver transplantation: Preliminary experience. *Hepatobiliary Pancreat Dis Int* 2020; **19**: 365-370 [PMID: 32553774 DOI: 10.1016/j.hbpd.2020.06.002]
- 113 **Lee SK**, Jang JW, Nam H, Sung PS, Kim HY, Kwon JH, Lee SW, Song DS, Kim CW, Song MJ, Choi HJ, You YK, Bae SH, Choi JY, Yoon SK. Sorafenib for advanced hepatocellular carcinoma provides better prognosis after liver transplantation than without liver transplantation. *Hepatol Int* 2021; **15**: 137-145 [PMID: 33496932 DOI: 10.1007/s12072-020-10131-0]
- 114 **Peng Z**, Chen S, Xiao H, Wang Y, Li J, Mei J, Chen Z, Zhou Q, Feng S, Chen M, Qian G, Peng S, Kuang M. Microvascular Invasion as a Predictor of Response to Treatment with Sorafenib and Transarterial Chemoembolization for Recurrent Intermediate-Stage Hepatocellular Carcinoma. *Radiology* 2019; **292**: 237-247 [PMID: 31135299 DOI: 10.1148/radiol.2019181818]
- 115 **Kaibori M**, Matsushima H, Ishizaki M, Kosaka H, Matsui K, Kariya S, Yoshii K, Sekimoto M. The Impact of Sorafenib in Combination with Transarterial Chemoembolization on the Outcomes of Intermediate-Stage Hepatocellular Carcinoma. *Asian Pac J Cancer Prev* 2021; **22**: 1217-1224 [PMID: 33906315 DOI: 10.31557/APJCP.2021.22.4.1217]
- 116 **Zhou Q**, Wang X, Li R, Wang C, Wang J, Xie X, Li Y, Li S, Mao X, Liang P. Sorafenib as adjuvant therapy following radiofrequency ablation for recurrent hepatocellular carcinoma within Milan criteria: a multicenter analysis. *J Gastroenterol* 2022; **57**: 684-694 [PMID: 35816221 DOI: 10.1007/s00535-022-01895-3]
- 117 **Melancon MP**, Zhou M, Li C. Cancer theranostics with near-infrared light-activatable multimodal nanoparticles. *Acc Chem Res* 2011; **44**: 947-956 [PMID: 21848277 DOI: 10.1021/ar200022e]
- 118 **Zhou T**, Liang X, Wang P, Hu Y, Qi Y, Jin Y, Du Y, Fang C, Tian J. A Hepatocellular Carcinoma Targeting Nanostrategy with Hypoxia-Ameliorating and Photothermal Abilities that, Combined with Immunotherapy, Inhibits Metastasis and Recurrence. *ACS Nano* 2020; **14**: 12679-12696 [PMID: 32909732 DOI: 10.1021/acsnano.0c01453]
- 119 **Iavarone M**, Invernizzi F, Czauderna C, Sanduzzi-Zamparelli M, Bhoori S, Amadeo G, Manini MA, López MF, Anders M, Pinter M, Rodríguez MJB, Cristóbal MR, Soteras GA, Piñero F, Villadsen GE, Weinmann A, Crespo G, Mazzaferro V, Regnault H, Giorgio M, González-Diéguez ML, Donato MF, Varela M, Wörns MA, Bruix J, Lampertico P, Reig M. Preliminary experience on safety of regorafenib after sorafenib failure in recurrent hepatocellular carcinoma after liver transplantation. *Am J Transplant* 2019; **19**: 3176-3184 [PMID: 31365177 DOI: 10.1111/ajt.15551]
- 120 **Ho WJ**, Zhu Q, Durham J, Popovic A, Xavier S, Leatherman J, Mohan A, Mo G, Zhang S, Gross N, Charmsaz S, Lin D, Quong D, Wilt B, Kamel IR, Weiss M, Philosophie B, Burkhart R, Burns WR, Shubert C, Ejaz A, He J, Deshpande A, Danilova L, Stein-O'Brien G, Sugar EA, Laheru DA, Anders RA, Fertig EJ, Jaffee EM, Yarchon M. Neoadjuvant Cabozantinib and Nivolumab Converts Locally Advanced HCC into Resectable Disease with Enhanced Antitumor Immunity. *Nat Cancer* 2021; **2**: 891-903 [PMID: 34796337 DOI: 10.1038/s43018-021-00234-4]
- 121 **Yi C**, Chen L, Lin Z, Liu L, Shao W, Zhang R, Lin J, Zhang J, Zhu W, Jia H, Qin L, Lu L, Chen J. Lenvatinib Targets FGF Receptor 4 to Enhance Antitumor Immune Response of Anti-Programmed Cell Death-1 in HCC. *Hepatology* 2021; **74**: 2544-2560 [PMID: 34036623 DOI: 10.1002/hep.31921]
- 122 **Azhie A**, Grant RC, Herman M, Wang L, Knox JJ, Bhat M. Phase II clinical trial of cabozantinib for the treatment of recurrent hepatocellular carcinoma after liver transplantation. *Future Oncol* 2022; **18**: 2173-2191 [PMID: 35287469 DOI: 10.2217/fon-2021-1635]
- 123 **Mahn R**, Sadeghlar F, Bartels A, Zhou T, Weismüller T, Kupczyk P, Meyer C, Gaertner FC, Toma M, Vilz T, Knipper P,

- Glowka T, Manekeller S, Kalff J, Strassburg CP, Gonzalez-Carmona MA. Multimodal and systemic therapy with cabozantinib for treatment of recurrent hepatocellular carcinoma after liver transplantation: A case report with long term follow-up outcomes. *Medicine (Baltimore)* 2021; **100**: e27082 [PMID: 34559100 DOI: 10.1097/MD.00000000000027082]
- 124 **Iavarone M**, Invernizzi F, Ivanics T, Mazza S, Zavaglia C, Sanduzzi-Zamparelli M, Fraile-López M, Czauderna C, Di Costanzo G, Bhoori S, Pinter M, Manini MA, Amadeo G, Yunquera AF, Piñero F, Blanco Rodríguez MJ, Anders M, Aballay Soteras G, Villadsen GE, Yoon PD, Cesarini L, Díaz-González Á, González-Diéguez ML, Tortora R, Weinmann A, Mazzaferro V, Romero Cristóbal M, Crespo G, Regnault H, De Giorgio M, Varela M, Prince R, Scudeller L, Donato MF, Wörns MA, Bruix J, Sapisochin G, Lampertico P, Reig M. Regorafenib Efficacy After Sorafenib in Patients With Recurrent Hepatocellular Carcinoma After Liver Transplantation: A Retrospective Study. *Liver Transpl* 2021; **27**: 1767-1778 [PMID: 34388851 DOI: 10.1002/lt.26264]
 - 125 **Pardoll DM**. The blockade of immune checkpoints in cancer immunotherapy. *Nat Rev Cancer* 2012; **12**: 252-264 [PMID: 22437870 DOI: 10.1038/nrc3239]
 - 126 **Gao Y**, Xu Q, Li X, Guo Y, Zhang B, Jin Y, Zhu C, Shen Y, Yang P, Shi Y, Jin R, Liu D, Ouyang Y, Liu X, Wang W, Chen D, Yang T. Heterogeneity induced GZMA-F2R communication inefficient impairs antitumor immunotherapy of PD-1 mAb through JAK2/STAT1 signal suppression in hepatocellular carcinoma. *Cell Death Dis* 2022; **13**: 213 [PMID: 35256589 DOI: 10.1038/s41419-022-04654-7]
 - 127 **Toso C**, Meeberg G, Hernandez-Alejandro R, Dufour JF, Marotta P, Majno P, Kneteman NM. Total tumor volume and alpha-fetoprotein for selection of transplant candidates with hepatocellular carcinoma: A prospective validation. *Hepatology* 2015; **62**: 158-165 [PMID: 25777590 DOI: 10.1002/hep.27787]
 - 128 **Kaseb AO**, Hasanov E, Cao HST, Xiao L, Vauthey JN, Lee SS, Yavuz BG, Mohamed YI, Qayyum A, Jindal S, Duan F, Basu S, Yadav SS, Nicholas C, Sun JJ, Singh Raghav KP, Rashid A, Carter K, Chun YS, Tzeng CD, Sakamuri D, Xu L, Sun R, Cristini V, Beretta L, Yao JC, Wolff RA, Allison JP, Sharma P. Perioperative nivolumab monotherapy vs nivolumab plus ipilimumab in resectable hepatocellular carcinoma: a randomised, open-label, phase 2 trial. *Lancet Gastroenterol Hepatol* 2022; **7**: 208-218 [PMID: 35065057 DOI: 10.1016/S2468-1253(21)00427-1]
 - 129 **Cheng AL**, Hsu C, Chan SL, Choo SP, Kudo M. Challenges of combination therapy with immune checkpoint inhibitors for hepatocellular carcinoma. *J Hepatol* 2020; **72**: 307-319 [PMID: 31954494 DOI: 10.1016/j.jhep.2019.09.025]
 - 130 **Wang X**, Liu G, Chen S, Bi H, Xia F, Feng K, Ma K, Ni B. Combination therapy with PD-1 blockade and radiofrequency ablation for recurrent hepatocellular carcinoma: a propensity score matching analysis. *Int J Hyperthermia* 2021; **38**: 1519-1528 [PMID: 34702122 DOI: 10.1080/02656736.2021.1991011]
 - 131 **Friend BD**, Venick RS, McDiarmid SV, Zhou X, Naini B, Wang H, Farmer DG, Busuttil RW, Federman N. Fatal orthotopic liver transplant organ rejection induced by a checkpoint inhibitor in two patients with refractory, metastatic hepatocellular carcinoma. *Pediatr Blood Cancer* 2017; **64** [PMID: 28643391 DOI: 10.1002/pbc.26682]
 - 132 **Hoffman D**, Mehta N. Recurrence of hepatocellular carcinoma following liver transplantation. *Expert Rev Gastroenterol Hepatol* 2021; **15**: 91-102 [PMID: 32933351 DOI: 10.1080/17474124.2021.1823213]
 - 133 **Li Z**, Han N, Ren X, Zhang Y, Chu X. Effectiveness of TKI Inhibitors Combined With PD-1 in Patients With Postoperative Early Recurrence of HCC: A Real-World Study. *Front Oncol* 2022; **12**: 833884 [PMID: 35433466 DOI: 10.3389/fonc.2022.833884]
 - 134 **Qiu J**, Tang W, Du C. Immune Checkpoint Inhibitors in Patients with Recurrent Hepatocellular Carcinoma after Liver Transplantation: A Case Report and Literature Review. *Curr Cancer Drug Targets* 2020; **20**: 720-727 [PMID: 32433005 DOI: 10.2174/1568009620666200520084415]
 - 135 **Qasim W**, Brunetto M, Gehring AJ, Xue SA, Schurich A, Khakpoor A, Zhan H, Ciccorossi P, Gilmour K, Cavallone D, Moriconi F, Farzhenah F, Mazzoni A, Chan L, Morris E, Thrasher A, Maini MK, Bonino F, Stauss H, Bertoletti A. Immunotherapy of HCC metastases with autologous T cell receptor redirected T cells, targeting HBsAg in a liver transplant patient. *J Hepatol* 2015; **62**: 486-491 [PMID: 25308176 DOI: 10.1016/j.jhep.2014.10.001]
 - 136 **Tan AT**, Yang N, Lee Krishnamoorthy T, Oei V, Chua A, Zhao X, Tan HS, Chia A, Le Bert N, Low D, Tan HK, Kumar R, Irani FG, Ho ZZ, Zhang Q, Guccione E, Wai LE, Koh S, Hwang W, Chow WC, Bertoletti A. Use of Expression Profiles of HBV-DNA Integrated Into Genomes of Hepatocellular Carcinoma Cells to Select T Cells for Immunotherapy. *Gastroenterology* 2019; **156**: 1862-1876.e9 [PMID: 30711630 DOI: 10.1053/j.gastro.2019.01.251]
 - 137 **Hafezi M**, Lin M, Chia A, Chua A, Ho ZZ, Fam R, Tan D, Aw J, Pavesi A, Krishnamoorthy TL, Chow WC, Chen W, Zhang Q, Wai LE, Koh S, Tan AT, Bertoletti A. Immunosuppressive Drug-Resistant T-Cell Receptor T Cells for Immune Therapy of HCC in Liver Transplant Patients. *Hepatology* 2021; **74**: 200-213 [PMID: 33249625 DOI: 10.1002/hep.31662]
 - 138 **Tao L**, Wang S, Kang G, Jiang S, Yin W, Zong L, Li J, Wang X. PD-1 blockade improves the anti-tumor potency of exhausted CD3(+)CD56(+) NKT-like cells in patients with primary hepatocellular carcinoma. *Oncimmunology* 2021; **10**: 2002068 [PMID: 34777920 DOI: 10.1080/2162402X.2021.2002068]
 - 139 **Weng DS**, Zhou J, Zhou QM, Zhao M, Wang QJ, Huang LX, Li YQ, Chen SP, Wu PH, Xia JC. Minimally invasive treatment combined with cytokine-induced killer cells therapy lower the short-term recurrence rates of hepatocellular carcinomas. *J Immunother* 2008; **31**: 63-71 [PMID: 18157013 DOI: 10.1097/CJI.0b013e31815a121b]
 - 140 **Cassese G**, Han HS, Lee B, Lee HW, Cho JY, Panaro F, Troisi RI. Immunotherapy for hepatocellular carcinoma: A promising therapeutic option for advanced disease. *World J Hepatol* 2022; **14**: 1862-1874 [PMID: 36340753 DOI: 10.4254/wjh.v14.i10.1862]
 - 141 **Lee JH**, Lee JH, Lim YS, Yeon JE, Song TJ, Yu SJ, Gwak GY, Kim KM, Kim YJ, Lee JW, Yoon JH. Adjuvant immunotherapy with autologous cytokine-induced killer cells for hepatocellular carcinoma. *Gastroenterology* 2015; **148**: 1383-91.e6 [PMID: 25747273 DOI: 10.1053/j.gastro.2015.02.055]
 - 142 **Chen C**, Ma YH, Zhang YT, Zhang F, Zhou N, Wang X, Liu T, Li YM. Effect of dendritic cell-based immunotherapy on hepatocellular carcinoma: A systematic review and meta-analysis. *Cytotherapy* 2018; **20**: 975-989 [PMID: 30072299 DOI: 10.1016/j.jcyt.2018.06.002]
 - 143 **Cao J**, Kong FH, Liu X, Wang XB. Immunotherapy with dendritic cells and cytokine-induced killer cells for hepatocellular carcinoma: A meta-analysis. *World J Gastroenterol* 2019; **25**: 3649-3663 [PMID: 31367163 DOI: 10.1002/lt.26264]

10.3748/wjg.v25.i27.3649]

- 144 **Cai Z**, Su X, Qiu L, Li Z, Li X, Dong X, Wei F, Zhou Y, Luo L, Chen G, Chen H, Wang Y, Zeng Y, Liu X. Personalized neoantigen vaccine prevents postoperative recurrence in hepatocellular carcinoma patients with vascular invasion. *Mol Cancer* 2021; **20**: 164 [PMID: 34903219 DOI: 10.1186/s12943-021-01467-8]
- 145 **Peng S**, Chen S, Hu W, Mei J, Zeng X, Su T, Wang W, Chen Z, Xiao H, Zhou Q, Li B, Xie Y, Hu H, He M, Han Y, Tang L, Ma Y, Li X, Zhou X, Dai Z, Liu Z, Tan J, Xu L, Li S, Shen S, Li D, Lai J, Peng B, Peng Z, Kuang M. Combination Neoantigen-Based Dendritic Cell Vaccination and Adoptive T-Cell Transfer Induces Antitumor Responses Against Recurrence of Hepatocellular Carcinoma. *Cancer Immunol Res* 2022; **10**: 728-744 [PMID: 35476700 DOI: 10.1158/2326-6066.CIR-21-0931]



Published by **Baishideng Publishing Group Inc**
7041 Koll Center Parkway, Suite 160, Pleasanton, CA 94566, USA

Telephone: +1-925-3991568

E-mail: bpgoffice@wjgnet.com

Help Desk: <https://www.f6publishing.com/helpdesk>

<https://www.wjgnet.com>

