

World Journal of *Hepatology*

World J Hepatol 2024 February 27; 16(2): 112-299



EDITORIAL

- 112 New markers of fibrosis in hepatitis C: A step towards the Holy Grail?
Dabos KJ
- 115 Can rifaximin for hepatic encephalopathy be discontinued during broad-spectrum antibiotic treatment?
Huang CH, Amodio P
- 120 Insights into skullcap herb-induced liver injury
Soldera J
- 123 Non-invasive assessment of esophageal varices: Status of today
Gupta T
- 126 Contemporary concepts of prevention and management of gastroesophageal variceal bleeding in liver cirrhosis patients
Garbuzenko DV
- 135 Advancements in autoimmune hepatitis management: Perspectives for future guidelines
Mucenic M
- 140 Interleukins in liver disease treatment
Yang M, Zhang CY
- 146 Changes in the etiology of liver cirrhosis and the corresponding management strategies
Dai JJ, Liu YY, Zhang ZH

REVIEW

- 152 Metabolic-associated fatty liver disease and sarcopenia: A double whammy
Viswanath A, Fouda S, Fernandez CJ, Pappachan JM
- 164 Precision targeting in hepatocellular carcinoma: Exploring ligand-receptor mediated nanotherapy
Zhou XQ, Li YP, Dang SS

MINIREVIEWS

- 177 Dynamic changes and clinical value of lipocalin 2 in liver diseases caused by microbial infections
Chen F, Wu SS, Chen C, Zhou C
- 186 Recent advances in the diagnosis of drug-induced liver injury
Ahmed T, Ahmad J

ORIGINAL ARTICLE**Retrospective Cohort Study**

- 193 Predicting major adverse cardiovascular events after orthotopic liver transplantation using a supervised machine learning model: A cohort study

Soldera J, Corso LL, Rech MM, Ballotin VR, Bigarella LG, Tomé F, Moraes N, Balbinot RS, Rodriguez S, Brandão ABM, Hochegger B

- 211 Effects of SARS-CoV-2 infection on incidence and treatment strategies of hepatocellular carcinoma in people with chronic liver disease

Mak LY, Chung MSH, Li X, Lai FTT, Wan EYF, Chui CSL, Cheng FWT, Chan EWY, Cheung CL, Au ICH, Xiong X, Seto WK, Yuen MF, Wong CKH, Wong ICK

Retrospective Study

- 229 Epidemiological survey of cystic echinococcosis in southwest China: From the Qinghai-Tibet plateau to the area of Yunnan

Zi JR, Xiao D, Peng J, Wu FW, Li JX, Yan XL, Wang ZQ, Cai X, Xu Q, Li BF, Yang YM

Observational Study

- 241 Predictors of portal vein thrombosis after splenectomy in patients with cirrhosis

Li T, Wang LL, Li YP, Gan J, Wei XS, Mao XR, Li JF

- 251 Evaluation of G3BP1 in the prognosis of acute and acute-on-chronic liver failure after the treatment of artificial liver support system

Li WY, Wang LW, Dong J, Wang Y

Basic Study

- 264 Yinhuang granule alleviates carbon tetrachloride-induced liver fibrosis in mice and its mechanism

Ouyang H, Miao H, Li Z, Wu D, Gao SC, Dai YY, Gao XD, Chai HS, Hu WY, Zhu JF

CASE REPORT

- 279 Coinfection with hepatic cystic and alveolar echinococcosis with abdominal wall abscess and sinus tract formation: A case report

Wang MM, An XQ, Chai JP, Yang JY, A JD, A XR

- 286 Autoimmune hepatitis and primary sclerosing cholangitis after direct-acting antiviral treatment for hepatitis C virus: A case report

Morihisa Y, Chung H, Towatari S, Yamashita D, Inokuma T

LETTER TO THE EDITOR

- 294 Anti-oxidative stress treatment and current clinical trials

Zhang CY, Yang M

ABOUT COVER

Editorial Board Member of *World Journal of Hepatology*, Nobuyuki Takemura, MD, PhD, FACS, Professor, Department of Hepato-Biliary-Pancreatic Surgery and Pediatric Surgery, Saitama Medical Center, Saitama Medical University, Saitama 350-8550, Japan. takemuranobu-tyk@umin.ac.jp

AIMS AND SCOPE

The primary aim of *World Journal of Hepatology* (*WJH*, *World J Hepatol*) is to provide scholars and readers from various fields of hepatology with a platform to publish high-quality basic and clinical research articles and communicate their research findings online.

WJH mainly publishes articles reporting research results and findings obtained in the field of hepatology and covering a wide range of topics including chronic cholestatic liver diseases, cirrhosis and its complications, clinical alcoholic liver disease, drug induced liver disease autoimmune, fatty liver disease, genetic and pediatric liver diseases, hepatocellular carcinoma, hepatic stellate cells and fibrosis, liver immunology, liver regeneration, hepatic surgery, liver transplantation, biliary tract pathophysiology, non-invasive markers of liver fibrosis, viral hepatitis.

INDEXING/ABSTRACTING

The *WJH* is now abstracted and indexed in PubMed, PubMed Central, Emerging Sources Citation Index (ESCI), Scopus, Reference Citation Analysis, China Science and Technology Journal Database, and Superstar Journals Database. The 2023 Edition of Journal Citation Reports® cites the 2022 impact factor (IF) for *WJH* as 2.4.

RESPONSIBLE EDITORS FOR THIS ISSUE

Production Editor: Yi-Xuan Cai; Production Department Director: Xu Guo; Editorial Office Director: Xiang Li.

NAME OF JOURNAL

World Journal of Hepatology

ISSN

ISSN 1948-5182 (online)

LAUNCH DATE

October 31, 2009

FREQUENCY

Monthly

EDITORS-IN-CHIEF

Nikolaos Pyrsopoulos, Ke-Qin Hu, Koo Jeong Kang

EXECUTIVE ASSOCIATE EDITORS-IN-CHIEF**EDITORIAL BOARD MEMBERS**

<https://www.wjgnet.com/1948-5182/editorialboard.htm>

PUBLICATION DATE

February 27, 2024

COPYRIGHT

© 2024 Baishideng Publishing Group Inc

PUBLISHING PARTNER

Department of Infectious Diseases, the Second Affiliated Hospital of Xi'an Jiaotong University

INSTRUCTIONS TO AUTHORS

<https://www.wjgnet.com/bpg/gerinfo/204>

GUIDELINES FOR ETHICS DOCUMENTS

<https://www.wjgnet.com/bpg/GerInfo/287>

GUIDELINES FOR NON-NATIVE SPEAKERS OF ENGLISH

<https://www.wjgnet.com/bpg/gerinfo/240>

PUBLICATION ETHICS

<https://www.wjgnet.com/bpg/GerInfo/288>

PUBLICATION MISCONDUCT

<https://www.wjgnet.com/bpg/gerinfo/208>

Shuang-Suo Dang

ARTICLE PROCESSING CHARGE

<https://www.wjgnet.com/bpg/gerinfo/242>

STEPS FOR SUBMITTING MANUSCRIPTS

<https://www.wjgnet.com/bpg/GerInfo/239>

ONLINE SUBMISSION

<https://www.f6publishing.com>

PUBLISHING PARTNER'S OFFICIAL WEBSITE

http://2yuan.xjtu.edu.cn/Html/Departments/Main/Index_21148.html



Coinfection with hepatic cystic and alveolar echinococcosis with abdominal wall abscess and sinus tract formation: A case report

Miao-Miao Wang, Xiu-Qing An, Jin-Ping Chai, Jin-Yu Yang, Ji-De A, Xiang-Ren A

Specialty type: Gastroenterology and hepatology

Provenance and peer review: Unsolicited article; Externally peer reviewed.

Peer-review model: Single blind

Peer-review report's scientific quality classification

Grade A (Excellent): 0
Grade B (Very good): B
Grade C (Good): 0
Grade D (Fair): 0
Grade E (Poor): 0

P-Reviewer: Oprea V, Romania

Received: November 16, 2023

Peer-review started: November 16, 2023

First decision: December 25, 2023

Revised: December 29, 2023

Accepted: January 25, 2024

Article in press: January 25, 2024

Published online: February 27, 2024



Miao-Miao Wang, Xiu-Qing An, School of Continuing Education, Qinghai University, Xining 810000, Qinghai Province, China

Jin-Ping Chai, Department of Internal Medicine-Cardiovascular, Qinghai Provincial People's Hospital, Xining 810007, Qinghai Province, China

Jin-Yu Yang, Department of General Surgery, Qinghai Provincial People's Hospital, Xining 810007, Qinghai Province, China

Ji-De A, Department of Hepatic Hydatidosis, Qinghai Provincial People's Hospital, Xining 810007, Qinghai Province, China

Xiang-Ren A, Department of Medical Laboratory Medicine, Qinghai Provincial People's Hospital, Xining 810007, Qinghai Province, China

Corresponding author: Ji-De A, MD, Doctor, Department of Hepatic Hydatidosis, Qinghai Provincial People's Hospital, No. 2 Gonghe Road, Chengdong District, Xining 810007, Qinghai Province, China. 491607355@qq.com

Abstract

BACKGROUND

Hepatic cystic and alveolar echinococcosis coinfections, particularly with concurrent abscesses and sinus tract formation, are extremely rare. This article presents a case of a patient diagnosed with this unique presentation, discussing the typical imaging manifestations of both echinococcosis types and detailing the diagnosis and surgical treatment experience thereof.

CASE SUMMARY

A 39-year-old Tibetan woman presented with concurrent hepatic cystic and alveolar echinococcosis, accompanied by abdominal wall abscesses and sinus tract formation. Initial conventional imaging examinations suggested only hepatic cystic echinococcosis, but intraoperative and postoperative pathological examination revealed the coinfection. Following radical resection of the lesions, the patient's condition improved, and she was discharged soon thereafter. Subsequent outpatient follow-ups confirmed no recurrence of the hydatid lesion and normal surgical wound healing. Though mixed hepatic cystic and alveolar echinococcosis with abdominal wall abscesses and sinus tract formations are rare, the general treatment approach remains consistent with that of simpler infections of alveolar echinococcosis.

CONCLUSION

Lesions involving the abdominal wall and sinus tract formation, may require radical resection. Long-term prognosis includes albendazole and follow-up examinations.

Key Words: Cystic echinococcosis; Alveolar echinococcosis; Abdominal wall abscess; Surgical treatment; Sinus tract; Case report

©The Author(s) 2024. Published by Baishideng Publishing Group Inc. All rights reserved.

Core Tip: Echinococcosis, also known as hydatid disease, is a zoonotic parasitic disease caused by echinococcus infection, mostly parasitic in the liver. There are two common pathogenic types of hepatic echinococcosis, *Echinococcus granulosus* and *Echinococcus multilocularis*. Infection with a single species of echinococcus was common, while co-infection with two species of echinococcus was rare, accounting for only 0.92% of the patients with hepatic echinococcosis. This article introduces the diagnosis and treatment of a patient with co-infection of two types of hepatic echinococcosis, abdominal wall abscess and sinus formation.

Citation: Wang MM, An XQ, Chai JP, Yang JY, A JD, A XR. Coinfection with hepatic cystic and alveolar echinococcosis with abdominal wall abscess and sinus tract formation: A case report. *World J Hepatol* 2024; 16(2): 279-285

URL: <https://www.wjgnet.com/1948-5182/full/v16/i2/279.htm>

DOI: <https://dx.doi.org/10.4254/wjh.v16.i2.279>

INTRODUCTION

Echinococcosis is prevalent in pastoral areas like northwest and southwest China, with an average prevalence of approximately 1.08% in western China[1]. Two types of hepatic echinococcosis exist: Cystic echinococcosis (CE) caused by *Echinococcus granulosus* (*E. granulosus*), and alveolar echinococcosis (AE) caused by *Echinococcus multilocularis* (*E. multilocularis*). Clinical diagnosis relies primarily on imaging and immunological tests. Imaging typically involves abdominal ultrasonography (US) and computed tomography (CT), while immunological detection employs enzyme-linked immunosorbent assay (ELISA)[2-4]. Definitive diagnosis requires pathological examination.

Currently, no established guidelines or general consensus exists for treating coinfections with both echinococcosis types, though radical resection is widely considered optimal[5-7]. Such coinfections are rare, representing only 0.92% of all hepatic echinococcosis cases, and can be difficult to diagnose and manage[4]. To date, only five such cases have been documented at Qinghai Provincial People's Hospital, China (Table 1). Notably, only one case involved concurrent abdominal wall invasion and sinus tract formation.

This report details the diagnosis and treatment of a patient with a mixed hepatic echinococcosis infection, presenting with abdominal wall invasion and sinus tract formation, managed at the General Surgery Department of Qinghai Provincial People's Hospital.

CASE PRESENTATION

Chief complaints

A 39-year-old Tibetan woman presented to our hospital with intermittent upper abdominal pain and discomfort for over a month, worsening in the past week.

History of present illness

The patient had intermittent epigastric distension and pain in January without any obvious cause, not accompanied by nausea, vomiting, fever and other discomforts, and did not undergo formal diagnosis and treatment, and the above symptoms worsened a week ago, so the patient came to our outpatient clinic, and the outpatient clinic was admitted to the department of our department with "abdominal pain to be investigated", and the patient was in a clear state of mind since the onset of the disease, his mental state was clear, and the spirit was fine, and he had normal urination and defecation, and he did not see any significant reduction of his body weight in recent days. Since the onset of the disease, he has been in a clear state of mind, with a normal spirit, normal bowel movements and no significant weight loss.

Physical examination

Physical examination revealed normal skin, sclerae, palpebral conjunctiva, heart, and lungs. However, an abdominal microbulge, skin rupture with pus outflow, and tenderness were found 5.0 cm above the umbilicus (Figure 1A). No abdominal varices, gastrointestinal peristalsis, or swelling were observed, but umbilical secretions and decreased

Table 1 Clinical data of five patients

No.	Sex	Age (yr)	Lesion (location)	Child-Pugh score	Surgery	Postoperative complication	Case characteristics
1	Female	42	S5 and S8	A	Anatomic right hemihepatectomy	No	Surgical treatment of patients with preoperative misdiagnosis of echinococcosis and mixed infections of both types of echinococcosis should be based on ensuring the patient's surgical safety, and radical surgery should be performed to remove all lesions whenever possible
2	Female	26	S4, S5 and S8	A	Removal of the internal capsule, with subtotal excision of the external capsule the in Echinococcus granulosus lesions	Bile leakage, ascites, and bilateral pleural effusions	The patient traveled to an out-of-state hospital for autologous liver transplantation. Staged surgical treatment may be considered in end-stage patients with insufficient residual liver volume or in advanced patients who cannot be completely resected at one time, and only palliative surgery or conservative treatment is required for patients who have lost the chance of radical surgical treatment
3	Female	49	S2, S3, S7 and S8	A	Multiple segmental hepatectomy	No	Surgical treatment of patients with preoperative misdiagnosis of echinococcosis and mixed infections of both types of echinococcosis should be based on ensuring the patient's surgical safety, and radical surgery should be performed to remove all lesions whenever possible
4	Male	56	S4, S5, S6, S7 and S8	A	Extended right hemicolectomy	No	Ultrasound-guided PTCB for jaundice reduction was performed on day 2 of admission, and jaundice was reduced until surgery on day 33 after admission
5	Female	39	S6 and S7	A	Multiple hepatic segment resection with abdominal wall sinus resection	No	Misdiagnosed preoperatively as echinococcosis, intraoperative and postoperative pathology confirmed mixed infection of the two types of echinococcosis in the liver with abdominal wall abscesses and sinus tracts, and the surgery needed to be considered as radical resection of the lesions, sinus tracts, and abdominal wall abscesses, which in turn followed the principle of individualized treatment of echinococcosis

PTCD: Percutaneous transhepatic biliary drainage; S: Segment (Couinaud's segmentation method divides the liver into eight segments according to anatomical position).

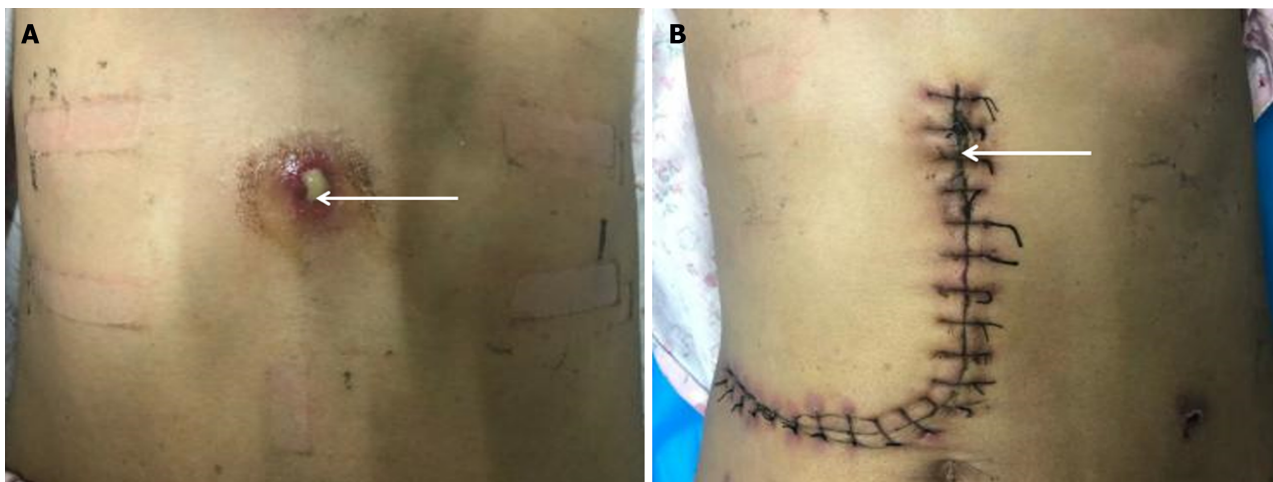


Figure 1 Preoperative lesions and postoperative incisions. A: Preoperative site of the patient's abdominal wall abscess; B: Postoperative abdominal wall abscess site. Note: The white arrows indicates the site of the abdominal wall abscess sinus tract.

abdominal breathing were present. Upper abdominal and periumbilical tenderness, rebound pain, and muscle tension were noted, while the rest of the abdomen was unremarkable.

Laboratory examinations

Initial laboratory tests showed: Red blood cells, 5.98×10^{12} cells/L; white blood cells, 5.54×10^{12} cells/L; hemoglobin, 167 g/L; and platelet count, 240×10^9 cells/L. Liver function tests revealed: Alanine aminotransferase, 9 U/L; aspartate aminotransferase, 13 U/L; total bilirubin, 7.2 mol/L; direct bilirubin, 1.4 mol/L; indirect bilirubin, 5.8 mol/L; albumin,

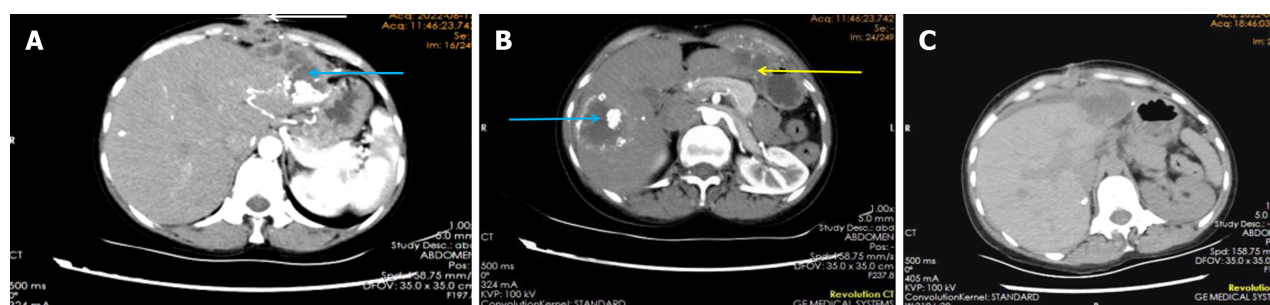


Figure 2 Pre- and postoperative imaging. A: Preoperative computed tomography (CT) images; B: Preoperative CT images; C: Postoperative CT images. Note: The white arrows indicate the site of the abdominal wall abscess sinus tract, the blue arrows indicate the site of the hepatic alveolar echinococcosis lesion, and the yellow arrows indicates the site of the hepatic cystic echinococcosis lesion.

32.2 g/L; and cholinesterase, 6140 U/L. A hydatid ELISA test yielded a positive result.

Imaging examinations

Abdominal color Doppler US revealed a 51 mm × 40 mm solid mass with a hyperechoic rim in the right hepatic lobe, suggestive of CE consolidation. Abdominal CT scan confirmed echinococcosis in the left lobe and anterior liver space, adhesion to the diaphragm, and a subxiphoid abscess with adjacent abdominal wall swelling. Scattered calcifications were identified within the right lobe CE (Figure 2A and B).

Further diagnostic work-up

Based on these findings, a diagnosis of hepatic CE with abdominal wall abscesses was made. The preoperative evaluation showed normal cardiopulmonary function and Child–Pugh grade A (5 points).

Intraoperatively (Figure 3), an oval cystic mass, measuring approximately 10.0 cm × 10.0 cm × 10.0 cm, was visualized in the right anterior hepatic lobe, exhibiting characteristics consistent with hepatic unilocular *E. granulosus*. Moreover, an irregular solid mass, measuring about 5.0 cm × 5.0 cm × 5.0 cm, in the left outer lobe was identified, presenting features compatible with hepatic *E. multilocularis*. Lastly, dense adhesions connected both masses to the anterior abdominal wall, characteristic of hepatic multilocular Echinococcus larvae.

FINAL DIAGNOSIS

Based on these findings, the diagnosis was revised to mixed-type encapsulated hepatic echinococcosis (cystic and alveolar), with abdominal wall abscess and sinus tract formation.

TREATMENT

A combined multisegmental hepatectomy with abdominal wall sinus tract resection was performed.

OUTCOME AND FOLLOW-UP

Postoperatively, the patient was encouraged to wake up and eat early to promote organ function recovery[8]. A follow-up CT scan 7 days postoperatively revealed a blurred fat space in the surgical area, with effusion, gas accumulation, and slight swelling of the right lower abdominal wall, with minimal exudate and pneumatosis; and unchanged scattered calcifications in the liver (Figure 2C).

Pathological examination of the liver hydatid tissue and fibrous cyst wall tissue revealed fibrous hyperplasia with hyalinization, necrosis, calcification, inflammatory cell infiltration, and minimal lamellar structures, consistent with echinococcosis (Figure 4). Nine days after surgery, the abdominal incision had healed well (Figure 1B), and the patient was discharged.

Regular oral albendazole therapy was initiated, as per the 2019 diagnostic criteria and expert guidelines for hepatic echinococcosis.

DISCUSSION

While relying on the aforementioned criteria, this patient's CT scan only revealed CE lesions and could not pinpoint the AE focus. Two factors might explain this. Initially, AE lesions often develop complete internal necrosis after infection,

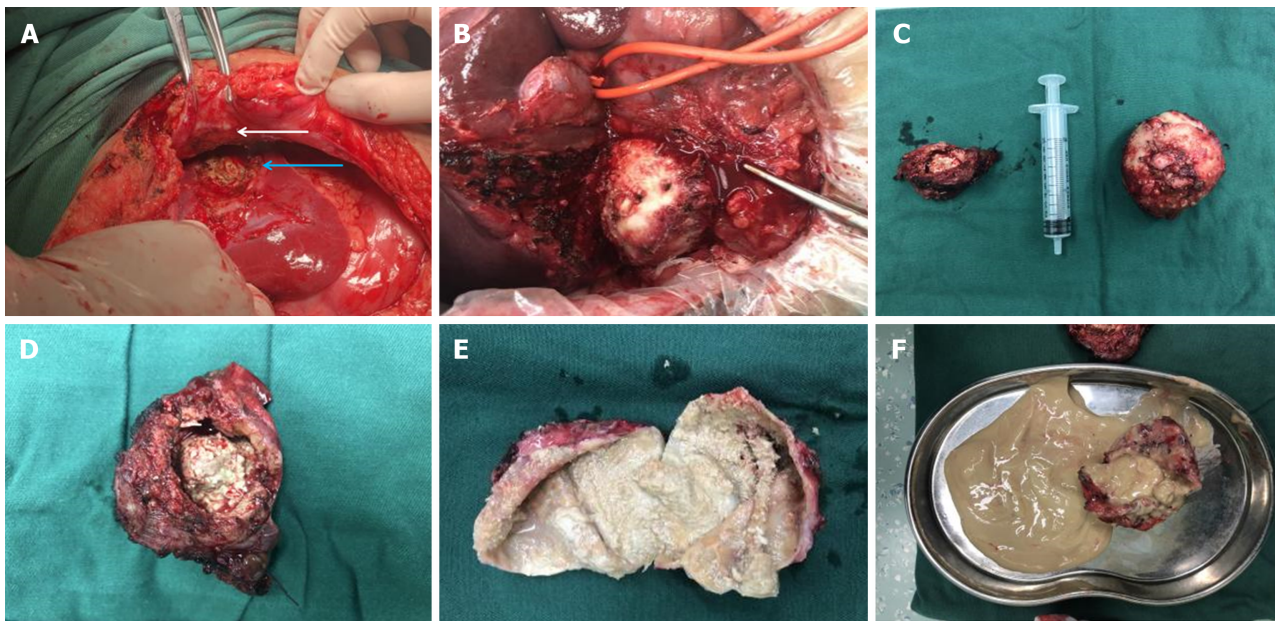


Figure 3 Intraoperative pathology specimens. A and B: Intraoperative visible lesions; C: Intraoperative excision of pathologic specimens (hepatic cystic echinococcosis and hepatic alveolar echinococcosis); D: Intraoperative excision of pathologic specimens (hepatic alveolar echinococcosis); E: Intraoperative excision of pathologic specimens (hepatic cystic echinococcosis); F: Intraoperative excision of pathologic specimens. Note: The white arrows indicate the site of the abdominal wall abscess sinus tract, and the blue arrows indicate the site of the hepatic alveolar echinococcosis lesion.

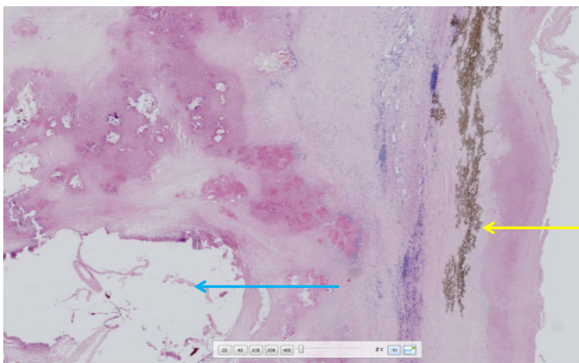


Figure 4 Postoperative pathology slides Histopathological examination by hematoxylin-eosin staining (200 ×) fibrous connective tissue proliferation and inflammatory cell infiltration are seen around the blue arrow vesicles, forming nodules of varying sizes (alveolar echinococcosis) yellow arrow laminar-like structures are clearly visible (cystic echinococcosis).

forming a thin and uniform abscess wall indistinguishable from CE on CT. Additionally, mixed CE and AE infections are uncommon and rarely appear clearly on scans. Even with CT, the optimal view for diagnosis is not always achieved, leading to potential bias in this report.

Surgical treatment for patients with combined CE and AE infections prioritizes surgical safety. Aim for radical surgery to remove all lesions comprehensively, while still employing individualized approaches for each patient. Postoperatively, all coinfecting patients should adhere to the standard AE diagnosis and treatment regimen, involving ongoing benzimidazole therapy[8].

Echinococcosis primarily targets organs like the liver, lungs, and spleen, with abdominal wall invasion is highly unusual. This patient presented with a long-standing abdominal wall abscess and sinus tract, but had no other symptoms of discomfort. Despite no major liver vessel involvement, the complications were significant. For such cases, successful surgery hinges on radical resection of the abdominal wall abscess and sinus tract. Insufficient resection risks AE recurrence, while exceeding necessary bounds can compromise remaining liver volume and functionality, leaving a large abdominal wall defect. Therefore, surgeons must ensure a safe 1.0-cm resection margin while preserving enough normal abdominal tissue (transverse diameter < 3 cm) and adequate blood supply[9,10]. By adhering to these principles, supported by thorough preoperative evaluation, accurate surgical planning, and optimal postoperative care, our patient achieved complete recovery and was discharged without complications.

CONCLUSION

This report summarized our experience in diagnosing and treating this rare condition: A mixed infection of both *Echinococcus* species with abdominal wall invasion and sinus tract formation. While the general treatment principles remain consistent with those of a simple infection by either *E. granulosus* or *E. multilocularis*, the presence of these additional complications necessitates additional considerations. For patients with long-standing lesions and established sinus tracts, radical resection of the affected tissue, including the sinus tracts and any abdominal wall abscesses, should be considered during surgery. This aligns with the principle of individualized treatment of echinococcosis. However, the long-term prognosis for such patients require postoperative albendazole treatment and regular follow-up protocols.

FOOTNOTES

Co-first authors: Miao-Miao Wang and Xiu-Qing An.

Co-corresponding authors: Ji-De A and Xiang-Ren A.

Author contributions: Wang MM, An XQ and Chai JP conceptualized and designed the research; Yang JY, A JD and A XR screened patients and acquired clinical data; Wang MM, An XQ and Chai JP collected blood specimen and performed laboratory analysis; Yang JY, A JD and A XR performed Data analysis; Wang MM, An XQ and Chai JP wrote the paper. All the authors have read and approved the final manuscript. Wang MM and An XQ prepared the first draft of the manuscript. Both authors have made crucial and indispensable contributions towards the completion of the project and thus qualified as the co-first authors of the paper. Both A JD and A XR have played important and indispensable roles in the experimental design, data interpretation and manuscript preparation as the co-corresponding authors. A XR conceptualized, designed, and supervised the whole process of the project. He searched the literature, revised and submitted the early version of the manuscript with the focus on the diagnosing and treating this rare condition: A mixed infection of both *Echinococcus* species with abdominal wall invasion and sinus tract formation. This collaboration between A JD and A XR is crucial for the publication of this manuscript and other manuscripts still in preparation.

Supported by National Natural Science Foundation of China, No. 82260412.

Informed consent statement: This published consent was obtained from the patients or their representatives.

Conflict-of-interest statement: All the authors report no relevant conflicts of interest for this article.

CARE Checklist (2016) statement: The authors have read CARE Checklist (2016), and the manuscript was prepared and revised according to CARE Checklist (2016).

Open-Access: This article is an open-access article that was selected by an in-house editor and fully peer-reviewed by external reviewers. It is distributed in accordance with the Creative Commons Attribution NonCommercial (CC BY-NC 4.0) license, which permits others to distribute, remix, adapt, build upon this work non-commercially, and license their derivative works on different terms, provided the original work is properly cited and the use is non-commercial. See: <https://creativecommons.org/licenses/by-nc/4.0/>

Country/Territory of origin: China

ORCID number: Miao-Miao Wang 0009-0001-7601-4818; Xiu-Qing An 0009-0001-3161-0528; Jin-Ping Chai 0000-0001-8873-1323; Jin-Yu Yang 0000-0001-6376-9835; Ji-De A 0000-0003-4478-1972; Xiang-Ren A 0000-0002-0305-996X.

S-Editor: Li L

L-Editor: A

P-Editor: Cai YX

REFERENCES

- Wang TP, Cao ZG. Current status of echinococcosis control in China and the existing challenges. *Zhongguo Jishengchongxue Yu Jishengchongbing Zazhi* 2018; **36**: 291-296
- Bayrak M, Altintas Y. Current approaches in the surgical treatment of liver hydatid disease: single center experience. *BMC Surg* 2019; **19**: 95 [PMID: 31315619 DOI: 10.1186/s12893-019-0553-1]
- Mihmanli M, Idiz UO, Kaya C, Demir U, Bostanci O, Omeroglu S, Bozkurt E. Current status of diagnosis and treatment of hepatic echinococcosis. *World J Hepatol* 2016; **8**: 1169-1181 [PMID: 27729953 DOI: 10.4254/wjh.v8.i28.1169]
- Wen H, Xu MQ. Applied hydatid disease. Beijing: Science Press, 2007
- Committee of Hydatid Surgery, Society of Surgeons. Expert consensus on diagnosis and treatment of hepatic cystic and alveolar echinococcosis (2019 edition). *Zhonghua Xiaohua Waike Zazhi* 2019; **18**: 711-721 [DOI: 10.3760/cma.j.issn.1673-9752.2019.08.002]
- Wen H, Vuitton L, Tuxun T, Li J, Vuitton DA, Zhang W, McManus DP. Echinococcosis: Advances in the 21st Century. *Clin Microbiol Rev* 2019; **32** [PMID: 30760475 DOI: 10.1128/CMR.00075-18]
- Kern P, Menezes da Silva A, Akhan O, Müllhaupt B, Vizcaychipi KA, Budke C, Vuitton DA. The Echinococcoses: Diagnosis, Clinical Management and Burden of Disease. *Adv Parasitol* 2017; **96**: 259-369 [PMID: 28212790 DOI: 10.1016/bs.apar.2016.09.006]

- 8 **Wang XQ**, Hang XM, Tian QS, Zhao SY, A JD. Hepatic cystic and alveolar echinococcosis co-infections: a report of 3 cases. *Zhongguo Xuexicheongbing Fangzhi Zazhi* 2020; **32**: 213-216 [DOI: [10.16250/j.32.1374.2019091](https://doi.org/10.16250/j.32.1374.2019091)]
- 9 **Wu JG**. Surgical strategies and significance of HIP2 expression for abdominal wall invasion of gastrointestinal cancer. Doctoral dissertations, Shanghai Jiaotong University School, 2019 [DOI: [10.27307/d.cnki.gsjtu.2019.000328](https://doi.org/10.27307/d.cnki.gsjtu.2019.000328)]
- 10 **Chinese Society of Hernia and Abdominal Wall Surgery**, Chinese Society of Hernia and Abdominal Wall Surgery; Chinese Medical Doctor Association. Guidelines for diagnosis and treatment of abdominal wall incisional hernia (2018 edition). *Zhonghua Waike Zazhi* 2018; **56**: 499-502 [DOI: [10.3760/cma.j.issn.0529-5815.2018.07.003](https://doi.org/10.3760/cma.j.issn.0529-5815.2018.07.003)]



Published by **Baishideng Publishing Group Inc**
7041 Koll Center Parkway, Suite 160, Pleasanton, CA 94566, USA

Telephone: +1-925-3991568

E-mail: office@baishideng.com

Help Desk: <https://www.f6publishing.com/helpdesk>

<https://www.wjgnet.com>

