

## Diagnosis and management of primary sclerosing cholangitis-perspectives from a therapeutic endoscopist

Kunjam Modha, Udayakumar Navaneethan

Kunjam Modha, Udayakumar Navaneethan, Digestive Disease Institute, the Cleveland Clinic, Cleveland, OH 44195, United States

Udayakumar Navaneethan, Center for Interventional Endoscopy, Florida Hospital, Orlando, FL 32803, United States

**Author contributions:** Modha K contributed to study concept and paper preparation; Navaneethan U contributed to study concept, design, paper preparation and critical revisions.

**Supported by** Research Grants from the Inflammatory Bowel Disease Working Group and the American College of Gastroenterology (to Navaneethan U).

**Conflict-of-interest:** Navaneethan U has received fees for serving as a speaker, and an advisory board member for AbbVie.

**Open-Access:** This article is an open-access article which was selected by an in-house editor and fully peer-reviewed by external reviewers. It is distributed in accordance with the Creative Commons Attribution Non Commercial (CC BY-NC 4.0) license, which permits others to distribute, remix, adapt, build upon this work non-commercially, and license their derivative works on different terms, provided the original work is properly cited and the use is non-commercial. See: <http://creativecommons.org/licenses/by-nc/4.0/>

**Correspondence to:** Udayakumar Navaneethan, MD, FACP, Center for Interventional Endoscopy, Florida Hospital, 601 E Rollins Street, Orlando, FL 32803, United States. [udhaykumar81@gmail.com](mailto:udhaykumar81@gmail.com)

**Telephone:** +1-216-5020981

**Fax:** +1-216-4446305

**Received:** July 14, 2014

**Peer-review started:** July 14, 2014

**First decision:** November 14, 2014

**Revised:** January 6, 2015

**Accepted:** January 18, 2015

**Article in press:** January 20, 2015

**Published online:** April 18, 2015

in the diagnosis and management of PSC. In patients presenting with a cholestatic profile, endoscopic retrograde cholangiopancreatography (ERCP) is warranted for a definite diagnosis of PSC. Dominant strictures of the bile duct occur in 36%-57% of PSC patients. Endoscopic balloon dilatation with or without stenting have been employed in the management of dominant strictures. In addition, PSC patients are at increased risk of developing cholangiocarcinoma with a 20% lifetime risk. Brush cytology obtained during ERCP and use of fluorescence *in situ* hybridization forms the initial diagnostic step in the investigation of patients with dominant biliary strictures. Our review aims to summarize the current evidence supporting the role of a therapeutic endoscopist in the management of PSC patients.

**Key words:** Endoscopy; Therapeutic endoscopy; Primary sclerosing cholangitis; Bile; Dominant strictures

© The Author(s) 2015. Published by Baishideng Publishing Group Inc. All rights reserved.

**Core tip:** A therapeutic endoscopist plays a key role in the diagnosis and management of patients with primary sclerosing cholangitis (PSC). Endoscopic balloon dilation of dominant strictures with or without stenting is performed. Brush cytology obtained during endoscopic retrograde cholangiopancreatography and use of fluorescence *in situ* hybridization forms the initial diagnostic step in the investigation of patients with dominant biliary strictures. Our review aims to summarize the current evidence supporting the role of a therapeutic endoscopist in the management of PSC patients.

### Abstract

Primary sclerosing cholangitis (PSC) is a chronic, cholestatic liver condition characterized by inflammation, fibrosis, and destruction of the intra- and extrahepatic bile ducts. The therapeutic endoscopist plays a key role

Modha K, Navaneethan U. Diagnosis and management of primary sclerosing cholangitis-perspectives from a therapeutic endoscopist. *World J Hepatol* 2015; 7(5): 799-805 Available from: URL: <http://www.wjgnet.com/1948-5182/full/v7/i5/799.htm> DOI: <http://dx.doi.org/10.4254/wjh.v7.i5.799>

## INTRODUCTION

Primary sclerosing cholangitis (PSC) is a chronic, cholestatic liver condition characterized by inflammation, fibrosis, and destruction of the intra- and extrahepatic bile ducts. It tends to run an unpredictable course, although it slowly progresses to biliary cirrhosis and end-stage liver disease in a majority of patients<sup>[1]</sup>. PSC occurs more commonly in men and often presents in the third and fourth decades of life. There is no proven treatment for PSC and liver transplantation is the only intervention known to improve survival<sup>[1,2]</sup>. About 60%-80% patients have coexisting inflammatory bowel disease (IBD) most likely ulcerative colitis<sup>[3]</sup>. PSC remains a challenge because its etiology and pathogenesis are still largely unknown.

The therapeutic endoscopist is often consulted in the evaluation of a patient with abnormal liver function tests in the setting of IBD. The endoscopist is thus faced with the responsibility for diagnosing PSC in these patients. The endoscopist is also consulted when these patients develop worsening liver function tests on follow-up. Screening these patients for the development of dominant strictures and treating them constitutes the responsibility of a therapeutic endoscopist. In addition, cholangiocarcinoma (CCA) needs to be ruled out when evaluating dominant strictures. A therapeutic endoscopist plays an integral part in the diagnosis and management of PSC patients and the endoscopist forms an important pillar in the therapeutic armamentarium of patients with PSC.

In this review, we discuss the role of therapeutic endoscopist in the various clinical settings in the management of PSC patients including the diagnosis and management. We review the current literature and present our experience in a tertiary care center proposing the management algorithm for patients with PSC.

## DIAGNOSIS OF PSC

PSC is diagnosed based on typical cholestatic biochemical profile and visualization of the biliary tree. The characteristic cholangiographic findings include multifocal, short, annular strictures alternating with normal or slightly dilated segments producing a "beaded" pattern of multifocal strictures and segmental dilations<sup>[4]</sup>. Both intra and extra hepatic bile ducts are involved. Less than 25% patients have intra-hepatic disease alone. PSC confined to extrahepatic bile ducts is rare (< 5%). The gall bladder, cystic and pancreatic ducts may also be involved.

Contrary to several other liver disorders, liver biopsy has not been useful in the diagnosis of PSC. It fell out of favor for numerous reasons. The histological features seen on liver biopsy specimens of PSC patients are non-specific in most cases<sup>[5]</sup>. Periductal fibrosis or "onion skinning" which is considered pathognomonic for PSC is not commonly seen<sup>[5]</sup>. Besides, a study

aimed at assessing the progression of histological stages of PSC over time reported that biopsy findings could be patchy and that more than one histological stage could be present in a single liver at a given time thus indicating high sampling variability<sup>[6]</sup>. Although using prognostic models for PSC is discouraged<sup>[7]</sup>, it is important to know that none of the recent models developed for this purpose have included histological stage as one of its variables. Usefulness of liver biopsy, although limited, was emphasized in a study<sup>[8]</sup> that looked at 138 patients out of which 79 had a liver biopsy after the diagnosis of PSC. In 78/79 patients, liver biopsy did not provide additional information. In one patient, findings of autoimmune hepatitis led to modification in treatment. Thus, the role of liver biopsy lies in diagnosing other co-existent liver disorders as in overlap syndrome that could potentially lead to adoption of a different treatment approach. It is also useful in diagnosing small duct PSC in which by definition, the cholangiogram is normal.

Cholangiography has been the diagnostic modality of choice for visualization of the biliary tree. Endoscopic retrograde cholangiography (ERC) was long considered the gold standard for this. However, due to the invasive nature of the procedure and the risk of adverse events with ERC, magnetic resonance cholangiography (MRC) has been suggested as a safer alternative. One of the earliest studies<sup>[9]</sup> comprising of 73 patients examined the performance of MRC using ERC findings as the reference. It reported a diagnostic accuracy of 90% compared to 97% of ERC. A meta-analysis that compared 6 studies reported a high sensitivity of 86% and specificity of 94%. In addition, positive predictive value and negative predictive value were found to be 15.3 and 0.15 respectively<sup>[10]</sup>.

ERC and MRC have comparable diagnostic accuracy, although the visualization of bile ducts may not be optimal for all patients with MRC. In patients with early changes of PSC, MRC may miss the diagnosis and ERC still has to be performed to exclude PSC. Also, in a large cohort of patients with PSC who had ERC performed in our institution, the overall risk of adverse events was very low at 4.3% including both diagnostic and therapeutic ERC<sup>[11]</sup>. Although MRC is recommended as the initial imaging test for diagnosis of PSC, ERC is required in patients with non diagnostic MRC and for therapeutic intervention on bile duct strictures. We follow the similar protocol in our institution and perform MRC as the first step and ERC as the next step even for diagnosis of PSC when MRC is normal or non-diagnostic. We will discuss the role of the advanced endoscopist in the management of PSC patients.

## THE DOMINANT STRICTURE

The presence of worsening symptoms in patients with PSC typically warrants investigation to exclude a dominant extrahepatic biliary stricture. A "dominant stricture" has been defined as a stenosis with a

diameter of 1.5 mm in the common bile duct or of 1 mm in the hepatic duct<sup>[12]</sup>. Dominant or major bile duct stenoses have a prevalence of 36%-57%<sup>[12]</sup>. It has been recommended that right upper quadrant pain, jaundice, pruritus, cholangitis are all acceptable indications for initiating treatment. High bilirubin level, presence of a common bile duct stricture and any dominant stricture have been found to be predictors of successful outcomes with clinical and laboratory improvement after endoscopic retrograde cholangiopancreatography (ERCP)<sup>[13]</sup>. This may help in the selection of patients more likely to benefit from an ERCP than those without these features in whom conservative management can be pursued. Endoscopic balloon dilatation with or without stenting have been used. The efficacy of these techniques were analyzed recently<sup>[14]</sup>. The effect of ursodeoxycholic acid with or without endoscopic therapy on survival has been difficult to ascertain due to the retrospective nature of these studies. One of the earliest small studies<sup>[15]</sup> that analyzed effects of endoscopic balloon dilatation in 12 symptomatic patients noted improvements in serum bilirubin, alkaline phosphatase and average radiographic stricture score, all results being statistically significant. On the other hand, another study<sup>[16]</sup> that analyzed outcomes after operative and non operative management of biliary strictures found that difference in bilirubin levels in 54 out of 146 patients who received endoscopic balloon dilation with or without stenting was not significant. Most patients in this study received percutaneous stenting. Moreover, none of the patients with serum bilirubin level of 5 mg/dL or higher was found to have a decrease in their level at 1 year. Some studies<sup>[17-19]</sup> have attempted to emphasize the prognostic value of cholangiographic findings. Intrahepatic strictures seem to have a poor prognosis<sup>[18,19]</sup>. This would theoretically go against therapeutic intervention on extrahepatic strictures. Definite indications and ideal candidates for therapeutic endoscopy remain to be elucidated in future long term outcome studies.

The search for an ideal endoscopic treatment has been ongoing for several years. A retrospective study<sup>[20]</sup> of 71 patients had found no significant difference between those patients who received endoscopic dilation alone vs those who received stenting in addition to dilation in achieving improvement in cholestasis. It found a significantly higher rate of complications and cholangitis in the stent group. It was suggested that the group that received both dilation and stenting possibly represented a cohort with more severe disease as stenting was only done when dilatation alone did not achieve adequate biliary drainage<sup>[21]</sup>. Besides, half of the stents were placed percutaneously and the authors reported a significantly higher rate of complications with percutaneous placement of stents as compared to the endoscopic approach. A randomized control study comparing short term stent therapy and balloon dilatation of dominant strictures is currently under way and is estimated to be completed in 2015 ([www.clinicaltrials.gov](http://www.clinicaltrials.gov)) (NCT01398917) and will hopefully answer the question of the right approach to dominant strictures. Also, plastic stents have been reported to be the best approach for intervening on benign dominant extrahepatic biliary strictures<sup>[22]</sup>.

Favorable outcomes have been reported with endoscopic therapy. A group of authors reported a positive long term outcome with repeated endoscopic dilations in 171 patients that were followed for 20 years with a survival rate of 81% at 5 years and 52% at 10 years<sup>[23]</sup>. Short term stenting up to 11 d was found to have a lower rate of complications of cholangitis/ jaundice (7% vs 50%) while producing significant effects in symptom reduction and biochemical resolution of cholestasis<sup>[24]</sup>. These complications were attributed to stent occlusion. The same authors found that 81% of patients in the short term stent group remained asymptomatic over a 19 mo follow up period with zero recurrence of clinical/biochemical cholestasis<sup>[25]</sup>. Similar results in favor of short term stent therapy were reported with regards to amelioration of symptoms and biochemical cholestasis with 80% of patients remaining re-intervention free at the end of 1 year<sup>[26]</sup>. One study aimed at assessing a survival benefit of endoscopic treatment of strictures reported a 5 year survival that was significantly ( $P = 0.027$ ) higher than the predicted 5-year survival as calculated by the Mayo risk score<sup>[27]</sup>. The authors suggested that these results only be used as indirect evidence. Other studies have supported this finding<sup>[28,29]</sup>.

A study<sup>[11]</sup> that retrospectively studied 129 patients did not find a difference in bilirubin and alkaline phosphatase levels between those with dominant strictures and those without. Patients with small duct PSC which by definition has a normal cholangiogram was not found to have bilirubin and alkaline phosphatase levels different from those with large duct PSC<sup>[30,31]</sup>. Studies that randomize patients with dominant strictures to endoscopic and non endoscopic therapy are needed to clarify this and are lacking at this time.

It is important to note that in premalignant conditions like PSC, risk of cancer would likely increase with longer duration of the disease. However, there are several caveats to generalizing this. If endoscopic treatment of biliary strictures in some way abates ongoing inflammation, this may delay cancer development or offset it. Secondly, newer methods at cancer detection as discussed below along with increased awareness of the nature of cancer progression in dominant strictures probably results in early diagnosis of CCA causing lead-time bias in survival studies involving endoscopic therapy<sup>[27]</sup>. Thus, the same study<sup>[27]</sup> that reported the survival benefit of endoscopic treatment did not find an increased frequency of cancer. Similarly, another multi-center case-control study<sup>[32]</sup> did not find that duration of PSC incurred an increase in CCA incidence.

Regardless of endoscopic treatment, dominant strictures have been found to carry a poor prognosis in general. A prospective study<sup>[33]</sup> that followed 171

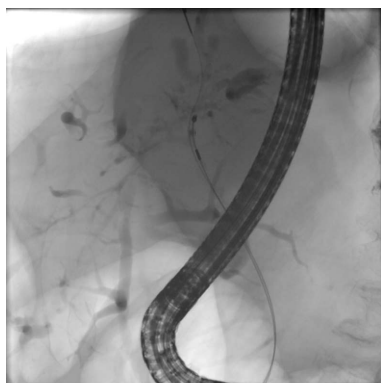


Figure 1 Brushing of a left hepatic duct dominant stricture for cytology.

patients for 20 years reported a reduced liver transplant free survival in those with dominant stenoses (25%) compared to those without (73.1%) ( $P = 0.011$ ) at 18 years. Additionally, a study<sup>[34]</sup> found the presence of dominant stenoses when accompanied with IBD to be associated with an increased risk of carcinomas including biliary, gall bladder and colorectal malignancies as compared to those without coexisting IBD. The survival in the former group was also reported to be reduced but with a weaker statistical significance ( $P = 0.045$ ). It is important to know that all but one patient with dominant stenoses in this study had strictures treated endoscopically. Another study<sup>[35]</sup> that followed 128 patients with PSC reported several important findings. A proportion of the 128 patients with PSC also underwent liver biopsies and patients with dominant stenoses had a more advanced stage of PSC on histology than those without. Survival was reduced in patients with dominant stenoses (13%) as compared to those without (23%). These studies suggest that patients with dominant stenoses may represent a sicker group of people with a worse outcome. Also, it appeared that development of CCA was mainly responsible for this finding. After excluding those patients with CCA, the survival difference ceased to be statistically significant. All of the CCA developed in patients with dominant stenoses and none developed in those without dominant stenoses ( $P < 0.001$ ). Close to half of these cancers occurred within 4 mo of diagnosis of PSC. In addition, CCA in PSC has an extremely poor prognosis with a median survival of 5 mo<sup>[36]</sup>. This not only emphasizes the need for early detection of these strictures, ideally at the time of diagnosis but also underlines the importance of adequate differentiation of benign from malignant strictures.

In our experience, we do not routinely place stents in PSC patients at the time of ERCP. Balloon dilation alone is preferred. In patients in whom the strictures are refractory or in patients with cholangitis, we place stents on a short term basis and will remove the stents within 10-14 d. We also recommend oral antibiotics for a minimum of 5 d after dilatation and/or stenting to reduce the risk for cholangitis. With this protocol,

we have published our experience on the role of ERCP in PSC patients in our institution. The overall risk of adverse events was low at 4.7% and cholangitis was still the most common adverse event.

## SCREENING FOR CCA

The risk of developing CCA in PSC patients after 10 years and 20 years is 9% and 19% respectively<sup>[37]</sup>. Thus a therapeutic endoscopist plays a key role in screening/surveillance for CCA in patients with PSC who have dominant strictures. Guidelines for screening/surveillance are not concrete but tumor markers and imaging modalities have been proposed. A cut off value of cancer antigen 19-9 (CA19-9) of  $> 130$  U/mL in symptomatic patients has a sensitivity and specificity of 79% and 98% respectively<sup>[38]</sup>. A study that followed 230 patients over 6 years reported sensitivity of ultrasound, computed tomography, magnetic resonance imaging (MRI) as 57%, 75% and 63% respectively when imaging alone was considered. The positive predictive value of ERCP, magnetic resonance cholangiopancreatography (MRCP) and MRCP + MRI was 23%, 21% and 23% respectively<sup>[39]</sup>. Bile duct brushings have been routinely employed for tissue sampling during ERCP (Figure 1). Studies on the utility of bile duct brushings in the diagnosis of CCA have reported a wide range of results. A meta-analysis performed by us found a high specificity of 97% but only a modest sensitivity of 43% across 54 studies<sup>[40]</sup>. Further studies using special cytology techniques have been done which have shown promising results in augmenting the sensitivity of brush cytology tissue specimens.

One such technique is fluorescence *in situ* hybridization (FISH). It detects chromosomal abnormalities with the help of fluorescent labeled DNA. Aneuploidy or abnormalities in the number of chromosomes in a cell is seen in a majority of cancers. Aneuploidy causes chromosomal instability that may lead to carcinogenesis by lending the cells the ability to expand incessantly<sup>[41]</sup>. Patients with CCA associated with PSC have a higher (80%) prevalence of DNA aneuploidy than those with PSC and without CCA (12%)<sup>[42]</sup>. A study that analyzed 86 strictures in PSC patients using different techniques reported a higher sensitivity of FISH as compared to routine cytology in diagnosing malignant pancreaticobiliary strictures with a somewhat lower specificity<sup>[43]</sup>. These results were also reproduced in another report of 131 patients. FISH had a higher sensitivity (34%) than conventional cytology (15%) ( $P < 0.01$ )<sup>[44]</sup>. In a small proportion of patients who do not have a discrete mass on imaging and in whom equivocal cytology results are obtained, a high (CA 19-9 level  $> 129$  mg/dL) along with presence of FISH polysomy highly predicts the risk of malignancy<sup>[45]</sup>. Also, all FISH abnormalities do not predict risk of cancer. This was also concluded in another study in which patients with tetrasomy and trisomy abnormalities had similar clinical outcomes to patients with negative FISH results<sup>[46]</sup>.



**Table 1 Screening for cholangiocarcinoma: Performance characteristics of different tests**

	Sensitivity (%)	Specificity (%)	PPV	NPV
CA19-9 <sup>[38]</sup>	79	98	56	99
Ultrasound <sup>[39]</sup>	57	94	48	95
CT <sup>[39]</sup>	75	80	38	95
MRI <sup>[39]</sup>	63	79	40	91
Bile duct brushings <sup>[40]</sup>	43	97	78	87
FISH <sup>[47]</sup>	68	70	-	-
FISH polysomy <sup>[47]</sup>	51	93	-	-
pCLE <sup>[54]</sup>	100	61	22	100
Cholangioscopy <sup>[56]</sup>	92	93	79	97
IDUS <sup>[55]</sup>	87	90	70	96

CA19-9: Cancer antigen 19-9; CT: Computed tomography; MRI: Magnetic resonance imaging; FISH: Fluorescence *in situ* hybridization; pCLE: Probe based confocal laser endomicroscopy; IDUS: Intraductal ultrasound; PPV: Positive predictive value; NPV: Negative predictive value.

Although earlier studies reported modest sensitivity and specificity of FISH, a meta-analysis conducted by us found modest sensitivity with a high specificity<sup>[47]</sup>. Thus, the sensitivity and accuracy of FISH in diagnosing CCA remains debatable. A study that followed 30 patients with serial polysomy testing found that only 18% of patients with follow up negative polysomy result developed CCA compared to 69% of those who had a subsequent positive polysomy test ( $P = 0.01$ )<sup>[48]</sup>. This highlights the limitations of the positive predictive values of a FISH testing.

Meanwhile, newer methods for improved detection of malignancy continue to emerge. These methods are based on clinicopathogenesis of cancers. Thus, one of the recent techniques relies on angiogenesis being an important component of cancer progression. Probe based confocal laser endomicroscopy (pCLE) detects neovascularization and abnormal vessels in biliary strictures. This method has been utilized in diagnosing gastrointestinal neoplasia<sup>[49]</sup> and has been recently applied to biliary malignancies. Studies<sup>[50-53]</sup> have reported sensitivity of pCLE ranging from 83%-98% and specificity of 33%-75%. However, a study<sup>[54]</sup> reported to be the first series studying pCLE in PSC patients analyzed 20 strictures and reported a sensitivity and negative predictive value of 100% with a somewhat lower specificity of 61%. Intraductal ultrasonography (IDUS) has been used to analyze dominant strictures in 40 PSC patients. IDUS was reported to be superior to ERC with regards to sensitivity (87.5% vs 62.5%,  $P = 0.05$ ), specificity (90.6% vs 53.1%,  $P < 0.001$ ), accuracy (90% vs 55%,  $P < 0.001$ ), positive predictive value (70% vs 25%,  $P < 0.001$ ), and negative predictive value (96.7% vs 85%,  $P = 0.049$ )<sup>[55]</sup>.

Peroral cholangioscopy has recently been employed in the approach to PSC patients<sup>[56]</sup>. A recent study that looked at 53 patients with PSC and dominant stenoses found a specificity of 93% compared to 51% for that of ERC ( $P < 0.001$ ) and negative predictive value of 98% compared to 84% to that of ERC ( $P = 0.025$ )<sup>[56]</sup>. A recent study<sup>[57]</sup> reported a sensitivity of

75%, specificity of 55% and negative predictive value of 92% in a subgroup of PSC patients. Narrow band imaging (NBI) has been used for better visualization of the mucosal surface by filtering light in the green and blue spectrums. A recent study<sup>[58]</sup> comprising a small number of patients found an increased biopsy rate when using NBI as a result of finding more suspicious lesions but did not lead to increased detection of dysplasia. More studies in this area are needed. Table 1 summarizes the various techniques used in the diagnosis of CCA in PSC patients.

Recently, we have studied bile aspirated at the time of ERCP in the surveillance for CCA. We have studied oxidized phospholipids and volatile organic compounds in bile to screen for CCA and found them to be clinically very useful<sup>[59,60]</sup>.

Our clinical experience is to do two sets of brushings, one for cytology and the other for FISH. In addition, we aspirate bile for ongoing research studies.

In conclusion, our review highlights the important role played by a therapeutic endoscopist in the diagnosis and management of PSC. As newer diagnostic and therapeutic interventions emerge, this role will continue to expand.

## REFERENCES

- 1 Navaaneethan U, Shen B. Hepatopancreatobiliary manifestations and complications associated with inflammatory bowel disease. *Inflamm Bowel Dis* 2010; **16**: 1598-1619 [PMID: 20198712 DOI: 10.1002/ibd.21219]
- 2 Gohlke F, Lohse AW, Dienes HP, Löhr H, Märker-Hermann E, Gerken G, Meyer zum Büschenfelde KH. Evidence for an overlap syndrome of autoimmune hepatitis and primary sclerosing cholangitis. *J Hepatol* 1996; **24**: 699-705 [PMID: 8835745 DOI: 10.1016/S0168-8278(96)80266-2]
- 3 Bambha K, Kim WR, Talwalkar J, Torgerson H, Benson JT, Therneau TM, Loftus EV, Yawn BP, Dickson ER, Melton LJ. Incidence, clinical spectrum, and outcomes of primary sclerosing cholangitis in a United States community. *Gastroenterology* 2003; **125**: 1364-1369 [PMID: 14598252 DOI: 10.1016/j.gastro.2003.07.011]
- 4 MacCarty RL, LaRusso NF, Wiesner RH, Ludwig J. Primary sclerosing cholangitis: findings on cholangiography and pancreatography. *Radiology* 1983; **149**: 39-44 [PMID: 6412283 DOI: 10.1148/radiology.149.1.6412283]
- 5 Lee YM, Kaplan MM. Primary sclerosing cholangitis. *N Engl J Med* 1995; **332**: 924-933 [PMID: 7877651 DOI: 10.1056/NEJM199504063321406]
- 6 Angulo P, Larson DR, Therneau TM, LaRusso NF, Batts KP, Lindor KD. Time course of histological progression in primary sclerosing cholangitis. *Am J Gastroenterol* 1999; **94**: 3310-3313 [PMID: 10566735 DOI: 10.1111/j.1572-0241.1999.01543.x]
- 7 Chapman R, Fevery J, Kalloo A, Nagorney DM, Boberg KM, Shneider B, Gores GJ. Diagnosis and management of primary sclerosing cholangitis. *Hepatology* 2010; **51**: 660-678 [PMID: 20101749 DOI: 10.1002/hep.23294]
- 8 Burak KW, Angulo P, Lindor KD. Is there a role for liver biopsy in primary sclerosing cholangitis? *Am J Gastroenterol* 2003; **98**: 1155-1158 [PMID: 12809842 DOI: 10.1111/j.1572-0241.2003.07401.x]
- 9 Angulo P, Pearce DH, Johnson CD, Henry JJ, LaRusso NF, Petersen BT, Lindor KD. Magnetic resonance cholangiography in patients with biliary disease: its role in primary sclerosing cholangitis. *J Hepatol* 2000; **33**: 520-527 [PMID: 11059855 DOI: 10.1034/j.1600-0641.2000.033004520.x]
- 10 Dave M, Elmunzer BJ, Dwamena BA, Higgins PD. Primary

- sclerosing cholangitis: meta-analysis of diagnostic performance of MR cholangiopancreatography. *Radiology* 2010; **256**: 387-396 [PMID: 20656832 DOI: 10.1148/radiol.10091953]
- 11 **Navaneethan U**, Jegadeesan R, Nayak S, Lourdasamy V, Sanaka MR, Vargo JJ, Parsi MA. ERCP-related adverse events in patients with primary sclerosing cholangitis. *Gastrointest Endosc* 2015; **81**: 410-419 [PMID: 25085336]
  - 12 **Björnsson E**, Lindqvist-Ottosson J, Asztely M, Olsson R. Dominant strictures in patients with primary sclerosing cholangitis. *Am J Gastroenterol* 2004; **99**: 502-508 [PMID: 15056092 DOI: 10.1111/j.1572-0241.2004.04106.x]
  - 13 **Enns R**, Eloubeidi MA, Mergener K, Jowell PS, Branch MS, Baillie J. Predictors of successful clinical and laboratory outcomes in patients with primary sclerosing cholangitis undergoing endoscopic retrograde cholangiopancreatography. *Can J Gastroenterol* 2003; **17**: 243-248 [PMID: 12704468]
  - 14 **Aljiffry M**, Renfrew PD, Walsh MJ, Laryea M, Molinari M. Analytical review of diagnosis and treatment strategies for dominant bile duct strictures in patients with primary sclerosing cholangitis. *HPB (Oxford)* 2011; **13**: 79-90 [PMID: 21241424 DOI: 10.1111/j.1477-2574.2010.00268.x]
  - 15 **Wagner S**, Gebel M, Meier P, Trautwein C, Bleck J, Nashan B, Manns MP. Endoscopic management of biliary tract strictures in primary sclerosing cholangitis. *Endoscopy* 1996; **28**: 546-551 [PMID: 8911801 DOI: 10.1055/s-2007-1005552]
  - 16 **Ahrendt SA**, Pitt HA, Kallou AN, Venbrux AC, Klein AS, Herlong HF, Coleman J, Lillemoe KD, Cameron JL. Primary sclerosing cholangitis: resect, dilate, or transplant? *Ann Surg* 1998; **227**: 412-423 [PMID: 9527065 DOI: 10.1097/00000658-199803000-00014]
  - 17 **Ponsioen CY**, Vrouenraets SM, Prawirodirdjo W, Rajaram R, Rauws EA, Mulder CJ, Reitsma JB, Heisterkamp SH, Tytgat GN. Natural history of primary sclerosing cholangitis and prognostic value of cholangiography in a Dutch population. *Gut* 2002; **51**: 562-566 [PMID: 12235081 DOI: 10.1136/gut.51.4.562]
  - 18 **Olsson RG**, Asztely MS. Prognostic value of cholangiography in primary sclerosing cholangitis. *Eur J Gastroenterol Hepatol* 1995; **7**: 251-254 [PMID: 7743307]
  - 19 **Craig DA**, MacCarty RL, Wiesner RH, Grambsch PM, LaRusso NF. Primary sclerosing cholangitis: value of cholangiography in determining the prognosis. *AJR Am J Roentgenol* 1991; **157**: 959-964 [PMID: 1927817 DOI: 10.2214/ajr.157.5.1927817]
  - 20 **Kaya M**, Petersen BT, Angulo P, Baron TH, Andrews JC, Gostout CJ, Lindor KD. Balloon dilation compared to stenting of dominant strictures in primary sclerosing cholangitis. *Am J Gastroenterol* 2001; **96**: 1059-1066 [PMID: 11316147 DOI: 10.1111/j.1572-0241.2001.03690.x]
  - 21 **Michaels A**, Levy C. Endoscopic and surgical management of primary sclerosing cholangitis. *Medscape J Med* 2008; **10**: 242 [PMID: 19099036]
  - 22 **Abu-Wasel B**, Keough V, Renfrew PD, Molinari M. Biliary stent therapy for dominant strictures in patients affected by primary sclerosing cholangitis. *Pathobiology* 2013; **80**: 182-193 [PMID: 23652282 DOI: 10.1159/000347057]
  - 23 **Gotthardt DN**, Rudolph G, Klöters-Plachky P, Kulaksiz H, Stiehl A. Endoscopic dilation of dominant stenoses in primary sclerosing cholangitis: outcome after long-term treatment. *Gastrointest Endosc* 2010; **71**: 527-534 [PMID: 20189511 DOI: 10.1016/j.gie.2009.10.041]
  - 24 **van Milligen de Wit AW**, van Bracht J, Rauws EA, Jones EA, Tytgat GN, Huibregtse K. Endoscopic stent therapy for dominant extrahepatic bile duct strictures in primary sclerosing cholangitis. *Gastrointest Endosc* 1996; **44**: 293-299 [PMID: 8885349 DOI: 10.1016/S0016-5107(96)70167-0]
  - 25 **van Milligen de Wit AW**, Rauws EA, van Bracht J, Mulder CJ, Jones EA, Tytgat GN, Huibregtse K. Lack of complications following short-term stent therapy for extrahepatic bile duct strictures in primary sclerosing cholangitis. *Gastrointest Endosc* 1997; **46**: 344-347 [PMID: 9351039 DOI: 10.1016/S0016-5107(97)70123-8]
  - 26 **Ponsioen CY**, Lam K, van Milligen de Wit AW, Huibregtse K, Tytgat GN. Four years experience with short term stenting in primary sclerosing cholangitis. *Am J Gastroenterol* 1999; **94**: 2403-2407 [PMID: 10483999 DOI: 10.1111/j.1572-0241.1999.01364.x]
  - 27 **Baluyut AR**, Sherman S, Lehman GA, Hoen H, Chalasani N. Impact of endoscopic therapy on the survival of patients with primary sclerosing cholangitis. *Gastrointest Endosc* 2001; **53**: 308-312 [PMID: 11231388 DOI: 10.1016/S0016-5107(01)70403-8]
  - 28 **Gluck M**, Cantone NR, Brandabur JJ, Patterson DJ, Bredfeldt JE, Kozarek RA. A twenty-year experience with endoscopic therapy for symptomatic primary sclerosing cholangitis. *J Clin Gastroenterol* 2008; **42**: 1032-1039 [PMID: 18580600 DOI: 10.1097/MCG.0b013e3181646713]
  - 29 **Stiehl A**, Rudolph G, Klöters-Plachky P, Sauer P, Walker S. Development of dominant bile duct stenoses in patients with primary sclerosing cholangitis treated with ursodeoxycholic acid: outcome after endoscopic treatment. *J Hepatol* 2002; **36**: 151-156 [PMID: 11830325 DOI: 10.1016/S0168-8278(01)00251-3]
  - 30 **Angulo P**, Maor-Kendler Y, Lindor KD. Small-duct primary sclerosing cholangitis: a long-term follow-up study. *Hepatology* 2002; **35**: 1494-1500 [PMID: 12029635 DOI: 10.1053/jhep.2002.33202]
  - 31 **Björnsson E**, Boberg KM, Cullen S, Fleming K, Clausen OP, Fausa O, Schrupf E, Chapman RW. Patients with small duct primary sclerosing cholangitis have a favourable long term prognosis. *Gut* 2002; **51**: 731-735 [PMID: 12377815 DOI: 10.1136/gut.51.5.731]
  - 32 **Chalasani N**, Baluyut A, Ismail A, Zaman A, Sood G, Ghalib R, McCashland TM, Reddy KR, Zervos X, Anbari MA, Hoen H. Cholangiocarcinoma in patients with primary sclerosing cholangitis: a multicenter case-control study. *Hepatology* 2000; **31**: 7-11 [PMID: 10613720 DOI: 10.1002/hep.510310103]
  - 33 **Rudolph G**, Gotthardt D, Klöters-Plachky P, Kulaksiz H, Rost D, Stiehl A. Influence of dominant bile duct stenoses and biliary infections on outcome in primary sclerosing cholangitis. *J Hepatol* 2009; **51**: 149-155 [PMID: 19410324 DOI: 10.1016/j.jhep.2009.01.023]
  - 34 **Rudolph G**, Gotthardt D, Kloeters-Plachky P, Rost D, Kulaksiz H, Stiehl A. In PSC with dominant bile duct stenosis, IBD is associated with an increase of carcinomas and reduced survival. *J Hepatol* 2010; **53**: 313-317 [PMID: 20472317 DOI: 10.1016/j.jhep.2010.02.030]
  - 35 **Chapman MH**, Webster GJ, Bannoo S, Johnson GJ, Wittmann J, Pereira SP. Cholangiocarcinoma and dominant strictures in patients with primary sclerosing cholangitis: a 25-year single-centre experience. *Eur J Gastroenterol Hepatol* 2012; **24**: 1051-1058 [PMID: 22653260 DOI: 10.1097/MEG.0b013e3283554bbf]
  - 36 **Rosen CB**, Nagorney DM, Wiesner RH, Coffey RJ, LaRusso NF. Cholangiocarcinoma complicating primary sclerosing cholangitis. *Ann Surg* 1991; **213**: 21-25 [PMID: 1845927 DOI: 10.1097/00000658-199101000-00004]
  - 37 **Claessen MM**, Vleggaar FP, Tytgat KM, Siersema PD, van Buuren HR. High lifetime risk of cancer in primary sclerosing cholangitis. *J Hepatol* 2009; **50**: 158-164 [PMID: 19012991 DOI: 10.1016/j.jhep.2008.08.013]
  - 38 **Levy C**, Lypm J, Angulo P, Gores GJ, Larusso N, Lindor KD. The value of serum CA 19-9 in predicting cholangiocarcinomas in patients with primary sclerosing cholangitis. *Dig Dis Sci* 2005; **50**: 1734-1740 [PMID: 16133981 DOI: 10.1007/s10620-005-2927-8]
  - 39 **Charatcharoenwitthaya P**, Enders FB, Halling KC, Lindor KD. Utility of serum tumor markers, imaging, and biliary cytology for detecting cholangiocarcinoma in primary sclerosing cholangitis. *Hepatology* 2008; **48**: 1106-1117 [PMID: 18785620 DOI: 10.1002/hep.22441]
  - 40 **Trikudanathan G**, Navaneethan U, Njei B, Vargo JJ, Parsi MA. Diagnostic yield of bile duct brushings for cholangiocarcinoma in primary sclerosing cholangitis: a systematic review and meta-analysis. *Gastrointest Endosc* 2014; **79**: 783-789 [PMID: 24140129 DOI: 10.1016/j.gie.2013.09.015]
  - 41 **Zhang F**, Zhao D, Wang S, Hong L, Li Q. Aneuploidy directly contribute to carcinogenesis by disrupting the asymmetric division of adult stem cells. *Med Hypotheses* 2007; **68**: 237-238 [PMID:

- 16890378 DOI: 10.1016/j.mehy.2006.06.007]
- 42 **Bergquist A**, Tribukait B, Glaumann H, Broomé U. Can DNA cytometry be used for evaluation of malignancy and premalignancy in bile duct strictures in primary sclerosing cholangitis? *J Hepatol* 2000; **33**: 873-877 [PMID: 11131447 DOI: 10.1016/S0168-8278(00)80117-8]
- 43 **Moreno Luna LE**, Kipp B, Halling KC, Sebo TJ, Kremers WK, Roberts LR, Barr Fritcher EG, Levy MJ, Gores GJ. Advanced cytologic techniques for the detection of malignant pancreaticobiliary strictures. *Gastroenterology* 2006; **131**: 1064-1072 [PMID: 17030177 DOI: 10.1053/j.gastro.2006.08.021]
- 44 **Kipp BR**, Stadheim LM, Halling SA, Pochron NL, Harmsen S, Nagorney DM, Sebo TJ, Therneau TM, Gores GJ, de Groen PC, Baron TH, Levy MJ, Halling KC, Roberts LR. A comparison of routine cytology and fluorescence in situ hybridization for the detection of malignant bile duct strictures. *Am J Gastroenterol* 2004; **99**: 1675-1681 [PMID: 15330900 DOI: 10.1111/j.1572-0241.2004.30281.x]
- 45 **Barr Fritcher EG**, Voss JS, Jenkins SM, Lingineni RK, Clayton AC, Roberts LR, Halling KC, Talwalkar JA, Gores GJ, Kipp BR. Primary sclerosing cholangitis with equivocal cytology: fluorescence in situ hybridization and serum CA 19-9 predict risk of malignancy. *Cancer Cytopathol* 2013; **121**: 708-717 [PMID: 23839915 DOI: 10.1002/cncy.21331]
- 46 **Bangarulingam SY**, Björnsson E, Enders F, Barr Fritcher EG, Gores G, Halling KC, Lindor KD. Long-term outcomes of positive fluorescence in situ hybridization tests in primary sclerosing cholangitis. *Hepatology* 2010; **51**: 174-180 [PMID: 19877179 DOI: 10.1002/hep.23277]
- 47 **Navaneethan U**, Njei B, Venkatesh PG, Vargo JJ, Parsi MA. Fluorescence in situ hybridization for diagnosis of cholangiocarcinoma in primary sclerosing cholangitis: a systematic review and meta-analysis. *Gastrointest Endosc* 2014; **79**: 943-950.e3 [PMID: 24360654 DOI: 10.1016/j.gie.2013.11.001]
- 48 **Barr Fritcher EG**, Kipp BR, Voss JS, Clayton AC, Lindor KD, Halling KC, Gores GJ. Primary sclerosing cholangitis patients with serial polysomy fluorescence in situ hybridization results are at increased risk of cholangiocarcinoma. *Am J Gastroenterol* 2011; **106**: 2023-2028 [PMID: 21844920 DOI: 10.1038/ajg.2011.272]
- 49 **Meining A**, Saur D, Bajbouj M, Becker V, Peltier E, Höfler H, von Weyhern CH, Schmid RM, Prinz C. In vivo histopathology for detection of gastrointestinal neoplasia with a portable, confocal miniprobe: an examiner blinded analysis. *Clin Gastroenterol Hepatol* 2007; **5**: 1261-1267 [PMID: 17689297 DOI: 10.1016/j.cgh.2007.05.019]
- 50 **Meining A**, Chen YK, Pleskow D, Stevens P, Shah RJ, Chuttani R, Michalek J, Slivka A. Direct visualization of indeterminate pancreaticobiliary strictures with probe-based confocal laser endomicroscopy: a multicenter experience. *Gastrointest Endosc* 2011; **74**: 961-968 [PMID: 21802675 DOI: 10.1016/j.gie.2011.05.009]
- 51 **Meining A**, Shah RJ, Slivka A, Pleskow D, Chuttani R, Stevens PD, Becker V, Chen YK. Classification of probe-based confocal laser endomicroscopy findings in pancreaticobiliary strictures. *Endoscopy* 2012; **44**: 251-257 [PMID: 22261749 DOI: 10.1055/s-0031-1291545]
- 52 **Giovannini M**, Bories E, Monges G, Pesenti C, Caillol F, Delperro JR. Results of a phase I-II study on intraductal confocal microscopy (IDCM) in patients with common bile duct (CBD) stenosis. *Surg Endosc* 2011; **25**: 2247-2253 [PMID: 21424206 DOI: 10.1007/s00464-010-1542-8]
- 53 **Caillol F**, Filoche B, Gaidhane M, Kahaleh M. Refined probe-based confocal laser endomicroscopy classification for biliary strictures: the Paris Classification. *Dig Dis Sci* 2013; **58**: 1784-1789 [PMID: 23314855 DOI: 10.1007/s10620-012-2533-5]
- 54 **Heif M**, Yen RD, Shah RJ. ERCP with probe-based confocal laser endomicroscopy for the evaluation of dominant biliary stenoses in primary sclerosing cholangitis patients. *Dig Dis Sci* 2013; **58**: 2068-2074 [PMID: 23475187 DOI: 10.1007/s10620-013-2608-y]
- 55 **Tischendorf JJ**, Meier PN, Schneider A, Manns MP, Krüger M. Transpapillary intraductal ultrasound in the evaluation of dominant bile duct stenoses in patients with primary sclerosing cholangitis. *Scand J Gastroenterol* 2007; **42**: 1011-1017 [PMID: 17613933 DOI: 10.1080/00365520701206761]
- 56 **Tischendorf JJ**, Krüger M, Trautwein C, Duckstein N, Schneider A, Manns MP, Meier PN. Cholangioscopic characterization of dominant bile duct stenoses in patients with primary sclerosing cholangitis. *Endoscopy* 2006; **38**: 665-669 [PMID: 16673310 DOI: 10.1055/s-2006-925257]
- 57 **Liu R**, Cox RN K, Siddiqui A, Feurer M, Baron T, Adler DG. Peroral cholangioscopy facilitates targeted tissue acquisition in patients with suspected cholangiocarcinoma. *Minerva Gastroenterol Dietol* 2014; **60**: 127-133 [PMID: 24780947]
- 58 **Azeem N**, Gostout CJ, Knipschild M, Baron TH. Cholangioscopy with narrow-band imaging in patients with primary sclerosing cholangitis undergoing ERCP. *Gastrointest Endosc* 2014; **79**: 773-779.e2 [PMID: 24206748]
- 59 **Navaneethan U**, Gutierrez NG, Venkatesh PG, Jegadeesan R, Zhang R, Jang S, Sanaka MR, Vargo JJ, Parsi MA, Feldstein AE, Stevens T. Lipidomic profiling of bile in distinguishing benign from malignant biliary strictures: a single-blinded pilot study. *Am J Gastroenterol* 2014; **109**: 895-902 [PMID: 24710507 DOI: 10.1038/ajg.2014.60]
- 60 **Navaneethan U**, Parsi MA, Lourdasamy V, Bhatt A, Gutierrez NG, Grove D, Sanaka MR, Hammel JP, Stevens T, Vargo JJ, Dweik RA. Volatile organic compounds in bile for early diagnosis of cholangiocarcinoma in patients with primary sclerosing cholangitis: a pilot study. *Gastrointest Endosc* 2015; **81**: 943-949.e1 [PMID: 25500329 DOI: 10.1016/j.gie.2014.09.041]

**P-Reviewer:** Gumerova A, Hara K, Kaya M, Kovacs SJ

**S-Editor:** Ji FF **L-Editor:** A **E-Editor:** Liu SQ





Published by **Baishideng Publishing Group Inc**

8226 Regency Drive, Pleasanton, CA 94588, USA

Telephone: +1-925-223-8242

Fax: +1-925-223-8243

E-mail: [bpgoffice@wjgnet.com](mailto:bpgoffice@wjgnet.com)

Help Desk: <http://www.wjgnet.com/esps/helpdesk.aspx>

<http://www.wjgnet.com>

