

Hyperammonemia-induced encephalopathy: A rare devastating complication of bariatric surgery

Michelle L Kromas, Omar Y Mousa, Savio John

Michelle L Kromas, Department of Anesthesiology, SUNY Upstate Medical University, Syracuse, NY 13210, United States
Omar Y Mousa, Savio John, Department of Medicine, SUNY Upstate Medical University, Syracuse, NY 13210, United States
Author contributions: Kromas ML and Mousa OY participated in patient care and initial evaluation, diagnosis, and follow-up of patient as described in report; Kromas ML, Mousa OY and John S analyzed the laboratory and imaging findings and conducted review of previous publications and wrote the paper.

Ethics approval: The case report was deemed to meet criteria for exemption from review by SUNY Upstate Medical University Institutional Review Board.

Informed consent: The patient provided informed verbal consent for inclusion in case report at time of discharge from hospital.

Conflict-of-interest: The authors including Michelle L Kromas, Omar Y Mousa, Savio John have no conflicts of interest to disclose including but not limited to receipt of research funding, fees for service as speakers, or owning shares or stocks in any organizations.

Open-Access: This article is an open-access article which was selected by an in-house editor and fully peer-reviewed by external reviewers. It is distributed in accordance with the Creative Commons Attribution Non Commercial (CC BY-NC 4.0) license, which permits others to distribute, remix, adapt, build upon this work non-commercially, and license their derivative works on different terms, provided the original work is properly cited and the use is non-commercial. See: <http://creativecommons.org/licenses/by-nc/4.0/>

Correspondence to: Omar Y Mousa, MD, Department of Medicine, SUNY Upstate Medical University, 750 East Adams Street, Syracuse, NY 13210, United States. omar.mousa@hotmail.com
Telephone: +1-315-4644480
Fax: +1-315-4644484

Received: December 16, 2014

Peer-review started: December 17, 2014

First decision: January 8, 2015

Revised: January 26, 2015

Accepted: March 16, 2015

Article in press: March 18, 2015

Published online: May 8, 2015

Abstract

The clinical manifestations of hyperammonemia are usually easily identifiable to the clinician when associated with liver disease and lead to prompt diagnosis and treatment. However, hyperammonemia-induced encephalopathy is rare in adults in the absence of overt liver disease, thus diagnosis is often delayed or missed leading to potentially life threatening complications. Without proper treatment, such patients can decompensate rapidly with poor outcomes including seizures, coma, and death. Early assessment of plasma ammonia levels in patients with normal hepatic function and characteristic symptoms of encephalopathy can lead to early intervention while investigating the underlying etiology. We describe a patient who presented with a 2-year progression of waxing and waning acute mental status changes after a Roux-en-Y gastric bypass surgery. He was found to have elevated ammonia level as well as orotic aciduria; results consistent with a urea cycle disorder. After consulting neurology as well as toxicology, he ultimately improved after dietary protein restriction, sodium benzoate and lactulose therapy. While rare, clinicians should have a high index of suspicion for late onset urea cycle disorders in symptomatic patients presenting with encephalopathy secondary to hyperammonemia.

Key words: Hyperammonemia; Urea cycle; Bariatric surgery; Encephalopathy; Hepatic

© The Author(s) 2015. Published by Baishideng Publishing Group Inc. All rights reserved.

Core tip: Encephalopathy secondary to hyperammonemia in the absence of hepatic dysfunction presents a diagnostic dilemma to many clinicians. As such, early and accurate diagnosis can be easily missed, leading to increased morbidity and mortality. We describe a case of adult onset urea cycle disorder presenting with encephalopathy after gastric bypass surgery.

Although this challenging diagnosis is rare, treatment is inexpensive and readily available. Thus early recognition and intervention can prevent the rapid decline that may occur if the diagnosis is unrecognized.

Kromas ML, Mousa OY, John S. Hyperammonemia-induced encephalopathy: A rare devastating complication of bariatric surgery. *World J Hepatol* 2015; 7(7): 1007-1011 Available from: URL: <http://www.wjgnet.com/1948-5182/full/v7/i7/1007.htm> DOI: <http://dx.doi.org/10.4254/wjh.v7.i7.1007>

INTRODUCTION

Obesity is a prevalent and challenging issue in healthcare, affecting more than 60% of the United States population and contributing to a myriad of other comorbidities. Gastric bypass surgery (GBS) has been offered as an effective treatment for morbid obesity with reported success rates of weight loss up to 60%-70% of excess body weight^[1,2]. However, GBS can be complicated by nutritional derangements and rare neurological manifestations, including encephalopathy^[3,4]. Carnitine deficiency has been implicated in hyperammonemia-induced encephalopathy in the setting of valproic acid use as well as GBS^[5-8]. Case reports have also unmasked ornithine transcarbamylase (OTC) deficiency in the setting of GBS^[9]. Our case presents hyperammonemic encephalopathy following GBS related to an underlying late onset urea cycle disorder (UCD).

The disposal of nitrogen in the body is based on ammonia conversion to urea. Complete or partial enzyme deficiencies in the process of ammonia conversion leads to UCD. Classical presentation of such disorders occurs in neonates who can develop neurological manifestations and fail to thrive. Interestingly, some patients with similar manifestations presented in adulthood. The mechanism was either related to partially deficient enzymes of the urea cycle (UC) or enzyme mutation that is provoked by a certain stressor.

CASE REPORT

A 56-year-old male patient was hospitalized with worsening neurological symptoms including tremors, confusion, ataxia, and labile emotions. He reported his recurrent neurologic symptoms that progressed over a 2-year period to his primary care physician. His symptoms started mildly within 2 mo of a Roux-en-Y GBS, which the patient underwent for morbid obesity without comorbidities. He was otherwise healthy with no previous substance abuse or exposure to toxins. Of note he had lost 20 pounds prior to the surgery with proper nutritional guidance and 108 pounds post-operatively. He sought multiple medical subspecialties for advice and was diagnosed with Parkinson's disease. He was treated with levodopa and he followed with a neurologist without improvement. His disabling symptoms continued to progress, mandating referral to the emergency room.

On physical examination he had tremors, ataxia, poor concentration and impaired memory. He developed general weakness that made him wheelchair-bound and dependent. Laboratory investigation and appropriate imaging studies reflected a UCD (Table 1). We managed our patient conservatively through the administration of lactulose and sodium benzoate as well as dietary modification, by providing foods low in protein. The symptoms of our patient improved gradually during his hospitalization. He specifically had resolution of confusion, ataxia, and tremors over a course of 1 wk following treatment initiation.

DISCUSSION

Ammonia is a usual component of the body fluids, which exists mainly as ammonium ion. Excess ammonia from the products of protein catabolism enters the UC in the liver for conversion into urea, prior to renal excretion^[10,11]. Abnormalities in this process can lead to hyperammonemia, which increases the entry of ammonia to the brain and leads to neurological disorders. This can be due to impaired hepatic function and portal hypertension, where an excess nitrogen load over saturates the capacity of liver metabolism and bypasses it *via* portosystemic shunting^[12]. Other causes of hyperammonemia include congenital UCD, Reye syndrome, as well as encephalopathies of metabolic or toxic natures. Hyperammonemia can be toxic with signs and symptoms that include: episodic irritability, vomiting, ataxia, mental retardation, and lethargy that can progress to alteration of consciousness and coma^[13,14].

Both acute and chronic hyperammonemia alters the brain neurotransmitter system. Acute hyperammonemia causes accumulation of glutamate extracellularly in the brain, which activates the N-methyl D-aspartate receptor, causing seizures. Chronic hyperammonemia leads to an increase in inhibitory neurotransmission *via* down regulation of glutamate receptors and increased GABAergic tone, causing deterioration of cognitive function and coma. Most cases of hyperammonemia in the pediatric population are due to enzyme defects in the UC. This includes deficiencies of N-acetylglutamate synthetase, carbamoyl phosphate synthetase I, ornithine transcarbamoylase, argininosuccinic acid synthetase, argininosuccinylase and arginase. Adults with partially deficient enzymes can have disease manifestations during stressful medical conditions such as postpartum stress, short bowel disease, parenteral nutrition with high nitrogen consumption, heart-lung transplantation, and gastrointestinal bleeding as discussed in previous reports^[15-18]. Previous reports suggested that encephalopathy secondary to hyperammonemia in the setting of UCD can be unmasked by GBS^[19,20]. Furthermore, the rapid weight loss that occurs in these patient's results in protein catabolism and a large nitrogen load, which can further contribute to the symptoms. The mechanism by which gastric bypass disturbs the function of UC and the disposal of ammonia in such patient populations is not

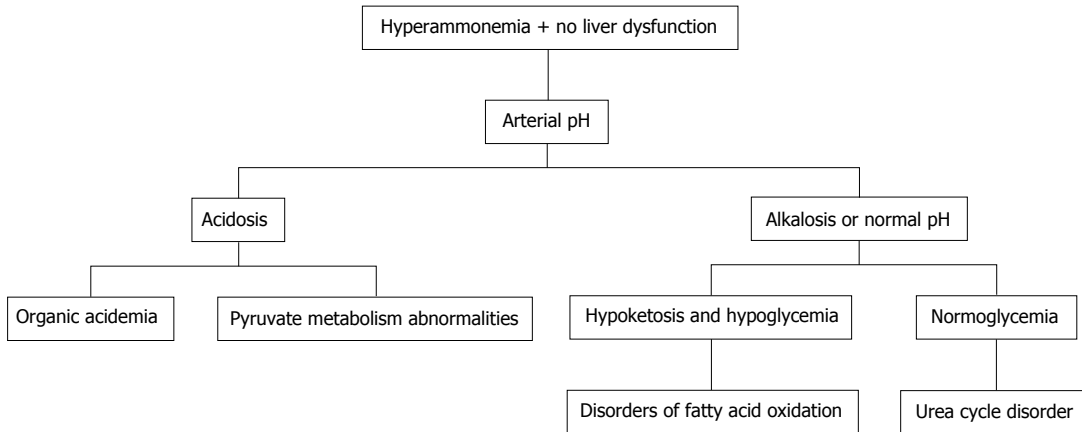


Figure 1 Algorithm for hyperammonemia workup in patients with normal hepatic panel. The arterial pH and blood glucose are among the initial tests to identify etiology of non-hepatic hyperammonemia.

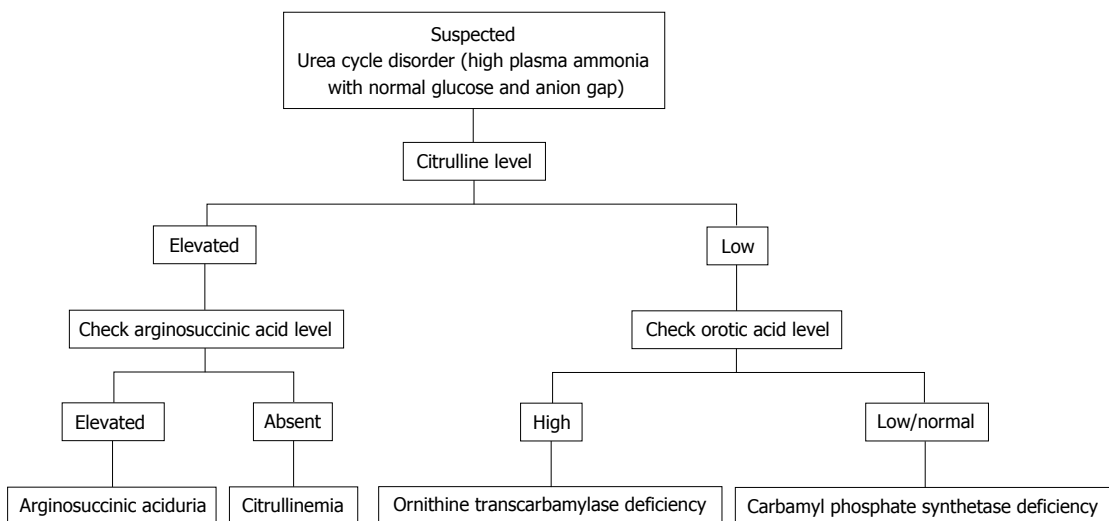


Figure 2 Algorithm of urea cycle disorder workup. Citrulline level, arginosuccinic acid level, and orotic acid level are the primary tests in the workup of urea cycle disorder.

Table 1 Laboratory investigations and imaging at time of hospitalization

Laboratory investigation/imaging	Values
BMP	Within normal limits (Cr 1.0 mg/dL)
CBC	Within normal limits (platelets 158 K/ μ L)
Iron panel	Within normal limits
Hepatic panel	AST 30 U/L ALT 9 U/L Alkaline phosphatase 52 U/L Total Bilirubin 0.9 mg/dL
Urine orotic acid	1.4 mmol/mol of creatinine
Ammonia level	155 mcg/dL
Carnitine level, zinc, manganese, vitamin B12, vitamin A, vitamin D	Within normal limits
Abdominal ultrasound	No evidence of liver disease or cirrhosis
MRI brain	No acute or chronic intracranial abnormalities

MRI: Magnetic resonance imaging; BMP: Basic metabolic panel; CBC: Complete blood count; AST: Aspartate aminotransferase; ALT: Alanine aminotransferase.

fully understood. Table 2 shows the different etiologies of hyperammonemia of non-hepatic origin.

Distinguishing features of UCD in neonates comprises critically elevated ammonia levels (> 1000 mmol/L), whereas other etiologies seldom present with ammonia levels greater than 200-300 mmol/L. In addition, UCD is suggested by normal blood glucose and anion gap, as well as respiratory alkalosis from central hyperventilation. The initial workup of a UCD should include glucose, electrolytes, amino acids, serum ammonia, lactate, urine organic acids, orotic acid and arterial blood gases looking for arterial pH and carbon dioxide. OTC gene mutations cannot be revealed by DNA analysis in up to 20% of patients with OTC deficiency. Therefore other lab measures may give an indication as to the etiology of hyperammonemia without a history of liver disease^[21]. The workup to identify the etiology of hyperammonemia of non-hepatic origin is outlined in Figure 1 and the workup to identify the UCD specifically is further outlined in Figure 2.

The management of hyperammonemia includes prevention of seizures and cerebral edema, medical

Table 2 Etiology of hyperammonemia of non-hepatic origin^[21]

Age	Category	Examples
Adults	Stressful events	-
	Partial enzyme deficiency	-
Pediatrics	Infection	Urinary tract infections (urease-producing organism, such as proteus mirabilis)
	Medications	Valproate
		Topiramate
		Salicylates such as aspirin
		Acetazolamide
		Zonisamide
		High-dose chemotherapy (5-fluorouracil)
	Infection	Urinary tract infections (urease-producing organism, such as proteus mirabilis)
	Organic acidemias	Isovalericacidemia, propionic acidemia, methylmalonicacidemia, glutaricacidemia type II, multiple carboxylase deficiency, beta-ketothiolase deficiency
	Congenital lactic acidosis	Pyruvate dehydrogenase deficiency
		Pyruvate carboxylase deficiency
		Mitochondrial disorders
	Fatty acid oxidation defects	Acyl CoA dehydrogenase deficiency
	Dibasic aminoacid transport defects	Systemic carnitine deficiency
		Lysinuric protein intolerance
	Miscellaneous	Hyperammonemia-hyperornithinemia-homocitrullinuria
		Transient hyperammonemia of the newborn asphyxia
		Reye syndrome
		Lactic acidosis

therapy to remove excess ammonia and dietary protein restriction. The medications used for treatment assist in offloading the UC by converting nitrogen to non-urea products that are easily excreted. These include sodium benzoate and arginine, followed by phenylacetate and phenylbutyrate. Our patient's cognitive impairment resolved after dietary protein withdrawal and implementation of medical therapy that included sodium benzoate and lactulose. He showed significant improvement over a period of one week following initiation of medical therapy.

A major proportion of the United States population is obese resulting in very high rates of annual bariatric surgeries. Even though it is rare for hyperammonemic encephalopathy to complicate GBS, it is yet more unusual for the etiology to be adult onset UCD. Such non-specific neurological presentation is a true diagnostic challenge especially when liver disease is absent, thus delaying the management plan, thus increasing associated morbidity and mortality.

Early diagnosis is crucial to prevent complications. Conservative management should include dietary modification with protein restriction. Patient satisfaction following GBS can be improved by educating these patients about the potential complications. Raising awareness among internists of this possible complication of GBS is also important and having a high index of suspicion for unmasked UCD post-GBS can prevent the debilitating consequences of unrecognized and untreated disease, improve its' outcomes as well as have a great impact on utilization of health care resources.

COMMENTS

Case characteristics

A 56-year-old male presents with progressive tremors, confusion, ataxia and

emotional lability.

Clinical diagnosis

The authors' patient was not oriented to place or time, demonstrated tremor and ataxia.

Differential diagnosis

Manganese toxicity, Parkinson's disease, hepatic encephalopathy.

Laboratory diagnosis

Basic metabolic panel, hepatic function panel, complete blood count, iron panel, carnitine level, zinc level, manganese, vitamin B12, vitamin A, and vitamin D levels were within normal limits. Ammonia level 155 mcg/dL and urine orotic acid 1.4 mmol/mol of creatinine.

Imaging diagnosis

Imaging of the abdomen was unremarkable.

Treatment

The authors administered lactulose, sodium benzoate and modified his diet.

Related reports

The physiology of adult onset urea cycle disorder is poorly understood and several case reports of similar occurrences have been cited in the case report presented by the authors.

Term explanation

All terms used in this case report are common and do not require further explanation.

Experiences and lessons

Hyperammonemia encephalopathy in the absence of overt liver disease identified on imaging and blood work, can be the result of non-hepatic etiology and should be thoroughly evaluated as described in this case report.

Peer-review

The authors have described the rare complication of non-hepatic hyperammonemia-induced encephalopathy in the setting of gastric bypass surgery that has not been well described in the literature. Furthermore, the article highlights the appropriate workup, differential diagnosis, and treatment for this clinical scenario.

REFERENCES

- 1 **Sugerman HJ**, Kellum JM, Engle KM, Wolfe L, Starkey JV, Birkenhauer R, Fletcher P, Sawyer MJ. Gastric bypass for treating severe obesity. *Am J Clin Nutr* 1992; **55**: 560S-566S [PMID: 1733127]
- 2 **Benotti PN**, Forse RA. The role of gastric surgery in the multidisciplinary management of severe obesity. *Am J Surg* 1995; **169**: 361-367

- [PMID: 7879845 DOI: 10.1016/S0002-9610(99)80177-9]
- 3 **Koffman BM**, Greenfield LJ, Ali II, Pirzada NA. Neurologic complications after surgery for obesity. *Muscle Nerve* 2006; **33**: 166-176 [PMID: 15973660 DOI: 10.1002/mus.20394]
 - 4 **Thaisethawatkul P**, Collazo-Clavell ML, Sarr MG, Norell JE, Dyck PJ. A controlled study of peripheral neuropathy after bariatric surgery. *Neurology* 2004; **63**: 1462-1470 [PMID: 15505166 DOI: 10.1212/01.WNL.0000142038.43946.06]
 - 5 **Hamer HM**, Knake S, Schomburg U, Rosenow F. Valproate-induced hyperammonemic encephalopathy in the presence of topiramate. *Neurology* 2000; **54**: 230-232 [PMID: 10636156 DOI: 10.1212/WNL.54.1.230]
 - 6 **Verrotti A**, Greco R, Morgese G, Chiarelli F. Carnitine deficiency and hyperammonemia in children receiving valproic acid with and without other anticonvulsant drugs. *Int J Clin Lab Res* 1999; **29**: 36-40 [PMID: 10356662 DOI: 10.1007/s005990050060]
 - 7 **Lokrantz CM**, Eriksson B, Rosén I, Asztely F. Hyperammonemic encephalopathy induced by a combination of valproate and pivmecillinam. *Acta Neurol Scand* 2004; **109**: 297-301 [PMID: 15016014 DOI: 10.1046/j.1600-0404.2003.00227.x]
 - 8 **Ohtani Y**, Endo F, Matsuda I. Carnitine deficiency and hyperammonemia associated with valproic acid therapy. *J Pediatr* 1982; **101**: 782-785 [PMID: 6813444 DOI: 10.1016/S0022-3476(82)80320-X]
 - 9 **Hu WT**, Kantarci OH, Merritt JL, McGrann P, Dyck PJ, Lucchinetti CF, Tippmann-Peikert M. Ornithine transcarbamylase deficiency presenting as encephalopathy during adulthood following bariatric surgery. *Arch Neurol* 2007; **64**: 126-128 [PMID: 17210820 DOI: 10.1001/archneur.64.1.126]
 - 10 **Wakabayashi Y**, Iwashima A, Yamada E, Yamada R. Enzymological evidence for the indispensability of small intestine in the synthesis of arginine from glutamate. II. N-acetylglutamate synthase. *Arch Biochem Biophys* 1991; **291**: 9-14 [PMID: 1929439 DOI: 10.1016/0003-9861(91)90097-3]
 - 11 **Windmueller HG**, Spaeth AE. Source and fate of circulating citrulline. *Am J Physiol* 1981; **241**: E473-E480 [PMID: 7325229]
 - 12 **Riordan SM**, Williams R. Treatment of hepatic encephalopathy. *N Engl J Med* 1997; **337**: 473-479 [PMID: 9250851 DOI: 10.1056/NEJM199708143370707]
 - 13 **Butterworth RF**. Effects of hyperammonaemia on brain function. *J Inher Metab Dis* 1998; **21** Suppl 1: 6-20 [PMID: 9686341 DOI: 10.1023/A:1005393104494]
 - 14 **Cooper AJ**. Role of glutamine in cerebral nitrogen metabolism and ammonia neurotoxicity. *Ment Retard Dev Disabil Res Rev* 2001; **7**: 280-286 [PMID: 11754523 DOI: 10.1002/mrdd.1039]
 - 15 **Summar ML**, Barr F, Dawling S, Smith W, Lee B, Singh RH, Rhead WJ, Sniderman King L, Christman BW. Unmasked adult-onset urea cycle disorders in the critical care setting. *Crit Care Clin* 2005; **21**: S1-S8 [PMID: 16227111 DOI: 10.1016/j.ccc.2005.05.002]
 - 16 **Panlaqui OM**, Tran K, Johns A, McGill J, White H. Acute hyperammonemic encephalopathy in adult onset ornithine transcarbamylase deficiency. *Intensive Care Med* 2008; **34**: 1922-1924 [PMID: 18651132 DOI: 10.1007/s00134-008-1217-2]
 - 17 **Schultz RE**, Salo MK. Under recognition of late onset ornithine transcarbamylase deficiency. *Arch Dis Child* 2000; **82**: 390-391 [PMID: 10799432 DOI: 10.1136/adc.82.5.390]
 - 18 **Yoshino M**, Nishiyori J, Yamashita F, Kumashiro R, Abe H, Tanikawa K, Ohno T, Nakao K, Kaku N, Fukushima H. Ornithine transcarbamylase deficiency in male adolescence and adulthood. *Enzyme* 1990; **43**: 160-168 [PMID: 2095337]
 - 19 **Fenves A**, Boland CR, Lepe R, Rivera-Torres P, Spechler SJ. Fatal hyperammonemic encephalopathy after gastric bypass surgery. *Am J Med* 2008; **121**: e1-e2 [PMID: 18187055 DOI: 10.1016/j.amjmed.2007.08.032]
 - 20 **Walker V**. Severe hyperammonaemia in adults not explained by liver disease. *Ann Clin Biochem* 2012; **49**: 214-228 [PMID: 22349554 DOI: 10.1258/acb.2011.011206]
 - 21 **Yamaguchi S**, Brailey LL, Morizono H, Bale AE, Tuchman M. Mutations and polymorphisms in the human ornithine transcarbamylase (OTC) gene. *Hum Mutat* 2006; **27**: 626-632 [PMID: 16786505 DOI: 10.1002/humu.20339]

P- Reviewer: Chiang TA, Galvao FFH, Zhong YS **S- Editor:** Tian YL

L- Editor: A **E- Editor:** Liu SQ





Published by **Baishideng Publishing Group Inc**

8226 Regency Drive, Pleasanton, CA 94588, USA

Telephone: +1-925-223-8242

Fax: +1-925-223-8243

E-mail: bpgoffice@wjgnet.com

Help Desk: <http://www.wjgnet.com/esps/helpdesk.aspx>

<http://www.wjgnet.com>

