

Metastatic recurrence to a solitary lymph node four years after hepatic lobectomy for primary hepatocellular carcinoma

Michael L Caparelli, Nathan J Roberts, Timothy S Braverman, Robert M Stevens, Edward R Broun, Shyam Allamaneni

Michael L Caparelli, Nathan J Roberts, Shyam Allamaneni, Department of Surgery, the Jewish Hospital, Cincinnati, OH 45236, United States

Timothy S Braverman, Department of Pathology, the Jewish Hospital, Cincinnati, OH 45236, United States

Robert M Stevens, Department of Radiology, the Jewish Hospital, Cincinnati, OH 45236, United States

Edward R Broun, Department of Oncology, Hematology Care, Inc., Cincinnati, OH 45236, United States

Author contributions: Caparelli ML wrote the paper; Caparelli ML, Roberts NJ and Allamaneni S designed the report and edited the content; Roberts NJ and Allamaneni S performed the operation; Braverman TS provided pathology report and micrographs; Stevens RM provided critical findings for imaging studies; Broun ER contributed intellectual discussion of the patient case; all members edited the report.

Institutional review board statement: This case report was exempt from the Institutional Review Board standards at the Jewish Hospital in Cincinnati.

Informed consent statement: The patient involved in this study gave her verbal consent authorizing use and disclosure of her protected health information.

Conflict-of-interest statement: All the authors have no conflicts of interest to declare.

Open-Access: This article is an open-access article which was selected by an in-house editor and fully peer-reviewed by external reviewers. It is distributed in accordance with the Creative Commons Attribution Non Commercial (CC BY-NC 4.0) license, which permits others to distribute, remix, adapt, build upon this work non-commercially, and license their derivative works on different terms, provided the original work is properly cited and the use is non-commercial. See: <http://creativecommons.org/licenses/by-nc/4.0/>

Manuscript source: Unsolicited manuscript

Correspondence to: Shyam Allamaneni, MD, Surgical Oncologist, Department of Surgery, the Jewish Hospital, 4777 E Galbraith Road, Cincinnati, OH 45236, United States. drallamaneni@gmail.com
Telephone: +1-513-6865392
Fax: +1-513-6865394

Received: March 14, 2016

Peer-review started: March 14, 2016

First decision: April 20, 2016

Revised: May 9, 2016

Accepted: July 14, 2016

Article in press: July 18, 2016

Published online: August 18, 2016

Abstract

This report describes a patient that developed recurrent metastatic hepatocellular carcinoma (HCC) to a supra-pancreatic lymph node four years after being treated for primary HCC *via* complete left hepatectomy. Metastatic HCC was proven by pathologic confirmation. The report addresses the role of surgical resection as a treatment modality for recurrent HCC to solitary lymph nodes. The role of biological chemotherapy as adjuvant treatment is also addressed.

Key words: Hepatocellular carcinoma; Lymph node; Recurrence; Metastatic; Extrahepatic

© **The Author(s) 2016.** Published by Baishideng Publishing Group Inc. All rights reserved.

Core tip: Recurrence of primary hepatocellular carcinoma to a solitary extracellular site is a rare occurrence, especially after complete hepatic lobectomy for the

primary tumor. In this report we describe a case of recurrence to a solitary suprapancreatic lymph node four years after initial resection. This is the only report to describe such a recurrence this long after the primary resection.

Caparelli ML, Roberts NJ, Braverman TS, Stevens RM, Broun ER, Allamaneni S. Metastatic recurrence to a solitary lymph node four years after hepatic lobectomy for primary hepatocellular carcinoma. *World J Hepatol* 2016; 8(23): 994-998 Available from: URL: <http://www.wjgnet.com/1948-5182/full/v8/i23/994.htm> DOI: <http://dx.doi.org/10.4254/wjh.v8.i23.994>

INTRODUCTION

Hepatocellular carcinoma (HCC) is the fifth most common cancer in the world, with the highest prevalence rates occurring in the eastern hemisphere. However, there has been a rise in prevalence in the Western hemisphere. It has been postulated that this pattern is due to higher incidence of hepatitis B and C virus seen outside of the United States^[1]. Tumor staging and strategies for treatment of HCC have been well described with current guidelines following the recommendations of the 2010 AHPBA/SSO/SSAT consensus conference on HCC^[2]. Current guidelines are primarily geared toward patients with primary resectable and non-resectable HCC. However, data is lacking with regard to the treatment of recurrent extrahepatic HCC. Systemic chemotherapy has proven to be of minimal benefit for patients with advanced, and recurrent extrahepatic HCC. There are current studies being conducted that support the use of multikinase inhibitors, including Sorafenib, as a viable option for patients with advanced and extrahepatic HCC^[3].

It is well known that the most common type of recurrence of HCC is intrahepatic. The most common sites for hematogenous spread are the lung, followed by the adrenal gland, and bone^[4]. Metastases of HCC to lymph nodes (LN) are quite rare. In one report that included a subset of Japanese patients who underwent hepatic resection, the prevalence of lymphatic involvement was as low as 2.2%^[5]. Another study showed that the 5-year survival rate for patients with lymph node metastasis is approximately 20%^[6]. There have been few reports describing metastasis to LN that have been treated with surgical resection, and their results have been varied^[7-11]. With this in mind, the importance of surgical resection of extrahepatic HCC recurrent to lymph nodes cannot be understated as a viable treatment modality. Interestingly, this is the first reported case where isolated lymph node metastasis has occurred greater than 3 years after initial hepatic resection. We describe a case of HCC recurrent to a solitary suprapancreatic lymph node treated by complete surgical resection.

CASE REPORT

The patient is a 67-year-old woman who presented with a suprapancreatic mass on magnetic resonance imaging (MRI). She initially presented 4 years prior with HCC of the left lobe of the liver measuring 10.8 cm × 7.4 cm × 9.5 cm. She was asymptomatic at the time of the discovery and the tumor was found due to imaging studies prior to a recent thoracic aortic aneurysm repair. Interestingly she did not have known risk factors for developing HCC such as cirrhosis, chronic hepatitis, tobacco use, diabetes, nonalcoholic fatty liver disease, hemochromatosis, or alpha-1 antitrypsin deficiency. Laboratory findings at that time showed a alpha fetoprotein (AFP) level of 119000 ng/mL. She subsequently underwent complete left hepatic lobectomy and had no complications post procedure. The patient was in remission for almost 4 years, but had a steady increase in AFP, 177-883 ng/mL, from year 3 to 4. Serial computed tomography (CT) imaging showed no evidence of recurrence over that time period. Subsequent MRI showed a soft tissue mass medial to the right hepatic lobe/porta hepatis measuring 4.6 cm × 5.6 cm (Figure 1). CT guided biopsy of the mass revealed a poorly differentiated malignant neoplasm, favoring HCC. The patient had no history of viral hepatitis, alcoholic liver disease, jaundice, abdominal pain, weight loss, chronic cough, bloody stools, bone pain, or any other signs to suggest metastatic disease. She was subsequently taken to the operating room for *en bloc* resection of a large suprapancreatic retroperitoneal mass, celiac and portal lymphadenectomy. Pathology showed the suprapancreatic mass to be consistent with HCC, high grade within a lymph node structure. Portal and celiac axis lymph nodes were negative for metastasis. Interestingly, immunohistochemical stains for the recurrent carcinoma showed not only tumor markers that confirm hepatocellular origin, but might suggest a more aggressive tumor - staining positive for cytokeratin 19 (CK19), glypican 3 (G3) and hepatocyte paraffin 1 (HP1). Microscopic pathologic figures are shown in Figures 2 and 3. The patient's post-operative course has been uncomplicated and at eight months post op she is disease free. Current AFP level is 2.2 ng/mL.

DISCUSSION

The recurrence of HCC can be classified as early or late phase^[12]. Early phase recurrence typically occurs within the first two years post-resection, and is related to aggressive features of the primary tumor such as high tumor grade, local invasion, and multifocal tumors. Late recurrence occurs more than two years after resection and is related to *de novo* tumor formation, typically in patients with cirrhotic liver disease. The fact that our patient recurred to an extrahepatic LN nearly four years post-surgery is remarkable, and of the first to be reported this late, post-resection. The initial tumor was without aggressive characteristics, as it was moderately

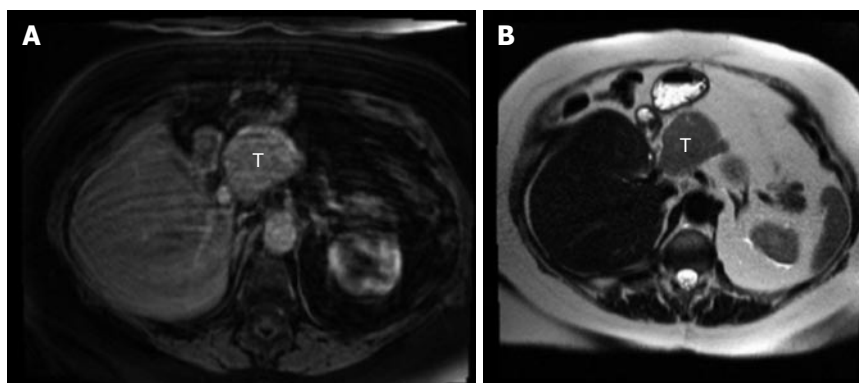


Figure 1 Suprapancreatic mass. The left panel (A) shows an axial post contrast T1 fat suppressed sequence that demonstrates an arterial phase enhancing mass medial to the liver; the right panel (B) shows an axial T2 HASTE sequence demonstrating a mass with increased T2 signal medial to the liver. T: Tumor.

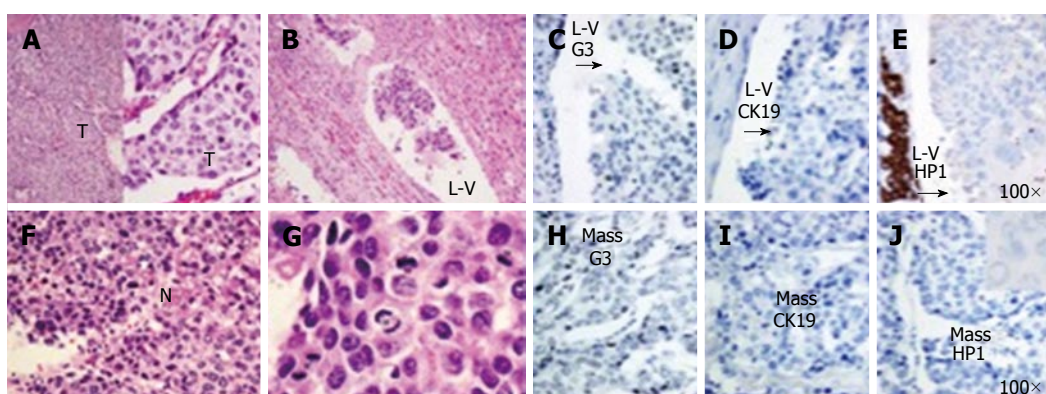


Figure 2 Initial hepatic lobectomy. On the left-hand set of H and E-stained quarter panel images, the upper left two-image combination quarter panel (A) shows the trabecular architecture, the trabeculae as "T"; the upper right H and E quarter panel (B) shows L-V; the lower H and E quarter panels show high power views of solid pattern tumor with focal geographic necrosis [lower left (F) as "N"] and numerous mitoses [lower right (G) with "M" times 4]; on the right-hand set of IHC-stained split full-height images, the mass, along the bottom (H-J) show negative G3 (H), CK19 (I), HP1 (J); the L-V, along the top (C-E) with a similar pattern, but with weak but convincing HP1 positivity. Both HP1 stains are inset with 100 × high power images (100 ×). Arrows on the L-V IHC (C and D) stains indicate the tumor (opposite vessel wall). L-V: Lymph-vascular tumor; Mass: Main mass; LN: Lymph node; G3: Glypican 3; CK19: Cytokeratin 19; HP1: Hepatocyte paraffin 1; T: Tumor.

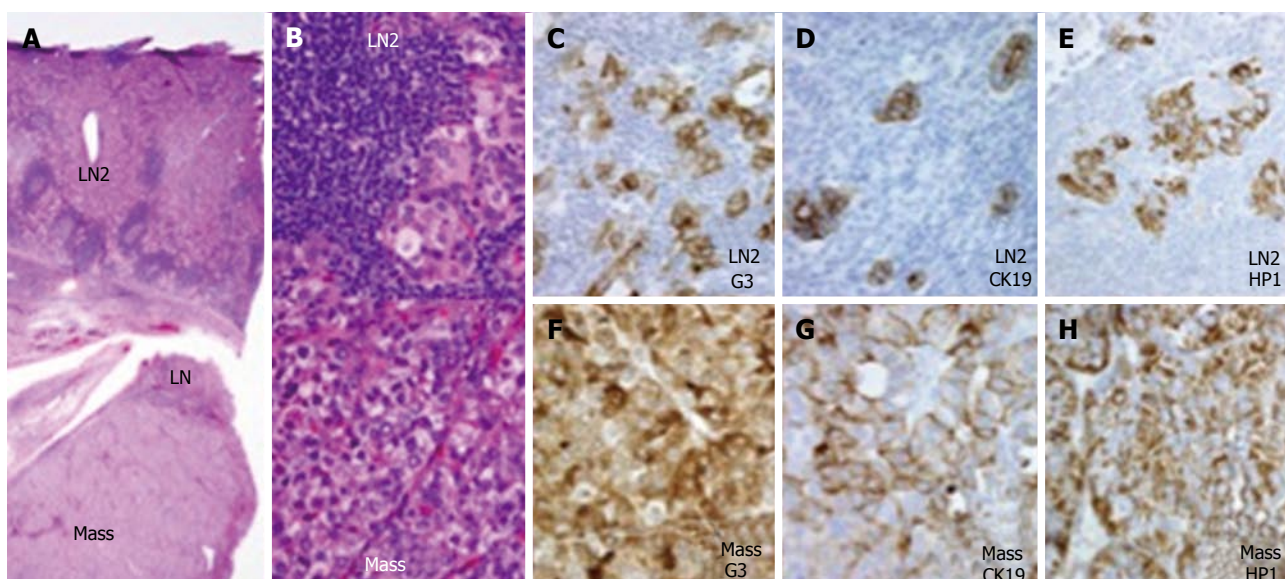


Figure 3 Resected recurrence. A: The H and E-stained shows a tiny area of likely LN at one end; B: Shows obvious tumor cells nests; On the right-hand set of IHC stained split full-height images, both the main mass (F-H); and obvious nodal tumor (LN2) (C-E), are strongly positive on G3 (C), CK19 (D), and HP1 (E) stains. Mass: Main mass; LN: Lymph node; G3: Glypican 3; CK19: Cytokeratin 19; HP1: Hepatocyte paraffin 1.

differentiated and without local invasion. Additionally, the initial tumor stained negative for CK19, G3 and was only weakly positive for HP1 in the lympho-vascular invasive sample as seen in Figure 1. Interestingly, the recurrent tumor was positive for these three biomarkers, suggesting hepatocellular origin and a more aggressive tumor^[13]. Clonal selection, therapeutic selection, or possibly both may explain this finding.

LN status is essential to the staging of cancers, including HCC. The presence of LN metastasis is associated with poorer survival and higher risk of tumor recurrence^[4]. Although the most common intra- and extra-hepatic recurrence is to liver and lung respectively, metastases to LNs are not that uncommon. There have been two reports that showed LN metastases in 28% and 25% of autopsied cases of HCC, respectively^[14,15]. However, a more recent study of surgical patients in Japan showed only 2.2% LN involvement in patients that underwent hepatic resection^[5]. This discrepancy may be due to the fact that more advanced HCC cases that are more likely to have extrahepatic metastases are less likely to undergo resection. This finding illuminates the importance LN dissection in hepatic surgery. LN dissection is not the current standard when performing hepatic resection for HCC. In a study by Ercolani *et al.*^[16] the role of lymphadenectomy was addressed. In 40 patients with HCC the incidence of LN metastases was 7.5%. It was also found that the most common site of LN metastases from HCC is the hepatic pedicle node, followed by the retropancreatic space, and common hepatic artery station. The authors concluded that regional lymphadenectomy is a safe procedure after liver resection; however, this is yet to become common practice.

Several case reports have been published on the findings of metastatic HCC to LNs^[7-11]. Patients in these reports often had cirrhosis, and all but one of these patients underwent resection with varied short-term survival results. One report described a patient with a solitary suprapancreatic LN metastasis that underwent pancreaticoduodenectomy and had reported disease free survival for 27 mo. Another patient with LN metastases to two paraaortic mediastinal LNs underwent complete resection, but had recurrence and died 13 mo later^[10]. It is reasonable to argue liver disease, and multiple LN involvement may be factors for worse prognosis post LN resection.

Our patient appears to be an excellent candidate for resection, as she had a solitary LN, and is without cirrhotic, viral or alcoholic liver disease. In addition, adjuvant treatment with sorafenib - an oral multikinase inhibitor that has been shown to suppress tumor growth and angiogenesis by inhibiting the Raf/MEK/ERK signaling pathway and receptor kinases, such as VEGFR-1, VEGFR-2, VEGFR-3, and PDGFR β - should be considered^[3]. Sorafenib was shown to increase survival in patients with advanced HCC in the SHARP (Sorafenib HCC Assessment Randomized Protocol) trial. However, data is lacking on whether this multikinase inhibitor is useful in the

treatment of recurrent extrahepatic HCC. One recent study showed that the therapeutic effect of sorafenib was comparable in advanced HCC with or without extra-hepatic metastasis^[3]. It may be beneficial to initiate adjuvant treatment in patients with recurrent LN involvement, but further studies need to be performed prior to this becoming standard.

COMMENTS

Case characteristic

A 67-year-old woman who presented with a suprapancreatic mass on magnetic resonance imaging (MRI). The patient was asymptomatic at the time of presentation. Imaging studies were performed because of increased serum alpha fetoprotein levels led to increase suspicion for recurrence of primary hepatocellular carcinoma (HCC) resected four years prior.

Clinical diagnosis

The patient was asymptomatic at the time of presentation.

Differential diagnosis

Recurrent primary HCC, metastatic cancer, reactive lymphadenopathy, primary tumor of unknown origin, lymphoma.

Laboratory diagnosis

Elevated alpha fetoprotein level of 883 ng/mL.

Imaging diagnosis

MRI showed a soft tissue mass medial to the right hepatic lobe/porta hepatis measuring 4.6 cm \times 5.6 cm.

Pathological diagnosis

HCC, high grade within a lymph node structure.

Treatment

Surgical resection of lesion.

Related reports

HCC is a primary liver cancer. HCC typically does not recur to an extrahepatic solitary lymph node after primary resection.

Term explanation

HCC is a primary liver cancer. It is the fifth most common human cancer worldwide.

Experiences and lessons

Surgical resection of HCC recurrence to a solitary lymph node is a viable option and may also be curative. Long term follow-up of this patient will further illuminate the possibility of cure.

Peer-review

An interesting case presentation with a long period disease-free up to 4 years. It should be benefit to the knowledge of the hepatologists and keep in mind for the importance of clinical follow-up after extensive hepatectomy.

REFERENCES

- 1 **Chen KW**, Ou TM, Hsu CW, Horng CT, Lee CC, Tsai YY, Tsai CC, Liou YS, Yang CC, Hsueh CW, Kuo WH. Current systemic treatment of hepatocellular carcinoma: A review of the literature. *World J Hepatol* 2015; 7: 1412-1420 [PMID: 26052386 DOI: 10.4254/wjh.v7.i10.1412]
- 2 **Munene G**, Vauthey JN, Dixon E. Summary of the 2010 AHPBA/

- SSO/SSAT Consensus Conference on HCC. *Int J Hepatol* 2011; **2011**: 565060 [PMID: 21994863 DOI: 10.4061/2011/565060]
- 3 **Nakano M**, Tanaka M, Kuromatsu R, Nagamatsu H, Tajiri N, Satani M, Niizeki T, Aino H, Okamura S, Iwamoto H, Shimose S, Shirono T, Koga H, Torimura T. Sorafenib for the treatment of advanced hepatocellular carcinoma with extrahepatic metastasis: a prospective multicenter cohort study. *Cancer Med* 2015; **4**: 1836-1843 [PMID: 26471348 DOI: 10.1002/cam4.548]
- 4 **Katyal S**, Oliver JH, Peterson MS, Ferris JV, Carr BS, Baron RL. Extrahepatic metastases of hepatocellular carcinoma. *Radiology* 2000; **216**: 698-703 [PMID: 10966697 DOI: 10.1148/radiology.216.3.r00se24698]
- 5 **Liver Cancer Study Group of Japan**. Primary liver cancer in Japan. Clinicopathologic features and results of surgical treatment. *Ann Surg* 1990; **211**: 277-287 [PMID: 2155591]
- 6 **Xiaohong S**, Huikai L, Feng W, Ti Z, Yunlong C, Qiang L. Clinical significance of lymph node metastasis in patients undergoing partial hepatectomy for hepatocellular carcinoma. *World J Surg* 2010; **34**: 1028-1033 [PMID: 20174806 DOI: 10.1007/s00268-010-0400-0]
- 7 **Shoji F**, Shirabe K, Yano T, Maehara Y. Surgical resection of solitary cardiophrenic lymph node metastasis by video-assisted thoracic surgery after complete resection of hepatocellular carcinoma. *Interact Cardiovasc Thorac Surg* 2010; **10**: 446-447 [PMID: 20022882 DOI: 10.1510/icvts.2009.225284]
- 8 **Taniai N**, Yoshida H, Mamada Y, Mizuguchi Y, Fujihira T, Akimaru K, Tajiri T. A case of recurring hepatocellular carcinoma with a solitary Virchow's lymph node metastasis. *J Nippon Med Sch* 2005; **72**: 245-249 [PMID: 16113497 DOI: 10.1272/jnms.72.245]
- 9 **Kurokawa T**, Yamazaki S, Moriguchi M, Aoki M, Watanabe Y, Higaki T, Takayama T. Resection of solitary metachronous lymph node metastasis from hepatocellular carcinoma following transarterial chemotherapy with cisplatin: a case report. *Anticancer Res* 2011; **31**: 3991-3993 [PMID: 22110232]
- 10 **Utsumi M**, Matsuda H, Sadamori H, Shinoura S, Umeda Y, Yoshida R, Satoh D, Hashimoto M, Yagi T, Fujiwara T. Resection of metachronous lymph node metastases from hepatocellular carcinoma after hepatectomy: report of four cases. *Acta Med Okayama* 2012; **66**: 177-182 [PMID: 22525476]
- 11 **Ueda J**, Yoshida H, Mamada Y, Taniai N, Mineta S, Yoshioka M, Kawano Y, Shimizu T, Hara E, Kawamoto C, Kaneko K, Uchida E. Surgical resection of a solitary para-aortic lymph node metastasis from hepatocellular carcinoma. *World J Gastroenterol* 2012; **18**: 3027-3031 [PMID: 22736929 DOI: 10.3748/wjg.v18.i23.3027]
- 12 **Colecchia A**, Schiumerini R, Cucchetti A, Cescon M, Taddia M, Marasco G, Festi D. Prognostic factors for hepatocellular carcinoma recurrence. *World J Gastroenterol* 2014; **20**: 5935-5950 [PMID: 24876717 DOI: 10.3748/wjg.v20.i20.5935]
- 13 **Feng J**, Zhu R, Chang C, Yu L, Cao F, Zhu G, Chen F, Xia H, Lv F, Zhang S, Sun L. CK19 and Glypican 3 Expression Profiling in the Prognostic Indication for Patients with HCC after Surgical Resection. *PLoS One* 2016; **11**: e0151501 [PMID: 26977595 DOI: 10.1371/journal.pone.0151501]
- 14 **Edmondson HA**, Steiner PE. Primary carcinoma of the liver: a study of 100 cases among 48,900 necropsies. *Cancer* 1954; **7**: 462-503 [PMID: 13160935]
- 15 **Anthony PP**. Hepatocellular carcinoma: an overview. *Histopathology* 2001; **39**: 109-118 [PMID: 11493326]
- 16 **Ercolani G**, Grazi GL, Ravaioli M, Grigioni WF, Cescon M, Gardini A, Del Gaudio M, Cavallari A. The role of lymphadenectomy for liver tumors: further considerations on the appropriateness of treatment strategy. *Ann Surg* 2004; **239**: 202-209 [PMID: 14745328 DOI: 10.1097/01.sla.0000109154.00020.e0]

P- Reviewer: Chetty R, Chiu KW, Delladetsima IK, Mihaila RG, Pan JJ, Zhu X **S- Editor:** Qiu S **L- Editor:** A **E- Editor:** Li D





Published by **Baishideng Publishing Group Inc**

8226 Regency Drive, Pleasanton, CA 94588, USA

Telephone: +1-925-223-8242

Fax: +1-925-223-8243

E-mail: bpgoffice@wjgnet.com

Help Desk: <http://www.wjgnet.com/esps/helpdesk.aspx>

<http://www.wjgnet.com>

