

# World Journal of *Gastrointestinal Pathophysiology*

*World J Gastrointest Pathophysiol* 2023 January 22; 14(1): 1-11



**MINIREVIEWS**

- 1 Growth hormone and gastrointestinal malignancy: An intriguing link

*Palui R, Sridharan K, Kamalanathan S, Sahoo J, Naik D*

## Contents

*World Journal of Gastrointestinal Pathophysiology*

**Bimonthly Volume 14 Number 1 January 22, 2023**

### ABOUT COVER

Editorial Board Member of *World Journal of Gastrointestinal Pathophysiology*, José E Manautou, PhD, Chairman, Professor, Department of Pharmaceutical Sciences, University of Connecticut, Storrs, CT 06269, United States. jose.manautou@uconn.edu

### AIMS AND SCOPE

The primary aim of the *World Journal of Gastrointestinal Pathophysiology* (WJGP, *World J Gastrointest Pathophysiol*) is to provide scholars and readers from various fields of gastrointestinal pathophysiology with a platform to publish high-quality basic and clinical research articles and communicate their research findings online.

WJGP mainly publishes articles reporting research results and findings obtained in the field of gastrointestinal pathophysiology and covering a wide range of topics including disorders of the esophagus, stomach and duodenum, small intestines, pancreas, biliary system, and liver.

### INDEXING/ABSTRACTING

The WJGP is now abstracted and indexed in PubMed, PubMed Central, Reference Citation Analysis, China National Knowledge Infrastructure, China Science and Technology Journal Database, and Superstar Journals Database.

### RESPONSIBLE EDITORS FOR THIS ISSUE

**Production Editor:** Yi-Xuan Cai; **Production Department Director:** Xu Guo; **Editorial Office Director:** Yun-Xiao Jiao Wu.

#### NAME OF JOURNAL

*World Journal of Gastrointestinal Pathophysiology*

#### ISSN

ISSN 2150-5330 (online)

#### LAUNCH DATE

April 15, 2010

#### FREQUENCY

Bimonthly

#### EDITORS-IN-CHIEF

Kusum K Kharbanda, Tsutomu Nishida, Somchai Amornyingtin

#### EDITORIAL BOARD MEMBERS

<https://www.wjgnet.com/2150-5330/editorialboard.htm>

#### PUBLICATION DATE

January 22, 2023

#### COPYRIGHT

© 2023 Baishideng Publishing Group Inc

#### INSTRUCTIONS TO AUTHORS

<https://www.wjgnet.com/bpg/gerinfo/204>

#### GUIDELINES FOR ETHICS DOCUMENTS

<https://www.wjgnet.com/bpg/gerinfo/287>

#### GUIDELINES FOR NON-NATIVE SPEAKERS OF ENGLISH

<https://www.wjgnet.com/bpg/gerinfo/240>

#### PUBLICATION ETHICS

<https://www.wjgnet.com/bpg/gerinfo/288>

#### PUBLICATION MISCONDUCT

<https://www.wjgnet.com/bpg/gerinfo/208>

#### ARTICLE PROCESSING CHARGE

<https://www.wjgnet.com/bpg/gerinfo/242>

#### STEPS FOR SUBMITTING MANUSCRIPTS

<https://www.wjgnet.com/bpg/gerinfo/239>

#### ONLINE SUBMISSION

<https://www.f6publishing.com>

© 2023 Baishideng Publishing Group Inc. All rights reserved. 7041 Koll Center Parkway, Suite 160, Pleasanton, CA 94566, USA

E-mail: [bpgoffice@wjgnet.com](mailto:bpgoffice@wjgnet.com) <https://www.wjgnet.com>



## Growth hormone and gastrointestinal malignancy: An intriguing link

Rajan Palui, Kalyani Sridharan, Sadishkumar Kamalanathan, Jayaprakash Sahoo, Dukhabandhu Naik

**Specialty type:** Gastroenterology and hepatology

**Provenance and peer review:** Invited article; Externally peer reviewed.

**Peer-review model:** Single blind

**Peer-review report's scientific quality classification**

Grade A (Excellent): 0  
Grade B (Very good): B  
Grade C (Good): C  
Grade D (Fair): 0  
Grade E (Poor): 0

**P-Reviewer:** Cozzi R, Italy;  
Sulbaran MN, Brazil

**Received:** November 16, 2022

**Peer-review started:** November 16, 2022

**First decision:** December 11, 2022

**Revised:** December 25, 2022

**Accepted:** January 17, 2023

**Article in press:** January 17, 2023

**Published online:** January 22, 2023



**Rajan Palui**, Department of Endocrinology, The Mission Hospital, Durgapur 713212, West Bengal, India

**Kalyani Sridharan**, Department of Endocrinology, All India Institute of Medical Science, Rishikesh 249203, Uttarakhand, India

**Sadishkumar Kamalanathan, Jayaprakash Sahoo, Dukhabandhu Naik**, Department of Endocrinology, Jawaharlal Institute of Postgraduate Medical Education and Research, Puducherry 605006, India

**Corresponding author:** Jayaprakash Sahoo, MD, DM, Additional Professor & Head, Department of Endocrinology, Jawaharlal Institute of Postgraduate Medical Education and Research, Room 5444, Fourth Floor, Super specialty Block, D. Nagar, Puducherry 605006, India.  
[jppgi@yahoo.com](mailto:jppgi@yahoo.com)

### Abstract

Growth hormone (GH) excess is associated with several systemic complications, one of which is the increased risk of neoplastic processes particularly of the gastrointestinal (GI) tract. Among the GI neoplasms, the most reported association is with benign and malignant neoplasms of the colon. In the majority of published literature, an increased incidence of GI neoplasms, both colonic adenomas as well as colorectal carcinoma is reported. However, the studies on colon cancer-specific mortality rate are conflicting with recent studies reporting similar cancer-specific mortality rates in comparison to controls. Many studies have reported an association of colorectal neoplasms with GH levels. Pathogenic mechanisms put forward to explain this association of GH excess and GI neoplasms primarily involve the increased GH-insulin-like growth factor 1 (IGF-1) signaling. Both GH and IGF-1 have proliferative, anti-apoptotic, and angiogenic effects on the systemic tissues leading to cellular proliferation. Other contributing factors to the increased risk of GI neoplasms include slow intestinal transit with a redundant large bowel, altered bile acids, deranged local immune response, shared genetic susceptibility factors and hyperinsulinemia. In view of the increased risk association, most guidelines for the care of acromegaly patients recommend an initial screening colonoscopy. Recommendations for further follow-up colonoscopy differ but broadly, the guidelines agree that it depends on the findings at first colonoscopy and state of remission of GH excess. Regarding the concern about the risk of colorectal cancers in patients receiving recombinant GH therapy, most cohort studies do not show an increased risk.

**Key Words:** Acromegaly; Colonoscopy; Colorectal carcinoma; Recombinant growth

hormone

©The Author(s) 2023. Published by Baishideng Publishing Group Inc. All rights reserved.

**Core Tip:** Growth hormone (GH) excess is associated with systemic complications including an increased risk of gastrointestinal (GI) neoplasms. Although most studies show an increased incidence of all GI neoplasms, most evidence is for increased colorectal adenomas and carcinomas. However, recent studies show similar colon cancer-specific mortality rates in acromegaly as compared to the general population. Screening guidelines for acromegaly recommend an initial colonoscopy in all patients with further follow-up recommended for patients with high risk. Most cohort studies do not report any increased risk of GI neoplasms for patients on recombinant GH therapy.

**Citation:** Palui R, Sridharan K, Kamalanathan S, Sahoo J, Naik D. Growth hormone and gastrointestinal malignancy: An intriguing link. *World J Gastrointest Pathophysiol* 2023; 14(1): 1-11

**URL:** <https://www.wjgnet.com/2150-5330/full/v14/i1/1.htm>

**DOI:** <https://dx.doi.org/10.4291/wjgp.v14.i1.1>

## INTRODUCTION

Physiologically, growth hormone (GH) is secreted from the anterior pituitary gland and produces its tissue mediator, insulin-like growth factor 1 (IGF-1) from the liver. The GH-IGF-1 duo have potential proliferative, anti-apoptotic, and angiogenetic effects on the systemic tissues. Acromegaly is a rare endocrine disorder of excessive GH production mostly from a pituitary adenoma[1]. As the disease is indolent and evolves very slowly, most of the patients suffer a significant diagnostic delay[2]. Due to this prolonged exposure to GH-IGF-1 excess, patients with acromegaly suffer from metabolic as well as systemic complications involving musculoskeletal, cardiovascular, respiratory, neurological and gastrointestinal (GI) systems[3]. Epidemiological data also suggest a higher prevalence of neoplastic complications in patients with acromegaly because of the proliferative action of GH and IGF-1[4]. Among the various neoplastic complications in acromegaly, tumors involving the GI system are well known.

The purpose of this review was to explore the various GI neoplasms reported in acromegaly as well as the pathophysiology behind it. The current updates regarding the screening of GI neoplasms in acromegaly have been discussed. The potential risk of GI neoplasia associated with therapeutic GH administration has also been reviewed.

## EPIDEMIOLOGY OF GI NEOPLASIA IN GH EXCESS

Among the GI neoplasms reportedly associated with GH excess (acromegaly), colorectal neoplasms are one of the most common. Apart from malignant neoplasms, the incidence of various benign neoplasms such as polyps are also reportedly associated with GH excess. In the following sections, the major studies that reported the risk of benign as well as malignant neoplasms of the GI tract are described.

### **Malignant colorectal neoplasm**

The increased risk of colorectal neoplasm in acromegaly was initially reported in the studies by Klein *et al*[5] and Ituarte *et al*[6]. Later, the majority of the published studies in patients with acromegaly reported higher incidences of colorectal neoplasms. In a nationwide population-based study from Sweden, a total of 1296 patients with acromegaly were included[7]. The incidence of colorectal and anal cancer was significantly increased in the acromegaly cohort (standardized incidence ratio [SIR] 1.5; 95% confidence interval [CI]: 1.0 to 2.2). Of the 28 reported cases of colorectal and anal carcinomas, two were neuroendocrine tumors. The incidence of benign colorectal and anal tumors was also significantly high in patients with acromegaly (SIR 2.3; 95%CI: 1.6 to 3.3). In another recent study from Argentina, the risk of colorectal neoplasms was compared between 70 patients with acromegaly and control population[8]. Although there was no significant increase in the risk of non-precancerous polyp ( $P = 0.69$ ) in patients with acromegaly, the risk of both advanced adenoma ( $P = 0.0006$ ) and colorectal carcinoma ( $P = 0.0063$ ) was significantly high. The increased risk of colorectal cancer (SIR 1.67; 95%CI: 1.07 to 2.58) was also reported in an Italian multicenter cohort study of 1512 patients with acromegaly[9]. In the subgroup analysis, the increased risk of colorectal cancer was found in female patients but not in male patients. In the largest study from the United States, cancer incidence was studied in 1041 men with acromegaly



[10]. The cancer risk of the overall digestive organ was increased (SIR 2.0; 95%CI: 1.3 to 2.9) including the colon (SIR 3.1; 95%CI: 1.7 to 5.1) in comparison to the control population. In a combined cohort from Sweden and Denmark, a total of 1634 patients with acromegaly were followed up for 10.3 years[11]. The risk of overall digestive organ cancers (SIR 2.1; 95%CI: 1.6 to 2.7) as well as colon (SIR 2.6; 95%CI: 1.6 to 3.8) and rectal cancers (SIR 2.5; 95%CI: 1.3 to 4.2) was increased. In a single center study of 140 patients with active acromegaly from Japan, the risk of colon cancer was reported to be as high as 17.4 (SIR) in females and 19.0 (SIR) in males[12]. In another small study of 19 patients with acromegaly from Japan, the authors reported a higher risk of colon cancer (odds ratio [OR] 9.8; 95%CI: 1.0 to 97.2) and colon adenoma (OR 4.2; 95%CI: 1.3 to 13.7) compared to the matched control population[13]. The risk of colon cancer was found to be significantly associated with high GH levels in this study. In a multicenter study from Italy, 233 patients of acromegaly were evaluated for the risk of colonic neoplasia[14]. The authors reported an increased risk of colon carcinoma (risk ratio [RR] 4.9; 95%CI: 1.1 to 22.4) in this study.

However, not all the studies had reported significantly increased risk of colorectal neoplasms in acromegaly patients. The risk of colorectal cancer was not significantly elevated (SIR 1.4; 95%CI: 0.7 to 2.6) in a cohort of 529 Danish acromegaly patients[15]. Similarly, the incidence of colorectal cancer was not significantly higher in the cohort of acromegaly patients from Poland and Germany[16,17]. In the nationwide cohort of Finnish acromegaly patients, the authors did not report any excess risk of colorectal cancer (SIR 1.9; 95%CI: 0.7 to 4.1)[18]. However, a trend of increased incidence of colorectal cancer (SIR 4.44, 95%CI: 0.91 to 13.0) was observed in acromegaly patients who responded poorly with treatment (posttreatment GH > 2.5 µg/L). In one of the largest cohorts of acromegaly patients from the United Kingdom, a non-significant trend of increased risk of colon cancer (SIR 1.67; 95%CI: 0.87 to 2.93;  $P = 0.06$ ) was reported[19]. However, no significant difference in the risk of rectal cancer (SIR 0.86; 95%CI: 0.23 to 2.20;  $P = 0.69$ ) had been reported in this study. The results of the major studies have been summarized in Table 1.

In the first meta-analysis by Renehan *et al*[20], which included only population-based studies, increased risk of colorectal cancer (RR 2.04; 95%CI: 1.32 to 3.14) in acromegaly was reported. In another meta-analysis that evaluated the risk of colorectal neoplasm in acromegaly, a total of 701 patients from nine studies was included[21]. The risk of colonic adenoma (OR 2.486; CI: 1.908 to 3.238) as well as colorectal carcinoma (OR 4.351; CI: 1.533 to 12.354) were found to be significantly higher in patients with acromegaly. In the most recent study by Dal *et al*[15], the authors evaluated cancer risk in patients of Danish acromegaly cohort as well as performed a meta-analysis to determine the cancer risk in patients with acromegaly. In this meta-analysis, a total of 9677 acromegaly patients from 23 studies were included. Among the cancers related with the GI tract, the risk of colorectal carcinoma (SIR 2.6; 95%CI: 1.7 to 4.0; 14 studies) and gastric carcinoma (SIR 2.0; 95%CI: 1.4 to 2.9) was found to be significantly increased in acromegaly patients. The risk of colorectal carcinomas was found to be elevated unequivocally in single center (SIR 7.3; 95%CI: 2.6 to 20.6), multicenter (SIR 2.0; 95%CI: 1.3 to 3.1) as well as in population based (SIR 2.2; 95%CI: 1.7 to 3.0) studies.

There is no consensus on whether the rate of colon cancer-specific mortality is increased in acromegaly. While the initial studies demonstrated an increased cancer-specific mortality rate, later studies did not corroborate these findings[10,22]. The study by Ritvonen *et al*[22] showed that although the overall standardized mortality rate was increased in acromegaly patients as compared to controls, cancer-specific mortality rate was similar. The overall cancer-related mortality due to GI cancer was not significantly increased (standardized mortality rate 1.3; 95%CI: 0.8-1.9) in the nationwide population-based study of acromegaly patients from Sweden[7].

### Other malignant GI neoplasms

Studies that reported an increased risk of GI neoplasms other than those of colorectal origin in acromegaly are sparse in the literature. In the nationwide study from Sweden, the risk of gastric carcinoma (SIR 1.7; 95%CI: 0.6 to 4.0;  $P = 0.35$ ) was not significantly higher in acromegaly patients[7]. A trend toward increased risk of gastric carcinoma (4 patients in acromegaly cohort *vs* 1.1 expected from population-based registry; SIR not calculated) in acromegaly patients was reported in the Danish acromegaly cohort[15]. Ron *et al*[10] had reported increased risk of gastric cancer (SIR 2.5; 95%CI: 0.8 to 6.0) in a cohort of acromegaly patients from the United States. The increased risk of pancreatic cancer (SIR 2.6; 95%CI: 1.0 to 5.3) was reported in a cohort of acromegaly patients from Sweden (subgroup analysis)[11]. Similarly, in the study from Sweden, a trend of increased risk of pancreatic cancer (SIR 2.1; 95%CI: 0.9 to 4.1;  $P = 0.082$ ) has also been reported[7]. In the combined cohort of acromegaly patients from Sweden and Denmark, increased risk of small intestine cancer (SIR 6.0; 95%CI: 1.2 to 17.4) was reported[11]. The risk of esophageal cancer (SIR 3.1; 95%CI: 1.3 to 6.0) was also found to be elevated in acromegaly patients[10].

### Benign GI neoplasms

Apart from increased risk of malignancy, a higher incidence of GI polyps was also reported in acromegaly patients. A high prevalence of colonic polyp (as high as 40%) has been reported in cohorts of acromegaly patients[12,23,24]. In the study by Gonzalez *et al*[25], a total of 165 acromegaly patients from Mexico were included who were evaluated by colonoscopy. The authors reported significantly increased risk of development of colonic polyps overall (RR 6.21; 95%CI: 4.04 to 9.48;  $P < 0.001$ ) as well

**Table 1 The risk of colorectal and gastrointestinal neoplasms in acromegaly: The major studies**

Ref.	Country	Colorectal cancer risk	Other GI cancer risk
Esposito <i>et al</i> [7], 2021	Sweden	SIR 1.5; 95%CI: 1.0 to 2.2	Stomach (SIR 1.7; 95%CI: 0.6 to 4.0); pancreas (SIR 2.1; 95%CI: 0.9 to 4.1)
Battistone <i>et al</i> [8], 2021	Argentina	5.7% <i>vs</i> 0% ( $P = 0.0063$ )	Advanced colorectal adenoma: 27.3% <i>vs</i> 7% ( $P = 0.0006$ )
Terzolo <i>et al</i> [9], 2017	Italy	SIR 1.67; 95%CI: 1.07 to 2.58	NA
Dal <i>et al</i> [15], 2018	Denmark	SIR 1.4; 95%CI: 0.7 to 2.6	NA
Wolinski <i>et al</i> [16], 2017	Poland	2% <i>vs</i> 0% ( $P = 0.14$ )	NA
Petroff <i>et al</i> [17], 2015	Germany	4 <i>vs</i> 6.6 ( $P = 0.43$ )	NA
Kauppien-Makelin <i>et al</i> [18], 2010	Finland	SIR 1.9; 95%CI: 0.7 to 4.1	NA
Kurimoto <i>et al</i> [12], 2008	Japan	Male: (SIR 19.0; 95%CI: 5.18 to 48.64); female: (SIR 17.4; 95%CI: 4.74 to 44.55)	NA
Matano <i>et al</i> [13], 2005	Japan	OR 9.8; 95%CI: 1.0 to 97.2	NA
Terzolo <i>et al</i> [14], 2005	Italy	RR 4.9 (95%CI: 1.1 to 22.4).	NA
Baris <i>et al</i> [11], 2002	Sweden and Denmark	Colon (SIR 2.6; 95%CI: 1.6 to 3.8); rectum (SIR 2.5; 95%CI: 1.3 to 4.2)	Overall digestive system (SIR 2.1; 95%CI: 1.6 to 2.7); small intestine (SIR 6.0; 95%CI: 1.2 to 17.4)
Orme <i>et al</i> [19], 1998	United Kingdom	Colon cancer (SIR 1.67; 95%CI: 0.87 to 2.93, $P = 0.06$ ); rectal cancer (SIR 0.86; 95%CI: 0.23 to 2.20, $P = 0.69$ )	NA
Ron <i>et al</i> [10], 1991	United States	Colon (SIR 3.1; 95%CI: 1.7 to 5.1)	Overall digestive system (SIR 2.0; 95%CI: 1.3 to 2.9); esophagus (SIR 3.1; 95%CI: 1.3 to 6.0); stomach (SIR 2.5; 95%CI: 0.8 to 6.0)

CI: Confidence interval; GI: Gastrointestinal; NA: Not available; OR: Odds ratio; RR: Risk ratio; SIR: Standardized incidence rate.

as both adenomatous (RR 4.86; 95%CI: 2.5 to 9.92;  $P < 0.001$ ) and non-adenomatous colonic polyps (RR 4.85; 95%CI: 2.18-8.81;  $P < 0.001$ ). Majority of the polyps were located in descending colon and recto-sigmoid colon. High serum IGF-1 level was significantly associated with development of colonic polyps. In a study from Turkey, an increased risk of colonic polyps overall (OR 2.04, 95%CI: 1.2 to 3.47;  $P = 0.012$ ) and hyperplastic colonic polyps (OR 3.04, 95%CI: 1.4 to 6.6) were reported in acromegaly patients [26]. Higher IGF-1, male sex, and older age were associated with an increased risk of polyp. However, the prevalence of adenomatous polyp was not significantly different in acromegaly patients in comparison to control population. In another study from Turkey, where 66 acromegaly patients were compared with matched controls, a significantly higher risk of colorectal polyps was reported in acromegaly patients (OR: 3.191, 95%CI: 1.25 to 8.13)[27]. In these patients, 72% of the polyps were found at the rectosigmoid colon. In another recent study from Japan, which evaluated 178 acromegaly patients, significantly higher colorectal polyps were detected in patients with acromegaly compared to controls (66.8% *vs* 24.2%;  $P < 0.001$ )[28]. Moreover, the polyps were larger in size and mostly located in rectosigmoid colon in acromegaly patients. Agarwal *et al*[29] had also reported increased risk of colonic polyp (10.6% *vs* 0.8%) in a cohort of 47 Indian acromegaly patients. In the study by Matano *et al*[13], a high risk of hyperplastic polyps (OR 8.3; 95%CI: 2.1 to 3.27) in acromegaly patients has been reported. The authors also reported a possible association with high GH levels. In a multicenter study from Italy, Terzolo *et al*[14] also reported elevated risk of benign adenomatous polyps (RR 1.7; 95%CI: 1.1 to 2.5) in acromegaly patients. In the meta-analysis by Rokkas *et al*[21], a total of 573 acromegaly patients from seven studies were included to evaluate the risk of colonic polyps. The authors reported higher risk of hyperplastic polyp (OR 3.557; 95%CI: 2.587 to 4.891) in the pooled analysis.

Increased prevalence of small bowel polyps has also been reported in a study from Mexico, which used capsule endoscopy for detection of polyps in 61 acromegaly patients[30]. All of the detected polyps in acromegaly patients were pedunculated and located in the jejunum. Ronchi *et al*[31] also evaluated the risk of small bowel polyps in 18 acromegaly patients using the video capsule endoscopy technique. The prevalence of small bowel polyps was found to be significantly higher (RR 2.50; 95%CI: 1.23 to 5.07). However, there was no significant difference in overall small bowel lesions between the acromegaly and control population. Apart from small bowel polyps, the incidence of gall bladder and gastric polyps was also reported in acromegaly patients[12]. In a retrospective study, increased prevalence of gall bladder

polyps (29.03% *vs* 4.62%, RR 6.29; 95%CI: 3.62 to 10.96;  $P < 0.01$ ) were reported in a cohort of 31 newly diagnosed acromegaly patients from the United Kingdom[32]. High GH levels and older age (> 50 years) were associated with a higher risk of gall bladder polyps in these patients.

## **PATHOGENESIS OF GI NEOPLASMS IN ACROMEGALY**

### **Colon cancer**

Several hypotheses have been put forward regarding the pathogenic mechanisms underlying the association between acromegaly and increased risk of GI malignancy particularly colon cancer[20]. Of these, the primary mechanism involves the GH-IGF-1 axis. Other contributing factors include slow intestinal transit with a redundant large bowel, altered bile acids, deranged local immune response, shared genetic susceptibility factors and hyperinsulinemia[20,33].

**Excess GH signaling:** GH acts on most tissues through the GH receptor (GHR) and is proliferative and anti-apoptotic in its action[34]. The human colonic epithelia has been shown to harbor GHR abundantly [35]. Excess GH acts through the GHR on the colonic epithelia and activates the Janus kinase-signal transducer and activator of transcription 5 (STAT5) pathway[34]. STAT5 exerts cell proliferative and anti-apoptotic activity and is associated with malignancy in tissues other than the colon as well, such as the breast and the prostate[36,37]. In human colonic adenocarcinoma, the increased cellular expression of STAT5 has been found and correlates with a poor prognosis[38,39]. These studies demonstrate the role of GH-STAT5 signaling in colon cancer independent of IGF-1 signaling.

**Excess IGF-1 signaling:** GH mediates somatic growth predominantly by inducing the production of IGF-1 from the liver. Excess IGF-1 seen in acromegaly affects cellular growth and apoptosis at various tissue levels with the net result of favoring tumor progression[40,41]. Similar to GHR, IGF-1 receptors (IGF-1Rs) are expressed in human colonic adenomas and carcinomas[42]. While some studies report no difference in IGF-1R expression in colon cancer compared to normal colonic mucosa, others found an overexpression of IGF-1R[43-45]. Cats *et al*[46] found increased colonic cell proliferation measured by a labeling index in patients with acromegaly and it correlated with IGF-1 levels. However, in contrast to clear evidence of excessive local IGF-1 signaling, studies demonstrating an association between serum IGF-1 levels and the presence of colonic neoplasia is conflicting[25,47,48].

**Increased IGFBP-3 and IGF-2 levels:** The levels of IGF-binding protein 3 (IGFBP-3) are increased in acromegaly. IGFBP-3 has anti-proliferative and pro-apoptotic properties making it tumor-protective. In acromegaly, however, elevated GH increases the IGF-1 to IGFBP-3 ratio tipping in favor of increased cancer risk[49]. A study also found increased expression of IGF-2 transcripts in colorectal carcinoma cell lines suggesting that the growth of colorectal cancer could be mediated by IGF-2-mediated autocrine action on IGF-1R[50].

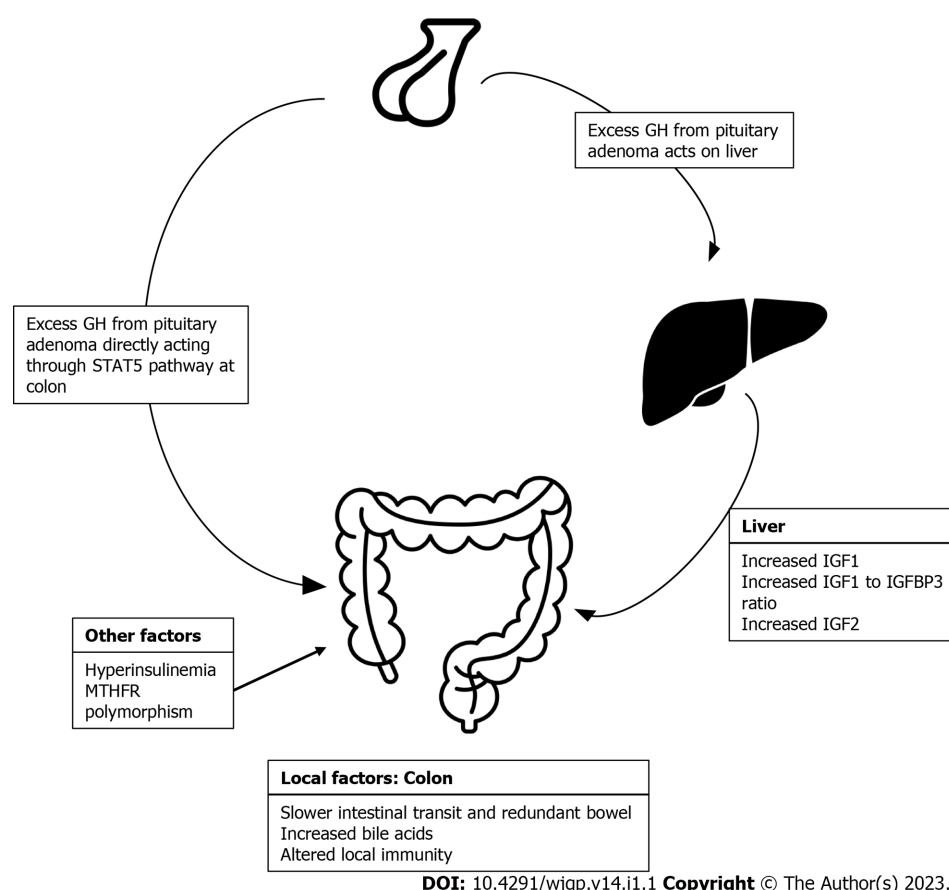
**Other factors:** Altered local immunity characterized by decrease in B cells, natural killer cells, and helper-inducer T cells has been associated with sporadic colon carcinogenesis and is also found in colonic mucosa of acromegaly patients[20]. Hyperinsulinemia as an underlying factor has been hypothesized to be associated with increased risk of colon cancer as the excess insulin acts through both insulin as well as IGF-1 receptors present abundantly on the colonic mucosa[51]. Acromegaly and type 2 diabetes mellitus are both associated with hyperinsulinemia and increased risk of colon cancer making hyperinsulinemia a plausible common underlying factor[49]. Few studies exist that have explored the genetic predisposition for colon cancer in patients with acromegaly. A study evaluated the polymorphisms in C677T methylene-tetrahydrofolate reductase gene and found that the TT genotype is associated with the increased odds of colon cancer in patients with acromegaly[52]. Association of some factors such as increased bile acids and slower colon transit time with risk of colon cancer in acromegaly are inconclusive[20].

To summarize, evidence for the pathogenic basis for increased risk of colon cancer in acromegaly is most robust for the GH-IGF-1 axis. Other contributing factors such as hyperinsulinemia, genetic predisposition, bile acids, and slower colon transit time need more evidence to substantiate the risk association (Figure 1).

### **Colon polyps**

The French Acromegaly registry found that serum IGF-1 levels, but not GH levels, correlated with the presence of colorectal polyps even after adjustment for age, body mass index, and smoking[53]. Similar conclusion associating the occurrence of colonic polyps with markers of disease activity, especially serum IGF 1 levels, have been found in other studies as well[54,55]. The study by Parolin *et al*[55] also demonstrated an association between increased polyps size and untreated acromegaly.





**Figure 1 Pathogenesis of colorectal neoplasm in acromegaly.** GH: Growth hormone; STAT5: Signal transducer and activator of transcription 5; IGF: Insulin-like growth factor; IGFBP-3: Insulin-like growth factor binding protein 3; MTHFR: Methylene-tetrahydrofolate reductase.

## SCREENING MODALITIES FOR COLORECTAL LESIONS IN ACROMEGALY

There is a good agreement in the published literature that the prevalence and incidence of colonic lesions is increased in patients with acromegaly. Therefore, most guidelines recommend an initial screening colonoscopy for all patients with acromegaly. Melmed *et al*[56] in the guidelines for patients with acromegaly in 2002 recommended that colonoscopy should be performed every 3-5 years depending upon the family history and previous polyps detection. Their 2009 update recommended an initial colonoscopy in all patients with acromegaly followed by subsequent follow-up similar to the general population[57]. The Endocrine Society clinical practice guidelines for acromegaly in 2014 recommended a baseline screening colonoscopy in all patients at the time of diagnosis while a repeat colonoscopy is suggested once every 5 years in those with a polyp or elevated IGF-1 levels and once every 10 years in those without a polyp and normal IGF-1 levels. On similar lines, the British Society of Gastroenterology and Association of Coloproctology considered acromegaly as a moderate to high-risk group for colorectal cancer and suggested in their 2010 guideline update that patients with acromegaly should be offered regular screening with colonoscopy beginning at the age of 40 years. They recommended that the frequency of repeat colonoscopy be determined by the findings at the initial colonoscopy and the activity of acromegaly. Patients with adenoma at first screening or elevated serum IGF-1 levels should be screened with a repeat colonoscopy 3-yearly, while those with normal initial colonoscopy or normal GH/IGF-1 levels should be screened every 5-10 years[58].

Although the above-mentioned guidelines recommend a more frequent follow-up colonoscopy in acromegaly patients, evidence accumulating in the last decade do not entirely support this strategy. Recent data do not show an increased colon cancer-specific mortality in acromegaly patients, especially in those with controlled disease[19,59]. A recent meta-analysis concluded that although cancer-specific mortality rate in acromegaly was increased in uncontrolled disease, it was similar to the general population in the subgroup with controlled disease. They concluded that the mortality rates decreased in the last decade in patients with acromegaly and the cancer incidence was more related to the longer age of survival rather than the GH/IGF-1 axis[60]. The presence of a colonic adenoma at first colonoscopy also predicted the occurrence of an adenoma at second (OR 4.4, 95%CI: 1.9 to 10.4) or third colonoscopies (OR 8.8, 95%CI: 2.9 to 26.5%)[54]. More importantly, a normal first colonoscopy in acromegaly patients was associated with normal second and third colonoscopies[54]. The above study findings highlight that the presence of a colonic lesion at first colonoscopy coupled with uncontrolled or

untreated acromegaly with high serum IGF-1 levels are associated with the greatest risk of incident colonic lesion. In view of the recent evidence, although both the Acromegaly Consensus Group and the Pituitary Society, recommend an initial screening colonoscopy in patients with acromegaly, they toned down their recommendation to suggest that follow-up colonoscopy testing should be performed similar to that in the general population[61,62].

Colonoscopy is technically difficult in acromegaly due to the increased length of colon and it requires a better and longer preparation time[33]. In addition, a pan-colonoscopy rather than a sigmoidoscopy is essential in acromegaly, since one-quarter of the adenomas and one-half of the carcinomas occur in the ascending and transverse colon[21].

Fecal occult blood and computed tomography (CT) colonography are the other modalities that have been tried for the diagnosis of colorectal lesions in patients with acromegaly. In a study by Bogazzi *et al* [63], colonoscopy was superior to fecal occult blood testing in detecting colonic lesions in acromegaly. By contrast, CT colonography was found to be comparable to conventional colonoscopy in terms of diagnostic accuracy, although there is an increased risk of radiation exposure and it does not allow for intervention[64].

## GI NEOPLASMS IN GH THERAPY

Several components of the GH-IGF-1 axis have been linked to the risk of carcinogenesis. As a result, there remains a safety concern for recombinant GH (rGH) therapy, specifically when it is being used in patients with history of a cancer or in patients without systemic GH deficiency. The possible risk of GI malignancy with GH therapy was first reported by Swerdlow *et al*[65]. In this cohort study from the United Kingdom, 1848 children and young adults who received rGH were followed up for the evaluation of cancer incidence and mortality. The incidence of colorectal cancer was high (SIR 7.9, 95%CI: 1.0 to 28.7;  $P = 0.05$ ); however, the absolute number of patients who developed colorectal cancer was only 2. The risk of colorectal carcinoma has reportedly remained high (SIR 11.1, 95%CI: 1.3 to 39.9;  $P = 0.03$ ) even after excluding the high-risk group (cancer survivor, chromosome fragility syndrome). The cancer mortality risk for colorectal cancer was also significantly high in this cohort. However, in the cohort study from France, the authors did not find any increased risk of colon cancer with rGH therapy [66]. In the prospective multinational Genetics and Neuroendocrinology of Short Stature International Study (GeNeSIS), more than 20000 patients who received rGH therapy were followed up. In this study also, the authors did not find any increased risk of cancer overall and only 1 patient developed rectal adenocarcinoma in the entire cohort[67]. In the recent Safety and Appropriateness of Growth Hormone Treatments in Europe cohort study, a total of 23984 patients who were treated with rGH in eight European countries (Belgium, France, Netherlands, Sweden, United Kingdom, Germany, Switzerland, and Italy) were evaluated for the risk of cancers[68]. The risk of colorectal cancer was not significantly higher (SIR 2.3; 95%CI: 0.9 to 6.2) in the overall cohort as well as in the subgroup patients who did not have any past history of cancer (SIR 1.4; 95%CI: 0.3 to 5.6). Although in the patients with a past history of cancer, the authors reported an increased risk of colorectal cancer (SIR 7.4; 95%CI: 1.9 to 29.7), the absolute number of cases with colorectal carcinoma was only 2. In the most recent study that combined the safety data from two large observational studies from the United States and Europe, the authors did not find any significant risk of GI malignancy with rGH treatment[69]. To summarize, although few studies showed increased risk of colorectal cancer, particularly in patients who were already in the high-risk group, the majority of the large cohort studies did not find any significant association between daily rGH therapy and increased risk of any GI cancer including colorectal adenocarcinoma[70].

Long-acting GH therapy (LAGH) has been approved by the United States Food and Drug Administration (lonapegsomatropin) for children with GH deficiency. However, there is theoretical concern regarding the possible risk of carcinogenic effect of increased IGF-1 level associated with LHGH therapy. Higher IGF-1 level is related to an increased risk of colon cancer in population-based studies [71]. However, none of the major human studies with LAGH therapy have reported any increased risk of colon cancer to date. In a recent meta-analysis, 11 studies with LHGH therapy also did not report any carcinogenic risk[72]. However, we need to remember that the follow-up duration of all published studies of LHGH therapy were short and inadequate to truly evaluate the long-term complications such as risk of cancer. Thus, future studies with long-term follow-up of children receiving LAGH therapy can only refute any possible carcinogenic effect of this molecule.

## GI NEOPLASMS CAUSING ACROMEGALY

While we have so far discussed acromegaly leading to an increased risk of GI tumors, GI neoplasia causing acromegaly also can occur, although quite rare. Non-pituitary neoplasms causing GH excess is seen in less than 1% of all cases of acromegaly[73]. Most of these are due to ectopic GH-releasing hormone (GHRH)-secreting tumors. The most commonly reported GHRH-secreting tumors to date have been pancreatic neuroendocrine tumors and bronchial tumors[74-76]. In most of these cases, acromegaly

is clinically indistinguishable from that due to a pituitary adenoma. Pituitary imaging reveals pituitary hyperplasia and serum GHRH levels are elevated in most of the cases. Ectopic GH-secreting tumors causing acromegaly are even more rare. Of the reported cases, most have been by a pituitary adenoma located in the sphenoid sinus and very rarely by neoplasms at other sites such as non-Hodgkin's lymphoma[77,78].

## CONCLUSION

Among the GI neoplasms, an intriguing link between colorectal neoplasms and acromegaly has been reported in most studies. However, the GI cancer-specific mortality rate was not found to be unequivocally elevated in acromegaly patients. Almost all guidelines advise an initial screening colonoscopy in acromegaly patients to facilitate the early diagnosis. Recommendations regarding the timing and frequency of repeat colonoscopy varies and needs individualization. The majority of large cohort studies did not report any significantly increased risk of gastrointestinal neoplasms in patients receiving rGH therapy.

## FOOTNOTES

**Author contributions:** Palui R and Sridharan K acquired the data and drafted the manuscript; Sahoo J, Kamalanathan S, and Naik D conceptualized the work, supervised the writing, provided intellectual input, and critically revised the manuscript; All authors approved the final version of the manuscript to be published.

**Conflict-of-interest statement:** All authors have no conflicts of interest to declare.

**Open-Access:** This article is an open-access article that was selected by an in-house editor and fully peer-reviewed by external reviewers. It is distributed in accordance with the Creative Commons Attribution NonCommercial (CC BY-NC 4.0) license, which permits others to distribute, remix, adapt, build upon this work non-commercially, and license their derivative works on different terms, provided the original work is properly cited and the use is non-commercial. See: <https://creativecommons.org/licenses/by-nc/4.0/>

**Country/Territory of origin:** India

**ORCID number:** Rajan Palui 0000-0002-2429-3595; Kalyani Sridharan 0000-0002-5867-5073; Sadishkumar Kamalanathan 0000-0002-2371-0625; Jayaprakash Sahoo 0000-0002-8805-143X; Dukhabandhu Naik 0000-0003-4568-877X.

**S-Editor:** Wang LL

**L-Editor:** Filipodia

**P-Editor:** Wang LL

## REFERENCES

- Colao A, Grasso LFS, Giustina A, Melmed S, Chanson P, Pereira AM, Pivonello R. Acromegaly. *Nat Rev Dis Primers* 2019; **5**: 20 [PMID: 30899019 DOI: 10.1038/s41572-019-0071-6]
- Molitch ME. Clinical manifestations of acromegaly. *Endocrinol Metab Clin North Am* 1992; **21**: 597-614 [PMID: 1521514 DOI: 10.1016/S0889-8529(18)30204-4]
- Vilar L, Vilar CF, Lyra R, Naves LA. Acromegaly: clinical features at diagnosis. *Pituitary* 2017; **20**: 22-32 [PMID: 27812777 DOI: 10.1007/s11102-016-0772-8]
- Boguszewski CL, Ayuk J. MANAGEMENT OF ENDOCRINE DISEASE: Acromegaly and cancer: an old debate revisited. *Eur J Endocrinol* 2016; **175**: R147-R156 [PMID: 27089890 DOI: 10.1530/EJE-16-0178]
- Klein I, Parveen G, Gavalier JS, Vanthiel DH. Colonic polyps in patients with acromegaly. *Ann Intern Med* 1982; **97**: 27-30 [PMID: 7092003 DOI: 10.7326/0003-4819-97-1-27]
- Ituarte EA, Petrini J, Hershman JM. Acromegaly and colon cancer. *Ann Intern Med* 1984; **101**: 627-628 [PMID: 6486593 DOI: 10.7326/0003-4819-101-5-627]
- Esposito D, Ragnarsson O, Johannsson G, Olsson DS. Incidence of Benign and Malignant Tumors in Patients With Acromegaly Is Increased: A Nationwide Population-based Study. *J Clin Endocrinol Metab* 2021; **106**: 3487-3496 [PMID: 34343297 DOI: 10.1210/clinem/dgab560]
- Battistone MF, Miragaya K, Rogozinski A, Agüero M, Alfieri A, Ballarino MC, Boero L, Danilowicz K, Diez S, Donoso M, Feinstein-Day P, Furioso A, Garcia-Basavilbaso N, Glerean M, Katz D, Loto M, Mallea-Gil S, Martinez M, Sabate MI, Servidio M, Slavinsky P, Stalldecker G, Sosa S, Szuman G, Tkatch J, Caldo I, Lubieniecki D, Guitelman M. Increased risk of preneoplastic colonic lesions and colorectal carcinoma in acromegaly: multicenter case-control study. *Pituitary* 2021; **24**: 96-103 [PMID: 33057946 DOI: 10.1007/s11102-020-01090-8]
- Terzolo M, Reimondo G, Berchialla P, Ferrante E, Malchiodi E, De Marinis L, Pivonello R, Grotto S, Losa M, Cannavo

- S, Ferone D, Montini M, Bondanelli M, De Menis E, Martini C, Puxeddu E, Velardo A, Peri A, Faustini-Fustini M, Tita P, Pigliaru F, Peraga G, Borretta G, Scaroni C, Bazzoni N, Bianchi A, Berton A, Serban AL, Baldelli R, Fatti LM, Colao A, Arosio M; Italian Study Group of Acromegaly. Acromegaly is associated with increased cancer risk: a survey in Italy. *Endocr Relat Cancer* 2017; **24**: 495-504 [PMID: [28710115](#) DOI: [10.1530/ERC-16-0553](#)]
- 10 **Ron E**, Gridley G, Hrubec Z, Page W, Arora S, Fraumeni JF Jr. Acromegaly and gastrointestinal cancer. *Cancer* 1991; **68**: 1673-1677 [PMID: [1913507](#) DOI: [10.1002/1097-0142\(19911015\)68:8<1673::aid-cnecr2820680802>3.0.co;2-0](#)]
- 11 **Baris D**, Gridley G, Ron E, Weiderpass E, Mellemkjaer L, Ekblom A, Olsen JH, Baron JA, Fraumeni JF Jr. Acromegaly and cancer risk: a cohort study in Sweden and Denmark. *Cancer Causes Control* 2002; **13**: 395-400 [PMID: [12146843](#) DOI: [10.1023/a:1015713732717](#)]
- 12 **Kurimoto M**, Fukuda I, Hizuka N, Takano K. The prevalence of benign and malignant tumors in patients with acromegaly at a single institute. *Endocr J* 2008; **55**: 67-71 [PMID: [18202526](#) DOI: [10.1507/endocrj.k07e-010](#)]
- 13 **Matano Y**, Okada T, Suzuki A, Yoneda T, Takeda Y, Mabuchi H. Risk of colorectal neoplasm in patients with acromegaly and its relationship with serum growth hormone levels. *Am J Gastroenterol* 2005; **100**: 1154-1160 [PMID: [15842593](#) DOI: [10.1111/j.1572-0241.2005.40808.x](#)]
- 14 **Terzolo M**, Reimondo G, Gasperi M, Cozzi R, Pivonello R, Vitale G, Scillitani A, Attanasio R, Cecconi E, Daffara F, Gaia E, Martino E, Lombardi G, Angeli A, Colao A. Colonoscopic screening and follow-up in patients with acromegaly: a multicenter study in Italy. *J Clin Endocrinol Metab* 2005; **90**: 84-90 [PMID: [15507515](#) DOI: [10.1210/jc.2004-0240](#)]
- 15 **Dal J**, Leisner MZ, Hermansen K, Farkas DK, Bengtson M, Kistorp C, Nielsen EH, Andersen M, Feldt-Rasmussen U, Dekkers OM, Sørensen HT, Jørgensen JOL. Cancer Incidence in Patients With Acromegaly: A Cohort Study and Meta-Analysis of the Literature. *J Clin Endocrinol Metab* 2018; **103**: 2182-2188 [PMID: [29590449](#) DOI: [10.1210/jc.2017-02457](#)]
- 16 **Wolinski K**, Stangierski A, Dyrda K, Nowicka K, Pelka M, Iqbal A, Car A, Lazizi M, Bednarek N, Czarnywojtek A, Gurgul E, Ruchala M. Risk of malignant neoplasms in acromegaly: a case-control study. *J Endocrinol Invest* 2017; **40**: 319-322 [PMID: [27770388](#) DOI: [10.1007/s40618-016-0565-y](#)]
- 17 **Petroff D**, Tönjes A, Grussendorf M, Droste M, Dimopoulou C, Stalla G, Jaursch-Hancke C, Mai M, Schopohl J, Schöfl C. The Incidence of Cancer Among Acromegaly Patients: Results From the German Acromegaly Registry. *J Clin Endocrinol Metab* 2015; **100**: 3894-3902 [PMID: [26244491](#) DOI: [10.1210/jc.2015-2372](#)]
- 18 **Kauppinen-Mäkelin R**, Sane T, Välimäki MJ, Markkanen H, Niskanen L, Ebeling T, Jaatinen P, Juonala M; Finnish Acromegaly Study Group, Pukkala E. Increased cancer incidence in acromegaly--a nationwide survey. *Clin Endocrinol (Oxf)* 2010; **72**: 278-279 [PMID: [19453622](#) DOI: [10.1111/j.1365-2265.2009.03619.x](#)]
- 19 **Orme SM**, McNally RJQ, Cartwright RA, Belchetz PE. Mortality and Cancer Incidence in Acromegaly: A Retrospective Cohort Study 1. *The Journal of Clinical Endocrinology & Metabolism* 1998; **83**: 2730-2734 [PMID: [9709939](#) DOI: [10.1210/jcem.83.8.5007](#)]
- 20 **Renahan AG**, O'Connell J, O'Halloran D, Shanahan F, Potten CS, O'Dwyer ST, Shalet SM. Acromegaly and colorectal cancer: a comprehensive review of epidemiology, biological mechanisms, and clinical implications. *Horm Metab Res* 2003; **35**: 712-725 [PMID: [14710350](#) DOI: [10.1055/s-2004-814150](#)]
- 21 **Rokkas T**, Pistiolas D, Sechopoulos P, Margantinis G, Koukoulis G. Risk of colorectal neoplasm in patients with acromegaly: a meta-analysis. *World J Gastroenterol* 2008; **14**: 3484-3489 [PMID: [18567075](#) DOI: [10.3748/wjg.14.3484](#)]
- 22 **Ritvonen E**, Löyttyniemi E, Jaatinen P, Ebeling T, Moilanen L, Nuutila P, Kauppinen-Mäkelin R, Schalén-Jäntti C. Mortality in acromegaly: a 20-year follow-up study. *Endocr Relat Cancer* 2016; **23**: 469-480 [PMID: [27185871](#) DOI: [10.1530/ERC-16-0106](#)]
- 23 **Krzentowska A**, Gołkowski F, Baldys-Waligórska A, Hubalewska-Dydejczyk A. Gastrointestinal tract polyps in acromegaly patients. *Przegl Lek* 2010; **67**: 1266-1269. [PMID: [21591351](#)]
- 24 **Baldys-Waligórska A**, Krzentowska A, Gołkowski F, Sokołowski G, Hubalewska-Dydejczyk A. The prevalence of benign and malignant neoplasms in acromegalic patients. *Endokrynol Pol* 2010; **61**: 29-34 [PMID: [20205101](#)]
- 25 **Gonzalez B**, Vargas G, Mendoza V, Nava M, Rojas M, Mercado M. The prevalence of colonic polyps in patients with acromegaly: a case-control, nested in a cohort colonoscopic study. *Endocr Pract* 2017; **23**: 594-599 [PMID: [28225314](#) DOI: [10.4158/EP161724.OR](#)]
- 26 **Iliaz R**, Dogansen SC, Tanrikulu S, Yalin GY, Cavus B, Gulluoglu M, Akyuz F, Yarman S. Predictors of colonic pathologies in active acromegaly: single tertiary center experience. *Wien Klin Wochenschr* 2018; **130**: 511-516 [PMID: [30062505](#) DOI: [10.1007/s00508-018-1367-3](#)]
- 27 **Koksal AR**, Ergun M, Boga S, Alkim H, Bayram M, Altuntas Y, Ozguven Yilmaz B, Alkim C. Increased prevalence of colorectal polyp in acromegaly patients: a case-control study. *Diagn Ther Endosc* 2014; **2014**: 152049 [PMID: [25614729](#) DOI: [10.1155/2014/152049](#)]
- 28 **Ochiai Y**, Inoshita N, Iizuka T, Nishioka H, Yamada S, Kitagawa M, Hoteya S. Clinicopathological features of colorectal polyps and risk of colorectal cancer in acromegaly. *Eur J Endocrinol* 2020; **182**: 313-318 [PMID: [31940279](#) DOI: [10.1530/EJE-19-0813](#)]
- 29 **Agarwal P**, Rai P, Jain M, Mishra S, Singh U, Gupta SK. Prevalence of colonic polyp and its predictors in patients with acromegaly. *Indian J Endocrinol Metab* 2016; **20**: 437-442 [PMID: [27366708](#) DOI: [10.4103/2230-8210.183455](#)]
- 30 **Blanco Velasco G**, González-Virla B, Palos-Cuellar R, Pérez-Cuadrado Robles E, Vargas-Ortega G, Solórzano-Pineda OM, Mendoza-Zubieta V, Hernández-Mondragón OV. Detection of polyps in the small bowel of patients with acromegaly via capsule endoscopy. *Rev Esp Enferm Dig* 2020; **112**: 118-120 [PMID: [31960686](#) DOI: [10.17235/reed.2020.6377/2019](#)]
- 31 **Ronchi CL**, Coletti F, Fesce E, Montefusco L, Ogliari C, Verrua E, Epaminonda P, Ferrante E, Malchiodi E, Morelli V, Beck-Peccoz P, Arosio M. Detection of small bowel tumors by videocapsule endoscopy in patients with acromegaly. *J Endocrinol Invest* 2009; **32**: 495-500 [PMID: [19494714](#) DOI: [10.1007/BF03346495](#)]
- 32 **Annamalai AK**, Gayton EL, Webb A, Halsall DJ, Rice C, Ibram F, Chaudhry AN, Simpson HL, Berman L, Gurnell M. Increased prevalence of gallbladder polyps in acromegaly. *J Clin Endocrinol Metab* 2011; **96**: E1120-E1125 [PMID: [21543430](#) DOI: [10.1210/jc.2010-2669](#)]
- 33 **Dworakowska D**, Grossman AB. Colonic Cancer and Acromegaly. *Front Endocrinol (Lausanne)* 2019; **10**: 390 [PMID: [31293513](#) DOI: [10.3389/fendo.2019.00390](#)]



- 34 **Thomas MJ.** The molecular basis of growth hormone action. *Growth Horm IGF Res* 1998; **8**: 3-11 [PMID: [10990439](#) DOI: [10.1016/s1096-6374\(98\)80316-x](#)]
- 35 **Lincoln DT, Kaiser HE, Raju GP, Waters MJ.** Growth hormone and colorectal carcinoma: localization of receptors. *In Vivo* 2000; **14**: 41-49 [PMID: [10757060](#)]
- 36 **Ferbeyre G, Moriggl R.** The role of Stat5 transcription factors as tumor suppressors or oncogenes. *Biochim Biophys Acta* 2011; **1815**: 104-114 [PMID: [20969928](#) DOI: [10.1016/j.bbcan.2010.10.004](#)]
- 37 **Tan SH, Nevalainen MT.** Signal transducer and activator of transcription 5A/B in prostate and breast cancers. *Endocr Relat Cancer* 2008; **15**: 367-390 [PMID: [18508994](#) DOI: [10.1677/ERC-08-0013](#)]
- 38 **Du W, Wang YC, Hong J, Su WY, Lin YW, Lu R, Xiong H, Fang JY.** STAT5 isoforms regulate colorectal cancer cell apoptosis via reduction of mitochondrial membrane potential and generation of reactive oxygen species. *J Cell Physiol* 2012; **227**: 2421-2429 [PMID: [21826656](#) DOI: [10.1002/jcp.22977](#)]
- 39 **Mao YL, Li ZW, Lou CJ, Pang D, Zhang YQ.** Phospho-STAT5 expression is associated with poor prognosis of human colonic adenocarcinoma. *Pathol Oncol Res* 2011; **17**: 333-339 [PMID: [21234733](#) DOI: [10.1007/s12253-010-9321-3](#)]
- 40 **Khandwala HM, McCutcheon IE, Flyvbjerg A, Friend KE.** The effects of insulin-like growth factors on tumorigenesis and neoplastic growth. *Endocr Rev* 2000; **21**: 215-244 [PMID: [10857553](#) DOI: [10.1210/edrv.21.3.0399](#)]
- 41 **Fürstenberger G, Senn HJ.** Insulin-like growth factors and cancer. *Lancet Oncol* 2002; **3**: 298-302 [PMID: [12067807](#) DOI: [10.1016/s1470-2045\(02\)00731-3](#)]
- 42 **Adenis A, Peyrat JP, Hecquet B, Delobelle A, Depadt G, Quandalle P, Bonnetterre J, Demaille A.** Type I insulin-like growth factor receptors in human colorectal cancer. *Eur J Cancer* 1995; **31A**: 50-55 [PMID: [7695979](#) DOI: [10.1016/0959-8049\(94\)00368-f](#)]
- 43 **Zenilman ME, Graham W.** Insulin-like growth factor I receptor messenger RNA in the colon is unchanged during neoplasia. *Cancer Invest* 1997; **15**: 1-7 [PMID: [9028384](#) DOI: [10.3109/07357909709018911](#)]
- 44 **Freier S, Weiss O, Eran M, Flyvbjerg A, Dahan R, Nephesh I, Safra T, Shiloni E, Raz I.** Expression of the insulin-like growth factors and their receptors in adenocarcinoma of the colon. *Gut* 1999; **44**: 704-708 [PMID: [10205209](#) DOI: [10.1136/gut.44.5.704](#)]
- 45 **Hakam A, Yeatman TJ, Lu L, Mora L, Marcet G, Nicosia SV, Karl RC, Coppola D.** Expression of insulin-like growth factor-I receptor in human colorectal cancer. *Hum Pathol* 1999; **30**: 1128-1133 [PMID: [10534157](#) DOI: [10.1016/s0046-8177\(99\)90027-8](#)]
- 46 **Cats A, Dullaart RP, Kleibeuker JH, Kuipers F, Sluiter WJ, Hardonk MJ, de Vries EG.** Increased epithelial cell proliferation in the colon of patients with acromegaly. *Cancer Res* 1996; **56**: 523-526 [PMID: [8564965](#)]
- 47 **Jenkins PJ, Fairclough PD, Richards T, Lowe DG, Monson J, Grossman A, Wass JA, Besser M.** Acromegaly, colonic polyps and carcinoma. *Clin Endocrinol (Oxf)* 1997; **47**: 17-22 [PMID: [9302367](#) DOI: [10.1046/j.1365-2265.1997.1911029.x](#)]
- 48 **Renahan AG, Bhaskar P, Painter JE, O'Dwyer ST, Haboubi N, Varma J, Ball SG, Shalet SM.** The prevalence and characteristics of colorectal neoplasia in acromegaly. *J Clin Endocrinol Metab* 2000; **85**: 3417-3424 [PMID: [10999843](#) DOI: [10.1210/jcem.85.9.6775](#)]
- 49 **Vilar L, Naves LA, Caldato C, Caldato M.** Acromegaly and colorectal cancer. *Transl Gastrointest Can* 2014; **4**: 28-38 [DOI: [10.3978/j.issn.2224-4778.2014.09.03](#)]
- 50 **Lahm H, Amstad P, Wyniger J, Yilmaz A, Fischer JR, Schreyer M, Givel JC.** Blockade of the insulin-like growth-factor-I receptor inhibits growth of human colorectal cancer cells: evidence of a functional IGF-II-mediated autocrine loop. *Int J Cancer* 1994; **58**: 452-459 [PMID: [8050827](#) DOI: [10.1002/ijc.2910580325](#)]
- 51 **Sandhu MS, Dunger DB, Giovannucci EL.** Insulin, insulin-like growth factor-I (IGF-I), IGF binding proteins, their biologic interactions, and colorectal cancer. *J Natl Cancer Inst* 2002; **94**: 972-980 [PMID: [12096082](#) DOI: [10.1093/jnci/94.13.972](#)]
- 52 **Torre ML, Russo GT, Ragonese M, Giandalia A, De Menis E, Arnaldi G, Alibrandi A, Buda C, Romanello G, Romeo EL, Cucinotta D, Trimarchi F, Cannavo S.** MTHFR C677T polymorphism, folate status and colon cancer risk in acromegalic patients. *Pituitary* 2014; **17**: 257-266 [PMID: [23807201](#) DOI: [10.1007/s11102-013-0499-8](#)]
- 53 **Maione L, Brue T, Beckers A, Delemer B, Petrossians P, Borson-Chazot F, Chabre O, François P, Bertherat J, Cortet-Rudelli C, Chanson P; French Acromegaly Registry Group.** Changes in the management and comorbidities of acromegaly over three decades: the French Acromegaly Registry. *Eur J Endocrinol* 2017; **176**: 645-655 [PMID: [28246150](#) DOI: [10.1530/EJE-16-1064](#)]
- 54 **Dworakowska D, Gueorguiev M, Kelly P, Monson JP, Besser GM, Chew SL, Akker SA, Drake WM, Fairclough PD, Grossman AB, Jenkins PJ.** Repeated colonoscopic screening of patients with acromegaly: 15-year experience identifies those at risk of new colonic neoplasia and allows for effective screening guidelines. *Eur J Endocrinol* 2010; **163**: 21-28 [PMID: [20435617](#) DOI: [10.1530/EJE-09-1080](#)]
- 55 **Parolin M, Dassie F, Russo L, Mazzocut S, Ferrara M, De Carlo E, Mioni R, Fallo F, Vettor R, Martini C, Maffei P.** Guidelines versus real life practice: the case of colonoscopy in acromegaly. *Pituitary* 2018; **21**: 16-24 [PMID: [28936751](#) DOI: [10.1007/s11102-017-0841-7](#)]
- 56 **Melmed S, Casanueva FF, Cavagnini F, Chanson P, Frohman L, Grossman A, Ho K, Kleinberg D, Lamberts S, Laws E, Lombardi G, Vance ML, Werder KV, Wass J, Giustina A; Acromegaly Treatment Consensus Workshop Participants.** Guidelines for acromegaly management. *J Clin Endocrinol Metab* 2002; **87**: 4054-4058 [PMID: [12213843](#) DOI: [10.1210/jc.2002-011841](#)]
- 57 **Melmed S, Colao A, Barkan A, Molitch M, Grossman AB, Kleinberg D, Clemmons D, Chanson P, Laws E, Schlechte J, Vance ML, Ho K, Giustina A.** Guidelines for Acromegaly Management: An Update. *The Journal of Clinical Endocrinology & Metabolism* 2009; **94**: 1509-1517. [PMID: [19208732](#) DOI: [10.1210/jc.2008-2421](#)]
- 58 **Cairns SR, Scholefield JH, Steele RJ, Dunlop MG, Thomas HJ, Evans GD, Eaden JA, Rutter MD, Atkin WP, Saunders BP, Lucassen A, Jenkins P, Fairclough PD, Woodhouse CR; British Society of Gastroenterology; Association of Coloproctology for Great Britain and Ireland.** Guidelines for colorectal cancer screening and surveillance in moderate and high risk groups (update from 2002). *Gut* 2010; **59**: 666-689 [PMID: [20427401](#) DOI: [10.1136/gut.2009.179804](#)]



- 59 **Lois K**, Bukowczan J, Perros P, Jones S, Gunn M, James RA. The role of colonoscopic screening in acromegaly revisited: review of current literature and practice guidelines. *Pituitary* 2015; **18**: 568-574 [PMID: [25052731](#) DOI: [10.1007/s11102-014-0586-5](#)]
- 60 **Bolfi F**, Neves AF, Boguszewski CL, Nunes-Nogueira VS. Mortality in acromegaly decreased in the last decade: a systematic review and meta-analysis. *Eur J Endocrinol* 2018; **179**: 59-71 [PMID: [29764907](#) DOI: [10.1530/EJE-18-0255](#)]
- 61 **Giustina A**, Barkan A, Beckers A, Biermasz N, Biller BMK, Boguszewski C, Bolanowski M, Bonert V, Bronstein MD, Casanueva FF, Clemmons D, Colao A, Ferone D, Fleseriu M, Frara S, Gadelha MR, Ghigo E, Gurnell M, Heaney AP, Ho K, Ioachimescu A, Katznelson L, Kelestimur F, Kopchick J, Krsek M, Lamberts S, Losa M, Luger A, Maffei P, Marazuela M, Mazziotti G, Mercado M, Mortini P, Neggers S, Pereira AM, Petersenn S, Puig-Domingo M, Salvatori R, Shimon I, Strasburger C, Tsagarakis S, van der Lely AJ, Wass J, Zatelli MC, Melmed S. A Consensus on the Diagnosis and Treatment of Acromegaly Comorbidities: An Update. *J Clin Endocrinol Metab* 2020; **105** [PMID: [31606735](#) DOI: [10.1210/clinem/dgz096](#)]
- 62 **Fleseriu M**, Biller BMK, Freda PU, Gadelha MR, Giustina A, Katznelson L, Molitch ME, Samson SL, Strasburger CJ, van der Lely AJ, Melmed S. A Pituitary Society update to acromegaly management guidelines. *Pituitary* 2021; **24**: 1-13 [PMID: [33079318](#) DOI: [10.1007/s11102-020-01091-7](#)]
- 63 **Bogazzi F**, Lombardi M, Scattina I, Urbani C, Marciano E, Costa A, Pepe P, Rossi G, Martino E. Comparison of colonoscopy and fecal occult blood testing as a first-line screening of colonic lesions in patients with newly diagnosed acromegaly. *J Endocrinol Invest* 2010; **33**: 530-533 [PMID: [20186003](#) DOI: [10.1007/BF03346642](#)]
- 64 **Pickhardt PJ**, Hassan C, Halligan S, Marmo R. Colorectal cancer: CT colonography and colonoscopy for detection--systematic review and meta-analysis. *Radiology* 2011; **259**: 393-405 [PMID: [21415247](#) DOI: [10.1148/radiol.11101887](#)]
- 65 **Swerdlow AJ**, Higgins CD, Adlard P, Preece MA. Risk of cancer in patients treated with human pituitary growth hormone in the UK, 1959-85: a cohort study. *Lancet* 2002; **360**: 273-277 [PMID: [12147369](#) DOI: [10.1016/s0140-6736\(02\)09519-3](#)]
- 66 **Carel JC**, Ecosse E, Landier F, Meguelli-Hakkas D, Kaguelidou F, Rey G, Coste J. Long-term mortality after recombinant growth hormone treatment for isolated growth hormone deficiency or childhood short stature: preliminary report of the French SAGhE study. *J Clin Endocrinol Metab* 2012; **97**: 416-425 [PMID: [22238382](#) DOI: [10.1210/jc.2011-1995](#)]
- 67 **Child CJ**, Zimmermann AG, Chrousos GP, Cummings E, Deal CL, Hasegawa T, Jia N, Lawrence S, Linglart A, Loche S, Maghnie M, Pérez Sánchez J, Polak M, Predieri B, Richter-Unruh A, Rosenfeld RG, Yeste D, Yorifuji T, Blum WF. Safety Outcomes During Pediatric GH Therapy: Final Results From the Prospective GeNeSIS Observational Program. *J Clin Endocrinol Metab* 2019; **104**: 379-389 [PMID: [30219920](#) DOI: [10.1210/jc.2018-01189](#)]
- 68 **Swerdlow AJ**, Cooke R, Beckers D, Borgström B, Butler G, Carel JC, Cianfarani S, Clayton P, Coste J, Deodati A, Ecosse E, Gausche R, Giacomozzi C, Hokken-Koelega ACS, Khan AJ, Kiess W, Kuehni CE, Mullis PE, Pfaffle R, Säwendahl L, Sommer G, Thomas M, Tidblad A, Tollerfield S, Van Eycken L, Zandwijken GRJ. Cancer Risks in Patients Treated With Growth Hormone in Childhood: The SAGhE European Cohort Study. *J Clin Endocrinol Metab* 2017; **102**: 1661-1672 [PMID: [28187225](#) DOI: [10.1210/jc.2016-2046](#)]
- 69 **Säwendahl L**, Polak M, Backeljauw P, Blair JC, Miller BS, Rohrer TR, Hokken-Koelega A, Pietropoli A, Kelepouris N, Ross J. Long-Term Safety of Growth Hormone Treatment in Childhood: Two Large Observational Studies: NordiNet IOS and ANSWER. *J Clin Endocrinol Metab* 2021; **106**: 1728-1741 [PMID: [33571362](#) DOI: [10.1210/clinem/dgab080](#)]
- 70 **Pollock NI**, Cohen LE. Growth Hormone Deficiency and Treatment in Childhood Cancer Survivors. *Front Endocrinol (Lausanne)* 2021; **12**: 745932 [PMID: [34745010](#) DOI: [10.3389/fendo.2021.745932](#)]
- 71 **Ma J**, Pollak MN, Giovannucci E, Chan JM, Tao Y, Hennekens CH, Stampfer MJ. Prospective study of colorectal cancer risk in men and plasma levels of insulin-like growth factor (IGF)-I and IGF-binding protein-3. *J Natl Cancer Inst* 1999; **91**: 620-625 [PMID: [10203281](#) DOI: [10.1093/jnci/91.7.620](#)]
- 72 **Ma L**, Li L, Pan W, Huang C, Liu L, Zhang X. Effect of Weekly Long-Acting Growth Hormone Replacement Therapy Compared to Daily Growth Hormone on Children With Short Stature: A Meta-Analysis. *Front Endocrinol (Lausanne)* 2021; **12**: 726172 [PMID: [34912293](#) DOI: [10.3389/fendo.2021.726172](#)]
- 73 **Borson-Chazot F**, Garby L, Raverot G, Claustat F, Raverot V, Sassolas G; GTE group. Acromegaly induced by ectopic secretion of GHRH: a review 30 years after GHRH discovery. *Ann Endocrinol (Paris)* 2012; **73**: 497-502 [PMID: [23122576](#) DOI: [10.1016/j.ando.2012.09.004](#)]
- 74 **Garby L**, Caron P, Claustat F, Chanson P, Tabarin A, Rohmer V, Arnault G, Bonnet F, Chabre O, Christin-Maitre S, du-Boullay H, Murat A, Nakib I, Sadoul JL, Sassolas G, Claustat B, Raverot G, Borson-Chazot F; GTE Group. Clinical characteristics and outcome of acromegaly induced by ectopic secretion of growth hormone-releasing hormone (GHRH): a French nationwide series of 21 cases. *J Clin Endocrinol Metab* 2012; **97**: 2093-2104 [PMID: [22442262](#) DOI: [10.1210/jc.2011-2930](#)]
- 75 **Srirangam Nadhamuni V**, Iacovazzo D, Evanson J, Sahdev A, Trouillas J, McAndrew L, R Kurawinski T, Bryant D, Hussain K, Bhattacharya S, Korbonits M. GHRH secretion from a pancreatic neuroendocrine tumor causing gigantism in a patient with MEN1. *Endocrinol Diabetes Metab Case Rep* 2021; **2021** [PMID: [34156350](#) DOI: [10.1530/EDM-20-0208](#)]
- 76 **Tadokoro R**, Sato S, Otsuka F, Ueno M, Ohkawa S, Katakami H, Taniyama M, Nagasaka S. Metastatic Pancreatic Neuroendocrine Tumor that Progressed to Ectopic Adrenocorticotrophic Hormone (ACTH) Syndrome with Growth Hormone-releasing Hormone (GHRH) Production. *Intern Med* 2016; **55**: 2979-2983 [PMID: [27746436](#) DOI: [10.2169/internalmedicine.55.6827](#)]
- 77 **Ramirez C**, Hernández-Ramírez LC, Espinosa-de-los-Monteros AL, Franco JM, Guinto G, Mercado M. Ectopic acromegaly due to a GH-secreting pituitary adenoma in the sphenoid sinus: a case report and review of the literature. *BMC Res Notes* 2013; **6**: 411 [PMID: [24119925](#) DOI: [10.1186/1756-0500-6-411](#)]
- 78 **Beuschlein F**, Strasburger CJ, Siegertetter V, Moradpour D, Lichter P, Bidlingmaier M, Blum HE, Reincke M. Acromegaly caused by secretion of growth hormone by a non-Hodgkin's lymphoma. *N Engl J Med* 2000; **342**: 1871-1876 [PMID: [10861322](#) DOI: [10.1056/NEJM200006223422504](#)]



Published by **Baishideng Publishing Group Inc**  
7041 Koll Center Parkway, Suite 160, Pleasanton, CA 94566, USA

**Telephone:** +1-925-3991568

**E-mail:** [bpgoffice@wjgnet.com](mailto:bpgoffice@wjgnet.com)

**Help Desk:** <https://www.f6publishing.com/helpdesk>

<https://www.wjgnet.com>

