

Observational Study

Digital chromoendoscopy utilization in clinical practice: A survey of gastroenterologists in Connecticut

Karl M Langberg, Neil D Parikh, Yanhong Deng, Maria Ciarleglio, Loren Laine, Harry R Aslanian

Karl M Langberg, Neil D Parikh, Loren Laine, Harry R Aslanian, Section of Digestive Diseases, Yale University School of Medicine, New Haven, CT 06510, United States

Yanhong Deng, Maria Ciarleglio, Department of Biostatistics, Yale School of Public Health, New Haven, CT 06510, United States

Loren Laine, VA Connecticut Healthcare System, West Haven, CT 06516, United States

Author contributions: Parikh ND and Aslanian HR contributed to editing, reviewing, study conception and design; Langberg KM and Parikh ND contributed to data acquisition, background research and writing of article; Deng Y and Ciarleglio M contributed data analysis; Laine L contributed with editing and reviewing the article.

Institutional review board statement: Waiver for IRB review was given by the Human Investigation Committee at Yale University.

Informed consent statement: All study participants provided informed consent prior to study enrollment.

Conflict-of-interest statement: None of the study authors have any conflicts of interest to disclose.

Data sharing statement: No additional data are available.

Open-Access: This article is an open-access article which was selected by an in-house editor and fully peer-reviewed by external reviewers. It is distributed in accordance with the Creative Commons Attribution Non Commercial (CC BY-NC 4.0) license, which permits others to distribute, remix, adapt, build upon this work non-commercially, and license their derivative works on different terms, provided the original work is properly cited and the use is non-commercial. See: <http://creativecommons.org/licenses/by-nc/4.0/>

Correspondence to: Harry R Aslanian, MD, Associate Professor of Medicine, Section of Digestive Diseases, Yale University School of Medicine, PO Box 208019, New Haven, CT 06510, United States. harry.aslanian@yale.edu
Telephone: +1-203-2005083

Fax: +1-203-2002235

Received: February 3, 2016
Peer-review started: February 14, 2016
First decision: March 1, 2016
Revised: March 13, 2016
Accepted: March 24, 2016
Article in press: March 25, 2016
Published online: May 6, 2016

Abstract

AIM: To use a survey to characterize and identify potential barriers to the use of digital chromoendoscopy (DC) by practicing gastroenterologists.

METHODS: An anonymous, internet-based survey was sent to gastroenterologists in Connecticut who were members of one of three national gastrointestinal organizations. The survey collected demographic information, frequency of DC use, types of procedures that the respondent performs, setting of practice (academic vs community), years out of training, amount of training in DC, desire to have DC training and perceived barriers to DC use. Responses were collected anonymously. The primary endpoint was the proportion of endoscopists utilizing DC. Associations between the various data collected were analyzed using χ^2 test.

RESULTS: One hundred and twenty-four gastroenterologists (48%) of 261 who received the online survey responded. Seventy-eight percent of surveyed gastroenterologists have used DC during the performance of upper endoscopy and 81% with lower endoscopy. DC was used in more than half of procedures by only 14% of gastroenterologists during upper endoscopy and 12% during lower endoscopy. Twenty-three percent (upper) and 21% (lower) used DC more than one quarter of the time. DC was used for 10% or less of endoscopies by 60% (upper) and

53% (lower) of respondents. Endoscopists reported lack of training as the leading deterrent to DC use with 36% reporting it as their primary deterrent. Eighty-nine percent of endoscopists never received formal training in DC. Lack of time (30% of respondents), lack of evidence (24%) and lack of reimbursement (10%) were additional deterrents. There were no differences in DC use relative to academic *vs* community practice setting or years out of training.

CONCLUSION: DC is used infrequently by most endoscopists, primarily due to a lack of training. Training opportunities should be expanded to meet the interest expressed by the majority of endoscopists.

Key words: Endoscopy; Surveys and questionnaires; Gastrointestinal diseases; Clinical practice patterns; Esophageal neoplasms; Colonic neoplasms; Narrow band imaging; Flexible spectral imaging color enhancement; I-scan

© The Author(s) 2016. Published by Baishideng Publishing Group Inc. All rights reserved.

Core tip: Digital chromoendoscopy (DC) is a technology present on most modern endoscopes that provides electronic contrast enhancement of the gastrointestinal mucosa. This survey study assessed the frequency of digital chromoendoscopy use and perceived barriers to its use among practicing gastroenterologists in Connecticut. DC was used in ten percent or less of endoscopies by the majority of respondents. Lack of training was the most commonly cited barrier to DC use and most desired formal training. Enhancing training opportunities for DC could increase its use.

Langberg KM, Parikh ND, Deng Y, Ciarlegio M, Laine L, Aslanian HR. Digital chromoendoscopy utilization in clinical practice: A survey of gastroenterologists in Connecticut. *World J Gastrointest Pharmacol Ther* 2016; 7(2): 268-273 Available from: URL: <http://www.wjgnet.com/2150-5349/full/v7/i2/268.htm> DOI: <http://dx.doi.org/10.4292/wjgpt.v7.i2.268>

INTRODUCTION

Image-enhanced endoscopy allows for *in vivo* characterization of colon polyps and detection of neoplasia in Barrett's esophagus^[1,2]. Image-enhanced endoscopy modalities include digital chromoendoscopy (DC), confocal laser endomicroscopy, autofluorescence and optical coherence tomography. DC was incorporated into new endoscope models as a standard feature approximately 10 years ago. DC modalities include narrow band imaging (NBI; Olympus, Tokyo, Japan), i-scan (Pentax, Tokyo, Japan), and flexible spectral imaging color enhancement (Fujinon, Saitama, Japan). These technologies are designed to provide contrast enhancement of the gastrointestinal mucosa as an

alternative to dye-based chromoendoscopy^[3]. NBI uses blue and green light, in addition to computerized image processing to visualize capillaries^[4]. Flexible spectral imaging color enhancement and i-scan use proprietary computerized post-processing software to enhance mucosal surface detail^[3,5,6].

DC has recently appeared in documents from the American Society of Gastrointestinal Endoscopy and American Gastroenterological Association for the endoscopic surveillance and management of colorectal cancers. The use of DC is supported in resect-and-discard or inspect-and-do-not-resect strategies for diminutive colorectal polyps as long as endoscopists meet pre-specified performance thresholds^[1,7]. Furthermore, decreases in the number of polypectomy specimens sent for histological assessment also may result in important cost savings^[8]. European Society for Gastrointestinal Endoscopy guidelines state that DC should be used in patients with Lynch syndrome and serrated polyposis syndrome, in addition to the resect-and-discard strategy^[9]. DC has also shown diagnostic utility in Barrett's esophagus^[2].

Despite DC's ease of use, lack of additional cost, widespread availability for the past decade, and potential diagnostic benefit, it is unclear how prevalent its use is in clinical practice. The aim of this study was to survey gastroenterologists to assess their use of DC and identify potential barriers.

MATERIALS AND METHODS

Identifying gastroenterologists

We searched the online membership databases for the American Society of Gastrointestinal Endoscopy, American Gastroenterology Association, and the American College of Gastroenterology to identify gastroenterologists in the state of Connecticut. Only members with an active email address were enrolled in the survey study.

Survey

An anonymous, internet based survey (SurveyMonkey, Palo Alto, California) was sent *via* e-mail. Non-responders were contacted up to three times *via* e-mail.

The survey comprised of 17 questions. The first part consisted of demographic information, including gender, practice setting, years as a practicing gastroenterologist, and number of endoscopic procedures performed per month. The second portion of the survey focused on specific types of endoscopic procedures performed and when DC was used in upper and lower endoscopies. The final part of the survey evaluated the physician's interest in learning DC, effort to self-train, and potential deterrents to routine DC use.

Endpoints

The primary endpoint was the proportion of endoscopists utilizing DC. Analyses were performed

Table 1 Demographic characteristics of endoscopists

Gender ($n^1 = 124$)	
Male	98 (79%)
Female	26 (21%)
Practice setting ($n^1 = 123$)	
Academic	40 (33%)
Community	83 (67%)
Average years in practice	16.5
Number of endoscopic procedures/month ($n^1 = 123$)	
Less than 25	17 (14%)
25 to 50	19 (15%)
51 to 75	24 (20%)
Greater than 75	63 (51%)
Number who perform specialized procedures ($n = 67$)	
Ablation of Barrett's esophagus	31 (46%)
Endoscopic mucosal resection for Barrett's	36 (54%)
Endoscopic mucosal resection for colon polyps	44 (66%)
Dye-based chromoendoscopy	24 (36%)

¹Numbers vary because number of respondents answering each question varied.

to compare the variation in DC use with different demographic categories: Practice setting, years in practice, and performance of interventional endoscopy procedures. Secondary outcomes included deterrents to DC use, percentage of physicians with formal training in DC, and percentage of physicians interested in additional DC training.

Statistical analysis

Summary statistics including means and standard deviations were calculated for quantitative variables; frequencies and percentages were calculated for categorical variables. Mean values were compared using two-sample *t* tests and associations between categorical variables were explored using χ^2 tests or Fisher's exact test, as appropriate. Statistical analyses were conducted by Deng Y and Ciarleglio M from Yale University School of Public Health using SAS 9.3 (Cary, NC).

RESULTS

Two hundred and sixty-one gastroenterologists with valid e-mail addresses received the online survey request. Of these, 124 (48%) responded. Table 1 summarizes the demographic characteristics of the responding physicians. All had access to DC enabled scopes in their practice.

Seventy-eight percent of surveyed gastroenterologists have used DC in upper endoscopy and 81% have used DC in lower endoscopy while 22% and 20% have never used the technology for upper and lower endoscopy respectively (Figure 1). DC was used some but less than 10% of the time by 38% (upper) and 33% (lower) of respondents. DC was used for 10% or less (combination of the < 10% and never groups) of endoscopies by 60% (upper) and 53% (lower) of respondents. Only 14% for upper endoscopy and 12% for lower endoscopy used DC in more than half of procedures and only 23% (upper) and 21% (lower) use

DC more than one quarter of the time (Figure 1). DC usage was similar by academic (82%) and community gastroenterologists (85%). The average number of years of practice was comparable for those who used DC (16.3 years) and those who did not (18.6 years). Gastroenterologists that performed interventional endoscopic procedures were more likely than general gastroenterologists to utilize DC in the upper GI tract (95% vs 71%, $P = 0.0034$) and the lower GI tract (91% vs 74%, $P = 0.0517$) (Figure 2).

Lack of training was the most commonly identified deterrent to DC use (36%), followed by lack of time (30%), lack of evidence (24%), and lack of reimbursement (10%) (Figure 3). Lack of training and lack of time were the most commonly stated reasons for not using DC irrespective of an academic or community setting (30% vs 38% for training, $P = 0.46$; 30% vs 30% for time, $P = 0.95$). Gastroenterologists who performed DC in < 10% of all procedures ranked lack of training as their primary deterrent (47% vs 19% among those who utilize DC in $\geq 10\%$ cases, $P < 0.05$), while lack of time was the most common deterrent in those who used DC in $\geq 10\%$ of procedures (42% vs 22% among those who use DC in < 10% of cases, $P < 0.05$). Eighty-nine percent ($n = 109$) of responding gastroenterologists had received no formal training in DC and 76% ($n = 93$) were interested in DC training. 82% of respondents reported some degree of self-training in DC, with learning performed *via* conferences (23%), publications (16%) and comparisons with histology (13%).

DISCUSSION

Our survey study demonstrated that DC is infrequently used in clinical practice by gastroenterologists. The majority of respondents (56%) use DC in less than one tenth of cases and one fifth never use DC. Physicians reported lack of training as the leading deterrent to DC use with approximately 90% of them having never received formal training.

DC is a standard option included on all modern endoscopes and was available to all survey respondents. While DC may not be required in endoscopic practice, it does improve diagnostic yield in Barrett's esophagus surveillance and it provides accurate characterization of diminutive colorectal polyps. In addition, training in DC may improve an endoscopist's ability to perform standard white-light endoscopy^[8].

In patients referred for Barrett's screening or surveillance, NBI with targeted biopsy of visible lesions identified similar proportions of patients with intestinal metaplasia and more dysplastic areas with fewer biopsies required than standard white light endoscopy with 4-quadrant biopsies plus targeted biopsies^[2]. Furthermore, flexible spectral imaging color enhancement was equally effective and less time consuming compared to dye-based chromoendoscopy for detection of high-grade dysplasia in Barrett's^[10].

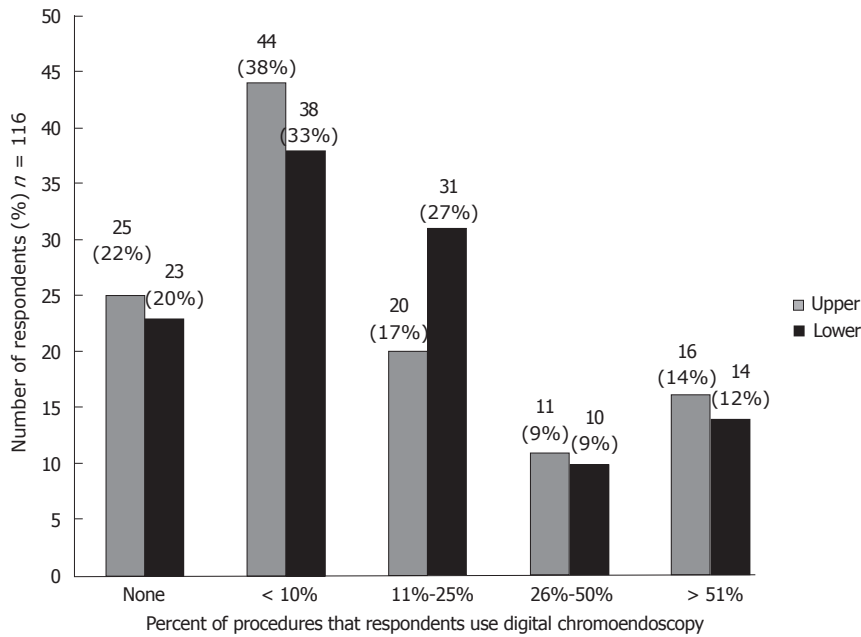


Figure 1 Percentage of digital chromoendoscopy use.

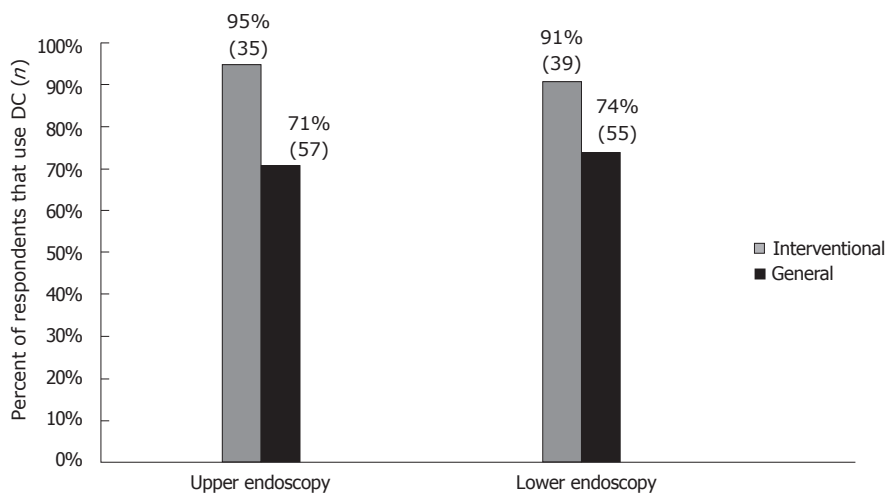


Figure 2 Digital chromoendoscopy and Interventional endoscopy.

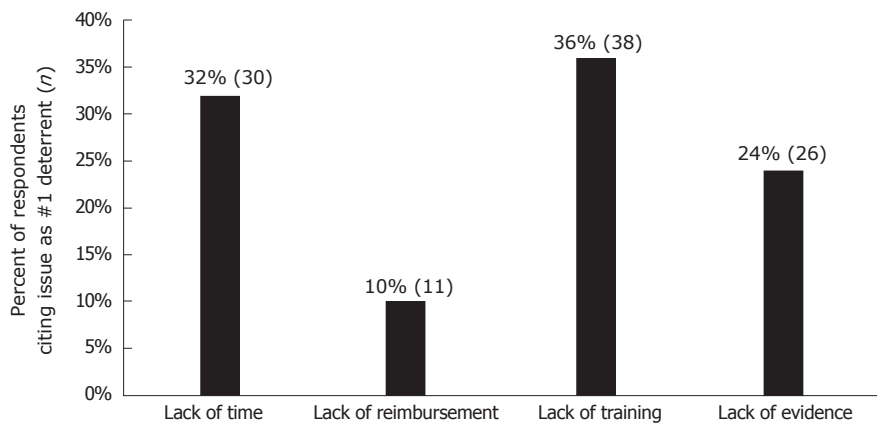


Figure 3 Deterrents to digital chromoendoscopy use.

In the lower GI tract, the majority of DC studies have focused on colorectal neoplasia and both NBI

and i-scan have been shown to be useful in the *in vivo* characterization of diminutive (≤ 5 mm) colon

polyps as hyperplastic vs adenomatous^[11]. Per current recommendations^[1,7], diminutive rectosigmoid polyps diagnosed as hyperplastic using NBI^[12], i-scan^[6,13] or flexible spectral imaging color enhancement^[11] may be left in place if endoscopists achieve the threshold of a negative predictive value $\geq 90\%$ for adenoma or can be resected and discarded if histological assessment based on DC leads to a $\geq 90\%$ agreement in appropriate post-polypectomy surveillance interval^[1]. Estimated savings to the health care system with such a "resect and discard" strategy are up to \$33 million annually^[14]. DC has not been clearly shown to improve detection of adenomas as compared to standard white-light endoscopy, and this may be a reason that some endoscopists do not employ DC during colonoscopy. Almost a quarter (24%) of endoscopists in our survey reported lack of evidence as a factor in not utilizing DC.

It is not surprising that gastroenterologists who performed interventional procedures such as endoscopic mucosal resection in Barrett's esophagus or colorectal lesions were more likely to use DC, as DC has benefit in Barrett's and may assist in identifying the borders of challenging polyps and residual neoplasia^[15]. Interestingly, we found no difference in DC utilization between academic and community physicians. The number of years in clinical practice also did not influence DC usage.

The lack of formal training appears to be one of the primary reasons behind the limited utilization of DC. In our survey, this factor was the most commonly listed deterrent and those that used DC in $< 10\%$ of procedures ranked this as the primary deterrent significantly more than those who used DC more frequently. Almost 90% of the surveyed gastroenterologists had never received formal training and three-fourths of them were interested in DC training. Despite its widespread availability, DC is not commonly a part of formal GI fellowship curriculum. Most gastroenterologists tend to self-learn DC through conferences, publications and comparisons with histology. Studies have shown that standardized training modules (computer-based) can significantly improve the endoscopist's diagnostic accuracy in DC^[16]. A rapid learning curve for DC has been reported. A 20-min didactic session was shown to significantly increase NBI accuracy for colorectal neoplasia from 48% to 91%^[17]. Our findings indicate that additional training opportunities would be of interest to gastroenterologists and could influence their endoscopic practice.

Lack of time (30%) was the second most common deterrent to use of DC and when comparing those gastroenterologists who used DC in $\geq 10\%$ of procedures vs the infrequent users ($< 10\%$), lack of time was the primary deterrent. At present, there is no reimbursement for use of DC for assessment of colon polyp histology or for the potential cost savings associated with resecting and discarding without pathologic evaluation or not resecting diminutive polyps. If DC was billable more

gastroenterologists might be willing to spend the additional time needed for examination with DC.

This survey study was not without limitations. While there was a sufficient response rate of 48%, the overall sample size is limited. This study was restricted to the state of Connecticut, potentially limiting generalizability nationally. In addition, like most surveys, results may be biased by self-reporting. Further investigation could include a wider survey area, objective reviews of case logs to determine actual DC use, and evaluation of the influence of training programs on the frequency of DC use and other clinical outcomes.

In conclusion, our study found that DC is used infrequently by most endoscopists despite being widely available. The most common reason for infrequent use was lack of training. The vast majority of those who responded had received no formal training and most stated that they would be interested in such training. Given the potential for DC to enhance diagnostic yield and reduce healthcare costs, the development of additional training opportunities should be considered.

COMMENTS

Background

Digital chromoendoscopy (DC) is a mode available on most modern endoscopes that enhances visual contrast between normal and abnormal gastrointestinal (GI) mucosa using digital image processing. It can be useful in both upper and lower endoscopy. Despite potential advantages the frequency of DC use is unknown.

Research frontiers

Establishing the role of DC, at present, in particular relation to a resect and discard strategy for diminutive colorectal polyps and the targeting of esophageal biopsies for Barrett's esophagus.

Innovations and breakthroughs

The study is the first to assess the frequency of and perceived barriers to DC use.

Applications

The authors' finding that a lack of training is a major barrier to DC use suggests that increased DC training as part of continuing medical education and gastroenterology fellowship may be beneficial.

Terminology

Digital chromoendoscopy: A group of technologies that enhances visual contrast between normal and abnormal GI mucosa using digital image post-processing.

Peer-review

The authors present a scientific paper very interesting, related to a topic of current debate.

REFERENCES

- 1 **Rex DK**, Kahi C, O'Brien M, Levin TR, Pohl H, Rastogi A, Burgart L, Imperiale T, Ladabaum U, Cohen J, Lieberman DA. The American Society for Gastrointestinal Endoscopy PIVI (Preservation and Incorporation of Valuable Endoscopic Innovations) on real-time endoscopic assessment of the histology of diminutive colorectal polyps. *Gastrointest Endosc* 2011; **73**: 419-422 [PMID: 21353837 DOI: 10.1016/j.gie.2011.01.023]
- 2 **Sharma P**, Hawes RH, Bansal A, Gupta N, Curvers W, Rastogi

- A, Singh M, Hall M, Mathur SC, Wani SB, Hoffman B, Gaddam S, Fockens P, Bergman JJ. Standard endoscopy with random biopsies versus narrow band imaging targeted biopsies in Barrett's oesophagus: a prospective, international, randomised controlled trial. *Gut* 2013; **62**: 15-21 [PMID: 22315471 DOI: 10.1136/gutjnl-2011-300962]
- 3 **Manfredi MA**, Abu Dayyeh BK, Bhat YM, Chauhan SS, Gottlieb KT, Hwang JH, Komanduri S, Konda V, Lo SK, Maple JT, Murad FM, Siddiqui UD, Wallace MB, Banerjee S. Electronic chromoendoscopy. *Gastrointest Endosc* 2015; **81**: 249-261 [PMID: 25484330 DOI: 10.1016/j.gie.2014.06.020]
 - 4 **Gono K**, Obi T, Yamaguchi M, Ohyama N, Machida H, Sano Y, Yoshida S, Hamamoto Y, Endo T. Appearance of enhanced tissue features in narrow-band endoscopic imaging. *J Biomed Opt* 2004; **9**: 568-577 [PMID: 15189095 DOI: 10.1117/1.1695563]
 - 5 **Pohl J**, May A, Rabenstein T, Pech O, Ell C. Computed virtual chromoendoscopy: a new tool for enhancing tissue surface structures. *Endoscopy* 2007; **39**: 80-83 [PMID: 17252465 DOI: 10.1055/s-2006-945045]
 - 6 **Hoffman A**, Kagel C, Goetz M, Tresch A, Mudter J, Biesterfeld S, Galle PR, Neurath MF, Kiesslich R. Recognition and characterization of small colonic neoplasia with high-definition colonoscopy using i-Scan is as precise as chromoendoscopy. *Dig Liver Dis* 2010; **42**: 45-50 [PMID: 19473893 DOI: 10.1016/j.dld.2009.04.005]
 - 7 **Lieberman D**, Brill J, Canto M, DeMarco D, Fennerty B, Gupta N, Laine L, Lightdale C, Montgomery E, Odze R, Rex D, Sharma P, Kochman M, Tokar J. Management of Diminutive Colon Polyps Based on Endoluminal Imaging. *Clin Gastroenterol Hepatol* 2015; **13**: 1860-1866; quiz 1868-1869 [PMID: 26192139 DOI: 10.1016/j.cgh.2015.07.011]
 - 8 **Kim JS**, Lee BI, Choi H, Kang BK, Kim JI, Lee HM, Im EJ, Kim BW, Kim SW, Choi MG, Choi KY. Brief education on microvasculature and pit pattern for trainees significantly improves estimation of the invasion depth of colorectal tumors. *Gastroenterol Res Pract* 2014; **2014**: 245396 [PMID: 24971089 DOI: 10.1155/2014/245396]
 - 9 **Kamiński MF**, Hassan C, Bisschops R, Pohl J, Pellisé M, Dekker E, Ignjatovic-Wilson A, Hoffman A, Longcroft-Wheaton G, Heresbach D, Dumonceau JM, East JE. Advanced imaging for detection and differentiation of colorectal neoplasia: European Society of Gastrointestinal Endoscopy (ESGE) Guideline. *Endoscopy* 2014; **46**: 435-449 [PMID: 24639382 DOI: 10.1055/s-0034-1365348]
 - 10 **Pohl J**, May A, Rabenstein T, Pech O, Nguyen-Tat M, Fissler-Eckhoff A, Ell C. Comparison of computed virtual chromoendoscopy and conventional chromoendoscopy with acetic acid for detection of neoplasia in Barrett's esophagus. *Endoscopy* 2007; **39**: 594-598 [PMID: 17611913 DOI: 10.1055/s-2007-966649]
 - 11 **Wanders LK**, East JE, Uitentuis SE, Leeftang MM, Dekker E. Diagnostic performance of narrowed spectrum endoscopy, autofluorescence imaging, and confocal laser endomicroscopy for optical diagnosis of colonic polyps: a meta-analysis. *Lancet Oncol* 2013; **14**: 1337-1347 [PMID: 24239209 DOI: 10.1016/S1470-2045(13)70509-6]
 - 12 **Ignjatovic A**, East JE, Suzuki N, Vance M, Guenther T, Saunders BP. Optical diagnosis of small colorectal polyps at routine colonoscopy (Detect InSpec Characterise Resect and Discard; DISCARD trial): a prospective cohort study. *Lancet Oncol* 2009; **10**: 1171-1178 [PMID: 19910250 DOI: 10.1016/S1470-2045(09)70329-8]
 - 13 **Basford PJ**, Longcroft-Wheaton G, Higgins B, Bhandari P. High-definition endoscopy with i-Scan for evaluation of small colon polyps: the HiSCOPE study. *Gastrointest Endosc* 2014; **79**: 111-118 [PMID: 23871094 DOI: 10.1016/j.gie.2013.06.013]
 - 14 **Hassan C**, Pickhardt PJ, Rex DK. A resect and discard strategy would improve cost-effectiveness of colorectal cancer screening. *Clin Gastroenterol Hepatol* 2010; **8**: 865-869, 869.e1-e3 [PMID: 20621680 DOI: 10.1016/j.cgh.2010.05.018]
 - 15 **Rogart JN**, Aslanian HR, Siddiqui UD. Narrow band imaging to detect residual or recurrent neoplastic tissue during surveillance endoscopy. *Dig Dis Sci* 2011; **56**: 472-478 [PMID: 20532981 DOI: 10.1007/s10620-010-1289-z]
 - 16 **McGill SK**, Soetikno R, Rastogi A, Rouse RV, Sato T, Bansal A, McQuaid K, Kaltenbach T. Endoscopists can sustain high performance for the optical diagnosis of colorectal polyps following standardized and continued training. *Endoscopy* 2015; **47**: 200-206 [PMID: 25264764 DOI: 10.1055/s-0034-1378096]
 - 17 **Raghavendra M**, Hewett DG, Rex DK. Differentiating adenomas from hyperplastic colorectal polyps: narrow-band imaging can be learned in 20 minutes. *Gastrointest Endosc* 2010; **72**: 572-576 [PMID: 20561618]

P- Reviewer: Braden B, Soria F, Terruzzi V **S- Editor:** Ji FF

L- Editor: A **E- Editor:** Wu HL





Published by **Baishideng Publishing Group Inc**

8226 Regency Drive, Pleasanton, CA 94588, USA

Telephone: +1-925-223-8242

Fax: +1-925-223-8243

E-mail: bpgoffice@wjgnet.com

Help Desk: <http://www.wjgnet.com/esps/helpdesk.aspx>

<http://www.wjgnet.com>

