


World Journal of *Cardiology*

World J Cardiol 2021 June 26; 13(6): 155-182



FIELD OF VISION

- 155 A Novel guide extension assisted stenting technique for coronary bifurcation lesions
Y-Hassan S, de Palma R

MINIREVIEWS

- 163 Is branched-chain amino acid nutritional supplementation beneficial or detrimental in heart failure?
Narita K, Amiya E
- 170 Cardiogenic shock in the setting of acute myocardial infarction: Another area of sex disparity?
Bukhari S, Fatima S, Elgendy IY

CASE REPORT

- 177 Novel economic treatment for coronary wire perforation: A case report
Abdalwahab A, McQuillan C, Farag M, Egred M

ABOUT COVER

Editorial Board Member of *World Journal of Cardiology*, Giuseppe De Luca, MD, PhD, Associate Professor, Department of Cardiology, Eastern Piedmont University, Novara 28100, Italy. p.de_luca@libero.it

AIMS AND SCOPE

The primary aim of *World Journal of Cardiology* (WJC, *World J Cardiol*) is to provide scholars and readers from various fields of cardiology with a platform to publish high-quality basic and clinical research articles and communicate their research findings online.

WJC mainly publishes articles reporting research results and findings obtained in the field of cardiology and covering a wide range of topics including acute coronary syndromes, aneurysm, angina, arrhythmias, atherosclerosis, atrial fibrillation, cardiomyopathy, congenital heart disease, coronary artery disease, heart failure, hypertension, imaging, infection, myocardial infarction, pathology, peripheral vessels, public health, Raynaud's syndrome, stroke, thrombosis, and valvular disease.

INDEXING/ABSTRACTING

The WJC is now abstracted and indexed in Emerging Sources Citation Index (Web of Science), PubMed, PubMed Central, Scopus, China National Knowledge Infrastructure (CNKI), China Science and Technology Journal Database (CSTJ), and Superstar Journals Database.

RESPONSIBLE EDITORS FOR THIS ISSUE

Production Editor: Ying-Yi Yuan; **Production Department Director:** Xiang Li; **Editorial Office Director:** Ya-Juan Ma.

NAME OF JOURNAL

World Journal of Cardiology

ISSN

ISSN 1949-8462 (online)

LAUNCH DATE

December 31, 2009

FREQUENCY

Monthly

EDITORS-IN-CHIEF

Ramdas G Pai, Dimitrios Tousoulis, Marco Matteo Ciccone

EDITORIAL BOARD MEMBERS

<https://www.wjgnet.com/1949-8462/editorialboard.htm>

PUBLICATION DATE

June 26, 2021

COPYRIGHT

© 2021 Baishideng Publishing Group Inc

INSTRUCTIONS TO AUTHORS

<https://www.wjgnet.com/bpg/gerinfo/204>

GUIDELINES FOR ETHICS DOCUMENTS

<https://www.wjgnet.com/bpg/gerinfo/287>

GUIDELINES FOR NON-NATIVE SPEAKERS OF ENGLISH

<https://www.wjgnet.com/bpg/gerinfo/240>

PUBLICATION ETHICS

<https://www.wjgnet.com/bpg/gerinfo/288>

PUBLICATION MISCONDUCT

<https://www.wjgnet.com/bpg/gerinfo/208>

ARTICLE PROCESSING CHARGE

<https://www.wjgnet.com/bpg/gerinfo/242>

STEPS FOR SUBMITTING MANUSCRIPTS

<https://www.wjgnet.com/bpg/gerinfo/239>

ONLINE SUBMISSION

<https://www.f6publishing.com>



A Novel guide extension assisted stenting technique for coronary bifurcation lesions

Shams Y-Hassan, Rodney de Palma

ORCID number: Shams Y-Hassan 0000-0001-5228-9035; Rodney de Palma 0000-0002-3004-9089.

Author contributions: Y-Hassan S contributed to the study conception, interpretation of the results, and manuscript write up; De Palma R contributed to interpretation of the results, critical review and manuscript write up; all authors have read and approved the final manuscript.

Conflict-of-interest statement: The authors have no competing interests to disclose.

Open-Access: This article is an open-access article that was selected by an in-house editor and fully peer-reviewed by external reviewers. It is distributed in accordance with the Creative Commons Attribution NonCommercial (CC BY-NC 4.0) license, which permits others to distribute, remix, adapt, build upon this work non-commercially, and license their derivative works on different terms, provided the original work is properly cited and the use is non-commercial. See: <http://creativecommons.org/licenses/by-nc/4.0/>

Manuscript source: Invited manuscript

Specialty type: Cardiac and

Shams Y-Hassan, Coronary Artery Disease Area, Heart and Vascular Theme, Karolinska Institutet and Karolinska University Hospital, Stockholm S-141 86, Sweden

Rodney de Palma, Buckinghamshire Healthcare NHS Trust, Buckinghamshire HP11 2TT, United Kingdom

Corresponding author: Shams Y-Hassan, MBChB, MD, Doctor, Research Scientist, Coronary Artery Disease Area, Heart and Vascular Theme, Karolinska Institutet and Karolinska University Hospital, SE-171 76, Stockholm S-141 86, Sweden. shams.younis-hassan@sl.se

Abstract

A challenging technical scenario frequently encountered in a percutaneous coronary intervention of a coronary bifurcation lesion (CBL) is stent implantation of only the stenosed segment without compromising the other two normal segments in non-true bifurcation lesions. Another is precise stent implantation covering the side branch ostium without leaving excessive stent metal at the other two segments of a bifurcation lesion in complex true bifurcation lesions. The aim of this study was to describe a novel stenting technique for both non-true and true CBLs by using a guide extension catheter (GuideLiner). With the assistance of a guide extension catheter mounted on both the main and the side-branch guidewires and with its intubation down to the bifurcation carina, a stent can be implanted in the side branch segment or distal main segment of the bifurcation lesion appropriately without compromising the other two segments of the coronary bifurcation. Stent implantation is described in three bifurcation lesions in three cases and shown in detail with illustrative figures. The technique facilitates side-branch only stenting in side-branch mono-ostial (medina 0, 0, 1) CBL or only the distal main segment in distal mono-ostial (medina 0, 1, 0) CBL without compromising the other two remaining segments when using the one-stent technique in non-true CBLs without leaving unnecessary excessive stent metal at the bifurcation site and when using a two-stent technique in complex true bifurcation lesions (tri-ostial or medina 1, 1, 1). Consequently, through optimizing stent deployment, the technique may have the potential to reduce the risk of subacute stent thrombosis and future in-stent restenosis. The most appropriate lesions suitable for the technique, and some other practical tips are also described.

Key Words: Coronary bifurcation lesion; GuideLiner stenting; Percutaneous coronary intervention; One- or two-stenting technique; Novel descriptive, intelligible and ordered

cardiovascular systems

Country/Territory of origin: Sweden**Peer-review report's scientific quality classification**

Grade A (Excellent): 0
 Grade B (Very good): B
 Grade C (Good): C, C
 Grade D (Fair): 0
 Grade E (Poor): 0

Received: January 20, 2021**Peer-review started:** January 20, 2021**First decision:** February 28, 2021**Revised:** March 18, 2021**Accepted:** May 17, 2021**Article in press:** May 17, 2021**Published online:** June 26, 2021**P-Reviewer:** Lim PO, Sato A**S-Editor:** Fan JR**L-Editor:** Filipodia**P-Editor:** Yuan YY

classification; Medina classification

©The Author(s) 2021. Published by Baishideng Publishing Group Inc. All rights reserved.

Core Tip: A novel stenting technique for coronary bifurcation lesions (CBLs) is presented. With the help of a guide extension-assisted technique using a GuideLiner mounted on both guidewires in the branches of the bifurcation lesion and advanced to the carina of the bifurcation, a stent can be implanted at the most possible appropriate site of the side branch in side-branch mono-ostial (medina 0, 0, 1) or in the distal mono-ostial (medina 0, 1, 0) in non-true CBLs. The technique can also be used to stent the side branch in two-stent techniques for complex true CBLs (tri-ostial or medina 1, 1, 1).

Citation: Y-Hassan S, de Palma R. A Novel guide extension assisted stenting technique for coronary bifurcation lesions. *World J Cardiol* 2021; 13(6): 155-162

URL: <https://www.wjgnet.com/1949-8462/full/v13/i6/155.htm>

DOI: <https://dx.doi.org/10.4330/wjc.v13.i6.155>

INTRODUCTION

Percutaneous coronary intervention (PCI) of a coronary bifurcation lesion (CBL) is a challenging procedure for interventionists[1]. The short- and long-term outcomes are closely related to the procedural success and optimization of the bifurcation stenting technique[2,3]. Several one- or two-stent techniques for PCI of CBLs have been described, depending on the type and location of the bifurcation lesions[1,4]. Stenting of the side branch in side-branch mono-ostial[5] (medina 0, 0, 1)[6] bifurcation stenoses is associated with difficulties in stent placement at the proper site with the risk of missing the side branch ostium or of excessive stent protrusion in the main branch. The same applies to stenting only the distal main segment in distal mono-ostial (medina 0, 1, 0) bifurcation stenoses. Consequently, the provisional stenting technique is typically employed in treating a distal mono-ostial stenosis (medina 0, 1, 0) but this requires “unnecessary” stenting of the normal proximal main segment of the bifurcation and the risk of compromising the side branch[1].

The provisional stenting technique is also recommended as the default strategy by most interventionists in tri-ostial (medina 1, 1, 1) or true bifurcation lesions[1]. However, this technique may lead to side-branch occlusion during stenting of the main branch and acute peri-procedural myocardial infarction. Improvements in the protection of the side branch have been reported with the jailed balloon protection of the side branch[7] or modified jailed balloon techniques[8]. The risk of side-branch occlusion is increased in complex tri-ostial (medina 1, 1, 1) bifurcation lesions where a two-stent technique should always be considered. However, the current two-stent techniques for the CBLs, such as crush[9] and culotte[10] stenting, leave multiple layers of stent struts at the bifurcation site causing difficulties in rewiring, balloon re-crossing, and the performance of sequential post-dilatation and final kissing balloon inflation. This may result in stent under expansion, and/or malapposition at the bifurcation site predisposing to acute and sub-acute stent thrombosis. Suboptimal stent implantation is also associated with an increased risk of future in-stent restenosis [1]. To overcome these challenges, the crush technique has evolved to mini-crush and double kissing (DK)-crush techniques[1]. The DK-crush stenting technique facilitates final kissing balloon inflation, but the technique has complex procedural steps and is time consuming. Other two-stent techniques include simultaneous kissing stenting, T-stenting and V-stenting techniques. The T-stenting technique does not leave multiple layers of stent struts, which facilitates final kissing balloon inflation, but has the potential of geographical miss at the side branch. These technical shortcomings highlight the need for a stent implantation technique that avoids unnecessary stenting of the normal segments and not leaving multiple layers of stent struts at the bifurcation site. A guide extension catheter can intubate the coronary arteries down to the carina of the bifurcation site. This may facilitate precise stent implantation at the ostium of the side branch or the distal main segment and thus enhance rewiring,

balloon re-crossing and final kissing balloon inflation in two-stent techniques.

METHODOLOGY

Description of the guide extension-assisted stenting technique using a GuideLiner catheter (Vascular Solutions Inc., Minneapolis, MN)

The GuideLiner is a guide extension catheter that is mounted coaxially on a monorail system extending through the guide catheter. It consists of a coaxial exchange system with a flexible extension of 20 cm and a radio-opaque marker 2 mm proximal to the tip of the catheter. The extension catheter has been used for deep vessel intubation to allow the smooth device delivery of balloons and stent platforms in calcified or tortuous vessel anatomy. Guide extension catheters have also been used to facilitate obtaining good angiographic and optical coherence tomographic (OCT) images by subselective injection of reduced contrast medium, and particularly useful in tortuous vessel or angulated bifurcation anatomy[11]. Further uses include stenting the main branch of a complex bifurcation lesion while retaining guide wires in both side branches of the bifurcation[12] and to facilitate side strut stenting technique for the treatment of right coronary artery ostial in-stent restenosis where there is ostial right coronary artery stent overhang into the aortic root[13].

In this novel technique, the coronary artery is engaged by conventional 6, 7, or 8F guide catheters, through radial (6 and 7F), or femoral (6, 7, and 8F) artery approaches. Two guidewires are placed in the branches of the bifurcation lesion, one in the main branch and one in the side branch (Figure 1A and B). The bifurcation lesion is predilated, preferably with undersized 1.5 or 2 mm balloon, and the ostium of the side branch should be dilated with a cutting or scoring balloon, especially the left anterior descending artery (LAD) ostium or the left circumflex artery (LCx) ostium. The dilated but still stenosed bifurcation lesion helps to prevent to-and-fro movement of the stent during stent implantation especially in LAD. Dilatation of the ostium by a cutting or scoring balloon helps to avoid stent sliding distally during stent implantation. Thereafter, the appropriate (6, 7, or 8F) GuideLiner mounted on both guidewires is introduced and placed near the tip of the guide catheter (Figure 1C). The stent is introduced somewhat distal to the lesion (Figure 1D) and then the GuideLiner introduced to the carina of the bifurcation, and the stent is retracted while the GuideLiner is advanced carefully against the carina until the proximal radio-opaque marker of the stent balloon is overlapping the distal radio-opaque marker of the GuideLiner (Figure 1E). Being mounted on both main and side-branch guidewires, the guide extension catheter will stop at the carina of the bifurcation just adjacent to the ostium of the side branch or ostium of the distal main segment of the main branch. The stent is then implanted slowly to avoid stent displacement (Figure 1F). During stent implantation, the proximal part of the stent balloon pushes the GuideLiner catheter backward. In this way the stent is implanted at the ostial region and distally without compromising the other two segments of the bifurcation (Figures 1-4). The stent balloon catheter is pulled out first followed by the GuideLiner. The stent is then post-dilated, and the stent apposition is checked in the conventional way. In tri-ostial bifurcation lesions (medina 1, 1, 1), and after stenting the side branch by GuideLiner technique described above (Figure 4), the procedure is completed conventionally with stenting of the main branch, proximal optimization technique (POT), rewiring of the side branch, balloon re-crossing of the main branch stent struts, sequential balloon dilatation, and final kissing balloon inflation. The technique is further illustrated and described in three bifurcation cases treated with this guide extension technique in Figures 1-4.

Coronary artery bifurcation lesions suitable for the GuideLiner-assisted stenting technique

This novel guide extension assisted stenting technique is characterized by keeping the guidewire access to both branches of the bifurcation during the whole procedure in side-branch mono-ostial (medina 0, 0, 1), distal mono-ostial (medina 0, 1, 0) CBL, and stenting only the lesion site without compromising the other two segments of the bifurcation. The most appropriate bifurcation sites suitable are the bifurcation lesions situated proximally in the coronary artery trees as left main stem/LAD/LCx, proximal LAD/diagonal, and proximal LCx/marginal bifurcation lesions. The most suitable types of CBLs for this technique are the side-branch mono-ostial (medina 0, 0, 1), the distal mono-ostial (medina 0, 1, 0) and potentially distal bi-ostial (medina 0, 1, 1)

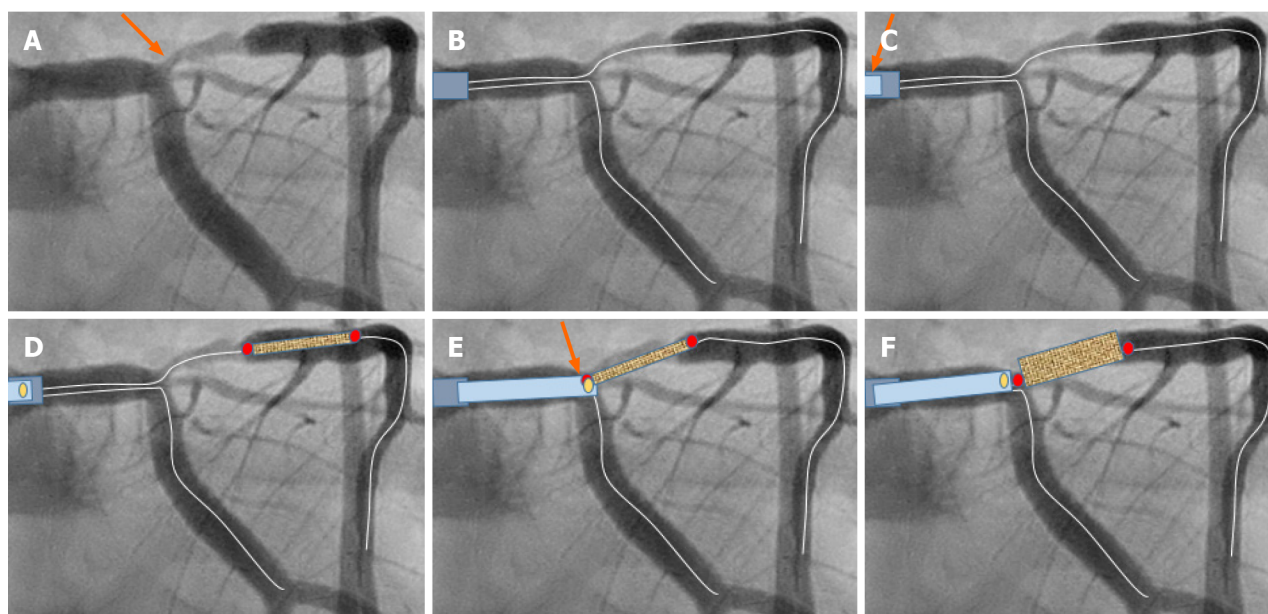


Figure 1 Schematic description of the guide extension-assisted technique in a coronary bifurcation lesion in the first case. A: Coronary angiography in a male patient admitted with unstable angina revealed a significant ostial and proximal left anterior descending artery (LAD) stenosis. It was classified as side branch mono-ostial (medina 0, 0, 1), left main stem/left circumflex artery (LCx)/LAD bifurcation stenosis (orange arrow). Evaluation by fractional flow reserve assessment was 0.76, indicating a significant stenosis. The guide extension-assisted percutaneous coronary intervention technique is demonstrated schematically. B: Two guide wires are placed in the left coronary artery (both LAD and LCx); C: After conventional pre-dilatation, the GuideLiner, mounted on both guidewires, is placed proximal to the tip of the mother guide catheter (orange arrow); D: The stent is introduced just distal to the stenosis; E: The GuideLiner is then advanced to the carina of the bifurcation and the stent is pulled back to a level where the proximal radio-opaque marker of the stent balloon overlaps the radio-opaque marker just proximal to the tip of the guide-liner (orange arrow). Because the GuideLiner is mounted on both wires, the carina of the bifurcation will prevent further introduction of the GuideLiner into the LAD or LCx; F: The stent is implanted slowly. Note that the GuideLiner is pushed backwards when the stent balloon is inflated.

bifurcation lesions when the proximal segment of the main branch is normal. The technique can also be utilized in tri-ostial bifurcation stenosis (medina 1, 1, 1) through stenting the side branch using the guide extension technique (Figure 4) and then conventional stent implantation in the main branch with the advantage of not leaving excessive stent metal at the carina and facilitation of the procedure by proximal optimization, rewiring, sequential balloon dilatation, and final kissing balloon inflation.

Side branch stenting

Side branch stenting is challenging for all interventionists. The crucial step is positioning the stent so that it covers the ostium of the side branch without protruding too much into the main branch. Achievement of geographical precision is more difficult when the bifurcation angle is of the “Y-type” and almost impossible when the ostium of the side branch cannot be visualized, which is the case in some bifurcation lesions as shown in Figure 3. One of the disadvantages of the T-stenting technique is that it may miss covering the ostium of the side branch. In contrast, the crush, mini-crush, and culotte stenting techniques[1] leave multiple strut layers in the main branch that may result major difficulty in rewiring the side branch and subsequent sequential and final kissing balloon inflations. The novel guide extension-assisted stenting technique of the side branch reduces the risk of missing the ostium substantially and avoids unnecessary stent protrusion into the main branch.

RESULTS

Three different types of CBLs in three cases that were successfully treated with PCI using a GuideLiner-assisted stenting technique. Two cases had non-true CBLs and one had a true CBL. The first case had left main stem/LCx/LAD bifurcation stenosis of a side-branch type mono-ostial (medina 0, 0, 1) bifurcation lesion. With a GuideLiner advanced to the carina of the bifurcation, the side branch (LAD) was stented successfully (Figure 2). The stent covered the ostium of the LAD without leaving stent struts in the left main stem or LCx, confirmed by StentBoost imaging (Figure 2F). The

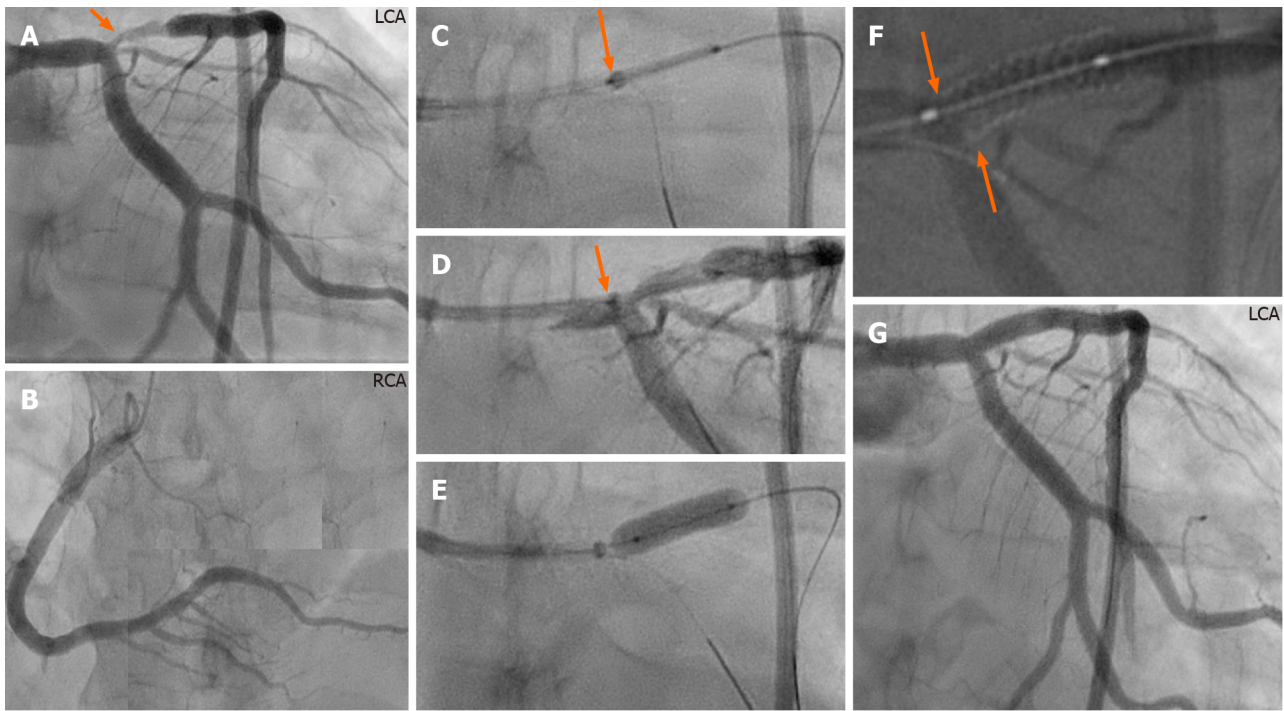


Figure 2 Annotated description of the guide extension technique in the bifurcation lesion in the first case. A and B: Left (A) and right (B) coronary angiography of the same patient in figure 1 showing stenosis at the ostium and proximal part of left anterior descending artery (LAD) (A, orange arrow); C and D: After engagement of the left coronary artery with 7F XB 3.5 guide catheter, a 7F GuideLiner, mounted on both guidewires, is advanced carefully against the carina of the bifurcation and the stent is placed at the stenosis site with the proximal radio-opaque marker of the stent balloon overlapping the radio-opaque marker just proximal to the tip of the GuideLiner (D, under contrast injection); E: A 3.5 mm × 15 mm stent was implanted with a pressure of 20 atm; note that the GuideLiner is pushed backwards during stent implantation. The stent is post-dilated in the conventional way; F: The proximal stent edge can be seen accurately placed at the ostium using StentBoost imaging (orange arrows); G: Final result, stent implanted in the LAD without compromising the left main stem or the left circumflex artery ostium. LCA: Left coronary artery; RCA: Right coronary artery.

bifurcation lesion in the second case treated with this novel technique was a LAD/diagonal bifurcation stenosis type distal mono-ostial (medina 0, 1, 0) where the stenosis was restricted to the distal main segment of the bifurcation. It is worth mentioning that visualization of the angle between the diagonal branch and the distal segment of the main branch (LAD) was ambiguous, making it especially suitable for this novel technique. With a GuideLiner intubated down to the carina of the bifurcation, the distal main segment was stented successfully (Figure 3). The stent covered the ostium of the distal main segment without leaving stent struts in proximal main segment or the side branch and this was confirmed by OCT (Figure 3E and F), which also showed a well-apposed stent to the vessel wall. The bifurcation lesion in the third case was a complex LAD/diagonal bifurcation stenosis of type tri-ostial (medina 1, 1, 1) (Figure 4). The side branch was stented by this novel technique after extending the GuideLiner to the carina of bifurcation. The stent covered the side-branch ostium without leaving stent struts at the bifurcation site. The main branch is then stented in the conventional way without leaving multiple layers of stent struts at the bifurcation site. Consequently, the procedure enhanced rewiring, balloon re-crossing and the performance of sequential post-dilatation and final kissing balloon inflations. StentBoost and optical coherence tomography confirmed well-apposed stents at the bifurcation site with no stent struts covering the ostium of the diagonal branch (Figure 4H and I)

DISCUSSION

The main advantage of the guide extension-assisted stenting technique is precise positioning of the stent at the side branch of a CBL especially in lesions where the side-branch ostium is challenging to visualize or ambiguous. The most appropriate CBLs suitable for this technique are the side-branch mono-ostial (medina 0, 0, 1), distal mono-ostial (medina 0, 1, 0), and potentially distal bi-ostial (medina 0, 1, 1) CBLs. In such lesions, the guide extension-assisted technique avoids stenting of the normal

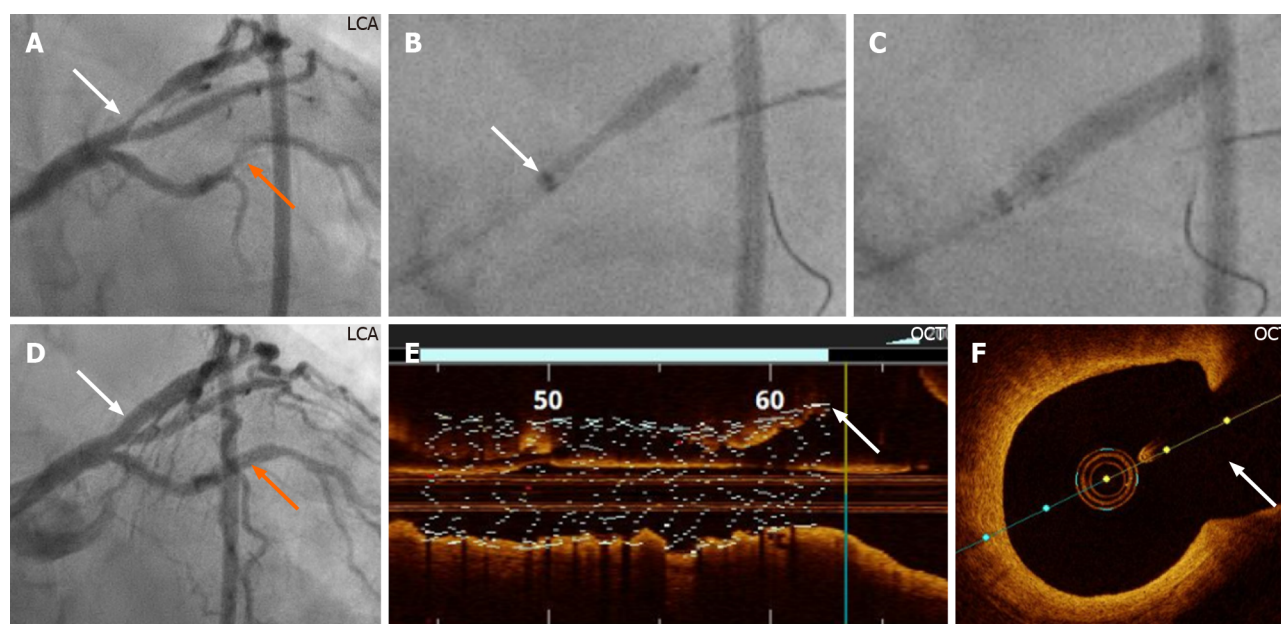


Figure 3 Demonstration of the guide extension technique during percutaneous coronary intervention of the bifurcation lesion of the second case. A: Left coronary artery (LCA) angiography reveals a stenosis in the obtuse marginal branch, (orange arrow) that was stented first after engagement of the left coronary artery with 7F-XB 3.5 guide catheter. There is also a distal mono-ostial (medina 0, 1, 0) left anterior descending artery (LAD)/diagonal bifurcation stenosis (white arrow), which was stented with the guide extension-assisted technique; B: Of note, angiography to visualize the angle between the diagonal branch and the distal segment of the main branch (LAD) was ambiguous, making it especially suitable for this novel technique. The GuideLiner, mounted on both the LAD and diagonal guidewires, was introduced to the carina site of the bifurcation. A Promus Premier 3.0 mm × 16 mm stent (Boston Scientific, Marlborough, MA, United States) positioned at the stenosis with the proximal stent balloon radio-opaque marker positioned on the GuideLiner radio-opaque marker just proximal to the tip of the GuideLiner (white arrow); C: The stent was implanted at a pressure of 22 atm; D: Angiographic final result (white and orange arrows); E and F: The implanted stent, checked by using OCT, is well-apposed to the vessel wall; the proximal stent edge can be seen positioned at the ostium of the distal segment of the main branch (E, white arrow), and no stent struts are seen to cover the diagonal branch ostium (F, white arrow). OCT: Optical coherence tomography.

proximal segment of the bifurcation with its subsequent risk of compromising the other branch of the bifurcation, and the subsequent need for re-crossing the stent struts for final kissing balloon inflation. The guide extension assisted technique can also be utilized for stenting the side-branch lesion in complex tri-ostial (medina 1, 1, 1) bifurcation lesions as demonstrated [Figure 4](#).

The bifurcation PCI principle of “keep it open” for the side branch and the provisional side-branch stenting, is currently regarded as the default procedure in the majority of bifurcation lesions, in part attributable to the fact that the two-stent techniques (crush and culotte) are more complex and may leave stent struts under expanded or malapposed, with increased risk of acute or subacute stent thrombosis and future in-stent-restenosis. However, in complex bifurcation lesions, the risk of compromising the side branch is substantial with a provisional approach. The incidence of side-branch occlusion was 13.4% for true bifurcation and 4.0% for non-true bifurcation lesions in a bifurcation stenting registry enrolling 2227 cases of bifurcation PCIs treated by the one-stent approach[14]. For this reason, a two-stent technique is frequently necessary for complex true bifurcation lesions. The DK-crush technique has been shown to be superior to the provisional side-branch stenting as well as to culotte techniques in terms of efficacy and safety[1,3]. Nonetheless, it must be recognized that the DK-crush technique is technically demanding and time consuming.

A simplified two-stent technique, which does not leave excess layers of stent struts at the bifurcation site, is thus highly desirable. The guide extension-assisted stenting technique for the side branch does not leave unnecessary stent metal in the main branch as may occur with crush and culotte techniques and consequently avoids the subsequent risks of subacute stent thrombosis and difficulties in performing rewiring, balloon re-crossing the stent strut toward the side branch, sequential balloon dilatation, and final kissing balloon inflation.

Limitations

The main limitation of the technique is that in Y-shaped side branch angulation, it is impossible to implant a stent covering the whole side-branch ostium circumferentially; in such cases the stent either protrudes somewhat into the main branch at the lower

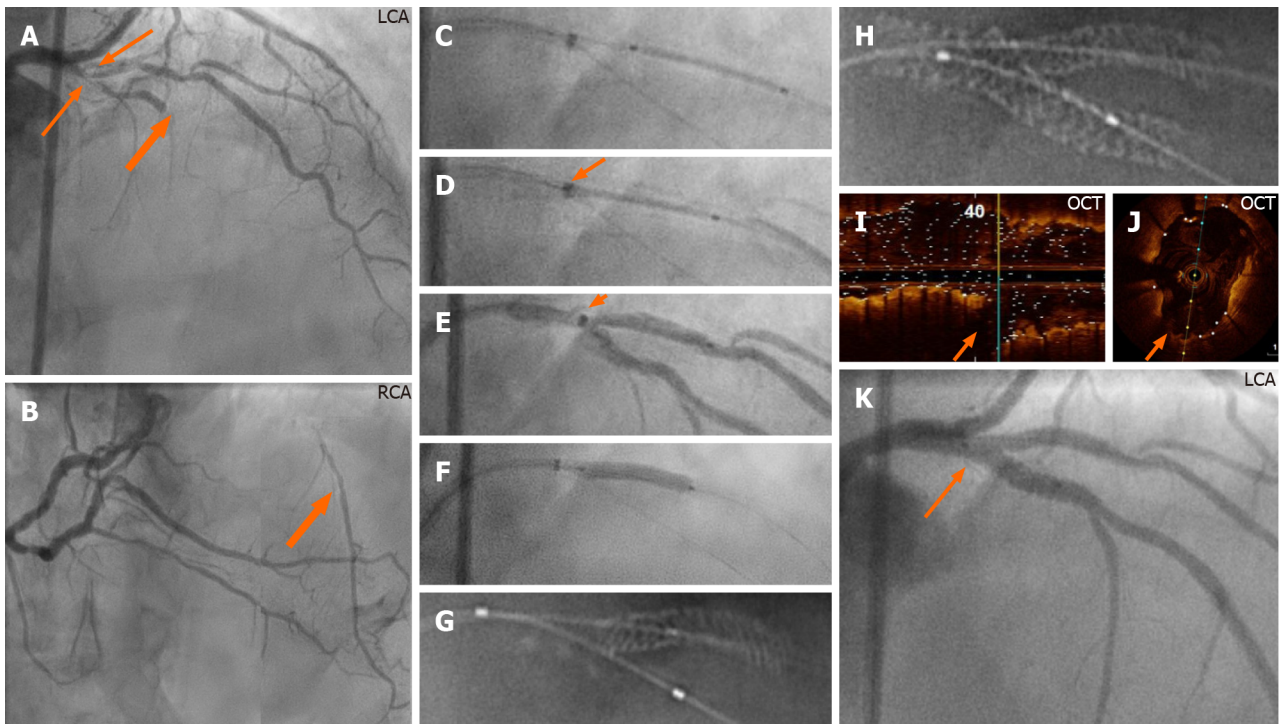


Figure 4 Demonstration of the guide extension technique in a complex true bifurcation lesion in the third case. A and B: Left (A) and right (B) coronary angiography. The left anterior descending artery (LAD) system reveals a proximal tri-ostial (medina 1, 1, 1) LAD/diagonal bifurcation stenosis where the LAD is subtotally occluded (thick orange arrows); B: The distal part of the LAD is filled by collateral circulation from the right coronary artery (thick orange arrow); C: The left coronary artery engaged with 7F-XB 3.5 guide catheter. After placing two guidewires, one in the LAD and another in the diagonal artery, and then conventional predilatation of both the main and the side branches, the GuideLiner, mounted on both guidewires, is positioned at the bifurcation carina. A Promus Premier (Boston Scientific, Marlborough, MA, United States) 2.5 mm × 16 mm stent is placed in the diagonal artery; D and E: The stent is retracted so that the proximal stent balloon radio-opaque marker overlaps the radio-opaque marker just proximal to the tip of the GuideLiner (D: Without contrast; E: With contrast; orange arrows); F: The stent was implanted at a pressure of 22 atm; the stent balloon pushes the guide extension catheter backwards; G: StentBoost imaging (Philips Medical Systems, Eindhoven, the Netherlands) shows that the proximal stent edge is positioned at the side-branch ostium. After stent implantation in the main branch with a Promus Premier (Boston Scientific, Marlborough, MA, United States) 3.0 mm × 24 mm stent post-dilated with a 3.5 mm high pressure balloon, rewiring of the side branch, sequential balloon dilatation, proximal optimization technique, and final kissing balloon inflation; H: StentBoost imaging reveals a precisely stented bifurcation lesion without unnecessary layers of struts; I and J: Optical coherence tomography confirmed a well-apposed stent and no struts covering the ostium of the diagonal artery (orange arrows); K: Final result (orange arrow). LCA: Left coronary artery; RCA: Right coronary artery.

edge of the side-branch ostium or misses somewhat the upper edge of the side-branch ostium. Care must also be taken to ensure that the proximal stent balloon marker is not proximal to the guide extension radio-opaque marker during stent implantation to avoid inadvertent “trapping” of the guide extension.

In addition, the use of guide extensions is associated with complications such as proximal dissection due to deep intubation, air embolism due to insufficient de-airing, and ischemia, which may limit the length of time that the equipment can be kept in place.

Finally, other guide extension catheters are currently available, including Guidezilla (Boston Scientific), Telescope (Medtronic), and Gudion (IMDS). The technique should be applicable to these platforms even though they were not tested in this reported experience.

CONCLUSION

A novel guide extension-assisted stenting technique for selected CBLs is described. This technique facilitates stenting only the diseased side branch or distal main segment in non-true bifurcation lesions without compromising the other branches. It may also facilitate precise stenting implantation in the side branch when using two-stent techniques in complex true bifurcation stenoses without leaving excess stent struts at the bifurcation site, which facilitates easier rewiring, balloon re-crossing, and performing final kissing balloon inflation. The technique may potentially reduce the risks of acute and subacute stent thrombosis as well as future in-stent restenosis and is worthy of further investigation.

REFERENCES

- 1 **Collet C**, Mizukami T, Grundeken MJ. Contemporary techniques in percutaneous coronary intervention for bifurcation lesions. *Expert Rev Cardiovasc Ther* 2018; **16**: 725-734 [PMID: 30221565 DOI: 10.1080/14779072.2018.1523717]
- 2 **Huang F**, Luo ZC. Cardiovascular outcomes associated with crush vs provisional stenting techniques for bifurcation lesions: a systematic review and meta-analysis. *BMC Cardiovasc Disord* 2019; **19**: 93 [PMID: 31014237 DOI: 10.1186/s12872-019-1070-y]
- 3 **Chen E**, Cai W, Chen LL. Crush vs Culotte stenting techniques for coronary bifurcation lesions: A systematic review and meta-analysis of clinical trials with long-term follow-up. *Medicine (Baltimore)* 2019; **98**: e14865 [PMID: 30946314 DOI: 10.1097/MD.00000000000014865]
- 4 **Y-Hassan S**, Lindroos MC, Sylvén C. A novel stenting technique for coronary artery bifurcation stenosis. *Catheter Cardiovasc Interv* 2009; **73**: 903-909 [PMID: 19455665 DOI: 10.1002/ccd.22031]
- 5 **Y-Hassan S**, Lindroos MC, Sylvén C. A Novel Descriptive, Intelligible and Ordered (DINO) classification of coronary bifurcation lesions. Review of current classifications. *Circ J* 2011; **75**: 299-305 [PMID: 21187658 DOI: 10.1253/circj.cj-10-0614]
- 6 **Medina A**, Suárez de Lezo J, Pan M. [A new classification of coronary bifurcation lesions]. *Rev Esp Cardiol* 2006; **59**: 183 [PMID: 16540043 DOI: 10.1157/13084649]
- 7 **Burzotta F**, Trani C, Sianos G. Jailed balloon protection: a new technique to avoid acute side-branch occlusion during provisional stenting of bifurcated lesions. Bench test report and first clinical experience. *EuroIntervention* 2010; **5**: 809-813 [PMID: 20142195 DOI: 10.4244/eijv5i7a135]
- 8 **Shishido K**, Moriyama N, Hayashi T, Yokota S, Miyashita H, Mashimo Y, Yokoyama H, Nishimoto T, Ochiai T, Tobita K, Yamanaka F, Mizuno S, Tanaka Y, Murakami M, Takahashi S, Saito S. The efficacy of modified jailed balloon technique for true bifurcation lesions. *Catheter Cardiovasc Interv* 2020; **96**: 20-28 [PMID: 32096918 DOI: 10.1002/ccd.28812]
- 9 **Colombo A**, Stankovic G, Orlic D, Corvaja N, Liistro F, Airolidi F, Chieffo A, Spanos V, Montorfano M, Di Mario C. Modified T-stenting technique with crushing for bifurcation lesions: immediate results and 30-day outcome. *Catheter Cardiovasc Interv* 2003; **60**: 145-151 [PMID: 14517916 DOI: 10.1002/ccd.10622]
- 10 **Chevalier B**, Glatt B, Royer T, Guyon P. Placement of coronary stents in bifurcation lesions by the "culotte" technique. *Am J Cardiol* 1998; **82**: 943-949 [PMID: 9794349 DOI: 10.1016/s0002-9149(98)00510-4]
- 11 **Mitomo S**, Naganuma T, Nakamura S, Tahara S, Ishiguro H. Potential advantages of the GuideLiner® catheter: insights from optical coherence tomography. *Cardiovasc Interv Ther* 2017; **32**: 56-61 [PMID: 26531167 DOI: 10.1007/s12928-015-0365-x]
- 12 **Warisawa T**, Naganuma T, Nakamura S. Off-label use of 7Fr GuideLiner in the bifurcation coronary intervention protecting 2 side branches. *Cardiovasc Interv Ther* 2017; **32**: 392-395 [PMID: 27757830 DOI: 10.1007/s12928-016-0435-8]
- 13 **Kassimis G**, Raina T. GuideLiner extension catheter-facilitated side strut stenting technique for the treatment of right coronary artery ostial in-stent restenosis. *Cardiovasc Revasc Med* 2018; **19**: 133-136 [PMID: 29117919 DOI: 10.1016/j.carrev.2017.09.010]
- 14 **Hahn JY**, Chun WJ, Kim JH, Song YB, Oh JH, Koo BK, Rha SW, Yu CW, Park JS, Jeong JO, Choi SH, Choi JH, Jeong MH, Yoon JH, Jang Y, Tahk SJ, Kim HS, Gwon HC. Predictors and outcomes of side branch occlusion after main vessel stenting in coronary bifurcation lesions: results from the COBIS II Registry (COronary BIfurcation Stenting). *J Am Coll Cardiol* 2013; **62**: 1654-1659 [PMID: 23954335 DOI: 10.1016/j.jacc.2013.07.041]



Published by **Baishideng Publishing Group Inc**
7041 Koll Center Parkway, Suite 160, Pleasanton, CA 94566, USA

Telephone: +1-925-3991568

E-mail: bpgoffice@wjgnet.com

Help Desk: <https://www.f6publishing.com/helpdesk>

<https://www.wjgnet.com>

