


World Journal of *Cardiology*

World J Cardiol 2022 March 26; 14(3): 108-189



REVIEW

- 108 Fundamentals of percutaneous coronary bifurcation interventions
Kirat T
- 139 Arrhythmic risk stratification in ischemic, non-ischemic and hypertrophic cardiomyopathy: A two-step multifactorial, electrophysiology study inclusive approach
Arsenos P, Gatzoulis KA, Tsiachris D, Dilaveris P, Sideris S, Sotiropoulos I, Archontakis S, Antoniou CK, Kordalis A, Skiadas I, Toutouzas K, Vlachopoulos C, Tousoulis D, Tsioufis K
- 152 Climatic influences on cardiovascular diseases
Abrignani MG, Lombardo A, Braschi A, Renda N, Abrignani V

MINIREVIEWS

- 170 Predictors of persistence of functional mitral regurgitation after cardiac resynchronization therapy: Review of literature
Russo E, Russo G, Braccio M, Cassese M

ORIGINAL ARTICLE

Retrospective Study

- 177 Risk profiles and outcomes of patients receiving antibacterial cardiovascular implantable electronic device envelopes: A retrospective analysis
Woodard DA, Kim G, Nilsson KR

LETTER TO THE EDITOR

- 187 Electrocardiographic alterations in patients with chronic obstructive pulmonary disease
Eyuboglu M

ABOUT COVER

Editorial Board Member of *World Journal of Cardiology*, Wattana Leowattana, MD, MSc, PhD, Associate Professor, Senior Researcher, Staff Physician, Clinical Tropical Medicine, Mahidol University, Siriraj Hospital, Faculty of Medicine, Rachatawee 10400, Bangkok, Thailand. leowattana@yahoo.com

AIMS AND SCOPE

The primary aim of *World Journal of Cardiology* (*WJC*, *World J Cardiol*) is to provide scholars and readers from various fields of cardiology with a platform to publish high-quality basic and clinical research articles and communicate their research findings online.

WJC mainly publishes articles reporting research results and findings obtained in the field of cardiology and covering a wide range of topics including acute coronary syndromes, aneurysm, angina, arrhythmias, atherosclerosis, atrial fibrillation, cardiomyopathy, congenital heart disease, coronary artery disease, heart failure, hypertension, imaging, infection, myocardial infarction, pathology, peripheral vessels, public health, Raynaud's syndrome, stroke, thrombosis, and valvular disease.

INDEXING/ABSTRACTING

The *WJC* is now abstracted and indexed in Emerging Sources Citation Index (Web of Science), PubMed, PubMed Central, Scopus, Reference Citation Analysis, China National Knowledge Infrastructure, China Science and Technology Journal Database, and Superstar Journals Database. The 2021 edition of Journal Citation Reports® cites the 2020 Journal Citation Indicator (JCI) for *WJC* as 0.36. The *WJC*'s CiteScore for 2020 is 0.3, and Scopus CiteScore rank 2020: Cardiology and Cardiovascular Medicine is 289/317.

RESPONSIBLE EDITORS FOR THIS ISSUE

Production Editor: Hua-Ge Yin; Production Department Director: Xiang Li; Editorial Office Director: Ya-Juan Ma.

NAME OF JOURNAL

World Journal of Cardiology

ISSN

ISSN 1949-8462 (online)

LAUNCH DATE

December 31, 2009

FREQUENCY

Monthly

EDITORS-IN-CHIEF

Ramdas G Pai, Dimitrios Tousoulis, Marco Matteo Ciccone, Pal Pacher

EDITORIAL BOARD MEMBERS

<https://www.wjnet.com/1949-8462/editorialboard.htm>

PUBLICATION DATE

March 26, 2022

COPYRIGHT

© 2022 Baishideng Publishing Group Inc

INSTRUCTIONS TO AUTHORS

<https://www.wjnet.com/bpg/gerinfo/204>

GUIDELINES FOR ETHICS DOCUMENTS

<https://www.wjnet.com/bpg/GerInfo/287>

GUIDELINES FOR NON-NATIVE SPEAKERS OF ENGLISH

<https://www.wjnet.com/bpg/gerinfo/240>

PUBLICATION ETHICS

<https://www.wjnet.com/bpg/GerInfo/288>

PUBLICATION MISCONDUCT

<https://www.wjnet.com/bpg/gerinfo/208>

ARTICLE PROCESSING CHARGE

<https://www.wjnet.com/bpg/gerinfo/242>

STEPS FOR SUBMITTING MANUSCRIPTS

<https://www.wjnet.com/bpg/GerInfo/239>

ONLINE SUBMISSION

<https://www.f6publishing.com>



Fundamentals of percutaneous coronary bifurcation interventions

Tamer Kirat

Specialty type: Cardiac and cardiovascular systems

Provenance and peer review: Invited article; Externally peer reviewed.

Peer-review model: Single blind

Peer-review report's scientific quality classification

Grade A (Excellent): 0
Grade B (Very good): B
Grade C (Good): 0
Grade D (Fair): 0
Grade E (Poor): 0

P-Reviewer: Guo L

Received: March 17, 2021

Peer-review started: March 17, 2021

First decision: July 8, 2021

Revised: July 22, 2021

Accepted: February 22, 2022

Article in press: February 22, 2022

Published online: March 26, 2022



Tamer Kirat, Department of Cardiology, Yücelen Hospital, Muğla 48000, Turkey

Corresponding author: Tamer Kirat, MD, Doctor, Staff Physician, Department of Cardiology, Yücelen Hospital, Kötekli Mevkii, Muğla 48000, Turkey. tamekir@hotmail.com

Abstract

Coronary bifurcation lesions (CBLs) account for 15%-20% of all percutaneous coronary interventions. The complex nature of these lesions is responsible for poorer procedural, early and late outcomes. This complex lesion subset has received great attention in the interventional cardiac community, and multiple stenting techniques have been developed. Of these, the provisional stenting technique is most often the default strategy; however, the elective double stenting (EDS) technique is preferred in certain subsets of complex CBLs. The double kissing crush technique may be the preferred EDS technique because of its efficacy and safety in comparative trials; however, this technique consists of many steps and requires training. Many new methods have recently been added to the EDS techniques to provide better stent scaffolding and to reduce early and late adverse outcomes. Intravascular imaging is necessary to determine the interventional strategy and postinterventional results. This review discusses the basic concepts, contemporary percutaneous interventional technical approaches, new methods, and controversial treatment issues of CBLs.

Key Words: Percutaneous coronary intervention; Coronary artery disease; Drug-eluting stents; Bifurcation lesion; Stenting technique; Left main intervention

©The Author(s) 2022. Published by Baishideng Publishing Group Inc. All rights reserved.

Core Tip: Coronary bifurcation lesions are one of the most challenging subsets in percutaneous interventions. Many different interventional techniques have been used to overcome the relatively poor procedural and long term outcomes of these lesions of great interest. In this review, basic aspects of coronary bifurcation lesions and step-by-step classical stenting techniques, as well as recently introduced techniques, modifications, trials and important issues in the latest guidelines are discussed.

Citation: Kirat T. Fundamentals of percutaneous coronary bifurcation interventions. *World J Cardiol* 2022; 14(3): 108-138

URL: <https://www.wjgnet.com/1949-8462/full/v14/i3/108.htm>

DOI: <https://dx.doi.org/10.4330/wjc.v14.i3.108>

INTRODUCTION

Percutaneous interventions of coronary bifurcation lesions (CBLs) are not only technically challenging, with lower procedural success and higher complication rates, but also have higher thrombosis and restenosis rates than nonbifurcation lesions[1-3]. The broad anatomical (*i.e.*, bifurcation site and angle, and vessel diameters) and pathological (*i.e.*, severity, locations and lengths of the atherosclerotic plaques) spectrum of CBL, as well as dynamic changes (carina, plaque shift and dissection) during intervention are responsible for the complexity of these lesions[3,4]. Many stenting and other interventional techniques have been developed and are used to provide optimum stent scaffolding, resulting in fewer clinical adverse outcomes. Operators should be familiar with these techniques and the basic aspects of CBLs.

BASIC ASPECTS

Anatomy

In epicardial coronary arteries, bifurcations show a fractal geometry[5] (a fractal is a geometric shape in which every smaller structure is similar to the whole part). This geometry provides minimum energy consumption and the optimum amount of blood required for the underlying myocardium[6]. A coronary bifurcation consists of a flow divider (carina) and three vessel segments: The proximal main vessel (PMV), the distal main vessel (DMV) and the side branch (SB) (Figure 1). There is a constant relationship between these three vessels that was identified by Murray's law 95 years ago[7] as:

$$(\text{Diameter of PMV})^3 = (\text{Diameter of DMV})^3 + (\text{Diameter of SB})^3$$

Nearly a decade ago, this law was modified in human coronary arteries by the Huo-Kassab law[8] as:

$$(\text{Diameter of PMV})^{7/3} = (\text{Diameter of DMV})^{7/3} + (\text{Diameter of SB})^{7/3}$$

Nearly at the same time, Finet's formula was created by IVUS measurements in normal human coronary arteries[9] as:

$$(\text{Diameter of PMV}) = 0.678 \text{ (i.e., approximately } 2/3) \times (\text{Diameter of DMV} + \text{Diameter of SB})$$

Huo *et al*[10] compared these 2 Laws and Finet's formula in the epicardial coronary bifurcations of patients and swine in a later study. They found that Huo-Kassab law accurately predicts all size diameters of the epicardial coronary bifurcation vessels whereas Murray's law and Finet's formula can only do so in certain size subsets[10]. However, due to its simplicity, Finet's formula is the most commonly used in clinical practice in most angiography units.

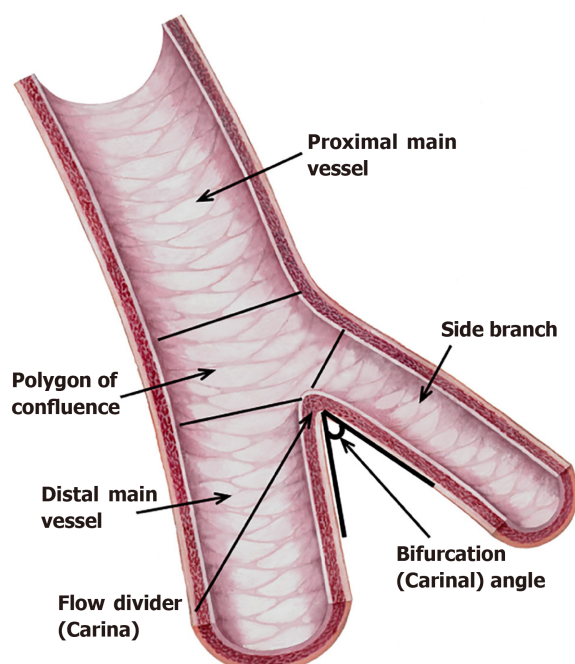
The polygon of confluence (POC) is an independent area between the PMV, DMV and SB whose boundaries are formed by the lines drawn vertically in the ostium of branches and at the end of the PMV (Figure 1)[11,12]. Finally, the bifurcation angle (carinal angle) is important in accessing the SB and in the decision of the stent treatment strategy.

Definition

A bifurcation lesion is a major epicardial coronary artery stenosis next to and/or including the ostium of a significant side branch[13,14]. A significant SB is a branch whose severe narrowing or acute occlusion before or during intervention can cause considerable ischemia or a new infarction area that will worsen the clinical course of a particular patient. To determine the significance of the SB, not only the diameter, length, location and collateral function of the SB but also the symptoms, left ventricular function and viability of the supplied myocardium should be evaluated[13,14].

Pathophysiology of atherosclerosis in CBL

Bifurcations are among the sites most affected by atherosclerotic processes in the coronary tree. *In vitro* and recent *in vivo* studies on the anatomy and flow patterns of coronary bifurcations have shown that local flow disturbances and thus endothelial shear stress (ESS) play the most important role in the localization and progression of atherosclerotic plaques[15]. ESS is the tangential force caused by the friction of the flowing blood on the endothelial surface[16]. The major determinants of ESS are the blood viscosity and the spatial gradient of the blood velocity. Endothelial mechanoreceptors sense ESS; and in response to high ESS, these receptors induce many intracellular signaling pathways resulting in the expression of many atheroprotective genes and suppression of many proatherogenic genes. Conversely, in the case of low or oscillatory ESS, atheroprotective genes are suppressed and proatherogenic genes that promote atherosclerosis are upregulated[15-17]. Indeed, in IVUS and autopsy studies of bifurcation



DOI: 10.4330/wjc.v14.i3.108 Copyright © The Author(s) 2022.

Figure 1 Coronary bifurcation anatomy.

lesions, atherosclerosis was most frequently demonstrated in the lateral walls of MVs and side branches where ESS was low and oscillatory and uncommon in the carina where ESS was high[18]. Moreover, the carinal angle was found to affect the severity of atherosclerosis as larger angles have been correlated with increased plaque burden[19]. This is again explained by the role of ESS since larger angles produce lower and more oscillatory ESS in the lateral walls of the bifurcation vessels. Finally, in addition to its most important role in plaque initiation and progression, low ESS has also been found to be associated with rupture-prone atherosclerotic plaque formation[19]. Thus, CBLs have an increased tendency for plaque rupture, platelet aggregation and atherothrombosis[20].

Classification

Various angiographic classifications of CBL have been proposed[21]. Because of its simplicity, the easiest to remember and most prevalently used is the Medina classification[22]. This classification is established on the presence ("1") or absence ("0") of significant stenosis ($\geq 50\%$) in the proximal main vessel (MV), distal MV and SB in CBLs, respectively (Figure 2). According to this classification, two different types are described: "true" and "non-true" CBLs. Significant stenosis ($\geq 50\%$) in both vessels (proximal MV and/or distal MV and SB), *i.e.*, Medina 1,1,1/1,0,1 and 0,1,1 classes are defined as "true", while all others are defined as "non-true" CBLs. "True" bifurcation lesions are more complex and more difficult to treat with poorer outcomes than "non-true" types[23]. However, in true bifurcation lesions, Medina 1,1,1 and 0,1,1 lesions were found to have a higher risk of cardiac death, myocardial infarction (MI), and more SB occlusion than Medina 1,0,1 lesions[23]; and only these two classes have been taken as the criterion or one of the criteria of complex true lesions in many bifurcation (especially left main) trials.

Finally, the Medina classification does not consider other important information that may direct treatment strategies, such as lesion size and length, calcification and bifurcation angles. Therefore, additional modalities such as multislice computed tomography (MSCT), intravascular ultrasound (IVUS), optical coherence tomography (OCT) and fractional flow reserve (FFR) or other functional tests may be necessary to clarify the true classification of a bifurcation lesion and to determine the treatment strategy[24].

PERCUTANEOUS CORONARY INTERVENTION (PCI) TECHNIQUES

Classification

Many stenting techniques have been developed and published. For simplicity, these techniques were classified by the European Bifurcation Club (EBC) as "MADS" in 2008. However, some techniques have been abandoned due to adverse outcomes or lack of effectivity. Therefore, an updated new classification called "MADS-2" was created by the EBC in 2020[25]. This classification is based on the location of the

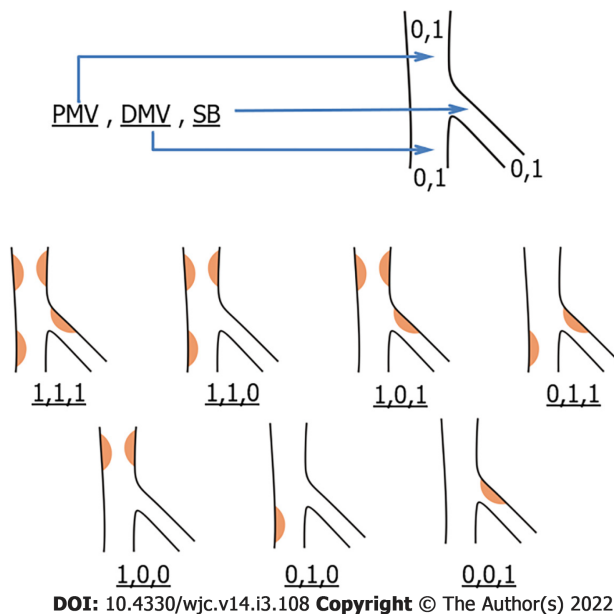


Figure 2 Medina classification. “1” indicates $\geq 50\%$ stenosis, and “0” indicates $< 50\%$ stenosis. Atherosclerosis is most often seen in the lateral walls of vessels where endothelial shear stress is low and oscillatory. DMV: Distal main vessel; PMV: Proximal main vessel; SB: Side branch.

first stent implanted (as Main vessel, Across side branch, Double lumen in proximal MV or Side branch). Balloon applications and dedicated bifurcation stent types are added to the original form in this new classification[25].

Although MADS-2 involves many stenting techniques, the most widely used major bifurcation stenting techniques recommended by the EBC are as follows[25]: (1) One-stent techniques: The provisional stenting technique (PST) and inverted provisional stenting technique; and (2) Two-stent techniques (Elective, or bail-out in PST): (a) T/T and protrusion (TAP) stenting; (b) Culotte/inverted culotte stenting techniques; and (c) Double kissing (DK)-crush technique.

Vascular access and guiding catheter selection

In one-stent techniques, most CBLs can be treated transradially or transfemorally using a 6 Fr guiding catheter (GC). However, if a rotablator with a burr size ≥ 2 mm is used or more than two balloons are used simultaneously in the GC, a 7 Fr or larger GC is required[26]. Although transfemoral is the most preferred route in this situation, an increasing number of operators prefer the transradial route using slender sheaths or sheathless guiding catheters.

Two-stent techniques can also be performed using 6 Fr GC except when there are two stents in the GC at the same time, such as mini-crush, V or simultaneous kissing stenting techniques[27].

Due to the challenging interventional nature of CBLs, guiding catheters with strong support (such as extra back-up guiding catheters for the left coronary artery and AL 0.75, AL1 or AR2 for the right coronary artery (RCA)) should be preferred[28].

Optimal views for bifurcation lesions[28,29]: (1) Left main coronary artery (LMCA) bifurcation: (a) Working view: RAO caudal ($0-30^\circ$, $25-30^\circ$); and (b) Side branch ostium visualization: LAO caudal ($30-60^\circ$, $25-30^\circ$), AP caudal (0 , $45-55^\circ$); (2) LAD-first diagonal bifurcation: (a) Working view: RAO cranial (10° , 40°); and (b) Side branch ostium visualization: AP/LAO cranial ($0-45^\circ$, $25-70^\circ$); (3) For early diagonals: LAO caudal ($45-55^\circ$, $25-30^\circ$); (4) LCx-first marginal: (a) Working view: RAO caudal ($0-15^\circ$, 25°); (b) Side branch ostium visualization: AP caudal (0 , $25-40^\circ$), LAO caudal ($45-55^\circ$, $25-30^\circ$); and (5) RCA-PDA/PL: (a) Working view: LAO $35-50^\circ$; and (b) Side branch ostium visualization: AP/LAO cranial ($0-55^\circ$, $30-40^\circ$).

Which technique should be selected? The PST or the elective double stenting technique?

Most of the randomized comparative trials prior to the mid-2010s showed no difference in major adverse cardiovascular events (MACE) between the PST and elective double stenting (EDS) techniques [26,30,31]. Even, lower mortality rates were found for the PST compared to EDS in two recent meta-analyses[32,33]. As a result, the provisional stenting technique has been recommended as the default strategy for CBLs in the guidelines and consensus statements for more than 15 years. However, it should be noted that the EDS techniques in these trials and meta-analyses were the culotte, T, and crush techniques. After the introduction of the DK-crush technique, in 2011, Chen *et al*[34] showed that there was a significant reduction in target lesion revascularization (TLR) and target vascular revascularization (TVR) rates in favor of the DK-crush technique *vs* the PST with no MACE differences in complex true

bifurcation lesions in the DKCRUSH II trial. Later, the DKCRUSH III trial showed that the culotte stenting technique was worse than the DK-crush technique in terms of MACE in patients with unprotected left main (LMCA) bifurcation lesions[35]. Moreover, the DKCRUSH V study presented in 2017 found a lower rate of target lesion failure (TLF) at 1 year with the DK-crush technique than with the PST in complex true LMCA bifurcation lesions[36].

Recently, the 3-year outcomes of the DKCRUSH V trial were published and confirmed the one-year results and additionally showed a reduction in the stent thrombosis rate in favor of the DK-crush technique[37]. Crimi *et al*[38] found that the DK-crush technique lowered device-oriented clinical events (defined as a composite of cardiac death, target-vessel MI, stent thrombosis and TLR or TVR) *vs* the PST and other EDS techniques in their recent meta-analysis. In another concurrent network meta-analysis, Di Gioia *et al*[39] showed that TLR was significantly lower with the DK-crush technique than with the PST and other EDS techniques with no differences in cardiac death, MI or stent thrombosis rates. In addition, in this meta-analysis, a clinical benefit was observed with EDS techniques over PST in CBL with SB lesion lengths ≥ 10 mm. In the recently published DEFINITION II trial, complex bifurcation lesions were defined by the sum of various criteria, as shown in Table 1. In this trial, the EDS technique (DK-crush 77.8%, culotte 17.9%, and other 4.3%) provided a significant reduction in TLF (mainly driven by target vessel MI and clinically driven TLR) compared to the PST in the defined complex bifurcation lesions at one year[40].

Despite the favorable results of the DK-crush technique in randomized studies and two meta-analyses, the recent guidelines still recommend the PST as the default strategy for complex CBLs and a class IIb indication for the DK-crush technique over the PST in true LMCA bifurcations[25,41-43]. The reason for this may be some reservations that have been described[30]: (1) The DK-crush technique has multiple steps and is a challenging technique; (2) The DKCRUSH trials mostly come from the same group of interventional experts who have performed this procedure for many years; and (3) The PST results in these trials were worse than previously published ones, which might be associated with a high SB stenting rate (29%-47%) due to the high rate of long SB lesions (mean 15-17 mm).

When deciding between the PST and EDS, the high risk of SB occlusion should also be considered, as SB occlusion may result in serious adverse clinical outcomes[44]. SB occlusion predictors by angiography, IVUS and OCT have been described recently[44,45]. Angiographically, plaque on the same side of the SB, SB stenosis $> 50\%$, POC stenosis $> 50\%$, bifurcation angle $> 70^\circ$, MV/SB diameter ratio (diameter of PMV+DMV/ $2 \times$ diameter of SB) > 1 and a low MV TIMI flow grade were found to be predictors of SB occlusion after MV stenting. A risk score was described based on these predictors[44]. According to this risk score, higher stenosis rates, larger bifurcation angles, larger MV/SB diameter ratios, a lower TIMI flow grade, and more predictors result in higher SB occlusion rates[44].

The recently published EBC-MAIN study, which compared the PST and EDS techniques in LMCA bifurcation lesions, showed that there were fewer MACE in the PST than EDS, although the difference was statistically insignificant. The authors consequently recommended the PST as the default strategy for LMCA bifurcation lesions. However, it should be noted that the DK-crush technique was used in only 5% of the EDS patients in this trial. In addition, the mean lesion lengths of the side vessels were not long: 5.8 cm and 7.9 cm in the PST and EDS patients, respectively[46].

Consequently, for non-true CBL, the default strategy is the PST[47]. In true complex CBL (Medina 1,1,1 or 0,1,1), if the SB is ≥ 2.5 mm and the SB lesion length ≥ 10 mm or the likelihood of SB occlusion is high or SB wiring is difficult, it is better to choose EDS; otherwise, the PST is preferred[38,39,41,45,48]. In true non-complex CBL (Medina 1,0,1), the inverted PST may be an appropriate treatment if there is no large difference between the SB and the PMV diameter[42]; otherwise, and in the case of the above risks, EDS may be preferred[39,45,48,49]. A proposed algorithm for choosing between the PST/inverted PST and the EDS technique is shown in Figure 3.

The ongoing BBK3 trial will provide more data on the outcomes of the PST or EDS techniques in non-LMCA bifurcation lesions[50].

The choice between the different EDS techniques depends partially on the bifurcation angle. The T technique can only be applied at bifurcation angles very close to 90° [25]. The TAP technique can be performed at bifurcation angles from 70° - 90° . Culotte/inverted culotte stenting and the DK-crush techniques (unlike the crush technique) can be implemented regardless of the bifurcation angle[51,52]; however, applying the culotte technique at $< 70^\circ$ angles gives better results[35]. If the bifurcation angle is from 70° - 90° , due to simplicity and familiarity, an increasing number of operators are using the T/TAP technique not only when a second stent is required in the PST[53] but also in the EDS technique as the first-line therapy and perform the culotte/inverted culotte or DK-crush techniques if the angle is $< 70^\circ$ [41,54].

In conclusion, in view of recent data, the DK-crush technique may be preferred over the other two-stent techniques regardless of the bifurcation angle; however, it is a complex procedure with many steps, and the operator's familiarity with a particular technique is an important factor in the choice of which EDS technique to perform and in obtaining the best result[45].

Table 1 DEFINITION criteria for a complex coronary bifurcation lesion[40]

Major criteria	Complex lesion definition	Minor criteria
For left main bifurcation (Major 1)	Major 1 or Major 2 + any 2 minor criteria	> Mild calcification
SB lesion length ≥ 10 mm and SB diameter stenosis $\geq 70\%$		Multiple lesions
		Bifurcation angle $< 45^\circ$ or $> 70^\circ$
For non-left main bifurcation (Major 2)		MV-RVD < 2.5 mm
SB lesion length ≥ 10 mm and SB diameter stenosis $\geq 90\%$		MV lesion length ≥ 25 mm
		Thrombus-containing lesions

All bifurcation lesions are in Medina 1,1,1 or 0,1,1. MV: Main vessel; RVD: Reference vessel diameter; SB: Side branch

PST

The step-by-step PST is shown in [Figure 4](#).

Wiring the vessels

In addition to the MV, the SB should also be wired in all CBLs. This wire helps to prevent SB occlusion after MV stenting, serves as a marker in case of SB occlusion, widens the angle between the PMV and SB for easier access, enhances support of the guiding catheter, and finally can be used as a rescue balloon guidewire that will be described later. To prevent the two wires from wrapping, the more difficult vessel (mostly the SB) should be wired first, and the second wire should be inserted without much manipulation.

Wire types and shaping

The types of wires are left to the operator's preference. Any type of wire (hydrophilic with or without polymer coating and hydrophobic) can be used[55,56]. One necessary point is not to jail the radiopaque tip part of the wire in the SB ostium during MV stenting.

Both wires should be ready for the exchange technique if needed after MV stenting. To accomplish this, the MV guidewire tip should be angled so that its length will be longer than the proximal MV reference diameter to reach the SB ostium. A 1-1.5 mm secondary bend can also be added to the tip to hook the struts of the MV stent[57]. The SB wire should be prepared as a sharp angled short tip that will make it easier to create a "U" shape to pass through the MV stent during wire exchange[58]. The MV wire should not be pushed too distally in order to maintain the shape of the tip for exchange and to reduce the risk of distal perforation or dissection that can occur during many maneuvers.

Troubleshooting SB wiring problems

SB wiring may be difficult in the following circumstances: a bifurcation angle greater than 70° - 90° , severe ostial SB stenosis, MV stenosis or severe calcifications in the proximal MV and/or ostial SB. In addition, tortuosity before or at the SB take-off may flatten or change the angle of the wire, resulting in difficult SB wiring[58].

Possible solutions for solving the SB wiring problem are the following[52,58]: (1) If the problem is wide angulation, a wide smooth bend or double bend shape given to the tip can help; (2) The workhorse wire can be replaced with a stiffer or hydrophilic polymer-coated wire. Stiffer wires are preferred first because hydrophilic wires can easily go subintimally and cause dissection or perforation; (3) Pull-back wire technique: A wide smooth bend or double bend wire is advanced into the DMV and pulled back to intubate the SB ostium. After intubating, a gentle counterclockwise rotation allows the wire to advance in the SB; (4) Reverse wire technique: When the SB has an excessively angled take-off (greater than 90°), a polymer-jacket wire with a 3-5 cm tip bent 180° , like a hairpin, is used in this technique ([Figure 5](#)). The wire is advanced in the DMV and pulled back to the bifurcation, and an attempt is made to enter the SB ostium. After intubation, the wire is gently withdrawn and gently rotated counterclockwise to allow the wire to advance in the SB; (5) A dual lumen microcatheter, a steerable-tip microcatheter (Venture, Teleflex, Wayne, PA, United States) or an angled microcatheter (SuperCross 45-90-120°-XT, Teleflex) can be used to direct the wire to the SB; (6) When there is a large plaque burden that prevents wiring the SB, debulking techniques such as rotational/orbital atherectomy or laser may be used; (7) Balloon dilatation of the MV to modify the plaque is performed by many operators as a last effort. However, it can cause plaque and/or carina shift, resulting in SB occlusion; and (8) Finally, if the SB cannot be wired, the decision to abandon the procedure can be made based on the patient's clinicopathological condition.

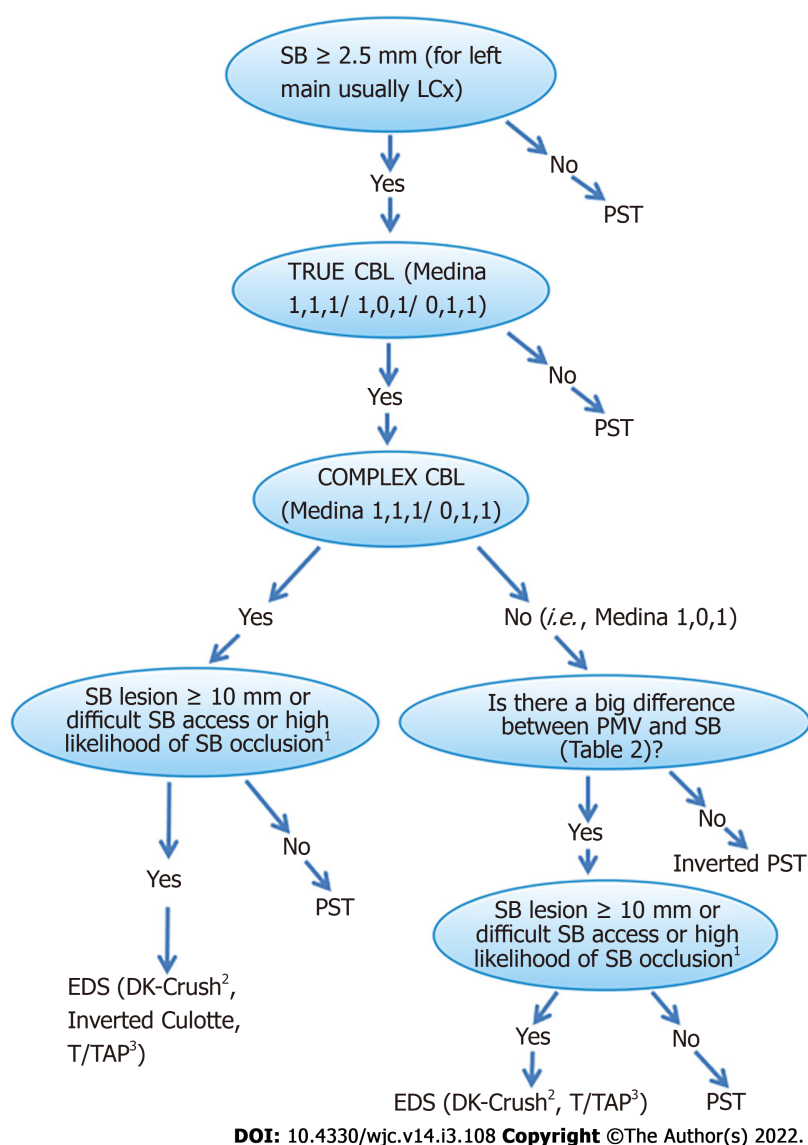


Figure 3 Proposed algorithm for selecting an optimum percutaneous coronary intervention strategy in both left main coronary artery and non-left main coronary artery bifurcation lesions. ¹Plaque on the same side of SB, SB stenosis > 50%, POC stenosis > 50%, bifurcation angle > 70%, MV/SB diameter ratio (diameter of PMV+DMV/2×diameter of SB) >1 and low MV TIMI flow grade are predictors of a high likelihood of SB occlusion. The larger the size of the numbers and/or the lower the TIMI flow grade and/or the more predictors, the higher the risk of SB occlusion. A recently created SB occlusion risk score may be used[44]. ²The DK-crush technique seems to be preferable to the other EDS techniques in view of the recent data; however, the operator's experience is decisive in the choice between the EDS technique and is important in obtaining the best result. ³The TAP technique cannot be considered the upfront technique in cases with difficult SB access and a high risk of SB occlusion because of SB stenting after MV stenting. CBL: Coronary bifurcation lesion; EDS: Elective double stenting; LCx: Left circumflex artery; LMCA: Left main coronary artery; MV: Main vessel; POC: Polygon of confluence; PST: Provisional stenting technique; SB: Side branch.

Predilation of the MV and the SB

Optimal preparation of the MV is necessary before stenting. Therefore, the operator can decide to predilate the MV and/or perform any debulking procedure according to the MV lesion properties.

Routine predilation of the SB has been a controversial issue in the PST. Predilation aims to prevent SB closure after MV stenting; however, it can cause dissection that may prevent guidewire advancement during wire exchange or may require an extra stent in the SB. A prospective randomized study showed that SB predilation resulted in improved flow with less need to treat the SB[59]. However, another double-blind smaller randomized study and a recent meta-analysis of eight trials demonstrated the opposite: SB predilation increased SB intervention rates and made no difference in procedural angiographic and long-term major cardiovascular outcomes[60,61]. Consequently, it seems that routine predilation of the SB cannot be recommended currently. Conditions that favor SB predilation with an undersized non-compliant balloon are severe ostial SB narrowing, extensive SB calcification, difficult SB access or decreased flow after MB predilation and/or debulking[14,49].

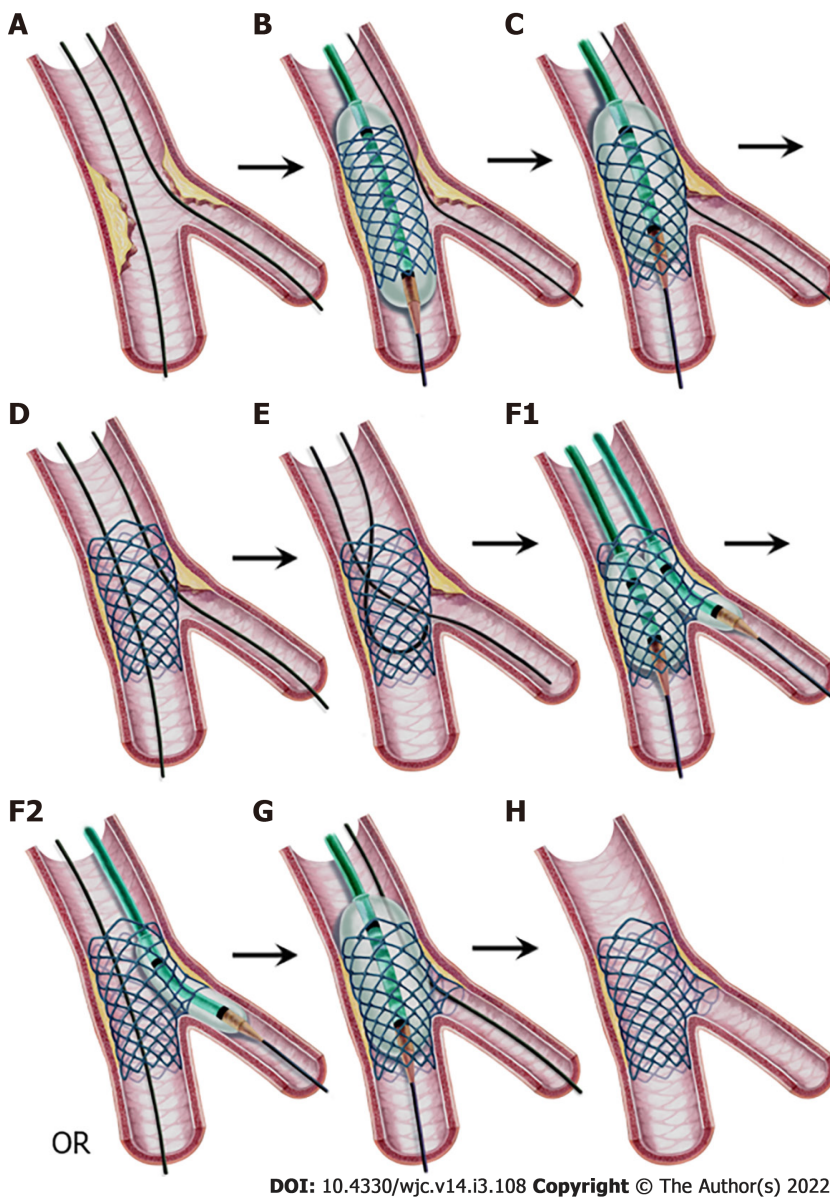


Figure 4 Provisional stenting technique, step-by-step. A: Both branches are wired; B: A stent sized to the distal MV diameter is implanted in the MV; C: Proximal optimization technique (POT) application with a balloon sized to the proximal MV diameter with its distal shoulder aligned to the carina; D: Stent view after POT. If the result is satisfactory, stop here. If not, proceed to step E; E: Guidewire exchange; First, the SB is wired through the most distal cell. Second, the retracted and released SB wire is advanced into the distal MV as a “U” shape; F1: Kissing balloon inflation sized to branch diameters, or F2: SB ostium ballooning as a part of the POT-side-POT technique; G: Final POT; and H: Final result. MV: Main vessel; POT: Proximal optimization technique; SB: Side branch.

When the SB is predilated, the angiographic result should be carefully evaluated before MV stenting. In situations where the SB is compromised, such as dissection or difficult SB access, the operator should be ready to change the stenting strategy to another strategy, such as the inverted PST or the DK-crush technique[49].

Newer side branch protection techniques

To prevent side branch occlusion during the PST, various novel techniques have been developed recently: the pre-kissing technique, jailed balloon, jailed semi-inflated balloon and modified jailed balloon techniques. The pre-kissing technique involves the simultaneous dilation of two undersized balloons (one in the MV and the other in the SB) whose proximal parts are aligned in the proximal MV before MV stenting. The aim of this technique is to sustain the central position of the carina while moving the atherosclerotic plaques away. Using first-generation drug eluting stents (DESs), this technique was shown to reduce SB-related complications in a small retrospective study[62].

The jailed balloon technique (JBT) and the jailed semi-inflated balloon technique (JSBT) involve implanting an MV stent while a semi-compliant balloon is in the SB protruding to the MV. The proximal marker of the SB balloon is positioned to align or 1-2 mm proximal to the marker of the MV stent (Figure 6). The SB balloon is uninflated (JBT) or inflated to low or moderate pressure (< 3 to 7 atm)

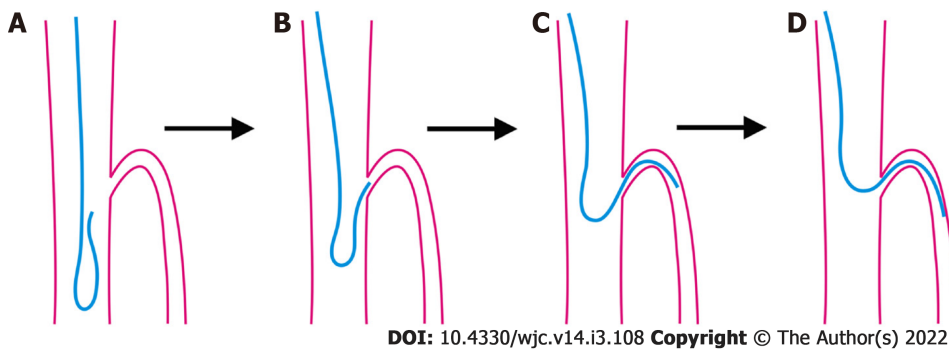


Figure 5 Reverse wire technique. A, B: The wire shaped as a hairpin is advanced into the distal main vessel and withdrawn back to the carina; C, D: When the tip intubates the side branch (SB) ostium, slight withdrawal and gentle counterclockwise rotation allow the wire to advance in the SB.

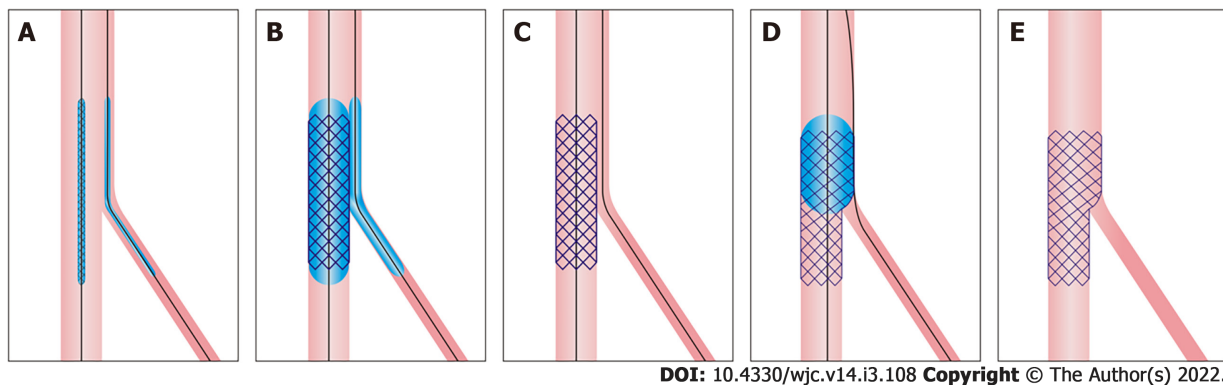


Figure 6 Jailed balloon technique and jailed semi-inflated balloon technique. A: A balloon is positioned in the side branch (SB) to align or 1-2 mm proximal to the main vessel (MV) stent in the proximal MV; B: The stent is deployed while the SB balloon is kept inflated at a low or moderate pressure (in the jailed semi-inflated balloon technique) or uninflated (in the jailed balloon technique); C: Both balloons are removed; D: Proximal optimization technique sized to the proximal MV diameter; and E: Final result.

(JSBT) during MV stent balloon inflation at nominal pressure. After MV stent implantation, if the SB flow is not compromised (*i.e.*, TIMI-3 flow), the uninflated SB balloon is inflated at low (< 3 atm) pressure in the JBT (not shown in Figure 6). If less than TIMI-3 flow in the SB is observed, the SB balloon is inflated at nominal pressure. After the balloons are removed, the proximal optimization technique (POT) is performed in the PMV[63,64].

In the modified jailed balloon technique (M-JBT), the MV stent is positioned across the SB, and a balloon is placed in the SB with its proximal end touching the MB stent (Figure 7). Both the MV stent and SB balloon are inflated at the same nominal pressure (*e.g.*, 12 atm) simultaneously. After deflation and removal of the balloons, the POT is performed in the PMV[65].

All three JBTs, the jailed semi-inflated balloon technique and the M-JBT were investigated in small-sized trials and found to have low SB loss, SB dissection and MACE rates[66,67]; however, larger randomized controlled trials are required for the routine use of these new techniques in the PST.

MV stenting

The preferred type of stent is new-generation DESs which reduce the risk of restenosis and repeat interventions compared to bare metal stents and early-generation DESs[68,69]. The diameter of the MV stent should be chosen at a 1:1 ratio according to the reference distal MV size (Figure 4B). The implantation of a larger stent can cause distal dissection and carinal shift, which can result in severe narrowing or even occlusion of the SB. The length of the stent should be selected so that its PMV part will be equal to or longer than the shortest balloon available (usually 6-8 mm) for the subsequent POT [25,48]. The stent should be implanted at nominal pressures, avoiding overexpansion, which is called the “distal optimization technique” (called “DOT” in the literature)[53].

POT

Since the diameter of the MV stent is chosen according to the diameter of the DMV, a semi-compliant or non-compliant balloon sized to the PMV diameter should be inflated in the PMV stent part to correct malapposition[25] (Figures 4B and 4C). The distal shoulder of the balloon (the point where balloon parallelism ends) should be aligned to the level of the carina so as to avoid stent underexpansion at the

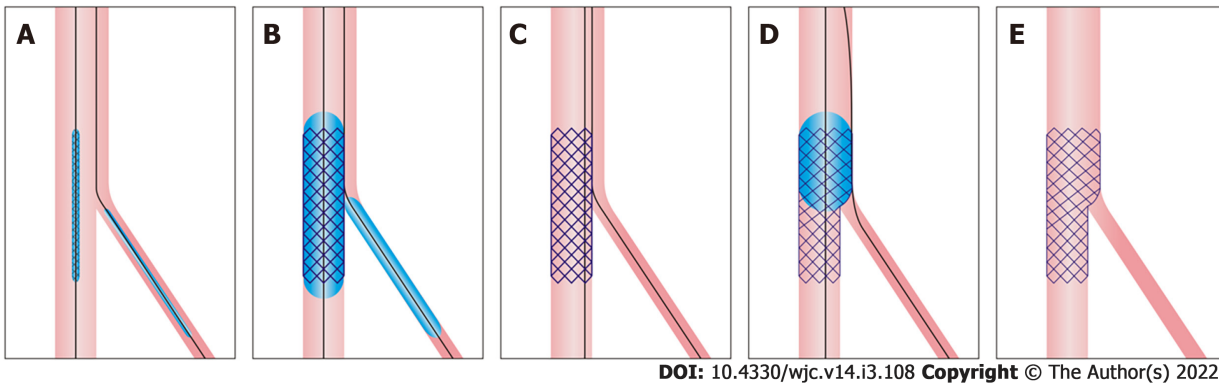


Figure 7 Modified jailed balloon technique. A: Semicompliant balloon in the side branch is positioned with its proximal end touching the main vessel (MV) stent; B: Both the MV stent and balloon are inflated at the same nominal pressure; C: Both balloons are removed; D: Proximal optimization technique sized to proximal MV diameter; E: Final result.

polygon of confluence (occurs when placed more proximally) and carinal shift (occurs when placed more distally)[70]. Many operators use the distal balloon marker as the distal shoulder; however, as the location of this marker varies between manufacturers, the operator should be familiar with the design of the balloon used to avoid misplacement[49,71]. The POT corrects the malapposition of the stent in the PMV, prevents understrut passing of subsequent wires, provides strut protrusion into the SB and widens the distance between struts in the SB ostium which facilitates subsequent wire and balloon passing into the SB.

When the POT balloon is shorter than the PMV stent part, the POT must be applied to the entire PMV stent part. Furthermore, the POT balloon should not be longer than the PMV part of the stent; otherwise, it can cause proximal stent edge dissection.

Finally, the overexpansion capacity of the available stent types should be known to select the correct stent in order to provide natural fractal anatomy of the coronary bifurcation with the POT [72] (Table 2).

Is routine kissing balloon inflation or POT-side-POT technique necessary after the first POT?

KBI involves the inflation of two non-compliant balloons (one in the MV and the other in the SB) whose proximal parts are aligned in the proximal MV. The aim of this procedure after MV stenting is to remove the stent struts at the SB ostium, to eliminate the stenosis in the SB, and to maintain the carina in its central position.

In a recent meta-analysis, routine final KBI resulted in a significant reduction in SB restenosis, but an increase in MV restenosis rates with no significant differences in clinical outcomes[73]. Another recent larger meta-analysis of final KBI *vs* no-final KBI in PST trials also showed similar results in that there was no difference in terms of MACEs and other outcomes[74].

SB dilatation to open the struts at the ostium of the SB after MV stent implantation was shown to cause stent distortion with malapposition of struts at the opposite side of the SB ostium in bench studies [75,76]. Therefore, the POT or KBI should be performed to correct this distortion[71,75,76]. POT-side-POT is a new technique that involves initial POT + SB balloon dilatation + final POT (or re-POT) and will be described later.

Presently, there are no convincing data for KBI and insufficient data for the POT-side-POT technique to recommend either of them for routine use after the first POT in PST.

When should we treat the SB after the POT?

After the POT, if the SB flow is TIMI-3 and there is < 75% stenosis in the ostium, or no dissection, then the operation is completed.

After MV stenting, the MV plaque and/or carina shift can create an angiographic image of SB ostial narrowing. However, angiography is unreliable with regard to the functional significance of SB stenosis in this situation. It was shown in a study that none of the < 75% and only 27% of the SB stenoses \geq 75% were found to be significant with the FFR[77]. This situation can be explained by the oval shape of the SB ostium (the narrower the carinal angle, the more oval the ostium) (Figure 8), the edge effect originating from angiography[57] and the recently shown elliptical stretch of the SB ostium after MV stenting[78].

Consequently, severe stenosis (\geq 75%) in the SB ostium, FFR \leq 0.8, less than TIMI-3 flow or dissection in the SB requires SB intervention.

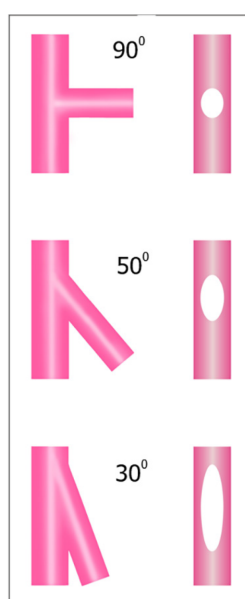
Technical steps of SB intervention after the POT

If the SB requires intervention after MV stenting and the POT, the sequential techniques and technical steps are as follows:

Table 2 Maximum-expansion capacity of stents

Manufacturer	Stent type	Stent size (mm)	Balloon ¹ (bench test) (mm)	Maximum expansion (bench test) (mm)[72]	Maximum expansion (mm) (manufacturer recommendation)
Biosensors	Biomatrix A	3	5	4.1	-
		4	6	5.9	5.8
Medtronic	Resolute Onyx	2.5	4	3.3	-
		3	5	4.4	-
		4	6	5.6	-
		5	6	6	6
Biotronik	Orsiro	3	5	4	-
		4	6	5.3	4.4
Abbott	Xience	3	5	4.1	3.75
		4	6	5.6	5.5
Terumo	Ultimaster	3	5	4.3	-
		4	6	5.8	5.5
Boston Scientific	Synergy	2.75	5	3.6	3.5
		3.5	5	4.2	4.25
		4	6	5.7	5.75

¹In the bench test, all balloons are inflated at 14 atm[72].



DOI: 10.4330/wjc.v14.i3.108 Copyright ©The Author(s) 2022.

Figure 8 Effect of bifurcation angle on side branch ostium ellipticity. Narrower angles result in more oval ostium shapes.

Guidewire exchange technique: The MV wire tip is pulled to the level of the carina and tried to pass into the SB through the most distal cell of the MV stent (carinal cell) at the SB ostium (Figure 4E). The passing of the wire through the distal cell is very important in the PST as subsequent balloon inflation will direct the struts to the non-carinal ostial segment of the SB, providing better scaffolding[26]. The jailed SB wire should not be retracted until the MV wire passes into the SB, since this wire indicates the SB ostium location and can be used when a rescue balloon is required as described next.

If the wire cannot be passed through the stent struts into the SB, the following options are available: (1) It can be reshaped; (2) The POT with a larger balloon can be performed again to open the cells and remove the struts at the SB ostium; (3) A hydrophilic polymer-coated or a stiffer wire can be used; (4) A

steerable-tip microcatheter (Venture, Teleflex), an angled microcatheter (SuperCross, Teleflex) or a dual lumen microcatheter can be used; and (5) Finally, a small balloon (1-1.5 mm) can be passed through the jailed wire under the stent struts and dilated at the ostium of the SB, which not only rescues the SB in case of occlusion but also allows the MV wire to enter the SB[26]. In extreme cases, the inverted crush technique can be implemented as a last effort to rescue the occluded SB.

After the MV wire is inserted in the SB, the jailed SB wire is withdrawn until it comes out under the stent struts and is then pushed forward into the stent. At this time, the tip should be formed into a “U” shape to easily cross the MV stent, avoiding passing under the struts (Figure 4E). While the jailed SB wire is being retracted, the guiding catheter may intubate deeply into the vessel, which can cause dissection and longitudinal stent deformation in the case of LMCA stenting[26]. Therefore, the guiding catheter tip should be withdrawn a few mm into the aorta beforehand; and while retracting the wire with right hand, the operator should control the guiding catheter with left hand while closely monitoring its tip[26].

Rarely, the jailed wire cannot be easily removed under the struts. In this case, a small balloon passed over the jailed wire with or without inflation at the jailed site may help.

Instead of the wire exchange technique, a third wire can be used to pass into the SB while the jailed wire is in place. The third wire is advanced into the DMV and then retracted back, and an attempt is made to enter through the most distal cell.

Kissing balloon inflation technique: After exchanging the wires, a non-compliant balloon sized to the SB diameter is inserted into the SB, and another non-compliant balloon sized to the DMV diameter is inserted into the MV. The balloons should be sufficiently short to prevent inflation outside the MV stent and disease-free regions in the SB. Moreover, minimal balloon overlap is recommended to keep elliptical stent deformation in the PMV to a minimum (Figure 4F1)[25,79]. First, the SB balloon is inflated at a high pressure to open the struts and eliminate the stenosis; and after deflation, the MV balloon is inflated to a high pressure. Subsequently, to maintain the carina in its central position, simultaneous inflation and deflation of both balloons is conducted using moderate pressures (at approximately 8-10 atm) as high pressures cause more oval distortion in the PMV segment of the stent[25].

A modified kissing balloon inflation (KBI) technique investigated in a bench test study was described by Mortier *et al*[80]. In this technique, the SB balloon is inflated to 12 atm and deflated to 4 atm. Then, the MB balloon is inflated to 12 atm; and finally, both balloons are deflated simultaneously. This technique was found to cause less elliptical stent deformation of the PMV segment with optimization of SB access compared to KBI with 12 atm inflation and deflation of both balloons simultaneously.

After KBI, to correct the oval (elliptical) stent deformation in the PMV segment, the POT should be performed again, which is termed the re-POT or final POT. In a recent bench test study, the position of the re-POT balloon was found to be an important factor in the alteration of the SB cell area size of the MV stent. The distal shoulder of the balloon positioned across the SB takeoff caused a reduction in the SB cell area whereas the distal shoulder positioned proximal to the SB takeoff did not[71]. The results of future *in vivo* tests and clinical studies of this approach are needed.

Balloon crossing problem to the SB: If the balloon does not cross to the SB through the stent struts, the following steps are performed[26,51]: (1) The first step is to check the position of the guiding catheter to determine whether it is at the ostium and coaxial to the vessel; (2) The second step is to use a smaller or the smallest balloon (1-1.5 mm) available; (3) It is suspected that the two wires are wrapped if the balloon cannot be forwarded to the SB ostium or if the MV wire is observed coming back while pushing the balloon. In this case, the MV wire is withdrawn back to the GC and inserted again into the DMV; (4) The next step is to inflate a balloon in the DMV stent part to increase the support of the GC (the anchor-balloon technique); (5) Performing the re-POT with a larger balloon to open the cells at the ostium of the SB is another choice; (6) Some operators advance a small balloon until it stops at the SB ostium, inflate it at high pressure with the objective of opening the struts, and then try to advance the balloon while deflating it[81]; and (7) As a last effort, the SB can be rewired from a different stent cell.

POT-Side-POT technique: After the first POT and exchanging wires, instead of the KBI, the POT-Side-(re)POT technique was proposed as an alternative and is increasingly used[82-84]. Technically, after the first POT, a balloon sized to the SB diameter is dilated in the SB to eliminate stenosis and remove the struts at the ostium, followed by the re-POT (Figures 4F2 and 4G). Because only one balloon is inserted and inflated at a time, this technique can be performed with 5 Fr guiding catheters, requires only one inflator, and permits more proper balloon positioning. In a small recent clinical prospective registry using optical coherence tomography (OCT), the global strut malapposition, ellipticity index and SB occlusion rates were significantly reduced with a good sixth-month safety outcome[83].

Inverted PST

In Medina 0,0,1 bifurcation lesions with a very large SB (for ex., ostial circumflex or ostial diagonal lesion), a stent from the PMV to the SB may be implanted. This is called the “inverted PST”[25]. In addition, if there is no large difference between the PMV and the SB, this technique can also be performed in Medina 1,0,1 Lesions (Figure 3). The technical steps are the same as for the PST. The only difference is that the DMV is considered the SB and the SB is considered the DMV.

SIDE BRANCH STENTING FOLLOWING THE PST

After KBI or POT-side-POT techniques, if there is dissection, TIMI flow grade < 3 or FFR ≤ 0.8 in the SB, a second stent is required. Since there is a poor correlation between angiography and FFR measurements, when there is a suspicion of severe stenosis in the SB ostium after PST, it is better to use FFR to decide on SB stent implantation[14].

T/TAP stenting techniques

These stenting techniques are the simplest methods of second stent implantation in the PST. If the bifurcation angle is very close to 90°, then implanting a second stent in the SB as a “T form” is suitable. Technically, optimal angiographic views of the SB ostium should be obtained and stent augmentation tools should be used for successful T stenting[25].

Bench test studies and clinical practice have demonstrated that the bifurcation angle is usually not 90°; thus, the second stent may not completely cover the SB ostium with the T stenting technique, resulting in increased restenosis rates[25]. Therefore, the TAP stenting technique was developed. The TAP technique allows complete coverage of the SB ostium at the cost of creating a metallic neocarina. The length of the metallic neocarina depends on the bifurcation angle; the narrower the bifurcation angle is, the longer the length of the neocarina. For this reason, the TAP technique is generally not recommended at bifurcation angles < 70°.

The technical steps of the TAP technique in the PST are as follows[25] (Figure 9): (1) After the MV stenting and exchanging wires, the SB ostium is dilated with a balloon; (2) A DES of the SB diameter and appropriate length is positioned in the SB; (3) A balloon sized to DMV diameter is placed uninflated in the MV for use in subsequent KBI; (4) The SB stent is implanted with great care so that the non-carinal ostium is completely covered with minimal protrusion in the carinal segment (Figure 9B); (5) After the implantation of the SB stent, the stent balloon is slightly withdrawn and inflated at high pressure to provide optimum stent expansion in the SB ostium and postdilation of the stent (Figure 9C); (6) The uninflated, parked MV balloon and SB stent balloon are aligned in the PMV. Simultaneous KBI at moderate pressure and deflation are implemented to hold the neocarina in a central position; and (7) As a last step, the re-POT is performed to correct the oval shape if KBI has been implemented in a long segment in the PMV; otherwise, this step is not mandatory. It is of utmost importance that the re-POT balloon should not reach the metallic neocarina (Figure 9E). If this happens, the neocarina can bend to the SB side, which can result in rejailing and reduction in the SB ostial cell area[71].

Culotte stenting technique in the PST (classical culotte technique)

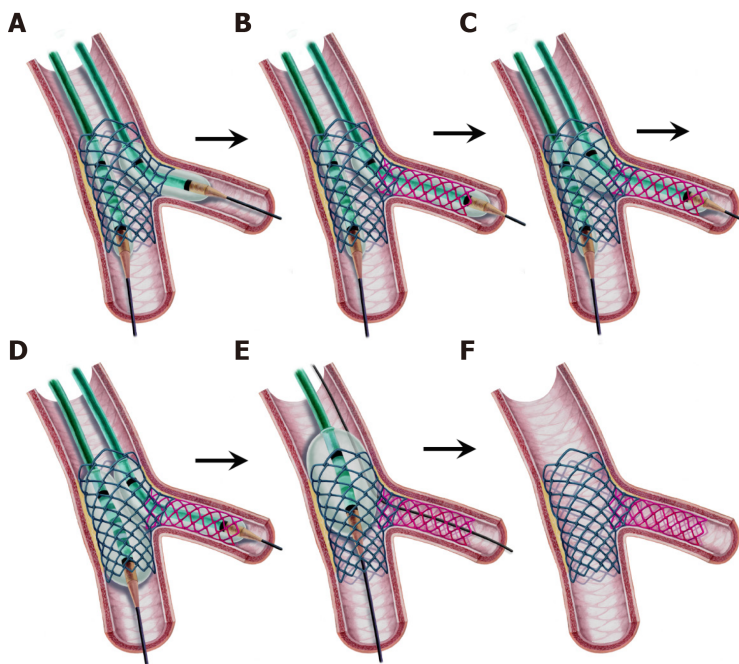
TAP is the most often used technique in the PST due to its simplicity; however, when the bifurcation angle is less than 70°, some operators prefer to use the culotte technique first introduced by Chevalier *et al*[85]. The culotte technique provides full coverage of the bifurcation; however, two layers of struts in the PMV are the disadvantage of this technique. Furthermore, before deciding to perform this technique, the overexpansion capacity of the available stent types should be known (Table 2)[72]. If the maximum expanded diameter of the available SB stent is less than the diameter of the PMV according to the table, then the culotte technique cannot be performed. This is especially the case when there is a large difference between the PMV and SB diameters.

The technical steps of culotte stenting in PST are the following[25] (Figure 10): (1) After the stages of the PST are completed (Figures 10A-C), wire exchange and balloon dilatation of the SB ostium is performed (Figures 10D and E); (2) A DES with the same diameter as the SB and an appropriate length that extends from the SB to overlap the proximal part of the MV stent is implanted while the MV wire is in place. The overlap part is long in the classical culotte technique but is kept at 1-3 mm in the “mini-culotte” technique (Figure 10F); (3) A new POT is performed through the SB wire with a non-compliant balloon sized to the PMV. The balloon distal shoulder should be aligned to the carinal level (Figure 10G); (4) Wire exchange should be performed for the second time. It should be noted that the SB wire must be passed from the cell closest to the carina into the DMV (Figure 10H). This allows the deployed SB stent struts to move to the lateral walls of the MV rather than the carina and the SB ostium during the next balloon inflation. The MV wire is retracted under the SB stent and advanced into the SB as a “U” shape; (5) A non-compliant balloon sized to the DMV and another non-compliant balloon sized to the SB are advanced into the relevant vessels, and the proximal balloon markers are aligned in the PMV. Each balloon is inflated at high pressure and deflated sequentially, followed by KBI at moderate pressures (Figure 10I); and (6) A last POT should be performed for correcting the oval shape created by previous KBI (Figure 10J).

ELECTIVE DOUBLE STENTING TECHNIQUES

Inverted culotte stenting technique

To maintain access to the SB during the procedure, the culotte stenting technique was modified to the “inverted culotte stenting technique” in elective double-stent implantation. Similar to the culotte



DOI: 10.4330/wjc.v14.i3.108 Copyright © The Author(s) 2022.

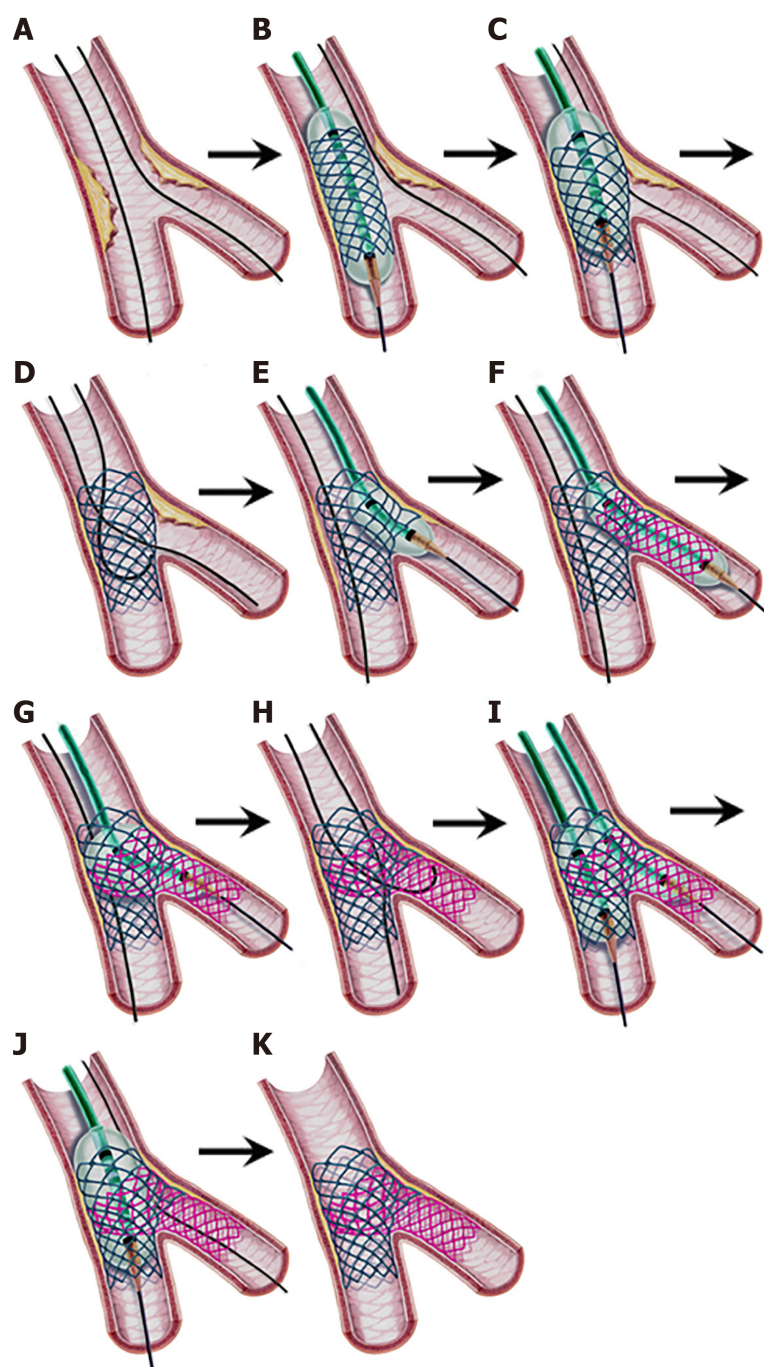
Figure 9 Step-by-step T and protrusion technique. A: After main vessel (MV) stenting, an uninflated balloon is positioned in the MV, and the side branch (SB) ostium is dilated by a balloon; B: The SB stent is deployed with minimal protrusion and covers the ostium completely; C: The stent balloon is withdrawn slightly and inflated at high pressure; D: Kissing balloon inflation; E: Proximal optimization technique with a short balloon not reaching the neocarina. (This step is not mandatory if the kissing balloon inflation area in the proximal MV is not long.); F: Final result.

technique, the inverted culotte technique provides full coverage of the bifurcation at the expense of two layers of struts in the PMV, and it cannot be performed when there is a large difference between the PMV and SB diameters.

The technical steps of inverted culotte stenting are as follows (Figure 11): (1) Both branches are wired, and MV predilation and/or debulking is performed with predilation of the SB; (2) A stent sized 1:1 to the SB diameter is deployed in the SB protruding into the PMV. The length of the stent is selected so that the PMV part is sufficiently long enough for the subsequent POT. In the “mini-culotte technique” introduced a decade ago, the PMV part of the SB stent is kept as short as 1-3 mm to reduce the length of the two stent layers[86,87] (Figure 11B). This technique was found to be associated with high procedural success and very good 9-month outcomes in a pilot study[88]. Randomized, controlled, larger comparative studies are needed to confirm the favorable outcomes of this method; (3) The PMV part of the stent is dilated with a non-compliant or semicompliant balloon sized to 1:1 to the PMV diameter. This is the first POT (Figure 11C); (4) Wire exchange (or a third wire advancement) should then be performed. The DMV should be wired from the closest cell to the carina for the reasons described above (Figure 11D); (5) Stent struts are opened by a DMV balloon. Instead, KBI, which is part of the recently introduced “DK-culotte technique”, can be performed[89,90] (Figure 11E). This technique was found to achieve better morphological properties than classical culotte stenting in a bench test study[89], and it reduced the total procedural time with better strut apposition than the culotte and even the DK-crush techniques in another study[90]; (6) An MV stent sized 1:1 to the DMV diameter is advanced and implanted. The length of the PMV part should be sufficient to cover the PMV part of the SB and be at least equal to the shortest POT balloon (Figure 11F); (7) A second POT is performed in the PMV (Figure 11G); (8) A second wire exchange is performed by passing the MV wire through the closest cell to the carina into the SB and the U-shaped SB wire into the DMV (Figure 11H); (9) KBI is performed with short non-compliant balloons sized 1:1 to the branches. Before KBI, sequential balloon inflation is recommended. The SB balloon is first inflated to a high pressure; and after deflation, the MV balloon is inflated to a high pressure. Then, both balloons are inflated at moderate pressures (at approximately 8-10 atm) and deflated simultaneously (Figure 11I). A recent mini-KBI in culotte stenting was described in a bench test study[91]. In this technique, the SB balloon only protrudes into the MV at the upper edge of the SB, and the KBI is performed. Compared to classical KBI, this modification significantly prevented stent deformation and overexpansion in the MV stent and provided better apposition of the MV stent and better expansion of the SB stent[91]; and (10) A final POT is performed in the PMV (Figure 11J).

Double-kissing crush technique

The crush technique was first introduced by Colombo *et al*[92]. The aim of this technique was to provide full coverage of the ostium to lessen SB restenosis with immediate patency of both branches. However,

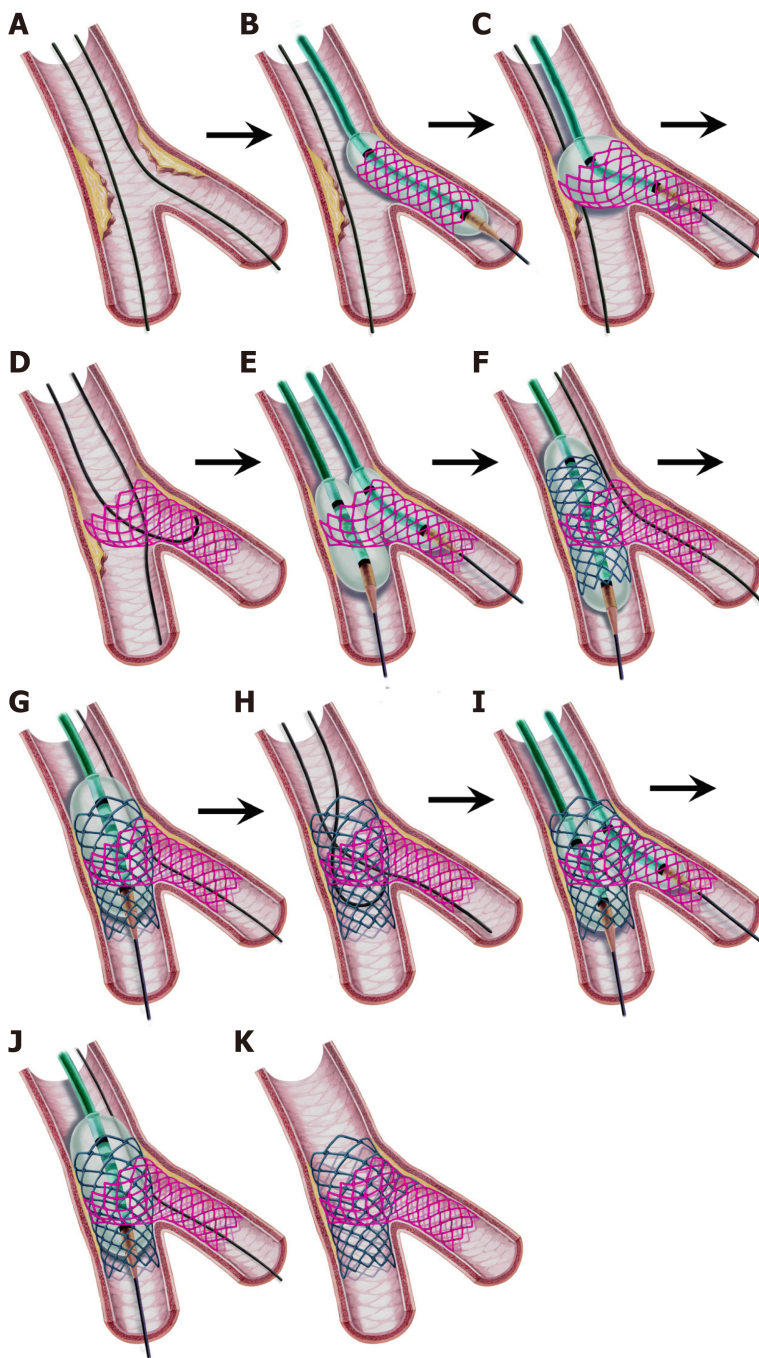


DOI: 10.4330/wjc.v14.i3.108 Copyright © The Author(s) 2022.

Figure 10 Step-by-step classical (provisional) culotte stenting. A: Both vessels are wired; B: After predilatation, the main vessel (MV) stent sized to the distal MV is deployed; C: First proximal optimization technique (POT); D: Wire exchange; E: Balloon dilatation of the side branch (SB) ostium; F: Deployment of the SB stent protruding into the proximal MV (1-3 mm in “mini-culotte”(shown) or more in classical culotte technique); G: POT for the SB stent; H: Second wire exchange with wiring the distal MV through the closest cell to the carina, and the other wire tip is “U” shaped to cross the SB stent; I: Kissing balloon inflation; J: Final POT; K: Final result.

in clinical practice and in trials, the rate of achievable KBI was found to be low, leading to suboptimal long-term outcomes. Thus, this technique is no longer recommended[49]. Some modifications of this technique, such as “mini-crush”[93], “step-crush”[94], and “double-kissing (DK) crush”[95] were described. As described before, the DK crush technique has received great attention due to its high final KBI success rate and its efficacy with long-term safety in complex bifurcation lesions in a series of trials [25,34-36,96]. Nonetheless, this technique is complex with many steps that require proper training and experience.

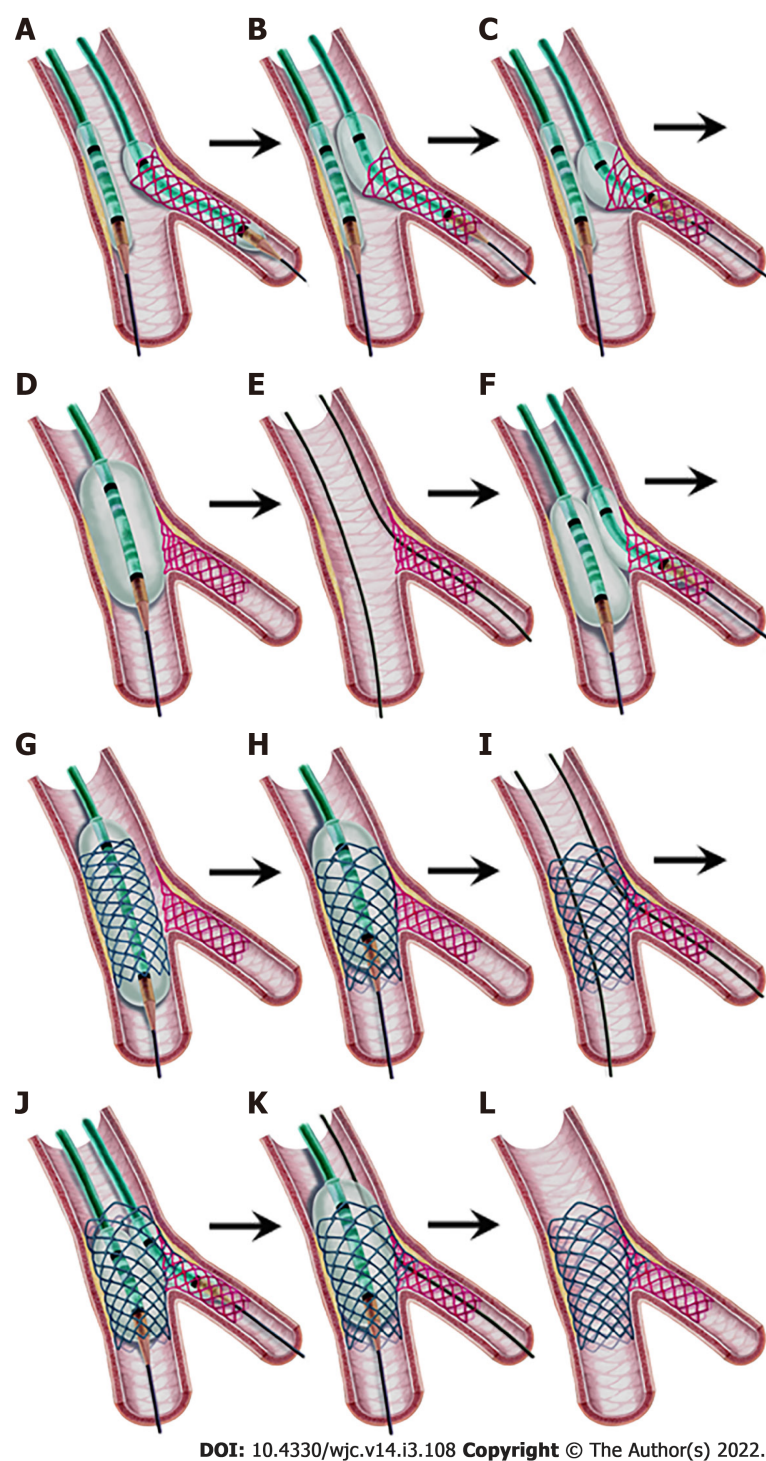
The technical steps of the contemporary DK-crush technique are as follows[25] (Figure 12): (1) After wiring the two branches, optimal preparation of the MV with balloon inflation and/or debulking with predilatation of the SB is performed; (2) A DES, sized to the SB diameter and with a length to ensure full coverage of the SB lesion, is advanced into the SB. The stent is positioned protruding 2-3 mm into the



DOI: 10.4330/wjc.v14.i3.108 Copyright © The Author(s) 2022.

Figure 11 Step-by-step inverted culotte stenting. A: Both vessels are wired; B: The side branch (SB) stent protruding in the proximal main vessel is deployed (protrusion part is 1-3 mm in the “Mini-culotte technique”); C: Proximal optimization technique (POT) for the SB stent; D: Wire exchange. The distal main vessel (MV) wiring from the closest cell to the carina and the “U” shaped wire is advanced into the SB; E: Kissing balloon inflation (KBI) (in the “double kissing mini-culotte” technique) or classical balloon dilatation only in the distal MV ostium may be performed; F: MV stenting; G: POT for the MV stent; H: Second wire exchange. Wiring the SB through the closest cell to the carina and the “U” shaped wire crossing the MV stent; I: KBI; J: Final POT; K: Final result.

PMV (Figure 12A); (3) A balloon sized to the PMV is positioned in the MV to crush the stent later. This balloon will be kept uninflated until the crushing procedure (Figure 12A); (4) After the SB stent is implanted, a new method called the “proximal side optimization” described by Lavarra[97,98] and considered useful by the EBC[25] may be performed. In this method, the stent balloon is slightly withdrawn and inflated at 4-6 atm higher than the nominal pressure (Figure 12B); and after removing this balloon, a new NC balloon (0.25-0.5 mm larger than the SB stent) is again inflated in the protruding part of the stent and the SB ostium (Figure 12C). The purpose of this method is to achieve adequate expansion and apposition of the SB stent in the ostium and to provide a larger stent cell area for rewiring; (5) After the SB balloon is removed, angiography should be performed to evaluate the results of SB stent implantation, such as the stent expansion, flow pattern, distal dissection or new lesion development. If an additional stent is required, it should be implanted at this time as the SB wire will be



DOI: 10.4330/wjc.v14.i3.108 Copyright © The Author(s) 2022.

Figure 12 Step-by-step double kissing-crush technique. A: After the preparation of the vessels, the side branch (SB) stent protruding 2-3 mm into the proximal main vessel (MV) is deployed while an uninflated proximal optimization technique (POT) balloon is positioned in the MV; B, C: "Proximal side optimization". A slightly withdrawn stent balloon is inflated at a higher pressure. Then, a new larger NC balloon is inflated in the protruding stent part to further open the struts; D: Crushing the stent by POT after the SB balloon and wire are removed; E: Wiring the SB through a non-distal cell; F: First kissing balloon inflation (KBI) after sequential inflation of the two balloons; G: MV stenting after the SB balloon and wire are removed; H: Second POT; I: Wiring the SB through a non-distal cell for the second time; J: Second KBI; K: Final POT; L: Final result.

removed in the next step and rewiring and stent advancement may be challenging in later steps[99]; (6) The SB wire is removed (some operators leave it in), and the pending uninflated MV balloon is positioned with its distal shoulder aligned to the carina. High-pressure inflation (POT) is performed to crush the protruding part of the SB stent, which is called "balloon crushing"[25]. It was demonstrated in bench tests that the POT is required to achieve total crushing. (Figure 12D); (7) The SB is rewired through a *non-distal* cell of the crushed stent (Figure 12E). Non-distal cell rewiring, the opposite of distal rewiring in the PST, is important because more frequent suboptimal KBI results and higher SB stent restenosis were found with distal wiring[100]. The mechanism of this is explained by the fact that the

KBI in the distal cell pushes the stent struts to the proximal side, causing incomplete coverage of the distal 1/3 of the SB ostium[100]. How to overcome wiring problems is explained in the relevant section of the PST; (8) An SB balloon sized 1:1 to the SB diameter and an MV balloon sized 1:1 to the DMV diameter are advanced. To perform the first KBI, the SB balloon is inflated at high pressure to open the struts; and after deflation, the MV balloon is inflated at high pressure. Eventually, simultaneous inflation and deflation of both balloons with moderate pressures (at approximately 8-10 atm) is conducted (Figure 12F). How to overcome balloon crossing problems is explained in the relevant section of the PST; (9) The two balloons and the SB wire are removed. A DES sized 1:1 to the DMV diameter is positioned across the SB covering all the distal and proximal MV lesions and deployed (Figure 12G). The PMV part of the DES should be at least equal to the shortest POT balloon; (10) After removing the stent balloon, a repeat POT with a balloon sized 1:1 to the PMV diameter should be performed (Figure 12H); (11) The SB is rewired again through a non-distal cell (Figure 12I); (12) A second KBI is performed (Figure 12J); (13) A final POT is performed to correct the oval shape of the PMV created by the previous KBI (Figure 12K).

Nano-crush technique

The “nano-crush” technique was first presented by Ray *et al*[101,102] at the 12th EBC meeting in 2016. Later, in 2017, Rigatelli *et al*[103] published a bench test and clinical outcome study of a technique with the same name. Although both procedures use a tiny SB stent part for crushing, the techniques are somewhat different from each other. Rigatelli *et al*[104] recently changed the name of their technique to the “nano inverted T stenting technique”.

In the nano-crush technique described by Ray *et al*[105], the SB stent is positioned uninflated in the SB, and a non-compliant MV balloon is positioned across the carina and then inflated at a nominal pressure. While the MV balloon is inflated, the SB stent is pulled back until a small part protrudes into the MV and is deployed. However, in the nano-crush technique described by Rigatelli *et al*[103,104], 0.5-1 mm protrusion of the proximal part of the SB stent for crushing is adjusted visually by angiography. Moreover, the KBI numbers and techniques are also different. Where Ray *et al*[102] perform double “classical” KBI at high pressures without a final POT, Rigatelli *et al*[103-105] perform only one “snuggle” KBI, then a final POT. The other steps are similar to the DK-crush stenting technique described before. Finally, Rigatelli *et al*[103-105] use only ultrathin strut stents in their technique.

Both techniques provided complete coverage of the SB ostium with a tiny amount of metal at the carina in bench tests[106,107]. In a clinical study with a small number of patients, Ray *et al*[102] demonstrated short procedural times and no procedural complications with acceptable clinical outcomes with their technique. Rigatelli *et al*[104,108] showed a low incidence of TLF, no stent thrombosis and a good survival rate in left main bifurcation lesions in a small registry study and less contrast use and less procedural and radiation exposure time in comparison to the culotte technique in left main bifurcation lesions in an observational study.

Further controlled, randomized, larger studies are needed to confirm the favorable procedural and long-term clinical outcomes of these techniques in left main and non-left main bifurcation lesions.

OTHER DOUBLE STENTING TECHNIQUES

Mini-crush and step-crush techniques

The mini-crush technique is a version of the crush technique in which the crushed part of the SB stent is 1-2 mm instead of 3-4 mm. The main advantage of the crush and mini-crush techniques is that instant patency of both branches is secured[52]. However, the main disadvantage of these techniques is that a 7 Fr guiding catheter is required because two stents are positioned in the coronary arteries at the same time. After the SB stent is deployed, the stent balloon and wire are withdrawn, and the prepositioned MV stent is inflated while the SB stent is crushed. The SB is rewired followed by balloon dilatation of the ostial struts, KBI and a final POT, sequentially. Rewiring the SB and balloon passing can be challenging due to three layers of stent struts, which is the reason for the low KBI rate in classical crush trials resulting in more adverse outcomes.

The step-crush technique is the same as the DK-crush technique except that the first KBI is not implemented in this technique.

Reverse (internal) crush technique

When a second stent is required in the PST, some operators use the reverse (internal) crush technique [48]. A stent is positioned in the SB, and a balloon is placed in the MV. The stent is pulled back prolapsing 2-3 mm into the MV and implanted. After the stent balloon and wire is removed, the MV balloon is inflated at a high pressure to crush the SB stent. After rewiring, KBI and the POT are subsequently performed. In this technique, the crushed SB part is on the MV stent facing the lumen, unlike the other crushing techniques where it is under the stent and adheres to the vessel wall. There is no large study investigating the safety and efficacy of this technique.

Inverted DK-crush technique

When the SB is larger than the DMV, the inverted DK-crush technique may be performed. The technical steps are the same as those of the DK-crush technique with the only difference being that the DMV is considered the SB and the SB is considered the DMV.

In addition, in very rare PST cases, when the SB is occluded after MV stenting and cannot be rewired, this technique can be used to rescue the SB. The PMV stent part is crushed with a balloon passed through the jailed wire, followed by the DK-crush technique steps.

V and simultaneous kissing stent techniques

The V and simultaneous kissing stent (SKS) techniques consist of the simultaneous implantation of the MV and SB stents. The two stents are positioned so their proximal parts overlap in the PMV to form a neocarina. If the neocarina is ≤ 2 mm, the technique is called “V stenting”; however, if it is ≥ 3 mm, it is called “SKS” [28,109]. Due to the simultaneous implantation of two stents, at least a 7 Fr guiding catheter is required. The main advantage of these two techniques is that access to both branches is maintained throughout the procedure without the need to rewire any branches. Therefore, these techniques are easy and fast and may be preferable to the more complex double stenting procedures in emergencies such as acute LMCA occlusion.

There are also disadvantages of these techniques [52]: (1) The possibility of PMV dissection is relatively higher because of barotrauma during two-stent implantation or postdilation; (2) If a proximal dissection occurs during the procedure or proximal restenosis develops on follow-up, a stent cannot be implanted simply proximal to the stents since a gap between the new stent and the others is inevitable. In this situation, one of the branch stents (mostly the SB) should be crushed by the new stent, but this results in four strut layers in the ostium of the branch causing difficulty for rewiring; (3) If restenosis or lesions occur distal to the stents during follow-up, wiring can be difficult as the wire can pass under or between the struts in the neocarina; and (4) Finally, SKS causes a long neocarina that has been shown to transform into a thin diaphragmatic membranous structure over time; however, the long-term adverse outcomes of this structure are unknown.

The main application of the V stenting technique is Medina 0,1,1 Lesions where the PMV is free of disease and the carinal angle is $< 90^\circ$. Although many authors recommend this technique in this situation [28,48,52], there is no large study investigating the acute and long-term clinical outcomes of this technique. Due to the long carina and the above disadvantages, the SKS technique is not approved by the interventional community for use in nonemergent bifurcation interventions [48,51].

PROCEDURAL COMPLICATIONS AND OUTCOMES OF CBL INTERVENTIONS

The PCI of CBLs has more procedural risks and higher rates of adverse outcomes and restenosis than non-CBLs [99,110]. In addition to classical PCI risks such as dissection, no-reflow and perforation, the procedural risks specific to CBL interventions include acute side branch closure (2.8%-5.2%), the fracture of a jailed wire, and SB stent embolism while passing or withdrawing it through the implanted MV stent [99,110]. Early (< 30 d) (especially more in the EDS techniques) and late stent thrombosis rates are higher than those for non-CBLs [111-113]. This may be due to higher rates of stent underexpansion and malapposition and more metallic and polymer burdens, which may provide stimuli for hypersensitivity and acute thrombogenicity reactions [99,111].

Long-term MACEs are also higher after successful DES implantation for CBLs compared to non-CBLs. Finally, distal LMCA interventions compared to non-LMCA bifurcations are associated with higher MACE (death and TVR) rates [2,99].

INTRAVASCULAR IMAGING IN CBLs

Since coronary angiography is two-dimensional lumenography, it has some limitations in evaluating lesion characteristics and post-intervention results. The intravascular imaging techniques IVUS and OCT provide accurate tomographic images and essential information that guides planning and optimizing PCI treatment [114,115]. OCT provides much higher resolution images of the luminal surface, calcifications, wire positions and SB ostium than IVUS [43]. On the other hand, IVUS has been used more, needs no extra contrast or vessel flushing and is better in evaluating the plaque burden [43].

Compared to angiography, better visualization of the location and extension of plaques using these imaging techniques before PCI can assist in selecting an appropriate stenting strategy and avoid unnecessary two-stent implantation [26]. In addition, proximal and distal vessel sizes and plaque locations can be determined more accurately to determine the stent size, and calcifications that require debulking before stenting can also be identified [47]. In patients without ostial side branch involvement (i.e., Medina 1,1,0/1,0,0/0,1,0), the “eyebrow” sign identified by IVUS was found to be a strong predictor of SB narrowing or occlusion after MV stent implantation [116], in which case the intervention strategy

can be changed. After stenting, OCT can help rewire through the distal cell, which is required for optimal stent scaffolding by subsequent balloon or KBI[115]. Stent expansion and apposition status, distal or proximal stent edge dissection, or residual stenosis can be well identified by both IVUS and OCT[43].

The MAIN-COMPARE registry trial, comparing the use of IVUS in LMCA bifurcation lesions to angiography alone, showed a lower 3-year mortality rate; and the other registry trial SCAAR showed a significantly lower primary endpoint (all-cause mortality, restenosis, or definitive stent thrombosis)[117, 118]. In addition, a recently published analysis of the British Cardiovascular Intervention Society Database has shown lower in-hospital MACE and lower 1-year death rates with the use of IVUS in LMCA interventions[119]. Finally, the results were found to be similar in two recent meta-analyses[120, 121]. In view of these data, IVUS is recommended as the gold standard for PCI of LMCA bifurcation lesions; and although there are no large data, it has been reported that OCT is feasible in LMCA bifurcation lesions in recent guidelines[41,47].

In non-LMCA lesions, an observational PCI study found a lower 7-year cardiac death, MI and MACE rates in the IVUS guided compared to angiography alone in true bifurcation lesions[122]. There are no randomized trials confirming the clinical benefits of routine IVUS use in non-LMCA bifurcation lesions, but the EBC emphasizes the benefit of intravascular imaging in all CBLs in the latest guidelines[20,47].

Although OCT provides superior images compared to IVUS, there are limited clinical data that only come from observational trials with a small number of bifurcation patients[115]. The results of ongoing large randomized trials OCTOBER (comparing two-year MACE between OCT guided or angiography alone interventions in CBLs) and OPTIMUM (comparing 3D OCT guided *vs* angiography alone provisional stenting in terms of malapposed struts in bifurcation lesions) will shed more light on the benefits of OCT use in CBL interventions[123,124].

LEFT MAIN BIFURCATION LESIONS

LMCA stenosis is detected in 5-8% of patients undergoing diagnostic angiography[125], and left main bifurcation lesions (LM-BLs) account for approximately 80% of LMCA lesions[125,126]. The LMCA with its bifurcation has specific properties and requires some different technical approaches[26,42,43,126]: (1) The LMCA supplies > 75% of the blood of the myocardium in a right dominant coronary system, so any complication may result in catastrophic outcomes; (2) The LMCA diameter is between 3.5-6.5 mm with a mean of 4.75-5 mm, so the overexpansion capacity of the stent to be used should be known (Table 2); (3) The left circumflex artery (LCx) is usually the side branch and supplies > 10% of the blood of the myocardium in > 95% of cases, so its loss during PCI is unacceptable; (4) The bifurcation angle is wider than the other bifurcations with a mean value of 70°-80°, so LCx rewiring may be more difficult, and it should be noted that worse outcomes were found with culotte stenting than with the DK-crush technique in patients with bifurcation angles > 70° in LM-BLs[35]; (5) The guiding catheter is close to the LMCA stent, so wires can go behind the struts. In addition, during the withdrawal of jailed wires or balloons, the guiding catheter can enter the LMCA and cause longitudinal compression of the LMCA stent, which is associated with adverse outcomes if untreated[26,57,127]; (6) Diffuse LMCA disease can be overlooked when using angiography due to the lack of a reference segment. Due to the physical laws of coronary bifurcation, LMCA diffuse disease should be considered when the LMCA reference diameter is similar to that of the LAD; and (7) A total of 10%-15% of patients have trifurcation with the addition of an intermediate (ramus) branch, so the complexity of PCI increases, and larger guides are required for triple kissing inflations.

CABG is the gold standard treatment for LMCA lesions according to both recent European Society of Cardiology/European Association for Cardio-Thoracic Surgery (ESC/EACTS) and American Heart Association/American College of Cardiology (AHA/ACC) guidelines[41,128]. However, there are some differences in PCI implementation between these guidelines. The ESC/EACTS recommends PCI as a Class I indication for LMCA patients with SYNTAX scores < 22 (low risk), Class IIa with SYNTAX scores between 23-32 (intermediate risk), and Class III with higher scores. On the other hand, the AHA/ACC classifies LMCA lesions as ostial, trunk and bifurcation. LMCA bifurcation lesions with an increased risk of surgical outcomes (Society of Thoracic Surgeons (STS) score > 2) are Class IIb indications whereas ostial and trunk lesions with a very high risk of surgical outcomes (STS score ≥ 5) are recommended as Class IIa indications for PCI. After these guidelines, 5-year results of two important EXCEL and NOBLE trials have been published, which have caused intense debate about the treatment of LMCA disease with PCI *vs* CABG[129,130]. Repeat revascularization rates were higher in the PCI arms of both trials. Although mortality rates were similar between the CABG and PCI arms, PCI was inferior in terms of the nonprocedural MI in the NOBLE trial. On the other hand, no significant difference between CABG and PCI was found in the primary outcome (composite of death, stroke or MI) in the EXCEL trial. However, the primary outcome definition that does not include repeat revascularization and the MI definition that differs from the second or third universal definition of MI have been criticized[131]. Moreover, although the cardiac death rates were not different, a higher total mortality rate in the PCI arm was noted[47]. A meta-analysis of five randomized trials involving EXCEL

and NOBLE was recently published and found that individual total mortality, cardiac death, stroke and MI rates were not different between the CABG and PCI arms, and unplanned revascularization rates were significantly higher in the PCI arm, as expected[132]. Finally, the multidisciplinary heart team approach, which considers the anatomical and clinicopathological status of each patient and the experience of the operators, is required in the LMCA treatment decision[45,47].

LM-BLs that involves only one branch (*i.e.*, Medina 1,1,0 or 1,0,1) are considered non-complex lesions, and the default strategy is the PST[42]. Two-branch involvement (*i.e.*, Medina 1,1,1 or 0,1,1) in LM-BLs is a complex true lesion. The EBC still recommends the PST for the vast majority of these complex lesions [42], and recommends the EDS techniques in the case of long SB (usually LCx) lesions (≥ 10 mm) or difficult SB access[49]. Furthermore, EDS is preferred in cases where there is a high risk of SB occlusion [48]. Finally, as described before, preferring the DK-crush technique over the PST in complex-true LMCA lesions is a Class IIb indication in the 2018 ESC/EACTS myocardial revascularization guidelines [40].

As described before, the EBC-MAIN trial was recently published and showed that there was no statistically significant difference between the PST and EDS techniques in LM-BL interventions in short SB lesions. The DK-crush technique was used in only 5% of EDS patients in this trial[46].

In light of the latest data and expert opinions, the PST is most often the default strategy[37-39,46,48]. However, it is better to prefer EDS if the SB (usually LCx) is ≥ 2.5 mm and the lesion length is ≥ 10 mm or the likelihood of SB occlusion is high or SB wiring is difficult in complex-true (Medina 1,1,1; 0,1,1) LM-BLs; furthermore, if the operator is familiar with the technique, the DK-crush technique may be preferred over other EDS techniques (Figure 3).

Angiographical LMCA stenosis $> 50\%$ is considered significant; however, there are many cases of ambiguous lesions. FFR and/or IVUS should be used to decide on revascularization for these lesions. Collected data showed that if FFR > 0.8 , then it is safe to defer revascularization; and if FFR ≤ 0.8 , then revascularization of the LMCA is indicated[42,133]. On the other hand, an IVUS-derived minimum lumen area (MLA) of 6 mm^2 is usually considered to be the cut-off value of significant LMCA lesions [42]; however, this value was determined in Western populations who typically have larger body and vessel sizes, and an IVUS-derived MLA of 4.5 mm^2 was found to be the cut-off value in an Asian population study[134]. Consequently, in LMCA lesions, it is recommended to defer revascularization if the MLA $> 6 \text{ mm}^2$, to revascularize if the MLA $< 4.5 \text{ mm}^2$ and to evaluate with FFR measurement if the MLA is between 4.5 and 6 mm^2 [135]. There is no defined cut-off value for OCT yet[42].

After LMCA stenting, IVUS-derived minimum stent area cut-off values for predicting angiographic restenosis were 5 mm^2 for the ostial LCx, 6.3 mm^2 for the ostial left anterior descending artery (LAD), 7.2 mm^2 for the polygon of confluence, and 8.2 mm^2 for the LMCA above the polygon of confluence (the so-called 5-6-7-8 rule) in a study[136]. However, this trial was conducted in Asian patients and it appears that larger LMCA cut-off values should be targeted in other populations and large body size patients [127]. Indeed, in an IVUS substudy of the EXCEL trial, the minimum LMCA stent area cut-off value for predicting angiographic restenosis was 9.8 mm^2 ; and in the NOBLE trial substudy, this value was found to be 13.4 mm^2 [137,138].

After crossover stenting in the LMCA during the PST, whether the nonobstructed SB (usually LCx) ostium should be opened is a matter of debate[47]. A recent large registry, however, showed that there was no significant difference between the KBI and non-KBI arms in terms of TLR in patients with crossover stenting from the LMCA to the LAD[139].

The optimal PCI strategy for isolated ostial LAD lesions and ostial LCx lesions (Medina 0,1,0 and 0,0,1) is uncertain[25]. The extension of LMCA bifurcation plaques may not be detected by angiography, so IVUS/OCT is preferred for isolated ostial LAD or LCx lesions. Indeed, angiographic assessment was found to underestimate the extension and severity of lesions. Distal LMCA atherosclerotic plaques extended 90% to the LAD, 66% to the LCx, and 62% to both whereas isolated ostial plaque involvement of the LAD and LCx was only 9% and 17%, respectively, in an IVUS study[140]. In conclusion, if the anatomy is appropriate according to IVUS/OCT (the carinal angle is approximately 90° , the LMCA is free of plaque and there is certain visualization of the ostium of the other branch), then ostial stenting may be preferred to avoid LMCA stenting. Otherwise, the PST (from LMCA to LAD stenting) for isolated ostial LAD and the inverted PST (from LMCA to LCx stenting) for isolated ostial LCx seem to be the preferred options[25,47].

Finally, after successful LMCA stenting, late (3-12 mo) control angiography may be considered regardless of symptoms according to recent guidelines (Class IIb, level of evidence C)[41].

DRUG-COATED BALLOONS IN CBLs

Drug-coated balloons (DCBs) are a new technology intended for the prevention of restenosis as an alternative option to DESs[26]. The use of DCBs in CBL is attractive due to the high rate of restenosis after CBL intervention. Observational studies using a DES in the MB and a DCB in the SB showed good SB results[141]. The PEPCAD-BIF trial showed that DCBs provided very acceptable late lumen loss in SB lesions without both major dissections and significant early vessel recoil[142]. In the BABILON trial,

a DCB in the SB plus a bare metal stent in the MV was found to be worse than the provisional DES strategy in terms of MACE and TLR[26]. It should be noted that these and all the other studies to date on the use of DCBs in de novo CBLs are heterogeneous and include a small number of patients[47]. A recent meta-analysis that included four studies with 349 patients treated with DCBs *vs* standard balloon angioplasty, showed that the DCB reduced the SB late lumen loss, but the SB binary restenosis rates and the clinical outcomes (MACE and TLR) were not different[143]. Consequently, there still is insufficient conclusive data on the use of DCBs in de novo CBLs[48]. A new “POT-side DCB-POT” method was recently described in a case report[144], and more research is expected on the clinical consequences of this technique.

DCBs have been tested in in-stent restenosis (especially after two-stent implantation) and have been found to provide a good clinical outcome without requiring extra stent implantation[145]. Therefore, the method was reported as “feasible” in this case in the latest EBC guidelines[47].

DEDICATED BIFURCATION STENTS

The difficulties in accessing the SB after MV stenting, or vice versa, resulted in the development of dedicated bifurcation stents (DBSs). Although many types are available, 4 DBSs were studied in randomized trials: BiOSS Expert and BiOSS LIM (Balton, Warsaw, Poland), the Tryton stent (Tryton Medical, Durham, North Carolina) and the Axxess bifurcation stent (Biosensors International, Singapore).

The BiOSS Expert is a paclitaxel-eluting balloon-expandable dedicated bifurcation stent that is implanted in the MV and has an open side to the ostium of the SB. In the Polbos I trial, the BiOSS Expert was compared with many types of DESs using the PST. Although the MACE rates were similar, the TLR rate was higher in the BiOSS Expert group[146]. The BiOSS LIM is a sirolimus-eluting balloon-expandable dedicated stent. In the Polbos II trial, no difference was found between the BiOSS LIM and provisional DES techniques in terms of the MACE and TLR rates[147].

The Tryton stent is a balloon expandable dedicated cobalt chromium non-DES. This stent is implanted in the SB, and a DES is implanted in the MV through the open struts of this dedicated stent. A pooled analysis of the Tryton pivotal randomized controlled trial and post-approval confirmatory study comparing this stent with the PST with a DES showed that the Tryton stent was clinically non-inferior to the PST with good angiographic outcomes at 1 year[148].

The Axxess stent is a self-expandable biolimus-eluting dedicated stent that is designed for EDS. It is implanted in the proximal MV with its distal end aligned to the carina, allowing easy access to both the distal MV and the SB[149]. In the COBRA study, Axxess with two biolimus-eluting stents (in the distal MV and the SB) was compared to the culotte stenting technique with two everolimus-eluting stents and found no difference in stent coverage at 9 mo and similar favorable clinical outcomes at 5 years[150].

Consequently, DBSs have not yet been found to be superior to conventional bifurcation stenting strategies for routine use in CBLs[151].

ANTITHROMBOTIC THERAPY

Since the periprocedural and long-term risk of stent thrombosis (ST) of coronary bifurcation PCI is high [112], antithrombotic therapy is an important part of CBL treatment. The anatomical properties of bifurcations lead to a relatively high rate of strut malapposition, stent underexpansion and isolated strut noncoverage, resulting in thrombosis[113]. EDS, except for the DK-crush technique, has been found to cause higher ST risk than one-stent implantation. In addition, the ST rate of “bail-out” second stent implantation in the PST was shown to be higher than that in EDS[152]. Therefore, careful preselection of the stenting strategy is required. ST most often occurs acutely or in the first 30 d postprocedure rather than later[20].

Unfractionated heparin is the standard anticoagulant agent for every PCI procedure. Given the complex and time-consuming nature of bifurcation intervention, close monitoring of ACT values is required. In order to prevent ST in the acute and early phases, IV cangrelor may be preferred in P2Y₁₂ inhibitor-naïve patients (ESC Class IIb, LOE A recommendation)[40].

Dual antiplatelet therapy (DAPT) with P2Y₁₂ inhibitors and aspirin is the standard treatment after every coronary stent implantation. In acute coronary syndrome (ACS), the potent P2Y₁₂ inhibitors prasugrel and ticagrelor are preferred over clopidogrel. Due to the results of the recent ISAR-REACT 5 trial, prasugrel is preferred over ticagrelor in the latest ESC guidelines (Class IIa)[153]. In stable coronary artery disease (CAD), although they have not been documented to be more efficient than clopidogrel, the potent P2Y₁₂ inhibitors prasugrel or ticagrelor may be considered in high ST risk situations, such as LMCA interventions, according to the ESC guidelines (Class IIb, LOE C recommendation)[41].

The duration of DAPT depends on the clinical presentation (stable CAD or ACS) and the ST and bleeding risk. In both stable CAD and ACS interventions, high ST risk patients such as bifurcation PCI ≥ 2 stents and LMCA PCI, the duration of DAPT may be prolonged beyond 12 mo if the bleeding risk is not high (Class IIb indication for stable CAD and class IIa indication for ACS)[41,154]. However, in the case of high bleeding risk (e.g., PRECISE-DAPT score ≥ 25), DAPT duration may be considered as 3 mo for stable CAD and 3–6 mo for ACS patients with the cessation of P2Y₁₂ inhibitor (Class IIa indication according to ESC and Class IIb indication according to the latest AHA/ACC guidelines, for both stable CAD and ACS)[41,154–156]. Finally, after the recent publication of 5 large trials that also included CBLs, the AHA/ACC recommends a class IIa indication for a shorter DAPT duration (1–3 months) followed by P2Y₁₂ inhibitor monotherapy to reduce the risk of bleeding events in selected patients [156].

CONCLUSION

Coronary bifurcation lesions are complex and require meticulous preplanning of the stenting strategy. The provisional stenting technique is the default strategy in most cases. However, two-stent techniques, especially the DK-crush technique, may be the upfront-stenting strategy in some patients with complex lesions. Multiple consecutive steps are required to perform a successful stenting procedure. During the procedure, intravascular imaging is an essential tool since it is not only helpful in the selection of the stenting technique but also necessary for optimization of the result. The results of ongoing and anticipated future trials are awaited to clarify various unresolved issues in percutaneous coronary bifurcation interventions.

ACKNOWLEDGEMENTS

I would like to thank the illustrator Coşkun Kuzgun for drawing clear and explanatory figures.

FOOTNOTES

Author contributions: The author reviewed the literature and related books, and wrote the article.

Conflict-of-interest statement: Author declares no conflict of interests for this article.

Open-Access: This article is an open-access article that was selected by an in-house editor and fully peer-reviewed by external reviewers. It is distributed in accordance with the Creative Commons Attribution NonCommercial (CC BY-NC 4.0) license, which permits others to distribute, remix, adapt, build upon this work non-commercially, and license their derivative works on different terms, provided the original work is properly cited and the use is non-commercial. See: <https://creativecommons.org/licenses/by-nc/4.0/>

Country/Territory of origin: Turkey

ORCID number: Tamer Kırat 0000-0002-7746-0844.

Corresponding Author's Membership in Professional Societies: European Society of Cardiology, No. 169218; Turkish Society of Cardiology, No. 1216.

S-Editor: Ma YJ

L-Editor: A

P-Editor: Yu HG

REFERENCES

- 1 **Latib A**, Colombo A. Bifurcation disease: what do we know, what should we do? *JACC Cardiovasc Interv* 2008; **1**: 218–226 [PMID: 19463303 DOI: 10.1016/j.jcin.2007.12.008]
- 2 **Burzotta F**, Annone U, Paraggio L, D'Ascenzo F, Biondi-Zoccai G, Aurigemma C, Romagnoli E, Verdrosi D, Trani C, Crea F. Clinical outcome after percutaneous coronary intervention with drug-eluting stent in bifurcation and nonbifurcation lesions: a meta-analysis of 23 981 patients. *Coron Artery Dis* 2020; **31**: 438–445 [PMID: 32040027 DOI: 10.1097/MCA.0000000000000847]
- 3 **Stankovic G**, Darremont O, Ferenc M, Hildick-Smith D, Louvard Y, Albiero R, Pan M, Lassen JF, Lefèvre T; European Bifurcation Club. Percutaneous coronary intervention for bifurcation lesions: 2008 consensus document from the fourth meeting of the European Bifurcation Club. *EuroIntervention* 2009; **5**: 39–49 [PMID: 19577982 DOI: 10.4244/eijv5i1a8]

- 4 **Colombo A**, Stankovic G. Bifurcations and branch vessel stenting. In: Topol EJ, Teirstein PS. Textbook of Interventional Cardiology. 8th ed. Philadelphia, PA: Saunders Elsevier, 2019: 400–418 [DOI: [10.1016/b978-1-4377-2358-8.00020-6](https://doi.org/10.1016/b978-1-4377-2358-8.00020-6)]
- 5 **Kamiya A**, Takahashi T. Quantitative assessments of morphological and functional properties of biological trees based on their fractal nature. *J Appl Physiol* (1985) 2007; **102**: 2315-2323 [PMID: [17347385](https://pubmed.ncbi.nlm.nih.gov/17347385/) DOI: [10.1152/japplphysiol.00856.2006](https://doi.org/10.1152/japplphysiol.00856.2006)]
- 6 **Colombo A**, Stankovic G. PCI for bifurcation lesions In: Grech DE (editor). Practical Interventional Cardiology. 3rd Edition. Boca Raton, Florida: Taylor and Francis Group, 2018: 239-246 [DOI: [10.1201/9781315113753-16](https://doi.org/10.1201/9781315113753-16)]
- 7 **Murray CD**. The Physiological Principle of Minimum Work: I. The Vascular System and the Cost of Blood Volume. *Proc Natl Acad Sci U S A* 1926; **12**: 207-214 [PMID: [16576980](https://pubmed.ncbi.nlm.nih.gov/16576980/) DOI: [10.1073/pnas.12.3.207](https://doi.org/10.1073/pnas.12.3.207)]
- 8 **Huo Y**, Kassab GS. A scaling law of vascular volume. *Biophys J* 2009; **96**: 347-353 [PMID: [19167288](https://pubmed.ncbi.nlm.nih.gov/19167288/) DOI: [10.1016/j.bpj.2008.09.039](https://doi.org/10.1016/j.bpj.2008.09.039)]
- 9 **Finet G**, Gilard M, Perrenot B, Rioufol G, Motreff P, Gavitt L, Prost R. Fractal geometry of arterial coronary bifurcations: a quantitative coronary angiography and intravascular ultrasound analysis. *EuroIntervention* 2008; **3**: 490-498 [PMID: [19736093](https://pubmed.ncbi.nlm.nih.gov/19736093/) DOI: [10.4244/eijv3i4a87](https://doi.org/10.4244/eijv3i4a87)]
- 10 **Huo Y**, Finet G, Lefèvre T, Louvard Y, Moussa I, Kassab GS. Optimal diameter of diseased bifurcation segment: a practical rule for percutaneous coronary intervention. *EuroIntervention* 2012; **7**: 1310-1316 [PMID: [22433194](https://pubmed.ncbi.nlm.nih.gov/22433194/) DOI: [10.4244/EIJV7I11A206](https://doi.org/10.4244/EIJV7I11A206)]
- 11 **Ramcharitar S**, Onuma Y, Aben JP, Consten C, Weijers B, Morel MA, Serruys PW. A novel dedicated quantitative coronary analysis methodology for bifurcation lesions. *EuroIntervention* 2008; **3**: 553-557 [PMID: [19608480](https://pubmed.ncbi.nlm.nih.gov/19608480/) DOI: [10.4244/eijv3i5a100](https://doi.org/10.4244/eijv3i5a100)]
- 12 **Genuardi L**, Chatzizisis YS, Chiastra C, Sgueglia G, Samady H, Kassab GS, Migliaavacca F, Trani C, Burzotta F. Local fluid dynamics in patients with bifurcated coronary lesions undergoing percutaneous coronary interventions. *Cardiol J* 2021; **28**: 321-329 [PMID: [32052855](https://pubmed.ncbi.nlm.nih.gov/32052855/) DOI: [10.5603/CJ.a2020.0024](https://doi.org/10.5603/CJ.a2020.0024)]
- 13 **Louvard Y**, Thomas M, Dzavik V, Hildick-Smith D, Galassi AR, Pan M, Burzotta F, Zelizko M, Dudek D, Ludman P, Sheiban I, Lassen JF, Darremont O, Kastrati A, Ludwig J, Iakovou I, Brunel P, Lansky A, Meerkink D, Legrand V, Medina A, Lefèvre T. Classification of coronary artery bifurcation lesions and treatments: time for a consensus! *Catheter Cardiovasc Interv* 2008; **71**: 175-183 [PMID: [17985377](https://pubmed.ncbi.nlm.nih.gov/17985377/) DOI: [10.1002/ccd.21314](https://doi.org/10.1002/ccd.21314)]
- 14 **Lassen JF**, Holm NR, Banning A, Burzotta F, Lefèvre T, Chieffo A, Hildick-Smith D, Louvard Y, Stankovic G. Percutaneous coronary intervention for coronary bifurcation disease: 11th consensus document from the European Bifurcation Club. *EuroIntervention* 2016; **12**: 38-46 [PMID: [27173860](https://pubmed.ncbi.nlm.nih.gov/27173860/) DOI: [10.4244/EIJV12I1A7](https://doi.org/10.4244/EIJV12I1A7)]
- 15 **Giannoglou GD**, Antoniadis AP, Koskinas KC, Chatzizisis YS. Flow and atherosclerosis in coronary bifurcations. *EuroIntervention* 2010; **6** Suppl J: J16-J23 [PMID: [21930484](https://pubmed.ncbi.nlm.nih.gov/21930484/) DOI: [10.4244/EIJV6SUPJA4](https://doi.org/10.4244/EIJV6SUPJA4)]
- 16 **Chatzizisis YS**, Coskun AU, Jonas M, Edelman ER, Feldman CL, Stone PH. Role of endothelial shear stress in the natural history of coronary atherosclerosis and vascular remodeling: molecular, cellular, and vascular behavior. *J Am Coll Cardiol* 2007; **49**: 2379-2393 [PMID: [17599600](https://pubmed.ncbi.nlm.nih.gov/17599600/) DOI: [10.1016/j.jacc.2007.02.059](https://doi.org/10.1016/j.jacc.2007.02.059)]
- 17 **Resnick N**, Yahav H, Shay-Salit A, Shushy M, Schubert S, Zilberman LC, Wofovitz E. Fluid shear stress and the vascular endothelium: for better and for worse. *Prog Biophys Mol Biol* 2003; **81**: 177-199 [PMID: [12732261](https://pubmed.ncbi.nlm.nih.gov/12732261/) DOI: [10.1016/s0079-6107\(02\)00052-4](https://doi.org/10.1016/s0079-6107(02)00052-4)]
- 18 **Soulis JV**, Giannoglou GD, Chatzizisis YS, Farmakis TM, Giannakoulas GA, Parcharidis GE, Louridas GE. Spatial and phasic oscillation of non-Newtonian wall shear stress in human left coronary artery bifurcation: an insight to atherogenesis. *Coron Artery Dis* 2006; **17**: 351-358 [PMID: [16707958](https://pubmed.ncbi.nlm.nih.gov/16707958/) DOI: [10.1097/00019501-200606000-00005](https://doi.org/10.1097/00019501-200606000-00005)]
- 19 **Ding Z**, Biggs T, Seed WA, Friedman MH. Influence of the geometry of the left main coronary artery bifurcation on the distribution of sudanophilia in the daughter vessels. *Arterioscler Thromb Vasc Biol* 1997; **17**: 1356-1360 [PMID: [9261267](https://pubmed.ncbi.nlm.nih.gov/9261267/)]
- 20 **Zimarino M**, Angiolillo DJ, Dangas G, Capodanno D, Barbato E, Hahn JY, Giustino G, Watanabe H, Costa F, Cuisset T, Rossini R, Sibbing D, Burzotta F, Louvard Y, Shehab A, Renda G, Kimura T, Gwon HC, Chen SL, Costa RA, Koo BK, Storey RF, Valgimigli M, Mehran R, Stankovic G. Antithrombotic therapy after percutaneous coronary intervention of bifurcation lesions. *EuroIntervention* 2021; **17**: 59-66 [PMID: [32928716](https://pubmed.ncbi.nlm.nih.gov/32928716/) DOI: [10.4244/EIJ-D-20-00885](https://doi.org/10.4244/EIJ-D-20-00885)]
- 21 **Movahed MR**, Kern K, Thai H, Ebrahimi R, Friedman M, Slepian M. Coronary artery bifurcation lesions: a review and update on classification and interventional techniques. *Cardiovasc Revasc Med* 2008; **9**: 263-268 [PMID: [18928952](https://pubmed.ncbi.nlm.nih.gov/18928952/) DOI: [10.1016/j.carrev.2008.05.003](https://doi.org/10.1016/j.carrev.2008.05.003)]
- 22 **Medina A**, Suárez de Lezo J, Pan M. [A new classification of coronary bifurcation lesions]. *Rev Esp Cardiol* 2006; **59**: 183 [PMID: [16540043](https://pubmed.ncbi.nlm.nih.gov/16540043/) DOI: [10.1157/13084649](https://doi.org/10.1157/13084649)]
- 23 **Park TK**, Park YH, Song YB, Oh JH, Chun WJ, Kang GH, Jang WJ, Hahn JY, Yang JH, Choi SH, Choi JH, Lee SH, Jeong MH, Kim HS, Lee JH, Yu CW, Rha SW, Jang Y, Yoon JH, Tahk SJ, Seung KB, Park JS, Gwon HC. Long-Term Clinical Outcomes of True and Non-True Bifurcation Lesions According to Medina Classification- Results From the COBIS (COronary BIfurcation Stent) II Registry. *Circ J* 2015; **79**: 1954-1962 [PMID: [26134457](https://pubmed.ncbi.nlm.nih.gov/26134457/) DOI: [10.1253/circj.CJ-15-0264](https://doi.org/10.1253/circj.CJ-15-0264)]
- 24 **Louvard Y**, Medina A. Definitions and classifications of bifurcation lesions and treatment. *EuroIntervention* 2015; **11** Suppl V: V23-V26 [PMID: [25983165](https://pubmed.ncbi.nlm.nih.gov/25983165/) DOI: [10.4244/EIJV11SVA5](https://doi.org/10.4244/EIJV11SVA5)]
- 25 **Burzotta F**, Lassen JF, Louvard Y, Lefèvre T, Banning AP, Darremont O, Pan M, Hildick-Smith D, Chieffo A, Chatzizisis YS, Dzavik V, Gwon HC, Hikichi Y, Murasato Y, Koo BK, Chen SL, Serruys P, Stankovic G. European Bifurcation Club white paper on stenting techniques for patients with bifurcated coronary artery lesions. *Catheter Cardiovasc Interv* 2020; **96**: 1067-1079 [PMID: [32579300](https://pubmed.ncbi.nlm.nih.gov/32579300/) DOI: [10.1002/ccd.29071](https://doi.org/10.1002/ccd.29071)]
- 26 **Sawaya FJ**, Lefèvre T, Chevalier B, Garot P, Hovasse T, Morice MC, Rab T, Louvard Y. Contemporary Approach to Coronary Bifurcation Lesion Treatment. *JACC Cardiovasc Interv* 2016; **9**: 1861-1878 [PMID: [27659563](https://pubmed.ncbi.nlm.nih.gov/27659563/) DOI: [10.1016/j.jcin.2016.06.056](https://doi.org/10.1016/j.jcin.2016.06.056)]
- 27 **Kirat T**, Köse N, Altun İ, Akın F, Ergün G, Soylu MÖ. Stent diameter and type matters in the decision of 6 FR or 7 FR

- guiding catheter selection during simultaneous kissing stent technique in bifurcation lesions. *Int J Cardiol* 2016; **221**: 1151-1152 [PMID: [26874997](#) DOI: [10.1016/j.ijcard.2016.01.086](#)]
- 28 **Panwar SR**, Rajamanickam A, Kini A, Bifurcation Lesions. In: Kini A, Sharma S, Narula J. Practical Manual of Interventional Cardiology. London, Springer, 2014: 139-159 [DOI: [10.1007/978-1-4471-6581-1_16](#)]
 - 29 **Kočka V**, Thériault-Lauzier P, Xiong TY, Ben-Shoshan J, Petr R, Laboš M, Buithieu J, Mousavi N, Pilgrim T, Praz F, Overtchouk P, Beaudry JP, Spaziano M, Pelletier JP, Martucci G, Dandona S, Rinfret S, Windecker S, Leipsic J, Piazza N. Optimal Fluoroscopic Projections of Coronary Ostia and Bifurcations Defined by Computed Tomographic Coronary Angiography. *JACC Cardiovasc Interv* 2020; **13**: 2560-2570 [PMID: [33153569](#) DOI: [10.1016/j.jcin.2020.06.042](#)]
 - 30 **Pan M**, Ojeda S. Complex Better Than Simple for Distal Left Main Bifurcation Lesions: Lots of Data But Few Crushing Operators. *JACC Cardiovasc Interv* 2020; **13**: 1445-1447 [PMID: [32553332](#) DOI: [10.1016/j.jcin.2020.04.039](#)]
 - 31 **Ferenc M**, Neumann FJ. Complex Stenting for Complex Lesions: DKCRUSH-V Calling for Novel Treatment Strategies for Bifurcation Lesions. *JACC Cardiovasc Interv* 2019; **12**: 1938-1940 [PMID: [31521653](#) DOI: [10.1016/j.jcin.2019.06.009](#)]
 - 32 **Nairooz R**, Saad M, Elgendy IY, Mahmoud AN, Habash F, Sardar P, Anderson D, Shavelle DM, Abbott JD. Long-term outcomes of provisional stenting compared with a two-stent strategy for bifurcation lesions: a meta-analysis of randomised trials. *Heart* 2017; **103**: 1427-1434 [PMID: [28314731](#) DOI: [10.1136/heartjnl-2016-310929](#)]
 - 33 **Behan MW**, Holm NR, de Belder AJ, Cockburn J, Erglis A, Curzen NP, Niemelä M, Oldroyd KG, Kervinen K, Kumsars I, Gunnes P, Stables RH, Maeng M, Ravkilde J, Jensen JS, Christiansen EH, Cooter N, Steigen TK, Vikman S, Thuesen L, Lassen JF, Hildick-Smith D. Coronary bifurcation lesions treated with simple or complex stenting: 5-year survival from patient-level pooled analysis of the Nordic Bifurcation Study and the British Bifurcation Coronary Study. *Eur Heart J* 2016; **37**: 1923-1928 [PMID: [27161619](#) DOI: [10.1093/eurheartj/ehw170](#)]
 - 34 **Chen SL**, Santoso T, Zhang JJ, Ye F, Xu YW, Fu Q, Kan J, Paiboon C, Zhou Y, Ding SQ, Kwan TW. A randomized clinical study comparing double kissing crush with provisional stenting for treatment of coronary bifurcation lesions: results from the DKCRUSH-II (Double Kissing Crush versus Provisional Stenting Technique for Treatment of Coronary Bifurcation Lesions) trial. *J Am Coll Cardiol* 2011; **57**: 914-920 [PMID: [21329837](#) DOI: [10.1016/j.jacc.2010.10.023](#)]
 - 35 **Chen SL**, Xu B, Han YL, Sheiban I, Zhang JJ, Ye F, Kwan TW, Paiboon C, Zhou YJ, Lv SZ, Dangas GD, Xu YW, Wen SY, Hong L, Zhang RY, Wang HC, Jiang TM, Wang Y, Sansoto T, Chen F, Yuan ZY, Li WM, Leon MB. Clinical Outcome After DK Crush Versus Culotte Stenting of Distal Left Main Bifurcation Lesions: The 3-Year Follow-Up Results of the DKCRUSH-III Study. *JACC Cardiovasc Interv* 2015; **8**: 1335-1342 [PMID: [26315736](#) DOI: [10.1016/j.jcin.2015.05.017](#)]
 - 36 **Chen SL**, Zhang JJ, Han Y, Kan J, Chen L, Qiu C, Jiang T, Tao L, Zeng H, Li L, Xia Y, Gao C, Santoso T, Paiboon C, Wang Y, Kwan TW, Ye F, Tian N, Liu Z, Lin S, Lu C, Wen S, Hong L, Zhang Q, Sheiban I, Xu Y, Wang L, Rab TS, Li Z, Cheng G, Cui L, Leon MB, Stone GW. Double Kissing Crush Versus Provisional Stenting for Left Main Distal Bifurcation Lesions: DKCRUSH-V Randomized Trial. *J Am Coll Cardiol* 2017; **70**: 2605-2617 [PMID: [29096915](#) DOI: [10.1016/j.jacc.2017.09.1066](#)]
 - 37 **Chen X**, Li X, Zhang JJ, Han Y, Kan J, Chen L, Qiu C, Santoso T, Paiboon C, Kwan TW, Sheiban I, Leon MB, Stone GW, Chen SL; DKCRUSH-V Investigators. 3-Year Outcomes of the DKCRUSH-V Trial Comparing DK Crush With Provisional Stenting for Left Main Bifurcation Lesions. *JACC Cardiovasc Interv* 2019; **12**: 1927-1937 [PMID: [31521645](#) DOI: [10.1016/j.jcin.2019.04.056](#)]
 - 38 **Crimi G**, Mandurino-Mirizzi A, Gritti V, Scotti V, Strozzi C, de Silvestri A, Montalto C, di Giacomo C, d'Ascenzo F, Repetto A, Ferlini M, Marinoni B, Ferrario M, de Servi S, Visconti LO, Klersy C. Percutaneous Coronary Intervention Techniques for Bifurcation Disease: Network Meta-analysis Reveals Superiority of Double-Kissing Crush. *Can J Cardiol* 2020; **36**: 906-914 [PMID: [31924454](#) DOI: [10.1016/j.cjca.2019.09.002](#)]
 - 39 **Di Gioia G**, Sonck J, Ferenc M, Chen SL, Colaiori I, Gallinoro E, Mizukami T, Kodeboina M, Nagumo S, Franco D, Bartunek J, Vanderheyden M, Wyffels E, De Bruyne B, Lassen JF, Bennett J, Vassilev D, Serruys PW, Stankovic G, Louvard Y, Barbato E, Collet C. Clinical Outcomes Following Coronary Bifurcation PCI Techniques: A Systematic Review and Network Meta-Analysis Comprising 5,711 Patients. *JACC Cardiovasc Interv* 2020; **13**: 1432-1444 [PMID: [32553331](#) DOI: [10.1016/j.jcin.2020.03.054](#)]
 - 40 **Zhang JJ**, Ye F, Xu K, Kan J, Tao L, Santoso T, Munawar M, Tresukosol D, Li L, Sheiban I, Li F, Tian NL, Rodríguez AE, Paiboon C, Lavarra F, Lu S, Vichairuangthum K, Zeng H, Chen L, Zhang R, Ding S, Gao F, Jin Z, Hong L, Ma L, Wen S, Wu X, Yang S, Yin WH, Zhang J, Wang Y, Zheng Y, Zhou L, Zhu Y, Xu T, Wang X, Qu H, Tian Y, Lin S, Liu L, Lu Q, Li Q, Li B, Jiang Q, Han L, Gan G, Yu M, Pan D, Shang Z, Zhao Y, Liu Z, Yuan Y, Chen C, Stone GW, Han Y, Chen SL. Multicentre, randomized comparison of two-stent and provisional stenting techniques in patients with complex coronary bifurcation lesions: the DEFINITION II trial. *Eur Heart J* 2020; **41**: 2523-2536 [PMID: [32588060](#) DOI: [10.1093/eurheartj/ehaa543](#)]
 - 41 **Neumann FJ**, Sousa-Uva M, Ahlsson A, Alfonso F, Banning AP, Benedetto U, Byrne RA, Collet JP, Falk V, Head SJ, Jüni P, Kastrati A, Koller A, Kristensen SD, Niebauer J, Richter DJ, Seferovic PM, Sibbing D, Stefanini GG, Windecker S, Yadav R, Zembala MO; ESC Scientific Document Group. 2018 ESC/EACTS Guidelines on myocardial revascularization. *Eur Heart J* 2019; **40**: 87-165 [PMID: [30165437](#) DOI: [10.1093/eurheartj/ehy394](#)]
 - 42 **Burzotta F**, Lassen JF, Banning AP, Lefèvre T, Hildick-Smith D, Chieffo A, Darremont O, Pan M, Chatzizisis YS, Albiero R, Louvard Y, Stankovic G. Percutaneous coronary intervention in left main coronary artery disease: the 13th consensus document from the European Bifurcation Club. *EuroIntervention* 2018; **14**: 112-120 [PMID: [29786539](#) DOI: [10.4244/EIJ-D-18-00357](#)]
 - 43 **Banning AP**, Lassen JF, Burzotta F, Lefèvre T, Darremont O, Hildick-Smith D, Louvard Y, Stankovic G. Percutaneous coronary intervention for obstructive bifurcation lesions: the 14th consensus document from the European Bifurcation Club. *EuroIntervention* 2019; **15**: 90-98 [PMID: [31105066](#) DOI: [10.4244/EIJ-D-19-00144](#)]
 - 44 **Dou K**, Zhang D, Xu B, Yang Y, Yin D, Qiao S, Wu Y, Yan H, You S, Wang Y, Wu Z, Gao R, Kirtane AJ. An angiographic tool for risk prediction of side branch occlusion in coronary bifurcation intervention: the RESOLVE score system (Risk prEdiction of Side branch OccLusion in coronary bifurcation interVention). *JACC Cardiovasc Interv* 2015;

- 8: 39-46 [PMID: [25616815](#) DOI: [10.1016/j.jcin.2014.08.011](#)]
- 45 **Loh PH**, Lassen JF, Jepson N, Koo BK, Chen S, Harding SA, Hu F, Lo S, Ahmad WAW, Ye F, Guagliumi G, Hiremath MS, Uemura S, Wang L, Whelan A, Low A. Asia Pacific consensus document on coronary bifurcation interventions. *EuroIntervention* 2020; **16**: e706-e714 [PMID: [32250248](#) DOI: [10.4244/EIJ-D-19-00977](#)]
 - 46 **Hildick-Smith D**, Egred M, Banning A, Brunel P, Ferenc M, Hovasse T, Wlodarczak A, Pan M, Schmitz T, Silvestri M, Erglis A, Kretov E, Lassen JF, Chieffo A, Lefèvre T, Burzotta F, Cockburn J, Darremont O, Stankovic G, Morice MC, Louvard Y. The European bifurcation club Left Main Coronary Stent study: a randomized comparison of stepwise provisional vs. systematic dual stenting strategies (EBC MAIN). *Eur Heart J* 2021; **42**: 3829-3839 [PMID: [34002215](#) DOI: [10.1093/eurheartj/ehab283](#)]
 - 47 **Burzotta F**, Lassen JF, Lefèvre T, Banning AP, Chatzizisis YS, Johnson TW, Ferenc M, Rathore S, Albiero R, Pan M, Darremont O, Hildick-Smith D, Chieffo A, Zimarino M, Louvard Y, Stankovic G. Percutaneous coronary intervention for bifurcation coronary lesions: the 15th consensus document from the European Bifurcation Club. *EuroIntervention* 2021; **16**: 1307-1317 [PMID: [33074152](#) DOI: [10.4244/EIJ-D-20-00169](#)]
 - 48 **Brilakis E**. Bifurcations. In: Manual of Percutaneous Coronary Interventions. 1st ed. London: Elsevier, 2021: 267-301 [DOI: [10.1016/b978-0-12-819367-9.00016-0](#)]
 - 49 **Lassen JF**, Burzotta F, Banning AP, Lefèvre T, Darremont O, Hildick-Smith D, Chieffo A, Pan M, Holm NR, Louvard Y, Stankovic G. Percutaneous coronary intervention for the left main stem and other bifurcation lesions: 12th consensus document from the European Bifurcation Club. *EuroIntervention* 2018; **13**: 1540-1553 [PMID: [29061550](#) DOI: [10.4244/EIJ-D-17-00622](#)]
 - 50 **Ferenc M**. Culotte Versus DK-CRUSH Technique in Non-left Main Coronary Bifurcation Lesions (BBK-3). [accessed 2022 February 18]. In: ClinicalTrials.gov [Internet] Bad Krozingen: U.S. National Library of Medicine. Available from: <https://clinicaltrials.gov/ct2/show/NCT04192760> ClinicalTrials.gov Identifier: NCT04192760
 - 51 **Favero L**, Pacchioni A, Reimers B. Elective Double Stenting for Non-Left Main Coronary Artery Bifurcation Lesions: Patient Selection and Technique. In: Moussa DI, Colombo A. Tips and Tricks in Interventional Therapy of Coronary Bifurcation Lesions. UK: Informa, 2010: 83-115 [DOI: [10.3109/9781841847276-6](#)]
 - 52 **Colombo A**, Latib A. Bifurcations. In: Bhatt LD. Cardiovascular intervention: a companion to Braunwald's heart disease. Philadelphia: Elsevier, 2016: 155-183
 - 53 **Gwon HC**. Understanding the Coronary Bifurcation Stenting. *Korean Circ J* 2018; **48**: 481-491 [PMID: [29856142](#) DOI: [10.4070/kej.2018.0088](#)]
 - 54 **Milasinovic D**, Wijns W, Ntsekhe M, Hellig F, Mohamed A, Stankovic G. Step-by-step manual for planning and performing bifurcation PCI: a resource-tailored approach. *EuroIntervention* 2018; **13**: e1804-e1811 [PMID: [29175768](#) DOI: [10.4244/EIJ-D-17-00580](#)]
 - 55 **Chatterjee A**, Brott B, Foley F, Leesar MA. Electron microscopic examination of polymer coated hydrophilic guidewires used for side-branch protection during bifurcation coronary intervention. *J Am Coll Cardiol* 2014; **63**: A1916 [DOI: [10.1016/s0735-1097\(14\)61919-7](#)]
 - 56 **Chatterjee A**, Brott BC, Foley R, Alli O, Sasse M, Ahmed M, Al Solaiman F, Reddy G, Ather S, Leesar MA. Safety of hydrophilic guidewires used for side-branch protection during stenting and proximal optimization technique in coronary bifurcation lesions. *Cardiovasc Revasc Med* 2016; **17**: 456-462 [PMID: [27210866](#) DOI: [10.1016/j.carrev.2016.04.006](#)]
 - 57 **Spaziano M**, Louvard Y, and Lefèvre T. Treatment of Coronary Bifurcation Lesions In: Lanzer P. Textbook of Catheter-Based Cardiovascular Interventions. Switzerland: Springer 2018: 745-776 [DOI: [10.1007/978-3-319-55994-0_46](#)]
 - 58 **Burzotta F**, De Vita M, Sgueglia G, Todaro D, Trani C. How to solve difficult side branch access? *EuroIntervention* 2010; **6** Suppl J: J72-J80 [PMID: [21930495](#) DOI: [10.4244/EIJV6SUPJA12](#)]
 - 59 **Pan M**, Medina A, Romero M, Ojeda S, Martin P, Suarez de Lezo J, Segura J, Mazuelos F, Novoa J. Assessment of side branch predilation before a provisional T-stent strategy for bifurcation lesions. A randomized trial. *Am Heart J* 2014; **168**: 374-380 [PMID: [25173550](#) DOI: [10.1016/j.ahj.2014.05.014](#)]
 - 60 **Peighambari M**, Sanati H, Hadjkarimi M, Zahedmehr A, Shakerian F, Firouzi A, Kiani R, Sadeghipour P, Kzaemi Asl S. The Effects of Side Branch Predilation During Provisional Stenting of Coronary Bifurcation Lesions: A Double-Blind Randomized Controlled Trial. *Res Cardiovasc Med* 2016; **5**: e31378 [PMID: [26949691](#) DOI: [10.5812/cardiovascmed.31378](#)]
 - 61 **Mirzaee S**, Isa M, Thakur U, Cameron JD, Nicholls SJ, Dundon BK. Impact of Side-Branch Predilation on Angiographic Outcomes in Non-Left Main Coronary Bifurcation Lesions. *J Invasive Cardiol* 2020; **32**: 42-48 [PMID: [31958071](#)]
 - 62 **Burzotta F**, Shoeib O, Aurigemma C, Porto I, Leone AM, Niccoli G, Genuardi L, Trani C, Crea F. Procedural Impact of a Kissing-Balloon Predilation (Pre-Kissing) Technique in Patients With Complex Bifurcations Undergoing Drug-Eluting Stenting. *J Invasive Cardiol* 2019; **31**: 80-88 [PMID: [30927529](#)]
 - 63 **Burzotta F**, Trani C, Sianos G. Jailed balloon protection: a new technique to avoid acute side-branch occlusion during provisional stenting of bifurcated lesions. Bench test report and first clinical experience. *EuroIntervention* 2010; **5**: 809-813 [PMID: [20142195](#) DOI: [10.4244/eijv5i7a135](#)]
 - 64 **Ermis E**, Uçar H, Demirelli S, İpek E, Gür M, Çaylı M. Assessment of side branch patency using a jailed semi-inflated balloon technique with coronary bifurcation lesions. *Türk Kardiyol Dern Ars* 2018; **46**: 340-348 [PMID: [30024390](#) DOI: [10.5543/tkda.2018.47347](#)]
 - 65 **Saito S**, Shishido K, Moriyama N, Ochiai T, Mizuno S, Yamanaka F, Sugitatsu K, Tobita K, Matsumi J, Tanaka Y, Murakami M. Modified jailed balloon technique for bifurcation lesions. *Catheter Cardiovasc Interv* 2018; **92**: E218-E226 [PMID: [29205789](#) DOI: [10.1002/ccd.27334](#)]
 - 66 **Tondas AE**, Mulawarman R, Trifitriana M, Pranata R, Abisha SE, Toruan MPL. A Systematic Review of Jailed Balloon Technique for Coronary Bifurcation Lesion: Conventional-Jailed Balloon Technique vs Modified-Jailed Balloon Technique. *Cardiovasc Revasc Med* 2020; **21**: 1193-1199 [PMID: [32169406](#) DOI: [10.1016/j.carrev.2020.03.001](#)]
 - 67 **Shishido K**, Moriyama N, Hayashi T, Yokota S, Miyashita H, Mashimo Y, Yokoyama H, Nishimoto T, Ochiai T, Tobita K, Yamanaka F, Mizuno S, Tanaka Y, Murakami M, Takahashi S, Saito S. The efficacy of modified jailed balloon technique for true bifurcation lesions. *Catheter Cardiovasc Interv* 2020; **96**: 20-28 [PMID: [32096918](#) DOI: [10.1002/ccd.27334](#)]

- 10.1002/ccd.28812]
- 68 **Colombo A**, Moses JW, Morice MC, Ludwig J, Holmes DR Jr, Spanos V, Louvard Y, Desmedt B, Di Mario C, Leon MB. Randomized study to evaluate sirolimus-eluting stents implanted at coronary bifurcation lesions. *Circulation* 2004; **109**: 1244-1249 [PMID: [14981005](#) DOI: [10.1161/01.CIR.0000118474.71662.E3](#)]
 - 69 **Watanabe Y**, Mitomo S, Naganuma T, Kawamoto H, Takagi K, Chieffo A, Carlino M, Montorfano M, Nakamura S, Colombo A. Clinical outcomes of double stent strategy for unprotected left main distal bifurcation lesions using current generation drug eluting stent comparing to early generation drug eluting stent; The Milan and New Tokyo (MITO) registry. *Catheter Cardiovasc Interv* 2021; **97**: E198-E208 [PMID: [32384579](#) DOI: [10.1002/ccd.28962](#)]
 - 70 **Dérinay F**, Rioufol G, Nishi T, Kobayashi Y, Fearon WF, Veziers J, Guérin P, Finet G. Optimal balloon positioning for the proximal optimization technique? *Int J Cardiol* 2019; **292**: 95-97 [PMID: [31130279](#) DOI: [10.1016/j.ijcard.2019.05.041](#)]
 - 71 **Andreasen LN**, Holm NR, Webber B, Ormiston JA. Critical aspects of balloon position during final proximal optimization technique (POT) in coronary bifurcation stenting. *Catheter Cardiovasc Interv* 2020; **96**: 31-39 [PMID: [32087046](#) DOI: [10.1002/ccd.28801](#)]
 - 72 **Ng J**, Foin N, Ang HY, Fam JM, Sen S, Nijjer S, Petraco R, Di Mario C, Davies J, Wong P. Over-expansion capacity and stent design model: An update with contemporary DES platforms. *Int J Cardiol* 2016; **221**: 171-179 [PMID: [27400317](#) DOI: [10.1016/j.ijcard.2016.06.097](#)]
 - 73 **Zhong M**, Tang B, Zhao Q, Cheng J, Jin Q, Fu S. Should kissing balloon inflation after main vessel stenting be routine in the one-stent approach? *PLoS One* 2018; **13**: e0197580 [PMID: [29949587](#) DOI: [10.1371/journal.pone.0197580](#)]
 - 74 **Liu G**, Ke X, Huang ZB, Wang LC, Huang ZN, Guo Y, Long M, Liao XX. Final kissing balloon inflation for coronary bifurcation lesions treated with single-stent technique : A meta-analysis. *Herz* 2019; **44**: 354-362 [PMID: [29181563](#) DOI: [10.1007/s00059-017-4647-1](#)]
 - 75 **Ormiston JA**, Webster MW, Ruygrok PN, Stewart JT, White HD, Scott DS. Stent deformation following simulated side-branch dilatation: a comparison of five stent designs. *Catheter Cardiovasc Interv* 1999; **47**: 258-264 [PMID: [10376516](#) DOI: [10.1002/\(SICI\)1522-726X\(199906\)47:2<258::AID-CCD27>3.0.CO;2-C](#)]
 - 76 **Ormiston JA**, Webster MW, El Jack S, Ruygrok PN, Stewart JT, Scott D, Currie E, Panther MJ, Shaw B, O'Shaughnessy B. Drug-eluting stents for coronary bifurcations: bench testing of provisional side-branch strategies. *Catheter Cardiovasc Interv* 2006; **67**: 49-55 [PMID: [16003787](#) DOI: [10.1002/ccd.20453](#)]
 - 77 **Koo BK**, Kang HJ, Youn TJ, Chae IH, Choi DJ, Kim HS, Sohn DW, Oh BH, Lee MM, Park YB, Choi YS, Tahk SJ. Physiologic assessment of jailed side branch lesions using fractional flow reserve. *J Am Coll Cardiol* 2005; **46**: 633-637 [PMID: [16098427](#) DOI: [10.1016/j.jacc.2005.04.054](#)]
 - 78 **Vassilev DI**, Kassab GS, Collet C, Gutiérrez-Chico JL, Rigatelli G, Gil RJ, Serruys PW. Elliptical stretch as a cause of side branch ostial compromise after main vessel stenting in coronary bifurcations: New insights from numerical analysis. *Cardiol J* 2020; **27**: 507-517 [PMID: [30394509](#) DOI: [10.5603/CJ.a2018.0124](#)]
 - 79 **Murasato Y**, Finet G, Foin N. Final kissing balloon inflation: the whole story. *EuroIntervention* 2015; **11** Suppl V: V81-V85 [PMID: [25983179](#) DOI: [10.4244/EIJV11SVA18](#)]
 - 80 **Mortier P**, Hikichi Y, Foin N, De Santis G, Segers P, Verhegghe B, De Beule M. Provisional stenting of coronary bifurcations: insights into final kissing balloon post-dilation and stent design by computational modeling. *JACC Cardiovasc Interv* 2014; **7**: 325-333 [PMID: [24650404](#) DOI: [10.1016/j.jcin.2013.09.012](#)]
 - 81 **Latib A**, Chieffo A, Colombo A. Elective Double Stenting for Left Main Coronary Artery Bifurcation Lesions: Patient Selection and Technique. In: Moussa ID, Colombo A (editors). *Tips and Tricks in Interventional Therapy of Coronary Bifurcation Lesions*, England, Informa Healthcare, 2010, 149-191 [DOI: [10.3109/9781841847276-9](#)]
 - 82 **Finet G**, Derinay F, Motreff P, Guerin P, Pilet P, Ohayon J, Darremont O, Rioufol G. Comparative Analysis of Sequential Proximal Optimizing Technique Versus Kissing Balloon Inflation Technique in Provisional Bifurcation Stenting: Fractal Coronary Bifurcation Bench Test. *JACC Cardiovasc Interv* 2015; **8**: 1308-1317 [PMID: [26315733](#) DOI: [10.1016/j.jcin.2015.05.016](#)]
 - 83 **Dérinay F**, Finet G, Souteyrand G, Maillard L, Aminian A, Lattuca B, Cayla G, Cellier G, Motreff P, Rioufol G. Benefit of a new provisional stenting strategy, the re-proximal optimisation technique: the rePOT clinical study. *EuroIntervention* 2018; **14**: e325-e332 [PMID: [29553940](#) DOI: [10.4244/EIJ-D-17-00941](#)]
 - 84 **Foin N**, Torii R, Mortier P, De Beule M, Viceconte N, Chan PH, Davies JE, Xu XY, Krams R, Di Mario C. Kissing balloon or sequential dilation of the side branch and main vessel for provisional stenting of bifurcations: lessons from micro-computed tomography and computational simulations. *JACC Cardiovasc Interv* 2012; **5**: 47-56 [PMID: [22230150](#) DOI: [10.1016/j.jcin.2011.08.019](#)]
 - 85 **Chevalier B**, Glatt B, Royer T, Guyon P. Placement of coronary stents in bifurcation lesions by the "culotte" technique. *Am J Cardiol* 1998; **82**: 943-949 [PMID: [9794349](#) DOI: [10.1016/s0002-9149\(98\)00510-4](#)]
 - 86 **Kawasaki T**, Koga H, Serikawa T. Modified culotte stenting technique for bifurcation lesions: the cross-stenting technique. *J Invasive Cardiol* 2010; **22**: 243-246 [PMID: [20440044](#)]
 - 87 **Wen S**, Yu H, Lee H. Mini-culotte stenting for bifurcation coronary disease. *Chin Med J (Engl)* 2014; **127**: 978-979 [PMID: [24571900](#)]
 - 88 **Chen LL**, Fan L, Chen ZY, Zhen XC, Luo YK, Lin CG, Peng YF. Modified culotte stenting for treatment of complex coronary bifurcation lesions: immediate and 9-month outcomes in a pilot study. *Chin Med J (Engl)* 2011; **124**: 1943-1950 [PMID: [22088451](#)]
 - 89 **Hu F**, Tu S, Cai W, Jiang Z, Zheng H, Xiao L, Qiu C, Xiong C, Yao Y, Chen L. Double kissing mini-culotte versus mini-culotte stenting: insights from micro-computed tomographic imaging of bench testing. *EuroIntervention* 2019; **15**: 465-472 [PMID: [30530401](#) DOI: [10.4244/EIJ-D-18-00688](#)]
 - 90 **Toth GG**, Sasi V, Franco D, Prassl AJ, Di Serafino L, Ng JCK, Szanto G, Schneller L, Ang HY, Plank G, Wijns W, Barbato E. Double-kissing culotte technique for coronary bifurcation stenting. *EuroIntervention* 2020; **16**: e724-e733 [PMID: [32338608](#) DOI: [10.4244/EIJ-D-20-00130](#)]
 - 91 **Liu J**, Li L, Chen C, Wei J, Chen X, Li B, Chen Y, Luo J, Chen SL. Modified kissing balloon inflation associated with

- better results after Culotte stenting for bifurcation lesions: A bench test. *Catheter Cardiovasc Interv* 2020; **96**: E34-E44 [PMID: [31580011](#) DOI: [10.1002/ccd.28497](#)]
- 92 **Colombo A**, Stankovic G, Orlic D, Corvaja N, Liistro F, Airolidi F, Chieffo A, Spanos V, Montorfano M, Di Mario C. Modified T-stenting technique with crushing for bifurcation lesions: immediate results and 30-day outcome. *Catheter Cardiovasc Interv* 2003; **60**: 145-151 [PMID: [14517916](#) DOI: [10.1002/ccd.10622](#)]
 - 93 **Galassi AR**, Tomasello SD, Sacchetta G, Seminara D, Canonico L, Tamburino C. The "mini-crush technique" for the treatment of coronary trifurcation lesions. *EuroIntervention* 2008; **4**: 358-364 [PMID: [19110810](#) DOI: [10.4244/eijv4i3a64](#)]
 - 94 **Collins N**, Dzavik V. A modified balloon crush approach improves side branch access and side branch stent apposition during crush stenting of coronary bifurcation lesions. *Catheter Cardiovasc Interv* 2006; **68**: 365-371 [PMID: [16892432](#) DOI: [10.1002/ccd.20791](#)]
 - 95 **Chen S**, Zhang J, Ye F, Zhu Z, Lin S, Shan S, Kwan TW. DK crush (double-kissing and double-crush) technique for treatment of true coronary bifurcation lesions: illustration and comparison with classic crush. *J Invasive Cardiol* 2007; **19**: 189-193 [PMID: [17404406](#)]
 - 96 **Chen SL**, Zhang JJ, Ye F, Chen YD, Patel T, Kawajiri K, Lee M, Kwan TW, Mintz G, Tan HC. Study comparing the double kissing (DK) crush with classical crush for the treatment of coronary bifurcation lesions: the DKCRUSH-I Bifurcation Study with drug-eluting stents. *Eur J Clin Invest* 2008; **38**: 361-371 [PMID: [18489398](#) DOI: [10.1111/j.1365-2362.2008.01949.x](#)]
 - 97 **Lavarra F**. Proximal Side-Branch Optimization in Crush Stenting: A Step-by-Step Technical Approach in a Silicone Phantom Model. *Cardiovasc Revasc Med* 2021; **28**: 88-91 [PMID: [32958440](#) DOI: [10.1016/j.carrev.2020.07.037](#)]
 - 98 **Lavarra F**. Proximal side optimization: a modification of the double kissing crush technique. *US Cardiol Rev* 2020; **14**: e02 [DOI: [10.15420/usc.2020.07](#)]
 - 99 **Erglis A**, Price MJ. Stenting Approaches to the Bifurcation Lesion. In: Price MJ (Editor). *Coronary stenting: A companion to Topol's Textbook of interventional cardiology*. Pennsylvania: Elsevier Saunders, 2012: 176-196
 - 100 **Zhang JJ**, Chen SL, Ye F, Yang S, Kan J, Liu YQ, Zhou Y, Sun XW, Zhang AP, Wang X, Chen J. Mechanisms and clinical significance of quality of final kissing balloon inflation in patients with true bifurcation lesions treated by crush stenting technique. *Chin Med J (Engl)* 2009; **122**: 2086-2091 [PMID: [19781289](#)]
 - 101 **Ray S**, Bhattacharjee P. "Nano crush" technique for bifurcation stenting, presented in 12th EBC bifurcation meeting; 2016 Oct 15-16; Rotherdam, Netherlands [DOI: [10.1002/9781444347005.ch4](#)]
 - 102 **Ray S**, Bhattacharjee P, Mukherjee P. Letter to the editor regarding the original article by Gianluca Rigatelli *et al.* presenting novel stenting technique for complex coronary bifurcation. *Catheter Cardiovasc Interv* 2019; **94**: 311 [PMID: [30790441](#) DOI: [10.1002/ccd.28153](#)]
 - 103 **Rigatelli G**, Zuin M, Dell'Avvocata F, Vassilev D, Daggubati R, Nguyen T, Nguyễn MTN, Foin N. Complex coronary bifurcation treatment by a novel stenting technique: Bench test, fluid dynamic study and clinical outcomes. *Catheter Cardiovasc Interv* 2018; **92**: 907-914 [PMID: [29368394](#) DOI: [10.1002/ccd.27494](#)]
 - 104 **Rigatelli G**, Zuin M, Vassilev D, Dinh H, Dell'Avvocata F, Van Tan N, Nghia N, Ronco F, Roncon L. Feasibility, safety and long-term outcomes of complex left main bifurcation treatment using the nano-inverted-t stenting: a multicentre prospective registry. *Int J Cardiovasc Imaging* 2021; **37**: 1107-1119 [PMID: [33200318](#) DOI: [10.1007/s10554-020-02106-x](#)]
 - 105 **Rigatelli G**, Zuin M, Dash D. Thin and crush: The new mantra in left main stenting? *World J Cardiol* 2018; **10**: 191-195 [PMID: [30510635](#) DOI: [10.4330/wjc.v10.i11.191](#)]
 - 106 **Ray S**, Mukherjee P, Bandyopadhyay S, Karmakar S, Mitra S, Bhattacharjee P. A novel "nano-crush" technique for the management of coronary bifurcation lesions: in vitro bench test analysis and preliminary report on real-world clinical evaluation in patients with one-year angiographic follow-up. *AsiaIntervention* 2019; **5**: 41-51 [DOI: [10.1016/j.jacc.2017.03.084](#)]
 - 107 **Morris PD**, Gosling R, Rothman A, Iqbal J, Chiastra C, Colombo M, Migliavacca F, Banning A, Gunn JP. Double-Kissing Nanocrush for Bifurcation Lesions: Development, Bioengineering, Fluid Dynamics, and Initial Clinical Testing. *Can J Cardiol* 2020; **36**: 852-859 [PMID: [32088059](#) DOI: [10.1016/j.cjca.2019.08.037](#)]
 - 108 **Rigatelli G**, Zuin M, Vassilev D, Dinh H, Giatti S, Carraro M, Zanon F, Roncon L, Dung HT. Culotte versus the novel nano-crush technique for unprotected complex bifurcation left main stenting: difference in procedural time, contrast volume and X-ray exposure and 3-years outcomes. *Int J Cardiovasc Imaging* 2019; **35**: 207-214 [PMID: [30446919](#) DOI: [10.1007/s10554-018-1497-8](#)]
 - 109 **Sweeny JM**, Sharma SK. Simultaneous kissing stent technique: A contemporary review. In: Waksman R, Ormiston JA. *Bifurcation Stenting*. UK: Blackwell Publishing, 2012: 48-56 [DOI: [10.1002/9781444347005.ch5](#)]
 - 110 **Lansky AJ**, Yaqub M, Hermiller JB, Smith RS, Farhat N, Caputo R, Williams JE, Sanz M, Koo K, Sood P, Sudhir K, Stone GW. Side branch occlusion with everolimus-eluting and paclitaxel-eluting stents: three-year results from the SPIRIT III randomised trial. *EuroIntervention* 2010; **6** Suppl J: J44-J52 [PMID: [21930490](#) DOI: [10.4244/EIJV6SUPJA8](#)]
 - 111 **Zhou Y**, Chen S, Huang L, Hildick-Smith D, Ferenc M, Jabbour RJ, Azzalini L, Colombo A, Chieffo A, Zhao X. Definite stent thrombosis after drug-eluting stent implantation in coronary bifurcation lesions: A meta-analysis of 3,107 patients from 14 randomized trials. *Catheter Cardiovasc Interv* 2018; **92**: 680-691 [PMID: [29214736](#) DOI: [10.1002/ccd.27443](#)]
 - 112 **Grundeken MJ**, Wykrzykowska JJ, Ishibashi Y, Garg S, de Vries T, Garcia-Garcia HM, Onuma Y, de Winter RJ, Buszman P, Linke A, Ischinger T, Klauss V, Eberli F, Corti R, Wijns W, Morice MC, di Mario C, Meier B, Jüni P, Yazdani A, Copt S, Windecker S, Serruys PW. First generation versus second generation drug-eluting stents for the treatment of bifurcations: 5-year follow-up of the LEADERS all-comers randomized trial. *Catheter Cardiovasc Interv* 2016; **87**: E248-E260 [PMID: [26649651](#) DOI: [10.1002/ccd.26344](#)]
 - 113 **Bechiri MY**, Souteyrand G, Lefèvre T, Trouillet C, Rangé G, Cayla G, Dérimey F, Mangin L, Meneveau N, Caussin C, Motreff P, Amabile N. Characteristics of stent thrombosis in bifurcation lesions analysed by optical coherence tomography. *EuroIntervention* 2018; **13**: e2174-e2181 [PMID: [29278349](#) DOI: [10.4244/EIJ-D-17-00794](#)]
 - 114 **Mintz GS**, Lefèvre T, Lassen JF, Testa L, Pan M, Singh J, Stankovic G, Banning AP. Intravascular ultrasound in the evaluation and treatment of left main coronary artery disease: a consensus statement from the European Bifurcation Club.

- EuroIntervention* 2018; **14**: e467-e474 [PMID: 29688182 DOI: 10.4244/EIJ-D-18-00194]
- 115 **Onuma Y**, Katagiri Y, Burzotta F, Holm NR, Amabile N, Okamura T, Mintz GS, Darremont O, Lassen JF, Lefèvre T, Louvard Y, Stankovic G, Serruys PW. Joint consensus on the use of OCT in coronary bifurcation lesions by the European and Japanese bifurcation clubs. *EuroIntervention* 2019; **14**: e1568-e1577 [PMID: 30479307 DOI: 10.4244/EIJ-D-18-00391]
 - 116 **Suárez de Lezo J**, Medina A, Martín P, Novoa J, Suárez de Lezo J, Pan M, Caballero E, Melián F, Mazuelos F, Quevedo V. Predictors of ostial side branch damage during provisional stenting of coronary bifurcation lesions not involving the side branch origin: an ultrasonographic study. *EuroIntervention* 2012; **7**: 1147-1154 [PMID: 22030298 DOI: 10.4244/EIJV7I10A185]
 - 117 **Park SJ**, Kim YH, Park DW, Lee SW, Kim WJ, Suh J, Yun SC, Lee CW, Hong MK, Lee JH, Park SW; MAIN-COMPARE Investigators. Impact of intravascular ultrasound guidance on long-term mortality in stenting for unprotected left main coronary artery stenosis. *Circ Cardiovasc Interv* 2009; **2**: 167-177 [PMID: 20031713 DOI: 10.1161/CIRCINTERVENTIONS.108.799494]
 - 118 **Andell P**, Karlsson S, Mohammad MA, Götzberg M, James S, Jensen J, Fröbert O, Angerås O, Nilsson J, Omerovic E, Lagerqvist B, Persson J, Koul S, Erlinge D. Intravascular Ultrasound Guidance Is Associated With Better Outcome in Patients Undergoing Unprotected Left Main Coronary Artery Stenting Compared With Angiography Guidance Alone. *Circ Cardiovasc Interv* 2017; **10** [PMID: 28487356 DOI: 10.1161/CIRCINTERVENTIONS.116.004813]
 - 119 **Kinnaird T**, Johnson T, Anderson R, Gallagher S, Sinker A, Ludman P, de Belder M, Copt S, Oldroyd K, Banning A, Mamas M, Curzen N. Intravascular Imaging and 12-Month Mortality After Unprotected Left Main Stem PCI: An Analysis From the British Cardiovascular Intervention Society Database. *JACC Cardiovasc Interv* 2020; **13**: 346-357 [PMID: 32029252 DOI: 10.1016/j.jcin.2019.10.007]
 - 120 **Wang Y**, Mintz GS, Gu Z, Qi Y, Wang Y, Liu M, Wu X. Meta-analysis and systematic review of intravascular ultrasound versus angiography-guided drug eluting stent implantation in left main coronary disease in 4592 patients. *BMC Cardiovasc Disord* 2018; **18**: 115 [PMID: 29898668 DOI: 10.1186/s12872-018-0843-z]
 - 121 **Ye Y**, Yang M, Zhang S, Zeng Y. Percutaneous coronary intervention in left main coronary artery disease with or without intravascular ultrasound: A meta-analysis. *PLoS One* 2017; **12**: e0179756 [PMID: 28640875 DOI: 10.1371/journal.pone.0179756]
 - 122 **Chen L**, Xu T, Xue XJ, Zhang JJ, Ye F, Tian NL, Chen SL. Intravascular ultrasound-guided drug-eluting stent implantation is associated with improved clinical outcomes in patients with unstable angina and complex coronary artery true bifurcation lesions. *Int J Cardiovasc Imaging* 2018; **34**: 1685-1696 [PMID: 29981016 DOI: 10.1007/s10554-018-1393-2]
 - 123 **Holm NR**, Andreassen LN, Walsh S, Kajander OA, Witt N, Eek C, Knaapen P, Koltowski L, Gutiérrez-Chico JL, Burzotta F, Kockman J, Ormiston J, Santos-Pardo I, Laanmets P, Mylotte D, Madsen M, Hjort J, Kumsars I, Råmunddal T, Christiansen EH. Rational and design of the European randomized Optical Coherence Tomography Optimized Bifurcation Event Reduction Trial (OCTOBER). *Am Heart J* 2018; **205**: 97-109 [PMID: 30205242 DOI: 10.1016/j.ahj.2018.08.003]
 - 124 **Miyazaki Y**, Muramatsu T, Asano T, Katagiri Y, Sotomi Y, Nakatani S, Takahashi K, Kogame N, Higuchi Y, Ishikawa M, Kyono H, Yano M, Ozaki Y, Serruys PW, Okamura T, Onuma Y. Online three-dimensional OFDI-guided versus angiography-guided PCI in bifurcation lesions: design and rationale of the randomised OPTIMUM trial. *EuroIntervention* 2021; **16**: 1333-1341 [PMID: 31289018 DOI: 10.4244/EIJ-D-18-00902]
 - 125 **Gogas BD**, Fei Y, Song L, Alexopoulos D, Lavarra F, Rab T, King SB 3rd, Chen SL. Left Main Coronary Interventions: A Practical Guide. *Cardiovasc Revasc Med* 2020; **21**: 1596-1605 [PMID: 32546382 DOI: 10.1016/j.carrev.2020.05.014]
 - 126 **Rab T**, Sheiban I, Louvard Y, Sawaya FJ, Zhang JJ, Chen SL. Current Interventions for the Left Main Bifurcation. *JACC Cardiovasc Interv* 2017; **10**: 849-865 [PMID: 28473107 DOI: 10.1016/j.jcin.2017.02.037]
 - 127 **Case BC**, Yerasi C, Forrestal BJ, Shlofmitz E, Garcia-Garcia HM, Mintz GS, Waksman R. Intravascular ultrasound guidance in the evaluation and treatment of left main coronary artery disease. *Int J Cardiol* 2021; **325**: 168-175 [PMID: 33039578 DOI: 10.1016/j.ijcard.2020.10.008]
 - 128 **Patel MR**, Calhoon JH, Dehmer GJ, Grantham JA, Maddox TM, Maron DJ, Smith PK. ACC/AATS/AHA/ASE/ASNC/SCAI/SCCT/STS 2017 Appropriate Use Criteria for Coronary Revascularization in Patients With Stable Ischemic Heart Disease : A Report of the American College of Cardiology Appropriate Use Criteria Task Force, American Association for Thoracic Surgery, American Heart Association, American Society of Echocardiography, American Society of Nuclear Cardiology, Society for Cardiovascular Angiography and Interventions, Society of Cardiovascular Computed Tomography, and Society of Thoracic Surgeons. *J Nucl Cardiol* 2017; **24**: 1759-1792 [PMID: 28608183 DOI: 10.1007/s12350-017-0917-9]
 - 129 **Stone GW**, Kappetein AP, Sabik JF, Pocock SJ, Morice MC, Puskas J, Kandzari DE, Karpaliotis D, Brown WM 3rd, Lembo NJ, Banning A, Merkely B, Horkay F, Boonstra PW, van Boven AJ, Ungi I, Bogáts G, Mansour S, Noiseux N, Sabaté M, Pomar J, Hickey M, Gershlick A, Buszman PE, Bochenek A, Schampaert E, Pagé P, Modolo R, Gregson J, Simonton CA, Mehran R, Kosmidou I, Génèreux P, Crowley A, Dressler O, Serruys PW; EXCEL Trial Investigators. Five-Year Outcomes after PCI or CABG for Left Main Coronary Disease. *N Engl J Med* 2019; **381**: 1820-1830 [PMID: 31562798 DOI: 10.1056/NEJMoa1909406]
 - 130 **Holm NR**, Mäkilä T, Lindsay MM, Spence MS, Erglis A, Menown IBA, Trovik T, Kellerth T, Kalinauskas G, Mogensen LJH, Nielsen PH, Niemelä M, Lassen JF, Oldroyd K, Berg G, Stradins P, Walsh SJ, Graham ANJ, Endresen PC, Fröbert O, Trivedi U, Anttila V, Hildick-Smith D, Thuesen L, Christiansen EH; NOBLE investigators. Percutaneous coronary angioplasty versus coronary artery bypass grafting in the treatment of unprotected left main stenosis: updated 5-year outcomes from the randomised, non-inferiority NOBLE trial. *Lancet* 2020; **395**: 191-199 [PMID: 31879028 DOI: 10.1016/S0140-6736(19)32972-1]
 - 131 **Taggart DP**, Gaudino M. PCI or CABG for Left Main Coronary Artery Disease. *N Engl J Med* 2020; **383**: 290 [PMID: 32668123 DOI: 10.1056/NEJMc2000645]
 - 132 **Ahmad Y**, Howard JP, Arnold AD, Cook CM, Prasad M, Ali ZA, Parikh MA, Kosmidou I, Francis DP, Moses JW, Leon MB, Kirtane AJ, Stone GW, Karpaliotis D. Mortality after drug-eluting stents vs. coronary artery bypass grafting for left

- main coronary artery disease: a meta-analysis of randomized controlled trials. *Eur Heart J* 2020; **41**: 3228-3235 [PMID: [32118272](#) DOI: [10.1093/eurheartj/ehaa135](#)]
- 133 **Modi BN**, van de Hoef TP, Piek JJ, Perera D. Physiological assessment of left main coronary artery disease. *EuroIntervention* 2017; **13**: 820-827 [PMID: [28606883](#) DOI: [10.4244/EIJ-D-17-00135](#)]
 - 134 **Park SJ**, Ahn JM, Kang SJ, Yoon SH, Koo BK, Lee JY, Kim WJ, Park DW, Lee SW, Kim YH, Lee CW, Park SW. Intravascular ultrasound-derived minimal lumen area criteria for functionally significant left main coronary artery stenosis. *JACC Cardiovasc Interv* 2014; **7**: 868-874 [PMID: [25147031](#) DOI: [10.1016/j.jcin.2014.02.015](#)]
 - 135 **Johnson TW**, Räber L, di Mario C, Bourantas C, Jia H, Mattesini A, Gonzalo N, de la Torre Hernandez JM, Prati F, Koskinas K, Joner M, Radu MD, Erlinge D, Regar E, Kunadian V, Maehara A, Byrne RA, Capodanno D, Akasaka T, Wijns W, Mintz GS, Guagliumi G. Clinical use of intracoronary imaging. Part 2: acute coronary syndromes, ambiguous coronary angiography findings, and guiding interventional decision-making: an expert consensus document of the European Association of Percutaneous Cardiovascular Interventions. *Eur Heart J* 2019; **40**: 2566-2584 [PMID: [31112213](#) DOI: [10.1093/eurheartj/ehz332](#)]
 - 136 **Kang SJ**, Ahn JM, Song H, Kim WJ, Lee JY, Park DW, Yun SC, Lee SW, Kim YH, Lee CW, Mintz GS, Park SW, Park SJ. Comprehensive intravascular ultrasound assessment of stent area and its impact on restenosis and adverse cardiac events in 403 patients with unprotected left main disease. *Circ Cardiovasc Interv* 2011; **4**: 562-569 [PMID: [22045969](#) DOI: [10.1161/CIRCINTERVENTIONS.111.964643](#)]
 - 137 **Maehara A**. Abstract 903-08. Presented at: American College of Cardiology Scientific Session; March 17-19, 2017; Washington, DC
 - 138 **Ladwiniec A**, Walsh SJ, Holm NR, Hanratty CG, Mäkilä T, Kellerth T, Hildick-Smith D, Mogensen LJH, Hartikainen J, Menown IBA, Erglis A, Eriksen E, Spence MS, Thuesen L, Christiansen EH. Intravascular ultrasound to guide left main stem intervention: a NOBLE trial substudy. *EuroIntervention* 2020; **16**: 201-209 [PMID: [32122821](#) DOI: [10.4244/EIJ-D-19-01003](#)]
 - 139 **Nishida K**, Toyofuku M, Morimoto T, Ohya M, Fuku Y, Higami H, Yamaji K, Muranishi H, Yamaji Y, Furukawa D, Tada T, Ko E, Kadota K, Ando K, Sakamoto H, Tamura T, Kawai K, Kimura T; AOI LMCA Stenting Registry Investigators. Prognostic impact of final kissing balloon technique after crossover stenting for the left main coronary artery: from the AOI-LMCA registry. *Cardiovasc Interv Ther* 2019; **34**: 197-206 [PMID: [29691767](#) DOI: [10.1007/s12928-018-0522-0](#)]
 - 140 **Oviedo C**, Maehara A, Mintz GS, Araki H, Choi SY, Tsujita K, Kubo T, Doi H, Templin B, Lansky AJ, Dangas G, Leon MB, Mehran R, Tahk SJ, Stone GW, Ochiai M, Moses JW. Intravascular ultrasound classification of plaque distribution in left main coronary artery bifurcations: where is the plaque really located? *Circ Cardiovasc Interv* 2010; **3**: 105-112 [PMID: [20197513](#) DOI: [10.1161/CIRCINTERVENTIONS.109.906016](#)]
 - 141 **Jeger RV**, Eccleshall S, Wan Ahmad WA, Ge J, Poerner TC, Shin ES, Alfonso F, Latib A, Ong PJ, Rissanen TT, Saucedo J, Scheller B, Kleber FX; International DCB Consensus Group. Drug-Coated Balloons for Coronary Artery Disease: Third Report of the International DCB Consensus Group. *JACC Cardiovasc Interv* 2020; **13**: 1391-1402 [PMID: [32473887](#) DOI: [10.1016/j.jcin.2020.02.043](#)]
 - 142 **Kleber FX**, Rittger H, Ludwig J, Schulz A, Mathey DG, Boxberger M, Degenhardt R, Scheller B, Strasser RH. Drug eluting balloons as stand alone procedure for coronary bifurcational lesions: results of the randomized multicenter PEPCAD-BIF trial. *Clin Res Cardiol* 2016; **105**: 613-621 [PMID: [26768146](#) DOI: [10.1007/s00392-015-0957-6](#)]
 - 143 **Megaly M**, Rofael M, Saad M, Shishehbor M, Brilakis ES. Outcomes With Drug-Coated Balloons for Treating the Side Branch of Coronary Bifurcation Lesions. *J Invasive Cardiol* 2018; **30**: 393-399 [PMID: [30218555](#)]
 - 144 **Tzanis G**, Kolyviras A, Giannini F, Colombo A, Tzifos V. POT-sideDCB-POT: A novel technique for treating coronary bifurcation lesions. *Hellenic J Cardiol* 2021; **62**: 161-163 [PMID: [32387590](#) DOI: [10.1016/j.hjc.2020.04.017](#)]
 - 145 **Harada Y**, Collieran R, Pinieck S, Giacoppo D, Michel J, Kufner S, Cassese S, Joner M, Ibrahim T, Laugwitz KL, Kastrati A, Byrne RA. Angiographic and clinical outcomes of patients treated with drug-coated balloon angioplasty for in-stent restenosis after coronary bifurcation stenting with a two-stent technique. *EuroIntervention* 2017; **12**: 2132-2139 [PMID: [27916742](#) DOI: [10.4244/EIJ-D-16-00226](#)]
 - 146 **Gil RJ**, Bil J, Džavik V, Vassilev D, Kern A, Formuszewicz R, Zalewska-Adamiec M, Dobrzycki S. Regular Drug-Eluting Stent vs Dedicated Coronary Bifurcation BioSS Expert Stent: Multicenter Open-Label Randomized Controlled POLBOS I Trial. *Can J Cardiol* 2015; **31**: 671-678 [PMID: [25828372](#) DOI: [10.1016/j.cjca.2014.12.024](#)]
 - 147 **Gil RJ**, Bil J, Grundeken MJ, Kern A, Iñigo Garcia LA, Vassilev D, Pawłowski T, Formuszewicz R, Dobrzycki S, Wykrzykowska JJ, Serruys PW. Regular drug-eluting stents versus the dedicated coronary bifurcation sirolimus-eluting BioSS LIM® stent: the randomised, multicentre, open-label, controlled POLBOS II trial. *EuroIntervention* 2016; **12**: e1404-e1412 [PMID: [26600564](#) DOI: [10.4244/EIJY15M11_11](#)]
 - 148 **Konigstein M**, Srdanovic I, Gore AK, Rahim HM, Génereux P, Ben-Yehuda O, Kumsars I, Lesiak M, Kini A, Fontos G, Slagboom T, Ungi I, Christopher Metzger D, Crowley A, Leon MB, Ali ZA. Outcomes of the Tryton-dedicated bifurcation stent for the treatment of true coronary bifurcations: Individual-patient-data pooled analysis. *Catheter Cardiovasc Interv* 2019; **93**: 1255-1261 [PMID: [30489011](#) DOI: [10.1002/ccd.27952](#)]
 - 149 **Dubois CL**, Wijns W. The AXCESS™ self-expanding biolimus A9™ eluting stent system for coronary bifurcation lesions. *EuroIntervention* 2010; **6** Suppl J: J130-J134 [PMID: [21930477](#) DOI: [10.4244/EIJV6SUPJA21](#)]
 - 150 **Bennett J**, Adriaenssens T, McCutcheon K, Dens J, Desmet W, Sinnaeve P, Vrolix M, Dubois C. 5-Year clinical follow-up of the COBRA (complex coronary bifurcation lesions: Randomized comparison of a strategy using a dedicated self-expanding biolimus A9-eluting stent vs. a culotte strategy using everolimus-eluting stents) study. *Catheter Cardiovasc Interv* 2018; **92**: E375-E380 [PMID: [29536609](#) DOI: [10.1002/ccd.27597](#)]
 - 151 **Rawasia WF**, Alkhouli M. Dedicated Bifurcation Stents vs. Conventional Stenting Strategy for Coronary Bifurcation Lesions: Insights from Randomized Clinical Trials. *Cardiovasc Revasc Med* 2020; **21**: 556-558 [PMID: [31928939](#) DOI: [10.1016/j.carrev.2019.12.033](#)]
 - 152 **Zimarino M**, Briguori C, Amat-Santos IJ, Radico F, Barbato E, Chieffo A, Cirillo P, Costa RA, Erglis A, Gamra H, Gil RJ, Kanic V, Kedev SA, Maddestra N, Nakamura S, Pellicano M, Petrov I, Strozzi M, Tesorio T, Vukcevic V, De

- Caterina R, Stankovic G; EuroBifurcation Club. Mid-term outcomes after percutaneous interventions in coronary bifurcations. *Int J Cardiol* 2019; **283**: 78-83 [PMID: [30528620](#) DOI: [10.1016/j.ijcard.2018.11.139](#)]
- 153 **Collet JP**, Thiele H, Barbato E, Barthélémy O, Bauersachs J, Bhatt DL, Dendale P, Dorobantu M, Edvardsen T, Folliquet T, Gale CP, Gilard M, Jobs A, Jüni P, Lambrinou E, Lewis BS, Mehilli J, Meliga E, Merkely B, Mueller C, Roffi M, Rutten FH, Sibbing D, Siontis GCM; ESC Scientific Document Group. 2020 ESC Guidelines for the management of acute coronary syndromes in patients presenting without persistent ST-segment elevation. *Eur Heart J* 2021; **42**: 1289-1367 [PMID: [32860058](#) DOI: [10.1093/eurheartj/ehaa575](#)]
- 154 **Valgimigli M**, Bueno H, Byrne RA, Collet JP, Costa F, Jeppsson A, Jüni P, Kastrati A, Kolh P, Mauri L, Montalescot G, Neumann FJ, Petricevic M, Roffi M, Steg PG, Windecker S, Zamorano JL, Levine GN; ESC Scientific Document Group; ESC Committee for Practice Guidelines (CPG); ESC National Cardiac Societies. 2017 ESC focused update on dual antiplatelet therapy in coronary artery disease developed in collaboration with EACTS: The Task Force for dual antiplatelet therapy in coronary artery disease of the European Society of Cardiology (ESC) and of the European Association for Cardio-Thoracic Surgery (EACTS). *Eur Heart J* 2018; **39**: 213-260 [PMID: [28886622](#) DOI: [10.1093/eurheartj/ehx419](#)]
- 155 **Costa F**, Van Klaveren D, Feres F, James S, Räber L, Pilgrim T, Hong MK, Kim HS, Colombo A, Steg PG, Bhatt DL, Stone GW, Windecker S, Steyerberg EW, Valgimigli M; PRECISE-DAPT Study Investigators. Dual Antiplatelet Therapy Duration Based on Ischemic and Bleeding Risks After Coronary Stenting. *J Am Coll Cardiol* 2019; **73**: 741-754 [PMID: [30784667](#) DOI: [10.1016/j.jacc.2018.11.048](#)]
- 156 **Lawton JS**, Tamis-Holland JE, Bangalore S, Bates ER, Beckie TM, Bischoff JM, Bittl JA, Cohen MG, DiMaio JM, Don CW, Fremes SE, Gaudino MF, Goldberger ZD, Grant MC, Jaswal JB, Kurlansky PA, Mehran R, Metkus TS Jr, Nnacheta LC, Rao SV, Sellke FW, Sharma G, Yong CM, Zwischenberger BA. 2021 ACC/AHA/SCAI Guideline for Coronary Artery Revascularization: Executive Summary: A Report of the American College of Cardiology/American Heart Association Joint Committee on Clinical Practice Guidelines. *Circulation* 2022; **145**: e4-e17 [PMID: [34882436](#) DOI: [10.1161/CIR.0000000000001039](#)]



Published by **Baishideng Publishing Group Inc**
7041 Koll Center Parkway, Suite 160, Pleasanton, CA 94566, USA

Telephone: +1-925-3991568

E-mail: bpgoffice@wjgnet.com

Help Desk: <https://www.f6publishing.com/helpdesk>

<https://www.wjgnet.com>

