

World Journal of *Cardiology*

World J Cardiol 2022 June 26; 14(6): 329-381



OPINION REVIEW

- 329 Metabolic and cardiovascular benefits with combination therapy of SGLT-2 inhibitors and GLP-1 receptor agonists in type 2 diabetes
Singh AK, Singh R

MINIREVIEWS

- 343 COVID-19 vaccination and cardiac dysfunction
Leowattana W, Leowattana T
- 355 Takotsubo cardiomyopathy: A comprehensive review
Barmore W, Patel H, Harrell S, Garcia D, Calkins Jr JB

ORIGINAL ARTICLE**Observational Study**

- 363 Association of obesity anthropometric indices with hypertension, diabetes mellitus and hypertriglyceridemia in apparently healthy adult Nigerian population
Sirisena A, Okeahialam B
- 372 Study of coronary sinus anatomy during levophase of coronary angiography
Pradhan A, Bajaj V, Vishwakarma P, Bhandari M, Sharma A, Chaudhary G, Chandra S, Sethi R, Narain VS, Dwivedi S

ABOUT COVER

Editorial Board Member of *World Journal of Cardiology*, Enkhsaikhan Purevjav, MD, PhD, Associate Professor, Department of Pediatrics, Cardiology Genetic Research Laboratory, UTHSC, Le Bonheur Children's Hospital, Memphis, TN 38103, United States. epurevja@uthsc.edu

AIMS AND SCOPE

The primary aim of *World Journal of Cardiology* (*WJC*, *World J Cardiol*) is to provide scholars and readers from various fields of cardiology with a platform to publish high-quality basic and clinical research articles and communicate their research findings online.

WJC mainly publishes articles reporting research results and findings obtained in the field of cardiology and covering a wide range of topics including acute coronary syndromes, aneurysm, angina, arrhythmias, atherosclerosis, atrial fibrillation, cardiomyopathy, congenital heart disease, coronary artery disease, heart failure, hypertension, imaging, infection, myocardial infarction, pathology, peripheral vessels, public health, Raynaud's syndrome, stroke, thrombosis, and valvular disease.

INDEXING/ABSTRACTING

The *WJC* is now abstracted and indexed in Emerging Sources Citation Index (Web of Science), PubMed, PubMed Central, Scopus, Reference Citation Analysis, China National Knowledge Infrastructure, China Science and Technology Journal Database, and Superstar Journals Database. The 2021 edition of Journal Citation Reports® cites the 2020 Journal Citation Indicator (JCI) for *WJC* as 0.36. The *WJC*'s CiteScore for 2020 is 0.3, and Scopus CiteScore rank 2020: Cardiology and Cardiovascular Medicine is 289/317.

RESPONSIBLE EDITORS FOR THIS ISSUE

Production Editor: Hua-Ge Yin; Production Department Director: Xiang Li; Editorial Office Director: Ya-Juan Ma.

NAME OF JOURNAL

World Journal of Cardiology

ISSN

ISSN 1949-8462 (online)

LAUNCH DATE

December 31, 2009

FREQUENCY

Monthly

EDITORS-IN-CHIEF

Ramdas G Pai, Dimitrios Tousoulis, Marco Matteo Ciccone, Pal Pacher

EDITORIAL BOARD MEMBERS

<https://www.wjnet.com/1949-8462/editorialboard.htm>

PUBLICATION DATE

June 26, 2022

COPYRIGHT

© 2022 Baishideng Publishing Group Inc

INSTRUCTIONS TO AUTHORS

<https://www.wjnet.com/bpg/gerinfo/204>

GUIDELINES FOR ETHICS DOCUMENTS

<https://www.wjnet.com/bpg/GerInfo/287>

GUIDELINES FOR NON-NATIVE SPEAKERS OF ENGLISH

<https://www.wjnet.com/bpg/gerinfo/240>

PUBLICATION ETHICS

<https://www.wjnet.com/bpg/GerInfo/288>

PUBLICATION MISCONDUCT

<https://www.wjnet.com/bpg/gerinfo/208>

ARTICLE PROCESSING CHARGE

<https://www.wjnet.com/bpg/gerinfo/242>

STEPS FOR SUBMITTING MANUSCRIPTS

<https://www.wjnet.com/bpg/GerInfo/239>

ONLINE SUBMISSION

<https://www.f6publishing.com>



COVID-19 vaccination and cardiac dysfunction

Wattana Leowattana, Tawitthep Leowattana

Specialty type: Cardiac and cardiovascular systems

Provenance and peer review: Invited article; Externally peer reviewed.

Peer-review model: Single blind

Peer-review report's scientific quality classification

Grade A (Excellent): A
Grade B (Very good): 0
Grade C (Good): C
Grade D (Fair): 0
Grade E (Poor): 0

P-Reviewer: Shamseldeen AA, Egypt; Watanabe A, Japan

A-Editor: Yao QG

Received: January 15, 2022

Peer-review started: January 15, 2022

First decision: March 16, 2022

Revised: March 27, 2022

Accepted: May 17, 2022

Article in press: May 17, 2022

Published online: June 26, 2022



Wattana Leowattana, Clinical Tropical Medicine, Faculty of Tropical Medicine, Mahidol University, Bangkok 10400, Thailand

Tawitthep Leowattana, Department of Medicine, Faculty of Medicine, Srinakharinwirot University, Bangkok 10110, Thailand

Corresponding author: Wattana Leowattana, MD, MSc, PhD, Professor, Clinical Tropical Medicine, Faculty of Tropical Medicine, Mahidol University, 420/6 Rajavithi road, Rajatawee, Bangkok 10400, Thailand. wattana.leo@mahidol.ac.th

Abstract

The coronavirus disease 2019 (COVID-19) mRNA vaccine against severe acute respiratory syndrome coronavirus 2 infections has reduced the number of symptomatic patients globally. A case series of vaccine-related myocarditis or pericarditis has been published with extensive vaccination, most notably in teenagers and young adults. Men seem to be impacted more often, and symptoms commonly occur within 1 wk after immunization. The clinical course is mild in the majority of cases. Based on the evidence, a clinical framework to guide physicians to examine, analyze, identify, and report suspected and confirmed cardiac dysfunction cases is needed. A standardized workup for every patient with strongly suspicious symptoms associated with the COVID-19 mRNA vaccine comprises serum cardiac troponin measurement and a 12-lead electrocardiogram (ECG). For patients with unexplained elevation of cardiac troponin and pathologic ECG, echocardiography is recommended. Consultation with a cardiovascular expert and hospitalization should be considered in this group of patients. Treatment is primarily symptomatic and supportive. Deferring a 2nd dose of the COVID-19 mRNA vaccination in individuals with suspected myocarditis or pericarditis after the 1st dose is suggested until further safety data become available.

Key Words: Cardiac dysfunction; Myocarditis; Pericarditis; COVID-19; mRNA vaccine; Electrocardiography; Echocardiography; SARS-CoV-2

©The Author(s) 2022. Published by Baishideng Publishing Group Inc. All rights reserved.

Core Tip: A possible hypersensitivity myocarditis with a consistent relationship to administering an mRNA coronavirus disease 2019 (COVID-19) vaccination was reported. While the actual prevalence of this adverse event is unclear at this time, the clinical manifestation and pathological findings point to a link with an inflammatory reaction to a COVID-19 immunization. However, acute myocarditis following mRNA COVID-19 vaccination was very low and mostly self-limited. Moreover, the high efficacy of mRNA COVID-19 vaccines in preventing further pandemic conditions, reducing disease severity, and the occurrence of a very low incidence of myocarditis following immunization should be a strength of an mRNA COVID-19 vaccine for public trust.

Citation: Leowattana W, Leowattana T. COVID-19 vaccination and cardiac dysfunction. *World J Cardiol* 2022; 14(6): 343-354

URL: <https://www.wjgnet.com/1949-8462/full/v14/i6/343.htm>

DOI: <https://dx.doi.org/10.4330/wjc.v14.i6.343>

INTRODUCTION

Myocarditis or pericarditis is an inflammatory heart condition caused by infections, drug exposure, or immune system activation[1,2]. It has a wide range of clinical manifestations and courses, with most cases resolving spontaneously. However, it is also a cause of sudden cardiac death in young people. Furthermore, in some instances, inflammation can induce significant scarring, which causes left ventricular (LV) remodeling and finally leads to dilated cardiomyopathy or a predominant hypokinetic nondilated phenotype of cardiomyopathy[3,4]. Myocarditis has previously been reported following non-mRNA vaccine immunization. The incidence of myocarditis after a live smallpox vaccination was 2.2-7.8 *per* 100000, which occurred within 30 d after immunization[5,6]. The majority of adverse events that occur after vaccination in these people resolve without long-term consequences. Measles-mumps-rubella, chickenpox, yellow fever, and oral polio vaccine, have a 0.24 *per* 100000 immunization risk of pericarditis or myocarditis in the 42 d following vaccination[7].

During post-marketing pharmacovigilance surveillance, a considerably higher incidence of myocarditis or pericarditis than predicted was detected after coronavirus disease 2019 (COVID-19) immunization using mRNA vaccines[8]. As a result, the United States Food and Drug Administration, followed by the European Medicines Agency, listed myocarditis and pericarditis as extremely uncommon adverse drug reactions in the product information for Moderna and Pfizer-BioNTech[9,10]. Myocarditis or pericarditis is becoming more common as an unusual consequence of the COVID-19 mRNA vaccines, particularly in young adults and adolescent men. This article delves deeper into this phenomenon and its possible pathophysiology. We also examine the trade-off between the danger of myocarditis or pericarditis from mRNA vaccination and the cardiac and other hazards associated with COVID-19.

INCIDENCE AND CLINICAL MANIFESTATIONS OF MYOCARDITIS AFTER COVID-19 VACCINATION

Witberg *et al*[11] analyzed Clalit Health Services, Israel's biggest health care organization, for the myocarditis patients who had been immunized with one dose of the mRNA vaccine BNT162b2 (Pfizer-BioNTech). Clalit Health Services provided health care for 4.7 million patients (52% of the total population) regarding socioeconomic status and prevalence of co-existing diseases. They explored 2558421 members who were vaccinated with one dose of the mRNA vaccine; along with 2401605 members who were vaccinated with 2 doses. They discovered 54 patients who satisfied the research criteria for myocarditis. There were 41 mild cases, 12 moderate cases, and 1 fatal case. The median age of these patients was 27 (21-35) years, with 94% of them being males. Within 42 d of the first dosage, the incidence of myocarditis *per* 100000 vaccinated people was 2.13 (1.56-2.70) (mild = 1.62, intermediate = 0.47, and severe = 0.04). There was a higher incidence among male patients than female patients, with 4.12 (2.99-5.26) and 0.23 (0-0.49) *per* 100000 vaccinations, respectively (Table 1). Among all patients aged 16 years to 29 years, the incidence was 5.49 (3.59-7.39) *per* 100000 vaccinations. The incidence was reduced to 1.13 (0.66-1.60) *per* 100000 vaccinations among the patients who were 30 years of age or older. Male patients between the ages of 16 and 29 had the greatest incidence, with 10.69 (6.93-14.46) occurrences *per* 100000 immunizations. The most common clinical presentation was chest pain in 82% of the patients. Only 1 patient presented with hemodynamic instability. The electrocardiogram (ECG) showed 53% ST-segment elevation, 24% minor abnormalities, and a 21% normal pattern at presentation. All available data for cardiac troponin T (41 cases) showed a median peak of troponin T of 680 ng/L

Table 1 Incidence and clinical manifestations of myocarditis after coronavirus disease 2019 mRNA vaccination

Ref.	Type of vaccine	Study population	Incidence	Cardiac assessment methods	Main findings and clinical outcomes
Witberg <i>et al</i> [11], Israel	Pfizer-BioNTech	54/2558421 (21-63 yr)	2.13/100000	Clinical presentation, ECG, ECHO, MRI, Troponin T	Myocarditis = 10.69/100000 in male ages 16-29 yr, 25.92% had LV dysfunction, 76% = mild, 22% = intermediate, 1 case had cardiogenic shock, 1 case died of unknown cause, 0.51/100000 after 1 st dose and 2.15/100000 after 2 nd dose
Mevorach <i>et al</i> [12], Israel	Pfizer-BioNTech	136/9289765 (≥ 16 yr)	1.46/100000	Clinical presentation, ECHO, MRI, Troponin T, Endomyocardial biopsy	Myocarditis = 15.07/100000 in male ages 16-19 yr, 0.35/100000 after 1 st dose, 2.28/100000 after 2 nd dose, 94.85% = mild, 4.41% = intermediate, 1 case was fatal, endo- interstitial edema with neutrophils and mononuclear-cells infiltrates with no giant cells
Montgomery <i>et al</i> [13], United States	Pfizer-BioNTech/Moderna	23/2810000 (20-51 yr)	0.82/100000	Clinical presentation, ECG, ECHO, MRI, Troponin T	Myocarditis = 1.88/100000 after 1 st dose, 3.49/100000 after 2 nd dose, and 4.36/100000 in male after 2 nd dose
Perez <i>et al</i> [14], United States	Pfizer-BioNTech/Moderna/Johnson and Johnson	7/175472 (12-106 yr)	55.35/100000, Person-yr	Clinical presentation, ECG, ECHO, MRI, Troponin T	The overall incidence rate was 55.35 (22.25-114.00) <i>per</i> 100000 person-yr during the 2 wk after a dose of vaccine. The IRR for myocarditis following COVID-19 mRNA vaccination was increased for males at 6.69 (2.35-15.52), but it was not statistically significant for females at 1.41 (0.03-8.45)
Das <i>et al</i> [15], United States	Pfizer-BioNTech	25/7735071 (12-17 yr)	0.32/100000	Clinical presentation, ECG, ECHO, MRI, Troponin T, CRP	Myocarditis = 0.04/100000 after 1 st dose, 0.28/100000 after 2 nd dose, and 0.26/100000 in male after 2 nd dose
Li <i>et al</i> [16], United States	Pfizer-BioNTech/Moderna/Janssen	Age ≥ 12 yr	0.598/100000	VAERS	Pfizer-BioNTech had a higher incidence rate of 0.670/100000 than the rate of 0.498/100000 found for Moderna. The incidence rate following the 2 nd dose was twice that of the 1 st dose and was the highest in adolescents aged 12-17 yr, at 2.094/100000. The Janssen vaccine was not associated with myocarditis or pericarditis
Patone <i>et al</i> [17], United Kingdom	Pfizer-BioNTech/Moderna/AstraZeneca	1615/38615491 (Age ≥ 16 yr)	4.18/100000	NIMS	The IRR of myocarditis = 1.76, 1.45, 8.38 after 1 st dose of AstraZeneca, Pfizer-BioNTech, Moderna. IRR of myocarditis = 1.75, 23.10 after 2 nd dose of Pfizer-BioNTech, Moderna. There was an increase in the risk of myocarditis within 1 wk after 1 st dose of adenovirus and mRNA vaccines and a higher increased risk after 2 nd dose of both mRNA vaccines, especially in under 40 yr
Simone <i>et al</i> [18], United States	Pfizer-BioNTech/Moderna	15/2392924 (Age ≥ 18 yr)	0.63/100000	KPSC members with clinical presentation, ECG, ECHO, Troponin I	Myocarditis = 0.08/100000 after 1 st dose, 0.58/100000 after 2 nd dose over a 10-d period, all were men aged 20-32 yr. The IRR of myocarditis = 0.38 after 1 st dose and 2.7 after 2 nd dose
Nygaard <i>et al</i> [19], Denmark	Pfizer-BioNTech	15/261334 (12-17 yr)	5.74/100000	Clinical presentation, ECG, ECHO, MRI, Troponin	Myocarditis = 3.06/100000 after 1 st dose, 2.68/100000 after 2 nd dose mostly in male (M:F = 6:1)
Husby <i>et al</i> [20], Denmark	Pfizer-BioNTech/Moderna	269/4931775 (Age ≥ 12 yr)	5.45/100000	Danish Vaccination Register	HR of myocarditis/pericarditis = 1.34, 3.92 within 28 d from the vaccination of Pfizer-BioNTech, Moderna respectively. Myocarditis or pericarditis occurred at 1.4/100000 for Pfizer-BioNTech and 4.2/100000 for Moderna. Vaccination with Moderna vaccine was associated with an increased risk of myocarditis or pericarditis, especially in aged 12-39 yr
Diaz <i>et al</i> [21], United States	Pfizer-BioNTech/Moderna/Janssen	57/2000287 (26-70 yr)	2.85/100000	Clinical presentation, ECG,	Myocarditis = 1.0/100000 and pericarditis = 1.8/100000. Myocarditis and pericarditis

				ECHO, Troponin	were observed after the COVID-19 vaccination. Myocarditis developed rapidly in younger patients, mostly after the 2 nd dose. Pericarditis affected older patients later, after either the 1 st or 2 nd dose
Chouchana <i>et al</i> [22], WHO	Pfizer-BioNTech/Moderna	2277/716576 reports	NA	VigiBase	Over all myocarditis = 3.57/100000 with 12–17 yr = 3.69/100000, 18–29 yr = 1.97/100000, and ≥ 30 yr = 0.21/100000. Younger male aged 12–17 yr were more prone to report myocarditis or pericarditis with 22.3/100000. The median time to onset for myocarditis was 3 d after vaccine injection
Barda <i>et al</i> [23], Israel	Pfizer-BioNTech	21/938812	2.23/100000	Clinical presentation, ECG, ECHO, Troponin	Vaccination was most strongly associated with an elevated risk of myocarditis [risk ratio, 3.24 (1.55-12.44)]. Alternatively, SARS-CoV-2 infection was associated with a substantially increased risk of myocarditis [risk ratio, 18.28 (3.95-25.12)]. The BNT162b2-mRNA vaccine increased the incidence of a few adverse events over a 42-d follow-up period

ECG: Electrocardiography; ECHO: Echocardiography; HR: Hazard ratio; IRR: Incidence rate ratio; KPSC: Kaiser Permanente Southern California; M:F: Male to female; MRI: Magnetic resonance imaging; NA: Not available; NIMS: The English National Immunisation; ROR: Reporting odds ratio; VAERS: Vaccine Adverse Events Reporting System; VigiBase: World Health Organization (WHO) global safety database; SARS-CoV-2: Severe acute respiratory syndrome coronavirus 2.

(275-2075). One patient's cardiac biopsy revealed perivascular lymphocyte and eosinophil infiltration. On admission, ECG findings (48 cases) showed 71% normal LV function. Fourteen patients (29%) showed some degree of LV dysfunction. Seventeen percent presented with mild symptom, four percent had mild symptom, four percent had moderate symptom, two percent had moderate-to-severe symptom, and two percent had severe symptom. Fifteen patients underwent cardiac magnetic resonance imaging (MRI) and showed normal LV function (Table 2). They concluded that the highest incidence of myocarditis after BNT162b2 mRNA vaccination was among male patients aged 16-29 years. The majority of myocarditis cases were mild to moderate in severity.

Mevorach *et al* [12] retrospectively reviewed data regarding myocarditis cases. During the surveillance period, 9289765 Israeli residents were included. Of those, 5442696 individuals received the 1st dose and 5125635 received two BNT162b2 mRNA vaccines. They found that 136 cases were confirmed as diagnoses of myocarditis. In most cases, the clinical presentations in 129 cases were mild with a resolution of myocarditis. The overall incidence of myocarditis *per* 100000 vaccinated people was 1.46. A comparison of risks 21 d after the 1st and 2nd doses based on age and gender revealed a risk difference of 1.76 *per* 100000 people. Male recipients had a risk difference of 3.19, while female recipients had a risk difference of 0.39. The highest difference was observed among male patients aged 16 and 19, at 13.73 *per* 100000 people. These findings pointed out that the 1st wk after the 2nd dose of vaccination was the leading risk period.

Myocarditis symptoms usually appear within a few days of receiving the 2nd dose of the vaccine. After the 2nd dose of vaccine, they estimated that definite cases of myocarditis occurred at a rate of 1 in 26000 males and 1 in 218000 females in the general Israeli population. The majority of the patients had normal or mildly reduced ejection fraction (EF), but the EF in 4 patients was severely reduced. MRIs were performed on 48 people who had a positive result from a T2-based sequence or a T1-based sequence that indicated myocarditis. They concluded that the myocarditis incidence that occurred after 2 doses of the mRNA vaccine was very low, although the incidence was higher than in unvaccinated people. Myocarditis was mostly discovered in young male recipients after the second dose of the vaccine.

Montgomery *et al* [13] retrospectively studied a United States Military Health System case series that experienced myocarditis after COVID-19 vaccination (BNT162b2-mRNA and mRNA-1273 vaccines). The authors found that 23 male patients aged 20-51 years were evaluated for acute-onset chest pain following 2810000 mRNA COVID-19 vaccinations and confirmed acute myocarditis. The overall incidence was 0.82 *per* 100000 doses of vaccination. Myocarditis was reported at 1.88 *per* 100000 vaccinations after the 1st dose, at 3.49 *per* 100000 vaccinations after the 2nd dose, and at 4.36 *per* 100000 vaccinations in males after the 2nd dose. T-wave inversions, ST-segment elevations, and nonspecific ST changes were reported in 83% of patients as abnormal ECG findings. In 17% of the recipients, echocardiography (ECHO) demonstrated reduced LVEFs (40% to 50%). They concluded that the number of cases of myocarditis observed in the Military Health System exceeded some estimates of expected numbers, particularly when considering the subset of the population who received the 2nd dose of the mRNA vaccine. It's time to pay more attention to myocarditis as a potential side effect of the mRNA COVID-19

Table 2 Characteristic of acute myocarditis patients after coronavirus disease 2019 mRNA vaccination

Ref.	Type of vaccine	No. of myocarditis cases	Male/Female (%)	Median age in yr (IQR)	Myocarditis after 1 st dose (%)	Myocarditis after 2 nd dose (%)	Clinical severity F/I/M
Witberg <i>et al</i> [11], Israel	Pfizer-BioNTech	54	51/3 (94/6)	27 (21–35)	17 (31.48)	37 (68.52)	1/12/41
Mevorach <i>et al</i> [12], Israel	Pfizer-BioNTech	136	118/18 (87/13)	- (16–> 30)	19 (13.97)	117 (86.03)	1/6/129
Montgomery <i>et al</i> [13], United States	Pfizer-BioNTech/Moderna	23	23/0 (100/0)	25 (20–51)	3 (13.04)	20 (86.96)	0/7/16
Perez <i>et al</i> [14], United States	Pfizer-BioNTech/Moderna	7	6/1 (86/14)	44 (22–71)	1 (14.29)	6 (85.71)	0/6/1
Das <i>et al</i> [15], United States	Pfizer-BioNTech	25	22/3 (88/12)	15 (12–17)	3 (12.00)	22 (88.00)	0/22/3
Simone <i>et al</i> [18], United States	Pfizer-BioNTech/Moderna	15	15/0 (100/0)	25 (20–32)	2 (13.33)	13 (86.67)	0/15/0
Nygaard <i>et al</i> [19], Denmark	Pfizer-BioNTech	15	13/2 (87/12)	17 (13–17)	8 (53.33)	7 (46.67)	0/1/14
Diaz <i>et al</i> [21], United States	Pfizer-BioNTech/Moderna	20	15/5 (75/25)	36 (26–48)	4 (20.00)	16 (80.00)	2/17/1

F/I/M: Fulminant/intermediate/mild; IQR: Interquartile range.

vaccination.

Perez *et al*[14] used the Mayo Clinic COVID-19 Vaccine Registry to conduct a retrospective case series study to assess post-immunization myocarditis. They discovered that a total of 7 people were diagnosed with myocarditis after receiving at least one dose of a COVID-19 mRNA vaccine (BNT162b2-mRNA and mRNA-1273 vaccines). The COVID-19 registry contained 175472 individuals (aged 12 years to 106 years), of whom 718 (0.4%) were adolescents aged 12 years to 15 years. Myocarditis was found to be 55.35 *per* 100000 person-years in the two weeks following a dose of COVID-19 mRNA vaccination. The incidence rate ratio (IRR) of myocarditis after mRNA vaccinations in males was 6.69 (2.35–15.52) which was higher than the Rochester Epidemiology Project during the years 2016–2020. However, the myocarditis IRR in females was 1.41 (0.03–8.45) which was not statistically significant. The most common presenting symptoms were chest pain, dyspnea, and fatigue, with a baseline troponin T of 486.5 ng/L (222.5–965.0). Seventy one percent of the patients had ECG abnormalities, including ST-segment changes. On ECHO examination, 3 patients (60%) were noted to have a reduced LVEF. Cardiac MRI was performed in 6 patients (86%) and showed myocardial delayed enhancement. Pericardial involvement was seen in 3 (50%) patients. Myocarditis is a rare side effect of COVID-19 mRNA vaccines, according to the authors. It affects adult males at a significantly higher rate than the general population.

Das *et al*[15] performed a study of 25 cases aged between 12 and 18 years who developed myopericarditis following the mRNA vaccine in 7735017 children and adolescents. The incidence of myopericarditis after COVID-19 mRNA vaccination was 0.32 *per* 100000 people. Myopericarditis has occurred in 0.04 *per* 100000 people after the 1st dose, 0.28 *per* 100000 persons following the 2nd dose, and 0.26 *per* 100000 males following the 2nd dose. The most common presenting symptom was chest pain. Sixty percent and seventy-two percent of patients reported the development of symptoms within 2 and 3 d of getting the second dosage of the vaccine, respectively. All 25 patients had elevated plasma troponin concentrations. Abnormal ECG was found in 84% of the patients, including 60% of the elevation of ST-segment, 24% of the isolation of nonspecific ST-segment changes, 4% of the depression of ST-segment, and 4% of the depression of PR interval. An ECHO was performed in all patients and showed normal LV function in 92% of the individuals. Cardiac MRI was done on 16 of 25 patients (64%) and revealed late gadolinium enhancement in 94% of cases. Myocardial edema on T2 mapping was found in 37.5% of the patients, and a small pericardial effusion was found in 19% of the patients. They concluded that the complication of mRNA vaccine-related myopericarditis has been observed primarily in men. It has not been thoroughly investigated if hormonal or other variables have a role in the manifestation of this disease.

Li *et al*[16] employed the Vaccination Adverse Event Reporting System, a nationwide early warning system that monitors potential vaccine safety issues, as the major data source. The COVID-19 mRNA vaccines and viral vector vaccinations were the vaccines studied in this study. They found that the incidence rate of myocarditis or pericarditis following COVID-19 vaccination was 0.598 (0.573–0.624) *per* 100000 doses of vaccinations. The incidence rate was highest in adolescents aged 12–17 years, with an incidence rate of 2.09 (1.90–2.30) *per* 100000 vaccinations. It decreased with increasing age to 0.59

(0.56–0.62) *per* 100000 in adults aged 18–64, and 0.19 (0.16–0.22) *per* 100000 aged 65 years and over. The incidence rate was higher for different vaccine types in the mRNA vaccines, at 0.59 (0.57–0.62) *per* 100000, than for a viral vector vaccine, at 0.56 (0.44–0.70) *per* 100000 vaccinations. Among mRNA vaccines, BNT162b2-mRNA vaccines had a higher incidence rate of 0.67 (0.63–0.70) cases *per* 100000 than the rate of 0.49 (0.46–0.53) cases *per* 100000 of the mRNA-1273 vaccine. Moreover, the incidence rate after the 2nd dose was twice that of the 1st dose of mRNA vaccinations. Fifty percent of myocarditis or pericarditis cases were reported 2 to 7 d after vaccinations, with 58.67% of cases having chest pain symptoms. They also found that reporting odds ratios (RORs) of the mRNA-1273 vaccine were 2.91 (2.21–3.83) compared with the RORs of the BNT162b2-mRNA vaccine at 5.37 (4.10–7.04). They concluded that the BNT162b2-mRNA vaccine was associated with significant risks of myocarditis or pericarditis in adolescents aged 12 to 17, with RORs ranging from 8.19 (4.37–15.36). A viral vector vaccine may be an alternative for consideration for individuals with myocardial injuries after mRNA vaccination.

Patone *et al*[17] conducted the study to find out the incidence of myocarditis or pericarditis after COVID-19 vaccinations in the United Kingdom using the English National Immunisation Database of COVID-19 vaccinations. During that period, 38615491 individuals received one dose of a viral vector vaccine ChAdOx1 ($n = 20615911$), an mRNA vaccine BNT162b2 ($n = 16993389$), or an mRNA vaccine 1273 ($n = 1006191$). Results showed an increased myocarditis risk at 1–7 d after the 1st dose of ChAdOx1-viral vector vaccine as an IRR of 1.76 (1.29–2.42), of BNT162b2-mRNA vaccine as an IRR of 1.45 (0.97–2.12), and of mRNA-1273 vaccine as an IRR of 8.38 (3.53–19.91). For the 2nd dose of the BNT162b2-mRNA vaccine, the IRR was 1.75 (1.13–2.70), the IRR of the mRNA-1273 vaccine was 23.10 (6.46–82.56). Over the 1–28 d post-vaccination, they observed an association with the 1st dose of ChAdOx1-viral vector vaccine, whose IRR was 1.29 (1.05–1.58), with BNT162b2-mRNA vaccine, whose IRR was 1.31 (1.03–1.66) and with mRNA-1273 vaccine, whose IRR was 2.97 (1.34–6.58). After a 2nd dose, the mRNA vaccine 1273 had higher risk [IRR = 9.84 (2.69–36.03)] compared with the BNT162b2-mRNA vaccine [IRR = 1.30 (0.98–1.72)]. They observed that severe acute respiratory syndrome coronavirus 2 (SARS-CoV-2) immunization in adults was linked with a low myocarditis risk after 1 wk of getting the 1st immunization of a viral vector vaccine and a mRNA vaccine, as well as after receiving the 2nd dose of both mRNA vaccines. COVID-19, on the other hand, was linked to an increased risk of hospitalization or mortality from myocarditis, pericarditis, and cardiac arrhythmia.

Simone *et al*[18] performed a study using Kaiser Permanente Southern California (KPSC) as a case study. The KPSC members' database (2392924) was used to evaluate acute myocarditis incidence and clinical outcomes among adults following mRNA vaccinations. In the vaccinated group, the authors discovered 15 cases of confirmed myocarditis (2 after the 1st dose and 13 after the 2nd dose). Over a 10-d observation period, the observed incidence after the 1st dosage was 0.08 cases *per* 100000 and 0.58 cases *per* 100000 after the 2nd dose. The IRR for myocarditis was 0.38 (0.05–1.40) after the 1st dose and 2.7 (1.4–4.8) after the 2nd dose. The most common clinical manifestation was chest pain (93%), which occurred between 1 and 5 d after vaccination. They determined that acute myocarditis following COVID-19 immunization was uncommon, with a prevalence of 5.8 occurrences in 1000000 people following the 2nd immunization (1 occurrence in 172414 fully immunized people). They proposed that the higher risk of myocarditis in adolescence males needs more research.

Nygaard *et al*[19] performed a prospective population-based cohort study to evaluate the incidence of myopericarditis after COVID-19 vaccination in Danish adolescents. They discovered that among 133477 males and 127857 females aged 12–17 years who got the first dose of the BNT162b2-mRNA vaccination, the incidence of myopericarditis was 97 and 16, respectively, *per* 1000000, corresponding to 1 in 10000 males and 1 in 63000 females. In contrast, 16900 males and 16044 females aged 12–17 years old infected with SARS-CoV-2 showed multisystem inflammatory syndrome in children, including myocarditis at an incidence of 1 in 2800 men and 1 in 5300 women, which was substantially more than the prevalence of myopericarditis following the immunization of the COVID-19 vaccine in both men and women. They determined that the frequency of myopericarditis in male adolescents following BNT162b2-mRNA immunization is greater than previously reported, and that more severe cases are more common.

Husby *et al*[20] conducted a study using the Danish Vaccination Register to evaluate the incidence of myocarditis or myopericarditis after BNT162b2-mRNA and mRNA-1273 vaccinations in Denmark. Among the cohort participants, 3482295 were vaccinated with BNT162b2-mRNA vaccines, whereas 498814 were immunized with mRNA-1273. Individuals who received the BNT162b2-mRNA vaccine exhibited a non-substantially higher risk of myocarditis in the 28-d following immunization compared to unvaccinated follow-up [hazard ratio (HR) = 1.34 (0.90–2.00)]. Individuals aged 12–39 years had a non-significantly higher rate in the 28-d following vaccination compared non-immunization people [HR = 1.48 (0.74–2.98)]. Individuals vaccinated with mRNA-1273, on the other hand, exhibited a substantially higher risk of myocarditis or myopericarditis compared to unvaccinated follow-up [HR = 3.92 (2.30–6.68)]. Furthermore, people aged 12–39 years had substantially higher rates of myocarditis or myopericarditis when compared to unvaccinated controls [HR = 5.24 (2.47–11.12)]. Myocarditis occurred at a rate of 1.7 (1.3–2.2) *per* 100000 vaccinated people. Within 28 d, the incidence rate of myocarditis following BNT162b2-mRNA vaccination or mRNA-1273 immunization was 1.4 (1.0–1.8) and 4.2 (2.6–6.4), respectively. Within 28 d of immunization, the equivalent rates of myocarditis from BNT162b2 vaccination was 1.6 (1.0–2.6) *per* 100000 people compared with mRNA-1273 vaccination was

5.7 (3.3-9.3) *per* 100000 people. The authors found that mRNA-1273 immunization was linked with a higher risk of myocarditis or myopericarditis compared to uninfected people, whereas BNT162b2-mRNA vaccination was related to a higher rate of myocarditis or myopericarditis among females. Furthermore, clinical outcomes following myocarditis or myopericarditis episodes were mostly modest, lending credence to the general safety of COVID-19 mRNA vaccinations.

Diaz *et al*[21] conducted a retrospective study to evaluate the incidence of myocarditis and pericarditis after COVID-19 vaccinations among 2000287 individuals who received at least one COVID-19 vaccination (52.6% received the BNT162b2-mRNA vaccine, 44.1% were given the mRNA-1273 vaccine, while 3.1% were given the Ad26.COV2.S vaccine). They found that 20 individuals had vaccine-related myocarditis [1.0 (0.61-1.54)] *per* 100000 vaccinations, and 37 individuals had pericarditis [1.8 (1.30-2.55)] *per* 100000 vaccinations, which occurred 3.5 d after being vaccinated. They concluded that mRNA vaccination was linked to myocarditis, particularly in adolescence males, within 3 d following the 2nd dose of immunization. Additionally, pericarditis may be more common than myocarditis among older patients.

Chouchana *et al*[22] conducted an observational retrospective analysis on inflammatory cardiac events that were reported regarding mRNA immunizations in the global safety database of the World Health Organization using a case-non-case methodology (VigiBase). Among the 26258646 reports in the VigiBase, 716576 were associated with the mRNA COVID-19 vaccination as a suspected medication, with 2277 cases of inflammatory heart responses identified as 1241 (54.5%) myocarditis, 851 (37.3%) pericarditis, and 167 (7.3%) myopericarditis. The majority of myocarditis cases have been observed in male patients aged between 12 and 29. Overall, the median duration from the beginning of myocarditis following immunization was 3 (2-14) d. When compared to myocarditis, a median onset of pericarditis was delayed to be 8 (3-21) d. Most of the myocarditis (81.8%) and pericarditis (57.8%) reported cases that required hospitalization, and 21.5% of myocarditis and 20.5% of pericarditis were life threatening. The overall incidence rate of myocarditis or pericarditis was 0.61 (0.57-0.65) *per* 100000 fully vaccinated individuals. In 2 doses of immunization, they found a significant increase in incidence rates in 12-17-year-old patients [3.69 (3.25-4.18) *per* 100000 people] and 18-29-year-old patients [1.97 (1.80-2.16) *per* 100000 people], while patients older than 30 years were 0.21 (0.19-0.24) *per* 100000 patients. Male patients had an elevated chance of reporting myocarditis with RORs = 9.4 (8.3-10.6) and diagnosed pericarditis with RORs = 3.7 (3.2-4.2). Age category analysis revealed a significant decrease in myocarditis reporting after mRNA immunizations in 12- to 17-year-olds [RORs = 22.3 (19.2-25.9)] and 18-to-29-year-olds [RORs = 6.6 (5.9-7.5)] individuals when compared to individuals older than 30 years. Across all age groups, this increased reporting was more significant in male patients than in female patients. While there was a considerable disproportionate reporting of myocarditis in teens and young adults, particularly in male patients, and it was an uncommon event, they discovered that it did not appear to compromise the vaccines' favorable benefit-risk balance.

Barda *et al*[23] evaluated the safety of the BNT162b2-mRNA COVID-19 vaccine using the largest health care organization in Israel. They discovered that the vaccinated and control groups each had an average of 884828 people. Vaccination was the strongest predictor of an increased risk of myocarditis [risk ratio, 3.24 (1.55-12.44)]. By contrast, infection with SARS-CoV-2 was linked to a significantly higher myocarditis rate [risk ratio, 18.28 (3.95-25.12)]. They concluded that the BNT162b2-mRNA vaccine increased the occurrence of a few side effects over a 42-d period of follow-up. Whereas the majority of these incidents were minor, myocarditis has the potential to be life-threatening. According to the findings, SARS-CoV-2 infection is a significant risk factor for myocarditis, as well as a number of other adverse outcomes.

Table 2 summarizes the characteristics of acute myocarditis patients, such as sex, age, occurrence after the 1st or 2nd dose of mRNA COVID-19 vaccination, and clinical severity. Many investigators' data indicated the same result: Acute myocarditis was more prevalent in younger males, and over 90% occurred after the 2nd dose of immunization. Furthermore, practically all patients had mild to moderate clinical presentation and prognosis. Figure 1 shows the number of acute myocarditis cases after the 1st and 2nd doses of the Pfizer-BioNTech mRNA COVID-19 vaccine. According to these data, the majority of the cases occurred shortly after the 2nd dose of immunization, generally within 5 d. Close observation and monitoring of vaccination recipients are critical during this period.

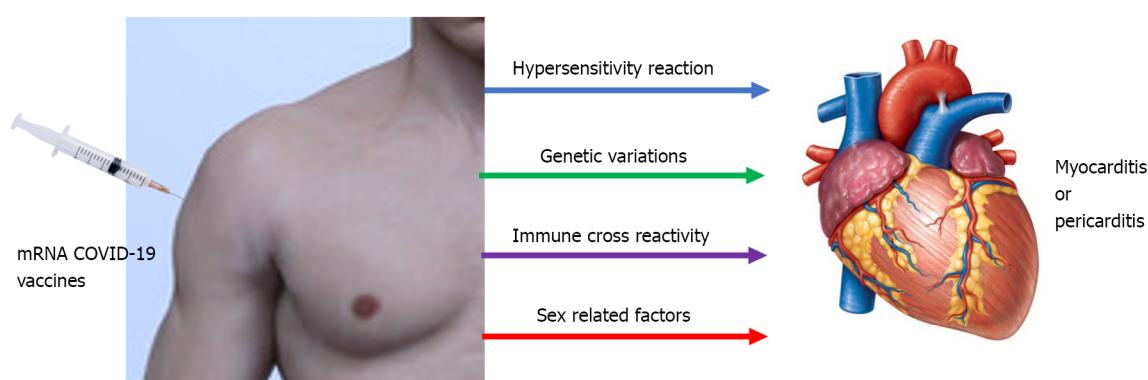
Table 3 shows the clinical presentation of the patients with acute myocarditis after mRNA COVID-19 vaccinations, which usually included chest pain, myalgia, fatigue, and fever. The common ECG abnormalities were ST-elevation, non-specific ST/T changes, PR depression, T-wave inversion, and ventricular fibrillation. ECHO showed the reduction of LVEF. Laboratory findings demonstrated the elevation of cardiac troponin and C-reactive protein. The imaging studies of acute myocarditis patients after mRNA COVID-19 vaccination showed myocardial inflammation, myocardial edema, and delayed iodine enhancement.

Despite the fact that the majority of the findings of various studies demonstrated the occurrence of acute myocarditis following mRNA COVID-19 immunization, the incidence was quite low. Furthermore, there were significant disparities across these trials in terms of ethnicity, age, underlying disorders, inherent immunity to the SARS-CoV-2 virus, and other genetic variables. More research should be conducted to understand this problem.

Table 3 Clinical presentation of the patients with acute myocarditis after coronavirus disease 2019 mRNA vaccination

Clinical presentation of acute myocarditis	
1	Chest pain, Myalgia, Fatigue, Fever
2	Abnormal ECG: ST-elevation, Non-specific ST/T changes, PR depression, T-wave inversion, Ventricular fibrillation
3	Elevation of cardiac troponin
4	Elevation of CRP
5	Abnormal ECHO: LVEF reduction
6	Abnormal cardiac MRI: Myocardial inflammation, Myocardial edema
7	Abnormal cardiac spectral CT: Delayed iodine enhancement

CRP: C-reactive protein; CT: Computerized tomography; ECG: Electrocardiogram; ECHO: Echocardiogram; LVEF: Left ventricular ejection fraction; MRI: Magnetic resonance imaging.



DOI: 10.4330/wjc.v14.i6.343 Copyright ©The Author(s) 2022.

Figure 1 Timelines of acute myocarditis occurrence after Pfizer-BioNTech and Moderna mRNA coronavirus disease 2019 vaccination. COVID-19: Coronavirus disease 2019.

HISTOPATHOLOGICAL FINDINGS OF MYOCARDITIS AFTER MRNA COVID-19 VACCINATION

Ameratunga *et al*[24] reported a 57-year-old woman who died of fulminant necrotizing myocarditis after receiving the first dose of the BNT162b2 mRNA vaccine. The clinical manifestations were lethargy, fatigue, breathlessness, stiff neck, and upper limb pain. After that, she complained of back pain, a sore throat, and hematuria without palpitation or chest pain. The autopsy findings showed that the heart was normal without pericardial effusion and intra-cardiac thrombosis. There was a large thymoma mass (710 g) in the left pleural cavity. The histopathology demonstrated fulminant necrotizing eosinophilic myocarditis. Multifocal aggregates of lymphoid cells, histiocytes, and many eosinophils with isolated myocyte necrosis were seen in the free walls of both ventricles, the interventricular septum, and throughout the conduction system (sinoatrial and atrioventricular nodes) (Table 4). They concluded that the danger of myocarditis and other deadly consequences of COVID-19 infection outweighed the risk of these uncommon vaccine-related side effects. The advantages of immunization substantially outweigh the hazards of COVID-19 infection. Choi *et al*[25] published the autopsy results of a 22-year-old man who had chest discomfort 5 d after receiving the 1st dose of the BNT162b2-mRNA vaccination and died 7 h later. He developed ventricular fibrillation on ECG before cardiopulmonary resuscitation in the emergency department. The autopsy findings showed the heart weighed 470 g with multiple petechial hemorrhages on its surface.

There was no fibrin buildup or exudate in the pericardium. The coronary arteries were patent, and the cardiac valves were in good condition. Within the heart, histology revealed a diffuse inflammatory infiltrate with neutrophils and histiocyte predominance. Inflammatory infiltrates were more common in the atria and around the sinoatrial and atrioventricular nodes, but there were few or no inflammatory cells in the ventricular area. They concluded that the major cause of mortality was myocarditis, which was linked to the BNT162b2-mRNA vaccination. Schneider *et al*[26] conducted an autopsy of 18 deceased people after COVID-19 vaccinations and found that only 1 case was related to the BNT162b2-mRNA vaccine. The autopsy findings showed severe coronary sclerosis, massive cardiac hypertrophy,

Table 4 Gross and histopathological findings of the heart after coronavirus disease 2019 mRNA vaccination

Ref.	No. of cases (age, sex)/vaccine	Gross findings	Histopathological findings
Ameratunga <i>et al</i> [24]	1 (57, F)/Pfizer-BioNTech	The heart was normal without pericardial effusion and intra-cardiac thrombosis. There was a large thymoma mass (710 g) in the left pleural cavity	The heart sections showed fulminant necrotizing eosinophilic myocarditis. There were multifocal aggregates of lymphoid cells, histiocytes, and abundant eosinophils with focal myocyte necrosis in the free walls of both ventricles, interventricular septum, and around the conduction system (sino-atrial and atrioventricular nodes)
Choi <i>et al</i> [25]	1 (22, M)/Pfizer-BioNTech	The heart weighed 470 g with multiple petechial hemorrhages on its surface. The pericardium was smooth with no fibrin deposition or exudate. The coronary arteries were patent, and the heart valves were unremarkable	The myocardial sections showed a diffuse inflammatory infiltration with neutrophils and histiocytes predominance. The inflammatory infiltrates dominant in the atria and around the sinoatrial and atrioventricular nodes with no inflammatory cells in the ventricular muscles
Schneider <i>et al</i> [26]	1 (65, M)/Pfizer-BioNTech	The heart showed severe coronary sclerosis, massive cardiac hypertrophy, myocardial infarction scars	The myocardial sections showed myocarditis with lymphocytic and plasmacytoid infiltration of the perivascular space and the myocardium

F: Female; M: Male.

and myocardial infarction scars. The histopathology showed myocarditis with lymphocytic and plasmacytoid infiltration of the perivascular space and the myocardium.

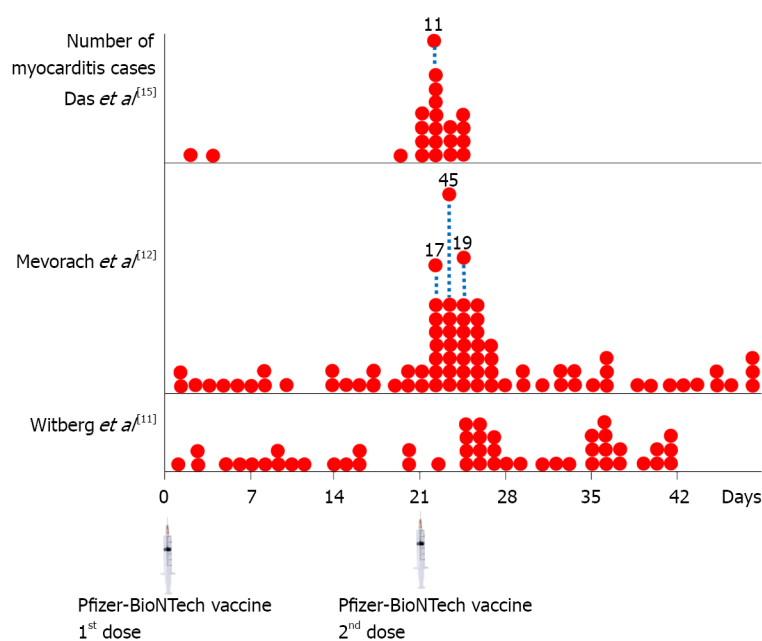
PATHOPHYSIOLOGY OF CARDIAC DYSFUNCTION AFTER MRNA COVID-19 VACCINATIONS

The mRNA COVID-19 vaccines are made up of the mRNA which was modified with nucleosides that codes for the spike protein of SARS-CoV-2 and is enclosed in nanoparticles of lipid that do not have live virus particles or DNA of virus. When the spike protein of a virus is created on the cell surface during the entry of mRNA-vaccine, it activates an adaptive immune response that detects and kills viruses expressing the spike protein. SARS-CoV-2 attachment to the host cell is blocked by vaccine-induced spike-protein IgG antibodies, which bind to the angiotensin-converting enzyme 2 receptor and destroy the virus[27].

Myocarditis caused by enterovirus or human herpesvirus infection is often severe in young adolescents and adult males. Genetic polymorphisms in genes producing HLA factors and, in a minority of individuals, genetic variants in genes encoding cytoskeletal, desmosomal, or sarcomeric proteins are related to this kind of myocarditis, which raises the chance of developing acute myocarditis following viral infection[28]. Myocarditis and pericarditis have previously been documented following immunization, particularly with smallpox and influenza vaccinations with shallow incidence rates[5]. There are sex-specific hormone alterations in COVID-19 mRNA-vaccination-related myocarditis and non-COVID-19 viral myocarditis[29].

Although potential processes are unclear, various ideas may be possible. mRNA immune reactivity, cross reactivity with cardiac proteins, SARS-CoV-2 spike protein antibodies, and hormonal alterations are the four main mechanisms by which COVID-19 mRNA vaccines might induce hyper-immunity. Immune-genetic background, age, and sex can all impact these processes. The immune system may detect the vaccine's mRNA as an antigen, triggering immunological pathways and pro-inflammatory cascades in the heart. Despite the fact that nucleotide changes to mRNA diminish its innate immunogenicity, the mRNA immune response could induce an abnormal innate and acquired immunity, explaining why mRNA vaccinations induce a stronger immune response than other COVID-19 immunization approaches[30]. Another proposed mechanism is molecular mimicry between the SARS-CoV-2 spike protein and cardiac self-antigen presentation. Antibodies against SARS-CoV-2 spike proteins may cross-react with myocardial-myosin heavy chain. These autoantibodies might be inadvertent bystanders that cause myocardial inflammation and damage (Figure 2).

Moreover, they could represent a specific immune-genetic background that predisposes to hyper-immunity and myocarditis in response to any stimulus[31,32]. Furthermore, while COVID-19 mRNA-vaccination-related myocarditis is more common in men, changes in hormone signaling may play a role in its etiology. Testosterone has the capacity to reduce anti-inflammatory immune cells while increasing the aggressiveness of T helper cell-type immune responses. On the other hand, estrogen suppresses pro-inflammatory T cells, leading to a reduction in cell-mediated immune response. As a result, testosterone may still promote an abnormal acquired and innate immune response, which may explain why mRNA immunizations produce a larger immunological response than other methods of COVID-19



DOI: 10.4330/wjc.v14.i6.343 Copyright ©The Author(s) 2022.

Figure 2 Coronavirus disease 2019 mRNA vaccine associated with myocarditis.

immunization in males than females[33-36].

CONCLUSION

Post-mRNA vaccination myocarditis is most common in young boys under 21 years old. The majority of instances appear within a few days of receiving the 2nd immunization dose. The most common symptom is chest pain, followed by fever or myalgia. The majority of patients have an abnormal ECG. Elevated cardiac troponin and inflammatory markers are mainly laboratory abnormalities. On cardiac MRI, most individuals have evidence of myocardial edema, or inflammation of the cardiac muscles. Possible causes of myocarditis or pericarditis following mRNA COVID-19 vaccines include antibodies to SARS-CoV-2 spike proteins, immune response to mRNA, cross reaction with cardiac proteins, and alteration in hormones. A more rigorous investigation was required to resolve this issue. Despite a few incidences of self-limited myocarditis, the risk-benefit evaluation for COVID-19 vaccination shows a positive balance for all age and gender categories; hence, COVID-19 vaccination is now recommended for all people aged 12 and above.

FOOTNOTES

Author contributions: Leowattana W wrote the paper; Leowattana T collected the data.

Conflict-of-interest statement: All the authors report no relevant conflicts of interest for this article.

Open-Access: This article is an open-access article that was selected by an in-house editor and fully peer-reviewed by external reviewers. It is distributed in accordance with the Creative Commons Attribution NonCommercial (CC BY-NC 4.0) license, which permits others to distribute, remix, adapt, build upon this work non-commercially, and license their derivative works on different terms, provided the original work is properly cited and the use is non-commercial. See: <https://creativecommons.org/licenses/by-nc/4.0/>

Country/Territory of origin: Thailand

ORCID number: Wattana Leowattana 0000-0003-4257-2480; Tawitthep Leowattana 0000-0003-2316-3585.

S-Editor: Fan JR

L-Editor: A

P-Editor: Fan JR

REFERENCES

- 1 **Caforio AL**, Pankuweit S, Arbustini E, Basso C, Gimeno-Blanes J, Felix SB, Fu M, Heliö T, Heymans S, Jahns R, Klingel K, Linhart A, Maisch B, McKenna W, Mogensen J, Pinto YM, Ristic A, Schultheiss HP, Seggewiss H, Tavazzi L, Thiene G, Yilmaz A, Charron P, Elliott PM; European Society of Cardiology Working Group on Myocardial and Pericardial Diseases. Current state of knowledge on aetiology, diagnosis, management, and therapy of myocarditis: A position statement of the European Society of Cardiology Working Group on Myocardial and Pericardial Diseases. *Eur Heart J* 2013; **34**: 2636-2648, 2648a [PMID: [23824828](#) DOI: [10.1093/eurheartj/ehd210](#)]
- 2 **Sagar S**, Liu PP, Cooper LT Jr. Myocarditis. *Lancet* 2012; **379**: 738-747 [PMID: [22185868](#) DOI: [10.1016/S0140-6736\(11\)60648-X](#)]
- 3 **Lyng TH**, Nielsen TS, Gregers Winkel B, Tfelt-Hansen J, Banner J. Sudden cardiac death caused by myocarditis in persons aged 1-49 years: a nationwide study of 14 294 deaths in Denmark. *Forensic Sci Res* 2019; **4**: 247-256 [PMID: [31489390](#) DOI: [10.1080/20961790.2019.1595352](#)]
- 4 **Maron BJ**, Haas TS, Ahluwalia A, Murphy CJ, Garberich RF. Demographics and Epidemiology of Sudden Deaths in Young Competitive Athletes: From the United States National Registry. *Am J Med* 2016; **129**: 1170-1177 [PMID: [27039955](#) DOI: [10.1016/j.amjmed.2016.02.031](#)]
- 5 **Su JR**, McNeil MM, Welsh KJ, Marquez PL, Ng C, Yan M, Cano MV. Myopericarditis after vaccination, Vaccine Adverse Event Reporting System (VAERS), 1990-2018. *Vaccine* 2021; **39**: 839-845 [PMID: [33422381](#) DOI: [10.1016/j.vaccine.2020.12.046](#)]
- 6 **Morgan J**, Roper MH, Sperling L, Schieber RA, Heffelfinger JD, Casey CG, Miller JW, Santibanez S, Herwaldt B, Hightower P, Moro PL, Hibbs BF, Levine NH, Chapman LE, Iskander J, Lane JM, Wharton M, Mootrey GT, Swerdlow DL. Myocarditis, pericarditis, and dilated cardiomyopathy after smallpox vaccination among civilians in the United States, January-October 2003. *Clin Infect Dis* 2008; **46** Suppl 3: S242-S250 [PMID: [18284365](#) DOI: [10.1086/524747](#)]
- 7 **Kuntz J**, Crane B, Weinmann S, Naleway AL; Vaccine Safety Datalink Investigator Team. Myocarditis and pericarditis are rare following live viral vaccinations in adults. *Vaccine* 2018; **36**: 1524-1527 [PMID: [29456017](#) DOI: [10.1016/j.vaccine.2018.02.030](#)]
- 8 **Gargano JW**, Wallace M, Hadler SC, Langley G, Su JR, Oster ME, Broder KR, Gee J, Weintraub E, Shimabukuro T, Scobie HM, Moulia D, Markowitz LE, Wharton M, McNally VV, Romero JR, Talbot HK, Lee GM, Daley MF, Oliver SE. Use of mRNA COVID-19 Vaccine After Reports of Myocarditis Among Vaccine Recipients: Update from the Advisory Committee on Immunization Practices - United States, June 2021. *MMWR Morb Mortal Wkly Rep* 2021; **70**: 977-982 [PMID: [34237049](#) DOI: [10.15585/mmwr.mm7027e2](#)]
- 9 **Oster M**. mRNA COVID-19 Vaccine-Associated Myocarditis. [cited 10 January 2022]. Available from: <https://www.fda.gov/media/153514/download>
- 10 **EMA**. Comirnaty and Spikevax: possible link to very rare cases of myocarditis and pericarditis. [cited 10 January 2022]. Available from: <https://www.ema.europa.eu/en/news/comirnaty-spikevax-possible-link-very-rare-cases-myocarditis-pericarditis>
- 11 **Witberg G**, Barda N, Hoss S, Richter I, Wiessman M, Aviv Y, Grinberg T, Auster O, Dagan N, Balicer RD, Kornowski R. Myocarditis after Covid-19 Vaccination in a Large Health Care Organization. *N Engl J Med* 2021; **385**: 2132-2139 [PMID: [34614329](#) DOI: [10.1056/NEJMoa2110737](#)]
- 12 **Mevorach D**, Anis E, Cedar N, Bromberg M, Haas EJ, Nadir E, Olsha-Castell S, Arad D, Hasin T, Levi N, Asleh R, Amir O, Meir K, Cohen D, Dichtiar R, Novick D, Hershkovitz Y, Dagan R, Leitersdorf I, Ben-Ami R, Miskin I, Saliba W, Muhsen K, Levi Y, Green MS, Keinan-Boker L, Alroy-Preis S. Myocarditis after BNT162b2 mRNA Vaccine against Covid-19 in Israel. *N Engl J Med* 2021; **385**: 2140-2149 [PMID: [34614328](#) DOI: [10.1056/NEJMoa2109730](#)]
- 13 **Montgomery J**, Ryan M, Engler R, Hoffman D, McClenathan B, Collins L, Loran D, Hrnecir D, Herring K, Platzer M, Adams N, Sanou A, Cooper LT Jr. Myocarditis Following Immunization With mRNA COVID-19 Vaccines in Members of the US Military. *JAMA Cardiol* 2021; **6**: 1202-1206 [PMID: [34185045](#) DOI: [10.1001/jamacardio.2021.2833](#)]
- 14 **Perez Y**, Levy ER, Joshi AY, Virk A, Rodriguez-Porcel M, Johnson M, Roellinger D, Vanichkachorn G, Huskins WC, Swift MD. Myocarditis Following COVID-19 mRNA Vaccine: A Case Series and Incidence Rate Determination. *Clin Infect Dis* 2021 [PMID: [34734240](#) DOI: [10.1093/cid/ciab926](#)]
- 15 **Das BB**, Kohli U, Ramachandran P, Nguyen HH, Greil G, Hussain T, Tandon A, Kane C, Avula S, Duru C, Hede S, Sharma K, Chowdhury D, Patel S, Mercer C, Chaudhuri NR, Patel B, Ang JY, Asmar B, Sanchez J, Khan D. Myopericarditis after messenger RNA Coronavirus Disease 2019 Vaccination in Adolescents 12 to 18 Years of Age. *J Pediatr* 2021; **238**: 26-32.e1 [PMID: [34339728](#) DOI: [10.1016/j.jpeds.2021.07.044](#)]
- 16 **Li M**, Yuan J, Lv G, Brown J, Jiang X, Lu ZK. Myocarditis and Pericarditis following COVID-19 Vaccination: Inequalities in Age and Vaccine Types. *J Pers Med* 2021; **11** [PMID: [34834458](#) DOI: [10.3390/jpm11111106](#)]
- 17 **Patone M**, Mei XW, Handunnetthi L, Dixon S, Zaccardi F, Shankar-Hari M, Watkinson P, Khunti K, Harnden A, Coupland CAC, Channon KM, Mills NL, Sheikh A, Hippisley-Cox J. Risks of myocarditis, pericarditis, and cardiac arrhythmias associated with COVID-19 vaccination or SARS-CoV-2 infection. *Nat Med* 2022; **28**: 410-422 [PMID: [34907393](#) DOI: [10.1038/s41591-021-01630-0](#)]
- 18 **Simone A**, Herald J, Chen A, Gulati N, Shen AY, Lewin B, Lee MS. Acute Myocarditis Following COVID-19 mRNA Vaccination in Adults Aged 18 Years or Older. *JAMA Intern Med* 2021; **181**: 1668-1670 [PMID: [34605853](#) DOI: [10.1001/jamainternmed.2021.5511](#)]
- 19 **Nygaard U**, Holm M, Bohnstedt C, Chai Q, Schmidt LS, Hartling UB, Petersen JJH, Thaarup J, Bjerre J, Vejstrup NG, Juul K, Stensballe LG. Population-based Incidence of Myopericarditis After COVID-19 Vaccination in Danish Adolescents. *Pediatr Infect Dis J* 2022; **41**: e25-e28 [PMID: [34889875](#) DOI: [10.1097/INF.0000000000003389](#)]
- 20 **Husby A**, Hansen JV, Fosbøl E, Thieson EM, Madsen M, Thomsen RW, Sørensen HT, Andersen M, Wohlfahrt J, Gislason G, Torp-Pedersen C, Køber L, Hviid A. SARS-CoV-2 vaccination and myocarditis or myopericarditis: population based cohort study. *BMJ* 2021; **375**: e068665 [PMID: [34916207](#) DOI: [10.1136/bmj-2021-068665](#)]
- 21 **Diaz GA**, Parsons GT, Gering SK, Meier AR, Hutchinson IV, Robicsek A. Myocarditis and Pericarditis After Vaccination

- for COVID-19. *JAMA* 2021; **326**: 1210-1212 [PMID: [34347001](#) DOI: [10.1001/jama.2021.13443](#)]
- 22 **Chouchana L**, Blet A, Al-Khalaf M, Kafil TS, Nair G, Robblee J, Drici MD, Valnet-Rabier MB, Micallef J, Salvo F, Treluyer JM, Liu PP. Features of Inflammatory Heart Reactions Following mRNA COVID-19 Vaccination at a Global Level. *Clin Pharmacol Ther* 2022; **111**: 605-613 [PMID: [34860360](#) DOI: [10.1002/cpt.2499](#)]
- 23 **Barda N**, Dagan N, Ben-Shlomo Y, Kepten E, Waxman J, Ohana R, Hernán MA, Lipsitch M, Kohane I, Netzer D, Reis BY, Balicer RD. Safety of the BNT162b2 mRNA Covid-19 Vaccine in a Nationwide Setting. *N Engl J Med* 2021; **385**: 1078-1090 [PMID: [34432976](#) DOI: [10.1056/NEJMoa2110475](#)]
- 24 **Ameratunga R**, Woon ST, Sheppard MN, Garland J, Ondruschka B, Wong CX, Stewart RAH, Tatley M, Stables SR, Tse RD. First Identified Case of Fatal Fulminant Necrotizing Eosinophilic Myocarditis Following the Initial Dose of the Pfizer-BioNTech mRNA COVID-19 Vaccine (BNT162b2, Comirnaty): an Extremely Rare Idiosyncratic Hypersensitivity Reaction. *J Clin Immunol* 2022; **42**: 441-447 [PMID: [34978002](#) DOI: [10.1007/s10875-021-01187-0](#)]
- 25 **Choi S**, Lee S, Seo JW, Kim MJ, Jeon YH, Park JH, Lee JK, Yeo NS. Myocarditis-induced Sudden Death after BNT162b2 mRNA COVID-19 Vaccination in Korea: Case Report Focusing on Histopathological Findings. *J Korean Med Sci* 2021; **36**: e286 [PMID: [34664804](#) DOI: [10.3346/jkms.2021.36.e286](#)]
- 26 **Schneider J**, Sottmann L, Greinacher A, Hagen M, Kasper HU, Kuhn C, Schlepper S, Schmidt S, Schulz R, Thiele T, Thomas C, Schmeling A. Postmortem investigation of fatalities following vaccination with COVID-19 vaccines. *Int J Legal Med* 2021; **135**: 2335-2345 [PMID: [34591186](#) DOI: [10.1007/s00414-021-02706-9](#)]
- 27 **Vitiello A**, Ferrara F. Brief review of the mRNA vaccines COVID-19. *Inflammopharmacology* 2021; **29**: 645-649 [PMID: [33932192](#) DOI: [10.1007/s10787-021-00811-0](#)]
- 28 **Heymans S**, Eriksson U, Lehtonen J, Cooper LT Jr. The Quest for New Approaches in Myocarditis and Inflammatory Cardiomyopathy. *J Am Coll Cardiol* 2016; **68**: 2348-2364 [PMID: [27884253](#) DOI: [10.1016/j.jacc.2016.09.937](#)]
- 29 **Vojdani A**, Kharratian D. Potential antigenic cross-reactivity between SARS-CoV-2 and human tissue with a possible link to an increase in autoimmune diseases. *Clin Immunol* 2020; **217**: 108480 [PMID: [32461193](#) DOI: [10.1016/j.clim.2020.108480](#)]
- 30 **Heymans S**, Cooper LT. Myocarditis after COVID-19 mRNA vaccination: clinical observations and potential mechanisms. *Nat Rev Cardiol* 2022; **19**: 75-77 [PMID: [34887571](#) DOI: [10.1038/s41569-021-00662-w](#)]
- 31 **Siripanthong B**, Nazarian S, Muser D, Deo R, Santangeli P, Khanji MY, Cooper LT Jr, Chahal CAA. Recognizing COVID-19-related myocarditis: The possible pathophysiology and proposed guideline for diagnosis and management. *Heart Rhythm* 2020; **17**: 1463-1471 [PMID: [32387246](#) DOI: [10.1016/j.hrthm.2020.05.001](#)]
- 32 **Liu PP**, Blet A, Smyth D, Li H. The Science Underlying COVID-19: Implications for the Cardiovascular System. *Circulation* 2020; **142**: 68-78 [PMID: [32293910](#) DOI: [10.1161/CIRCULATIONAHA.120.047549](#)]
- 33 **Fischinger S**, Boudreau CM, Butler AL, Streeck H, Alter G. Sex differences in vaccine-induced humoral immunity. *Semin Immunopathol* 2019; **41**: 239-249 [PMID: [30547182](#) DOI: [10.1007/s00281-018-0726-5](#)]
- 34 **Bozkurt B**, Kamat I, Hotez PJ. Myocarditis With COVID-19 mRNA Vaccines. *Circulation* 2021; **144**: 471-484 [PMID: [34281357](#) DOI: [10.1161/CIRCULATIONAHA.121.056135](#)]
- 35 **Hou X**, Zaks T, Langer R, Dong Y. Lipid nanoparticles for mRNA delivery. *Nat Rev Mater* 2021; **6**: 1078-1094 [PMID: [34394960](#) DOI: [10.1038/s41578-021-00358-0](#)]
- 36 **Milane L**, Amiji M. Clinical approval of nanotechnology-based SARS-CoV-2 mRNA vaccines: impact on translational nanomedicine. *Drug Deliv Transl Res* 2021; **11**: 1309-1315 [PMID: [33512669](#) DOI: [10.1007/s13346-021-00911-y](#)]



Published by **Baishideng Publishing Group Inc**
7041 Koll Center Parkway, Suite 160, Pleasanton, CA 94566, USA

Telephone: +1-925-3991568

E-mail: bpgoffice@wjgnet.com

Help Desk: <https://www.f6publishing.com/helpdesk>

<https://www.wjgnet.com>

