

Late endocarditis of Amplatzer atrial septal occluder device in a child

Neerod K Jha, Laszlo Kiraly, John SK Murala, Csaba Tamas, Haitham Talo, Hazem El Badaoui, Magdi Tofeig, Malaika Mendonca, Sameer Sajwani, Mary A Thomas, Sura Ahmed Al Doory, Mohammad D Khan

Neerod K Jha, Laszlo Kiraly, John SK Murala, Csaba Tamas, Department of Pediatric Cardiac Surgery, Sheikh Khalifa Medical City (managed by Cleveland Clinic), Abu Dhabi, United Arab Emirates

Haitham Talo, Hazem El Badaoui, Magdi Tofeig, Mohammad D Khan, Department of Pediatric Cardiology, Sheikh Khalifa Medical City (managed by Cleveland Clinic), Abu Dhabi, United Arab Emirates

Malaika Mendonca, Department of Critical Care, Sheikh Khalifa Medical City (managed by Cleveland Clinic), Abu Dhabi, United Arab Emirates

Sameer Sajwani, Sura Ahmed Al Doory, Department of Cardiology, Latifa Hospital, Dubai, United Arab Emirates

Mary A Thomas, Department of Pathology, Sheikh Khalifa Medical City (managed by Cleveland Clinic), Abu Dhabi, United Arab Emirates

Author contributions: Jha NK, Kiraly L, Murala JSK, Tamas C, Talo H, El Badaoui H, Tofeig M and Khan MD designed the report and written the manuscript; Mendonca M, Sajwani S, Thomas MA and Al Doory SA analysed the data and revised it with special reference to the specialty involved; all authors were involved in the patient management.

Institutional review board statement: None.

Informed consent statement: The authors state that all involved persons (subjects or legally authorized representative) gave their informed consent (written or verbal) prior to study inclusion.

Conflict-of-interest statement: There is no conflict-of-interest in this review.

Open-Access: This article is an open-access article which was selected by an in-house editor and fully peer-reviewed by external reviewers. It is distributed in accordance with the Creative Commons Attribution Non Commercial (CC BY-NC 4.0) license, which permits others to distribute, remix, adapt, build upon this work non-commercially, and license their derivative works on different terms, provided the original work is properly cited and

the use is non-commercial. See: <http://creativecommons.org/licenses/by-nc/4.0/>

Correspondence to: Dr. Neerod K Jha, MD, Cardiac Surgeon, Department of Pediatric Cardiac Surgery, Sheikh Khalifa Medical City, District-Karamah, Karamah Street, P.O. Box 51900, Abu Dhabi, United Arab Emirates. njha@skmc.ae
Telephone: +971-50-6107532
Fax: +971-2-8193489

Received: June 25, 2015

Peer-review started: July 12, 2015

First decision: August 14, 2015

Revised: August 24, 2015

Accepted: September 10, 2015

Article in press: September 16, 2015

Published online: October 26, 2015

Abstract

Bacterial endocarditis following atrial septal defect closure using Amplatzer device in a child is extremely rare. We report a 10-year-old girl who developed late bacterial endocarditis, 6 years after placement of an Amplatzer atrial septal occluder device. Successful explantation of the device and repair of the resultant septal defect was carried out using a homograft patch. The rare occurrence of this entity prompted us to highlight the importance of long-term follow up, review the management and explore preventive strategies for similar patients who have multiple co-morbidities and a cardiac device. A high index of suspicion is warranted particularly in pediatric patients.

Key words: Endocarditis; Atrial; Septal; Device

© The Author(s) 2015. Published by Baishideng Publishing Group Inc. All rights reserved.

Core tip: Bacterial endocarditis following atrial septal defect closure using Amplatzer device in a child is extremely rare.

We report a 10-year-old girl who developed late bacterial endocarditis, 6 years after placement of an Amplatzer atrial septal occluder device. This case report demonstrates the need for long-term follow up of patients with intracardiac device especially those with multiple co-morbidities or who have vulnerability to infection due to poor general condition or extremes of age such as our's. A high index of suspicion for device complication is required if sepsis or embolic phenomenon found. Incomplete endothelialization of the prosthetic devices may be linked to endocarditis and needs to be explored.

Jha NK, Kiraly L, Murala JSK, Tamas C, Talo H, El Badaoui H, Tofeig M, Mendonca M, Sajwani S, Thomas MA, Al Doory SA, Khan MD. Late endocarditis of Amplatzer atrial septal occluder device in a child. *World J Cardiol* 2015; 7(10): 703-706 Available from: URL: <http://www.wjgnet.com/1949-8462/full/v7/i10/703.htm> DOI: <http://dx.doi.org/10.4330/wjc.v7.i10.703>

INTRODUCTION

Bacterial endocarditis of intracardiac devices including Amplatzer atrial septal occluder in pediatric population is extremely rare. In view of the limited experience, this is an opportunity to highlight such cases in order to review management and explore preventive strategies for a successful outcome in the future. We, therefore, presenting herewith a child with multiple co-morbidities who developed late bacterial endocarditis of an Amplatzer device following closure of secundum atrial septal defect and underwent successful management.

CASE REPORT

A 10-year-old girl was referred to us with a high-grade intermittent fever of 2 wk duration being treated for septic shock and altered sensorium. She also had a pyopericardium which was drained. She required ventilatory and minimal inotropic support. She had generalised anasarca, bilateral mild pleural effusions and generalised muscle spasticity. Additionally, there was cellulitis on the chest wall requiring surgical debridement. Blood and wound cultures were positive for *Streptococcus Pyogenes*, sputum for *Pseudomonas* and urine for *Escherichia coli*. She was managed with appropriate antibiotics. Other medications included diuretics, anti-convulsive therapy and ACE-inhibitors. She was known to have global developmental delay associated with cerebral atrophy and epilepsy with clonic seizures. In the past, at the age of 4 years, she underwent device closure of atrial septal defect in a hospital abroad. However, the details of the procedure were not available.

Routine blood tests revealed elevated markers of infection in addition to evidence of hepato-renal dysfunction. Computerized tomography of the chest revealed minor effusions in the pleural cavities and an

Amplatzer device in the atrium.

A two dimensional echocardiogram confirmed moderately depressed biventricular function, thickened pericardium and a prosthetic device in the inter-atrial septum with attached mobile vegetation (Figure 1). Other cardiac structures were normal.

It was suspected that the atrial septal occluder device was infected and possibly was a source of multiple systemic embolization and persistent bacteraemia. Therefore, we proceeded for surgical removal of the device.

Surgery was performed through median sternotomy under systemic heparinization, standard cardiopulmonary bypass using aortic and bicaval cannulation, aortic cross-clamping and cardioplegic arrest at moderate systemic hypothermia via right atrial approach. The pericardium was thickened and adherent all around featuring constrictive pericarditis. The Amplatzer device's surface was partially covered with the soft tissue (endothelialized) with patchy bare areas. However, there was no active vegetation found (Figure 2). Other cardiac structures including valves were grossly normal. After explantation of the device, a resultant atrial septal defect was repaired using a patch obtained from a pulmonary homograft.

The patient had slow but steady recovery. The post-operative echocardiography showed improved cardiac function without residual defects. There was a constant decline in the levels of inflammatory markers. She recovered fully except that generalized spasticity persisted. The histopathological examination of the tissue attached to the device showed evidence of severe acute and chronic inflammation in the connective tissue (Figure 3). However, a stain for fungal organism and culture of the tissue within the device was negative. Further studies to investigate the tissue infection within the soft tissue such as biofilm study or electron microscopy was not available.

DISCUSSION

Transcatheter occlusion technique using Amplatzer device has become a preferred approach for atrial septal defects in selected patients. The common complications associated with occluding devices are mal-positioning or migration of device, thromboembolism, arrhythmias or endocarditis^[1-5]. Bacterial endocarditis of an Amplatzer septal occluder device in the pediatric population is very rare. However, few reports have described early and late endocarditis associated with such device in adult population^[2-4].

Early device infection could be due to inoculation of organisms during implantation. However, hematogenous infection is the primary source of late endocarditis. In our patient, the source of infection could have been cellulitis or respiratory infection. In addition, there was purulent pericarditis. This combination suggests a hematogenous spread of infection leading to prosthesis endocarditis. In the only published report in a 4-year-old

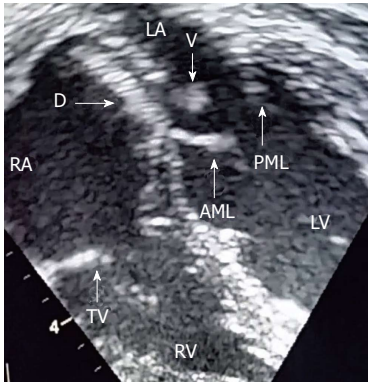


Figure 1 Two dimensional echocardiography image showing a large mobile vegetation (V) attached to the lower surface of an Amplatzer device (D) near the mitral valve. AML: Anterior mitral leaflet; PML: Posterior mitral leaflet; LV: Left ventricle; RV: Right ventricle; LA: Left atrium; TV: Tricuspid valve; RA: Right atrium.

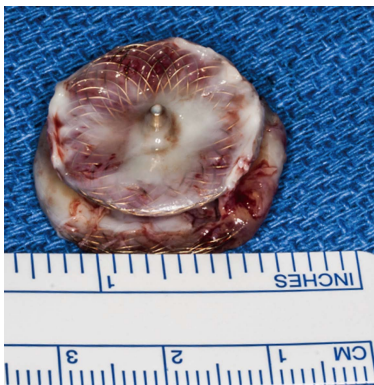

Figure 2 Explanted Amplatzer device showing embedded soft tissue and bare metal surface.

child, authors have proposed incomplete endothelialization of the device as a mechanism of late endocarditis^[3]. Upon closer look of the explanted device, we also have noticed gross evidence of incomplete endothelialization in the form of exposed metallic surface of the device in places without soft tissue coverage.

There are no established guidelines for the management of late endocarditis involving intra cardiac devices. We suggest that intensive management involving prolonged antibiotic therapy, monitoring of inflammatory markers and frequent blood cultures may be the first step. However, surgery is warranted if there is evidence of septal perforation, dehiscence, fistula formation, vegetation or embolization^[6,7]. The relative indication may include persistent positive blood cultures in spite of maximal medical therapy^[6,7]. The homograft patch may be the preferred choice for repair of resultant septal defect after explantation of the device in this situation presumably due to the resistant nature of the homograft tissue against infection and better antibiotic penetration as compared to synthetic materials. Bovine pericardium may be an alternative.

In the clinical and experimental studies, it has been

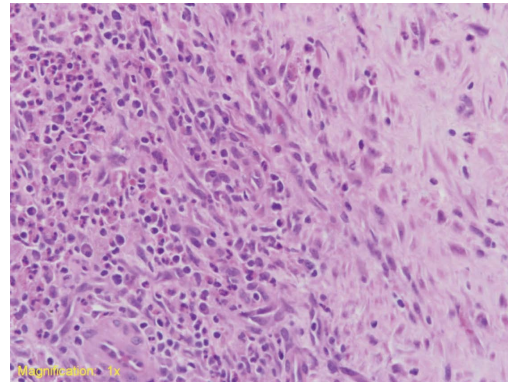


Figure 3 Microphotograph of the tissue within the explanted device showing connective tissue with dense, mixed, acute and chronic inflammatory infiltrates.

demonstrated that it takes 3-6 mo for complete neo-endothelialization of the device^[3]. Therefore, appropriate length of bacterial endocarditis prophylaxis for patients with atrial septal device closure was arbitrarily determined and usually extends from 6 mo to 1 year after implantation^[2-4]. We hope that in future, additional investigations, imaging techniques or biochemical markers will allow identification of patients with incomplete endothelialization who warrant long-term endocarditis prophylaxis.

This case report demonstrates the need for long-term follow up of patients with intracardiac devices especially those with multiple co-morbidities or who have vulnerability to infection due to poor general condition or extreme of age. A high index of suspicion for device complication is required, if sepsis or embolic phenomenon is found. An Intensive medical or surgical management and prolonged follow up is warranted for successful outcome.

COMMENTS

Case characteristics

A 10-year-old girl presented with late bacterial endocarditis of a cardiac Amplatzer device in addition to multiple co-morbidities and pancarditis.

Clinical diagnosis

Late bacterial endocarditis of cardiac prosthesis with cellulitis and pancarditis.

Differential diagnosis

Primary endocarditis of cardiac device, septicemia, pericarditis.

Laboratory diagnosis

Leucocytosis and mildly elevated hepato-renal function markers.

Imaging diagnosis

CT scan of the chest and an echocardiography showed evidence of a cardiac prosthesis (Amplatzer atrial septal occluder device) with a large vegetation.

Pathological diagnosis

The histopathology of the soft tissue attached to the explanted cardiac device showed the presence of acute and chronic inflammatory infiltrates. In addition, gross examination of the explanted Amplatzer device confirmed the presence of

bare metal exposed to the surface and the blood within the device.

Treatment

The patient was treated with intravenous antibiotics according to the culture and sensitivity reports of the blood, urine and pericardial fluids. Additionally, explantation of the atrial septal occluder device was done on cardiopulmonary bypass on urgent basis in order to remove the source of persistent bacteraemia and to avoid thromboembolism.

Related reports

The biofilm and electron microscopic studies were not available which may have a precise-diagnostic value to prove the presence of specific infection within the device.

Term explanation

Cardiopulmonary bypass is a term used to commonly indicate open heart surgery using a cardiopulmonary bypass machine with an oxygenator.

Experience and lessons

This case report not only represents a very rare occurrence of the late endocarditis of the cardiac device in association with pancarditis and multiple co-morbidities in a child but also provides authors an opportunity to focus their attention on the mechanism and prevention of this pathology for a better outcome in future. They have substantiated the hypothesis of the role of exposed bare metal surface and deficient soft tissue coverage (incomplete endothelialization) as a cause of prosthetic endocarditis. This fact not only guides us to explore the preventive measures while designing cardiac devices in future but also to be aware of a possibility of endocarditis in similar patients with multiple comorbidities and low resistance especially in pediatric population in order to have a cautious long-term follow-up and antibiotic prophylaxis.

Peer-review

The case report is very interesting and well described.

REFERENCES

- 1 **Chessa M**, Carminati M, Butera G, Bini RM, Drago M, Rosti L, Giamberti A, Pomè G, Bossone E, Frigiola A. Early and late complications associated with transcatheter occlusion of secundum atrial septal defect. *J Am Coll Cardiol* 2002; **39**: 1061-1065 [PMID: 11897451 DOI: 10.1016/s0735-1097(02)01711-4]
- 2 **Aruni B**, Sharifian A, Eryazici P, Herrera CJ. Late bacterial endocarditis of an Amplatzer atrial septal device. *Indian Heart J* 2013; **65**: 450-451 [PMID: 23993007 DOI: 10.1016/j.ihj.2013.06.002]
- 3 **Slesnick TC**, Nugent AW, Fraser CD, Cannon BC. Images in cardiovascular medicine. Incomplete endothelialization and late development of acute bacterial endocarditis after implantation of an Amplatzer septal occluder device. *Circulation* 2008; **117**: e326-e327 [PMID: 18458175 DOI: 10.1161/circulationaha.107.754069]
- 4 **Zahr F**, Katz WE, Toyoda Y, Anderson WD. Late bacterial endocarditis of an amplatzer atrial septal defect occluder device. *Am J Cardiol* 2010; **105**: 279-280 [PMID: 20102932 DOI: 10.1016/j.amjcard.2009.09.011]
- 5 **Balasundaram RP**, Anandaraja S, Juneja R, Choudhary SK. Infective endocarditis following implantation of amplatzer atrial septal occluder. *Indian Heart J* 2005; **57**: 167-169 [PMID: 16013359]
- 6 **Johnston LB**, Conly JM. Intracardiac device and prosthetic infections: What do we know? *Can J Infect Dis Med Microbiol* 2004; **15**: 205-209 [PMID: 18159493]
- 7 **Karchmer AW**, Longworth DL. Infections of intracardiac devices. *Cardiol Clin* 2003; **21**: 253-271, vii [PMID: 12874897]

P- Reviewer: Polewczyk A S- Editor: Qiu S L- Editor: A
E- Editor: Lu YJ





Published by **Baishideng Publishing Group Inc**

8226 Regency Drive, Pleasanton, CA 94588, USA

Telephone: +1-925-223-8242

Fax: +1-925-223-8243

E-mail: bpgoffice@wjgnet.com

Help Desk: <http://www.wjgnet.com/esps/helpdesk.aspx>

<http://www.wjgnet.com>

