

## Role of radionuclide imaging for diagnosis of device and prosthetic valve infections

Jean-François Sarrazin, François Philippon, Mikaël Trottier, Michel Tessier

Jean-François Sarrazin, François Philippon, Department of Cardiology, Institut Universitaire de Cardiologie et Pneumologie de Québec, Laval University, Québec, QC G1V 4G5, Canada

Mikaël Trottier, Michel Tessier, Department of Nuclear Medicine, Institut Universitaire de Cardiologie et Pneumologie de Québec, Laval University, Québec, QC G1V 4G5, Canada

**Author contributions:** Sarrazin JF, Philippon F, Trottier M and Tessier M drafted the article or made critical revisions to the manuscript and gave their final approval of the version of the article to be published.

**Conflict-of-interest statement:** No conflicts of interest.

**Open-Access:** This article is an open-access article which was selected by an in-house editor and fully peer-reviewed by external reviewers. It is distributed in accordance with the Creative Commons Attribution Non Commercial (CC BY-NC 4.0) license, which permits others to distribute, remix, adapt, build upon this work non-commercially, and license their derivative works on different terms, provided the original work is properly cited and the use is non-commercial. See: <http://creativecommons.org/licenses/by-nc/4.0/>

**Manuscript source:** Invited manuscript

**Correspondence to:** Jean-François Sarrazin, MD, FRCPC, FACC, FHRS, Department of Cardiology, Institut Universitaire de Cardiologie et Pneumologie de Québec, Laval University, 2725 chemin Sainte-Foy, Québec, QC G1V 4G5, Canada. [jean-francois.sarrazin@criucpq.ulaval.ca](mailto:jean-francois.sarrazin@criucpq.ulaval.ca)  
Telephone: +1-418-6564598  
Fax: +1-418-6564581

Received: April 24, 2016

Peer-review started: April 25, 2016

First decision: June 6, 2016

Revised: July 7, 2016

Accepted: July 20, 2016

Article in press: July 22, 2016

Published online: September 26, 2016

### Abstract

Cardiovascular implantable electronic device (CIED)

infection and prosthetic valve endocarditis (PVE) remain a diagnostic challenge. Cardiac imaging plays an important role in the diagnosis and management of patients with CIED infection or PVE. Over the past few years, cardiac radionuclide imaging has gained a key role in the diagnosis of these patients, and in assessing the need for surgery, mainly in the most difficult cases. Both  $^{18}\text{F}$ -fluorodeoxyglucose positron emission tomography/computed tomography ( $^{18}\text{F}$ -FDG PET/CT) and radiolabelled white blood cell single-photon emission computed tomography/computed tomography (WBC SPECT/CT) have been studied in these situations. In their 2015 guidelines for the management of infective endocarditis, the European Society of Cardiology incorporated cardiac nuclear imaging as part of their diagnostic algorithm for PVE, but not CIED infection since the data were judged insufficient at the moment. This article reviews the actual knowledge and recent studies on the use of  $^{18}\text{F}$ -FDG PET/CT and WBC SPECT/CT in the context of CIED infection and PVE, and describes the technical aspects of cardiac radionuclide imaging. It also discusses their accepted and potential indications for the diagnosis and management of CIED infection and PVE, the limitations of these tests, and potential areas of future research.

**Key words:** Device; Endocarditis; Fluorodeoxyglucose; Imaging; Infection; Leukocytes; Positron emission tomography/computed tomography; Prosthetic valve; Radionuclide; Scintigraphy

© **The Author(s) 2016.** Published by Baishideng Publishing Group Inc. All rights reserved.

**Core tip:** Cardiovascular implantable electronic device infection and prosthetic valve endocarditis remain a diagnostic challenge. This review article describes the evolving role of cardiac radionuclide imaging in the diagnosis and management of cardiac infections. It focuses on recent published studies, indications and limitations of both  $^{18}\text{F}$ -fluorodeoxyglucose positron emission tomography/computed tomography and

radiolabelled white blood cell single-photon emission computed tomography/computed tomography.

Sarrazin JF, Philippon F, Trottier M, Tessier M. Role of radionuclide imaging for diagnosis of device and prosthetic valve infections. *World J Cardiol* 2016; 8(9): 534-546 Available from: URL: <http://www.wjgnet.com/1949-8462/full/v8/i9/534.htm> DOI: <http://dx.doi.org/10.4330/wjc.v8.i9.534>

## INTRODUCTION

Cardiovascular implantable electronic device (CIED) infection and prosthetic valve endocarditis (PVE) carry significant morbidity and mortality as well as substantial financial burden to the society<sup>[1]</sup>. In some cases, establishing the diagnosis might be challenging since cultures are not always positive and they do not necessarily imply that the device/leads or heart valves are infected. Since device/lead extraction and repeat cardiac surgery are associated with significant risks, it is important to confirm the diagnosis and to plan the appropriate treatment. Cardiac imaging plays an important role in the pre-operative evaluation of patients with CIED infection and PVE. Radionuclide imaging has evolved over the past few years as an additional tool to confirm or exclude prosthetic infection and to guide the most appropriate clinical management, either complete removal or conservative treatment. In their 2015 guidelines for the management of infective endocarditis (IE), the European Society of Cardiology (ESC) addressed the use of nuclear medicine imaging for the diagnosis of IE<sup>[1]</sup>. The main objectives are to position <sup>18</sup>F-fluorodeoxyglucose positron emission tomography/computed tomography (<sup>18</sup>F-FDG PET/CT) and white blood cell single-photon emission computed tomography/computed tomography (WBC SPECT/CT) imaging in clinical practice and to review the actual knowledge and recent studies as well as to address areas of future research.

## CLINICAL PRESENTATION AND DIAGNOSIS OF CARDIAC INFECTIONS

CIED infection and PVE remain a diagnostic challenge. The clinical presentation can be highly variable because of multiple potential causative microorganisms, the presence of documented heart disease, cardiac devices or prosthetic valves, different modes of presentation, and sometimes non-specific symptoms at the time of initial presentation. The modified Duke criteria are considered the gold standard for the diagnosis of endocarditis<sup>[2,3]</sup>. However, the early diagnostic accuracy is often sub-optimal with several patients being misclassified<sup>[4]</sup>. This is true mainly in patients with CIED infection and PVE. The early diagnosis of IE is imperative since postponement of antibiotic therapy and/or surgery can

lead to a poor outcome<sup>[5,6]</sup>.

A high level of expertise is required and it often includes cardiologists, nuclear medicine specialists, electrophysiologists, cardiac surgeons and infectious disease specialists. The concept of a "Heart Team approach" or "Endocarditis Team" has been proposed to improve the diagnosis and management of CIED infection and PVE. The use of a multidisciplinary task force with a well-defined protocol has been shown to decrease the 1-year mortality of patients with IE from 18.5% to 8.2%<sup>[7]</sup>.

In addition, cardiac imaging plays an essential role in the diagnosis and management of IE. In recent guidelines, transthoracic echocardiography (TTE) and transesophageal echocardiography (TEE) remain the initial recommended imaging techniques for the diagnosis of IE (class I indication, level of evidence B)<sup>[1]</sup>. Some echocardiographic information is included as major criteria for the diagnosis of IE. The sensitivity for the identification of vegetations with TTE is 75% for native valves, but may be lower in patients with poor echogenicity or prosthetic valves or very small vegetations<sup>[8]</sup>. On the other hand, the sensitivity of TEE is superior at 85%-90%. However, a negative echocardiography does not rule out IE, and it has been recommended to repeat the TEE 3 to 5 d later or sooner when there is a high suspicion of IE or a change in the clinical status (class I, level of evidence B)<sup>[9]</sup>. In addition, non-infective vegetations such as strands or thrombi on valvular prosthesis or leads can lead to a false diagnosis of IE in up to 15% of cases<sup>[4]</sup>. These findings highlight the limitations of echocardiography and the potential benefits of other imaging techniques in such instances.

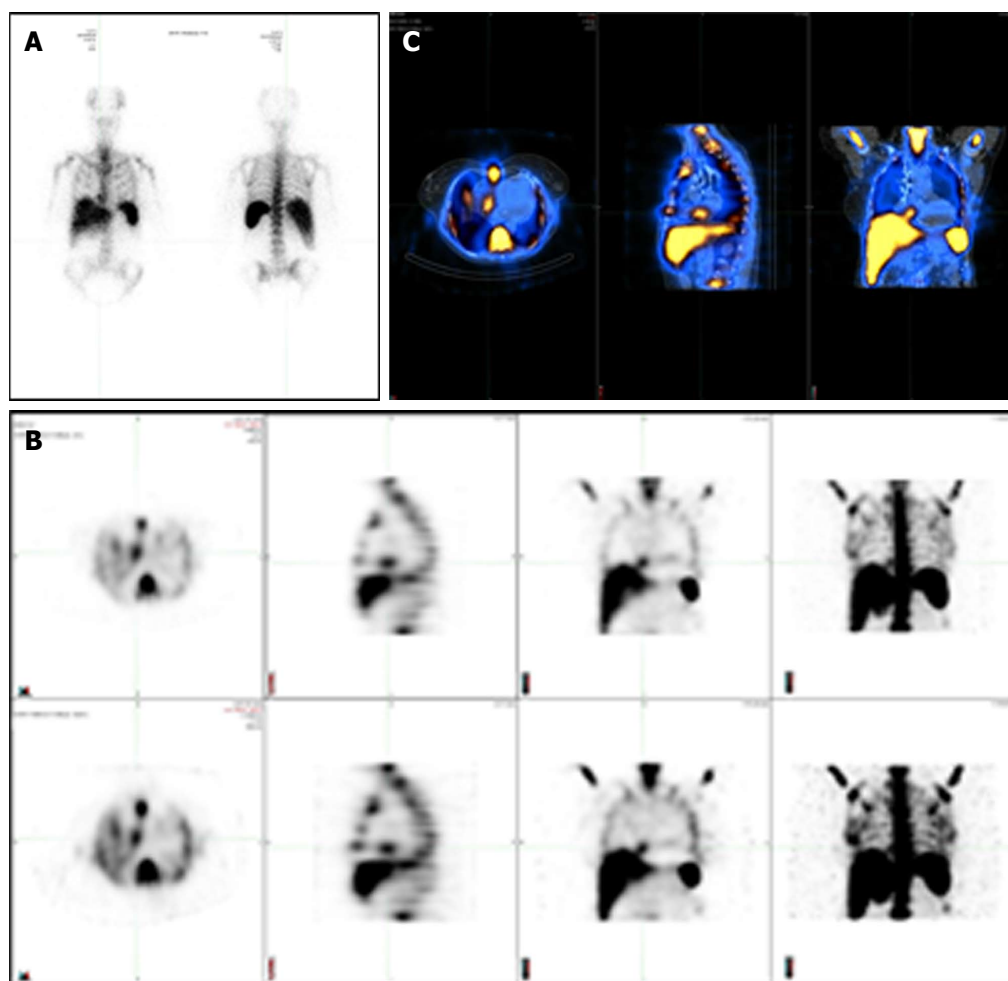
Investigation of patients with IE can also include other imaging techniques, such as multislice computed tomography for detection of abscesses or pseudoaneurysms, magnetic resonance imaging for detection of cerebral lesions, <sup>18</sup>F-FDG PET/CT, and radiolabelled WBC hybrid SPECT/CT imaging.

## USE OF CARDIAC NUCLEAR IMAGING IN CARDIAC INFECTIONS

PET imaging has been used for cancer diagnosis and staging and to detect infection in orthopaedic prostheses. In cardiology, it is used to evaluate myocardial viability, ischemia and to identify infection associated with vascular grafts, CIED and prosthetic valves.

With the combination of radionuclide imaging to CT scan (hybrid technology), nuclear imaging has provided significant supplementary information in patients with suspected IE. Two radionuclide imaging techniques are presently used in the diagnosis of CIED infection and PVE: (1) radiolabelled WBC SPECT/CT using either <sup>111</sup>In-oxine or <sup>99m</sup>Tc-hexamethylpropyleneamine oxime (HMPAO); and (2) <sup>18</sup>F-FDG PET/CT.

WBC SPECT/CT imaging uses autologous radio-



**Figure 1** Different modalities in cardiac nuclear imaging. A: Planar scintigraphy with a single two-dimensional image; B: Single photon emission computed tomography (SPECT) displayed as transverse, sagittal, coronal and MIP attenuation corrected (top row) and uncorrected images (bottom row); C: Hybrid SPECT/CT with precisely registered CT image.

labelled leukocytes ( $^{111}\text{In}$ -oxine or  $^{99\text{m}}\text{Tc}$ -HMPAO) that are injected intravenously back to the patient to look for infection in the body by imaging gamma rays. The accumulation of radiolabelled leukocytes is time-dependent between initial and late images. Planar images are obtained from different angulations with subsequent SPECT acquisition, 3D reconstruction and fusion with low-dose CT for further anatomical localization and attenuation correction. Figure 1 shows the differences between planar scintigraphy, conventional SPECT imaging and hybrid SPECT/CT. The sensitivity of this test depends on neutrophil granulocytes accumulation and is higher during acute infection. Studies have shown that cells participating in infection and inflammation, mainly neutrophils and macrophages, are able to express a great amount of glucose transporters, mainly GLUT1 or GLUT3 as well as hexokinase activity<sup>[10-14]</sup>. WBC SPECT/CT using  $^{99\text{m}}\text{Tc}$ -HMPAO is performed 4 h following injection of radiolabelled leukocytes, although images at 24 h are possible but with loss of some image quality, whereas WBC SPECT/CT using  $^{111}\text{In}$ -oxine allows imaging up to 72 h with potentially better sensitivity (typically performed at 4, 24 and sometimes 48 h).

This is based on the half-life of each radioactive isotope, being 6 h for  $^{99\text{m}}\text{Tc}$  and 67 h for  $^{111}\text{In}$ . WBC SPECT/CT allows a higher specificity for the identification of active infection. However, leukocytes radiolabelling is more time-consuming. It also associated with manipulation of blood products.

$^{18}\text{F}$ -FDG PET/CT is a well-known non-invasive imaging technique that allows 3D calculation of metabolic activity within the body obtained from the emission of positrons subsequent to the disintegration of a radioactive compound.  $^{18}\text{F}$ -FDG is a glucose analogue, which is incorporated and retained within cells with a high metabolic activity, such as inflammatory cells. It is usually performed approximately 1 h after the injection of  $^{18}\text{F}$ -FDG. This tracer is actively incorporated by leukocytes, macrophages and  $\text{CD4}^+$  T-lymphocytes located at areas of infection *via* glucose transporters, primarily GLUT 1 and GLUT3, which are insulin sensitive and present in the myocardium<sup>[12-14]</sup>. Inside the cells,  $^{18}\text{F}$ -FDG is phosphorylated and remains intracellular without further transformation.

Each technique has advantages and weaknesses for the identification of active infection in cases of

**Table 1 Advantages and limitations of  $^{18}\text{F}$ -fluorodeoxyglucose positron emission tomography/computed tomography and white blood cell single-photon emission computed tomography/computed tomography for the diagnosis of device infection and prosthetic valve endocarditis**

Advantages	Limitations
$^{18}\text{F}$ -FDG PET/CT	
Excellent spatial resolution	Moderate radiation exposure (8-30 mSv depending on the study performed)
Short acquisition time	Not available in several centers
High sensitivity for the detection of hypermetabolic activity	Physiological uptake of $^{18}\text{F}$ -FDG in the myocardium might prevent adequate detection of cardiac infection
Detection of peripheral events	Recent surgery may demonstrate residual inflammatory changes without evidence of infection
Detection of other sources of fever or bacteremia in patients with CIED	Possible uptakes can be found in active thrombi, cardiac tumours or metastasis, and foreign body reactions
Detection of CIED infection and PVE in cases of a negative TEE	Possible false-negative test in patients with small vegetations or prolonged antibiotic therapy Less useful for infectious brain embolisms because of high glucose metabolism in the brain
WBC SPECT/CT	
High specificity for the presence of active infection	Time-consuming It involves blood products handling Cases of false-negative study seen with <i>Candida</i> and <i>Enterococcus</i> infection

CIED: Cardiovascular implantable electronic device;  $^{18}\text{F}$ -FDG PET/CT:  $^{18}\text{F}$ -fluorodeoxyglucose positron emission tomography/computed tomography; PVE: Prosthetic valve endocarditis; TEE: Transesophageal echocardiography; WBC SPECT/CT: Radiolabelled white blood cell single-photon emission computed tomography/computed tomography.

presumed PVE (Table 1).  $^{18}\text{F}$ -FDG PET/CT has the convenience of a shorter procedure time and a high sensitivity for the identification of hypermetabolic areas. It also has an excellent spatial resolution. However, it does not discriminate enough between infection and inflammation, mainly in the first few months postoperatively. Also, evaluation of  $^{18}\text{F}$ -FDG uptakes around cardiac valves can be more difficult if residual physiological myocardial uptake is present. For this reason, it is recommended to prepare the patient with the Atkins diet, which is a low-carbohydrate diet<sup>[15]</sup>. It is also suggested injecting a heparin bolus before administration of  $^{18}\text{F}$ -FDG. Unfractionated heparin increases plasma free fatty acids *via* activation of lipoprotein and hepatic lipases<sup>[16]</sup>. This can lead to a reduction in glucose consumption within the normal myocardium

### Technical aspects

In the literature, there are significant variations in the  $^{18}\text{F}$ -FDG PET/CT protocols used. Normally,  $^{18}\text{F}$ -FDG PET/CT is performed after a fasting period of 8 to 12 h. Eating foods rich in fat but very low in carbohydrates the evening prior to the exam is suggested in order to

decrease the physiological uptake of  $^{18}\text{F}$ -FDG within the myocardium<sup>[17]</sup>. Patients should avoid bread, cereals, pasta, potatoes, rice, beans, fruit juice, chewing gum and drinking alcohol. Unfractionated heparin (50 IU/kg) can also be administered intravenously 15 min prior to  $^{18}\text{F}$ -FDG injection in an attempt to reduce more the physiological uptake. PET imaging is usually performed 1 h after the injection of 4-5 MBq/kg of  $^{18}\text{F}$ -FDG. Simultaneously, a whole-body low-dose CT without intravenous contrast is carried out for correction of attenuation and anatomic localization. The capillary glucose is measured, and patients receive an insulin injection if the fasting glucose is above 7.7 mmol/L or 140 mg/dL. The analysis is then performed using dedicated softwares. Both attenuation-corrected and non-attenuation-corrected images are reviewed in order to recognize potential artefacts that could be related to close proximity of objects of high density, such as device generator or prosthesis. A visual analysis is first performed to identify sites of hypermetabolic or abnormal  $^{18}\text{F}$ -FDG uptakes in close proximity to prosthetic valves and device generator/leads with further confirmation in the uncorrected images. In patients with CIED, focal uptake can be further classified based on the location (pocket infection, lead infection or both). Then, semi-quantitative analyses are done to measure the maximal standardized uptake value ( $\text{SUV}_{\text{max}}$ ). However, it is important to recognize that these values have to be used with caution, since they can be falsely elevated due to the attenuation correction when measured in close proximity to a metallic object. For this reason, a semi-quantitative count ratio on non-attenuation-corrected images is likely superior to  $\text{SUV}_{\text{max}}$  (compared to an organ of reference, *i.e.*, lung, mediastinum or liver parenchyma). In addition, whole-body acquisition allows for the detection of silent embolic events and extracardiac abnormal uptakes.

Autologous radiolabelled WBC scintigraphy with  $^{111}\text{In}$ -oxine was introduced in the mid-1970s. Over the years, it has been mainly substituted by  $^{99\text{m}}\text{Tc}$ -HMPAO, which has more advantageous physical characteristics, cost, availability, and lower radiation burden<sup>[18]</sup>.  $^{99\text{m}}\text{Tc}$  has a shorter imaging time because of a half-life of 6 h compared to 67 h for Indium. However, Indium is often preferred for the detection of CIED infection and PVE since it allows acquisitions over a longer period of time (up to 72 h).

There are several methods for labelling WBC, but the main principles and technique are similar. Around 40-60 mL of venous blood is taken from the patient and then combined to 10 mL of acid-citrate-dextrose anticoagulant solution. This syringe is then put in an upright position for 1 to 2 h to facilitate erythrocyte sedimentation by gravity. After erythrocytes have been removed, blood centrifugation is then performed to separate leukocytes from platelets. HMPAO is labelled with  $^{99\text{m}}\text{Tc}$  and incubated for 15 min with leukocytes. The routine dose of  $^{111}\text{In}$  labelled leukocytes is 10-20 MBq (0.3-0.5 mCi) while the quantity of  $^{99\text{m}}\text{Tc}$ -HMPAO labelled



leukocytes is 185-370 MBq (5-10 mCi). Radiolabelled leukocytes are separated from HMPAO by centrifugation. The majority of labelled leukocytes are neutrophils. For this reason, the procedure is mainly useful for identification of a neutrophil-mediated process, such as a bacterial infection. A labelling efficiency of at least 40% should be achieved. Radiolabelled leukocytes are tested by the trypan blue exclusion test for viability. The cells are then resuspended in plasma before reinjection into the patient. For  $^{99m}\text{Tc}$ -HMPAO labelled leukocytes, the scintigraphy is performed 4 and 24 h (delayed images) after injection, and sometimes 48 h or rarely 72 h for  $^{111}\text{In}$  labelled leukocytes. Images are acquired using a SPECT/CT system. Scintigraphy is considered positive when an area of labelled WBC uptake superior to background activity is identified in the involved area and when the signal increases over time.

## DEVICE INFECTION

CIED infection is associated with significant morbidity and mortality. Device infection prevalence is increasing in parallel with broader indications for ICD implantation and cardiac resynchronization, the presence of more comorbidities, and the growing number of implants in the world<sup>[19]</sup>. It is known however that the infection burden increases more than the increase in device implantations. This is probably related to more comorbidities and change in pathogens<sup>[20]</sup>. Cardiac device infections can present as a superficial or deep generator pocket infection or cardiac-device-related IE with involvement of the leads and/or extension to cardiac valves. It should be initially suspected in patients with CIED who consult for unexplained fever. Deep pocket infection and/or lead infection require complete system extraction. However, superficial infection not in contact with the device can be treated with antibiotic therapy alone. The diagnosis is sometimes quite obvious in the presence of significant pocket redness or pus, bacteremia or lead vegetation on TEE. Unfortunately, several cases are more complicated to assess. Since device and lead extraction can be associated with significant morbidity (major complications = 1.5%-2%) and mortality (0.8%) even in an experienced center, a definite diagnosis is important<sup>[21]</sup>. On the other hand, CIED infection can be overestimated with echocardiography since non-infectious accretions can be found in up to 21% by TTE and 28% by TEE in CIED patients without infection<sup>[22]</sup>. These patients can have fever or bacteremia for another reason. Thus, another form of imaging is proposed before proceeding to extraction/surgery.

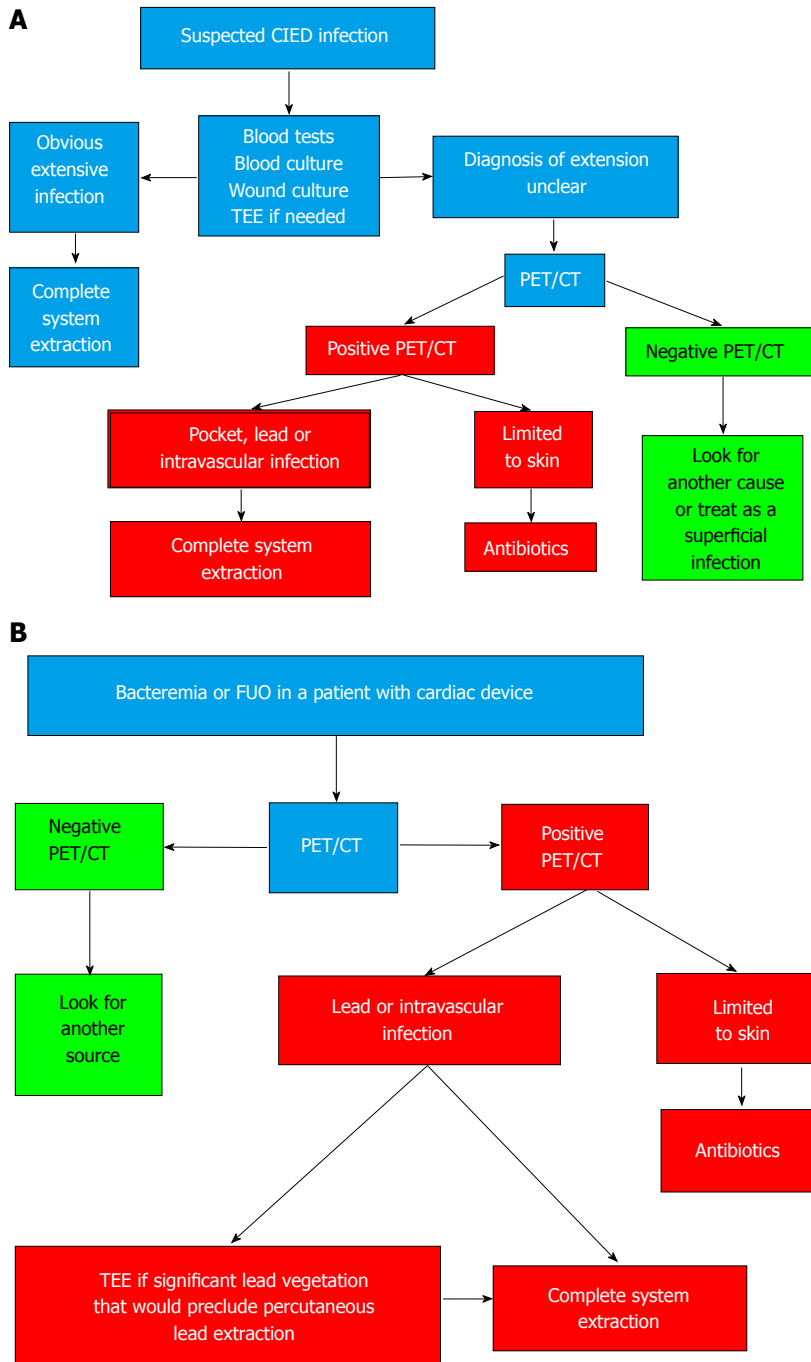
### Studies using $^{18}\text{F}$ -FDG PET/CT

The first report of cardiac infection detected by  $^{18}\text{F}$ -FDG PET was published in 2006<sup>[23]</sup>. Afterwards, 2 small pilot studies were published on device infection and  $^{18}\text{F}$ -FDG PET/CT. Bensimhon *et al.*<sup>[24]</sup> evaluated the diagnostic value of  $^{18}\text{F}$ -FDG PET/CT in 21 patients with presumed device infection, which were compared to 14 patients

without infection.  $^{18}\text{F}$ -FDG PET/CT had a sensitivity and specificity of 80% and 100%, respectively for diagnosis of infection. Patients with false negative studies for lead infection had received antibiotics for a longer period of time prior to the  $^{18}\text{F}$ -FDG PET/CT (20 d vs 3.2 d;  $P < 0.01$ ). The sensitivity was lower for the diagnosis of lead infection (60% compared to 100% for pocket infection). Ploux *et al.*<sup>[25]</sup> investigated the role of  $^{18}\text{F}$ -FDG PET/CT in 10 patients with CIED and fever of unknown origin. These patients were compared to a control group of 40 patients.  $^{18}\text{F}$ -FDG PET/CT showed increased  $^{18}\text{F}$ -FDG uptakes along the leads in 6 out of 10 patients who had initial comprehensive negative investigation. Subsequently, these patients had complete extraction of the implanted material and lead cultures were positive on all 6 patients. This showed the promising value of  $^{18}\text{F}$ -FDG PET/CT in difficult CIED cases.

In 2012, our group evaluated the usefulness of  $^{18}\text{F}$ -FDG PET/CT for the identification of CIED infection<sup>[26]</sup>. We compared 3 groups: 42 patients with suspected CIED infection, 12 patients with recent device implantation (between 4 and 8 wk postoperatively) but no clinical signs of infection, and 12 patients with devices implanted for more than 6 mo and also no device infection. We showed an excellent correlation between sites of  $^{18}\text{F}$ -FDG uptakes on  $^{18}\text{F}$ -FDG PET/CT and clinical findings on TEE or at the time of extraction.  $^{18}\text{F}$ -FDG PET/CT using a qualitative visual score had a sensitivity and specificity for diagnosis of CIED infection of 89% and 86%, respectively. We also demonstrated that  $^{18}\text{F}$ -FDG PET/CT could identify patients with superficial infection without direct involvement of the generator or leads that could be treated only with antibiotics. Negative  $^{18}\text{F}$ -FDG PET/CT identified a group of patients that had an excellent outcome without device extraction. Finally, we were able to identify a semi-quantitative ratio between the maximal uptake and normal lung parenchyma uptake, which was useful in differentiating between CIED infection and residual normal post-operative changes; a ratio of 1.5 had the best combination of sensitivity and specificity. Based on this information, we suggested an algorithm using  $^{18}\text{F}$ -FDG PET/CT for the evaluation of CIED infection (Figure 2). An important clinical aspect of  $^{18}\text{F}$ -FDG PET/CT is its high negative predictive value.

Since, Cautela *et al.*<sup>[27]</sup> demonstrated that  $^{18}\text{F}$ -FDG PET/CT had a high accuracy for the diagnosis of skin and pocket CIED infection (sensitivity 86.7% and specificity 100%), but a lower sensitivity of only 30.8% and a specificity of 62.5% for lead or cardiac involvement. Many patients with a false-negative test were already on antibiotics. The size of the vegetations might also have influenced the results. It cannot be excluded that some patients with lead extraction had a non-infectious cause for the vegetations seen on the lead. Finally, a possible limitation of this study is suboptimal patient preparation in order to partially explain the lower sensitivity observed for lead or cardiac involvement. It is of the utmost importance to make

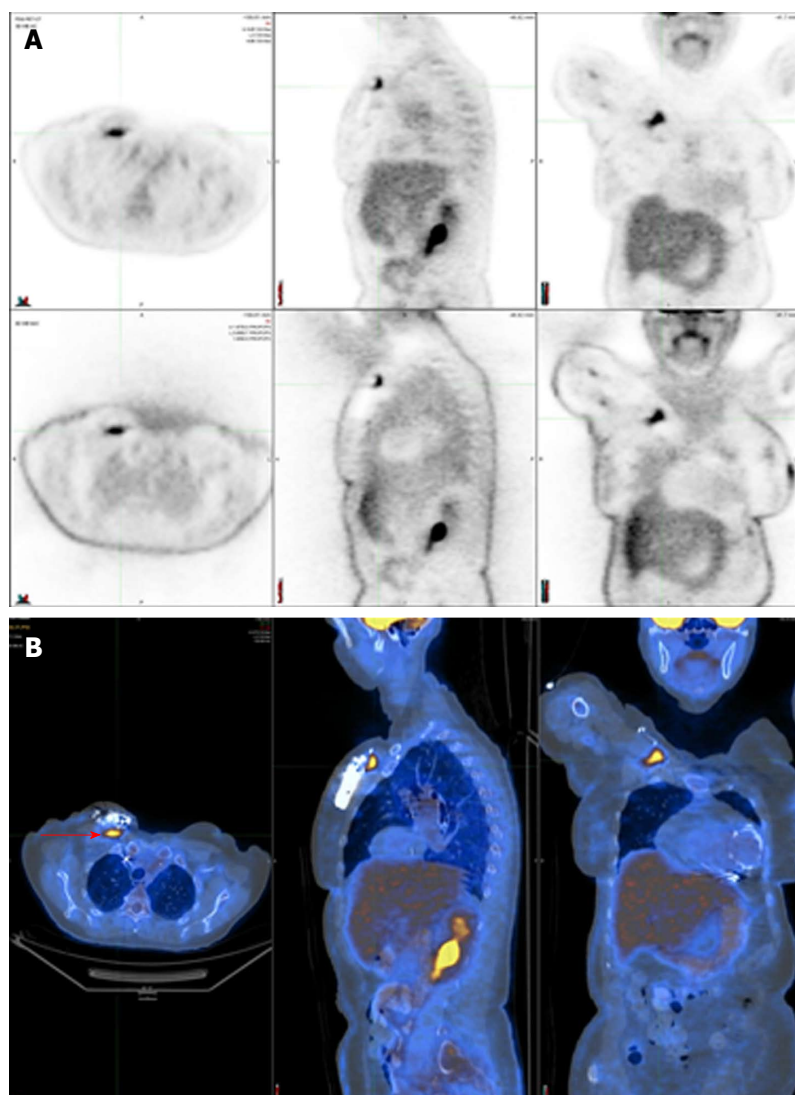


**Figure 2** Proposed algorithms incorporating  $^{18}\text{F}$ -fluorodeoxyglucose positron emission tomography/computed tomography in the evaluation and management of patients with possible device infection. A: Initial CIED infection suspicion; B: Patients with cardiac device and bacteremia or fever of unknown origin (FUO) (Reprinted from Sarrazin JF, Philippon F, Tessier M, Guimond J, Molin F, Champagne J, Nault I, Blier L, Nadeau M, Charbonneau L, Trottier M, O'Hara G. Usefulness of fluorine-18 positron emission tomography/computed tomography for identification of cardiovascular implantable electronic device infections. *J Am Coll Cardiol* 2012; 59: 1616-1625, with permission from Elsevier). CIED: Cardiovascular implantable electronic device; PET/CT: Positron emission tomography/computed tomography; TEE: Transesophageal echocardiography.

sure that physiologic myocardial uptake is suppressed to be able to realize an optimal evaluation. Ideally, every patient should be prepared with the Atkins diet and receive a heparin bolus before  $^{18}\text{F}$ -FDG injection. Ahmed *et al.*<sup>[28]</sup> demonstrated that  $^{18}\text{F}$ -FDG PET/CT had a high diagnostic accuracy for the detection of patient with pocket infection that eventually required extraction. They find that the optimal semi-quantitative ratio cut-off

value for the early identification of patients with pocket infection was  $> 2.0$ , giving a sensitivity of 97% and a specificity of 98%.

Figure 3 shows a positive  $^{18}\text{F}$ -FDG PET/CT in a patient with a deep pocket infection, while Figure 4 shows another positive  $^{18}\text{F}$ -FDG PET/CT but in a patient with a lead infection. Note how the physiologic myocardial uptake is well suppressed in this case.



**Figure 3** Positive  $^{18}\text{F}$ -fluorodeoxyglucose positron emission tomography/computed tomography in a patient with a deep pocket infection shown by focal  $^{18}\text{F}$ -fluorodeoxyglucose uptake just underneath the generator (red arrow). A: SPECT displayed as transverse, sagittal, and coronal attenuation corrected (top row) and uncorrected images (bottom row); B: Hybrid SPECT/CT displayed as transverse, sagittal, and coronal images. SPECT/CT: Single-photon emission computed tomography/computed tomography.

### Studies using WBC SPECT/CT

The diagnostic accuracy of radiolabelled WBC scintigraphy was evaluated by Erba *et al.*<sup>[29]</sup>. They obtained a sensitivity of 94% for both detection and localization of CIED infection. Two cases of false-negative scans were seen in patients with *Candida* and *Enterococcus* infection. No false-positive studies were seen, confirming the high specificity of this technique. They demonstrated the superiority of SPECT/CT over planar and SPECT alone imaging.

Based on these studies,  $^{18}\text{F}$ -FDG PET/CT and WBC SPECT/CT might play an additional role in the diagnosis of CIED infection, but data were judged not sufficient at the moment to be incorporated into the diagnostic criteria of IE involving pacemaker or defibrillator leads in the latest European guidelines<sup>[1]</sup>. Overall,  $^{18}\text{F}$ -FDG PET/CT seems to have an excellent sensitivity for the diagnosis of pocket infection, but a lower sensitivity in the context of lead infection.

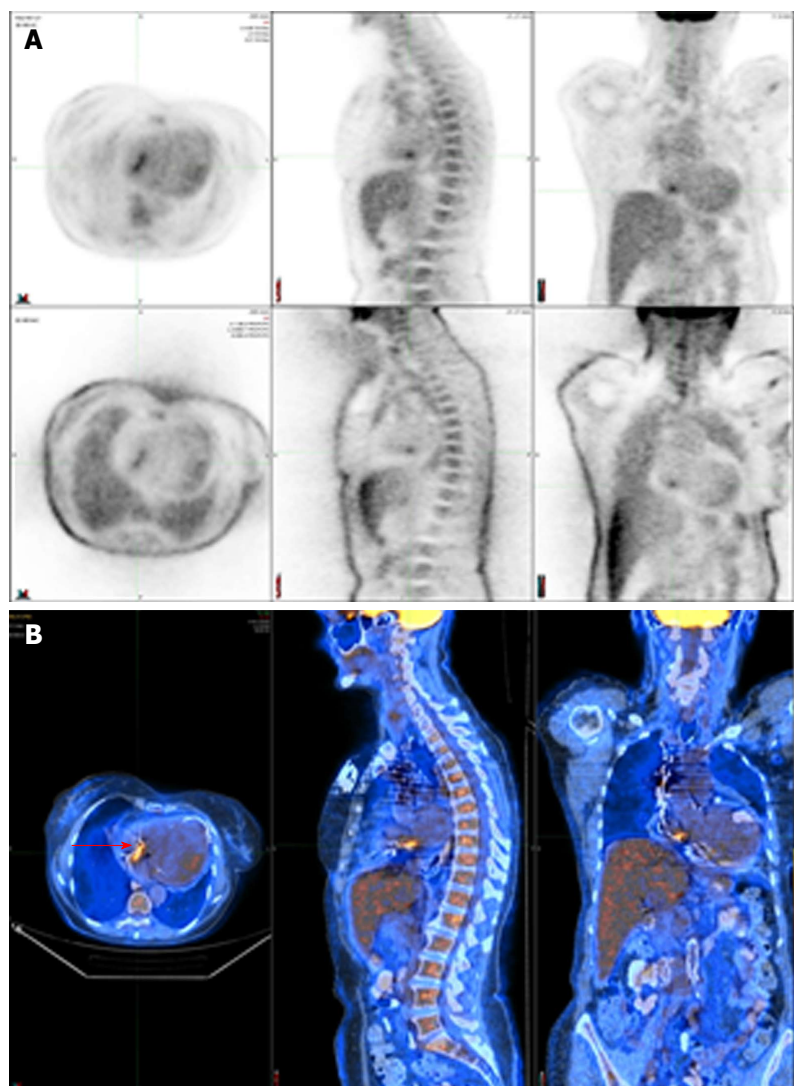
## PROSTHETIC VALVE INFECTION

Early diagnosis of PVE is also challenging. PVE is a

severe form of IE and accounts for 10%-30% of all cases of IE. The diagnosis is often more difficult than in native valve endocarditis. Since the initial echocardiography is often normal or inconclusive in PVE, other imaging techniques are sometimes necessary. The use of  $^{18}\text{F}$ -FDG PET/CT in patients with PVE has evolved as a useful tool.

### Studies using $^{18}\text{F}$ -FDG PET/CT

Case reports have demonstrated the possible benefits of  $^{18}\text{F}$ -FDG PET/CT in the diagnosis of prosthetic valves<sup>[30]</sup>. Saby *et al.*<sup>[31]</sup> demonstrated the incremental benefit of using abnormal  $^{18}\text{F}$ -FDG uptake as a major criterion for the modified Duke criteria in the detection of PVE. They have shown that  $^{18}\text{F}$ -FDG PET/CT significantly increases the sensitivity of IE diagnosis from 70% to 97% ( $P = 0.008$ ) on admission. They determined that  $^{18}\text{F}$ -FDG PET/CT had an adequate diagnostic value when abnormal  $^{18}\text{F}$ -FDG uptake is found near the prosthetic valve. They also showed that abnormal  $^{18}\text{F}$ -FDG uptake could be seen prior to detection of valvular damage by echocardiography in multiple patients, which emphasizes the benefit of  $^{18}\text{F}$ -FDG PET/CT to identify



**Figure 4** Positive  $^{18}\text{F}$ -fluorodeoxyglucose positron emission tomography/computed tomography in a patient with a lead infection (red arrow). A: SPECT displayed as transverse, sagittal, and coronal attenuation corrected (top row) and uncorrected images (bottom row); B: Hybrid SPECT/CT displayed as transverse, sagittal, and coronal images. SPECT/CT: Single-photon emission computed tomography/computed tomography.

active infection before important damage has occurred.

Rouzet *et al.*<sup>[32]</sup> evaluated the ability of  $^{18}\text{F}$ -FDG PET/CT and radiolabelled WBC imaging to diagnose PVE in 39 patients with presumed PVE but inconclusive echocardiography findings.  $^{18}\text{F}$ -FDG PET/CT had a higher sensitivity (93% vs 64%) but leukocyte scintigraphy had a higher specificity (100% vs 71%). Since it has a higher specificity for the detection of IE, it could be used in cases of equivocal  $^{18}\text{F}$ -FDG PET/CT or within the initial two months after heart valve surgery<sup>[32]</sup>.

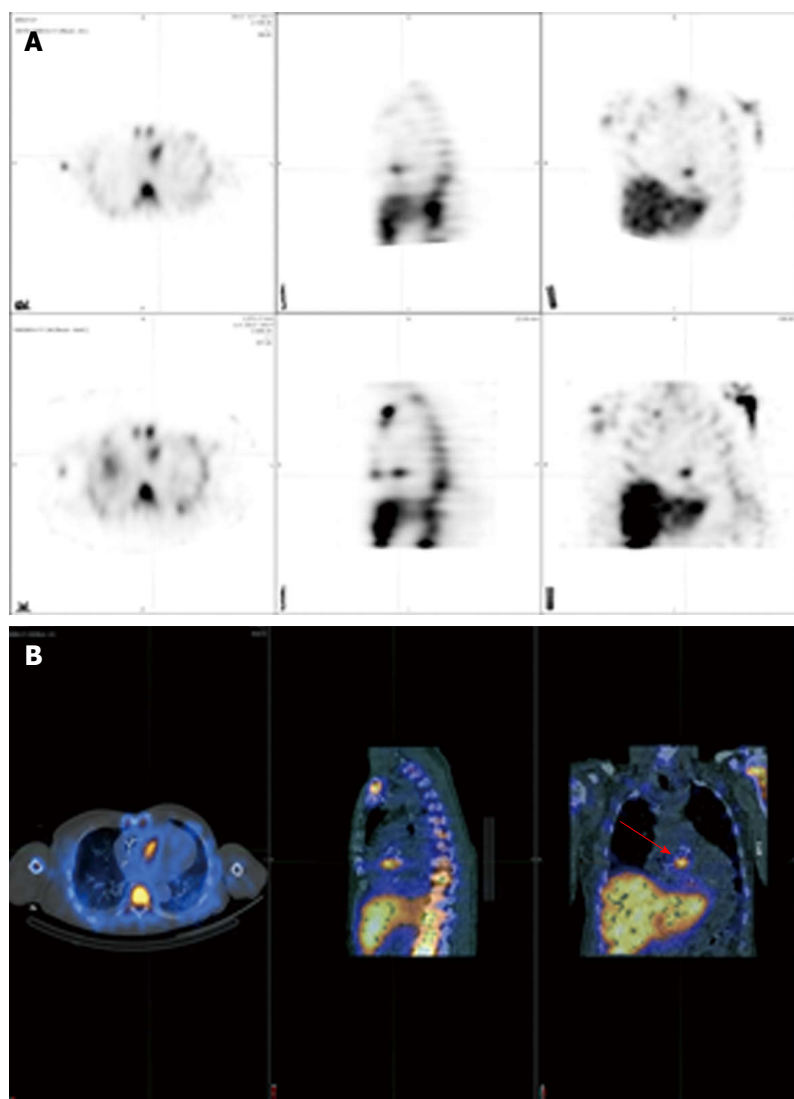
$^{18}\text{F}$ -FDG PET/CT can reduce the rate of misdiagnosed IE and help in the detection of peripheral events, including silent vascular phenomenon.  $^{18}\text{F}$ -FDG PET/CT can identify lesions of clinical importance not detected by conventional work-up in one out of seven IE patients<sup>[33]</sup>. It also improves the sensitivity of the modified Duke criteria in the most difficult situations. When endocarditis on a prosthetic valve is suspected, abnormal uptake around the site of insertion identified by  $^{18}\text{F}$ -FDG PET/CT (but more than 3 mo after prosthesis implantation) or radiolabelled WBC SPECT/CT could be considered a major diagnostic criterion. Results of  $^{18}\text{F}$ -FDG PET/CT should always be examined together with the other

conventional diagnostic tools (clinical, microbiological and echocardiographic data). In addition,  $^{18}\text{F}$ -FDG PET/CT can be considered to monitor response to antibiotic therapy.

#### **Studies using WBC SPECT/CT**

Erba *et al.*<sup>[34]</sup> assessed in another study the value of  $^{99\text{m}}\text{Tc}$ -HMPAO leukocyte scintigraphy in 131 patients with suspected endocarditis. In these patients, 51 had a confirmed diagnosis of IE and 35 had PVE (69%). Scintigraphy had a sensitivity of 90% and a specificity of 100%. No false-positive cases were seen, including patients evaluated for IE during the first two months after their surgery. However, false-negative studies were seen with *Candida* and *Enterococcus* endocarditis. It also identified cases of septic embolism. The test could be useful in patients with a high suspicion of IE but inconclusive TEE, in differentiating between infective and sterile vegetations identified with echocardiography, when other tests are contradictory, and to exclude valve involvement in patients with sepsis and prosthetic valve. In another study, Hyafil *et al.*<sup>[35]</sup> looked at the role of radiolabelled leukocyte imaging in patients with





**Figure 5** Positive  $^{111}\text{In}$  white blood cell single-photon emission computed tomography/computed tomography in a patient with endocarditis following an aortic valve replacement (red arrow). A: SPECT displayed as transverse, sagittal, and coronal attenuation corrected (top row) and uncorrected images (bottom row); B: Hybrid SPECT/CT displayed as transverse, sagittal, and coronal images. SPECT/CT: Single-photon emission computed tomography/computed tomography.

presumed PVE and unconvincing echocardiography. They showed an excellent positive predictive value of intense signal with WBC scintigraphy for the presence of an abscess. Also, a negative scan predicted the absence of recurrent endocarditis in medically treated patients. Downsides of radiolabelled leukocyte scintigraphy are the necessity of blood handling, a longer procedure time, and a somewhat lower spatial resolution in contrast to  $^{18}\text{F}$ -FDG PET/CT.

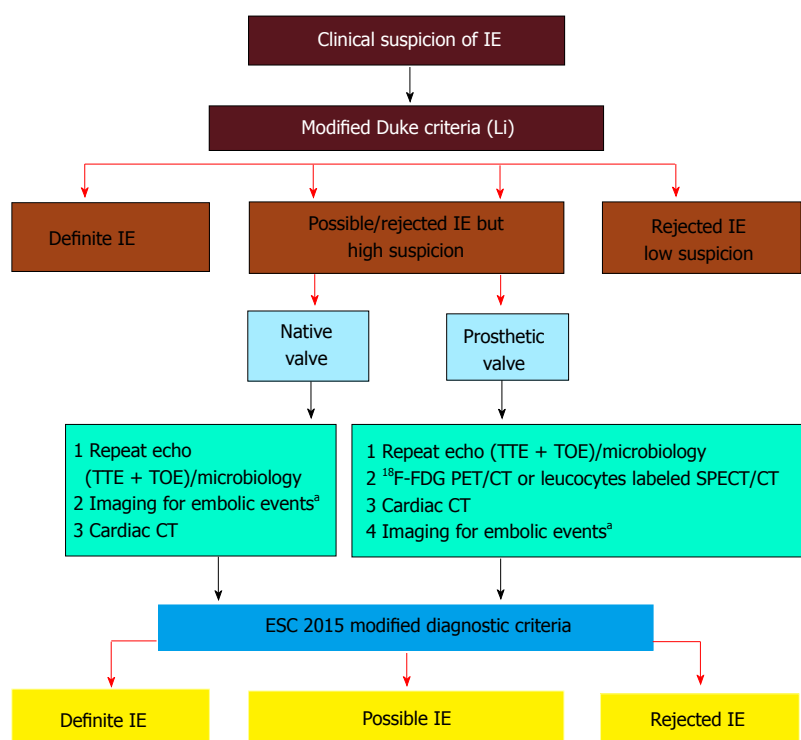
Figure 5 shows a positive  $^{111}\text{In}$  WBC SPECT/CT in a patient with endocarditis following an aortic valve replacement.

Table 2 shows the sensitivity and specificity of both  $^{18}\text{F}$ -FDG PET/CT and WBC SPECT/CT in the diagnosis of CIED infection and PVE.

## LIMITATIONS

Despite its benefits,  $^{18}\text{F}$ -FDG PET/CT can have false-positive and false-negative results. Postoperative inflammatory changes can lead to non-specific  $^{18}\text{F}$ -FDG uptakes during the first several weeks after surgery, mainly following cardiac surgery or device implantation.

Abnormal  $^{18}\text{F}$ -FDG uptake could also be caused by BioGlue surgical adhesive, a combination of bovine serum albumin and glutaraldehyde, used to seal the aortic root graft at time of surgery<sup>[36]</sup>. In addition, possible uptakes can be found in active thrombi, cardiac tumours or metastasis, post-surgical inflammation, and foreign body reactions like vascular grafts. At the other end of the spectrum,  $^{18}\text{F}$ -FDG PET/CT might be negative in patients with lower inflammation or when the test is performed after a long period of antibiotic therapy. The validity of  $^{18}\text{F}$ -FDG PET/CT in the context of slowly evolving infections is still unknown. Because of the high glucose metabolism in the brain,  $^{18}\text{F}$ -FDG PET/CT might not be the best test in order to detect infectious embolisms to the brain. However, an advantage of  $^{18}\text{F}$ -FDG PET/CT is the possibility to identify non-infectious causes of fever or underlying neoplasm. As opposed to echocardiography, cardiac nuclear imaging does not evaluate hemodynamic conditions associated with IE, such as valvular regurgitation, cardiac output, pulmonary arterial pressure and ventricular function. Another important issue remains that  $^{18}\text{F}$ -FDG PET/CT is less accessible than WBC SPECT/CT. The study quality



**Figure 6** European Society of Cardiology 2015 algorithm for diagnosis of infective endocarditis. Reprinted from Habib G, Lancellotti P, Antunes MJ, Bongiorni MG, Casalta JP, Del Zotti F, Dulgheru R, El Khoury G, Erba PA, Iung B, Miro JM, Mulder BJ, Plonska-Gosciniak E, Price S, Roos-Hesselink J, Snygg-Martin U, Thuny F, Tornos Mas P, Vilacosta I, Zamorano JL; Document Reviewers, Erol Ç, Nihoyannopoulos P, Aboyans V, Agewall S, Athanassopoulos G, Aytekin S, Benzer W, Bueno H, Broekhuizen L, Carerj S, Cosyns B, De Backer J, De Bonis M, Dimopoulos K, Donal E, Drexel H, Flachskampf FA, Hall R, Halvorsen S, Hoen B, Kirchhof P, Lainscak M, Leite-Moreira AF, Lip GY, Mestres CA, Piepoli MF, Punjabi PP, Rapezzi C, Rosenhek R, Siebens K, Tamargo J, Walker DM. 2015 ESC Guidelines for the management of infective endocarditis: The Task Force for the Management of Infective Endocarditis of the European Society of Cardiology (ESC). Endorsed by: European Association for Cardio-Thoracic Surgery, the European Association of Nuclear Medicine. *Eur Heart J* 2015; 36: 3075-3128. Reprinted by permission of Oxford University Press (UK)© European Society of Cardiology, [www.escardio.org/](http://www.escardio.org/). This image/content is not covered by the terms of the Creative Commons license of this publication. For permission to reuse, please contact the rights holder). <sup>a</sup>May include cerebral MRI, whole body CT, and/or PET/CT; CT: Computed tomography; FDG: Fluorodeoxyglucose IE: Infective endocarditis; PET: Positron emission tomography; SPECT: Single-photon emission computed tomography; TTE: Transthoracic echocardiography; <sup>18</sup>F-FDG PET/CT: <sup>18</sup>F-fluorodeoxyglucose positron emission tomography/computed tomography.

could be improved by using respiratory and ECG gated techniques. This could minimize imaging artefacts, although it is technically more challenging and time-consuming. Cardiac nuclear imaging is a source of radiation. Administration of approximately 200 MBq of <sup>18</sup>F-FDG for a PET study represents an effective dose between 3 and 4 mSv, which is similar to a low-dose CT. Then the total dose for a PET/CT would be approximately 7.5 mSv<sup>[37]</sup>. A follow-up study to monitor response to antibiotic therapy would increase radiation exposure. However, an initial PET scan combined to a low-dose CT and followed by a subsequent study would be equivalent to a percutaneous coronary intervention or an atrial fibrillation ablation procedure (approximately 15 mSv)<sup>[38]</sup>.

## GUIDELINES

The ESC guidelines for the management of infectious endocarditis were updated in 2015<sup>[1]</sup>. The Task Force added <sup>18</sup>F-FDG PET/CT or radiolabelled WBC SPECT/CT as a new major criterion if abnormal FDG uptakes are found around the area of prosthetic valve implantation in patients with a prosthesis implanted for more than

3 mo<sup>[1]</sup>. Nuclear imaging has also been incorporated in the new algorithm for the diagnosis of IE when the diagnosis is still possible or has been dismissed but when a high index of suspicion is still present (Figure 6). However, despite data for the key role of <sup>18</sup>F-FDG PET/CT in the diagnosis of CIED infection, actual studies were judged insufficient to incorporate the results of <sup>18</sup>F-FDG PET/CT at this time as a diagnostic criterion for device infection. For the moment, <sup>18</sup>F-FDG PET/CT or radiolabelled leukocyte scintigraphy have a class IIb level of evidence C indication as an additional tool in patients with suspected CIED infection, positive blood cultures and negative echocardiography<sup>[1]</sup>. Also, the AHA scientific statement on IE judged that more clinical trials are still required to better clarify the utility of <sup>18</sup>F-FDG PET/CT for the diagnosis and management of endocarditis<sup>[9]</sup>. Since most studies on cardiac radionuclide imaging have been published in the past 5 years, the use of <sup>18</sup>F-FDG PET/CT in device infection was not discussed in the 2010 AHA scientific statement on CIED infections and their management<sup>[21]</sup>.

Based on the recent ESC guidelines and previous studies, cardiac nuclear imaging could be considered in the following circumstances (Table 3): (1) accepted

**Table 2** Sensibility and specificity of  $^{18}\text{F}$ -fluorodeoxyglucose positron emission tomography/computed tomography and white blood cell single-photon emission computed tomography/computed tomography for both prosthetic valve endocarditis and cardiac device infection

	Test	Sensi- bility (%)	Speci- ficity (%)	Positive predictive value (%)	Negative predictive value (%)	Accuracy (%)
Prosthetic valve endocarditis						
Saby <i>et al</i> <sup>[31]</sup>	PET/CT	73	80	85	67	76
Rouzet <i>et al</i> <sup>[32]</sup>	PET/CT	93	71	68	94	80
	WBC	64	100	100	81	86
Erba <i>et al</i> <sup>[34]</sup>	WBC	90	100	100	94	N/A
Cardiovascular implantable electronic device infection						
Bensimhon <i>et al</i> <sup>[24]</sup>	PET/CT	80	100	100	84.6	N/A
	Pocket	100	100	100	100	N/A
	Lead	60	100	100	73	N/A
Ploux <i>et al</i> <sup>[25]</sup>	PET/CT	100	93	N/A	N/A	N/A
Sarrazin <i>et al</i> <sup>[26]</sup>	PET/CT	88.6	85.7	N/A	N/A	N/A
Cautela <i>et al</i> <sup>[27]</sup>	PET/CT					
	Pocket	86.7	100	N/A	N/A	N/A
	Lead	30.8	62.5	N/A	N/A	N/A
Ahmed <i>et al</i> <sup>[28]</sup>	PET/CT					
	Pocket	97	98	N/A	N/A	N/A
Erba <i>et al</i> <sup>[29]</sup>	WBC	93.7	100	100	93.9	96.8

N/A: Not available; PET/CT: Positron emission tomography/computed tomography; WBC: White blood cell.

indication<sup>[11]</sup>: Possible or rejected IE diagnosis based on the modified Duke criteria, but persistent high clinical suspicion of infection in patients with a prosthetic valve; and (2) potential indications: Unclear diagnosis of CIED infection; Evaluation of the extent of infection when the results would affect the management of the patient, for example differentiation between superficial and deep pocket infection where device and lead extraction is recommended; Bacteremia with organisms not commonly a source of IE or fever of unknown origin in patients with CIED; High clinical suspicion of IE but negative TEE and/or negative blood cultures; Search for embolic events when it would affect the management of the patient; Monitoring the success of antibiotic therapy in medically treated patients.

## FUTURE STUDIES

So far, available data on the diagnosis of CIED infection and PVE with either  $^{18}\text{F}$ -FDG PET/CT or WBC SPECT/CT come from small studies and limited number of patients. Larger studies would be useful to confirm the preliminary data suggesting the additional benefit of cardiac nuclear imaging. Despite encouraging results, some questions need to be answered. Is the use of  $^{18}\text{F}$ -FDG PET/CT cost-effective? Also, what is the consequence of prolonged antibiotic therapy prior to  $^{18}\text{F}$ -FDG PET/CT? There is also a need for standardization of the imaging techniques available since the imaging and data acquisition protocols are sometimes different from one center to another. There is still a need for further prospective studies in this

**Table 3** Indications for the use of cardiac nuclear imaging in the context of cardiovascular implantable electronic device infection and prosthetic valve endocarditis

Accepted indication
Possible or rejected IE, but high suspicion of infection in patients with prosthetic valve
Potential indications
Unclear diagnosis of CIED infection
Evaluation of the extent of infection
Bacteremia or fever of unknown origin in patients with CIED
Cases with high clinical suspicion of IE but negative TEE and/or negative blood cultures
Search for embolic events
Monitoring the success of antibiotic therapy

CIED: Cardiovascular implantable electronic device; IE: Infective endocarditis; TEE: Transesophageal echocardiography.

field of research before  $^{18}\text{F}$ -FDG PET/CT should be systematically performed for the diagnosis of IE or used as a first line investigation. At the moment, it should be restricted to difficult cases of suspected CIED infection or PVE.

## CONCLUSION

$^{18}\text{F}$ -FDG PET/CT appears to be a very promising imaging technique for the diagnosis of device infection and prosthetic valve endocarditis. Based on recent publications, there is growing evidence that cardiac nuclear imaging can play a key role in the diagnosis and management of patients with suspected CIED infections and PVE. This is now reflected in the most recent published guidelines. Although echocardiography remains an important initial test in the evaluation of these patients,  $^{18}\text{F}$ -FDG PET/CT and WBC SPECT/CT have clearly demonstrated their usefulness, mainly in difficult cases. Larger prospective studies will help to confirm the benefits of  $^{18}\text{F}$ -FDG PET/CT and clarify its role in the different algorithms of device and valve infections.

## REFERENCES

- Habib G**, Lancellotti P, Antunes MJ, Bongiorno MG, Casalta JP, Del Zotti F, Dulgheru R, El Khoury G, Erba PA, Iung B, Miro JM, Mulder BJ, Plonska-Gosciniak E, Price S, Roos-Hesselink J, Snygg-Martin U, Thuny F, Tornos Mas P, Vilacosta I, Zamorano JL, Erol C, Nihoyannopoulos P, Aboyans V, Agewall S, Athanassopoulos G, Aytekin S, Benzer W, Bueno H, Broekhuizen L, Carerj S, Cosyns B, De Backer J, De Bonis M, Dimopoulos K, Donal E, Drexel H, Flachskampf FA, Hall R, Halvorsen S, Hoen B, Kirchhof P, Lainscak M, Leite-Moreira AF, Lip GY, Mestres CA, Piepoli MF, Punjabi PP, Rapezzi C, Rosenhek R, Siebens K, Tamargo J, Walker DM. 2015 ESC Guidelines for the management of infective endocarditis: The Task Force for the Management of Infective Endocarditis of the European Society of Cardiology (ESC). Endorsed by: European Association for Cardio-Thoracic Surgery (EACTS), the European Association of Nuclear Medicine (EANM). *Eur Heart J* 2015; **36**: 3075-3128 [PMID: 26320109 DOI: 10.1093/eurheartj/ehv319]
- Li JS**, Sexton DJ, Mick N, Nettles R, Fowler VG, Ryan T, Bashore T, Corey GR. Proposed modifications to the Duke criteria for the diagnosis of infective endocarditis. *Clin Infect Dis* 2000; **30**:

- 633-638 [PMID: 10770721 DOI: 10.1086/313753]
- 3 **Prendergast BD.** Diagnostic criteria and problems in infective endocarditis. *Heart* 2004; **90**: 611-613 [PMID: 15145855 DOI: 10.1136/hrt.2003.029850]
- 4 **Habib G,** Derumeaux G, Avierinos JF, Casalta JP, Jamal F, Volot F, Garcia M, Lefevre J, Biou F, Maximovitch-Rodaminoff A, Fournier PE, Ambrosi P, Velut JG, Cribier A, Harle JR, Weiller PJ, Raoult D, Luccioni R. Value and limitations of the Duke criteria for the diagnosis of infective endocarditis. *J Am Coll Cardiol* 1999; **33**: 2023-2029 [PMID: 10362209 DOI: 10.1016/S0735-1097(99)00116-3]
- 5 **Thuny F,** Grisoli D, Cautela J, Riberi A, Raoult D, Habib G. Infective endocarditis: prevention, diagnosis, and management. *Can J Cardiol* 2014; **30**: 1046-1057 [PMID: 25151287 DOI: 10.1016/j.cjca.2014.03.042]
- 6 **Vilacosta I,** Graupner C, San Román JA, Sarriá C, Ronderos R, Fernández C, Mancini L, Sanz O, Sanmartín JV, Stoermann W. Risk of embolization after institution of antibiotic therapy for infective endocarditis. *J Am Coll Cardiol* 2002; **39**: 1489-1495 [PMID: 11985912 DOI: 10.1016/S0735-1097(02)01790-4]
- 7 **Botelho-Nevers E,** Thuny F, Casalta JP, Richet H, Gouret F, Collart F, Riberi A, Habib G, Raoult D. Dramatic reduction in infective endocarditis-related mortality with a management-based approach. *Arch Intern Med* 2009; **169**: 1290-1298 [PMID: 19636030 DOI: 10.1001/archinternmed.2009.192]
- 8 **Habib G,** Badano L, Tribouilloy C, Vilacosta I, Zamorano JL, Galderisi M, Voigt JU, Sicari R, Cosyns B, Fox K, Aakhus S. Recommendations for the practice of echocardiography in infective endocarditis. *Eur J Echocardiogr* 2010; **11**: 202-219 [PMID: 20223755 DOI: 10.1093/ejehocardiography/jeq004]
- 9 **Baddour LM,** Wilson WR, Bayer AS, Fowler VG, Tleyjeh IM, Rybak MJ, Barsic B, Lockhart PB, Gewitz MH, Levison ME, Bolger AF, Steckelberg JM, Baltimore RS, Fink AM, O'Gara P, Taubert KA. Infective Endocarditis in Adults: Diagnosis, Antimicrobial Therapy, and Management of Complications: A Scientific Statement for Healthcare Professionals From the American Heart Association. *Circulation* 2015; **132**: 1435-1486 [PMID: 26373316 DOI: 10.1161/CIR.0000000000000296]
- 10 **Gamelli RL,** Liu H, He LK, Hofmann CA. Augmentations of glucose uptake and glucose transporter-1 in macrophages following thermal injury and sepsis in mice. *J Leukoc Biol* 1996; **59**: 639-647 [PMID: 8656048]
- 11 **Fukuzumi M,** Shinomiya H, Shimizu Y, Ohishi K, Utsumi S. Endotoxin-induced enhancement of glucose influx into murine peritoneal macrophages via GLUT1. *Infect Immun* 1996; **64**: 108-112 [PMID: 8557327]
- 12 **Mochizuki T,** Tsukamoto E, Kuge Y, Kanegae K, Zhao S, Hikosaka K, Hosokawa M, Kohanawa M, Tamaki N. FDG uptake and glucose transporter subtype expressions in experimental tumor and inflammation models. *J Nucl Med* 2001; **42**: 1551-1555 [PMID: 11585872]
- 13 **Kubota R,** Yamada S, Kubota K, Ishiwata K, Tamahashi N, Ido T. Intratumoral distribution of fluorine-18-fluorodeoxyglucose in vivo: high accumulation in macrophages and granulation tissues studied by microautoradiography. *J Nucl Med* 1992; **33**: 1972-1980 [PMID: 1432158]
- 14 **Yamada S,** Kubota K, Kubota R, Ido T, Tamahashi N. High accumulation of fluorine-18-fluorodeoxyglucose in turpentine-induced inflammatory tissue. *J Nucl Med* 1995; **36**: 1301-1306 [PMID: 7790960]
- 15 **Coulden R,** Chung P, Sonnex E, Ibrahim Q, Maguire C, Abele J. Suppression of myocardial 18F-FDG uptake with a preparatory "Atkins-style" low-carbohydrate diet. *Eur Radiol* 2012; **22**: 2221-2228 [PMID: 22592807 DOI: 10.1007/s00330-012-2478-2]
- 16 **Persson E.** Lipoprotein lipase, hepatic lipase and plasma lipolytic activity. Effects of heparin and a low molecular weight heparin fragment (Fragmin). *Acta Med Scand Suppl* 1988; **724**: 1-56 [PMID: 2843005 DOI: 10.1111/j.1748-1716.1988.tb08452.x]
- 17 **Ahmed FZ,** James J, Memmott MJ, Arumugam P. Radionuclide Imaging of Cardiovascular Infection. *Cardiol Clin* 2016; **34**: 149-165 [PMID: 26590786 DOI: 10.1016/j.ccl.2015.06.004]
- 18 **de Vries EF,** Roca M, Jamar F, Israel O, Signore A. Guidelines for the labelling of leucocytes with (99m)Tc-HMPAO. Inflammation/Infection Taskgroup of the European Association of Nuclear Medicine. *Eur J Nucl Med Mol Imaging* 2010; **37**: 842-848 [PMID: 20198473 DOI: 10.1007/s00259-010-1394-4]
- 19 **Voigt A,** Shalaby A, Saba S. Rising rates of cardiac rhythm management device infections in the United States: 1996 through 2003. *J Am Coll Cardiol* 2006; **48**: 590-591 [PMID: 16875991 DOI: 10.1016/j.jacc.2006.05.016]
- 20 **Greenspon AJ,** Patel JD, Lau E, Ochoa JA, Frisch DR, Ho RT, Pavri BB, Kurtz SM. 16-year trends in the infection burden for pacemakers and implantable cardioverter-defibrillators in the United States 1993 to 2008. *J Am Coll Cardiol* 2011; **58**: 1001-1006 [PMID: 21867833 DOI: 10.1016/j.jacc.2011.04.033]
- 21 **Baddour LM,** Epstein AE, Erickson CC, Knight BP, Levison ME, Lockhart PB, Masoudi FA, Okum EJ, Wilson WR, Beerman LB, Bolger AF, Estes NA, Gewitz M, Newburger JW, Schron EB, Taubert KA. Update on cardiovascular implantable electronic device infections and their management: a scientific statement from the American Heart Association. *Circulation* 2010; **121**: 458-477 [PMID: 20048212 DOI: 10.1161/CIRCULATIONAHA.109.192665]
- 22 **Dundar C,** Tigen K, Tanalp C, Izgi A, Karaahmet T, Cevik C, Erkol A, Oduncu V, Kirma C. The prevalence of echocardiographic accretions on the leads of patients with permanent pacemakers. *J Am Soc Echocardiogr* 2011; **24**: 803-807 [PMID: 21493040 DOI: 10.1016/j.echo.2011.03.001]
- 23 **Vos FJ,** Bleeker-Rovers CP, van Dijk AP, Oyen WJ. Detection of pacemaker and lead infection with FDG-PET. *Eur J Nucl Med Mol Imaging* 2006; **33**: 1245 [PMID: 16826378]
- 24 **Bensimhon L,** Lavergne T, Hugonnet F, Mainardi JL, Latremouille C, Maunoury C, Lepillier A, Le Heuzey JY, Faraggi M. Whole body [(18)F]fluorodeoxyglucose positron emission tomography imaging for the diagnosis of pacemaker or implantable cardioverter defibrillator infection: a preliminary prospective study. *Clin Microbiol Infect* 2011; **17**: 836-844 [PMID: 20636421 DOI: 10.1111/j.1469-0691.2010.03312.x]
- 25 **Ploux S,** Riviere A, Amraoui S, Whinnett Z, Barandon L, Lafitte S, Ritter P, Papaioannou G, Clementy J, Jais P, Bordenave L, Haissaguerre M, Bordachar P. Positron emission tomography in patients with suspected pacing system infections may play a critical role in difficult cases. *Heart Rhythm* 2011; **8**: 1478-1481 [PMID: 21463705 DOI: 10.1016/j.hrthm.2011.03.062]
- 26 **Sarrazin JF,** Philippon F, Tessier M, Guimond J, Molin F, Champagne J, Nault I, Blier L, Nadeau M, Charbonneau L, Trottier M, O'Hara G. Usefulness of fluorine-18 positron emission tomography/computed tomography for identification of cardiovascular implantable electronic device infections. *J Am Coll Cardiol* 2012; **59**: 1616-1625 [PMID: 22538331 DOI: 10.1016/j.jacc.2011.11.059]
- 27 **Cautela J,** Alessandrini S, Cammilleri S, Giorgi R, Richet H, Casalta JP, Habib G, Raoult D, Mundler O, Deharo JC. Diagnostic yield of FDG positron-emission tomography/computed tomography in patients with CEID infection: a pilot study. *Europace* 2013; **15**: 252-257 [PMID: 23148119 DOI: 10.1093/europace/eus335]
- 28 **Ahmed FZ,** James J, Cunningham C, Motwani M, Fullwood C, Hooper J, Burns P, Qamruddin A, Al-Bahrani G, Armstrong I, Tout D, Clarke B, Sandoe JA, Arumugam P, Mamas MA, Zaidi AM. Early diagnosis of cardiac implantable electronic device generator pocket infection using <sup>18</sup>F-FDG-PET/CT. *Eur Heart J Cardiovasc Imaging* 2015; **16**: 521-530 [PMID: 25651856 DOI: 10.1093/ehjci/jeu295]
- 29 **Erba PA,** Sollini M, Conti U, Bandera F, Tascini C, De Tommasi SM, Zucchelli G, Doria R, Menichetti F, Bongioni MG, Lazzeri E, Mariani G. Radiolabeled WBC scintigraphy in the diagnostic workup of patients with suspected device-related infections. *JACC Cardiovasc Imaging* 2013; **6**: 1075-1086 [PMID: 24011775 DOI: 10.1016/j.jcmg.2013.08.001]
- 30 **Plank F,** Mueller S, Uprimny C, Hangler H, Feuchtnner G. Detection of bioprosthetic valve infection by image fusion of (18)fluorodeoxyglucose-positron emission tomography and



- computed tomography. *Interact Cardiovasc Thorac Surg* 2012; **14**: 364-366 [PMID: 22180605 DOI: 10.1093/icvts/ivr107]
- 31 **Saby L**, Laas O, Habib G, Cammilleri S, Mancini J, Tessonnier L, Casalta JP, Gouriet F, Riberi A, Avierinos JF, Collart F, Mundler O, Raoult D, Thuny F. Positron emission tomography/computed tomography for diagnosis of prosthetic valve endocarditis: increased valvular 18F-fluorodeoxyglucose uptake as a novel major criterion. *J Am Coll Cardiol* 2013; **61**: 2374-2382 [PMID: 23583251 DOI: 10.1016/j.jacc.2013.01.092]
  - 32 **Rouzet F**, Chequer R, Benali K, Lepage L, Ghodbane W, Duval X, Iung B, Vahanian A, Le Guludec D, Hyafil F. Respective performance of 18F-FDG PET and radiolabeled leukocyte scintigraphy for the diagnosis of prosthetic valve endocarditis. *J Nucl Med* 2014; **55**: 1980-1985 [PMID: 25453046 DOI: 10.2967/jnumed.114.141895]
  - 33 **Asmar A**, Ozcan C, Diederichsen AC, Thomassen A, Gill S. Clinical impact of 18F-FDG-PET/CT in the extra cardiac work-up of patients with infective endocarditis. *Eur Heart J Cardiovasc Imaging* 2014; **15**: 1013-1019 [PMID: 24711514 DOI: 10.1093/ehjci/jeu054]
  - 34 **Erba PA**, Conti U, Lazzeri E, Sollini M, Doria R, De Tommasi SM, Bandera F, Tascini C, Menichetti F, Dierckx RA, Signore A, Mariani G. Added value of 99mTc-HMPAO-labeled leukocyte SPECT/CT in the characterization and management of patients with infectious endocarditis. *J Nucl Med* 2012; **53**: 1235-1243 [PMID: 22787109 DOI: 10.2967/jnumed.111.099424]
  - 35 **Hyafil F**, Rouzet F, Lepage L, Benali K, Raffoul R, Duval X, Hvass U, Iung B, Nataf P, Lebtahi R, Vahanian A, Le Guludec D. Role of radiolabelled leucocyte scintigraphy in patients with a suspicion of prosthetic valve endocarditis and inconclusive echocardiography. *Eur Heart J Cardiovasc Imaging* 2013; **14**: 586-594 [PMID: 23456094 DOI: 10.1093/ehjci/jet029]
  - 36 **Schouten LR**, Verberne HJ, Bouma BJ, van Eck-Smit BL, Mulder BJ. Surgical glue for repair of the aortic root as a possible explanation for increased F-18 FDG uptake. *J Nucl Cardiol* 2008; **15**: 146-147 [PMID: 18242493]
  - 37 **Xia T**, Alessio AM, De Man B, Manjeshwar R, Asma E, Kinahan PE. Ultra-low dose CT attenuation correction for PET/CT. *Phys Med Biol* 2012; **57**: 309-328 [PMID: 22156174 DOI: 10.1088/0031-9155/57/2/309]
  - 38 **Picano E**, Vañó E, Rehani MM, Cuocolo A, Mont L, Bodi V, Bar O, Maccia C, Pierard L, Sicari R, Plein S, Mahrholdt H, Lancellotti P, Knuuti J, Heidbuchel H, Di Mario C, Badano LP. The appropriate and justified use of medical radiation in cardiovascular imaging: a position document of the ESC Associations of Cardiovascular Imaging, Percutaneous Cardiovascular Interventions and Electrophysiology. *Eur Heart J* 2014; **35**: 665-672 [PMID: 24401558 DOI: 10.1093/eurheartj/eh394]

**P- Reviewer:** Falconi M, Peteiro J, Said SAM **S- Editor:** Gong XM  
**L- Editor:** A **E- Editor:** Wu HL





Published by **Baishideng Publishing Group Inc**

8226 Regency Drive, Pleasanton, CA 94588, USA

Telephone: +1-925-223-8242

Fax: +1-925-223-8243

E-mail: [bpgoffice@wjgnet.com](mailto:bpgoffice@wjgnet.com)

Help Desk: <http://www.wjgnet.com/esps/helpdesk.aspx>

<http://www.wjgnet.com>

