

World Journal of *Cardiology*

World J Cardiol 2017 June 26; 9(6): 470-561



**REVIEW**

- 470** Cardiac damage in athlete's heart: When the "supernormal" heart fails!
Carbone A, D'Andrea A, Riegler L, Scarafile R, Pezzullo E, Martone F, America R, Liccardo B, Galderisi M, Bossone E, Calabrò R
- 481** Assessment of aortic valve disease - a clinician oriented review
Mărgulescu AD
- 496** Atrial tachyarrhythmia in adult congenital heart disease
Karbassi A, Nair K, Harris L, Wald RM, Roche SL
- 508** Influence of cardiac nerve status on cardiovascular regulation and cardioprotection
Kingma JG, Simard D, Rouleau JR

MINIREVIEWS

- 521** Management of ventricular tachycardia storm in patients with structural heart disease
Muser D, Santangeli P, Liang JJ
- 531** Wearable cardioverter defibrillator: Bridge or alternative to implantation?
Barraud J, Cautela J, Orabona M, Pinto J, Missenard O, Laine M, Thuny F, Paganelli F, Bonello L, Peyrol M

ORIGINAL ARTICLE**Clinical Trials Study**

- 539** Catheter ablation of atrial fibrillation facilitated by preprocedural three-dimensional transesophageal echocardiography: Long-term outcome
Kettering K, Gramley F, von Bardeleben S

Observational Study

- 547** Entirely subcutaneous defibrillator and complex congenital heart disease: Data on long-term clinical follow-up
Ferrero P, Ali H, Barman P, Foresti S, Lupo P, D'Elia E, Cappato R, Stuart AG

SYSTEMATIC REVIEWS

- 553** Interferon related pericarditis: Review
Nishio K, Arase T, Tada H, Tachibana H

CASE REPORT**558** Inadvertent cardiac phlebography*Aznaouridis K, Masoura C, Kastellanos S, Alahmar A*

ABOUT COVER

Editorial Board Member of *World Journal of Cardiology*, Dr. Joaquin De Haro, MD, PhD, Professor, Staff Physician, Surgeon, Angiology and Vascular Surgery Department, Hospital Universitario Getafe, 28905 Madrid, Spain

AIM AND SCOPE

World Journal of Cardiology (*World J Cardiol*, *WJC*, online ISSN 1949-8462, DOI: 10.4330) is a peer-reviewed open access journal that aims to guide clinical practice and improve diagnostic and therapeutic skills of clinicians.

WJC covers topics concerning arrhythmia, heart failure, vascular disease, stroke, hypertension, prevention and epidemiology, dyslipidemia and metabolic disorders, cardiac imaging, pediatrics, nursing, and health promotion. Priority publication will be given to articles concerning diagnosis and treatment of cardiology diseases. The following aspects are covered: Clinical diagnosis, laboratory diagnosis, differential diagnosis, imaging tests, pathological diagnosis, molecular biological diagnosis, immunological diagnosis, genetic diagnosis, functional diagnostics, and physical diagnosis; and comprehensive therapy, drug therapy, surgical therapy, interventional treatment, minimally invasive therapy, and robot-assisted therapy.

We encourage authors to submit their manuscripts to *WJC*. We will give priority to manuscripts that are supported by major national and international foundations and those that are of great basic and clinical significance.

INDEXING/ABSTRACTING

World Journal of Cardiology is now indexed in Emerging Sources Citation Index (Web of Science), PubMed, and PubMed Central.

FLYLEAF

I-IV Editorial Board

EDITORS FOR THIS ISSUE

Responsible Assistant Editor: *Xiang Li*
Responsible Electronic Editor: *Dan Li*
Proofing Editor-in-Chief: *Lian-Sheng Ma*

Responsible Science Editor: *Fang-Fang Ji*
Proofing Editorial Office Director: *Jin-Lei Wang*

NAME OF JOURNAL
World Journal of Cardiology

ISSN
ISSN 1949-8462 (online)

LAUNCH DATE
December 31, 2009

FREQUENCY
Monthly

EDITORS-IN-CHIEF
Jian-Jun Li, MD, PhD, Professor, Center for Coronary Artery Disease, Fu Wai Cardiovascular Hospital, Chinese Academy of Medical Science, Beijing 100037, China

Giuseppe De Luca, PhD, Assistant Professor, Department of Cardiology, Piedmont University, Novara 28100, Italy

Nathan D Wong, FACC, FAHA, PhD, Director, Professor, Heart Disease Prevention Program, Division of Cardiology, Department of Medicine, University of California, Irvine, CA 92629, United States

sity of California, Irvine, CA 92629, United States

EDITORIAL BOARD MEMBERS
All editorial board members resources online at <http://www.wjgnet.com/1949-8462/editorialboard.htm>

EDITORIAL OFFICE
Xiu-Xia Song, Director
World Journal of Cardiology
Baishideng Publishing Group Inc
7901 Stoneridge Drive, Suite 501, Pleasanton, CA 94588, USA
Telephone: +1-925-2238242
Fax: +1-925-2238243
E-mail: editorialoffice@wjgnet.com
Help Desk: <http://www.f6publishing.com/helpdesk>
<http://www.wjgnet.com>

PUBLISHER
Baishideng Publishing Group Inc
7901 Stoneridge Drive, Suite 501, Pleasanton, CA 94588, USA
Telephone: +1-925-2238242
Fax: +1-925-2238243
E-mail: bpgoffice@wjgnet.com
Help Desk: <http://www.f6publishing.com/helpdesk>
<http://www.wjgnet.com>

PUBLICATION DATE
June 26, 2017

COPYRIGHT
© 2017 Baishideng Publishing Group Inc. Articles published by this Open-Access journal are distributed under the terms of the Creative Commons Attribution Non-commercial License, which permits use, distribution, and reproduction in any medium, provided the original work is properly cited, the use is non commercial and is otherwise in compliance with the license.

SPECIAL STATEMENT
All articles published in journals owned by the Baishideng Publishing Group (BPG) represent the views and opinions of their authors, and not the views, opinions or policies of the BPG, except where otherwise explicitly indicated.

INSTRUCTIONS TO AUTHORS
<http://www.wjgnet.com/bpg/gerinfo/204>

ONLINE SUBMISSION
<http://www.f6publishing.com>

Interferon related pericarditis: Review

Kazuaki Nishio, Tsutomu Arase, Hiroko Tada, Hideaki Tachibana

Kazuaki Nishio, Tsutomu Arase, Hiroko Tada, Hideaki Tachibana, Department of Internal Medicine, Matsui Hospital, Tokyo 145-0082, Japan

Author contributions: Nishio K drafted the manuscript, and assisted with data analysis; Arase T, Tada H and Tachibana H were involved with data collection and data analysis.

Conflict-of-interest statement: The authors of this manuscript having no conflicts of interest to disclose.

Data sharing statement: There is no additional data available.

Open-Access: This article is an open-access article which was selected by an in-house editor and fully peer-reviewed by external reviewers. It is distributed in accordance with the Creative Commons Attribution Non Commercial (CC BY-NC 4.0) license, which permits others to distribute, remix, adapt, build upon this work non-commercially, and license their derivative works on different terms, provided the original work is properly cited and the use is non-commercial. See: <http://creativecommons.org/licenses/by-nc/4.0/>

Manuscript source: Invited manuscript

Correspondence to: Kazuaki Nishio, MD, Department of Internal Medicine, Matsui Hospital, 1-7-10, Ikegami, Ota-ku, Tokyo 145-0082, Japan. kazukun@jg7.so-net.ne.jp
Telephone: +81-3-37521111
Fax: +81-3-37521118

Received: November 11, 2016

Peer-review started: November 13, 2016

First decision: March 8, 2017

Revised: April 21, 2017

Accepted: May 3, 2017

Article in press: May 5, 2017

Published online: June 26, 2017

Abstract

AIM

To conduct a review of "interferon related pericarditis".

METHODS

We searched MEDLINE, EMBASE, Cinahl, and the Co-

chrane Database from the earliest available date through September 2016. A search strategy using the Medical Subject Headings and text keywords "interferon" and "pericarditis" were used.

RESULTS

Nine case reports were eligible for the present study. Six of 8 cases were women and the mean age was 43.8 ± 13.8 years with chronic hepatitis C in 6 cases, malignant melanoma in 2 cases and chronic myelogenous leukemia in 1 case. The patients complained of chest pain in 6 cases, dyspnea in 5 cases and edema in 2 cases. Pericardial friction rub was heard in 3 of 9 cases. Congestive heart failure occurred in 3 of 9 cases. Two mechanisms for pericarditis were demonstrated, one is autoimmune included lupus like syndrome in 2 cases and the other is cardio toxicity in 4 cases. Treatment of interferon related pericarditis is discontinuation of Interferon treatment. Four of 9 cases were treated with prednisone and 4 with nonsteroidal anti-inflammatory drugs.

CONCLUSION

Interferon related pericarditis still remains uncertain. Treatment of interferon related pericarditis rests mainly on early recognition and drug discontinuation. Interferon related pericarditis was treated with steroid and/or non-steroidal anti-inflammatory drugs.

Key words: Chronic hepatitis C; Chronic myelogeneous leukemia; Interferon; Malignant lymphoma; Pericarditis

© The Author(s) 2017. Published by Baishideng Publishing Group Inc. All rights reserved.

Core tip: Interferon is considered to be one of the treatments for many diseases. However, interferon therapy is associated with side effects. Recently some reports demonstrated acute pericarditis complicating interferon therapy. Two mechanisms for pericarditis were demonstrated, one is autoimmune included lupus like syndrome and the other is cardio toxicity. However, these two mechanisms are controversial. The aim of this study is to review of "interferon related pericarditis".

Nishio K, Arase T, Tada H, Tachibana H. Interferon related pericarditis: Review. *World J Cardiol* 2017; 9(6): 553-557 Available from: URL: <http://www.wjgnet.com/1949-8462/full/v9/i6/553.htm> DOI: <http://dx.doi.org/10.4330/wjc.v9.i6.553>

INTRODUCTION

Interferon is considered to be one of the treatments for many diseases. However, interferon therapy is associated with side effects, the most common being general symptoms such as fever, weight loss and headache. Some studies have demonstrated cardiac adverse effects of interferon for chronic hepatitis C (CHC)^[1,2]. Most frequently reported are arrhythmia, congestive heart failure and sudden death. Reported with rarer frequency are poly-neuropathy, paranoia and suicidal thoughts, diabetes mellitus, retinopathy, optical neuritis, diminution of hearing, seizures, loss of libido and cardio toxicity^[3]. Recently some reports demonstrated acute pericarditis complicating interferon therapy^[4-12]. We conducted a review of "interferon related pericarditis".

MATERIALS AND METHODS

Selection of case reports

We searched MEDLINE, EMBASE, Cinahl, and the Cochrane Database from the earliest available date through September 2016. A search strategy using the Medical Subject Headings and text keywords "interferon" and "pericarditis" were used. The retrieved studies were manually screened to assess their appropriateness for this study. All references cited in the studies were also reviewed to identify additional published articles not indexed in the database. The search was not restricted by language.

RESULTS

Patients

Nine case reports were eligible for the present study; seven were in English^[4,5,7,8,10-12] and two in French^[6,9]. Clinical characteristics of patients are shown in Table 1. Six of 8 cases were women and the mean age was 43.8 ± 13.8 years with CHC in 6 cases, malignant melanoma in 2 cases and chronic myelogenous leukemia in 1 case. The patients complained of chest pain in 6 cases, dyspnea in 5 cases and edema in 2 cases. Pericardial friction rub was heard in 3 of 9 cases^[5,8,9]. Congestive heart failure occurred in 3 of 9 cases^[8-10]. Two mechanisms for pericarditis were demonstrated, one is autoimmune included lupus like syndrome (AI group) in 2 cases and the other is cardio toxicity (CT group) in 4 cases. Three of 9 articles didn't mention the mechanisms for pericarditis.

Clinical history

Three cases had clinical history. The 28-year-old patient had allergic asthma since infancy^[4]. The 24-year-old woman following therapy with interferon α was diagnosed

with systemic lupus erythematosus (SLE), and she was treated with prednisone (40 mg/d)^[5]. When prednisone had been stopped completely for 3 mo, a pericarditis occurred. The patient had a recurrence of SLE. The 63-year-old man was diagnosed as diffuse large B cell non-Hodgkin's lymphoma and was treated with a full course of chemotherapy consisting of cyclophosphamide, adriamycin, vincristine and dexamethasone^[8].

Laboratory findings

The woman with SLE^[5] experienced four episodes of fever and pain in the left shoulder while breathing. Anti-nuclear antibody and anti-ds DNA antibody tests were negative, whereas circulating immune complexes were positive at the second and the third episode. CH50 and C4 levels were decreased with slightly elevated C3d level. Laboratory results of the 63-year-old man with non-Hodgkin's lymphoma presented antinuclear antibodies (titer 1/40)^[8]. The blood sample examination of the 67-year-old man with CHC showed anti-DNA antibody and anti-ds DNA IgM were positive^[10].

Interferon daily dose and duration of treatment with interferon

Figure 1 showed a relationship between the daily dose of interferon and the duration of treatment with interferon. Autoimmune due to interferon does not dependent on the daily dose but developed within one month with interferon treatment. Cardio toxicity due to interferon does not dependent on the daily dose or the duration of treatment with interferon.

Chest radiography

Chest radiography demonstrated abnormalities in three cases. Chest X-ray of the 63-year-old man showed an enlarged heart silhouette and bilateral pleural effusion^[8]. Chest radiograph of the 53-year-old woman showed cardiomegaly^[9]. Portable chest radiograph of the 67-year-old man revealed pulmonary vascular congestion without pleural effusion^[10].

Electrocardiogram

Electrocardiogram (ECG) demonstrated abnormality in one case. ECG showed gradual ST-segment elevation in leads V1 through V6 without elevated myocardial enzyme in the 67-year-old man^[10]. Coronary angiography showed that there was no significant coronary arterial stenosis in this case.

Ultrasound cardiology

Ultrasound cardiology (UCG) demonstrated pericardial effusion in 7 of 9 cases; mild in 2 cases^[6,12], moderate in 2 cases^[4,10], severe in 1 case^[9], and no presentation in 2 cases^[7,11]. The 53-year-old female was diagnosed with constructive pericarditis with pre-tamponade^[9].

Re-start and re-challenge test

The interferon treatment was restarted in three cases^[4,6,11]. The 28-year-old patient suffered a pericarditis relapse at

Table 1 Case reports of pericarditis associated with interferon

Ref.	Age/gender	Disease	Administered	Duration of IFN therapy	Mechanism
Fava <i>et al</i> ^[4]	28/NA	CML	IFN α	13 mo	NA
Boonen <i>et al</i> ^[5]	24/F	CHC	IFN α	1 mo	Autoimmune
Wisniewski <i>et al</i> ^[6]	42/F	CHC	IFN α	6 h	Cardio toxicity
Gressens <i>et al</i> ^[7]	40/F	CHC	IFN α 2b	3 mo	Cardio toxicity
Benjamini <i>et al</i> ^[8]	63/M	MM	IFN α 2b	1 mo	Cardio toxicity
Hamdani <i>et al</i> ^[9]	53/F	CHC	PEG IFN α 2a	6 mo	NA
Nishio <i>et al</i> ^[10]	67/M	CHC	PEG IFN 2a	15 d	Lupus like syndrome
Popescu <i>et al</i> ^[11]	38/F	CHC	PEG IFN 2a	7 mo	Cardio toxicity
Ashraf <i>et al</i> ^[12]	39/F	MM	IFN α	1 d	NA

CHC: Chronic hepatitis C; CML: Chronic myelogenous leukemia; F: Female; IFN: Interferon; M: Male; MM: Malignant melanoma; NA: Data not available; PEG IFN: Pegylated interferon.

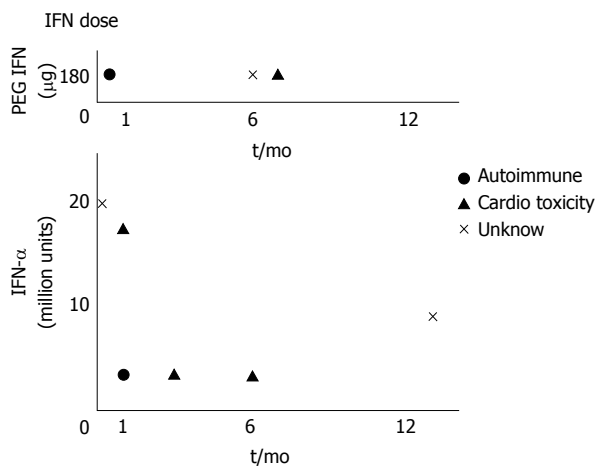


Figure 1 The relationship between interferon dose and duration of interferon therapy. PEG IFN: Pegylated interferon.

seven months after resumption of interferon α therapy^[4]. The 42-year-old female felt chest pain, after 7 h from administration of 1 million interferon α ^[6]. After the first dose of interferon administration symptoms reappeared and UCG showed an increase of pericardial fluid in the 38-year-old female^[11]. Re-challenge test was performed in one case^[12]. Within ten hours of the re-initiation of interferon therapy, the 39-year-old woman developed chest pain identical to her previous pain.

Complications

Two cases developed other complications. An electro-myography showed signs of polyneuropathy in the 40-year-old female^[7]. The 67-year-old man developed chronic inflammatory demyelinating polyneuropathy during treatment with pegylated interferon-2a for chronic active hepatitis C viral infection^[10].

Treatment

Treatment of drug-induced cardio toxicity rests mainly on early recognition and drug discontinuation. Interferon treatment was stopped in 7 of 9 cases. Four of 9 cases were treated with prednisone from 10 mg per day to 50 mg/d^[4,5,8,10] and 4 with nonsteroidal anti-inflammatory drugs (NSAIDs)^[5,7,11,12]. All of the AI group was treated with

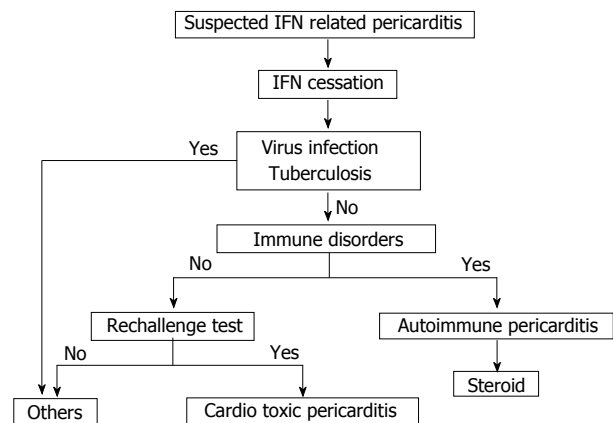


Figure 2 Algorithm of diagnoses and treatments for interferon related pericarditis. IFN: Interferon.

prednisone^[5,10] and two of the CT group were treated with NSAIDs^[7,11] and one of the CT group dexamethasone^[8]. The 53-year-old female was treated with medications of anti-tuberculosis, but died because multiple organ failure^[9]. Figure 2 showed an algorithm of the suspected interferon related pericarditis management.

DISCUSSION

Cardiac adverse effects of interferon α for CHC have been demonstrated^[1,2]. Most frequently reported are arrhythmias, congestive heart failure and sudden death. These side effects occurred during treatment with interferon α . However, pericarditis as a side effect of treatment with interferon is rare.

In 1988, the first report concerning interferon related pericarditis was presented by anonymity^[13]. This report demonstrated two patients with continuous interferon therapy for chronic myelogenous leukemia had severe side effects consisting of pleural effusions and pericarditis. Montastruc *et al*^[14] presented that there was an isolated pericarditis for which it was necessary to interrupt the interferon α treatment. However, these two articles didn't describe in detail. Consequently, 9 articles were enrolled in the present study. Two mechanisms for pericarditis were demonstrated, one is autoimmune in 2 articles and

the other is cardio toxicity in 4 articles. Three of 9 articles didn't mention the mechanisms for pericarditis.

Prospective study reported on autoimmune phenomena in 987 patients treated with interferon for CHC. Twelve patients developed hyperthyroidism, 6 hypothyroidism, 3 interstitial pneumonia, 1 SLE, 2 rheumatoid arthritis, 2 autoimmune hepatitis and 1 autoimmune thrombocytopenic purpura^[15]. In the present study, the appearance of lupus-like syndrome by the interferon treatment has been reported in 1 article and autoimmune in 1 article. The mechanism by which interferon α induces autoimmune mediated complications is largely unknown. However, interferon alpha induces numerous target genes in antigen-presenting cells (APCs), such that APCs are stimulated and enhance humoral autoimmunity, promote isotype switching, and potentially activate autoreactive T cells. Moreover, interferon alpha can synergistically amplify T cell autoreactivity by directly promoting T-cell activation and keeping activated T cells alive. *Via* the latter mechanisms, interferon can trigger autoimmune diseases^[16]. There is a possibility that interferon may damage endothelial cells, cause the thickening of capillary walls, and induce deposition of immune complexes. Interferon evokes the release of several cytokines, including tumor necrosis factor alpha, and interleukins 2, 6 and 1, affecting autonomic sympathetic nerve activity and vasopressor responses^[17]. Interferon induces an autoimmune reaction through various mechanisms including production of gamma globulins and interleukin-6 (IL-6)^[18] and inhibition of Allo-specific suppressor T lymphocytes, as well as activation of natural killer cells^[19]. IL-6 was significantly increased in pericardial effusion^[20]. Interferon has been associated with exacerbation or induction of a wide variety of clinical and serological immune disorders, including systemic lupus erythematosus, rheumatoid arthritis, autoimmune hepatitis, thyroid disease and diabetes mellitus. On the other hand, Orságová *et al.*^[21] demonstrated that positivity of antinuclear antibodies and smooth muscle antibodies or increased rheumatoid factor and circulating immune complexes are often found in patients with chronic hepatitis B and CHC treated with interferon, but their presence does not correlate with the development of autoimmune diseases.

The cardiac toxicity of interferon alpha is also well known and uncommon. The mechanism of interferon cardio toxicity is unclear and probably multifactorial. There are no established predisposing factors for interferon cardio toxicity. The secondary effects of interferon described include arrhythmia (atrial fibrillation, sinus bradycardia, atrioventricular block), ischemic cardiomyopathy and cardiomyopathy with the dosage levels used in the treatment of hepatitis C^[2]. Myocardial ischemia is mainly caused by cardio toxicity of interferon and antimetabolites^[22]. Patients with previous heart disease are probably at higher risk for arrhythmia and ischemic manifestations^[1]. Concerning drug toxicity, there have been reported cases of acute pericarditis after the administration of: Hydralazine, procainamide, isoniazid, phenylbutazone, dantrolene, doxorubicin, and penicillin.

These situations are extremely rare. Sonnenblick *et al.*^[23] demonstrated that the cardiac effects of interferon were not related to the daily dose, cumulative total dose, or period of therapy and cardiac toxicity was reversible following the cessation of the drug therapy. Interferon inhibits cardiac cell function *in vitro*^[24].

The Naranjo adverse drug reactions (ADR) Probability Scale^[25] is a validated tool used to determine the likelihood that the adverse drug reaction is caused by the implicated medication. The Naranjo algorithm requires a series of questions to be answered and scored. The total calculated score indicates the likelihood of causing an adverse drug reaction. Popescu *et al.*^[11] used the Naranjo ADR Probability Scale to evaluate the correlation of pericarditis with interferon administration. This scale indicated a very probable association.

Treatment of interferon-induced cardio toxicity rests mainly on early recognition and drug discontinuation. There is a high degree of individual variation in toxicity, but most adverse events are reversible upon cessation of the drug^[8]. In the present study, 4 of 9 patients were treated with prednisone and 4 with NSAIDs.

Chronic hepatitis C viral (HCV) infection and treatment with interferon are both associated with serological and clinical autoimmune manifestations^[26,27]. The serological immune response to HCV infection may include the development of cryoglobulinemia, rheumatoid factor, anti-cardiolipin, antinuclear, anti-liver-kidney-microsome 1 and anti-smooth muscle antibodies. Serological autoimmune manifestations were explained by the lymphotropism of HCV and the polyclonal activation of B cells. Interferon-based treatment of HCV infection may precipitate or exacerbate the associated autoimmune disease. Classically, type II Cryoglobulinaemia, glomerulonephritis and thyroiditis are described.

Interferon related pericarditis still remains uncertain. There may be two mechanisms for pericarditis, one is autoimmune and the other is cardio toxicity. Treatment of interferon related pericarditis rests mainly on early recognition and drug discontinuation. Interferon related pericarditis was treated with steroid and/or NSAIDs.

COMMENTS

Background

When the authors examine a new unusual patient that the authors have never treated before, the authors need to research previous case reports. However, the case report is individual. The authors need to know what kind of examinations they need and what kind of treatments they need as soon as possible. This manuscript aimed to summarize those previous case reports concerning interferon related pericarditis.

Research frontiers

There may be two mechanisms for interferon related pericarditis, one is autoimmune and the other is cardio toxicity. Treatment of interferon related pericarditis rests mainly on early recognition and drug discontinuation. Interferon related pericarditis was treated with steroid and/or nonsteroidal anti-inflammatory drugs.

Innovations and breakthroughs

This is the first article that was summarized interferon related pericarditis.

Applications

Readers will understand the previous case reports concerning interferon related pericarditis in a short time.

Terminology

Interferon related pericarditis is one of the side effects of interferon treatment.

Peer-review

In the current manuscript, the authors reviewed the 9 published interferon-related pericarditis cases. This interferon regimen complication is rare and this review is helpful to understand this rare complication.

REFERENCES

- Mansat-Krzyzanowska E, Dréno B, Chiffolleau A, Litoux P. [Cardiovascular manifestations associated with interferon alfa-2A]. *Ann Med Interne* (Paris) 1991; **142**: 576-581 [PMID: 1807177]
- Teragawa H, Hondo T, Amano H, Hino F, Ohbayashi M. Adverse effects of interferon on the cardiovascular system in patients with chronic hepatitis C. *Jpn Heart J* 1996; **37**: 905-915 [PMID: 9057685 DOI: 10.1536/ihj.37.905]
- Georg M, Walker B. Hepatitis C virus infection. *N Engl J Med* 2001; **345**: 41-52 [DOI 10.1056/NEJM200107053450107]
- Fava S, Luoni M, Stioui S. Pericarditis during interferon-alpha therapy in chronic myelogenous leukemia. *Haematologica* 1996; **81**: 484 [PMID: 8952166]
- Boonen A, Stockbrügger RW, van der Linden S. Pericarditis after therapy with interferon-alpha for chronic hepatitis C. *Clin Rheumatol* 1999; **18**: 177-179 [PMID: 10357129 DOI: 10.1007/s100670050081]
- Wisniewski B, Denis J, Fischer D, Labayle D. [Pericarditis secondary to interferon alpha in chronic hepatitis C]. *Gastroenterol Clin Biol* 2004; **28**: 315-316 [PMID: 15094688 DOI: 10.1016/S0399-8320(04)94929-9]
- Gressens B, Gohy P. Pericarditis due to interferon-alpha therapy during treatment for chronic hepatitis C. *Acta Gastroenterol Belg* 2004; **67**: 301-302 [PMID: 15587340]
- Benjamini O, Kimhi O, Lishner M. Severe pleuropericarditis and cardiomyopathy induced by high dose interferon alpha-2b. *Isr Med Assoc J* 2007; **9**: 486-7 [PMID: 17642403]
- Hamdani I, Kochlef A, Belhadj N, Kharrat J, Ghorbel A. [Acute pericardite which has occurred during the treatment of chronic hepatitis C by the interferon alpha2A]. *Tunis Med* 2008; **86**: 404-405 [PMID: 19476158]
- Nishio K, Konndo T, Okada S, Enchi M. Pericarditis and chronic inflammatory demyelinating polyneuropathy during therapy with pegylated interferon alfa-2a for chronic hepatitis C. *World J Hepatol* 2010; **2**: 358-361 [PMID: 21161021 DOI: 10.4254/wjh.v2.i9.358]
- Popescu C, Arama V, Gliga S. Acute pericarditis due to pegylated interferon alpha therapy for chronic HCV hepatitis - case report. *BMC Gastroenterol* 2011; **11**: 30 [PMID: 21453456 DOI: 10.1186/1471-230X-11-30]
- Ashraf F, Marmoush F, Shafi MI, Shah A. Recurrent Pericarditis, an Unexpected Effect of Adjuvant Interferon Chemotherapy for Malignant Melanoma. *Case Rep Cardiol* 2016; **2016**: 1342028 [PMID: 27418981 DOI: 10.1155/2016/1342028]
- Interferon in CML. *Br J Hospital Med* 1988; **1**: 77
- Montastruc M, Reiffers J, Bilhou-Nabera C. Recombinant interferon alpha (IFN) as initial treatment for chronic myelogenous leukemia (CML). *Journal Chronic Myeloid Leukemia*, 2nd International Conference, Bologna 1992: 103
- Okanoue T, Sakamoto S, Itoh Y, Minami M, Yasui K, Sakamoto M, Nishioji K, Katagishi T, Nakagawa Y, Tada H, Sawa Y, Mizuno M, Kagawa K, Kashima K. Side effects of high-dose interferon therapy for chronic hepatitis C. *J Hepatol* 1996; **25**: 283-291 [PMID: 8895006 DOI: 10.1016/S0168-8278(96)80113-9]
- Silva MO. Risk of autoimmune complications associated with interferon therapy. *Gastroenterol Hepatol* (N Y) 2012; **8**: 540-542 [PMID: 23293568]
- Takahashi H, Nishimura M, Sakamoto M, Ikegaki I, Nakanishi T, Yoshimura M. Effects of interleukin-1 beta on blood pressure, sympathetic nerve activity, and pituitary endocrine functions in anesthetized rats. *Am J Hypertens* 1992; **5**: 224-229 [PMID: 1318054 DOI: 10.1093/ajh/5.4.224]
- Itoh Y, Okanoue T, Enryo F, Morimoto M, Takeuchi T, Kagawa K, Kashima K. Elevated interleukin-6 and gamma-globulin during interferon therapy of hepatitis B. *Am J Gastroenterol* 1992; **87**: 1485-1487 [PMID: 1384310]
- Edwards BS, Merritt JA, Fuhlbrigge RC, Borden EC. Low doses of interferon alpha result in more effective clinical natural killer cell activation. *J Clin Invest* 1985; **75**: 1908-1913 [PMID: 4008643 DOI: 10.1172/JCI111905]
- Ristić AD, Pankuweit S, Maksimović R, Moosdorf R, Maisch B. Pericardial cytokines in neoplastic, autoreactive, and viral pericarditis. *Heart Fail Rev* 2013; **18**: 345-353 [PMID: 22850905 DOI: 10.1007/s10741-012-9334-y]
- Orságová I, Rožnovský L, Petroušová L, Konečná M, Kabieszová L, Martinek J, Kloudová A, Pavlísk L. [Investigation of autoimmunity markers during interferon alpha therapy of chronic hepatitis B and C - twenty years of experience]. *Klin Mikrobiol Infekc Lek* 2016; **22**: 61-67 [PMID: 27450524]
- Castel M, Despas F, Modesto A, Gales C, Honton B, Galinier M, Senard JM, Pathak A. [Cardiotoxicity of chemotherapies]. *Presse Med* 2013; **42**: 26-39 [PMID: 22727981 DOI: 10.1016/j.lpm.2012.04.014]
- Sonnenblick M, Rosin A. Cardiotoxicity of interferon. A review of 44 cases. *Chest* 1991; **99**: 557-561 [PMID: 1704826 DOI: 10.1378/chest.99.3.557]
- Lampidis TJ, Brouty-Boyd D. Interferon inhibits cardiac cell function in vitro. *Proc Soc Exp Biol Med* 1981; **166**: 181-185 [PMID: 6163151 DOI: 10.3181/00379727-166-41043]
- Naranjo CA, Busto U, Sellers EM, Sandor P, Ruiz I, Roberts EA, Janacek E, Domecq C, Greenblatt DJ. A method for estimating the probability of adverse drug reactions. *Clin Pharmacol Ther* 1981; **30**: 239-245 [PMID: 7249508 DOI: 10.1038/clpt.1981.154]
- Pawlotsky JM, Ben Yahia M, Andre C, Voisin MC, Intrator L, Roudot-Thoraval F, Deforges L, Duvoux C, Zafrani ES, Duval J. Immunological disorders in C virus chronic active hepatitis: a prospective case-control study. *Hepatology* 1994; **19**: 841-848 [PMID: 8138255 DOI: 10.1002/hep.1840190407]
- Pawlotsky JM, Roudot-Thoraval F, Simmonds P, Mellor J, Ben Yahia MB, André C, Voisin MC, Intrator L, Zafrani ES, Duval J, Dhumeaux D. Extrahepatic immunologic manifestations in chronic hepatitis C and hepatitis C virus serotypes. *Ann Intern Med* 1995; **122**: 169-173 [PMID: 7810933 DOI: 10.7326/0003-4819-122-3-19950210-00002]

P- Reviewer: Jin B, Kettering K S- Editor: Song XX L- Editor: A
E- Editor: Li D





Published by **Baishideng Publishing Group Inc**
7901 Stoneridge Drive, Suite 501, Pleasanton, CA 94588, USA
Telephone: +1-925-223-8242
Fax: +1-925-223-8243
E-mail: bpgoffice@wjgnet.com
Help Desk: <http://www.f6publishing.com/helpdesk>
<http://www.wjgnet.com>

